

Malabsorption syndromes



Dr. Ban Adil
MBChB, FICMS, MRCPCh



Malabsorption syndromes:

are conditions that affect the digestion or the absorption of nutrients.

Clinical feature

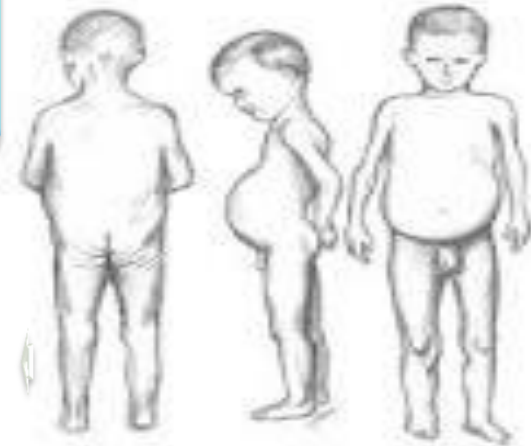
Diarrhea

- acidic
- Watery
- Steatorrhea (pale, foul-smelling, bulky stools
- absence of diarrhea do not exclude malabsorption

abdominal distention

failure to gain weight

fall in growth chart percentiles.



CLASSIFICATION :

BASED ON THE PREDOMINANT NUTRIENT WHICH IS MALABSORBED

CARBOHYDRATE MALABSORPTION

- Lactose malabsorption
- Congenital lactase deficiency
- Secondary lactase deficiency
- Glucose galactose malabsorption

FAT MALABSORPTION

- Cystic fibrosis
- Shwachman-Diamond syndrome
- Abetalipoproteinemia

AMINO ACID MALABSORPTION

- Enterokinase deficiency

MINERAL AND VITAMIN MALABSORPTION

- Congenital chloride diarrhea
- Acrodermatitis enteropathica (zinc malabsorption)
- Menke disease (copper malabsorption)
- Vitamin D-dependent rickets.
- Folate malabsorption
- Secondary to mucosal damage (celiac disease)
- Vitamin B₁₂ malabsorption
- Terminal ileal disease (e.g., Crohn disease) or resection

DRUG INDUCED

- Sulfasalazine:folic acid malabsorption
- Phenytoin:calcium malabsorption

CLINICAL APPROACH TO A CHILD WITH SUSPECTED MALABSORPTION



History:

Onset:

- In congenital chloride diarrhea and microvillus inclusion disease, the stool is watery since birth and can be mistaken for urine.
- Onset of symptoms after introduction of a particular food into a child's diet may provide diagnostic clues, such as seen with gluten in gluten-sensitive enteropathy

Nature :

- explosive watery diarrhea suggests carbohydrate malabsorption;
- loose, bulky stools are associated with celiac disease; and
- pasty and yellowish offensive stool suggests an exocrine pancreatic insufficiency.

Stool color is usually not helpful; green stool with undigested “peas and carrots” may suggest rapid intestinal transit in toddler's diarrhea.

Dietary history A common example is the child with chronic, nonspecific diarrhea (toddler's diarrhea) generally presents in well-appearing toddlers between 1 and 3 yr of age (toddler's diarrhea). The diarrhea is often brown and watery, at times containing undigested food particles. If the child's fluid intake is >150 mL/kg/24 hr, fluid intake should be reduced to no more than 90 mL/kg/24 hr.

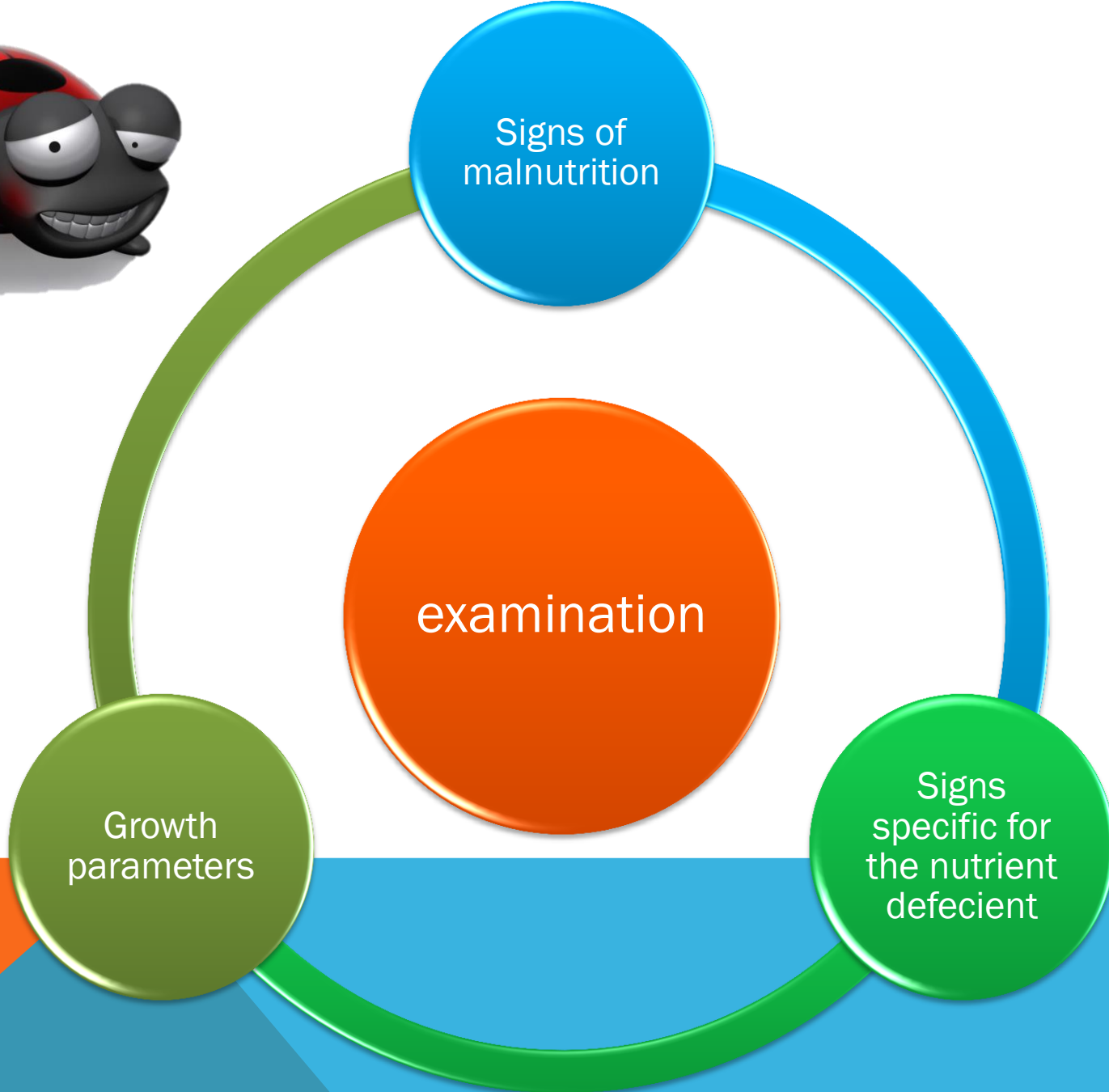
- **Appetite**

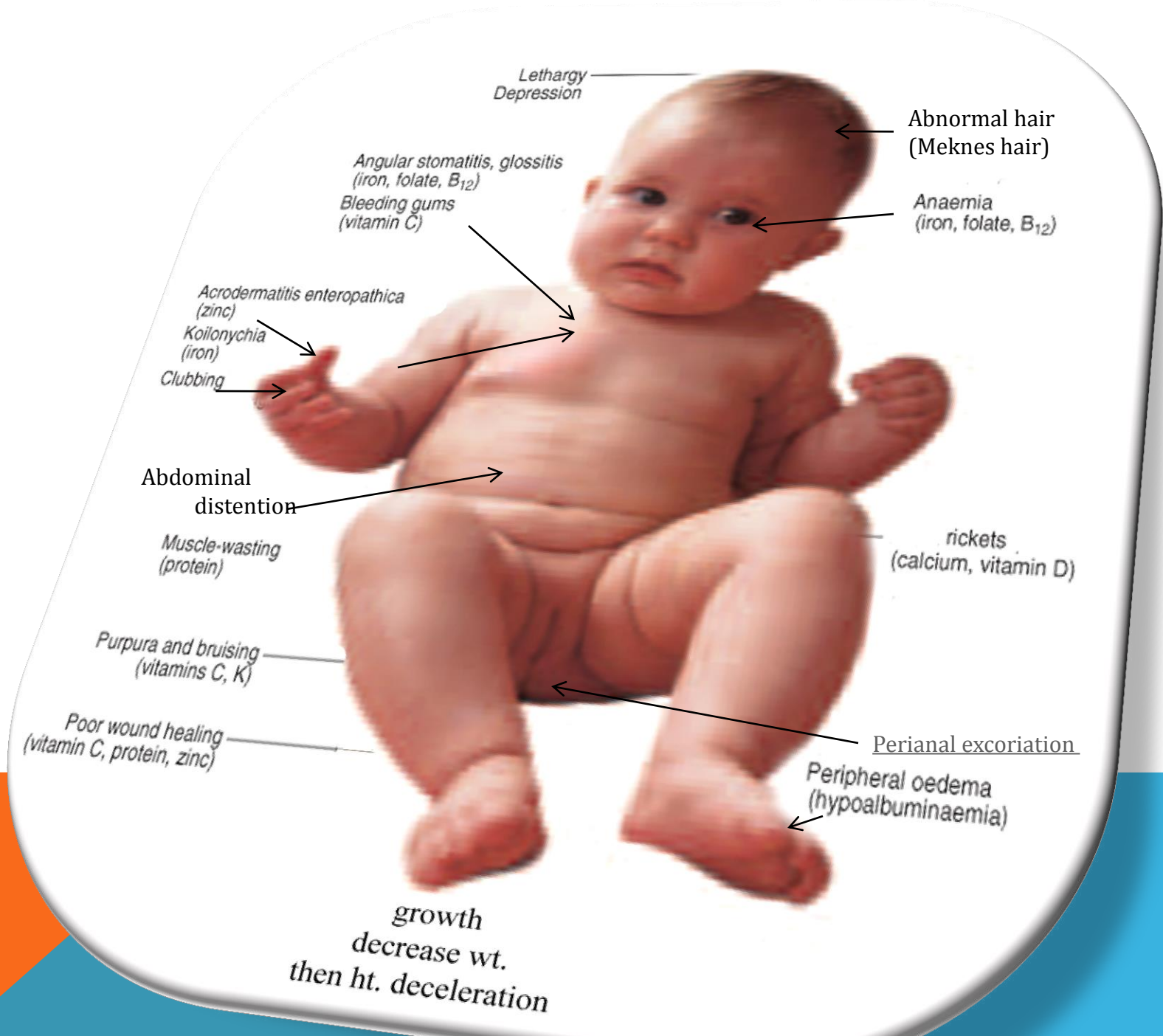very good appetites(voracious) as in exocrine pancreatic insufficiency(cystic fibrosis)

anorexia →celiac disease

Food avoidance →CHO malabsorption due to abdominal distension &abdominal pain.

Change in weight, then ↓ht. the OFC will be compromised when malnutrition become chronic.





Lethargy
Depression

Abnormal hair
(Meknes hair)

Angular stomatitis, glossitis
(iron, folate, B₁₂)
Bleeding gums
(vitamin C)

Anaemia
(iron, folate, B₁₂)

Acrodermatitis enteropathica
(zinc)
Koilonychia
(iron)
Clubbing

Abdominal
distention

Muscle-wasting
(protein)

rickets
(calcium, vitamin D)

Purpura and bruising
(vitamins C, K)

Poor wound healing
(vitamin C, protein, zinc)

Perianal excoriation

Peripheral oedema
(hypoalbuminaemia)

growth
decrease wt.
then ht. deceleration

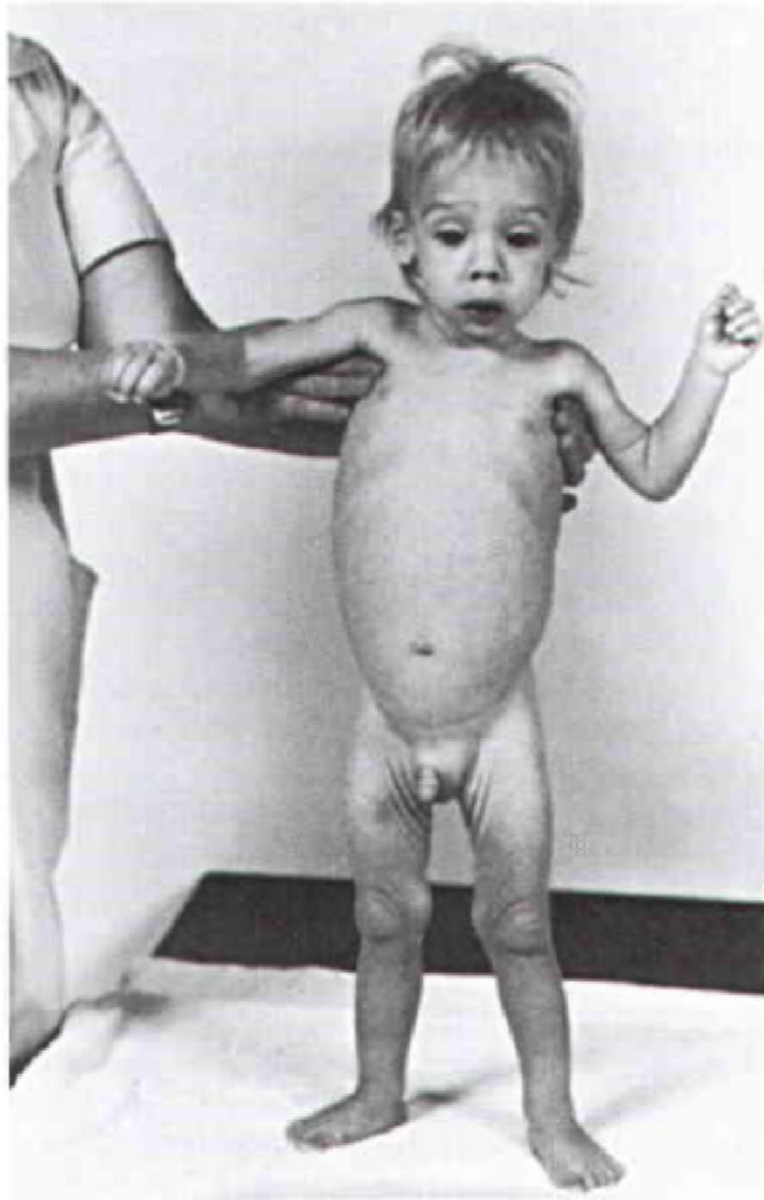

Figure 335-1. An 18-mo-old boy with active celiac disease. Note the loose skinfolds, marked proximal muscle wasting, and full abdomen. The child looks ill.

PHYSICAL FINDINGS:

- **signs of malnutrition:** include the disappearance of the subcutaneous fat, muscle wasting, and the appearance of skin being too loose for the child .
- **Specific findings may guide toward a particular disorder;**
- *edema* → protein-losing enteropathy,
- *digital clubbing* → cystic fibrosis and celiac disease,
- *perianal excoriation* and *gaseous abdominal* distention → carbohydrate malabsorption,
- *perianal and circumoral rash* → acrodermatitis enteropathica,
- abnormal hair → Menkes syndrome
- Long-term *calcium* and *vitamin D* malabsorption can lead to reduced bone mineral density and metabolic bone disease with increased risk of bone fractures.
- *Vitamin K* malabsorption, irrespective of the underlying mechanism (fat malabsorption, mucosal atrophy), can result in coagulopathy.
- Other nutrient deficiencies include *iron malabsorption* causing microcytic anemia and low reticulocyte count,
- low serum *folate* levels in conditions associated with mucosal atrophy,
- and low serum vitamin A and vitamin E concentration in fat malabsorption.

Investigation

stool examination

- stool occult blood and leukocytes to exclude inflammatory disorders,
- stool microscopy and antibody tests for parasites such as *Giardia*,
- stool pH and reducing substance for carbohydrate malabsorption, and
- quantitative stool fat examination to identify fat malabsorption.

A complete blood count

- peripheral smear for microcytic anemia,
- Macrocytic anemia → folate & B12
- lymphopenia (lymphangiectasia),
- neutropenia (Shwachman syndrome),
- and acanthocytosis (abetalipoproteinemia) is useful.

S.albumin.

- Depending on the initial investigation results, more specific investigations can be planned.

a microscopic examination of stool for fat:

mixing a small amount of stool with several drops of water or Sudan red stain. Fat droplets separate and can be easily identified, especially with a Sudan III stain. The presence of more than six to eight droplets per low-power field is abnormal.

Fat
malabsorption

A positive test should be confirmed with a **72-hr quantitative fecal fat test**, which remains the gold standard for assessing steatorrhea. Excretion of more than 7% of the total fat intake is abnormal and suggests the presence of malabsorption.

CARBOHYDRATE MALABSORPTION

Clinitest reagent for reducing substances is a simple screening test and can be performed at the bedside. The test is easily performed by combining 10 drops of water with 5 drops of stool and then adding a Clinitest tablet. The color change can be quantified as trace to 4+ using a color sheet provided by the manufacturer. Only 2+ or higher should raise the possibility of sugar malabsorption. Sucrose is not a reducing sugar and requires hydrolysis with hydrochloric acid before analysis.

Stool pH, obtained easily with pH paper, lower than 5.6 is also suggestive of carbohydrate malabsorption.



The **breath hydrogen test** can also be used to evaluate carbohydrate malabsorption. The gas produced by bacterial degradation of carbohydrates is largely absorbed in the colon, enters the portal and systemic venous return, goes to the lung, and is then released in the breath

PROTEIN MALABSORPTION

Protein loss cannot be evaluated directly because bacterial protein accounts for such a large proportion of the stool nitrogen.



Measurement of **spot stool α 1 -antitrypsin** levels is helpful in establishing a diagnosis of protein-losing enteropathy. This serum protein is resistant to digestion and therefore can be measured in stool in contrast to albumin.

GLUTEN-SENSITIVE ENTEROPATHY (CELIAC DISEASE)

-  Celiac disease is an immune-mediated enteropathy caused by permanent sensitivity to gluten in genetically susceptible individuals which lead to mucosal damage.
-  It is now estimated that the frequency of celiac disease in the United States is around 1:300



PATHOGENESIS.


-  Celiac disease develops only after dietary exposure to the protein gluten, which is found in wheat, rye, oat and barley.
-  The activity of gluten resides in the gliadin fraction



PATHOGENESIS:

A genetic predisposition

- monozygotic twins approaching 100%.
- Two to 5% of first-degree relatives have symptomatic gluten-sensitive enteropathy

 Individuals with **HLA-DQ2 and –DQ8** tissue type are at higher risk.

Celiac disease occurs at a higher frequency in children with

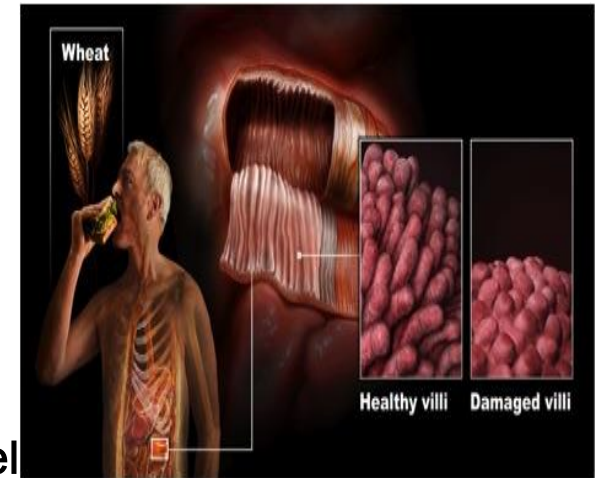
- type 1 diabetes and is 50 times more common
- Down syndrome.
- selective IgA deficiency.
- Turner syndrome,
- thyroiditis.

 **Environmental factors** such as viruses may also play a role

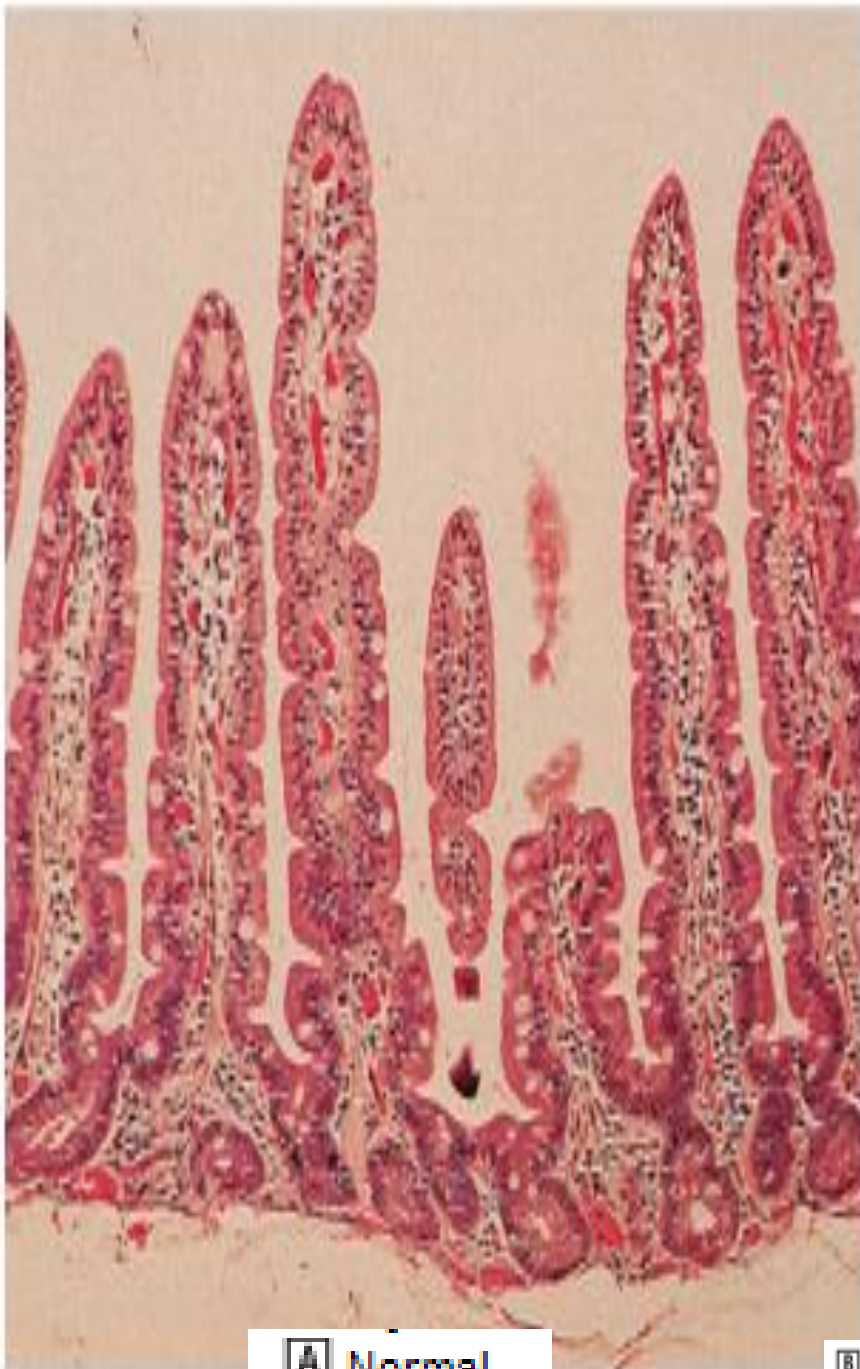


The inflammatory response results in :

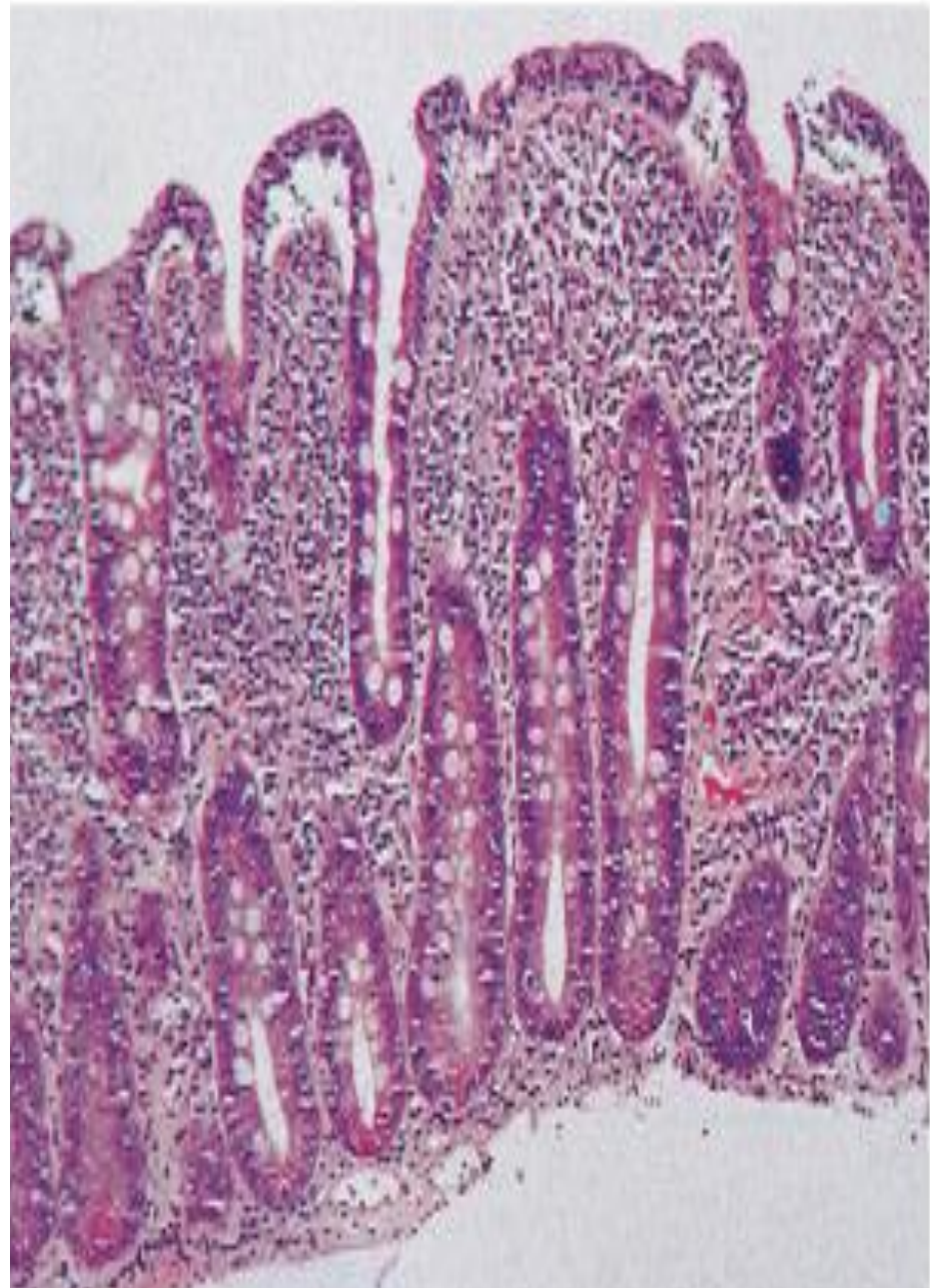
- Total or subtotal villus atrophy,
- crypt hyperplasia,
- increased number of intraepithelial lymphocytes,
- damage to the surface epithelium in the small bowel
- The injury is greatest in the proximal small bowel and extends distally for a variable distance.



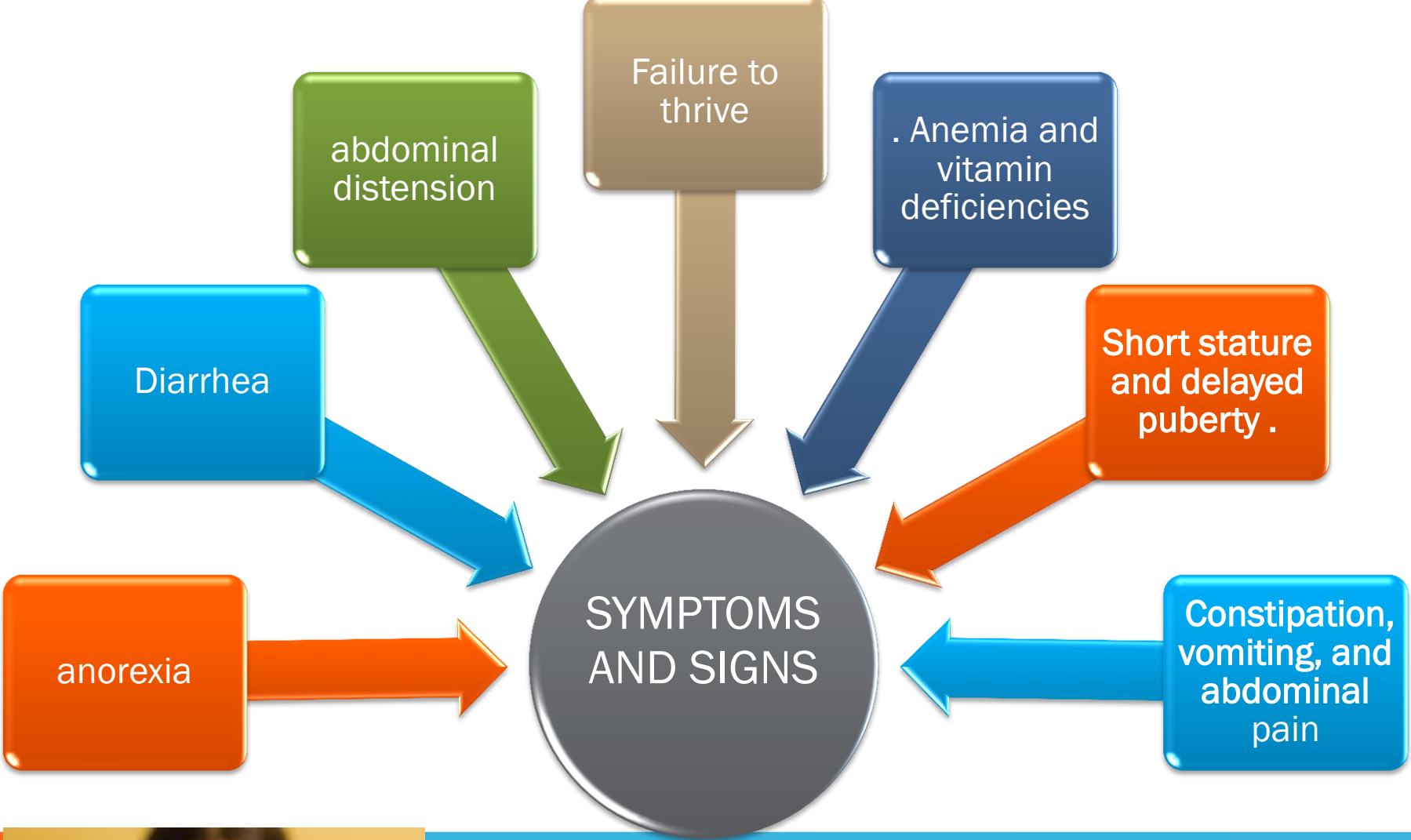A



A Normal.

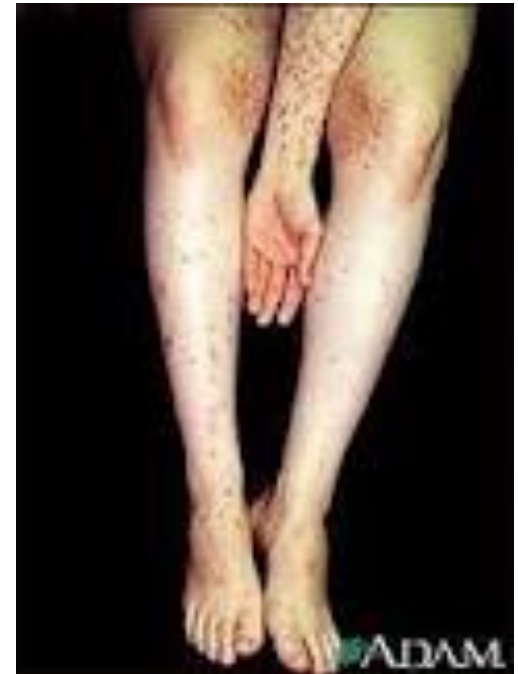

B Jejunum in coeliac disease showing subtotal villous atrophy and marked inflammatory infiltrate.



NONGASTROINTESTINAL MANIFESTATIONS OF CELIAC DISEASE

1. Dermatitis herpetiformis
2. Dental enamel hypoplasia
3. Osteopenia/osteoporosis
4. Short stature
5. Delayed puberty
6. Anemia (nonresponsive to iron therapy, seen in adults only)
7. Hepatitis
8. Arthritis
9. Brain calcifications
10. Neurologic symptoms

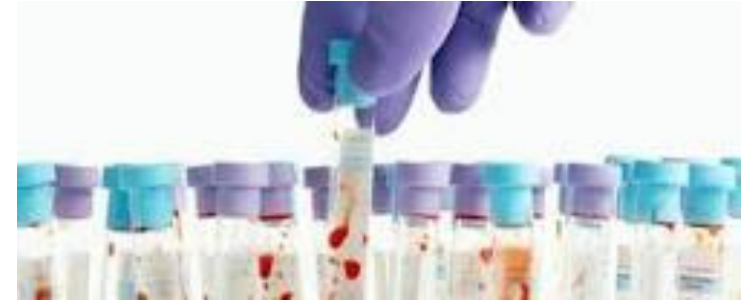

LABORATORY FINDINGS

1. increase Fat content of stools—A 3-day collection of stools usually reveals excessive fecal fat.
2. Impaired carbohydrate absorption
3. Hypoproteinemia —Hypoalbuminemia



SEROLOGIC TESTS



- **Antigliadin and antireticulin** antibodies are often present in celiac disease. However, there is a 10% false-positive rate for the IgG antigliadin antibody among healthy individuals.
- **Endomysial or tissue transglutaminase antibody** assays are the most sensitive and specific screening tests for celiac disease. As both of these antibodies are of the IgA class, screening for them in a patient who is IgA deficient may yield a falsely negative screen result.
- The best available serologic screening test, therefore, is a quantitative IgA level with a transglutaminase or endomysial antibody assay.

GENETIC TESTS

have an increasing role in the diagnosis

- Less than 2% of celiac patients lack both HLA specificities;
- at the same time, approximately one third of the “normal” population has one or the other marker;
- that means that the measurement of HLA DQ2 and/or DQ8 has a strong negative predictive value but a very weak positive predictive value for the diagnosis of celiac disease.
- With these limitations the test can prove useful to exclude celiac disease when the genetic studies are negative in subjects on a gluten-free diet or in subjects belonging to an at-risk group (e.g., 1st-degree relatives, insulin-dependent diabetics, patients with Down syndrome) to avoid long-term follow-up.

D. BIOPSY FINDINGS

- Total or subtotal villus atrophy,
- crypt hyperplasia,
- increased number of intraepithelial lymphocytes,
- damage to the surface epithelium in the small bowel.



The ultimate diagnosis of celiac disease relies on the demonstration of specific, though not pathognomonic, histopathologic abnormalities in the small bowel mucosa .

According to The European Society for Pediatric Gastroenterology, Hepatology and Nutrition (ESPGHAN) current criteria

- , the 2 requirements mandatory for the diagnosis of celiac disease are:
- the finding of villous atrophy with hyperplasia of the crypts and abnormal surface epithelium, while the patient is eating adequate amounts of gluten,
- and a full clinical remission after withdrawal of gluten from the diet.

The finding of circulating IgA celiac disease–associated antibodies at the time of diagnosis and their disappearance on a gluten-free diet adds weight to the diagnosis.

A control biopsy to verify the consequences of the gluten-free diet on the mucosal architecture is considered mandatory only in patients with an equivocal clinical response to the diet.

Gluten challenge is not considered mandatory except in situations where there is doubt about the initial diagnosis, for example, when an initial biopsy was not performed or when the biopsy specimen was inadequate or atypical of celiac disease.



Treatment

A. DIET

Treatment consists of dietary gluten restriction for life. All sources of wheat, rye, barley, and oat gluten must be eliminated during the initial treatment.

Clinical improvement is usually evident within a week, and histologic repair is complete after 3–12 months.

Tissue transglutaminase titers may decrease on a gluten free diet, but usually do not disappear.

B. CORTICOSTEROIDS

are indicated only in very ill patients with signs and symptoms of celiac crisis (profound malnutrition, diarrhea, edema, abdominal distention, and hypokalemia).

PROGNOSIS

Clinical and histologic recovery is the rule but may be slow.

Malignant lymphoma of the small bowel occurs with increased frequency in adults with long-standing disease.

Dietary treatment seems to decrease the risk of this complication.



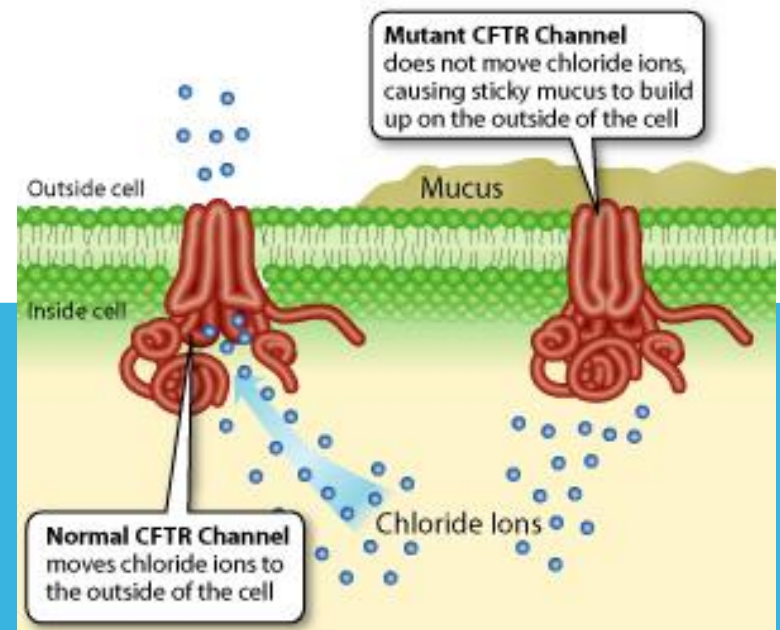
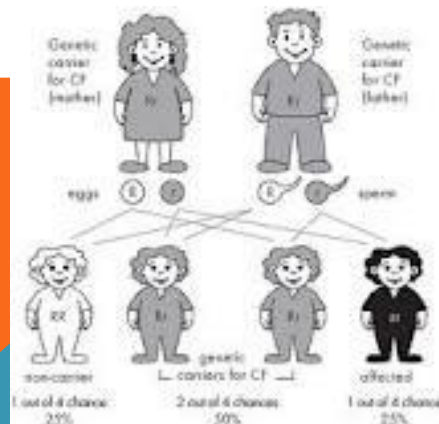
CYSTIC FIBROSIS

ETIOLOGY AND EPIDEMIOLOGY

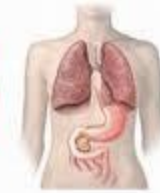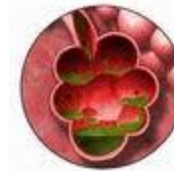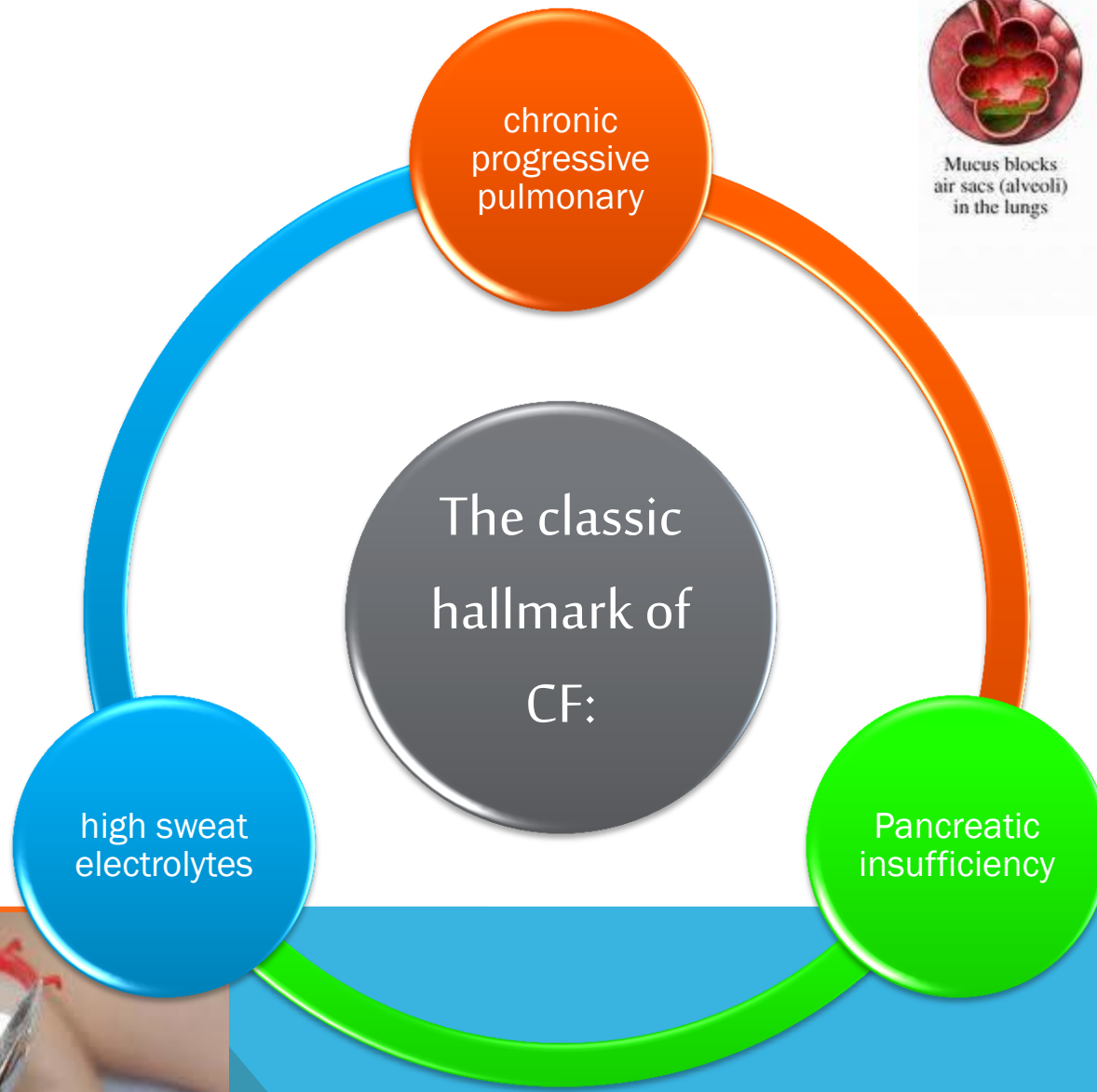
CF, an autosomal recessive disorder, In the U.S., 1 in 3200 white newborns is born with CF

The gene for CF, localized to the long arm of chromosome 7, termed cystic fibrosis transmembrane regulator (*CFTR*) The secretory and absorptive characteristics of epithelial cells are affected.

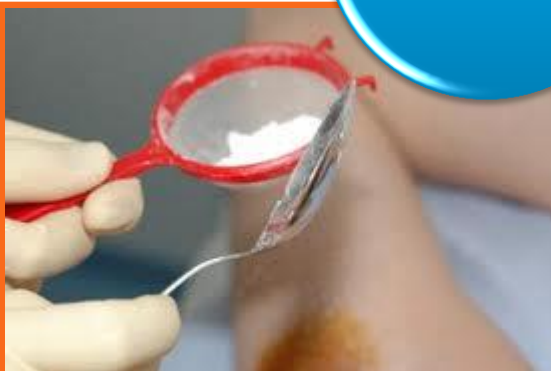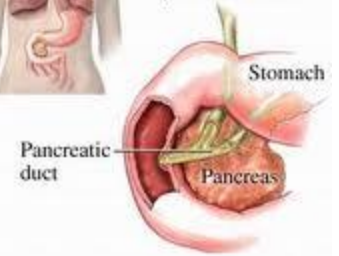
the respiratory epithelium exhibits marked impermeability to chloride and an excessive reabsorption of sodium. These lead to a relative dehydration of the airway secretions, resulting in impaired mucociliary transport and airway obstruction



THE CLASSIC HALLMARK OF CF:

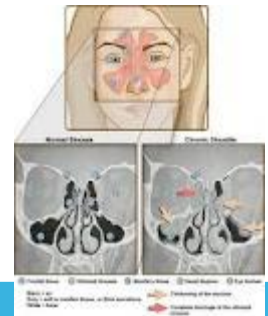
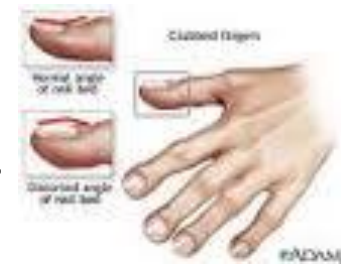
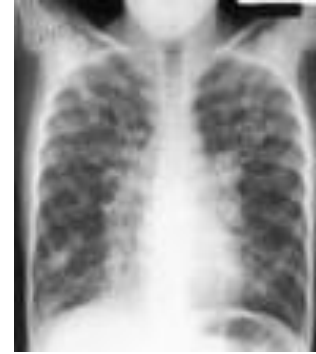
Mucus blocks pancreatic ducts







Chronic bronchial infection

- Most patients are colonized with *Haemophilus influenzae*, *Staphylococcus aureus*, or *Pseudomonas aeruginosa* or *Burkholderia cepacia*
- cough (the most common initial pulmonary manifestation), sputum production, hyperinflation, bronchiectasis, and pulmonary insufficiency and death.
- Digital clubbing is common, even without significant lung disease.
- Chronic sinusitis is nearly universal, and nasal polyposis is common.
- Other potential pulmonary complications of CF include atelectasis, progressive bronchiectasis, hemoptysis, and pneumothorax



PANCREATIC INSUFFICIENCY



-  Most patients with CF have exocrine pancreatic insufficiency early in life (if not at birth) as a result of **inspissation of mucus** in the pancreatic ducts.
-  Maldigestion with secondary malabsorption results in steatorrhea (large, fatty, floating, foul-smelling stools) and
-  many secondary deficiency states (vitamins A, D, E, and K) in untreated patients.
-  Nutrient malabsorption also results in failure to thrive despite a ravenous appetite.



In adolescent or adult patients, relative insulin deficiency may develop. Hyperglycemia and **CF-related diabetes** may become symptomatic; **ketoacidosis is rare**.

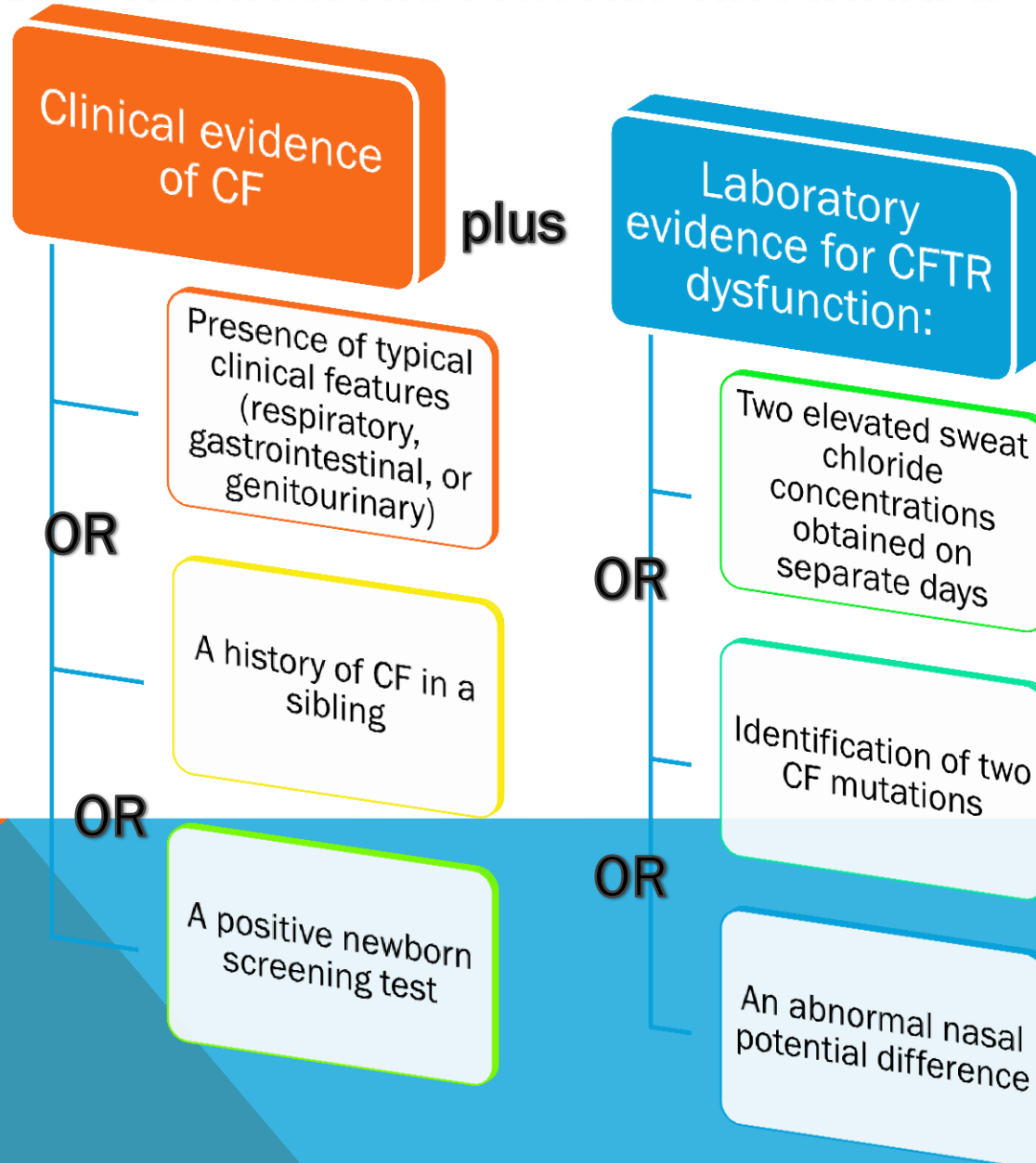



Secondary amenorrhea Women with CF have given birth, however...

Males are almost universally **azoospermic**, with atrophy or absence of the vas deferens.

The failure of the sweat ducts to conserve salt may lead to heat exhaustion or to unexplained **hypochloremic alkalosis** in infants.

DIAGNOSTIC CRITERIA FOR CYSTIC FIBROSIS (CF)





SWEAT TEST



The sweat test, which involves using pilocarpine iontophoresis to collect sweat and performing chemical analysis of its chloride content, is the standard approach to diagnosis of CF. The procedure requires care and accuracy. An electric current is used to carry pilocarpine into the skin of the forearm and locally stimulate the sweat glands. If an adequate amount of sweat is collected, the specimens are analyzed for chloride concentration. Testing may be difficult in the 1st 2 wk of life because of low sweat rates but is recommended any time after the 1st 48 hr of life. Positive results should be confirmed; for a negative result, the test should be repeated if suspicion of the diagnosis remains.

a positive result obtained from a sweat test on two or more occasions (positive if >60 mEq/L with adequate sweat collection of at least 75 mg,

borderline if 40 to 60 mEq/L, and

negative if <40 mEq/L

Non-CF conditions associated with elevated concentrations of sweat electrolytes(false +ve) include

- untreated adrenal insufficiency,
- ectodermal dysplasia,
- hereditary nephrogenic diabetes insipidus,
- hypothyroidism,
- hypoparathyroidism,
- familial cholestasis,
- pancreatitis,
- mucopolysaccharidoses, and
- malnutrition. Most of these conditions can be easily distinguished from CF by clinical criteria

False-negative test results may be encountered in children with hypoproteinemic edema.

TREATMENT :

Respiratory management

- 90% morbidity in CF is a result of chronic pulmonary sepsis and its complications
- Much of therapy is aimed at prevention of lung damage and early treatment of infection to minimize lung damage secondary to inflammation

Prevention of infection

- Prophylactic oral flucloxacillin against *Staphylococcus aureus* infection
- All regular immunizations
- Additional vaccine such as pneumovax and influenza; consider palivizumab for RSV protection
- Good infection control policy to prevent cross-infection

Physiotherapy

- Learnt at an early stage
- Multiple techniques that are adapted to patient age and severity of disease
- Reduces airways obstruction by improving clearance of secretions

- Decreases severity of infection by clearance of infected material
- Maintains respiratory function and exercise tolerance

Nutritional/gastrointestinal

- Direct link between pulmonary health and the patient's nutritional status
- Increased energy requirements due to increased demand and increased losses:
 - High-energy diet
- Malabsorption of fat:
 - > 90% patients require exocrine pancreatic supplements, e.g. Creon
 - Vitamin A, D and E supplements
- Close monitoring of weight, particularly in the younger child, to ensure growth and development:
 - Intervention with oral calorie supplements and use of enteral feeding via nasogastric tube or gastrostomy may be required in some patients

A classic movie title card for "The End". The text is written in a white, elegant, cursive script. The words "The" and "End" are stacked vertically, with a decorative flourish connecting them. The background is a dark, textured surface, possibly a stage curtain, with two large, draped red curtains framing the central text on the left and right sides.

*The
End*

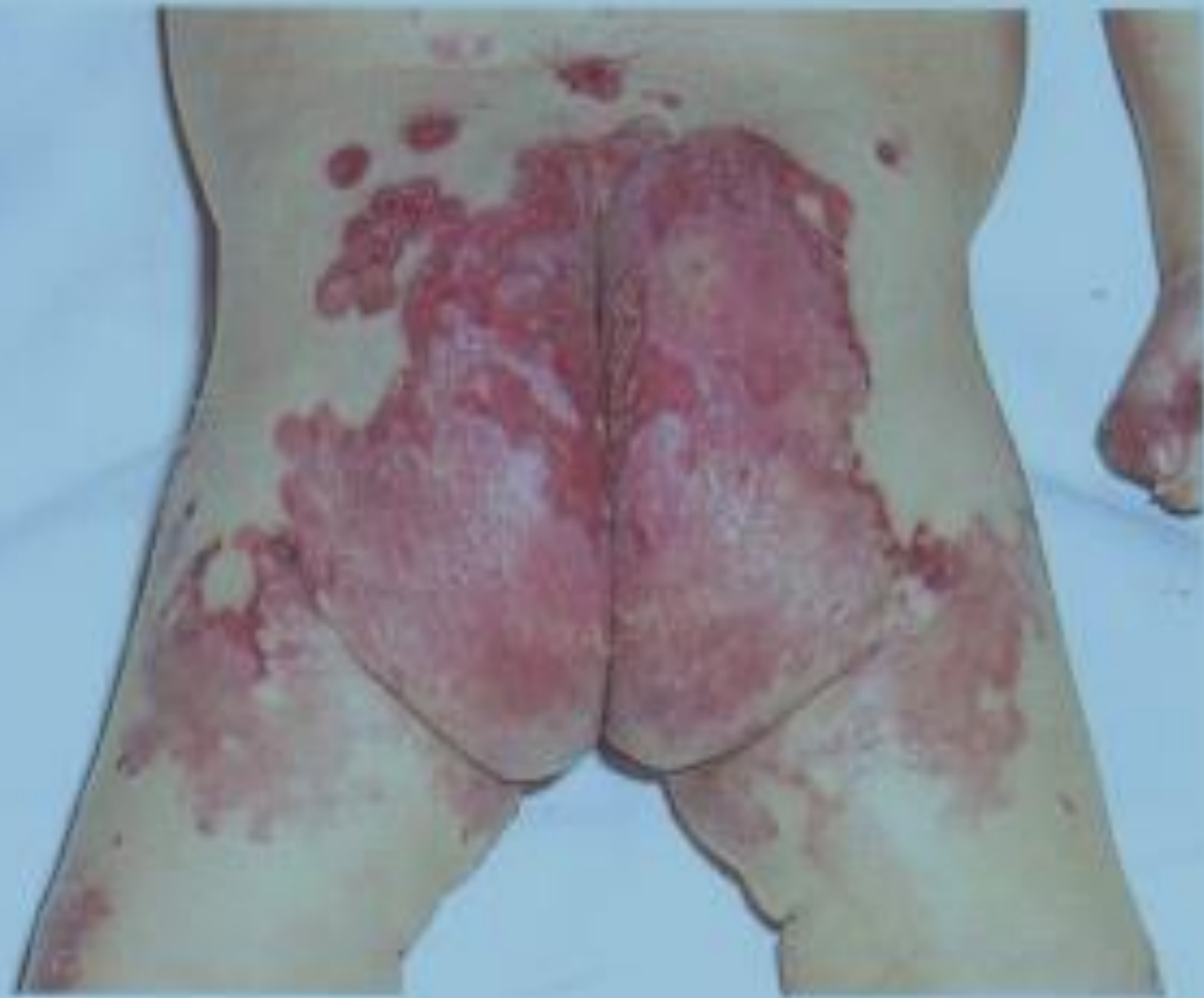

Fig. 135 Acrodermatitis enteropathica

