

Urinary stone disease II

Dr Ammar Fadil

Treatment of renal stone

- **Treatment for patients with calculi are commonly organized by stone size**
 1. Conservative therapy
 2. ESWL
 3. PCNL
 4. RIRS
 5. Open surgery

Classification

Stones may be classified according to

- ✓ size,
 - ✓ Location,
 - ✓ X-ray appearance,
 - ✓ shape &
 - ✓ composition
- ***Stone location***
 - Calyceal : upper, middle or lower calyx;
 - renal pelvis

1. Conservative treatment

Calculi 5mm and less are likely to pass spontaneously.

A. increase in fluid intake to achieve a daily urine output of 2 liters

B. Dissolution agents

Dissolution agents

- Uric acid stones are suitable for dissolution therapy.

A. Oral alkalinizing agents

alkalinize the urine to pH 6.5–7 include

- ✓ sodium bicarbonate 650 mg 3 or 4 times/d
- ✓ potassium citrate 30–60 meq/day, equivalent to 15–30 ML 3 or 4 times daily.

B. allopurinol

300–600 mg/day (inhibits conversion of hypoxanthine and xanthine to uric acid)

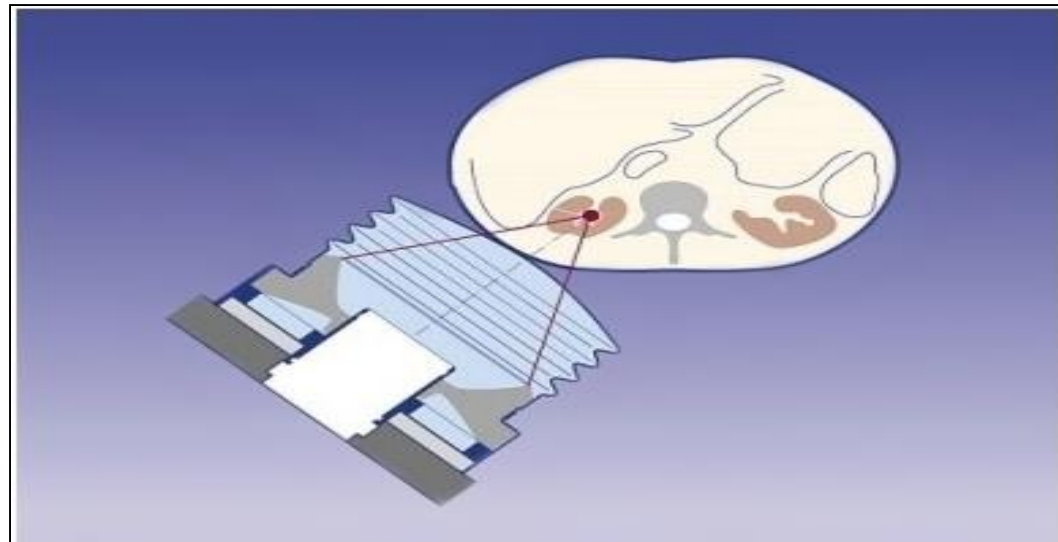
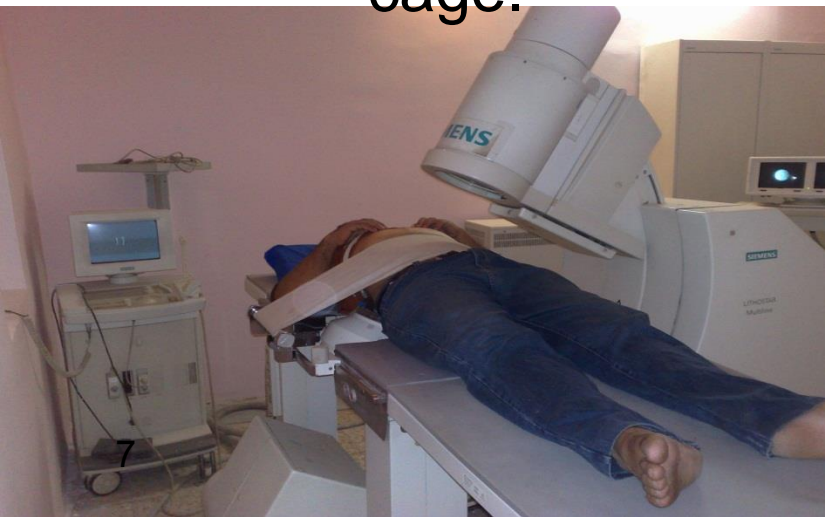
2. Extracorporeal shock wave lithotripsy “ESWL”

- **ESWL**
 - It is used for renal and ureteric stone
 - **Regarding renal stone is used for stone size ≤ 20 mm**

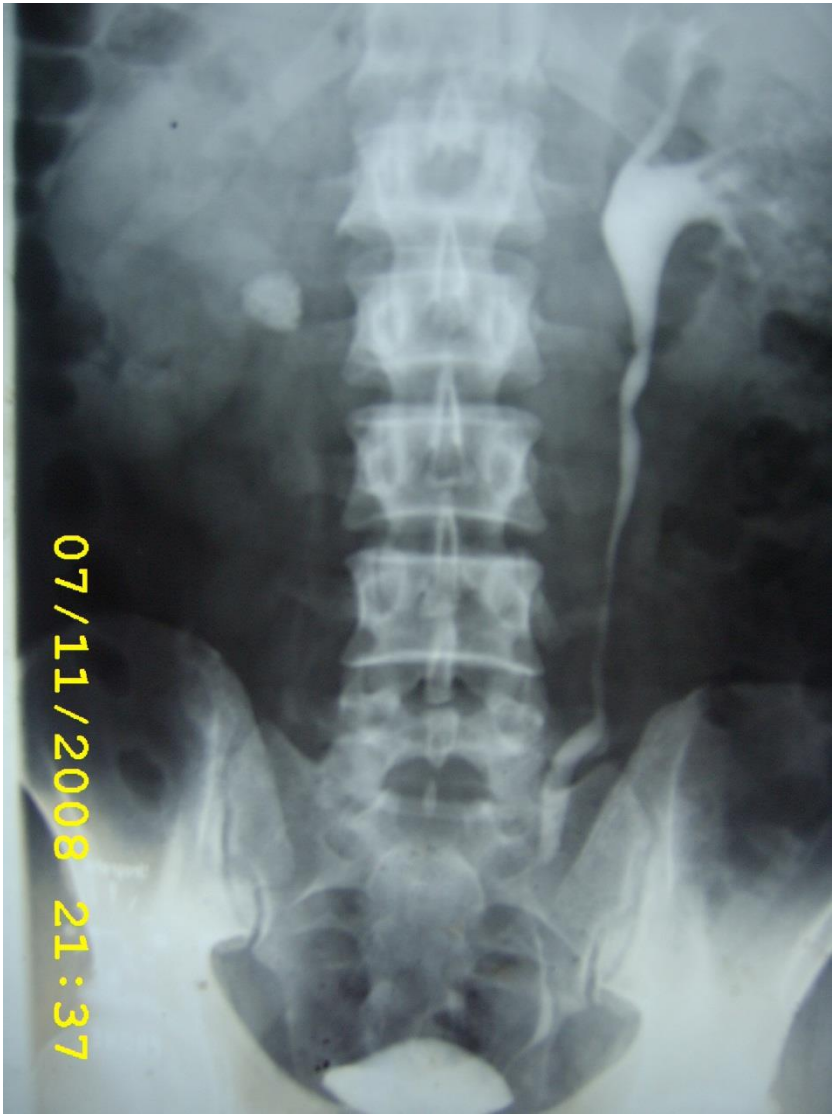
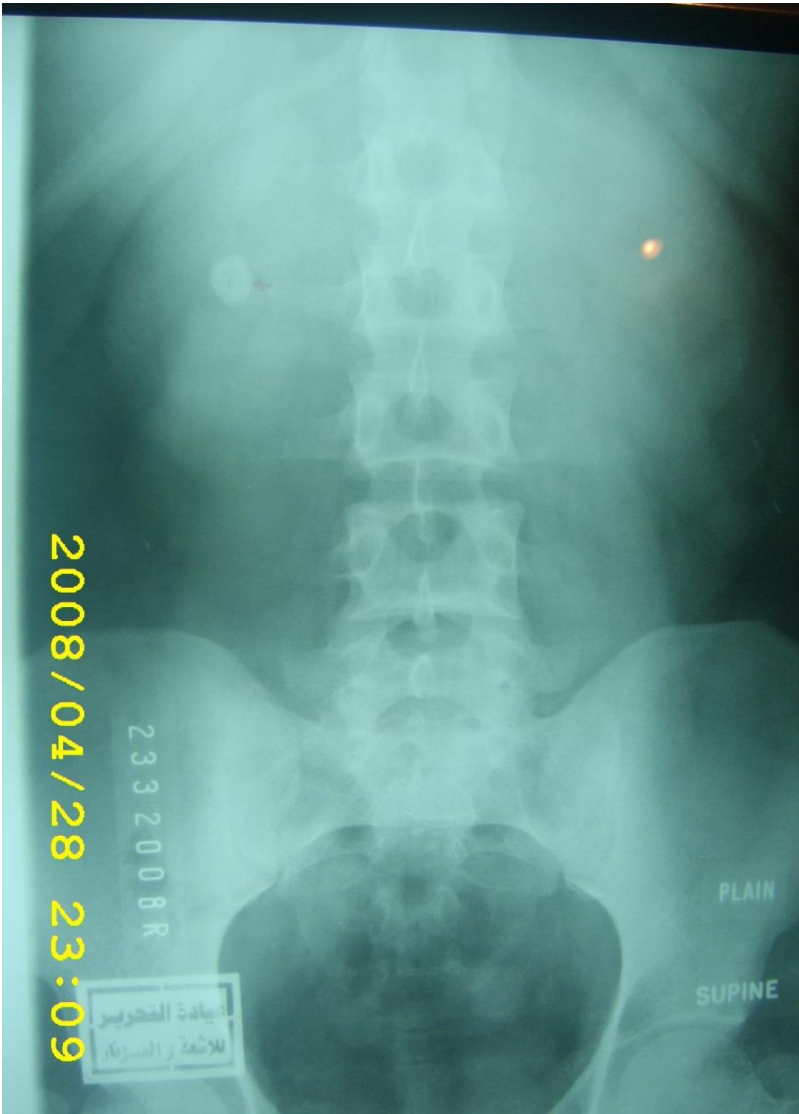principles

- **ESWL**

- It's acoustic shock waves
- are generated by a source external to the patient's body and are then propagated into the body and focused on a kidney stone.
- Underwater shock waves are generated by a spark gap electrical discharge contained within a Faraday cage.



ESWL



Contraindications

Absolute:

- 1) pregnancy
- 2) uncontrolled coagulation

relative

1. obstruction distal to stone
2. cardiac pacemaker – cardiologist should present.
3. AAA
4. severe orthopedic deformities
5. serum creatinine > 3 mg/dl

Complications

1. Hematuria

100% (disappears within 24 hr)

2. Renal hemorrhage

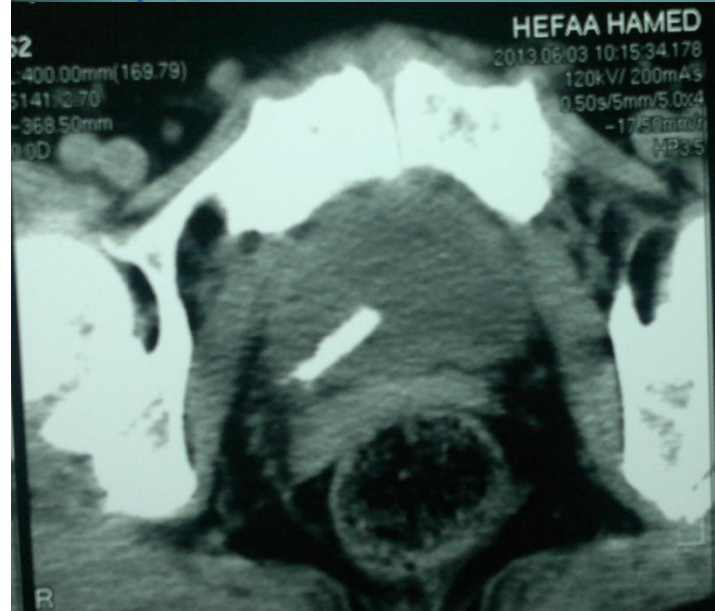
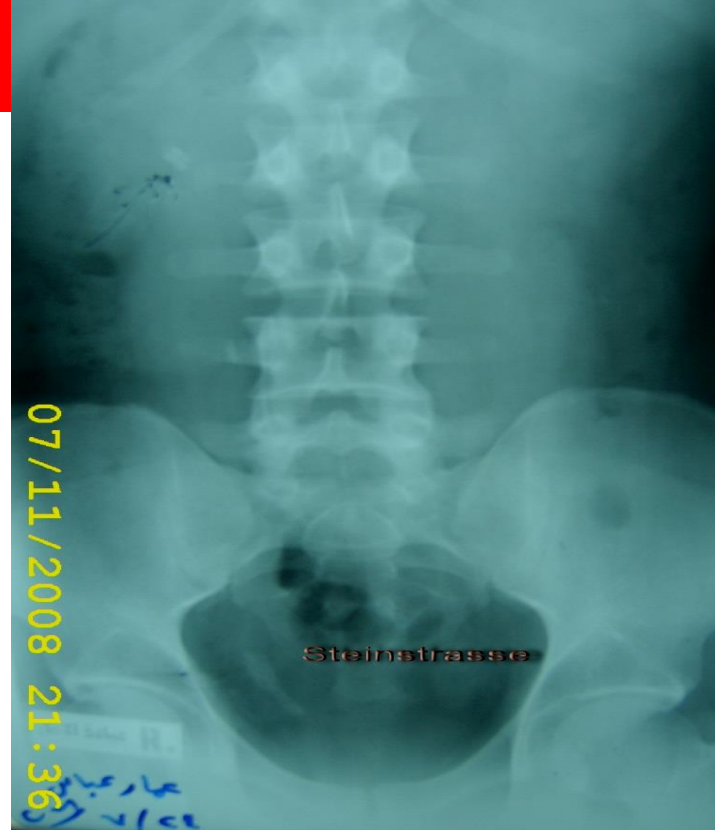perinephric, subcapsular,
intraparenchymal

3. Infection

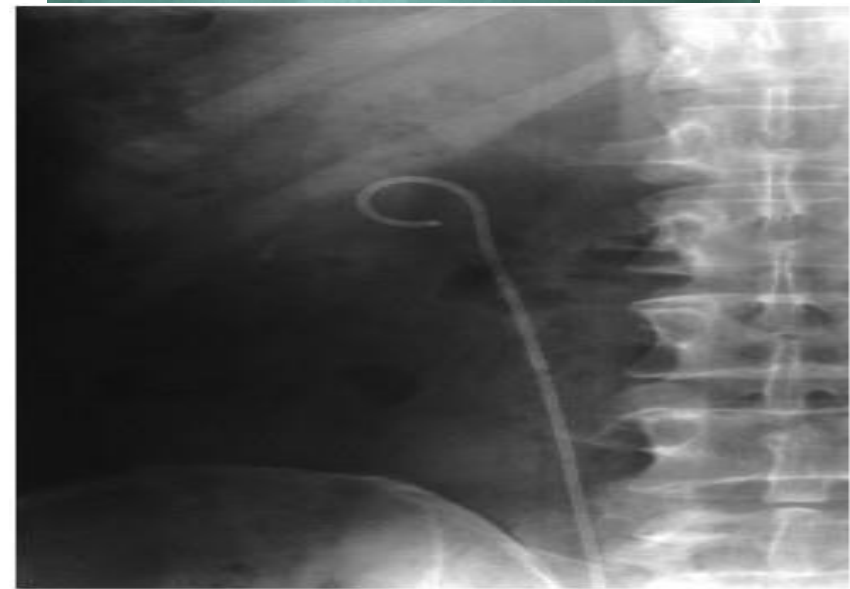many calculi contain bacteria which are released when the stone is broken. It is wise to give ABS.

4. Steinstrasse (SS)

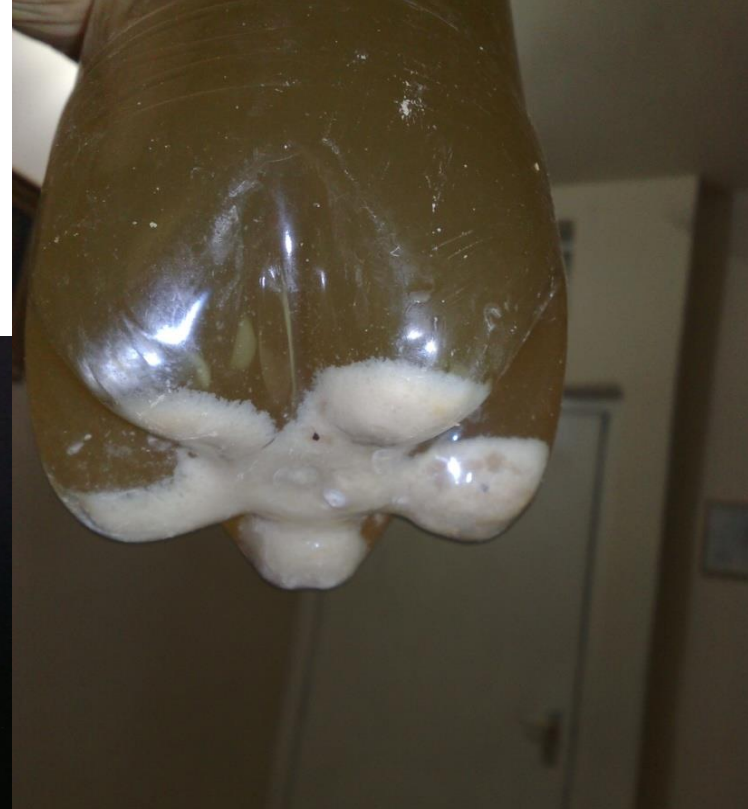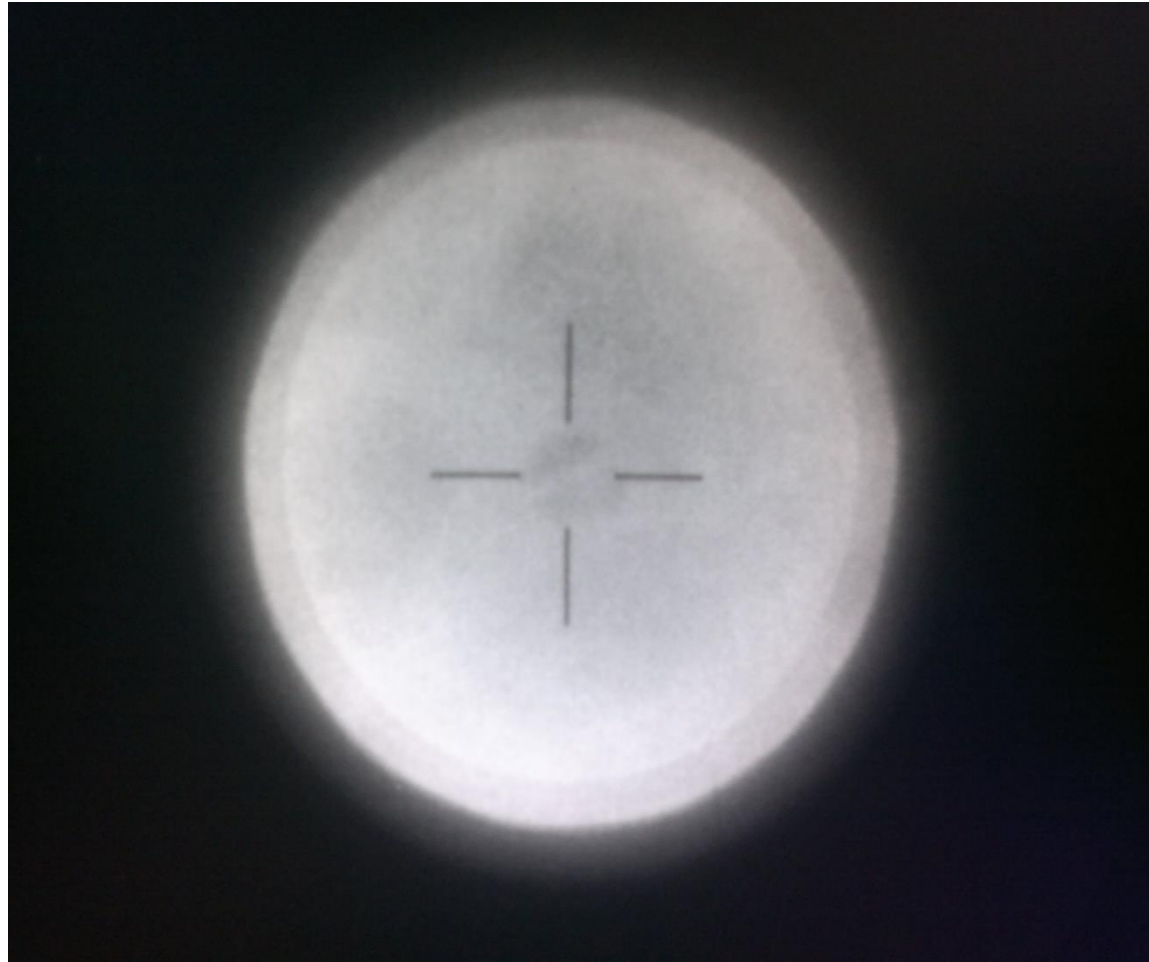
(German “street of stone”) 5%



- to avoid this (SS),
double J stent should be placed in the ureter so that the kidney can drain while the pieces of stone pass.
- JJ indication in ESWL
 - stone > 2 cm
 - Single kidney with stone



ESWL

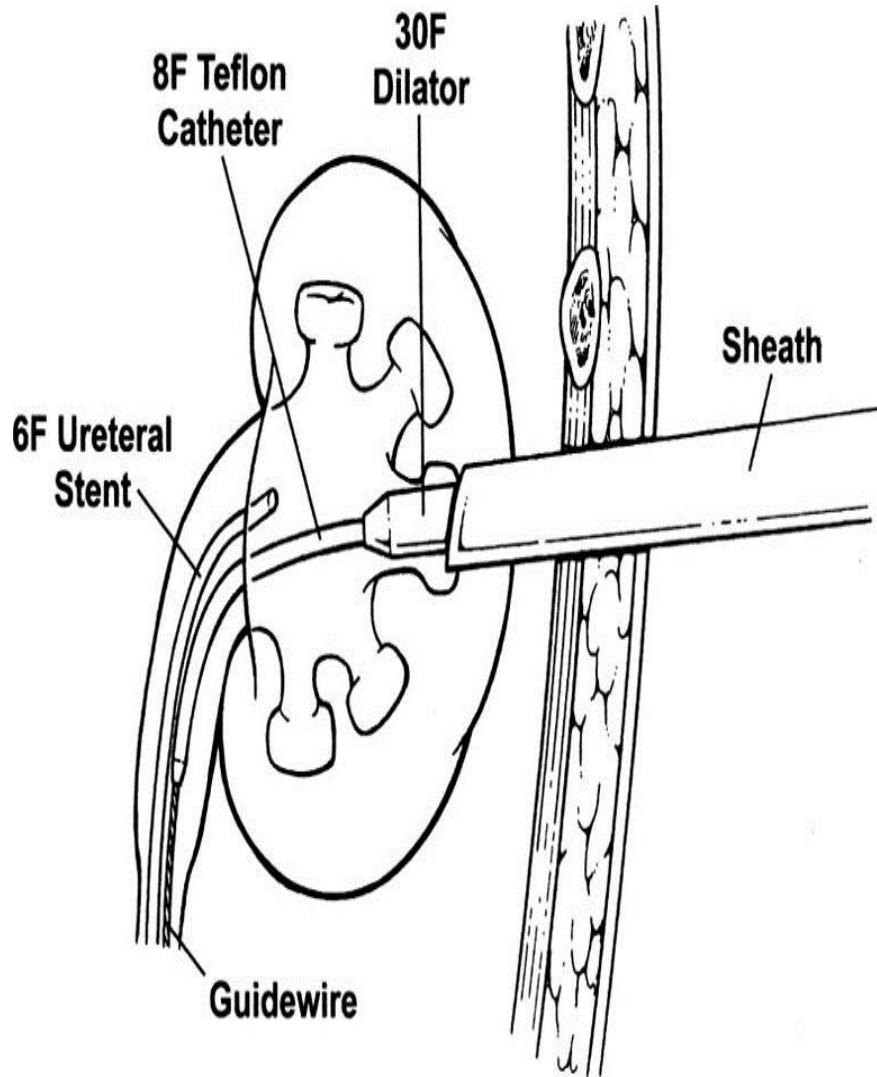


3. PCNL

PCNL is the removal of a kidney stone via a track developed between the surface of the skin and the collecting system of the kidney

- ✓ is recommended for stones >2 cm in diameter
- ✓ failed ESWL.
- ✓ It is the first-line option for staghorn calculi

PCNL



This involves the placement of a hollow needle into the collecting system through the loin and the renal parenchyma

A wire inserted through the needle is used to guide the passage of series of dilators which expand the track

PCNL

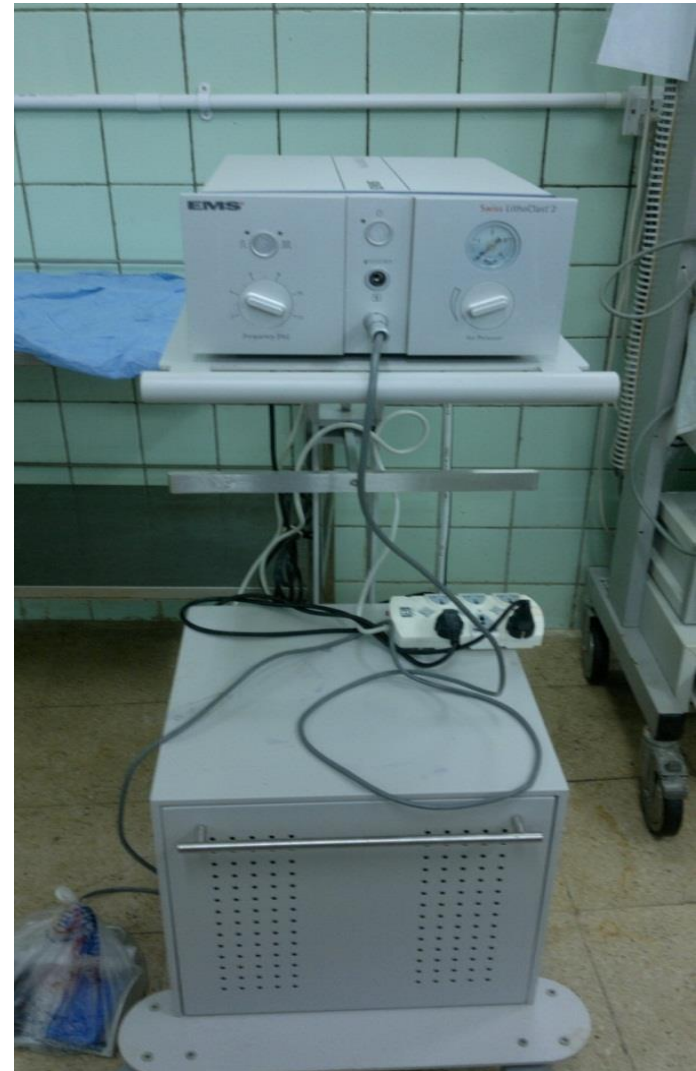- the nephroscope used to look for the stone.
- stones must be fragmented by
 - Lithoclast (pneumatic) lithotripter
 - Ultrasonic lithotripsy
 - laser

Intracorporeal techniques of stone fragmentation (fragmentation within the body)

A. Pneumatic (ballistic) lithotripsy

A metal projectile is propelled backward and forward at great speed by bursts of compressed air.

This technique is used for stone fragmentation in the **ureter and kidney**



B. Ultrasonic lithotripsy

The ultrasound energy is transmitted to a hollow metal probe, which in turn is applied to the stone this causes it to break into small fragments, uses include fragmentation of **renal calculi during PCNL**

C. Laser lithotripsy

The holmium:YAG laser is principally a photothermal mechanism of action, causing stone vaporization

Principal uses are for **ureteric stones & small renal stones**

4. RIRS

- RIRS retrograde intrarenal surgery
- Using flexible Ureterorenoscopy and using LASER for stone fragmentation

It is most suited to stones <2 cm in diameter

Cons

expensive equipment

FLEX-X²



Lightweight, ergonomic handle for greater operating comfort

Improved strain relief for greater durability

Easy to use single-lever control

Active deflection -- 270° up, 270° down

Laser resistant distal tip with Laserite™ material

7.5 Fr. distal shaft for easy access to UO

Unique shock absorber system* enhances maneuverability

Torque stable, 1:1 rotation

Stiffer 8.5 Fr. shaft engineered from proprietary polymers for faster, easier passage

Crush-resistant shaft stands up to back-table trauma, a frequent source of breakage

STORZ
KARL STORZ ENDOSCOPY
THE DIAMOND STANDARD

*Patent pending



5. Open surgery

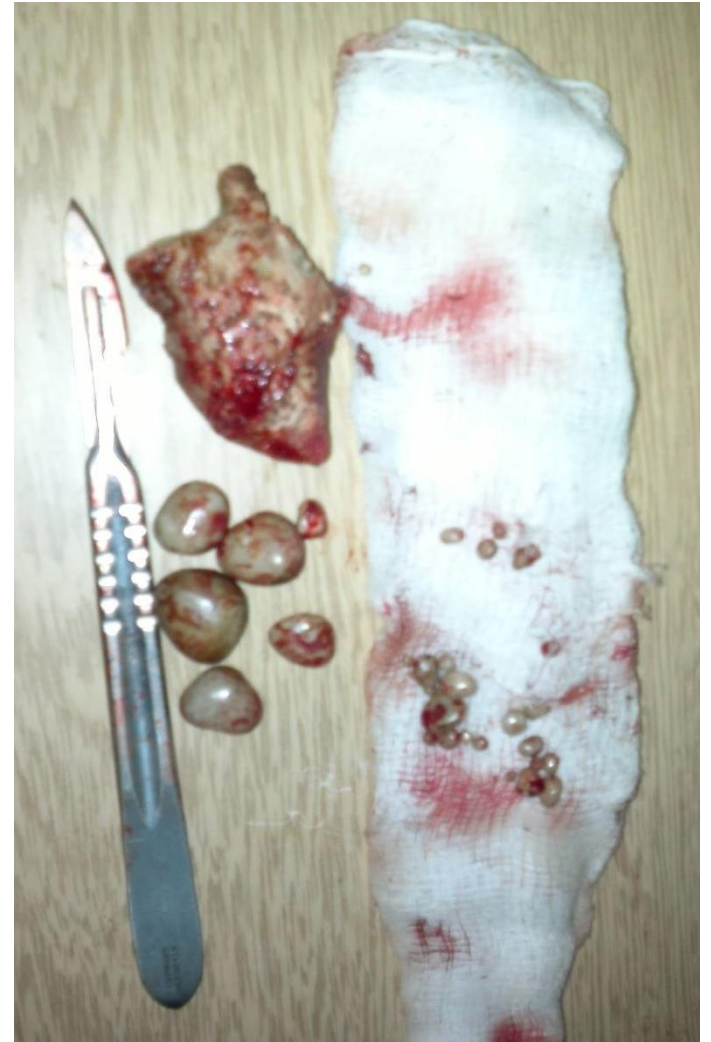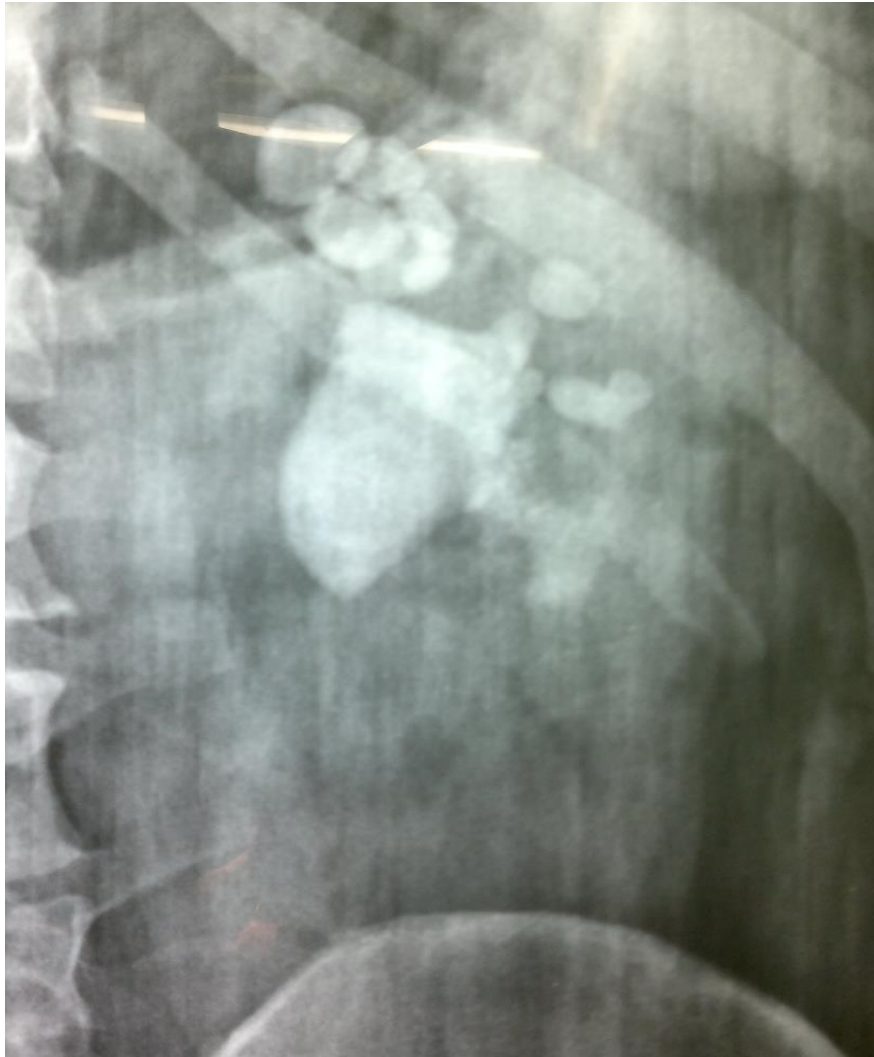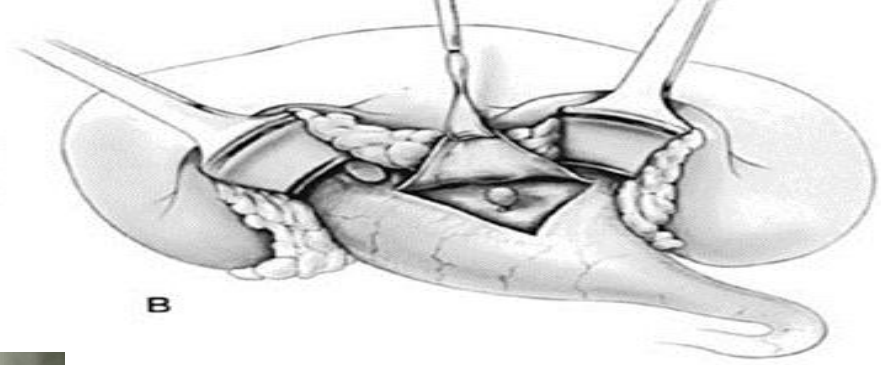
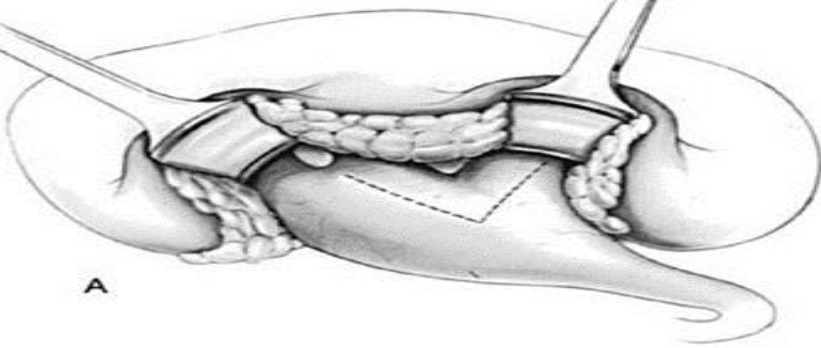
INDICATIONS:

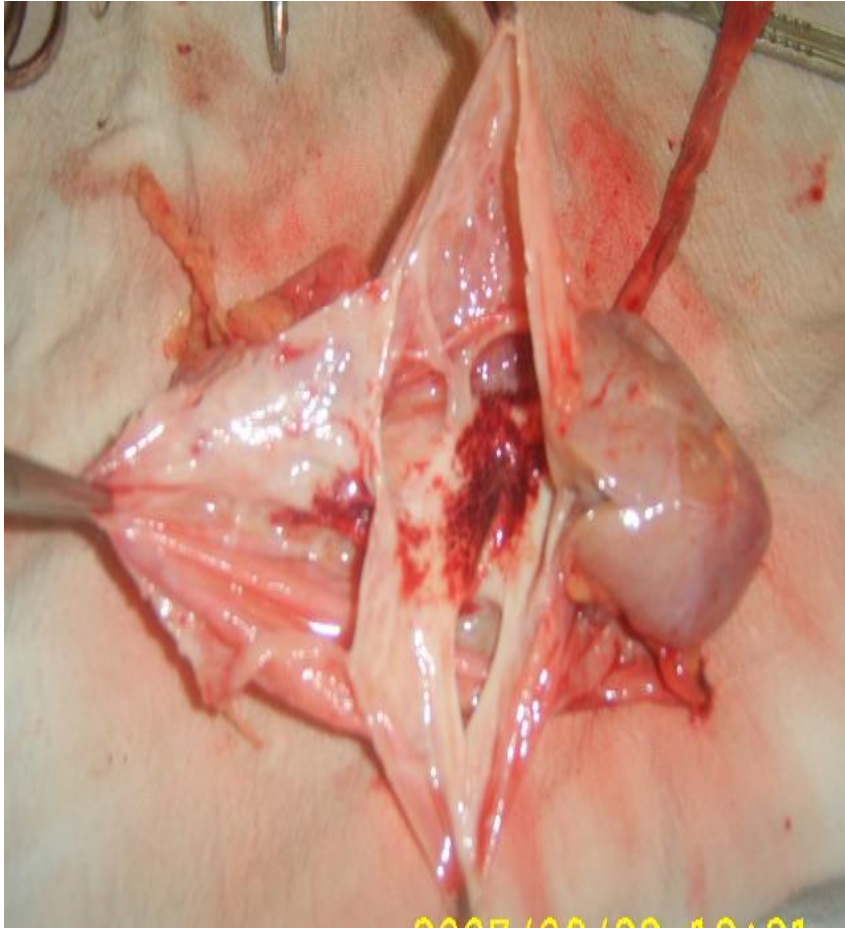- Complex stone burden (projection of stone into multiple calyces)
- Failure of endoscopic treatment (technical difficulty gaining access to the kidney)
- Body habitus that precludes endoscopic surgery e.g., gross obesity, Kyphoscoliosis
- Non functioning kidney
If the kidney is non functioning, the simplest way of removing the stone is to remove the kidney.

Open surgery

Operations for kidney stone are usually performed via a loin approach.

A. Pyelolithotomy for renal pelvic stone.





B. Nephrectomy is indicated when the kidney has been destroyed by obstruction and infection associated with stone disease.

Treatment of bilateral renal stones

- Usually the kidney with better function is treated first.
- the more painful one.

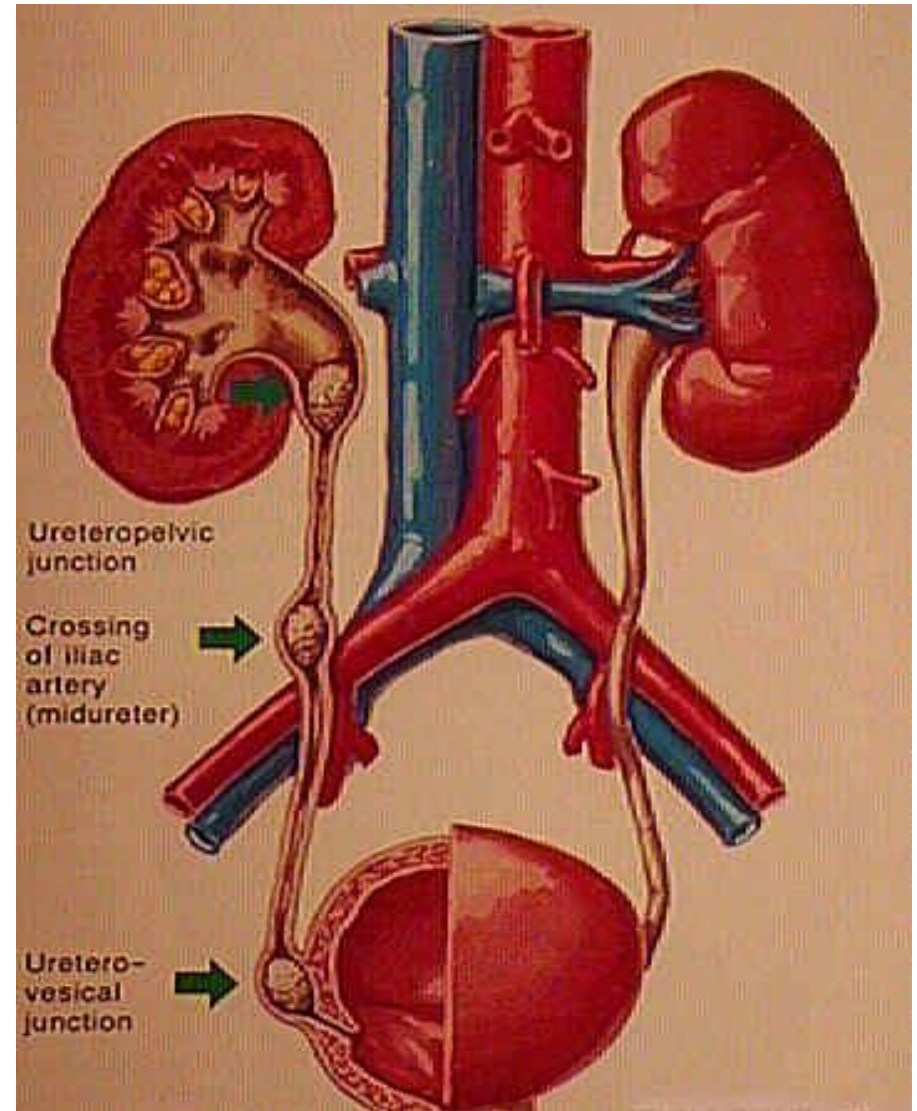
Ureteric calculus

Ureteral stones

- originate in the kidney
- become obstructed during passage through the ureter.
- Most are single small stones pass spontaneously
- some stones are too large to pass and lodge in the ureter.

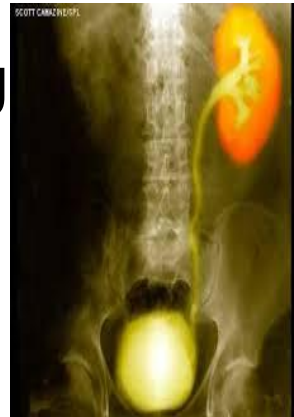the narrowest parts of the ureteral lumen and the locations of most impacted ureteral stones are

- **UPJ,**
- **crossing of the ureter over the iliac vessels**
- **UVJ**



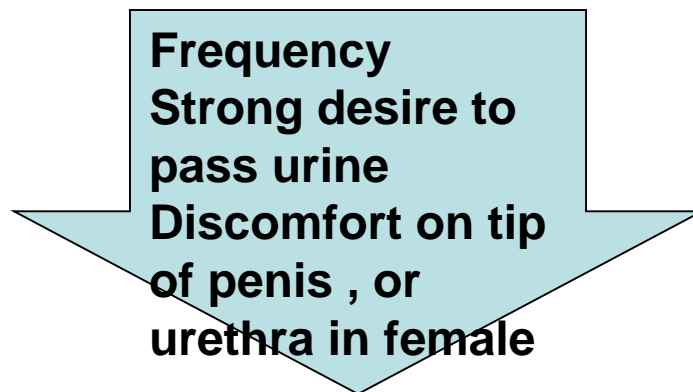
Patients with ureteric colic most commonly present with

- **sudden onset pain passing from loin to groin is colicky in nature.**
- As stone progress to the lower ureter pain are referred more to the groin, external genitalia and the anterior surface of the thigh.
- The patient cannot get comfortable, and tries to move in an attempt to relieve the pain.
- is frequently associated with nausea & vomiting
- Pain is occur from obstruction or renal capsular Distension

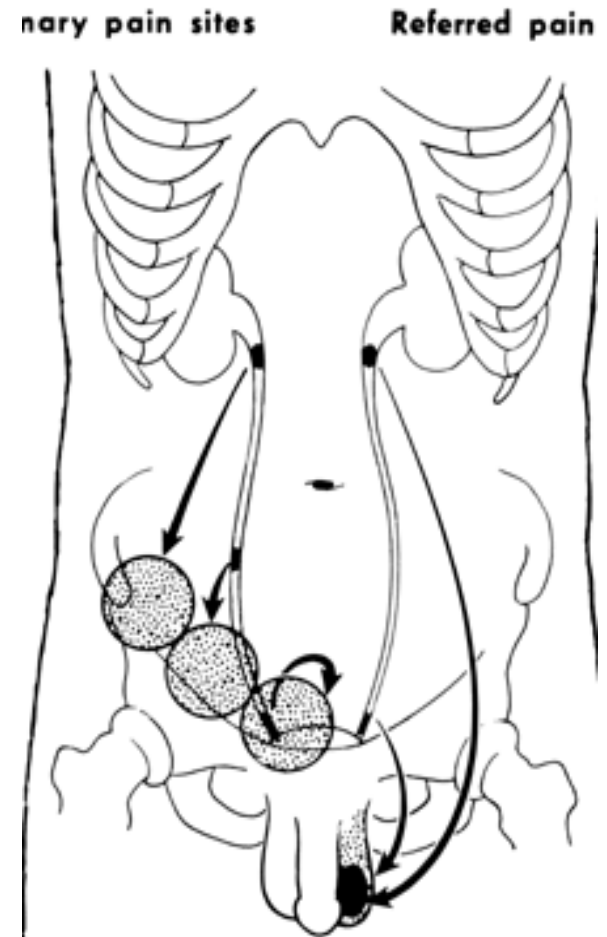


C/F

- Upper ureteric stone: loin pain radiating to testis
- Mid ureteral loin pain radiating to iliac fossa
- Lower ureteral loin pain radiating into bladder, vulva or scrotum.



**Pathognomonic
of UVJ stone**



C/F

There is often microscopic or gross hematuria owing to the abrasive effect of the stone on the urothelium.

Patients with stones may also present with infection that is complicated by the ureteral obstruction, resulting in dysuria, fever, leukocytosis, & sepsis.

D.D

- Musculoskeletal pain (L1 nerve root irritation, L1 Herpes zoster)
- pyelonephritis (fever, chills, pyuria)
- appendicitis
- acute abdomen (leaking abdominal aortic aneurysm)

Rt. Ureteric colic Vs AA (clinically)

- ✓ The presence of hematuria
 - although doesn't rule out appendicitis, because an inflamed appendix lying near the ureter can give rise to hematuria
- ✓ pt is usually in greater pain and less systemically ill.
- ✓ Renal tenderness
 - ✓ U/S show hydronephrosis suggesting presence of ureteric stone
 - ✓ CT scan

DX

O\E

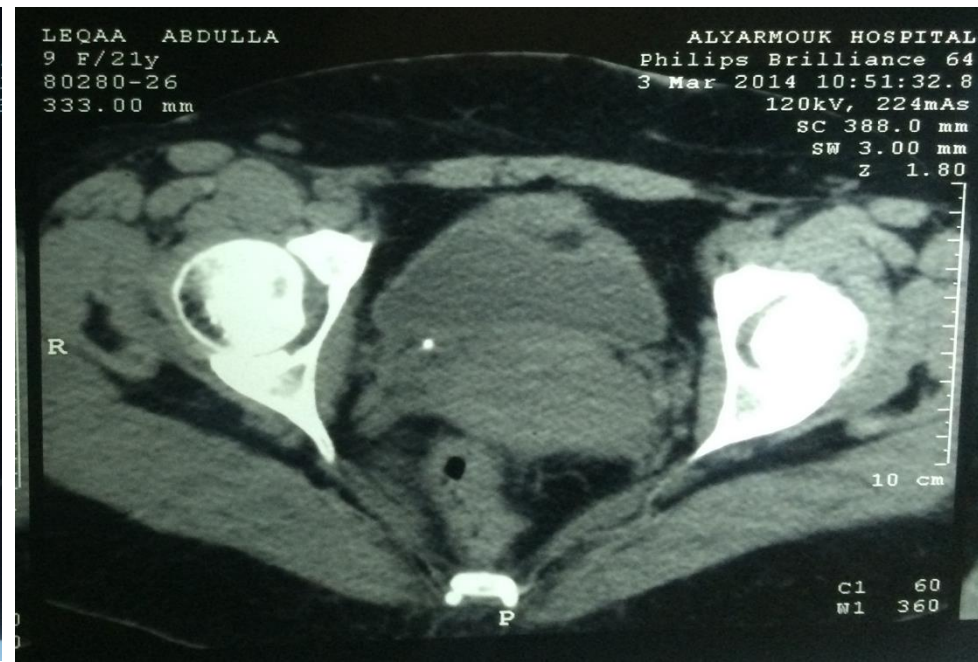
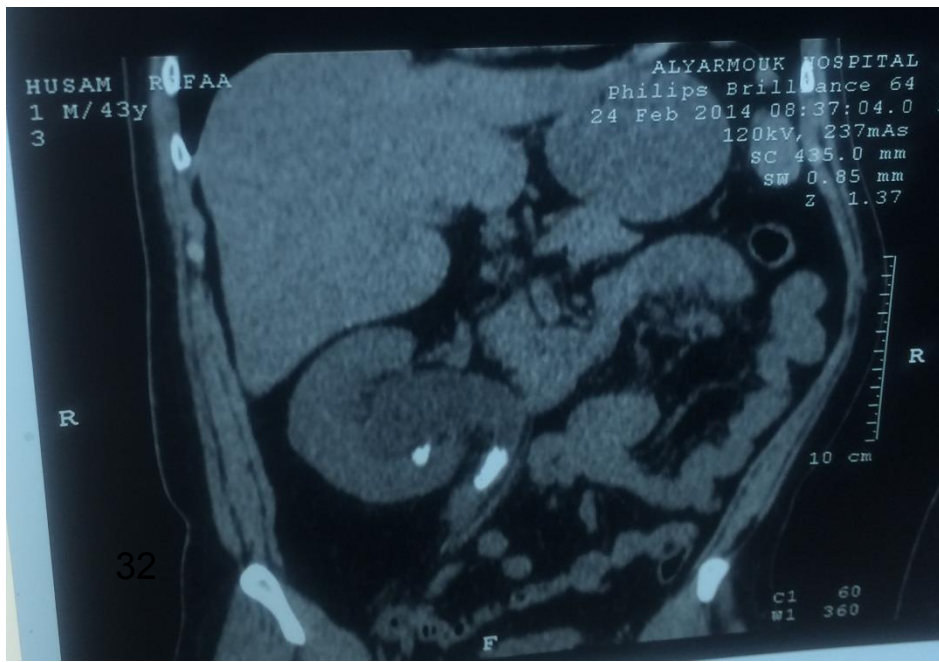renal angle tenderness as well as
tenderness in the ipsilateral lower abdomen

- Urinalysis frequently shows microscopic hematuria **> 3 RBC \HPF**
 - Initial blood studies should include (BUN, serum creatinine, calcium) serum uric acid and phosphorus.
 - Nonenhanced spiral computed tomography (CT)
- OR**
- U/S+KUB

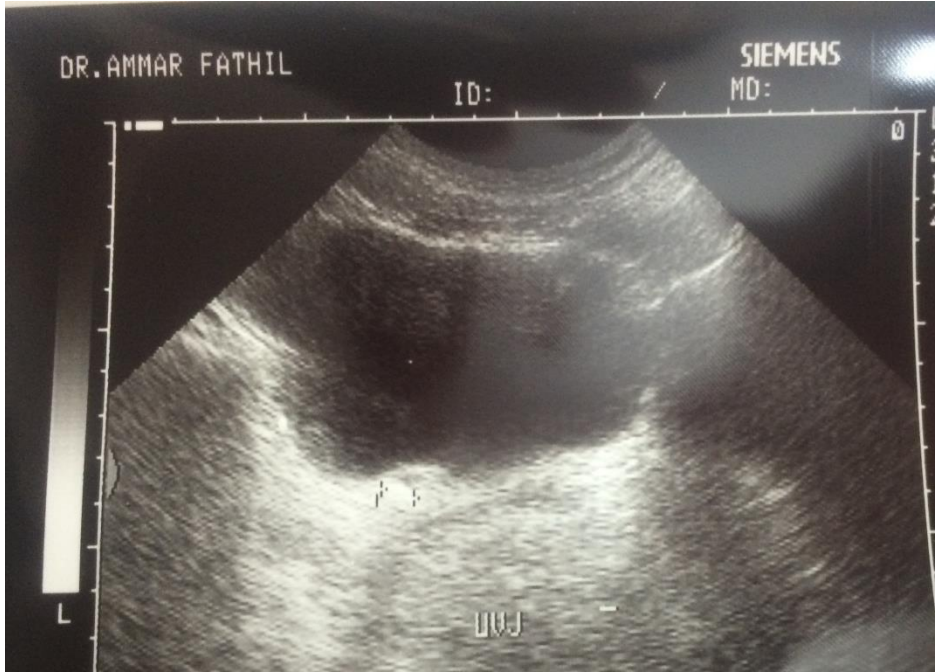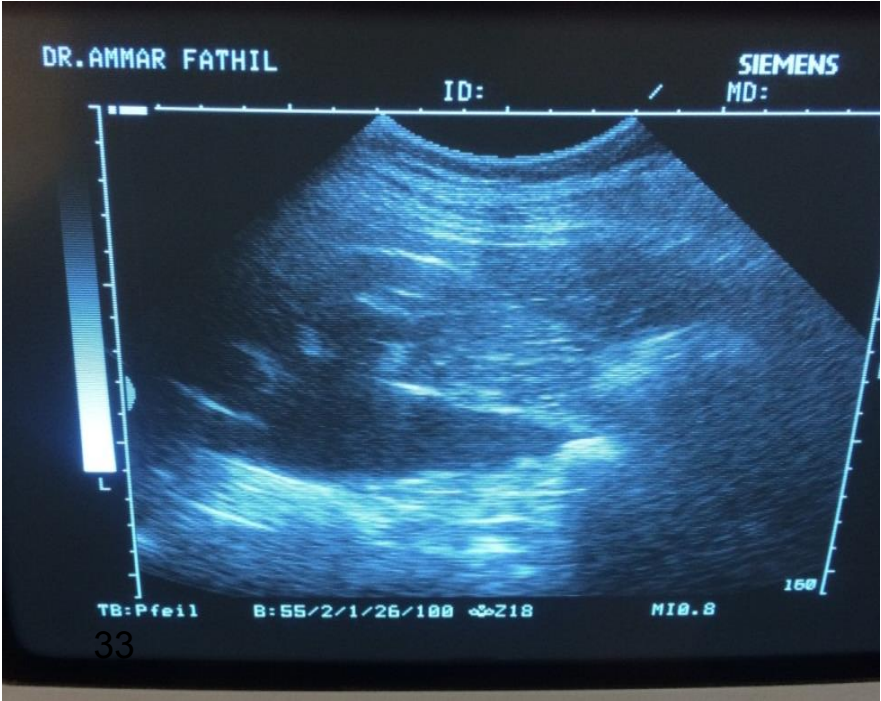
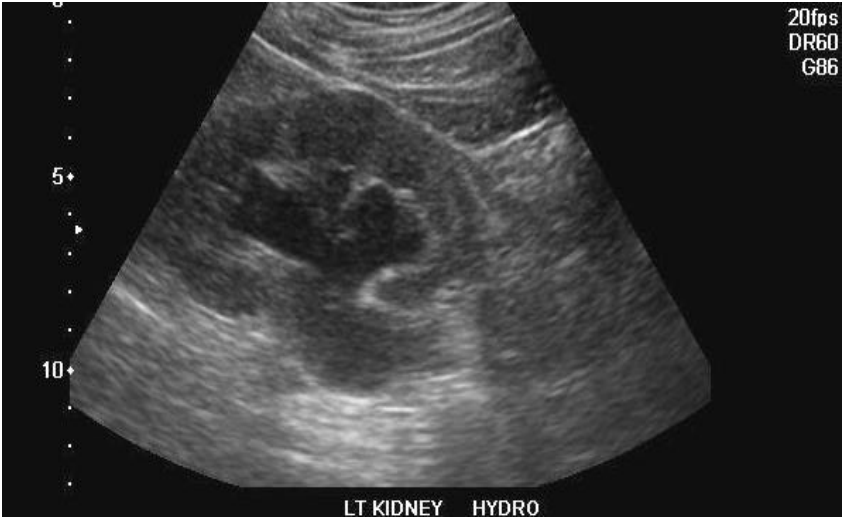
CT scan/ Renal colic

Non-enhanced (CT)

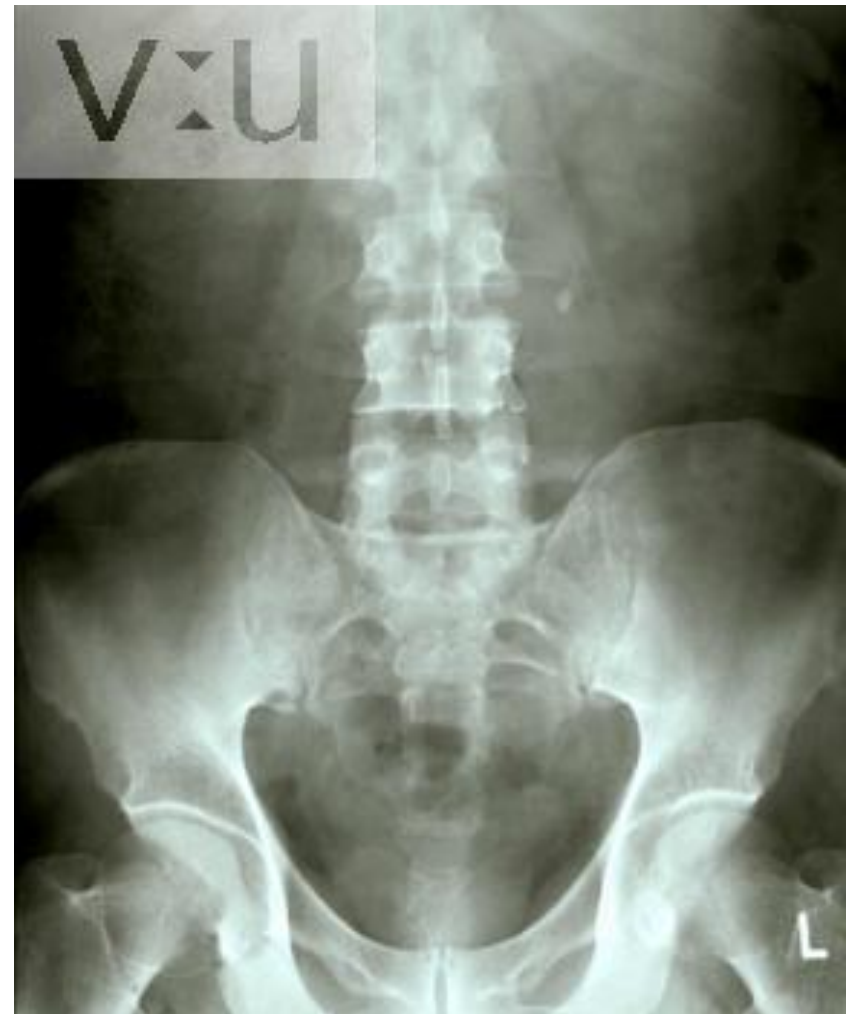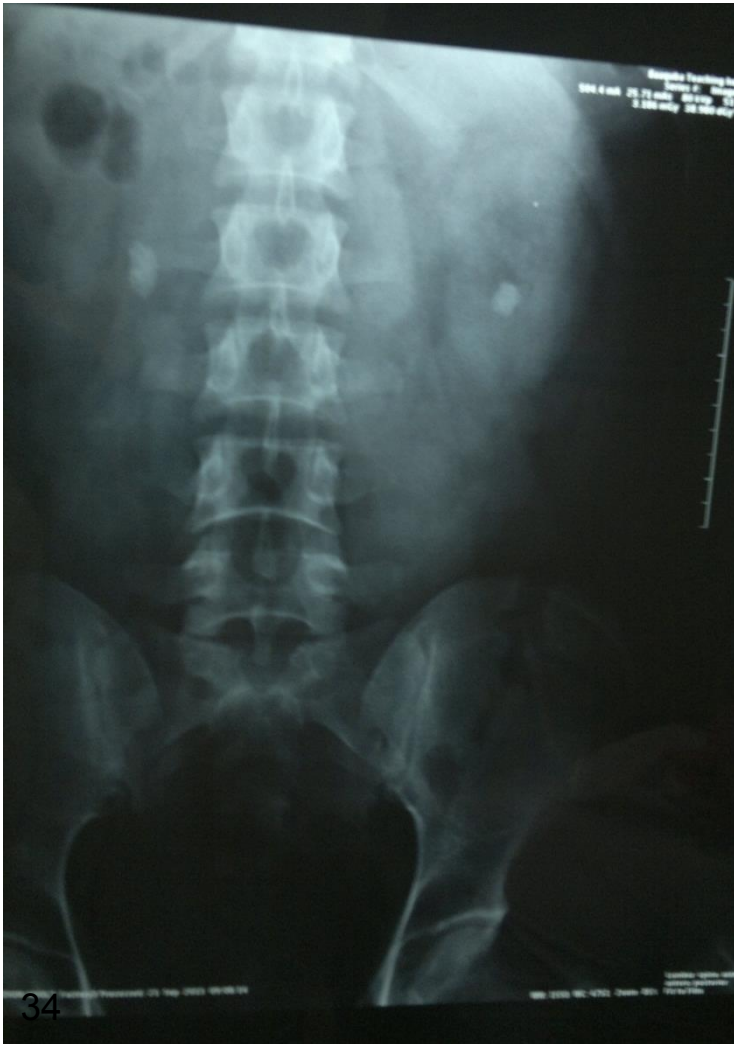- study of choice
- has high sensitivity and specificity for calculi.
- does not require bowel preparation or IV contrast



- US: Hydronephrosis
or
ureteric stone can be seen if its in
upper ureter or
near UVJ



KUB



Initial treatment of ureteric colic

1. Pain relief is the first therapeutic step in patients with an acute stone episode.

Non-steroidal anti-inflammatory drugs (NSAIDs) e.g.,
diclofenac—Voltaren IM 75 mg

- have better analgesic efficacy than opioids.
- Its analgesic effect is partly anti-inflammatory & partly by reducing ureteric peristalsis.
- Opioids are associated with a high rate of vomiting compared to NSAIDs
- When NSAIDs are inadequate, opiate analgesics such as tramal, pethedine or morphine are added
- May be managed with antidiuretic desmopressin.

2. Prevention of recurrent renal colic

- A. NSAID tablets or suppositories (e.g., diclofenac sodium, 100-150 mg/day, 3-10 days) may help reduce inflammation and risk of recurrent pain .
- B. Daily α -blockers(**MET**) Tamsulosine 0.4 mg

There is no need to !!

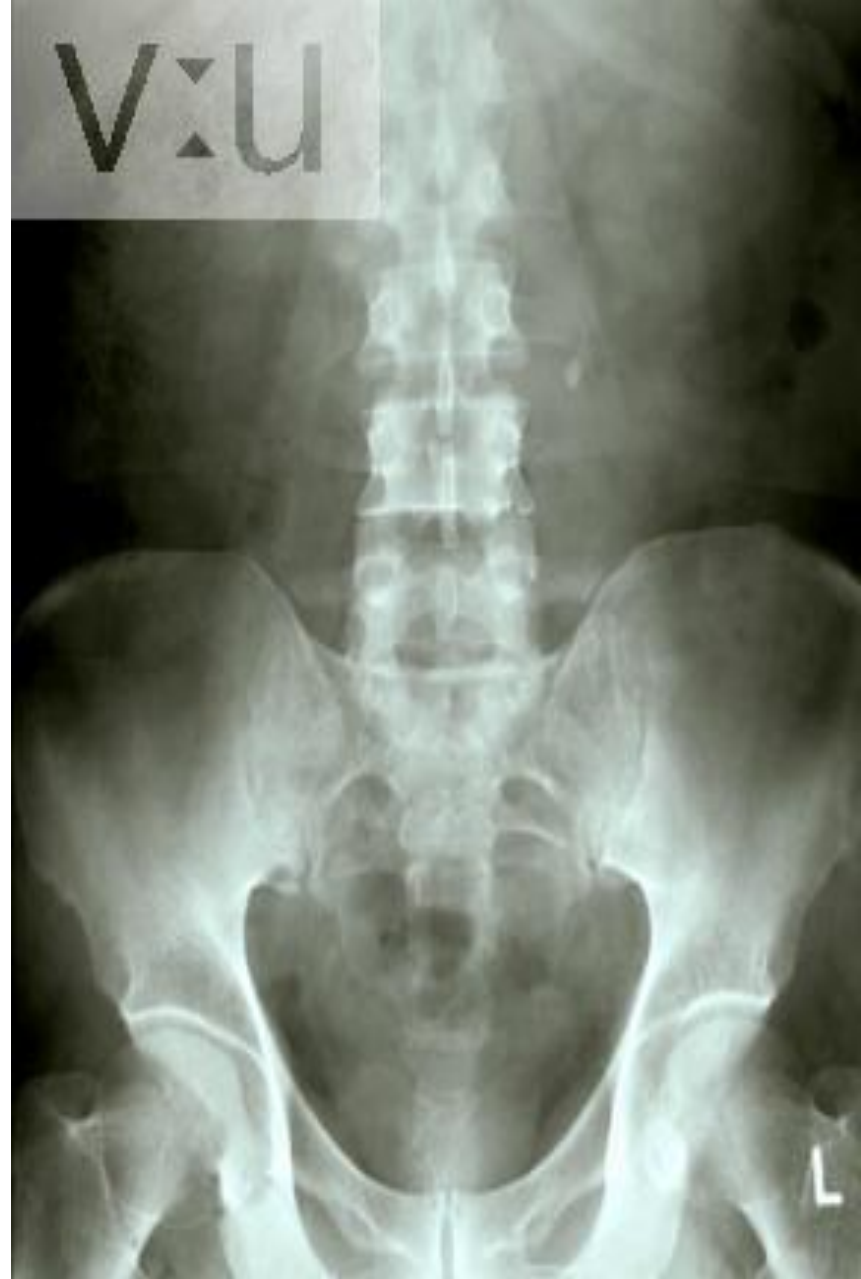encourage the patient to drink copious amounts of fluids or to give them **large volumes** of fluids intravenously in the hope that this will flush out the stone.

Initial treatment of colic

Renal blood flow and urine output from the affected kidney fall during an episode of acute, partial obstruction due to a stone

- MIS PRACTICE
 - I.V fluid unless pt has repeated vomiting

- The ureter can be divided into
 - upper third from the UPJ to the upper edge of the sacrum;
 - middle third from the upper to the lower edge of the sacrum;
 - lower third from the lower edge of the sacrum to the VUJ



Modalities of treatment of ureteric stone

- Expectant therapy
- ESWL
- Ureteroscopy
- Open surgery (ureterolithotomy)

1. Expectant therapy

conservative measures are recommended **depending on the clinical circumstance**

- stones pass spontaneously do so 4-6 weeks
- 80% will pass the stone spontaneously
- stones under 6 mm considered for observation
- Stones located more distally typically pass more readily than those located in the mid or upper ureter.

NSAID + MET

High fluid intake

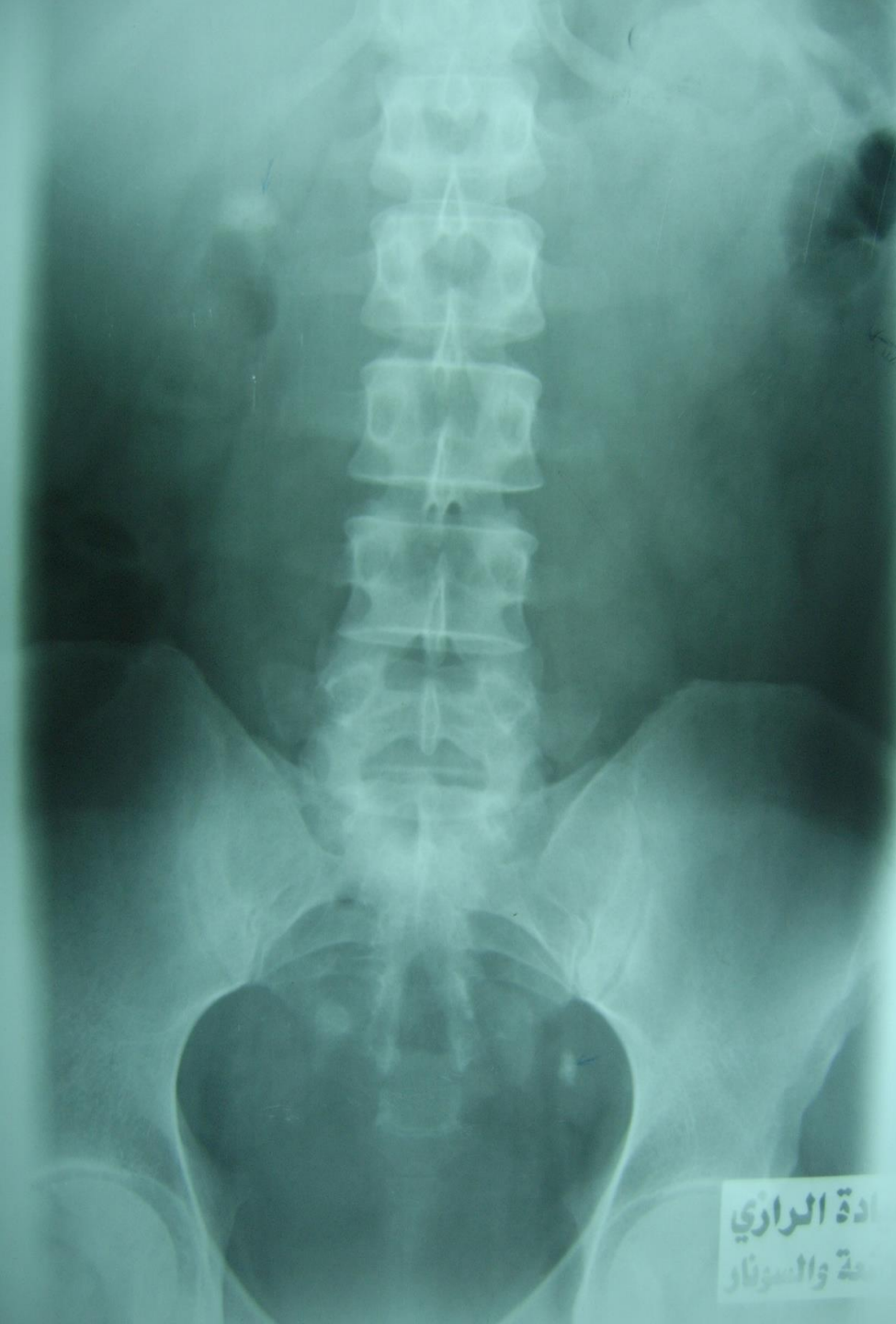(>7mm) typically do not pass

Indications for interventions

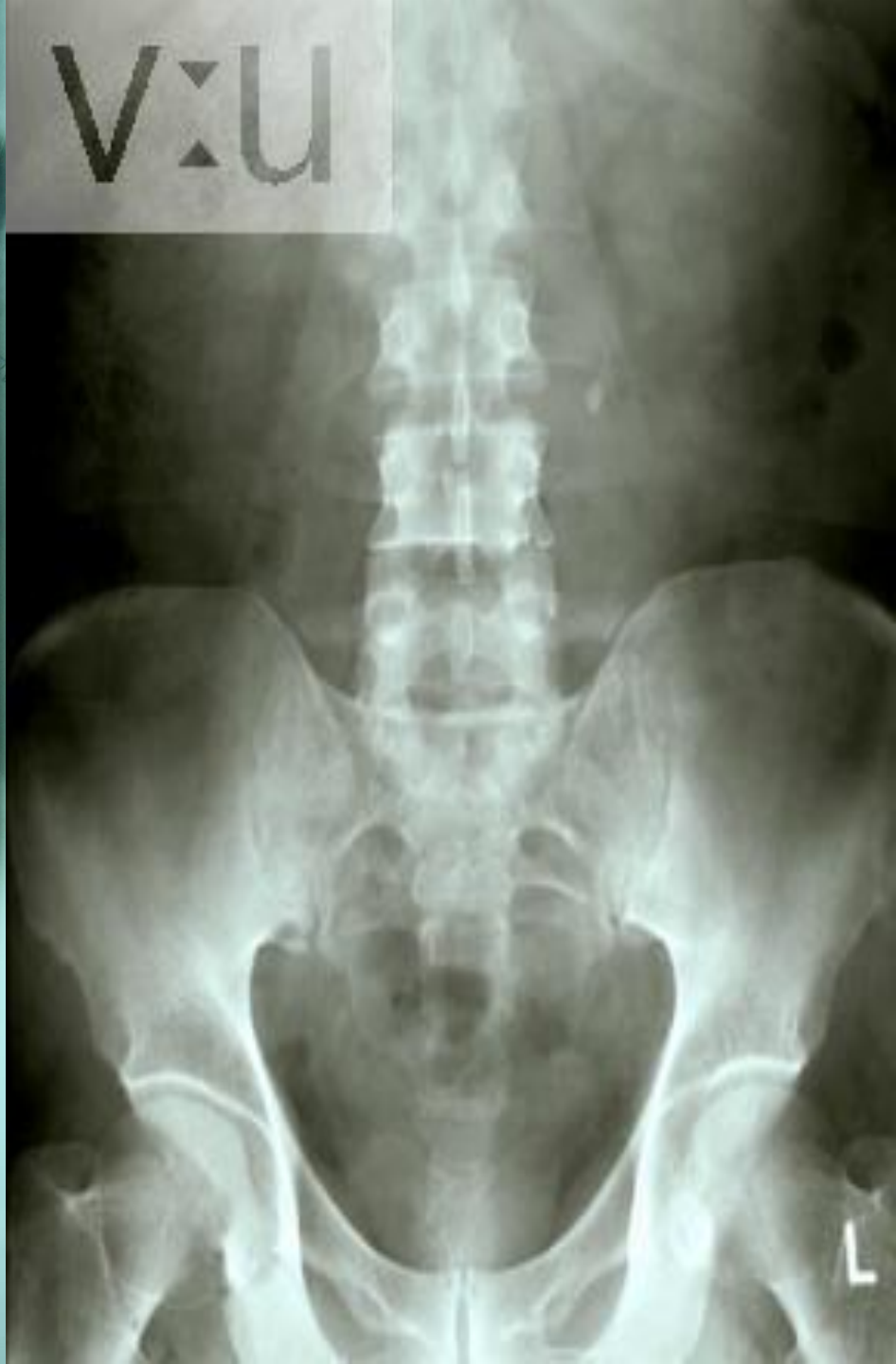- pain refractory to analgesics
- obstruction with infection
- Impaired renal function (solitary kidney obstructed by a stone, bilateral ureteric stones)
- lack of stone progression
- Large stone unlikely to pass
- pt preference

2.ESWL

- is more efficient for stones <1 cm in diameter than for those >1 cm in size
 - **ESWL: in situ;**
 - **after push-back into the kidney (JJ stent insertion**



أداة الرازي
للشدة والسونار

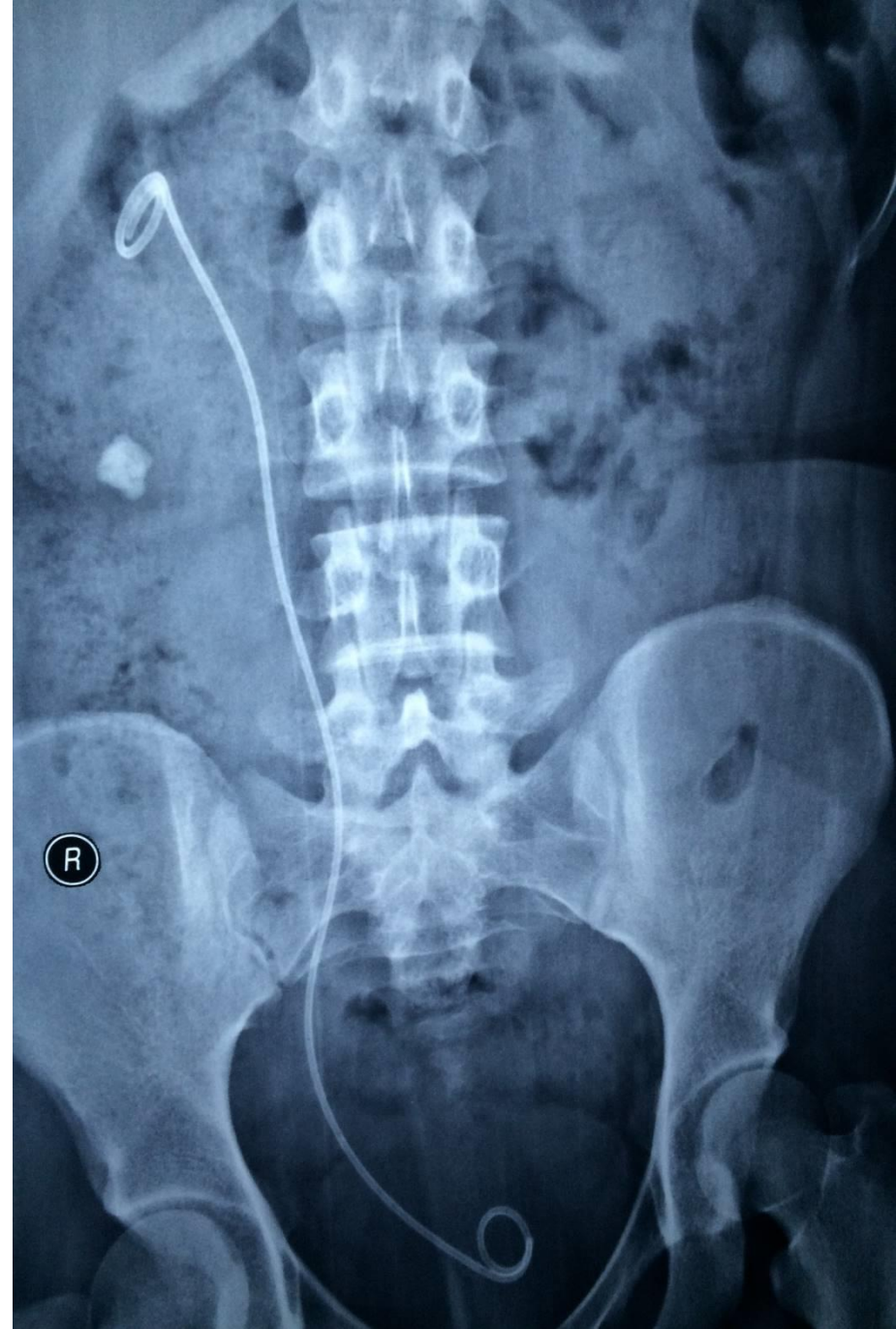


V:U

Push bang (back)

a stone that is lying in the upper part of the ureter can often be flushed back into the kidney by a JJ-stent.


The patient can then be treated by ESWL



3. Endoscopy

Ureteroscopy & intracorporeal lithotripsy

A ureteroscope is a long endoscope which can be passed transurethrally across the bladder into the ureter. Stones are fragmented using a laser lithotripter or lithoclast.



Recommendations

Upper ureteric stones

- <1 cm diameter: ESWL (in situ, push-back)
- >1 cm diameter: ureteroscopy, ESWL

Mid ureteric stone URS

Lower ureteric stones

- ESWL and ureteroscopy are acceptable options

4. Open Ureterolithotomy

Open ureterolithotomy is used when ESWL or ureteroscopy have been tried and failed or were not feasible.

Calculi in the upper third of the ureter are approached through a loin incision as used for a stone in the renal pelvis.

midureteric stones is through a muscle-cutting iliac fossa incision;

lower ureteric stones are best reached through a Pfannenstiel incision.

Prevention

- 50% of individuals experiencing recurrent another stone within 10 years of the first occurrence
- One mainstay of conservative management is the forced increase in fluid intake to achieve a daily urine output of 2 liters
- moderate animal protein (meat) intake
- sodium restriction
- Dietary calcium avoidance actually increases stone recurrence risk.

Fluid recommendation

- Patients should be strongly encouraged to consume enough fluids to produce 2 liters of urine per day.
- Soda flavored with phosphoric acid may increase stone risk, whereas soda with citric acid may decrease risk.
- Citrus juices (particularly lemon juice) may be a useful adjunct to stone prevention.

Pharmacological treatment

Recurrent Calcium stone

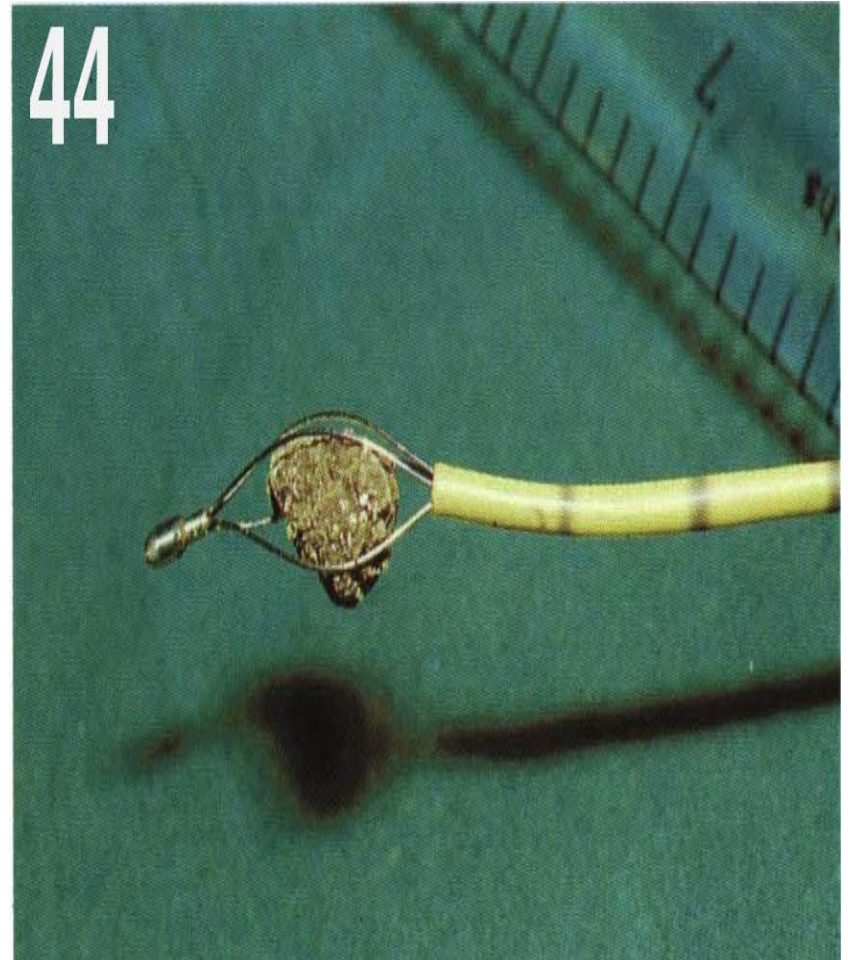
thiazide diuretic and / or potassium citrate

Recurrent Uric acid stone

Potassium citrate to raise urine PH & or Allopurinol

Dormia basket

- **The use of wire baskets used for small stones that are within 5 or 6 cm of the ureteric orifice**



Ureteric meatotomy

Stones often lodge in the intramural part of the ureter. endoscopic incision using a diathermy knife can enlarge the opening and free the stone.

