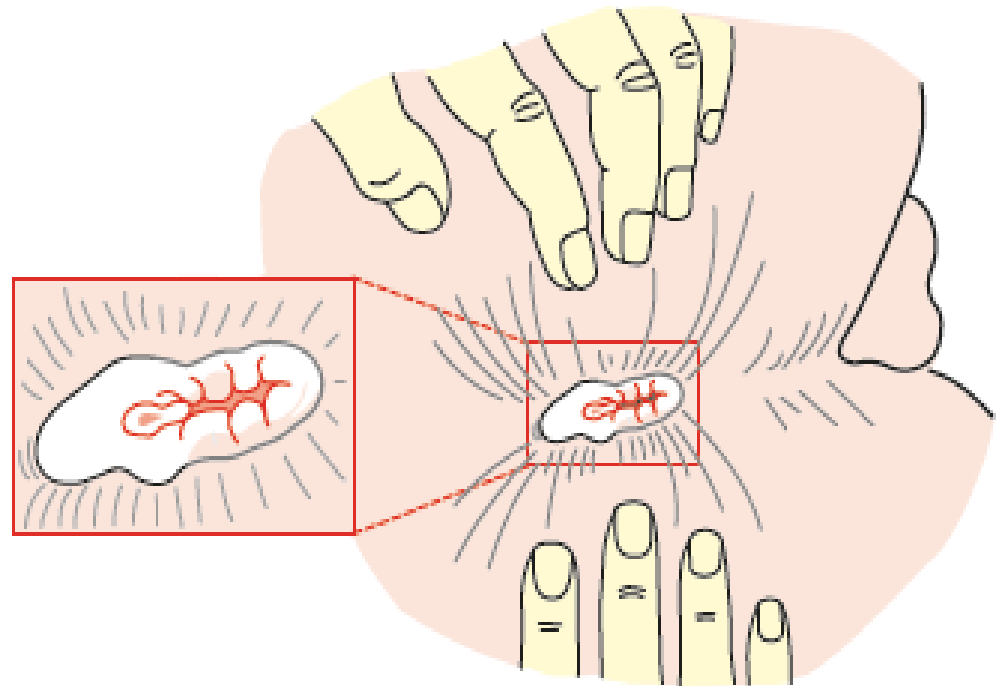




ANAL FISSURE


Definition

- An anal fissure (synonym: *fissure-in-ano*) is a *longitudinal* split in the anoderm of the distal anal canal which extends from the anal verge proximally towards, but not beyond, the dentate line.
- 90% located in
- Midline posterior



Aetiology

- Classically, acute anal fissures arise from the trauma caused by the strained evacuation of a hard stool
- or, less commonly, from the repeated passage of diarrhoea.
- The location in the posterior midline perhaps relates to the exaggerated shearing forces acting at that site at defaecation, combined with a less elastic anoderm.

- 
- Anterior anal fissure is much more common in women and may arise following vaginal delivery.

Clinical features


- Men and women are affected equally.
- Anterior fissures account for about 10 per cent of those encountered in women, but only 1 per cent in men.
- acute anal fissures are characterised by severe anal pain associated with defaecation.
- as well as the passage of fresh blood, normally noticed on the tissue after wiping.
- When chronic, patients may also complain of itching secondary to irritation from the sentinel tag, discharge from the ulcer

Anal fissure

- Acute or chronic
- Ischaemic ulcer in the midline of the anal canal
- Ectopic site suggests a more sinister cause
- Symptoms:
 - Pain on defaecation
 - Bright-red bleeding
 - Mucous discharge
 - Constipation

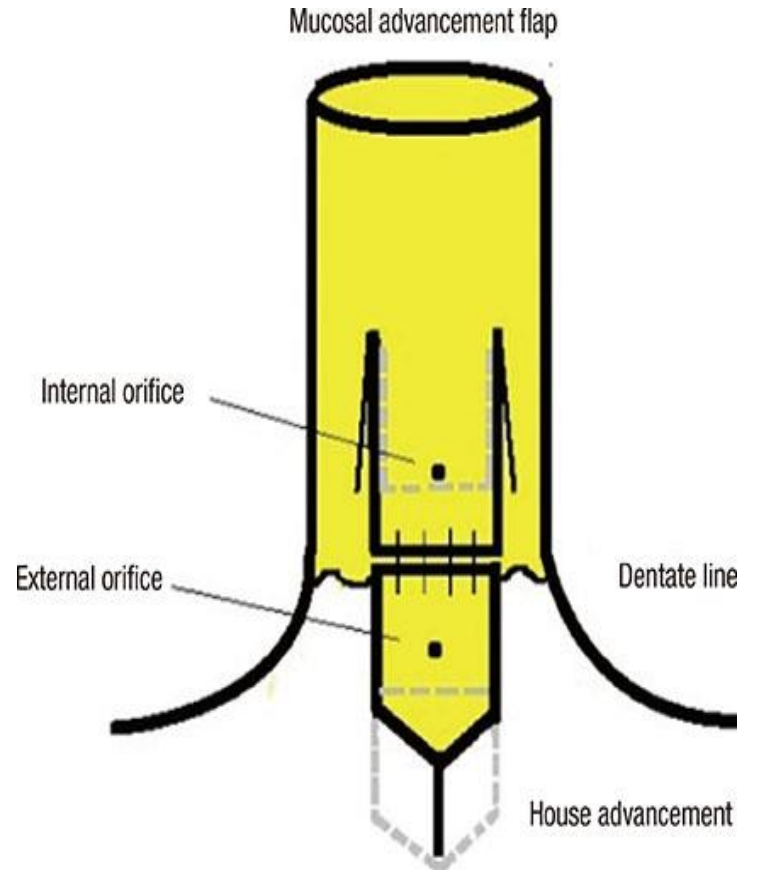
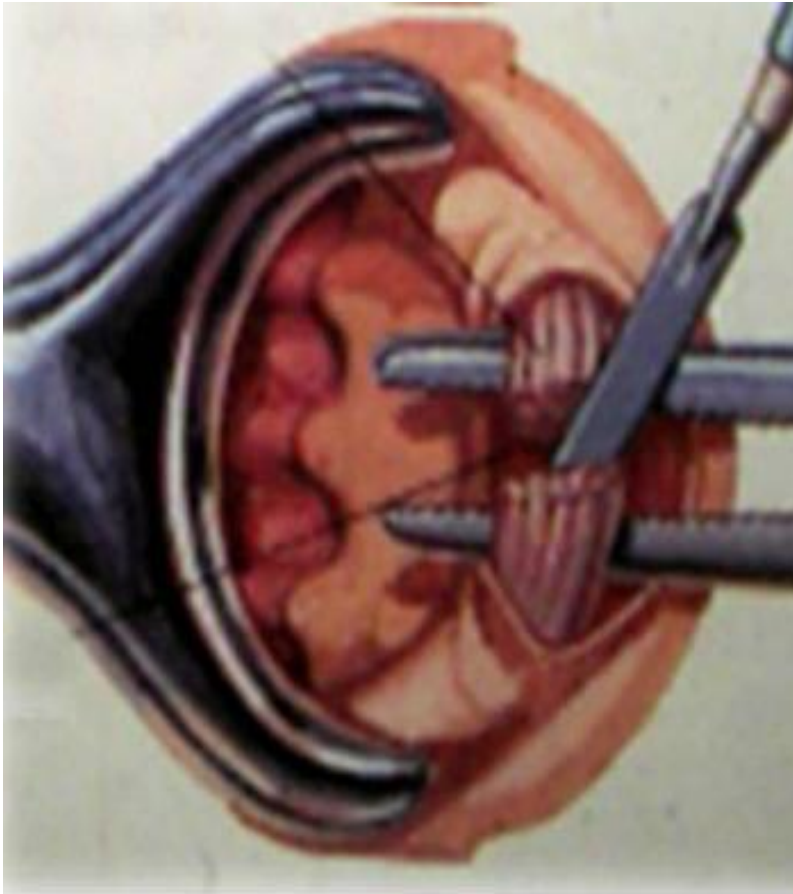
Treatment

- Emphasis must be placed on normalisation of bowel habits
- The addition of fibre to the diet to bulk up the stool, stool softeners and adequate water intake are simple and helpful measures.
- Warm baths and topical local anaesthetic agents relieve pain;

- 
- topical application of pharmacological agents that relax the internal sphincter,
 - most commonly nitric oxide donors (by reducing spasm, pain is relieved, and increased vascular perfusion promotes healing.
 - Such agents include glyceryl trinitrate (GTN) 0.2 per cent applied four times per day to the anal margin (although this may cause headaches) and
 - diltiazem 2 per cent applied twice daily.

Operative measures

- **Lateral anal sphincterotomy**
- the internal sphincter is divided away from the fissure itself – usually either in the right or the left lateral positions
- **Anal advancement flap**
- After excision of the edges of the fissure , an inverted house-shaped flap of perianal skin is carefully mobilised on its blood supply and advanced without tension to cover the fissure, and then sutured



Treatment of an anal fissure

- Conservative initially, consisting of stool-bulking agents and softeners, and chemical agents in the form of ointments designed to relax the anal sphincter and improve blood flow
- Surgery if above fails, consisting of lateral internal sphincterotomy or anal advancement flap

HAEMORRHOIDS

- Internal haemorrhoids (Greek: *haima*, blood; *rhoos*, flowing; synonym: piles, Latin: *pila*, a ball) are symptomatic anal cushions and characteristically lie in the 3, 7 and 11 o'clock positions (with the patient in the lithotomy position).
- External haemorrhoids relate to venous channels of the inferior haemorrhoidal plexus deep in the skin surrounding the anal verge

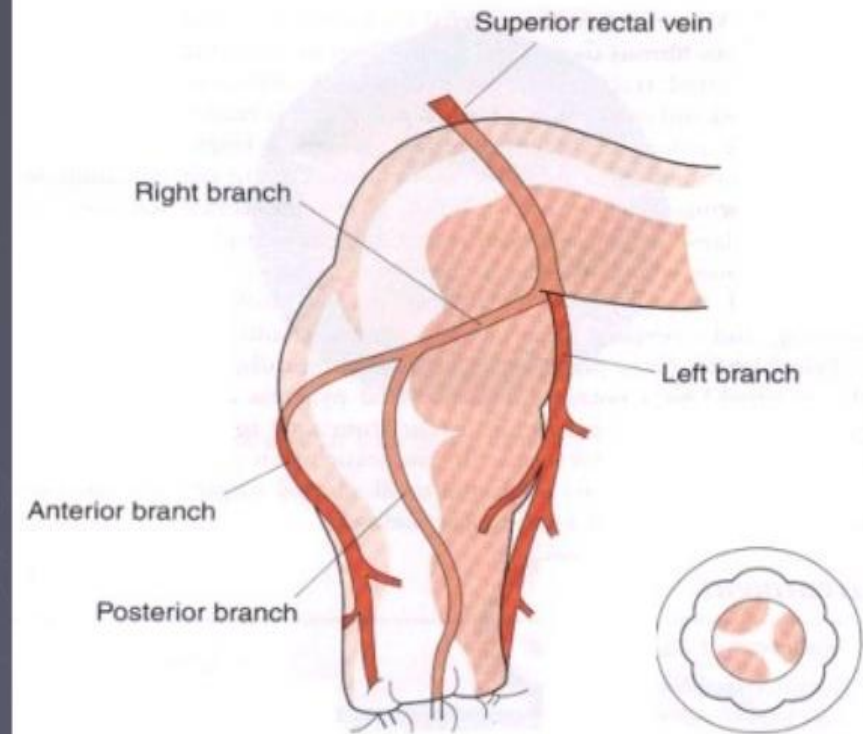
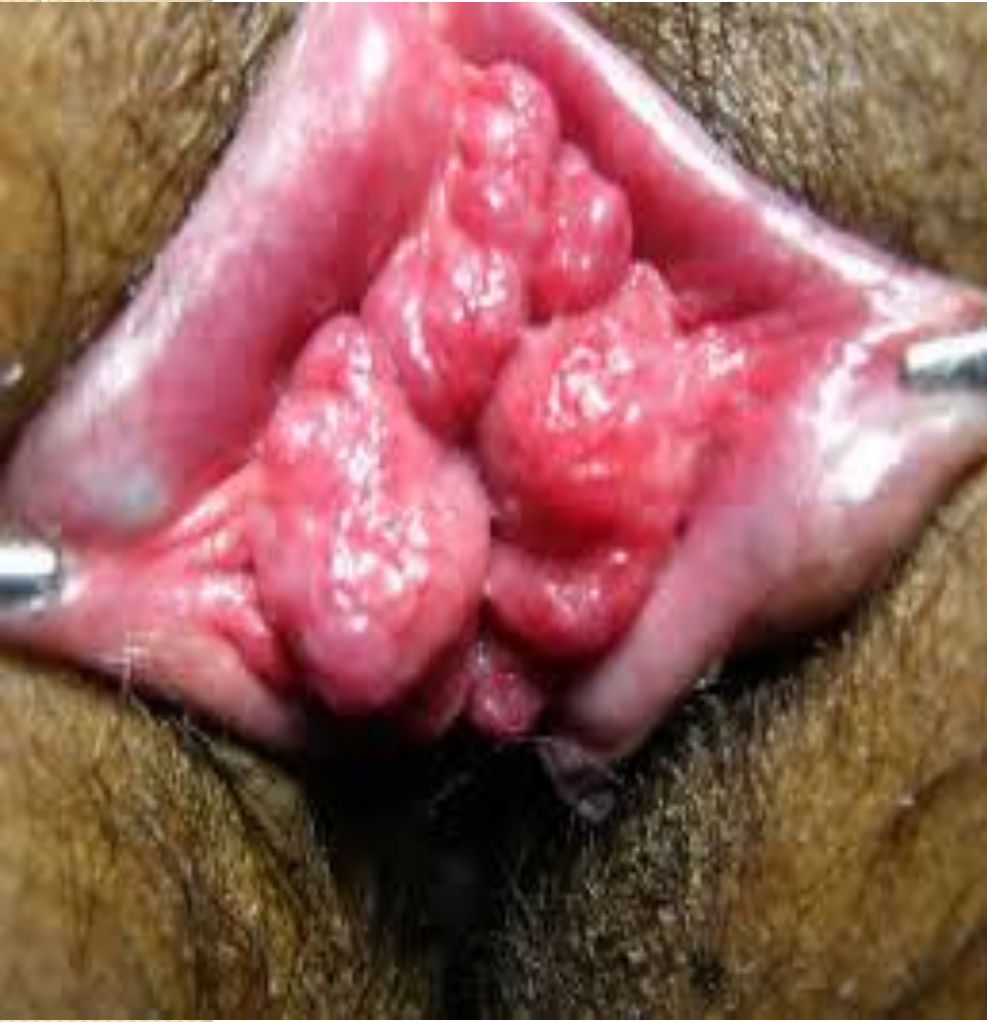
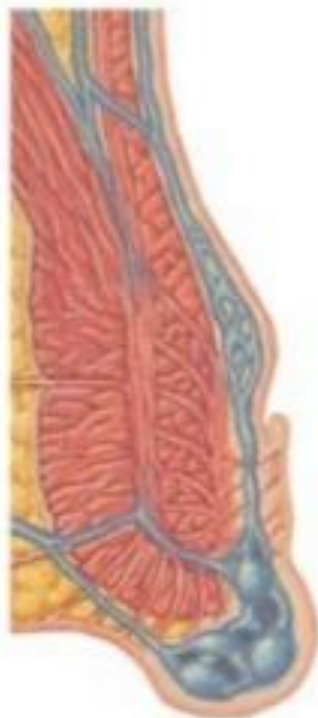
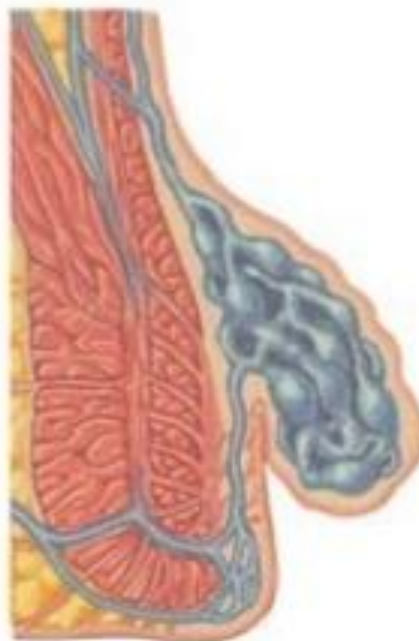Fig. 61.25 Disposition of anal vasculature illustrating why haemorrhoids are classically sited at 3, 7 and 11 o'clock.

External hemorrhoid



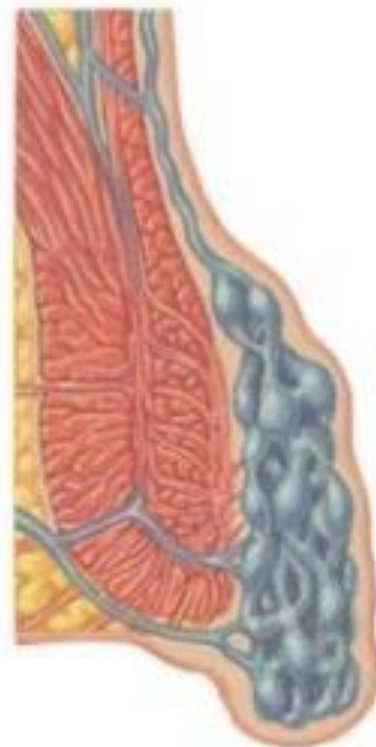Origin below dentate line
(external rectal plexus)

Internal hemorrhoid



Origin above dentate line
(internal rectal plexus)

Mixed hemorrhoid




Origin above and below dentate line
(internal and external rectal plexus)

Theories of development

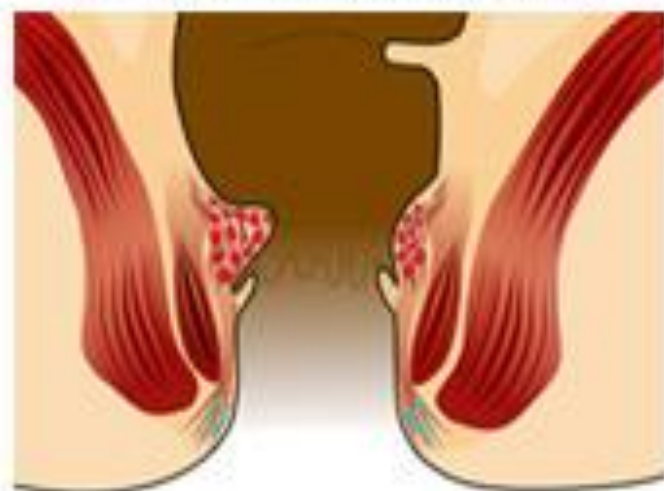- Portal hypertension and varicose veins
- Infection
- Diet and stool consistency
- Anal hypertonia
- Ageing
- **Current view** : Shearing forces acting on the anus (for a variety of reasons) lead to caudal displacement of the anal cushions and mucosal trauma. With time, fragmentation of the supporting structures (a normal consequence of ageing, but perhaps accelerated in those with haemorrhoids) leads to loss of elasticity of the cushions such that they no longer retract following defaecation

Clinical features

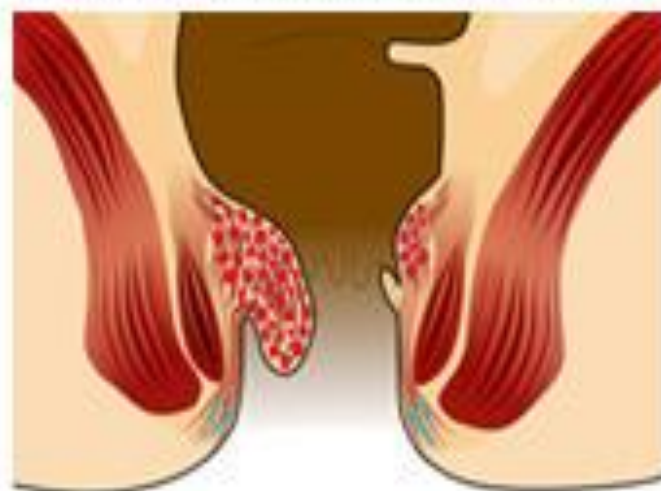- **Bleeding**, {usually painless} is the principal and earliest symptom. The nature of the bleeding is characteristically separate from the motion and is seen either on the paper on wiping or as a fresh splash in the pan. Sometimes , the bleeding may be sufficient to cause anaemia.
- Piles associated with bleeding alone are called first-degree haemorrhoids

- 
- Patients may complain of true ‘piles’, lumps that appear at the anal orifice during defaecation and which return spontaneously afterwards (second-degree haemorrhoids),
 - piles that have to be replaced manually (third-degree haemorrhoids)
 - or piles that lie permanently outside (fourth-degree haemorrhoids).

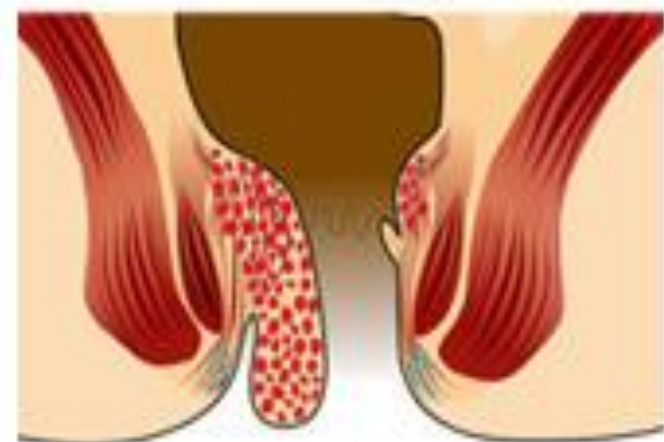
1st Degree: No Prolapse.
Just prominent blood vessels



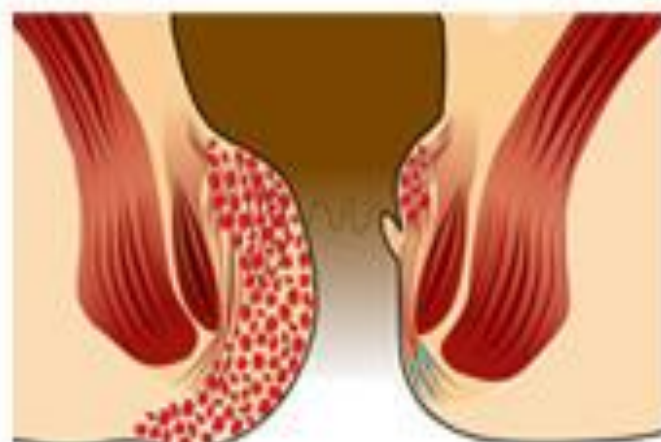
2nd Degree: Prolapse upon bearing down but spontaneously reduced.



3rd Degree: Prolapse upon bearing down and requires manual reduction.



4th Degree: Prolapsed and cannot be manually reduced.



Haemorrhoids: clinical features

- Haemorrhoids or piles are symptomatic anal cushions
- They are more common when intra-abdominal pressure is raised, e.g. in obesity, constipation and pregnancy
- Classically, they occur in the 3, 7 and 11 o'clock positions with the patient in the lithotomy position
- Symptoms of haemorrhoids:
 - bright-red, painless bleeding
 - mucous discharge
 - prolapse
 - pain only on prolapse

Complications of haemorrhoids

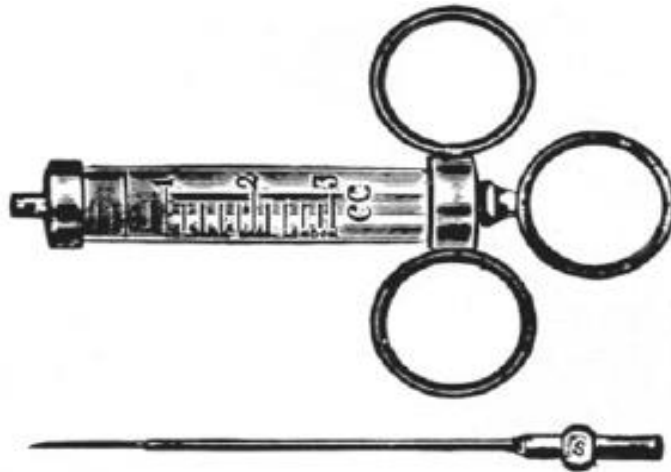
- Strangulation and thrombosis (Figure 73.28)
- Ulceration
- Gangrene
- Portal pyaemia
- Fibrosis

Management

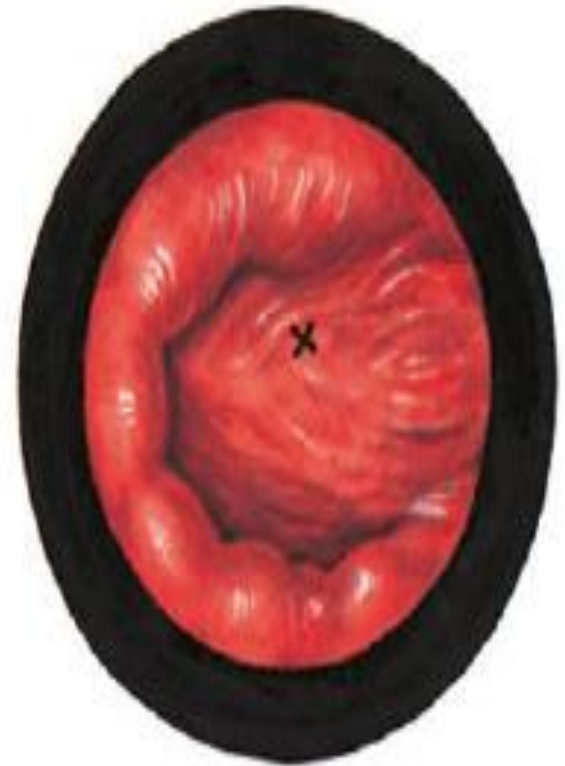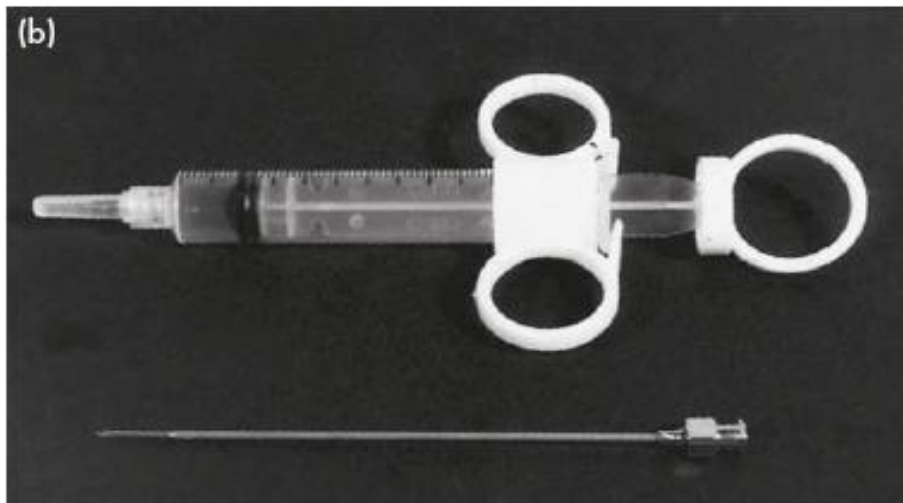
- Exclusion of other causes of rectal bleeding, especially colorectal malignancy, is the first priority.
- normalising bowel and defaecatory habits:
- stool softeners and bulking agents.
- In those with first- or second-degree piles whose symptoms are not improved by conservative measures, injection sclerotherapy the submucosal injection of 5 per cent phenol in arachis oil or almond oil, may be advised.

injection sclerotherapy

(a)




(b)



Correct site (cross) for injecting a haemorrhoid

Figure 73.30 Gabriel's syringe (a) has now been replaced by disposable syringes (b).

1111

- 
- The Barron' bander is a commonly available device used to slip tight elastic bands onto the base of the pedicle of each hemorrhoid The bands cause ischaemic necrosis of the piles{ 2nd degree hemorrhoid } .

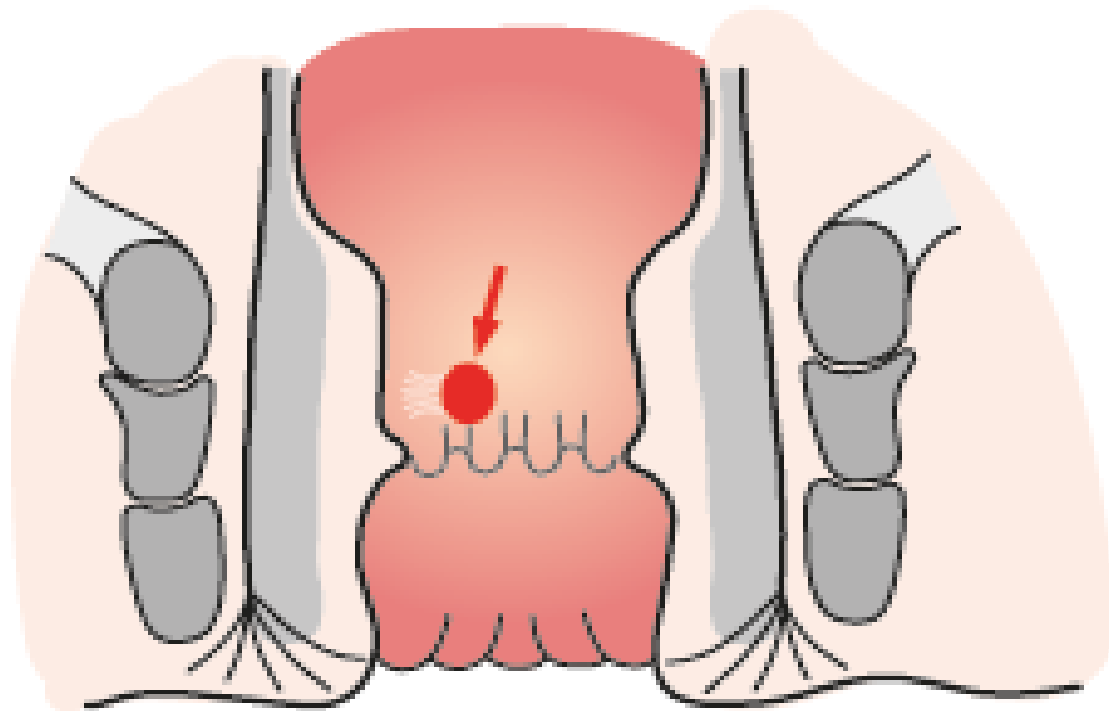



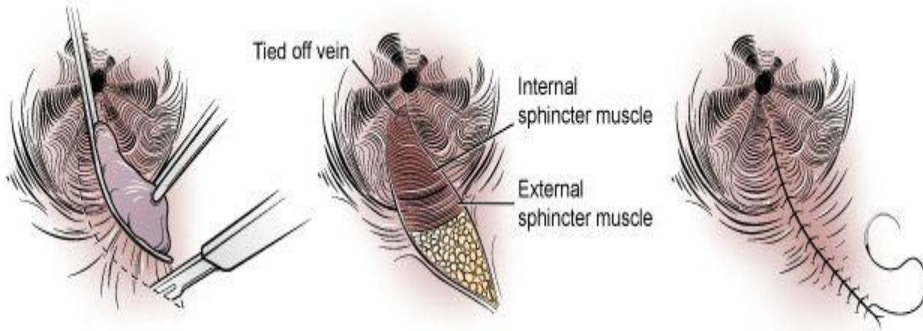
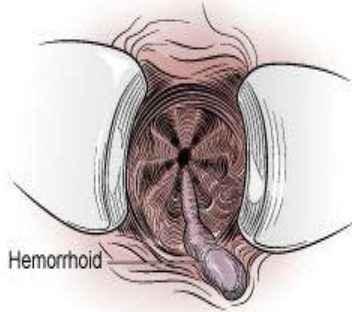
Figure 73.31 Barron's banding apparatus, with the appearance of a typical 'banded' haemorrhoid.

Operation

- Indications
- The indications for haemorrhoidectomy include:
 - • third- and fourth-degree haemorrhoids;
 - • second-degree haemorrhoids that have not been cured by non-operative treatments;
 - • fibrosed haemorrhoids;
 - • interoexternal haemorrhoids when the external haemorrhoid is well defined.

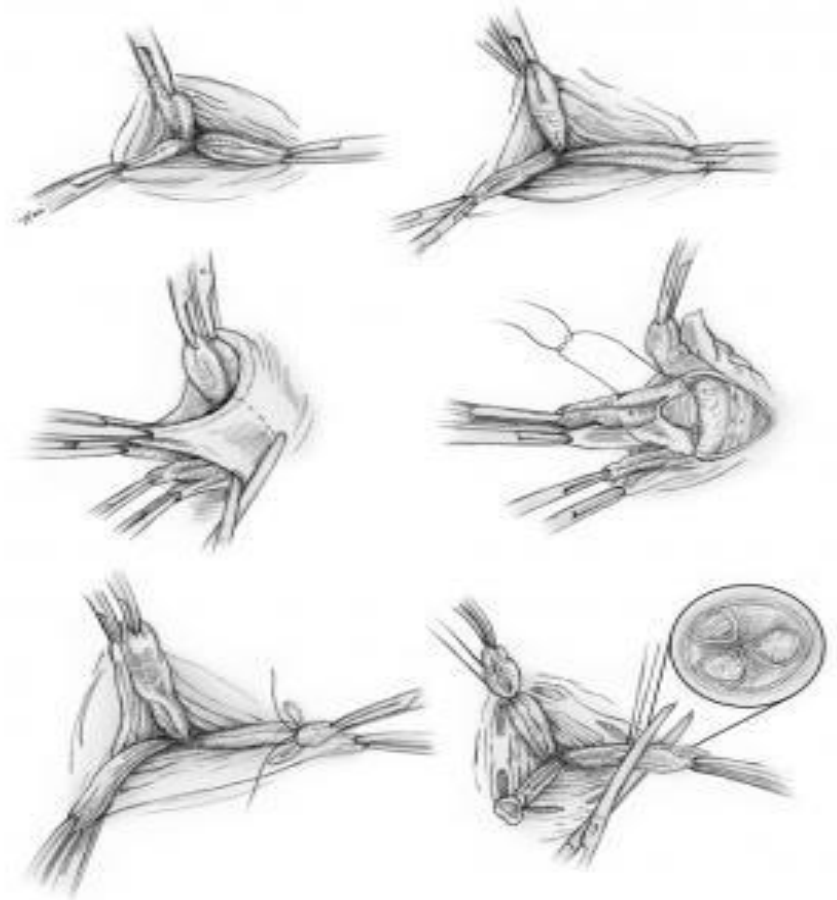
Closed

Closed Hemorrhoidectomy



The hemorrhoid is grasped and an incision is made around the hemorrhoid. The vein inside the hemorrhoid is tied off and the hemorrhoid is excised from the subcutaneous portion of the external and internal sphincters. The opening is then closed.

open

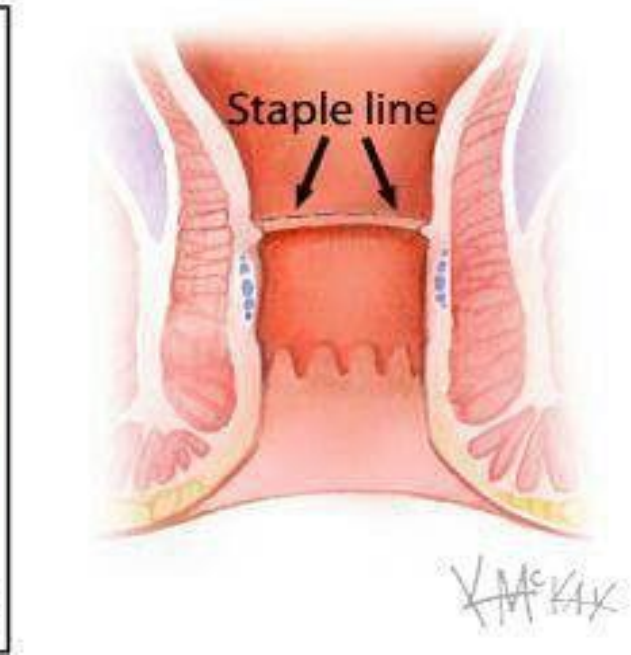
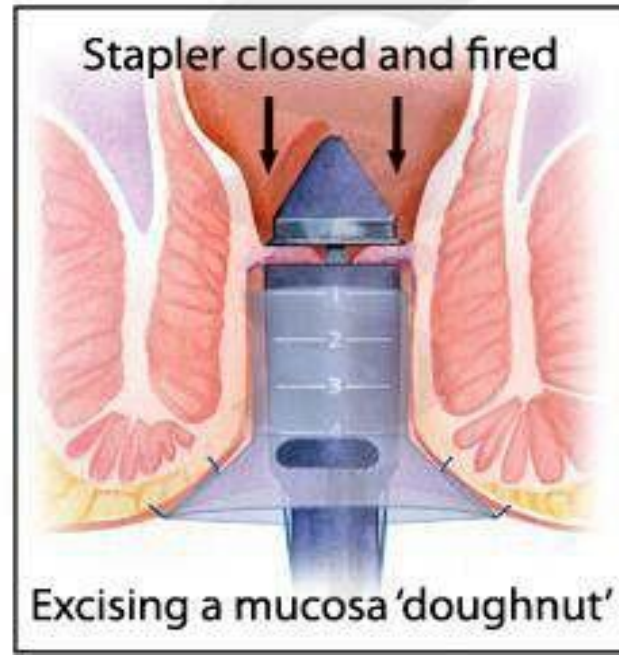
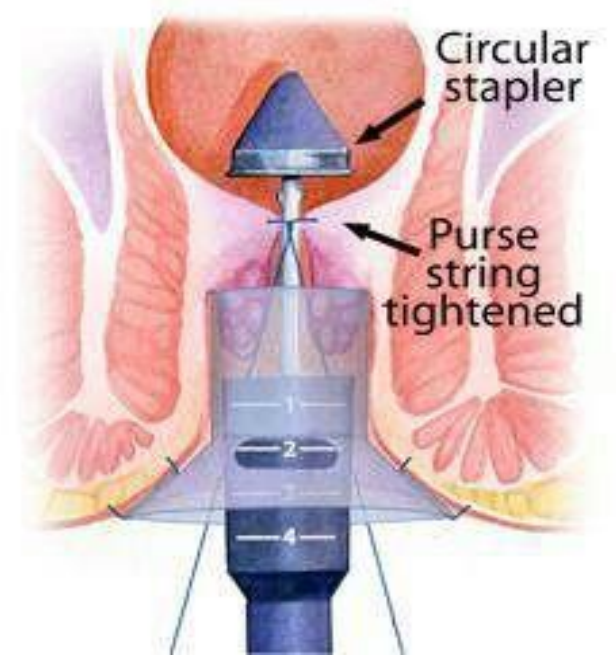
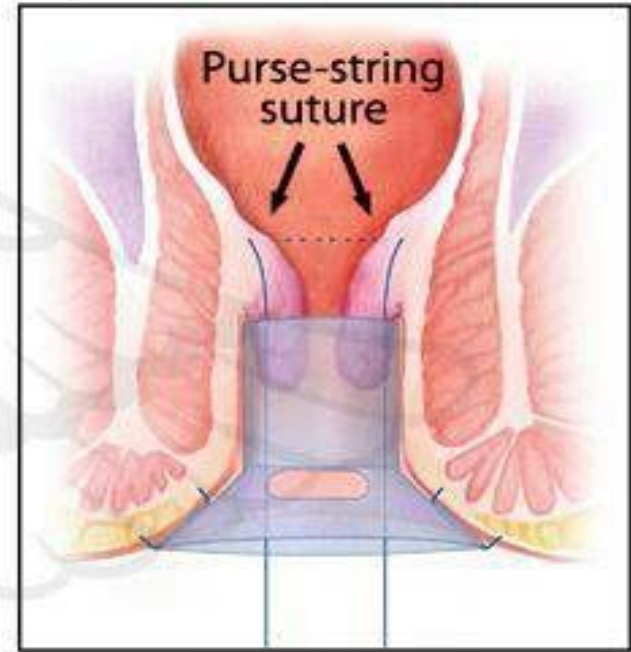
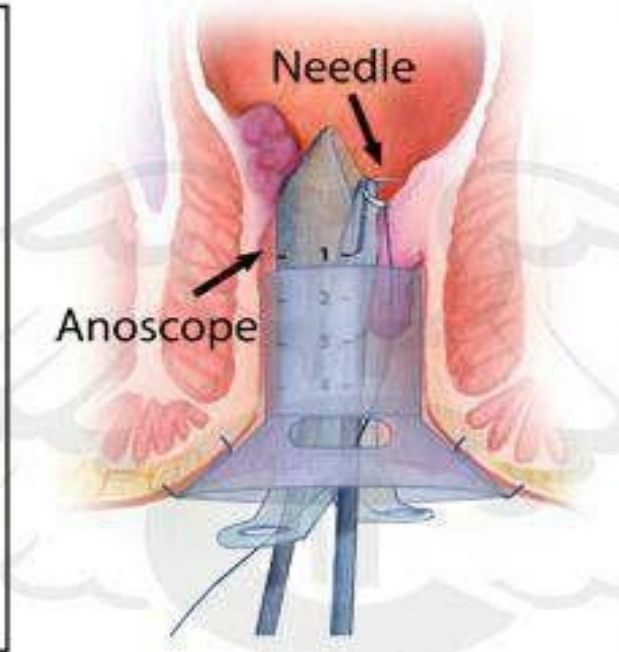
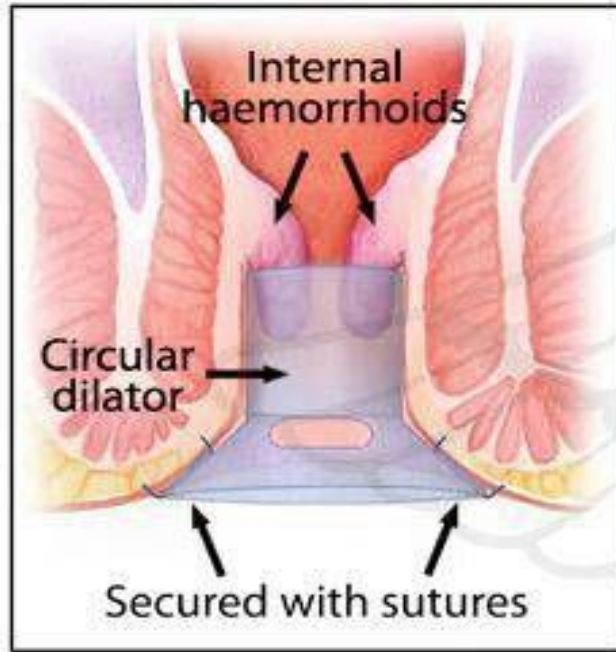


Open and closed hemorrhoidectomy

stapled haemorrhoidopexy

- utilises a purpose-designed stapling gun
- This procedure excises a strip of mucosa and submucosa (together with the vessels travelling within them) circumferentially, well above the dentate line

Stapled Haemorrhoidectomy



V. Mc KAY

Transanal haemorrhoidal dearterialisation

- is used for the treatment of second- and third-degree haemorrhoids. Some have recently advocated transanal Doppler-guided ligation of those vessels feeding the haemorrhoidal masses, to which others have added suture 'mucopexy' to deal with any prolapse

Treatment of haemorrhoids

- Symptomatic – advice about defaecatory habits, stool softeners and bulking agents
- Injection of sclerosant
- Banding
- Transanal haemorrhoidal dearterialisation/haemorrhoidopexy
- Haemorrhoidectomy

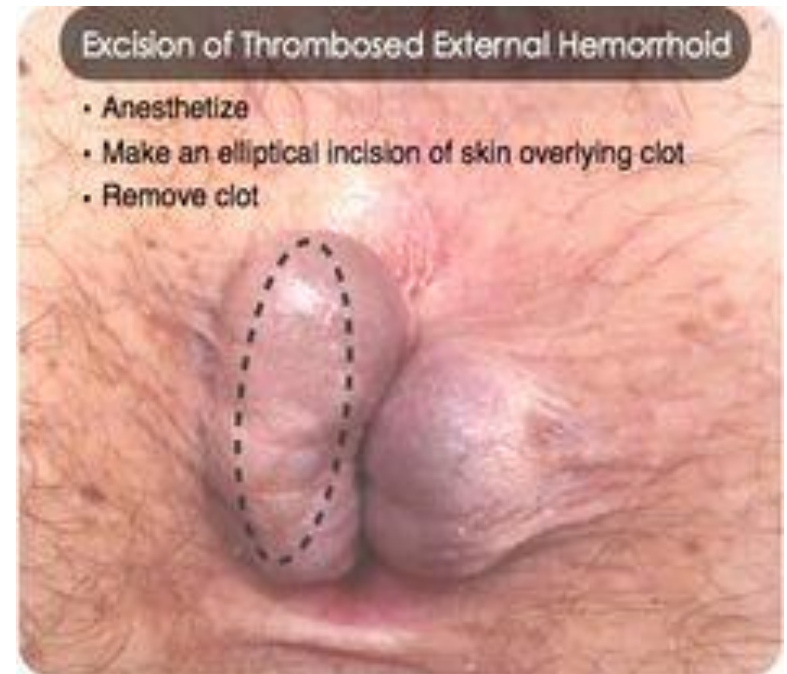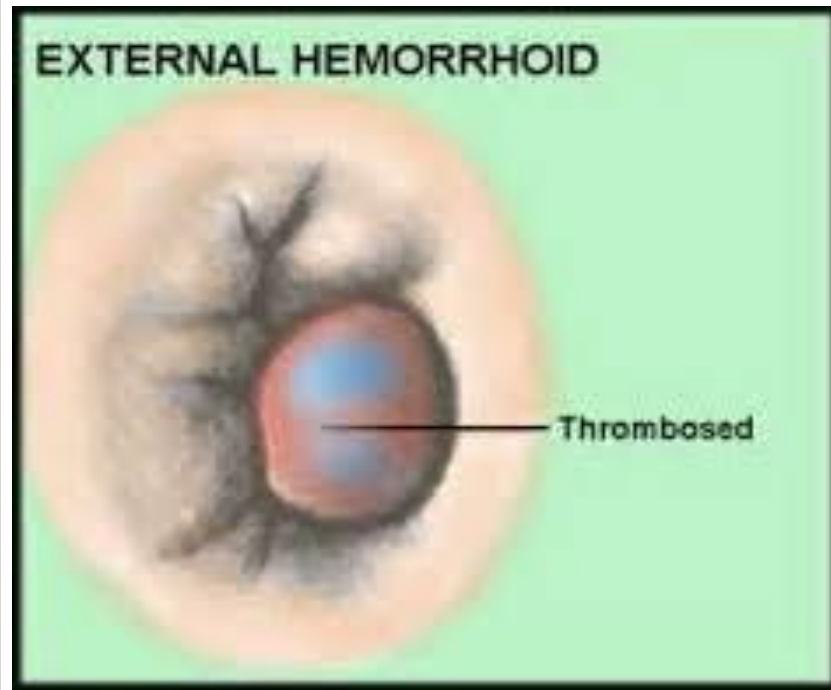
Complications of haemorrhoidectomy

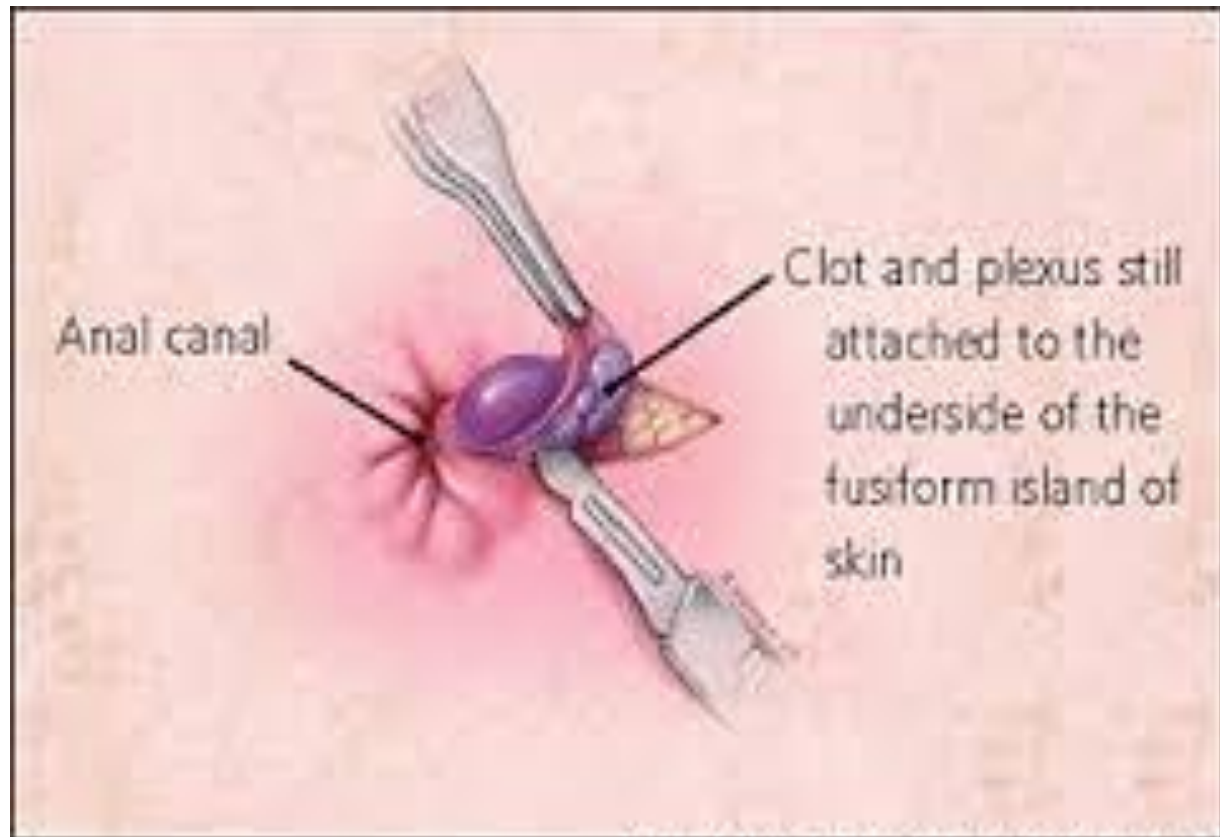
- Early
 - Pain
 - Acute retention of urine
 - Reactionary haemorrhage
- Late
 - Secondary haemorrhage
 - Anal stricture
 - Anal fissure
 - Incontinence

External haemorrhoids

- A thrombosed external haemorrhoid relates anatomically to the veins of the superficial or external haemorrhoidal plexus and is commonly termed a 'perianal haematoma'.
- It presents as a
- sudden onset, olive-shaped, painful blue subcutaneous swelling at the anal margin and is usually consequent upon straining at stool, coughing or lifting a heavy weight

- If the patient presents within the first 48 hours, the clot may be evacuated under local anaesthesia.





Anal canal

Clot and plexus still attached to the underside of the fusiform island of skin

PRURITUS ANI

- This is intractable itching around the anus, a common and embarrassing condition. Usually, the skin is reddened and hyperkeratotic and it may become cracked and moist.

Causes

- **Lack of cleanliness,**
- **anal or perianal discharge**
- **Vaginal discharge**
- **Parasitic causes. Threadworms should be excluded,**
- **Epidermophytosis**
- **Allergy**
- **Skin diseases**
- **psychoneurosis. And Diabetes**

Pruritus ani

- Common
- Numerous causes including skin diseases, parasites (threadworm), anal discharge, allergies, diabetes
- Treat the cause if possible
- Symptomatic treatment is the mainstay