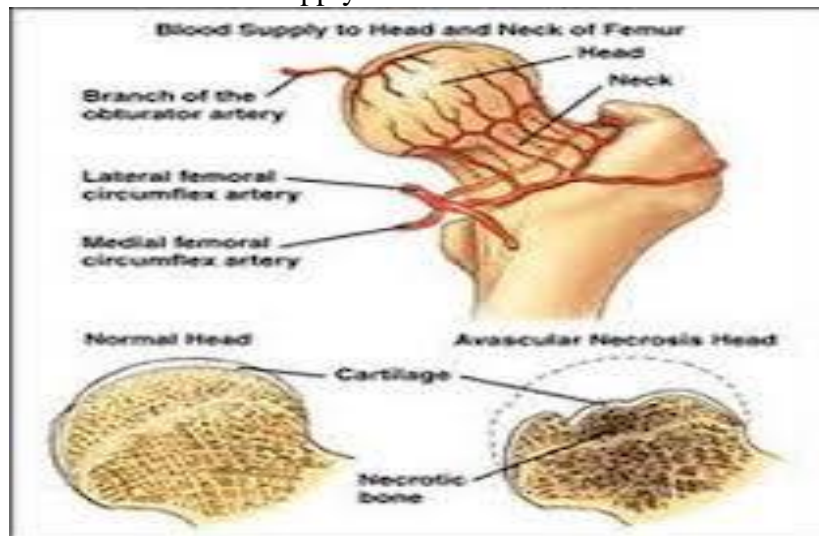


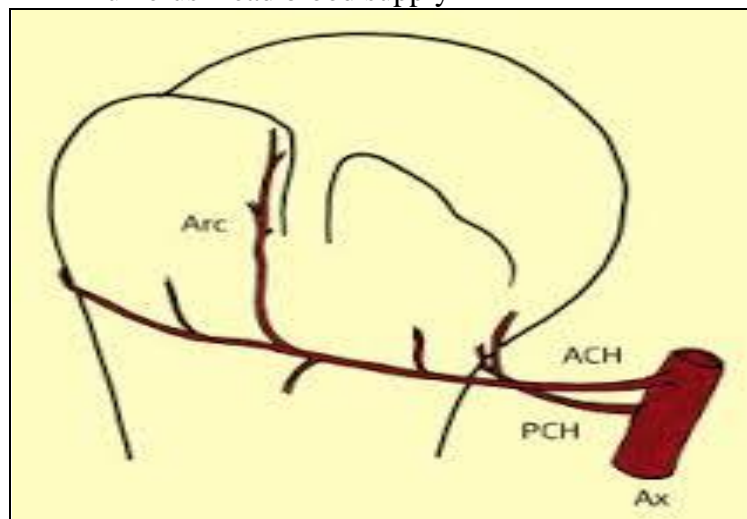
### **Avascular necrosis; AVN( Osteonecrosis, Bone infarction, Ischemic bone necrosis)**

Is a disease where there is cellular death (necrosis) of bone components due to interruption of the blood supply .Without blood, the bone tissue dies & the bone collapse. If AVN involve the bones of the joint, it often leads to destruction of the joint articular surface.

#### **Femoral head blood supply**



#### **Humerus head blood supply**



;

### **Causes**

There are many theories about what causes AVN. Proposed risk factors include, alcoholism, excessive steroid use, post trauma, caisson disease (decompression sickness), hypertension , vasculitis , radiation , chemotherapy , sickle cell aneamia, Gaucher's disease, rheumatoid arthritis, SLE & in some cases it is idiopathic(no cause is found).

**Pathology;**

The hematopoietic cells are most sensitive to anoxia & the first to die after reduction or removal of the blood supply, usually within 12 hours. Experimental evidence suggests that bone cells die within 12-48 hours, and that bone marrow fat cells die within 5 days. Upon reperfusion, repair of ischemic bone occurs in 2 phases; First, there is angiogenesis & movement of undifferentiated mesenchymal cells from adjacent living bone tissue grow into the dead marrow spaces, as well as entry the macrophages that degrade dead cellular & fat debris. Second, there is cellular differentiation of mesenchymal cells into osteoblasts or fibroblasts. Under favorable conditions, the remaining inorganic mineral volume forms a framework for establishment of new, fully functional bone tissue.

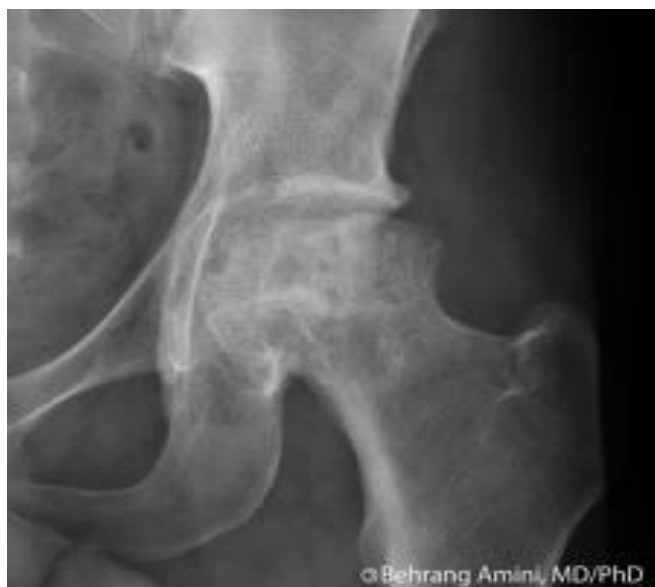**Clinical feature;**

AVN usually affects people between 30-50 years of age, the disease may affect just one bone, more than one bone at the same time or more than one bone at different time. Clinical AVN most common affects the ends(epiphysis) of long bones such as the femur( most common head of femur), other common sites include the humerus, condyle of femur, neck of talus & waist of scaphoid. Pain, limitation of movement of joint are the major classical feature of AVN.

**Diagnosis;**

In early stages, bone scan scintigraphy & MRI are the diagnostic modalities of choice. X-ray images of AVN in the early stages usually appear normal. In later stages it bone become resorped secondary to hyperemia, collapse of subchondral bone (crescent sign) & later resorption of the head of femur or humerus with arthritic changes. Also investigations of underlying diseases.

**X-Ray of hip joint**



**Treatment;**

AVN is especially common in the hip joint. A variety of methods are now used to treat AVN depend on;

- Stages of AVN
- Clinical signs and symptoms
- Physiologic condition
- Age
- Medical co morbidities

**Observation;**

- Normal x-ray
- Possible abnormal MRI
- No clinical signs.

**Core decompression with or without bone graft;**

- Normal X-ray.
- Abnormal MRI.
- Clinical signs & symptoms.

**Total hip replacement;**

- Age more than 50 years.
- X-ray showing severe arthritic changes (late stage).

## **Osteochondrosis;**

Is a term used to describe a group of disorders that affect the growing skeleton. these disorders result from abnormal growth , injury, or overuse of the developing growth plate & surrounding ossification centers ,resulting in fragmentation, segmentation of bone & overlying articular of the joint. The exact etiology of these disorders is unknown, but genetic causes, repetitive trauma , vascular abnormalities, mechanical factors & hormonal imbalance may all play a role, leading to failure of chondrocyte differentiation, subchondral bone necrosis& failure of blood supply to the growth cartilage then reperfusion & subsequent neo-ossification .generally symptoms appear between 10 and 14 years of age, boys are more commonly affected because of their greater susceptibility to childhood trauma & overuse injury.Areas of body most affected include the hip ,knee,foot,elbow& back.

### **Classifications;** we have 3 type

1-crushing type; occur in 2<sup>nd</sup> & 3<sup>rd</sup> metatarsal head called (*Freiberg's disease*) or navicular bone (*Kohler 's disease*),lunate of carpal bone(*Kienbock's disease*),head of femur(*perth's disease*).X-ray showing fragmentation & flattening of bone involved with sclerosis. treatment by rest & analgesia to prevent progression of the disease.

2-Traction type; mainly occur near attachment of achills tendon to apophysis of heel causing painful heel in childhood & adolescent called *Sever's disease* or around the attachment of pattellar tendon to tibial tuberosity called (*Osgood schlatter's disease*).X-ray showing fragmentation at site of attachment of tendon to bone. Rest & analgesia are important in treatment.

3-osteochondritis dessecans; mostly occur in lateral condyle of femur or talar dome usually the necrotic segment may separate & form as a loose body in the joint causing locking & severe pain in joint , X-ray may be normal in early stage of the disease when fragment still in it's place( not separated) & in this stage CT scan is indicated & later showing loose body in joint.tretment, in early stage by rest & analgesia , later when segment is separated ,if it's small excised it & drilling the site of defect(crater) to enhance growth ,if it's large fixation to it's place by screw.