

Salivary gland disorders

Dr. zaeem dahla
General surgeon MD

objectives

- To know the surgical anatomy of salivary glands.
- Autonomic innervations of SG and its effect on function .
- Inflammatory disorder of SG.
- Obstructive disorders.
- Neoplasm of SG.

Disorders of the salivary glands

There are many salivary glands, two submandibular glands, two sublingual glands and two parotid glands. In addition, there are multiple minor salivary glands.

Minor Salivary Glands

Anatomy

The mucosa of the oral cavity contains approximately 450 minor salivary glands. They are distributed in the mucosa of the lips, cheeks, palate, floor of the mouth, retromolar area, oropharynx, larynx and trachea as well as sinuses.

Common disorders of minor salivary glands

Cysts

Extravasation cysts are common and result from trauma to the overlying mucosa. They affect the lower lip, painless swelling, but not always, translucent. Some resolve spontaneously, but most require surgical excision.

Tumors

Histologically similar to those of major glands; however, up to 90% of minor salivary gland tumors are malignant. Common sites for tumor formation include the upper lip, palate and retro molar regions. Less common sites for minor salivary gland tumors include the nasal and pharyngeal cavities.

Benign minor salivary glands tumors present as painless , firm, slow growing swellings. Benign tumors less than 1 cm in diameter, can be managed by excisional biopsy, and the defect is allowed to heal by secondary intention .Where tumors of the palate are greater than 1 cm in diameter, incisional biopsy is recommended to establish a diagnosis prior to formal excision. Malignant minor salivary gland tumors are rare .They have a firm consistency , and may become necrotic with ulceration as a late presentation.

Malignant minor salivary gland tumors of the palate are managed by wide excision which may involve partial or total maxillectomy. The defect can be managed by either prosthetic obturation or immediate reconstruction,by using various micro vascular flaps.

The sublingual glands

Anatomy

The glands are a paired set of minor salivary glands lying in the anterior part of the floor of the mouth between the mucous membrane, the mylohyoid muscle and the body of the mandible close to the mental symphysis. Each gland has numerous excretory ducts that open either directly into the oral cavity or indirectly via ducts that drain into the submandibular duct.

Common disorders

Cysts

Minor mucous retention cysts develop in the floor of the mouth either from an obstructed minor salivary gland or from the sublingual salivary gland.

The term “ranula” should be applied only to a mucous extravasation cyst that arises from a sublingual gland. It produces a characteristic translucent swelling that takes on the appearance of a “frog's belly” (ranula).

A ranula can resolve spontaneously, but many also require formal surgical excision of the cyst and the affected sublingual gland.

Plunging ranula

Is a rare form of mucous retention cyst that can arise from both sublingual and submandibular salivary gland.

Mucus collects within the cyst, which perforates through the mylohyoid muscle diaphragm to enter the neck, which presents with a dumbbell-shaped swelling that is soft, fluctuant and painless in the submandibular or submental region of the neck.

Diagnosis:

U/S or MRI. Excision is usually performed via a cervical approach removing the cyst and both the submandibular and sublingual glands. Smaller plunging ranula can be treated by transoral sublingual gland excision.

Tumors

Extremely rare and are usually (85%) malignant. They present as a hard or firm painless swelling in the floor of the mouth. Treatment requires wide excision and neck dissection.

The submandibular glands

Anatomy

They are paired salivary glands that lie below the mandible on either side. They consist of a larger superficial and a smaller deep lobe that are continuous around the posterior border of the mylohyoid muscle . Important anatomical relations include the anterior facial vein running over the surface of the gland and the facial artery. The deep part of the gland lies on the hyoglosses muscle closely related to the lingual nerve and inferior to the hypoglossal nerve. The gland surrounded by a well defined capsule that is derived from the deep cervical fascia which split to enclose it . The gland is drained by a single submandibular duct (Wharton"s duct).It drains into the anterior floor of the mouth at the sublingual papilla. There are several lymph nodes immediately adjacent and sometimes within the superficial part of the gland.

Ectopic/ aberrant salivary gland tissue

The most common ectopic salivary tissue is the Stafne bone cyst, clearly demarcated radiolucency of the angle of the mandible. No treatment is required.

Inflammatory disorders of the submandibular gland

Inflammation of the submandibular gland is termed sialadenitis, which may be acute, chronic or acute on chronic.

Common causes are ;

1- Acute submandibular sialadenitis.

(a) Viral. The paramyxovirus (mumps) is a viral illness of the salivary glands that usually produces parotitis. The submandibular glands are occasionally involved, causing painful tender swollen glands.

(b) Bacterial. Bacterial sialadenitis is more common than viral sialadenitis and occurs secondary to obstruction . Following infection and despite control of acute symptoms with antibiotics, the gland frequently becomes chronically inflamed and requires formal excision.

2- Chronic submandibular sialadenitis.

Obstruction and trauma

The most common cause of obstruction within the submandibular gland is stone formation (sialolithiasis) within the gland and its associated duct system. 80% of salivary stones occur in the submandibular glands because their secretions are highly viscous .80% of submandibular stones are radio-opaque & can be identified on plain radiography.

Clinical symptoms

Acute painful swelling in the region of the submandibular gland , precipitated by eating. The swelling occurs rapidly and often resolves spontaneously over 1_2 hours after the meal is completed. This classical picture occurs when the stone causes complete obstruction , usually at the opening of the submandibular duct, if only partial obstruction , symptoms are more infrequent, producing minimal discomfort and swelling , not confined to mealtimes. Clinical examination reveals an enlarged firm submandibular gland , tender on bimanual examination. Pus may be visible ,draining from the sublingual papilla, the consequence of chronic and non- specific bacterial infection.

Management

If the stone is lying within the submandibular duct in the floor of the mouth anterior to the point at which the duct crosses the lingual nerve (second molar region), the stone can be removed by incising longitudinally over the duct . If the stone is proximal to the lingual nerve i.e. at the hilum of the gland ,treatment is by simultaneous submandibular gland excision and removal of the stone .Other causes of submandibular duct obstruction include external pressure,particularly trauma to the floor of the mouth ,as result from an overextended flange on a lower denture.

Submandibular gland excision

Indications;

- 1- Sialadinitis
- 2- Salivary tumors
- 3- Stone in the proximal duct

Complications;

1. Haematoma
2. Wound infection;
3. Marginal mandibular nerve injury;
4. Lingual nerve injury;
5. Hypoglossal nerve injury;
6. Transection of the nerve to the mylohyoid muscle producing submental skin anesthesia.

Tumors of submandibular glands

- . Are uncommon
- . Slow-growing, painless swelling
- . 50% are benign
- . Pain in both benign& malignant tumors

Clinical features

- 1** Facial nerve weakness.
- 2** Rapid enlargement of the swelling
- 3** Indurations and / or ulceration of the overlying skin
- 4** Cervical node enlargement

Investigation

- 1** CT scan and MRI
- 2** FNAC

Note; Open surgical biopsy is contraindicated as this may seed the tumor into surrounding tissue.

Management;

Surgical excision. If malignancy , modified neck dissection.

The parotid gland

Anatomy

The parotid gland lies in a recess bounded by the ramus of the mandible, the base of the skull and the mastoid process. It lies on the carotid sheath and the XIth and XIIth cranial nerves and extends forward over the masseter muscle. The gland is enclosed in a sheath of dense deep cervical fascia. Its upper pole extends just below the zygoma and its lower pole into the neck.

Several important structures run through the parotid gland ;

- 1** branches of the facial nerve .
- 2** the terminal branch of the external carotid artery that divides into the maxillary artery and the superficial temporal artery.
- 3** the retromandibular vein.
- 4** intraparotid lymph nodes.

The gland is divided into deep 20% and superficial lobes 80% by the facial nerve.

Developmental disorders

- . Agenesis
- . Duct atresia
- . Congenital fistula

All are extremely rare.

Inflammatory disorders

Viral infections

Mumps is the most common cause of acute painful parotid swelling and predominantly affect children. Symptoms resolve within 5-10 days. Treatment is symptomatic with paracetamol and adequate oral fluid intake. Complications of orchitis, oophoritis, pancreatitis, sensorineural deafness and meningoencephalitis. Other viral agents Coxsackie A and B, parainfluenza 1 and 3, Echo and lymphatic choriomeningitis.

Bacterial infections

Acute ascending bacterial infection, the infecting organism is usually *Staphylococcus aureus* or *Streptococcus viridans* treated by antibiotics. If the gland becomes fluctuant, U/S to identify abscess formation that may require aspiration or drainage. Chronic infection is rare.

Recurrent parotitis of childhood

Unknown aetiology, children usually present between the age of 3 and 6 years. The diagnosis is based on characteristic history and sialography 'snowstorm' appearance. Treatment by antibiotics or may require total conservative parotidectomy.

Human immunodeficiency virus (HIV)- associated sialadenitis

Chronic parotitis in children is the pathognomonic of HIV infection. It is similar to classical Sjogren's syndrome in adulthood . CT and MRI demonstrate the characteristic 'Swiss cheese' appearance of multiple large cystic lesions.

Obstructive parotitis

Intermittent painful swelling of the parotid gland, particularly at mealtimes.

Causes ;

- 1** Papillary obstruction .
- 2** Stone formation.

Papillary obstruction;

Can be caused by trauma to parotid papilla through either an overextended upper denture flange or fractured upper molar teeth.
Treated by papillotomy.

Stone formation

gland Less common in the parotid 20% than in the submandibular 80%. Parotid duct stones are usually radiolucent and rarely visible on plain radiography, parotid gland sialography is usually required to identify the stone, which needs surgical removal.

Tumors of the parotid gland

The parotid gland is the most common site of salivary tumors.

Most commonly arise in the superficial lobe.

Present as slow-growing, painless swelling below the ear, in front the ear.

Rarely arise from the deep lobe of the gland and present as parapharyngeal masses, symptoms include difficulty in swallowing and snoring. Clinical examination reveals a diffuse firm swelling in the soft palate and tonsil.

80% - 90% of parotid tumors are benign, the most common tumors being pleomorphic adenoma.

Neoplasms of the salivary gland

- 75% occur in the parotid glands.
 - In parotid glands, 80% of tumors are benign.
 - Of these 80% are Pleomorphic adenomas.
- 15% of salivary tumors occur in submandibular glands.
 - Of these 50% are benign and 50% are malignant.
- In carcinomas mucoepidermoid ca > adenoid cystic ca > adenocarcinoma

- 10% of salivary tumors occur in sublingual and minor salivary glands
 - 60-70% of these are malignant

Classification

- A. Epithelial tumors
- B. Connective tissue tumors
- C. Metastatic tumors

A. Epithelial tumors

- Benign
 - Pleomorphic adenoma (Mixed tumor)
 - Oxyphil adenoma
 - Papillary cystadenoma lymphomatosum (Warthin's tumor)
 - Basal cell adenoma

Epithelial tumors

- Malignant
 - Mucoepidermoid carcinoma
 - Adenoid cystic carcinoma
 - Acinic cell ca
 - Papillary adenocarcinoma
 - SCC
 - Undifferentiated ca
 - Ca arising in pleomorphic adenoma

Connective tissue tumors

- Benign
 - Hemangioma
 - Lipoma
 - Neurilemmoma
 - Fibroma
- Malignant
 - Malignant lymphoma
 - Above mentioned benign tumors may turn malignant.

Pleomorphic adenoma

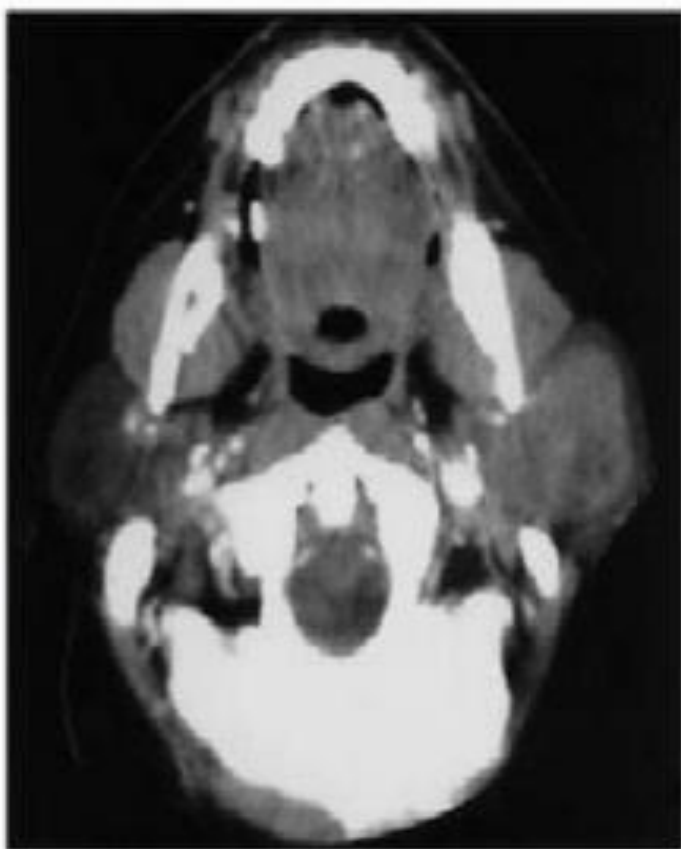
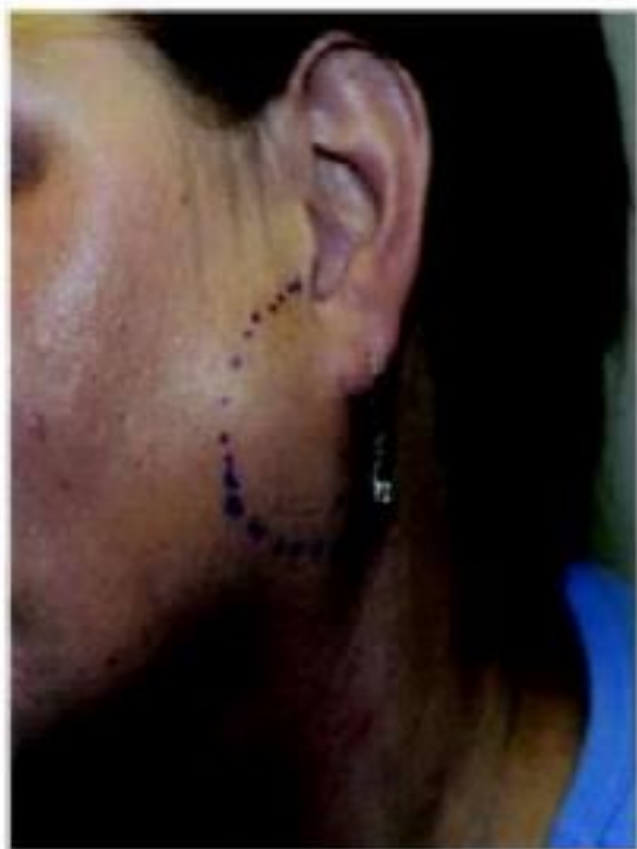- 'Mixed tumor'
- Commonest tumor of salivary glands.
- There is cartilage besides epithelial cells on histology.
- Sites : 90% → Parotids
 - 7% → Submandibular gland
 - 3% → rest

Pathology

- Macro : rubbery, bosselated, on cut section, mucoid appearance with zones of cartilage.
- Micro : pleomorphic stroma with pseudocartilage, lymphoid, myxoid and fibrous elements besides epithelial cells.

Clinical features

- Age : any age but common around 40 yrs
- Sex : slightly more incidence in females.
- Painless swelling since years.
- Slow growth.
- Site : usually below the lobule of ear.
- Variable consistency : firm and rubbery



Malignant transformation

- Malignant transformation may occur in 3% to 5%
- Signs of malignant transformation :
 - Long duration (10-20yrs)
 - Becomes painful
 - Starts growing rapidly
 - Becomes stony hard
 - Facial nerve involvement
 - L. node involvement.
 - Jaw movement restriction.

Treatment

- The tumor is **radioresistant**.
- Excision is the treatment of choice.
- For diagnosis FNAC can be done but incisional biopsy is contraindicated.
- Superficial parotidectomy is the treatment of choice.
- Submandibular gland : submandibular gland excision.

Warthin's tumor

- Represents 5-15% of parotid tumors.
- Occurs only in parotid.
- Almost always in lower portion of parotid gland.

Pathology

- Gross : soft and frequently cystic
- Micro : cores of papillary processes with abundant lymphoid tissue.

Clinical features

- Age : middle and old age
- Sex : much more common in males
- Painless slow growing tumor over angle of jaw
- May be bilateral
- Surface is smooth

Management

- FNAC
- Hot spot in ^{99m}Tc pertechnate scan
- Treatment : superficial parotidectomy

Mucoepidermoid carcinoma

- Slow growing
 - Invade local tissues to a limited degree
 - Occasionally metastasise to lymph nodes, lungs or skin.
 - Clinically they are hard, become fixed when very large.
-

Acinic cell tumor

- Almost all occur in parotid gland
- Composed of cells resembling acini
- Women > Men
- Rare and slow growing
- Tend to be soft and occasionally cystic

Adenoid Cystic Carcinoma

- Consists of myoepithelial and duct epithelial cells
- Slow growing but more invasive than the above described malignant tumors
- Tumor is always more extensive than the physical or radiological appearance
- Minor glands > submandibular > parotid

Adenocarcinomas, Epidermoid ca & Undifferentiated Ca

- Resemble various glandular elements seen in salivary glands
- Divided according to predominant cell type
- Demonstrate fixation to adjacent bone, pain, anesthesia of skin and paralysis of muscles

Malignant salivary gland tumors are divided into two distinct sub-groups;

1 Low-grad malignant tumors e.g.acinic cell carcinoma.

2 High-grade malignant tumors usually present as a rapidly growing., often painless swellings in and around the parotid gland .Presentation with advanced disease is common, and cervical lymph node metastasis may be present

.

Investigations

CT and MRI scanning.

FNAC

Open surgical biopsy is contraindicated

.

Management;

All tumors of the of the superficial lobe of the parotid gland should be managed by superficial parotidectomy. No role for enucleation even if a benign lesion is suspected.

Radical parotidectomy

This is performed for a high-grade malignant tumor, e.g. squamous cell carcinoma. Radical parotidectomy involves removal of all parotid gland, and elective sectioning of the facial nerve, removes the ipsilateral masseter muscle, and may require neck dissection, particularly where there is clinical, radiological, and cytological evidence of lymph node metastasis in the ipsilateral neck.

Complications of parotid gland surgery;

- 1** haematoma
- 2** infection
- 3** temporary facial nerve weakness
- 4** facial nerve injury
- 5** sialacele
- 6** facial numbness
- 7** permanent numbness of ear lobe
- 8** Frey's syndrome

Frey's syndrome;

(gustatory sweating) an inevitable consequence of parotidectomy. It results from damage to the autonomic innervations of the salivary gland with inappropriate regeneration of parasympathetic nerve fibers that stimulate the sweat glands of the overlying skin. The clinical features include sweating and erythema over the region of surgical excision of the parotid gland as a consequence of autonomic stimulation of salivation by the smell or taste of food.

.

Granulomatous sialadenitis;

Rare conditions affect the salivary glands, producing painless swellings of the parotid and submandibular glands. ***These include the following;***

Mycobacterial infection

Sarcoidosis and other like cat scratch disease, toxoplasmosis, syphilis, and allergic sialadenitis.

Tumor – like lesions

Sialadenosis

Adenomatoid hyperplasia

Multifocal monomorphic adenomatosis

Sialadenosis

Sialosis a non – inflammatory swelling particularly affecting the parotid glands. It is usually occurs in association with ;

- . Diabetes mellitus
- . Alcoholism and drugs
- . Pregnancy
- . Idiopathic diseases

Most patients between 40 and 70 years of age.

Treatment;

Is correction of underlying disorder.

Degenerative conditions

Sjogren's syndrome

It is autoimmune condition causing progressive destruction of salivary and lacrimal glands.

Primary

Secondary

In primary the xerostomia and keratoconjunctivitis sicca more severe, and the incidence of lymphoma is higher than that in secondary, female are affected more than male in the ratio 10:1.

The diagnosis is based on the history

Management

Symptomatic, artificial tears and saliva or the patient consume large volumes of water .