

# **TRACHEOSTOMY**

## **Definition**

Tracheostomy means creation an artificial opening in the trachea with tracheostomy tube insertion

## **Indications for tracheostomy**

- 1- upper airway obstruction with stridor, air hunger, retractions,
- 2- Prolonged or expected prolonged intubation
- 3- Inability of patient to manage secretions
- 4- Facilitation of ventilation support
- 5- Inability to intubate
- 6- Adjunct to manage head and neck surgery
- 7- Adjunct to manage significant head and neck trauma

## **Advantages of tracheostomy**

- 1- Reduce dead space by 50%
- 2- Reduction in air resistance
- 3- Easier tracheobronchial secretion toilet
- 4- Facilitate using of ventilation support

## **Technique**

The open surgical tracheotomy can be performed in the operating room or at the bedside in a monitored setting such as the ICU. The procedure is most commonly performed under general anesthesia in a previously intubated patient. Occasionally, when the patient presents in acute distress, the procedure is performed in the nonintubated patient under local anesthesia, while the patient breathes spontaneously.

The patient is placed on the operating table with a bolster underneath the shoulders to extend the neck and expose the laryngotracheal landmarks

The procedure begins with the palpation of the landmarks of the neck, including the thyroid cartilage, cricoid cartilage, and sternal notch.

A 2–3 cm incision is carried out in a vertical or horizontal fashion

The horizontal incision provides a more cosmetically pleasing postoperative scar, as it follows the relaxed skin tension lines. This benefit decreases, however, the longer the tracheostomy remains in place.

Vertical incision avoids the anterior jugular venous system, therefore minimizing cumbersome bleeding in cases of emergency tracheotomies.

Vertical incisions start just below the cricoid cartilage, whereas horizontal incisions are made either two finger's breadths below the cricoid cartilage or halfway between the cricoid cartilage

and the sternal notch, typically over the interspace between the second and third tracheal rings.

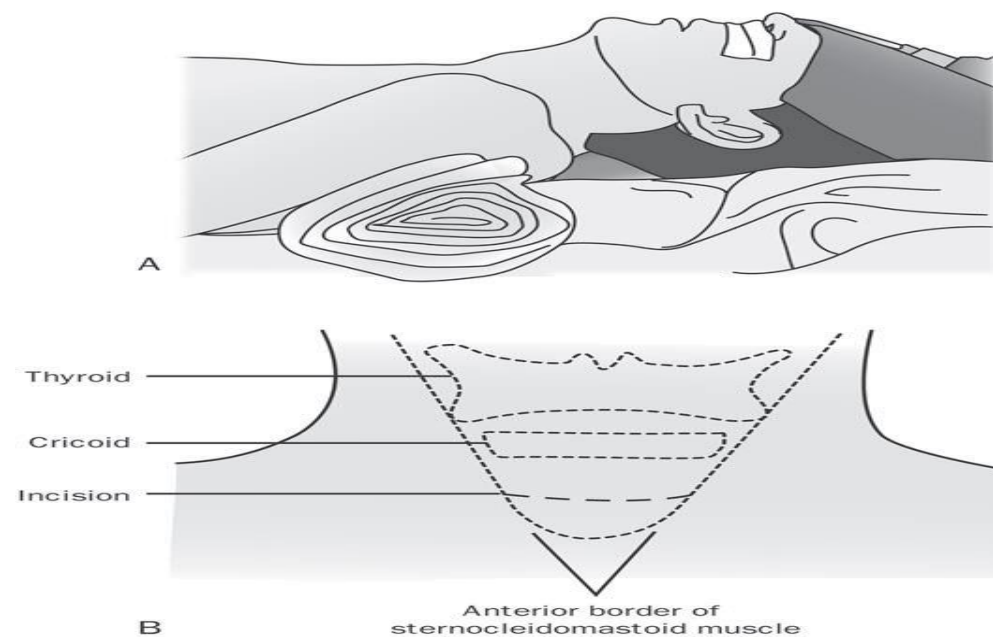
The subcutaneous tissues are then divided. Care should be exercised at this stage to avoid damage to the anterior jugular vein, which, when identified, should be lateralized or ligated in order to avoid unnecessary bleeding.

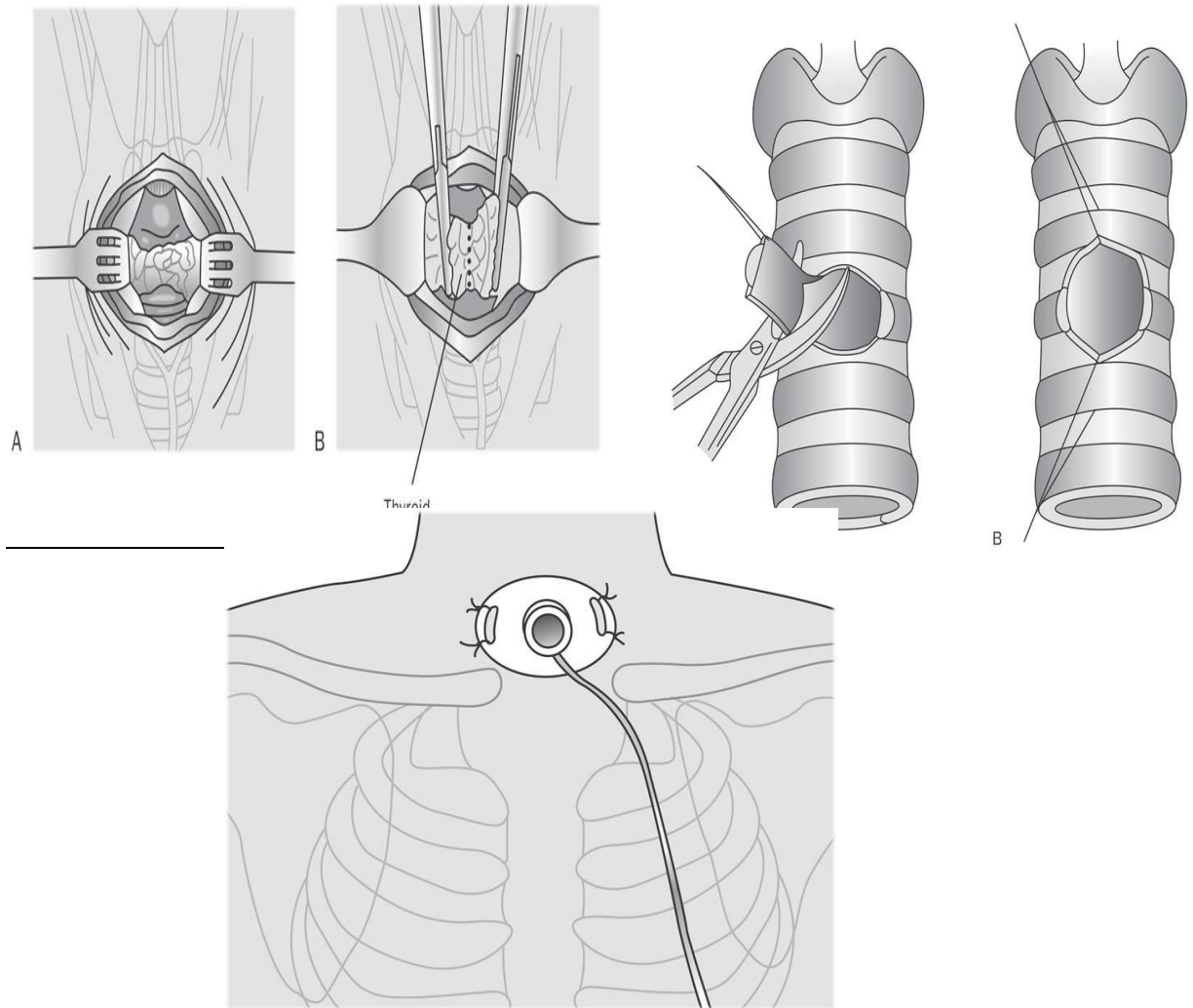
Once identified, the strap muscles should be divided vertically along their midline raphe until the thyroid isthmus is exposed. The isthmus can be retracted superiorly, inferiorly, or divided and ligated to expose the second and third tracheal rings, where the tracheal window will be performed.

There are multiple incision types for entrance into the trachea. Some surgeons prefer a single horizontal intercartilaginous incision, or make a tracheal window by removing a centimeter-wide portion of the anterior aspect of the second or third tracheal ring.

Once the trachea is entered, a tracheotomy dilator is used to optimize exposure to the tracheal lumen, taking care to prevent excess trauma to the cartilaginous framework of the trachea. Upon visualization of the endotracheal tube within the lumen, the anesthesiologist is asked to withdraw the tube until the posterior tracheal wall is visualized. The tracheostomy tube is then introduced into the lumen of the trachea under direct visualization.

Once successfully placed, the tracheostomy tube should be secured into place with nonabsorbable sutures placed through the flanges of the tube as well as tracheostomy ties placed around the patient's neck.





## **Postoperative Care**

1-In the initial postoperative period, the patient is usually placed in an intensive care setting in order to continuously monitor vital signs. Indeed, subtle changes in the patient's behavior, pulse, blood pressure, or respiratory rate may herald an obstruction of the tracheostomy tube with dried blood or secretions which requires immediate attention.

2-Tracheal suctioning must be performed as frequently as needed

3-The humidification of inhaled air is important for the mucociliary transport of secretions and to prevent the obstruction of the airway with dried secretions

4-The tracheostomy tube is rarely changed before the third postoperative day to allow the tract to mature and to avoid tissue collapse that would seal off the airway. Tube replacement done after the first 72 hours in adult and 5-7 days in children.

5-wound care to prevent infection

6-A post-tracheostomy chest X-ray is often advisable to detect possible complications of trapped air, below the skin, leading to subcutaneous emphysema, pneumomediastinum, pneumothorax, or infection.

## **Complications of Tracheostomy**

### **Early Complications**

- 1-Mild bleeding is the most common early complication Major hemorrhage is unusual and most often involves a branch of the superior thyroid artery.
- 2-Tube obstruction is the most common cause of ventilatory insufficiency in a post-tracheostomy patient and most often results from a mucous plug.
- 3-Displacement of the tracheostomy tube or dislocation of the tube from the tracheal lumen poses a considerable risk in the postoperative period.
- 4-Tracheostomy tube replacement in the early postoperative period and during the first tube change should be done under direct vision. Blind reinsertion poses the risk of creating a false passage for the tube
- 5-Subcutaneous emphysema results from the forced entrance of air into the fascial planes of the neck, usually resulting from closing the tracheostomy incision too tightly. Tube obstruction or displacement can also lead to escape of air into the fascial planes. Crepitus and soft tissue swelling can involve the neck, face
- 6-Pneumothorax occurs in less than 5% of tracheostomies and can result from damage to the pleural apices during dissection that veers away from the midline.

### **Late Complications**

- 1-Innominate artery erosion causing Tracheo-innominate fistula most commonly occurs at the tip of the tracheostomy tube.
- 2-significant infections occur rarely. Local cellulitis can generally be managed with local cleansing measures and topical antibiotics. Uncontrolled local infection can lead to such serious complications as mediastinitis, peristomal tissue loss, or tracheo-innominate fistula.
- 3-Dysphagia and aspiration Tracheostomies have been shown to decrease the protective glottic closure reflexes of both the true and false vocal cords.
- 4-Granulation tissue may form in the peristomal area due to chronic mucosal and skin irritation.
- 5-Tracheostomies may contribute to subglottic stenosis by causing chronic irritation to the Tracheal mucosa
- 6-tracheo-esophageal fistula

## Types of tracheostomy tubes

1- Metal, either silver or stainless steel.

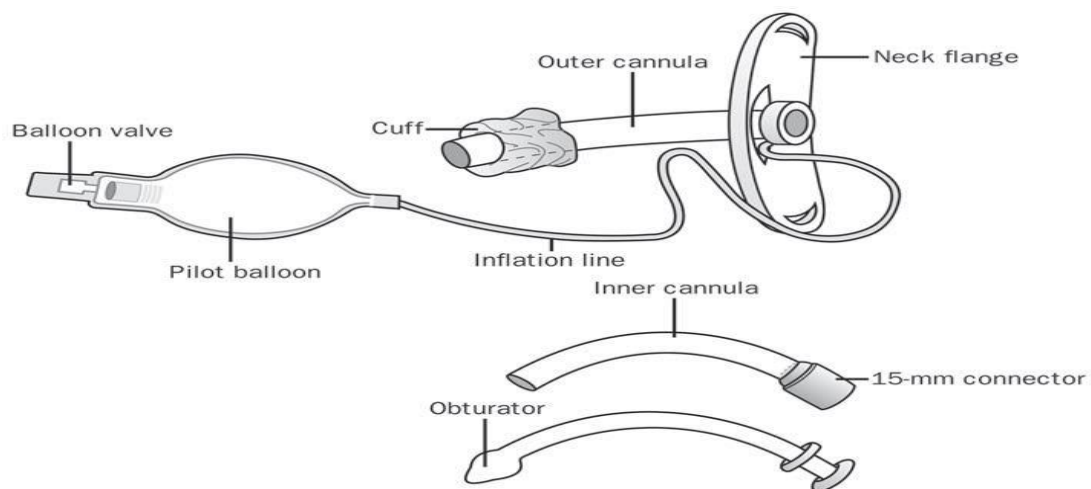
2-Medical-grade plastics such as polyvinyl chloride, polyurethane, silicone, or a combination

Plastic tubes have the advantages of being cheaper, lighter, easier to modify for special needs, and, depending on the material, more pliable. These softer materials have allowed for cuffs at the distal end of the tube so due to presence of cuff plastic tube can be used with ventilator ,or in patient with risk of aspiration like comatose patient .it is also can be used with radiotherapy

Metal tracheostomy Tubes cannot be connected to a ventilator and can not be used in patient with risk of aspiration because they do not have cuffs

## Parts of tracheostomy tubes

1-plastic tube



2- metal tube

- outer tube
- inner tube
- obturator

