

# Diseases of the pericardium

The normal pericardial sac contains about 50 mL of fluid, similar to lymph, which lubricates the surface of the heart. The pericardium limits distension of the heart, contributes to the haemodynamic interdependence of the ventricles, and acts as a barrier to infection. Nevertheless, congenital absence of the pericardium does not result in significant clinical or functional limitations.

## Acute pericarditis

### Aetiology

Pericardial inflammation may be due to a number of pathologies ([Box 18.128](#)) but sometimes remains unexplained. Pericarditis and myocarditis often coexist, and all forms of pericarditis may produce a pericardial effusion (see below) that, depending on the aetiology, may be fibrinous, serous, haemorrhagic or purulent.

### 18.128 Aetiology of acute pericarditis

Common	
<ul style="list-style-type: none"> <li>• Viral (e.g. Coxsackie B but often not identified)</li> </ul>	<ul style="list-style-type: none"> <li>• Acute MI</li> </ul>
Less common	
<ul style="list-style-type: none"> <li>• Uraemia</li> <li>• Malignant disease</li> <li>• Trauma (e.g. blunt chest)</li> </ul>	<ul style="list-style-type: none"> <li>• Connective tissue disease (e.g. systemic lupus erythematosus)</li> </ul>

• injury)	
<b>Rare (in UK)</b>	
• Bacterial infection	• Tuberculosis
• Rheumatic fever	

A fibrinous exudate may eventually lead to varying degrees of adhesion formation, whereas serous pericarditis often produces a large effusion of turbid, straw-coloured fluid with a high protein content.

A haemorrhagic effusion is often due to malignant disease, particularly carcinoma of the breast or bronchus, and lymphoma.

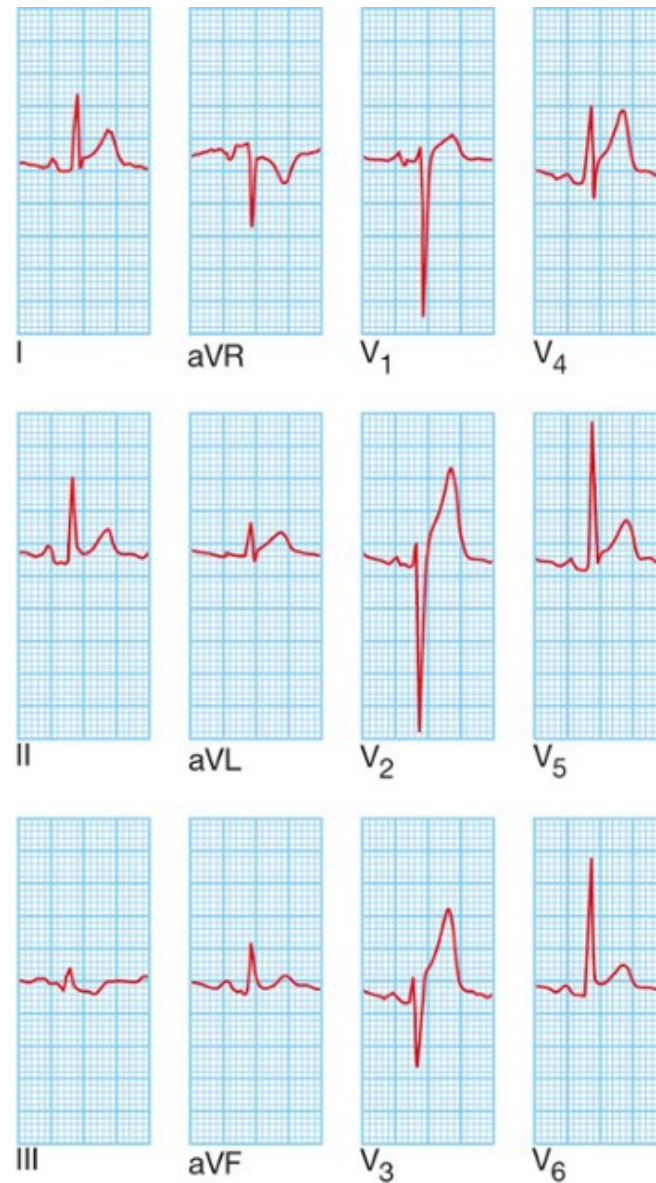
Purulent pericarditis is rare and may occur as a complication of septicaemia, by direct spread from an intrathoracic infection, or from a penetrating injury.

## Clinical features

The characteristic pain of pericarditis is retrosternal, radiates to the shoulders and neck, and is typically aggravated by deep breathing, movement, a change of position, exercise and swallowing. A low-grade fever is common. A pericardial friction rub is a high-pitched superficial scratching or crunching noise, produced by movement of the inflamed pericardium, and is diagnostic of pericarditis; it is usually heard in systole but may also be audible in diastole and frequently has a 'to-and-fro' quality.

## Investigations and management

The ECG shows ST elevation with upward concavity ([Fig. 18.104](#)) over the affected area, which may be widespread. PR interval depression is a very specific indicator of acute pericarditis. Later, there may be T-wave inversion, particularly if there is a degree of myocarditis.



**FIG.18.104 ECG in viral pericarditis.** Widespread ST elevation (leads I, II, aVL and V<sub>1</sub>–V<sub>6</sub>) is shown. T...

The pain is usually relieved by aspirin (600 mg 6 times daily) but a more potent anti-inflammatory agent, such as indometacin (25 mg 3 times daily), may be required. Colchicine or corticosteroids may suppress symptoms but there is no evidence that they

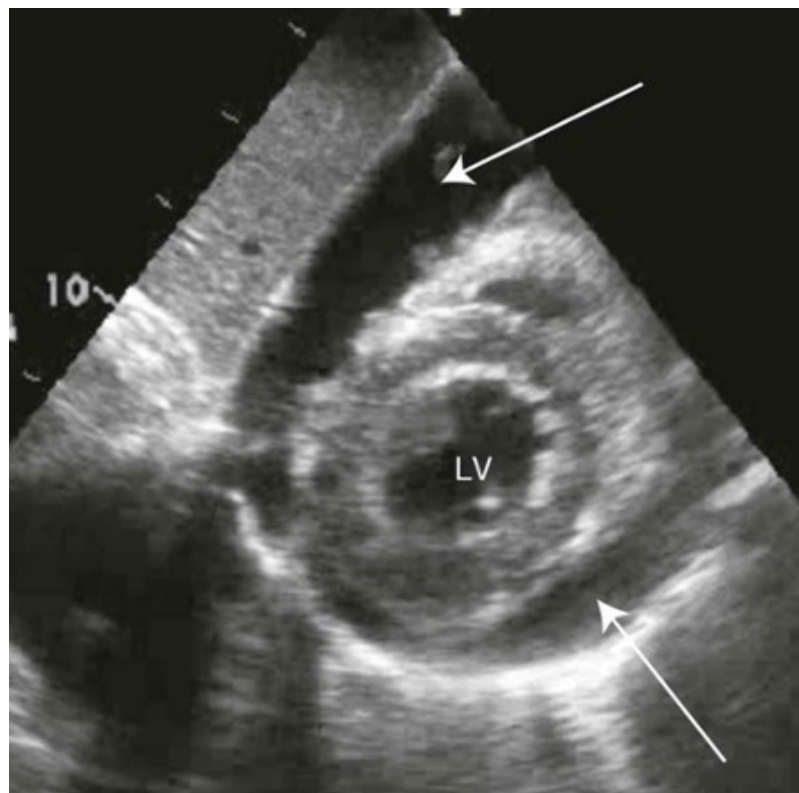
accelerate cure.

In viral pericarditis, recovery usually occurs within a few days or weeks but there may be recurrences (chronic relapsing pericarditis). Purulent pericarditis requires treatment with antimicrobial therapy, pericardiocentesis and, if necessary, surgical drainage.

## Pericardial effusion

If a pericardial effusion develops, there is sometimes a sensation of retrosternal oppression. An effusion is difficult to detect clinically. The heart sounds may become quieter, although a friction rub is not always abolished.

The QRS voltages on the ECG are often reduced in the presence of a large effusion. The QRS complexes may alternate in amplitude due to a to-and-fro motion of the heart within the fluid-filled pericardial sac (electrical alternans). The chest X-ray may show an increased size of the cardiac silhouette and, when there is a large effusion, this has a globular appearance. Echocardiography is the definitive investigation and is used to monitor the size of the effusion and its effect on cardiac function (Fig. 18.105 ).



**FIG.18.105 Pericardial effusion: echocardiogram (apical view).** Short axis view of the heart showin...

### Cardiac tamponade

This term is used to describe acute heart failure due to compression of the heart by a large or rapidly developing effusion, and is described in detail on [page 545](#). Typical physical findings are of a markedly raised JVP, hypotension, pulsus paradoxus ([p. 532](#)) and oliguria. Atypical presentations may occur when the effusion is loculated as a result of previous pericarditis or cardiac surgery.

### Pericardial aspiration (pericardiocentesis)

Aspiration of a pericardial effusion is indicated for diagnostic purposes or for the treatment of cardiac tamponade. A needle is inserted under echocardiographic guidance medial to the cardiac apex or below the xiphoid process, directed upwards towards the left shoulder. The route of choice will depend on the experience of the operator, the shape of the patient and the position of

the effusion. A few millilitres of fluid aspirated through the needle may be sufficient for diagnostic purposes but pericardial drainage is needed for symptom relief.

Complications of pericardiocentesis include arrhythmias, damage to a coronary artery, and bleeding with exacerbation of tamponade as a result of injury to the RV. When tamponade is due to cardiac rupture or aortic dissection, pericardial aspiration may precipitate further potentially fatal bleeding and, in these situations, emergency surgery is the treatment of choice. A viscous, loculated or recurrent effusion may also require formal surgical drainage.

## **Tuberculous pericarditis**

Tuberculous pericarditis may complicate pulmonary tuberculosis but may also be the first manifestation of the infection. In Africa, a tuberculous pericardial effusion is a common feature of AIDS (p. 405 ).

The condition typically presents with chronic malaise, weight loss and a low-grade fever. An effusion usually develops and the pericardium may become thick and unyielding, leading to pericardial constriction or tamponade. An associated pleural effusion is often present.

The diagnosis may be confirmed by aspiration of the fluid and direct examination or culture for tubercle bacilli. Treatment requires specific antituberculous chemotherapy (p. 693 ); in addition, a 3-month course of prednisolone (initial dose 60 mg a day, tapering down rapidly) improves outcome.

## **Chronic constrictive pericarditis**

Constrictive pericarditis is due to progressive thickening, fibrosis and calcification of the pericardium. In effect, the heart is encased in a solid shell and cannot fill properly. The calcification may extend into the myocardium, so there may also be impaired myocardial contraction. The condition often follows an attack of tuberculous pericarditis but can also complicate haemopericardium, viral pericarditis, rheumatoid arthritis and purulent pericarditis. It is often impossible to identify the original insult.

## **Clinical features and management**

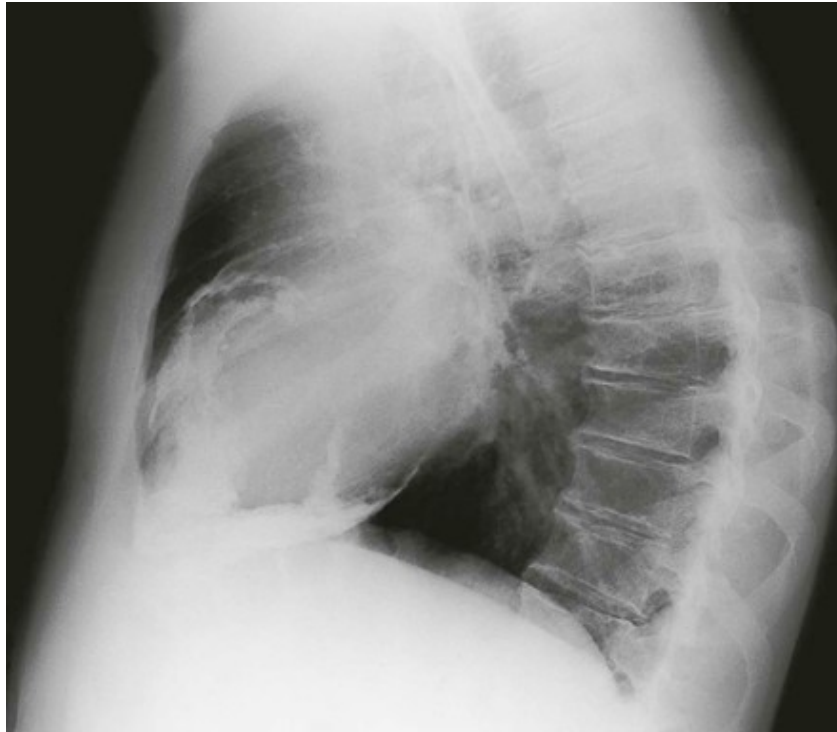
The symptoms and signs of systemic venous congestion are the hallmarks of constrictive pericarditis. Atrial fibrillation is common and there is often dramatic ascites and hepatomegaly (Box 18.129 ). Breathlessness is not a prominent symptom because the lungs are seldom congested.



### 18.129 Clinical features of constrictive pericarditis

- |  |  |
|--|--|
| <ul style="list-style-type: none"><li>● Fatigue</li><li>● Rapid, low-volume pulse</li><li>● Elevated JVP with a rapid y descent</li><li>● Kussmaul's sign (a paradoxical rise in the JVP during inspiration)</li><li>● Loud early third heart sound or 'pericardial knock'</li></ul> | <ul style="list-style-type: none"><li>● Hepatomegaly</li><li>● Ascites</li><li>● Peripheral oedema</li><li>● Pulsus paradoxus (excessive fall in BP during inspiration): present in some cases</li></ul> |
|--|--|

The condition is sometimes overlooked but should be suspected in any patient with unexplained right heart failure and a small heart. A chest X-ray, which may show pericardial calcification (Fig. 18.106 ), and echocardiography often help to establish the diagnosis. CT scanning is useful for imaging the pericardial calcification.



**FIG.18.106** Lateral chest X-ray from a patient with severe heart failure due to chronic constricti...

Constrictive pericarditis is often difficult to distinguish from restrictive cardiomyopathy and the final diagnosis may depend on complex echo–Doppler studies and cardiac catheterisation. Surgical resection of the diseased pericardium can lead to a dramatic improvement but carries a high morbidity with disappointing results in up to 50% of patients.