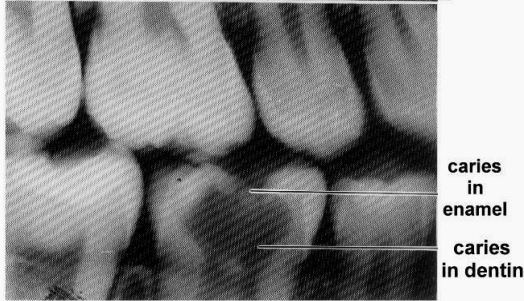
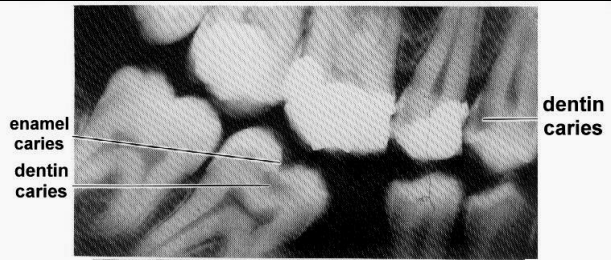
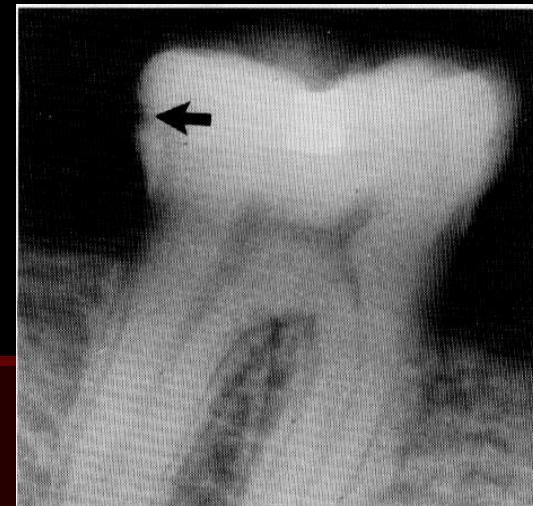


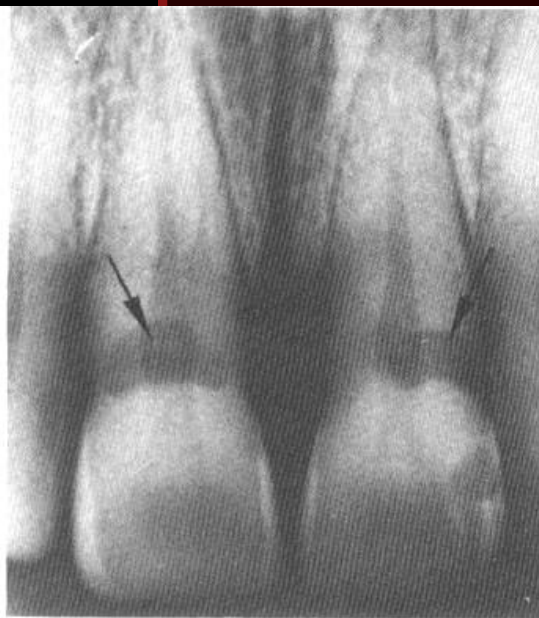
Dental Caries



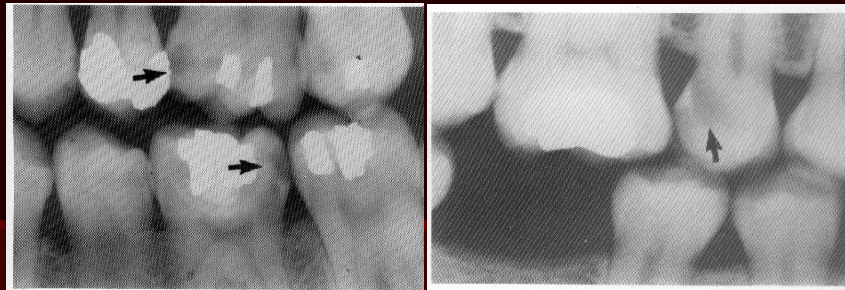occlusal caries



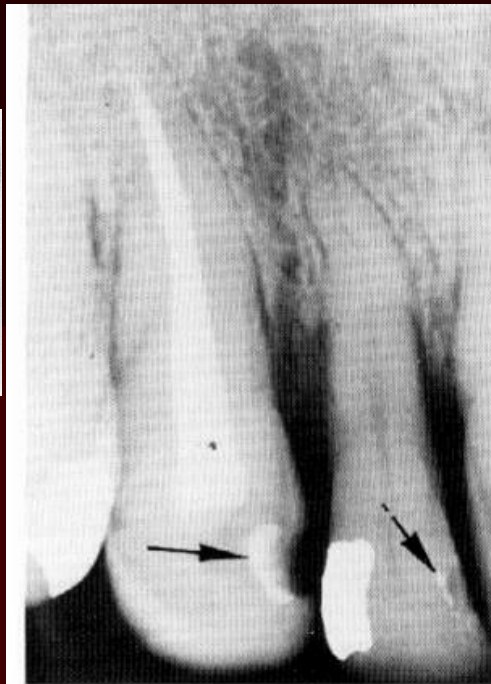
interproximal caries



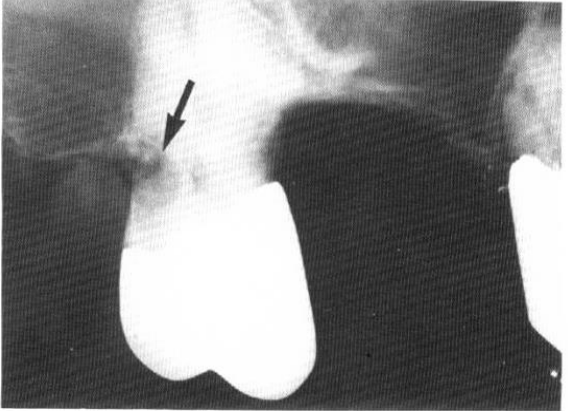
cervical caries



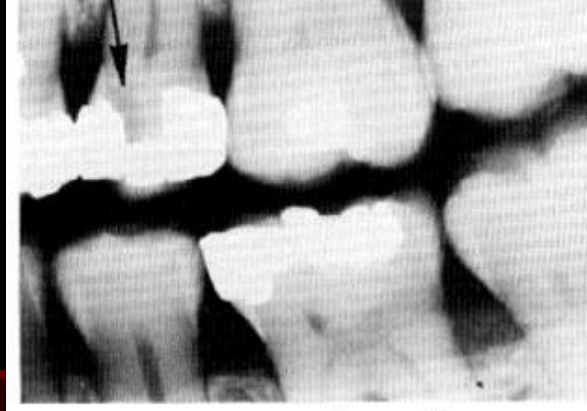
Interproximal caries



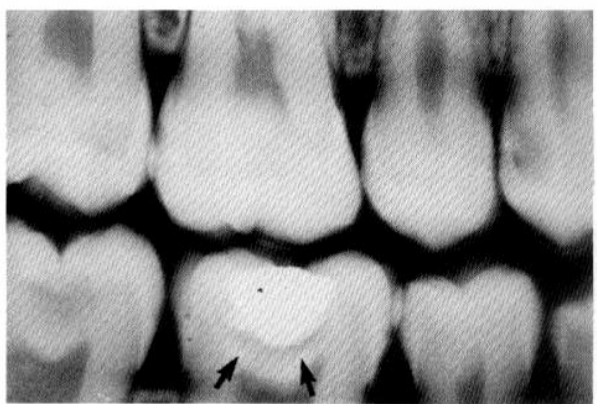silicate restoration



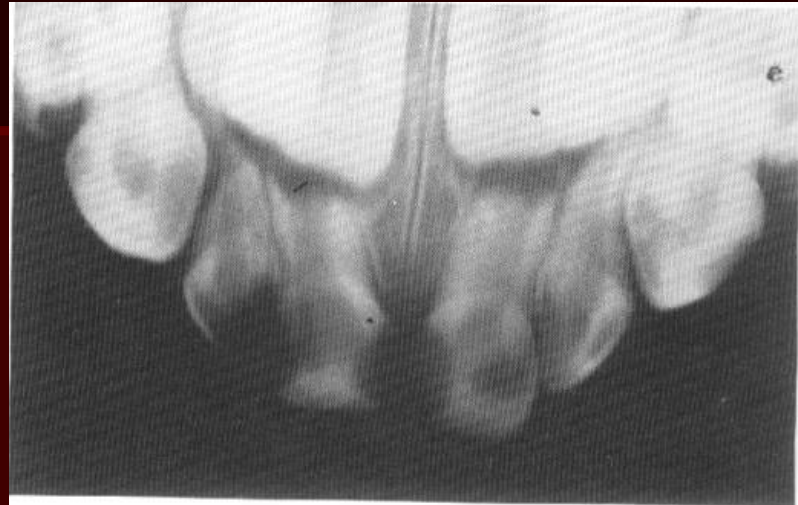cementum caries



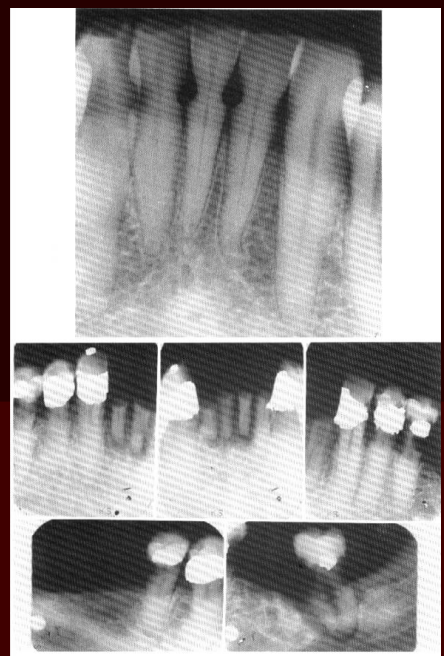recurrent caries



recurrent caries

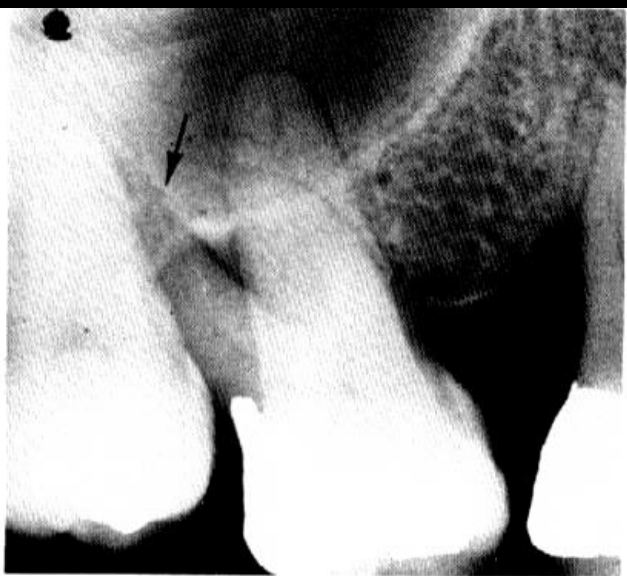


night bottle caries

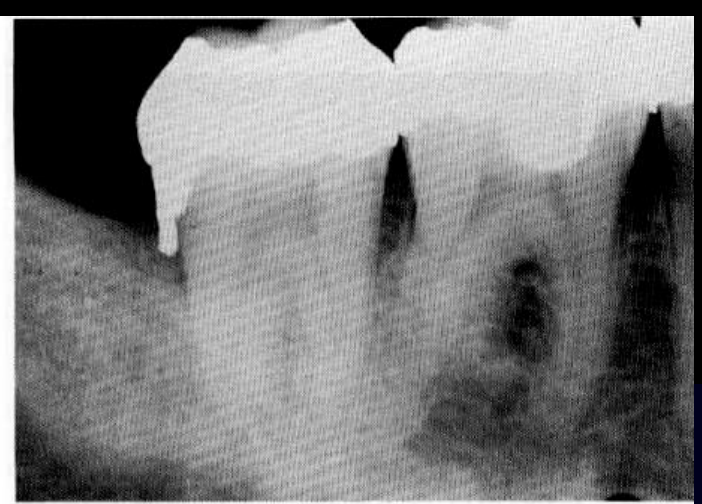

radiation caries

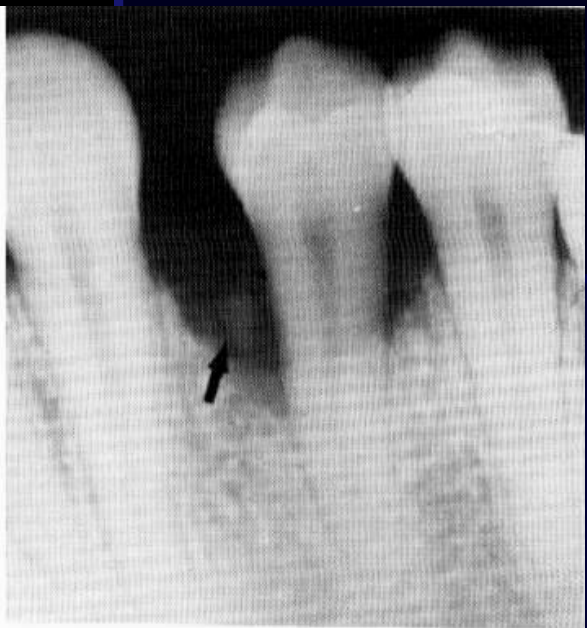
Periodontal Disease



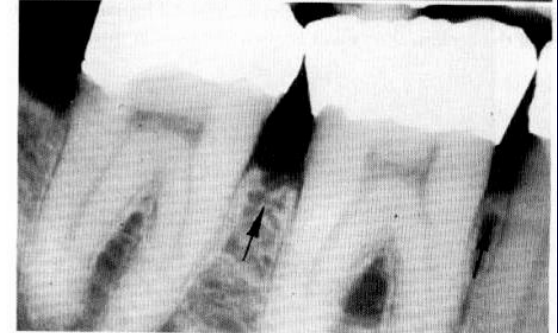
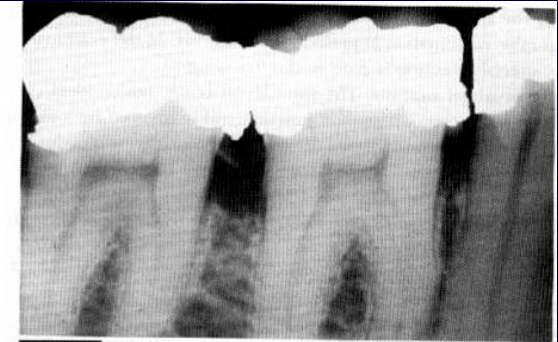
periodontal lesion



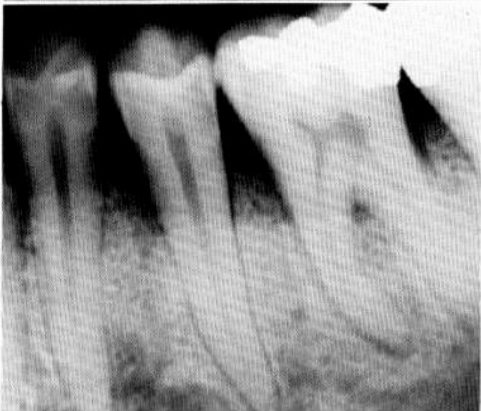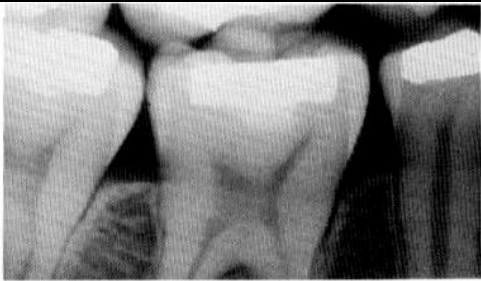amalgam overhung



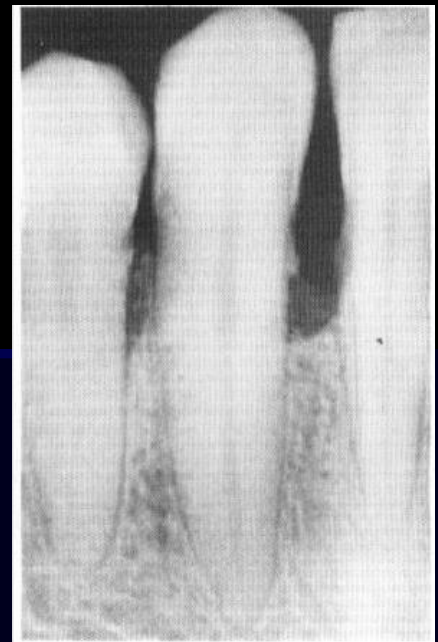foreign bodies



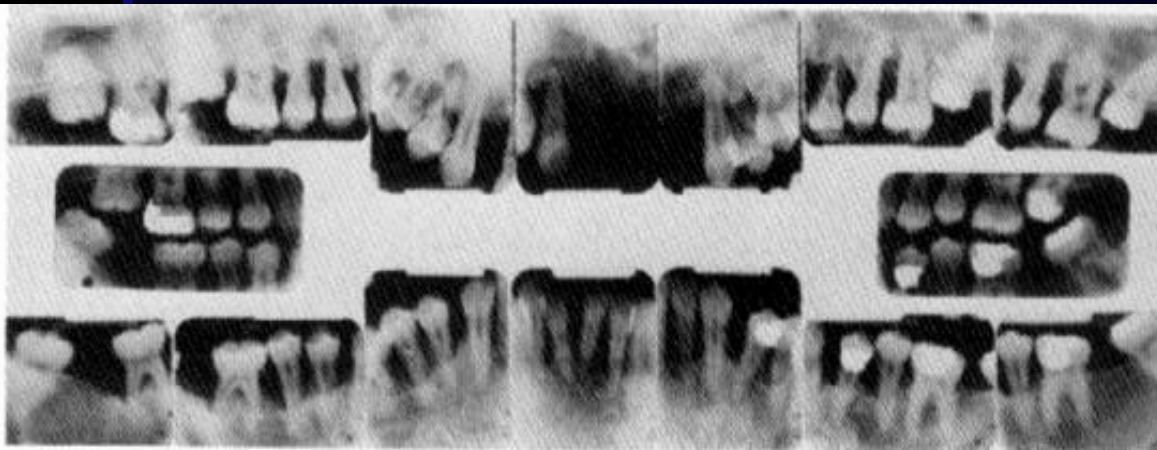
bone loss & overhung restoration



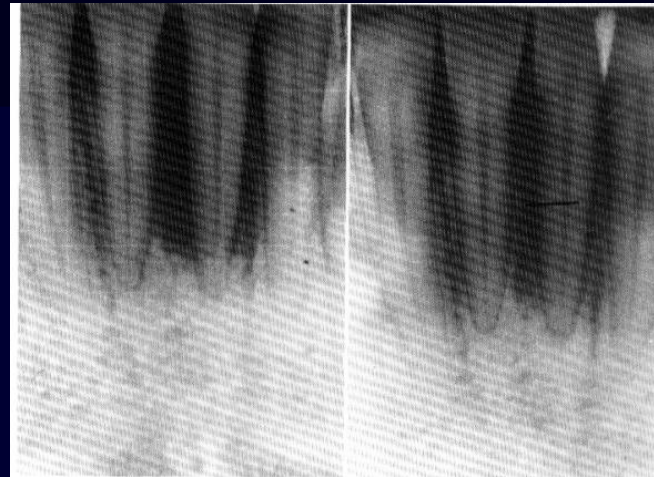
**interproximal septum
(alveolar crest recedes from
the cemento-enamel junction)**



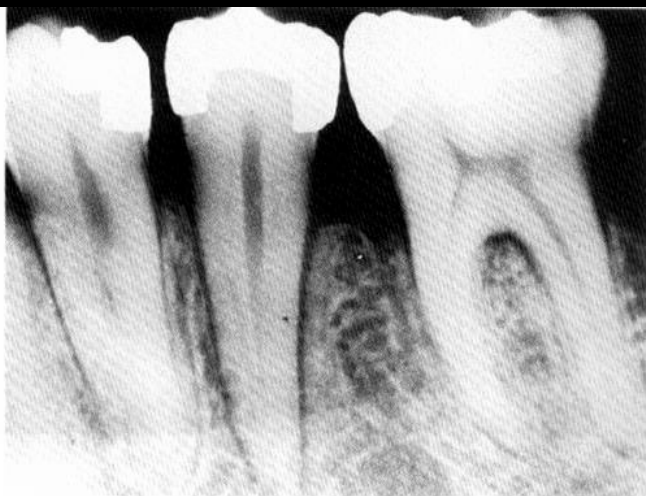moderate periodontitis



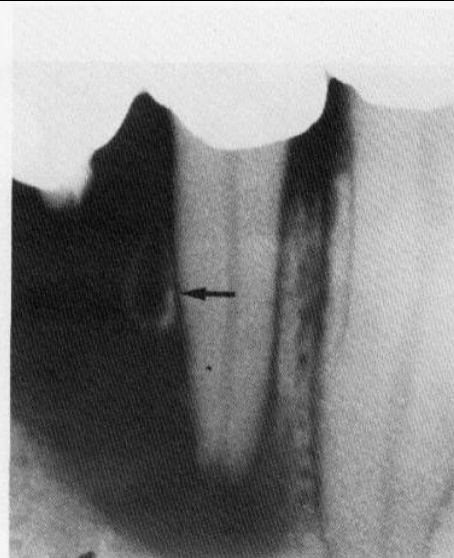
advanced periodontitis



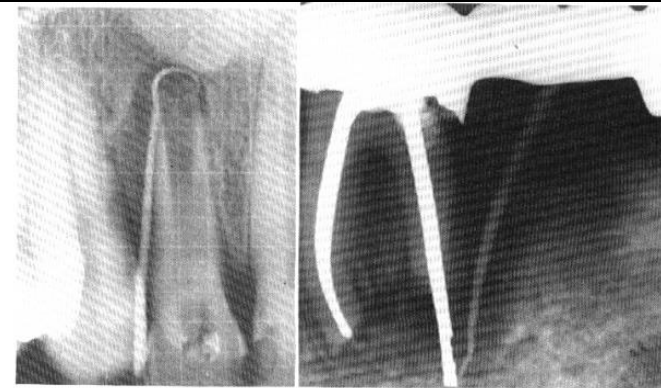
periodontal abscess



orthodontic tooth movement

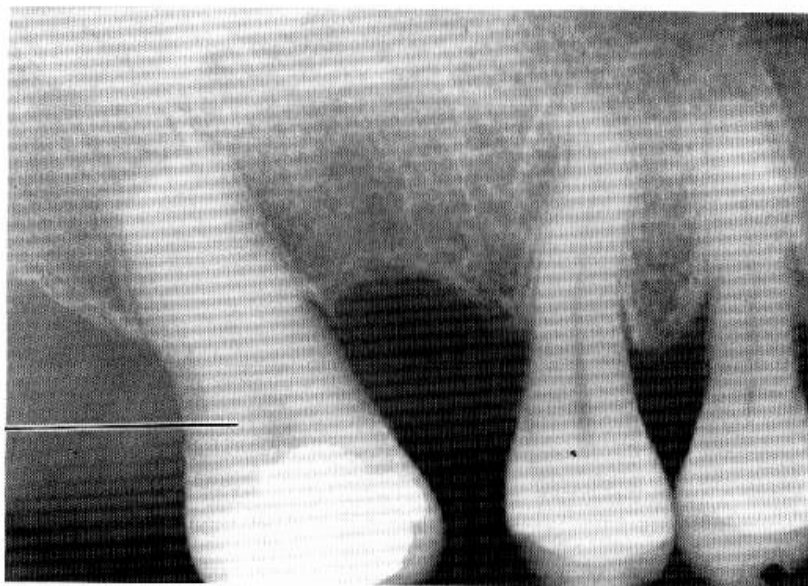


combined pulp - periodontal lesion

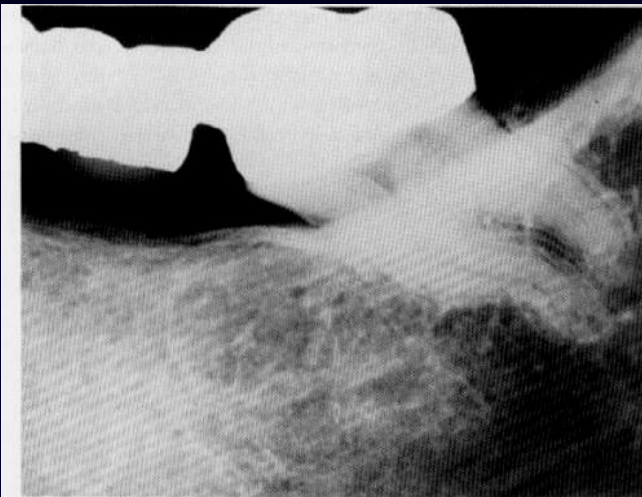


combined pulp - periodontal lesion

**tooth without
on
opposing molar**



atrophy of disuse



hyperfunction