Lymphatic drainage of the abdominal cavity

Presented by:

Yasir K. Hani
Ahmed Tahir
Zaid Fadil
Ayya Hussam
Maryam Majid
Ammar

Basma Ahmed
Tabarak Mahmmod
Tamara Amer
Mohammed Fadil
Istabarq Anwar

Introduction to lymph

Structure of the lymph node

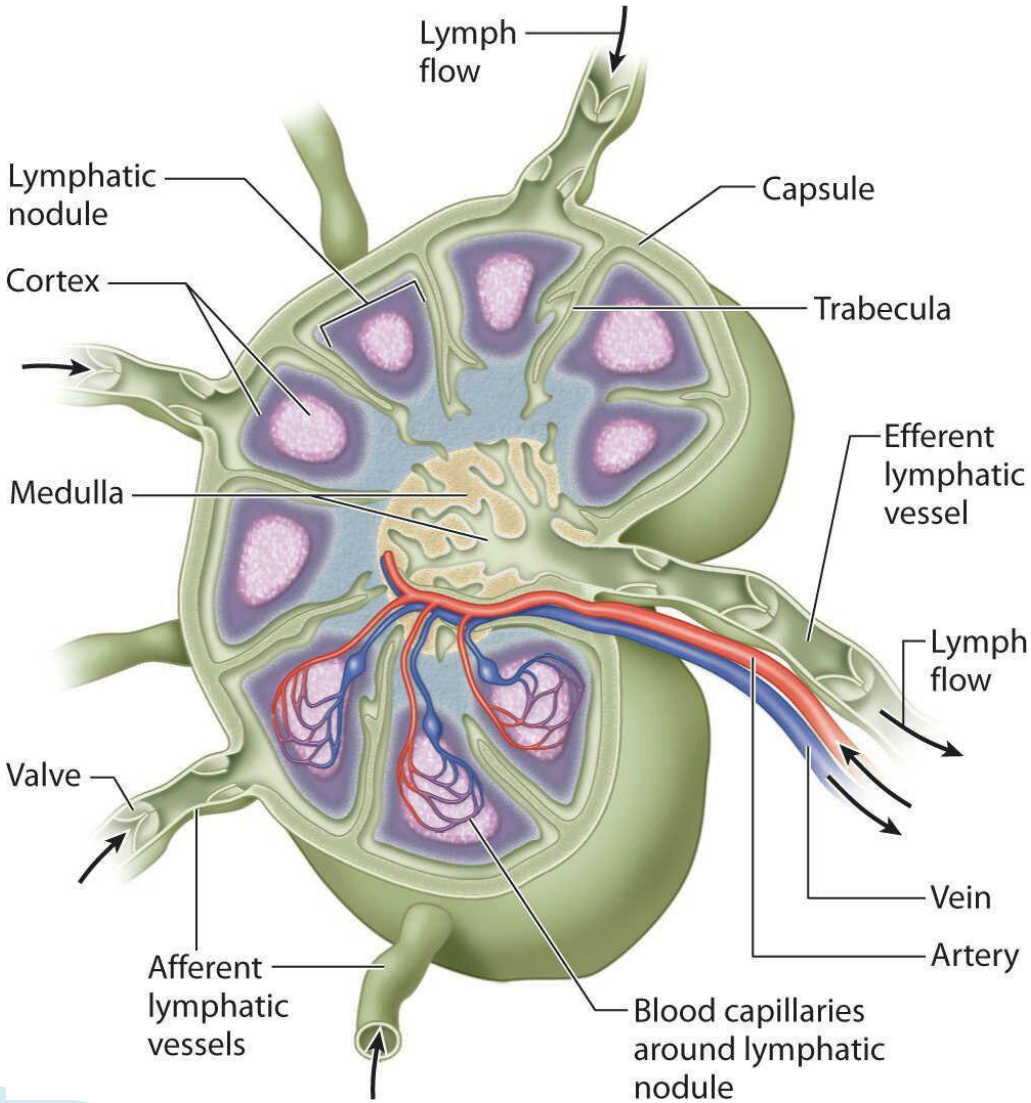

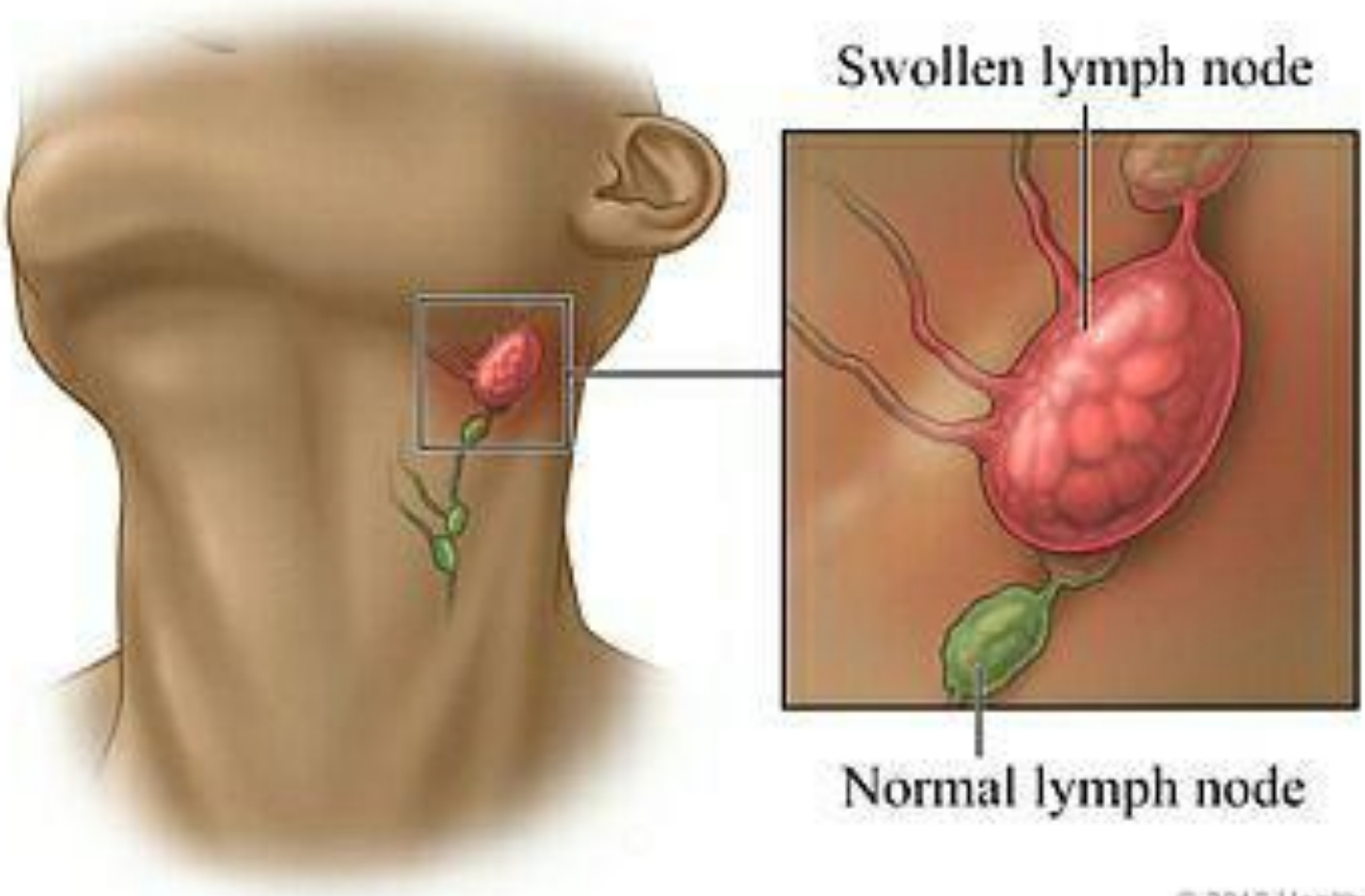

© 2016 Healthwise

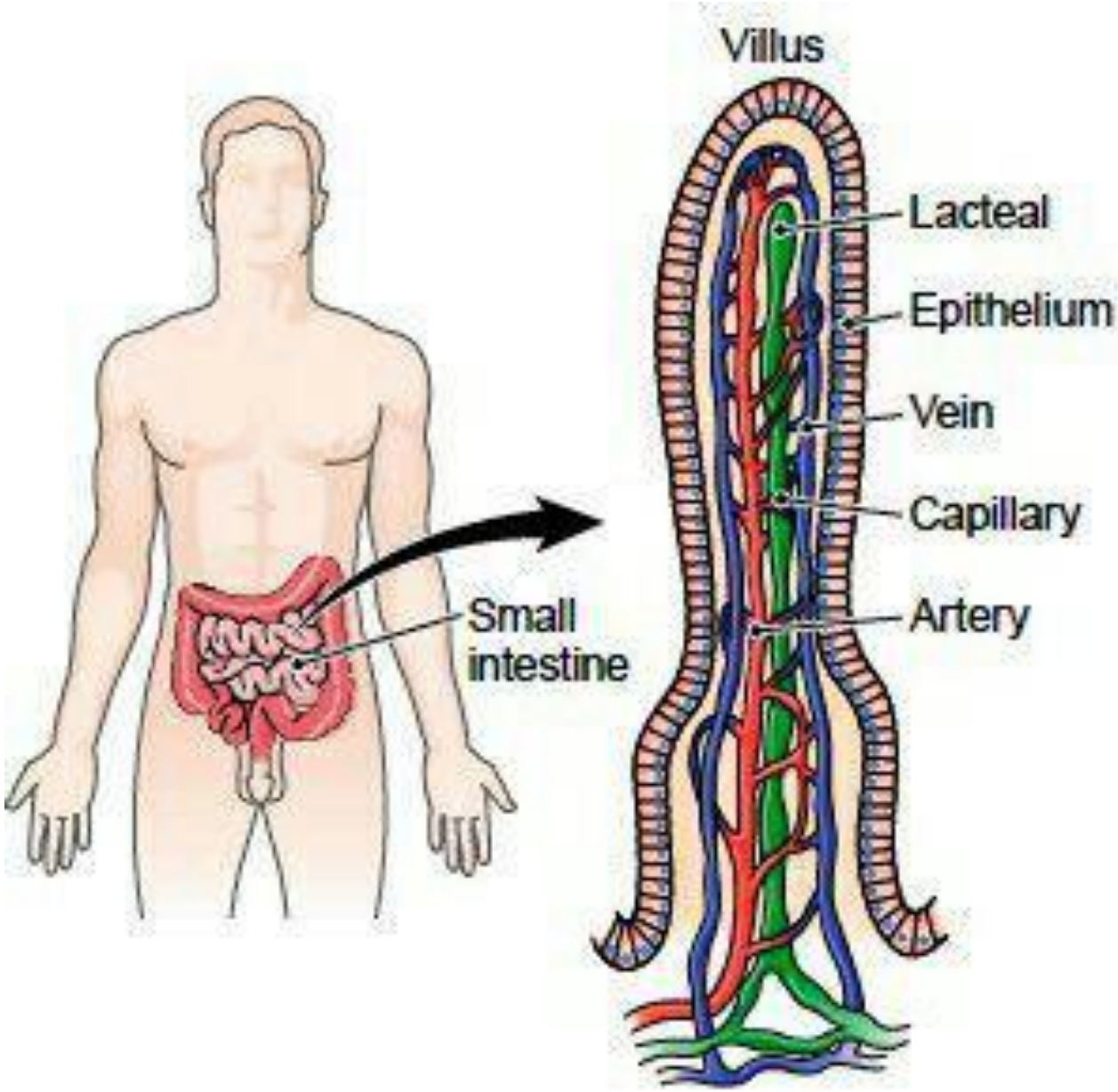
Villus
Lacteal
Epithelium
Vein
Capillary
Artery
Small
intestine

What is MALT ?

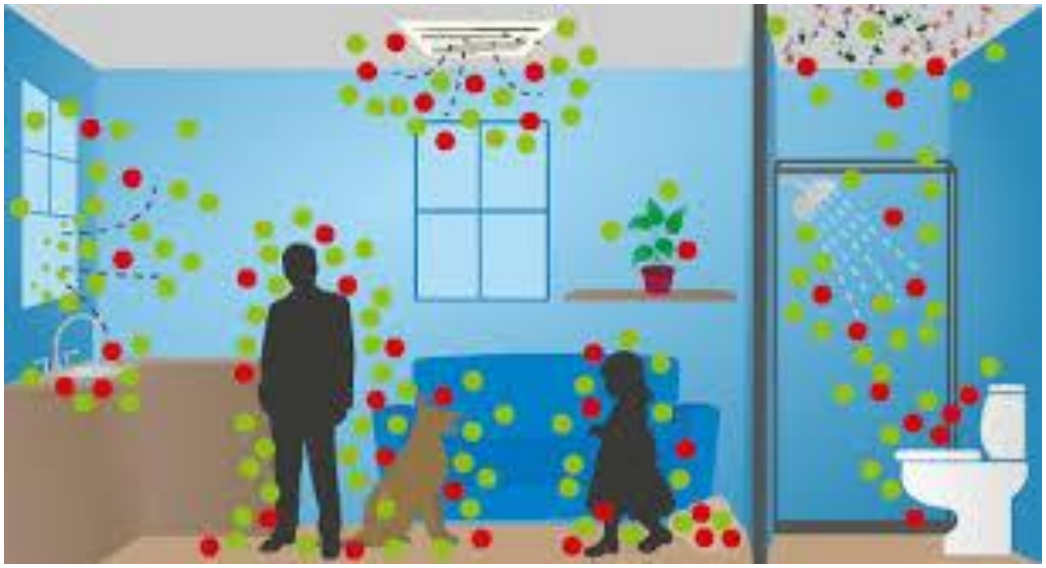



Mucosa-Associated Lymphatic Tissue (MALT)

Peyer's patches in the intestines

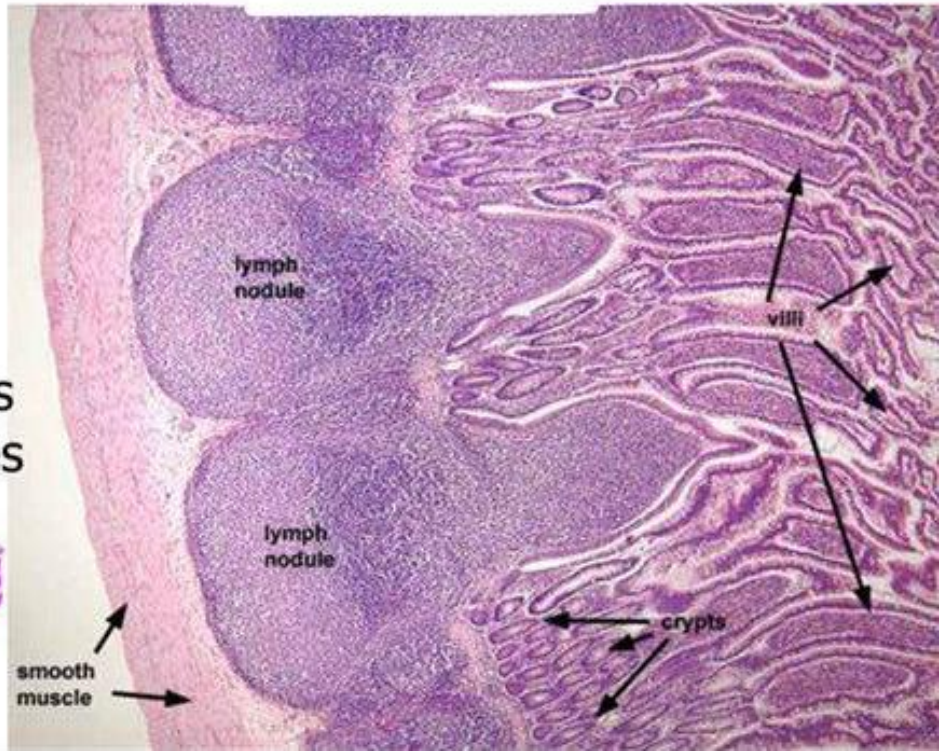

- Consists of lymphoid tissues of the
  - Intestinal tract
  - Genitourinary tract
  - Tracheobronchial tree
  - Mammary glands
- Un-encapsulated organs
- Contain both T & B lymphocytes (B predominating)
- Structurally these tissues include clusters of lymphoid cells in the lamina propria of Intestinal Villi, Tonsils, Appendix, & Peyer's Patches.

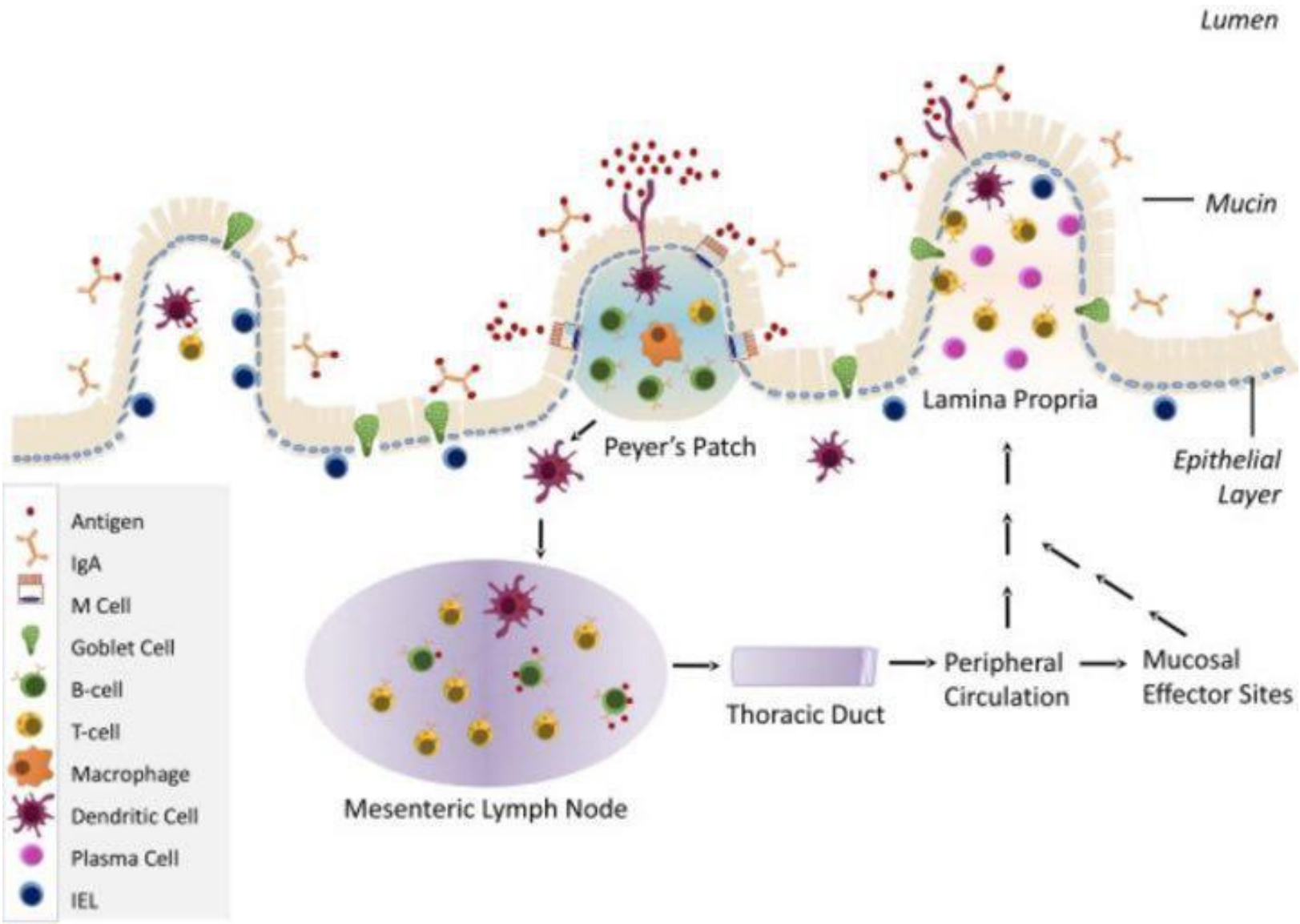
Lumen
Mucin
Lamina Propria
Peyer's Patch
Epithelial Layer
Antigen
IgA
M Cell
Goblet Cell
B-cell
T-cell
Macrophage
Dendritic Cell
Plasma Cell
IEL
Mesenteric Lymph Node
Thoracic Duct
Peripheral Circulation
Mucosal Effector Sites

MALT lymphoma - endoscopy

Lymph drainage of the stomach

Parts of the stomach

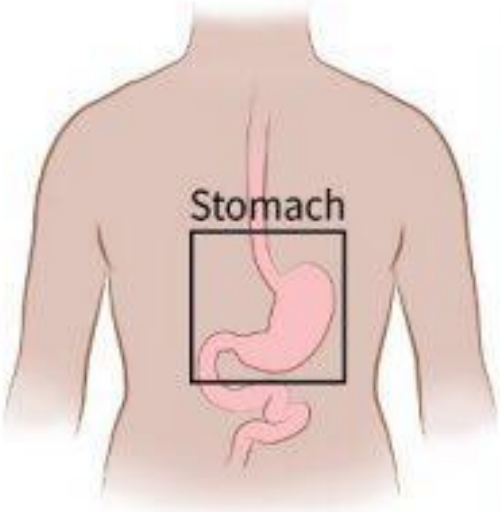

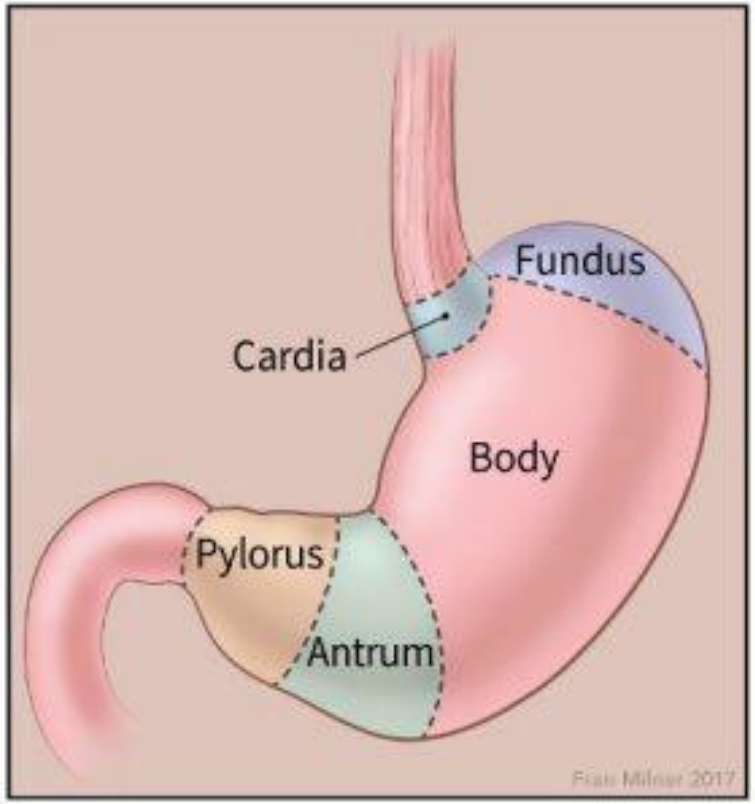

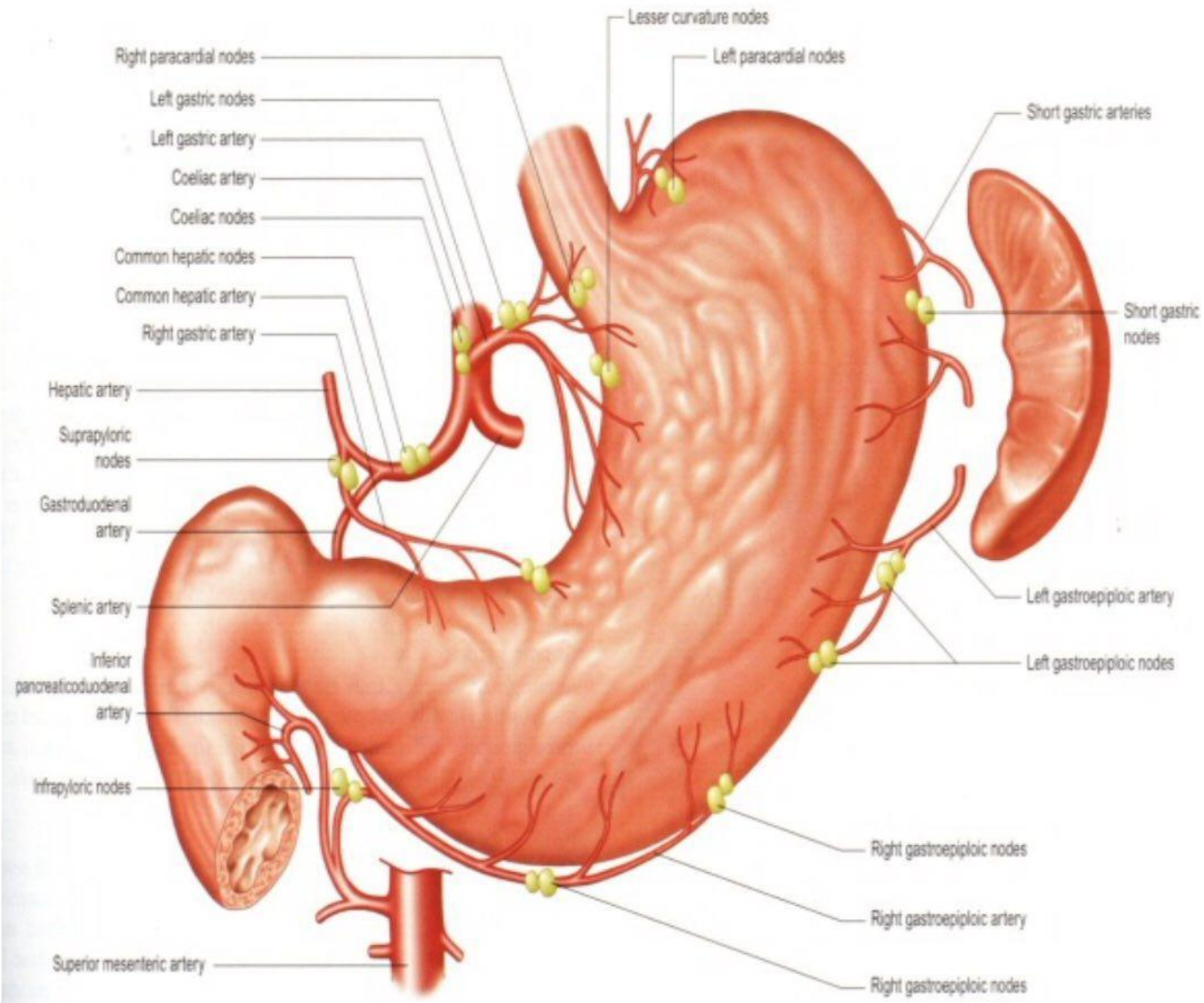
Lesser curvature nodes
Right paracardial nodes
Left paracardial nodes
Left gastric nodes
Short gastric arteries
Left gastric artery
Coeliac artery
Coeliac nodes
Common hepatic nodes
Common hepatic artery
Short gastric nodes
Right gastric artery
Hepatic artery
Suprapyloric nodes
Gastroduodenal artery
Splenic artery
Left gastroepiploic artery
Inferior pancreaticoduodenal artery
Left gastroepiploic nodes
Infrapyloric nodes
Right gastroepiploic nodes
Right gastroepiploic artery
Superior mesenteric artery
Right gastroepiploic nodes

Lymph drainage of the small intestine

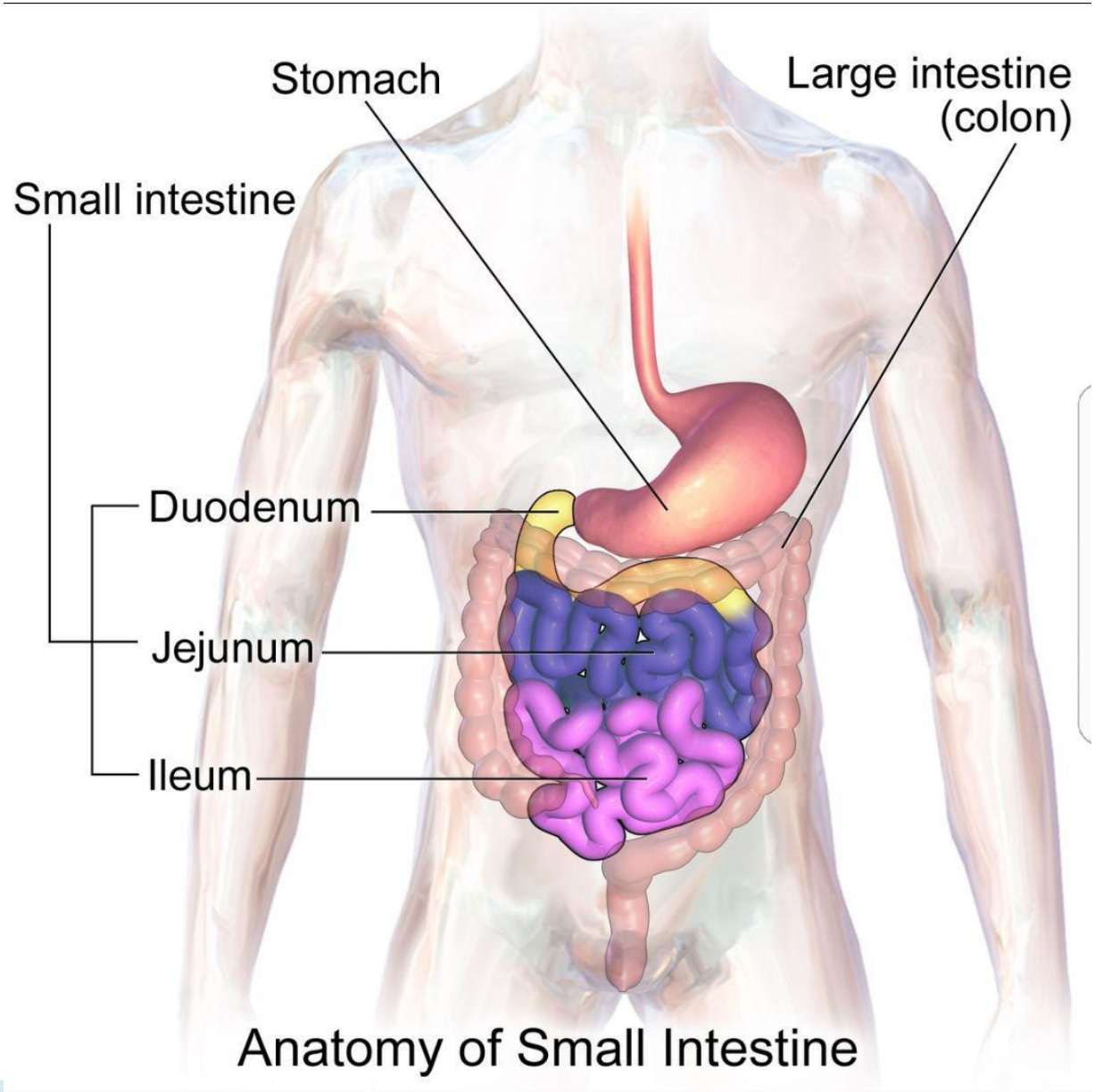
Stomach
Large intestine
(colon)
Small intestine
Duodenum
Jejunum
Ileum
Anatomy of Small Intestine

Lymph drainage of the duodenum

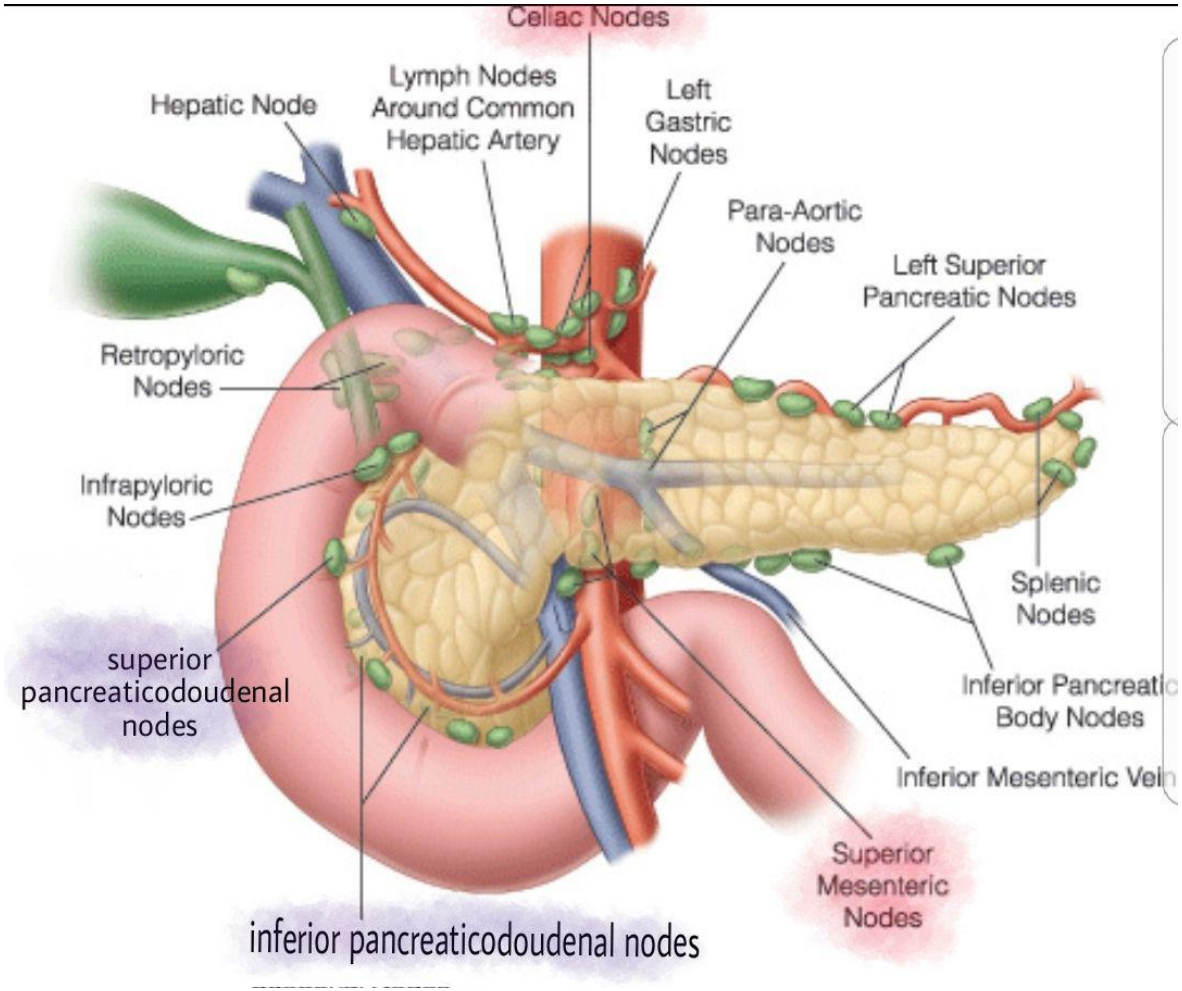

Lymph drainage of the jejunum and ilium

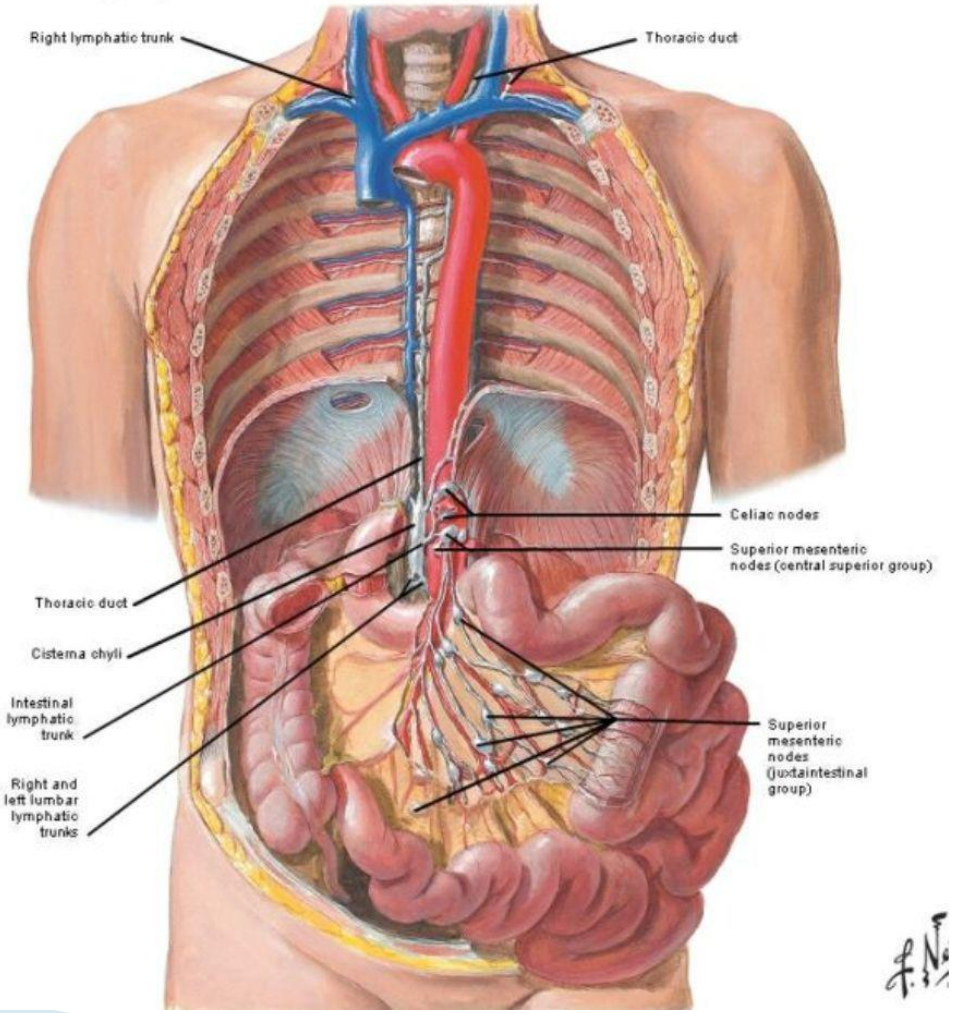

Lymph drainage of the colon

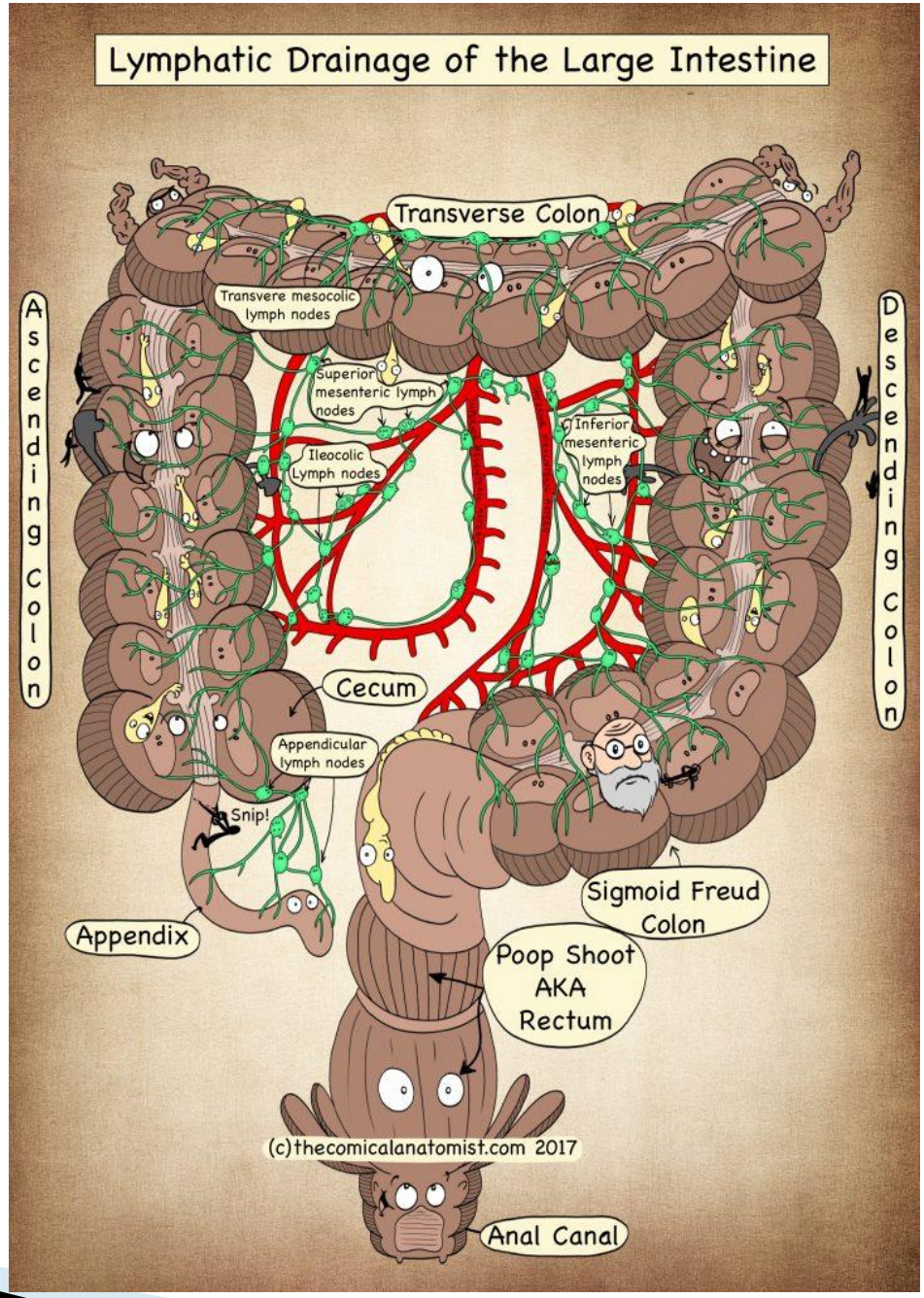
Lymphatic Drainage of the Large Intestine
Transverse Colon
Transvere mesocolic lymph nodes
Ascending Colon
Descending Colon
Superior mesenteric lymph nodes
Ileocolic Lymph nodes
Inferior mesenteric lymph nodes
Cecum
Appendicular lymph nodes
Snip!
Appendix
Sigmoid Freud Colon
Poop Shoot AKA Rectum
(c)thecomicalanatomist.com 2017
Anal Canal

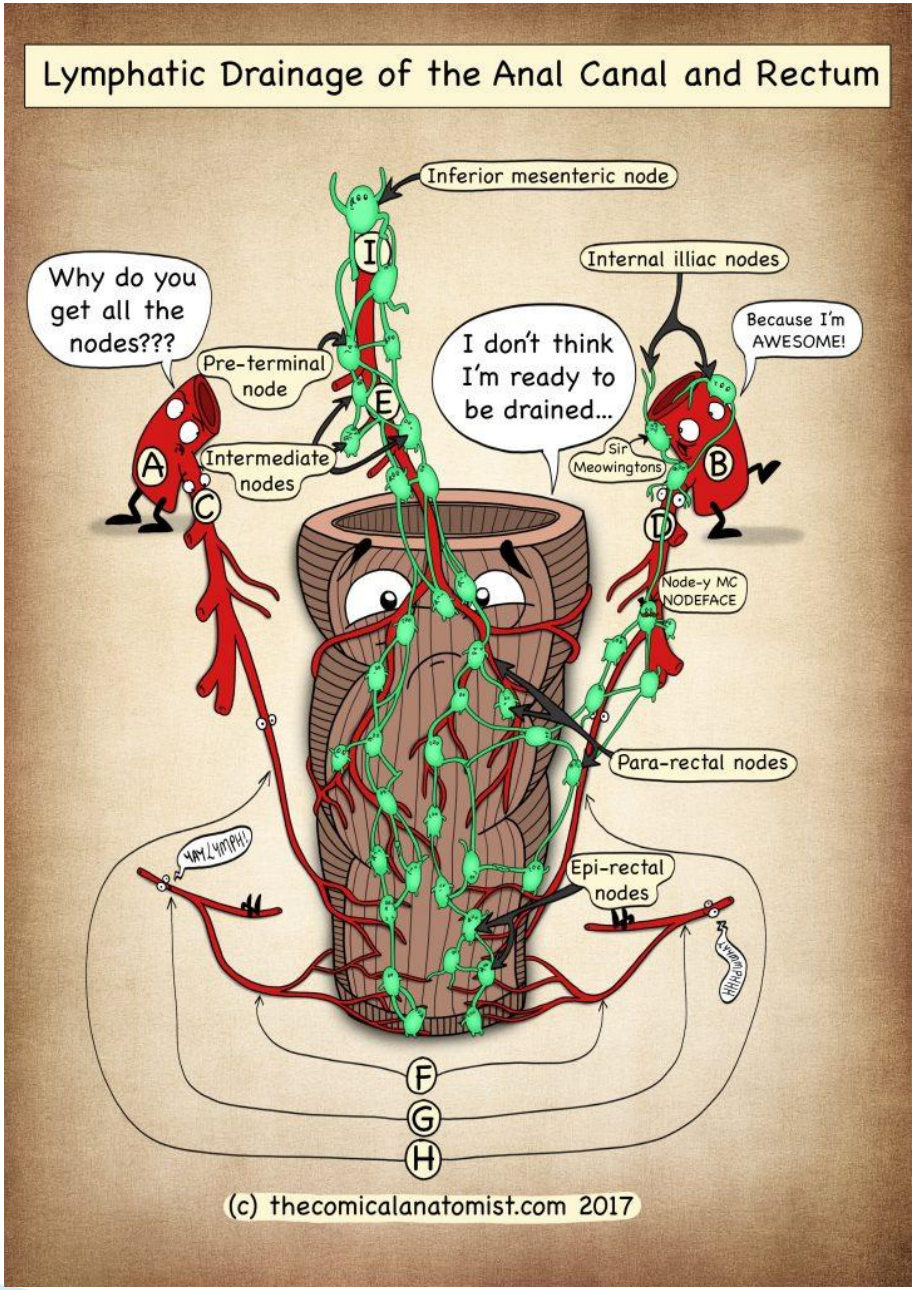
Lymphatic Drainage of the Anal Canal and Rectum
Inferior mesenteric node
Internal illiac nodes
Why do you get all the nodes???
Because I'm AWESOME!
I don't think I'm ready to be drained...
Pre-terminal node
Intermediate nodes
Sir Meowingtons
Node-y MC NODEFACE
Para-rectal nodes
Epi-rectal nodes
I
E
A
C
B
D
F
G
H
(c) thecomicalanatomist.com 2017

Lymph drainage of the kidney

Structure of the kidney

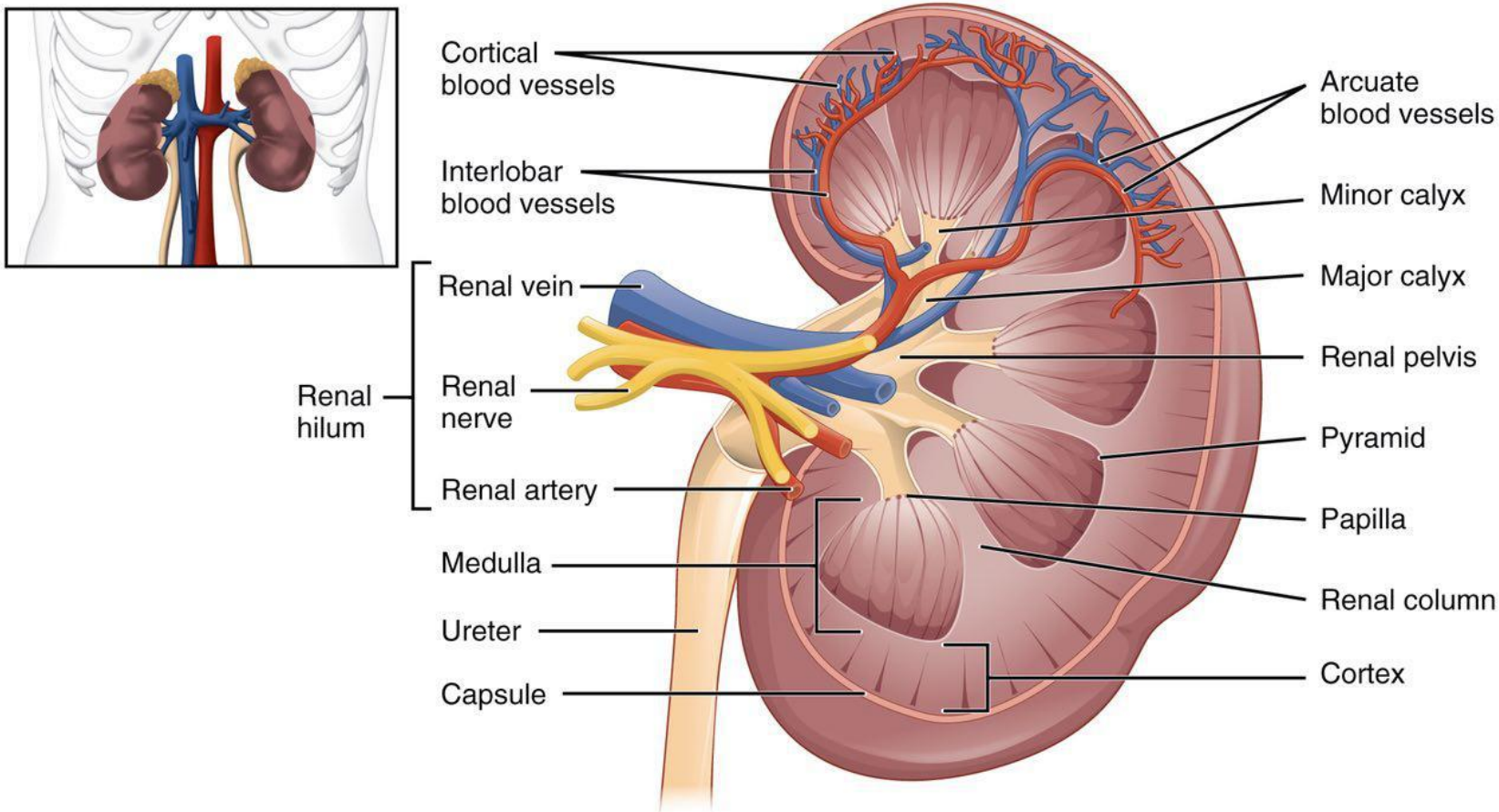

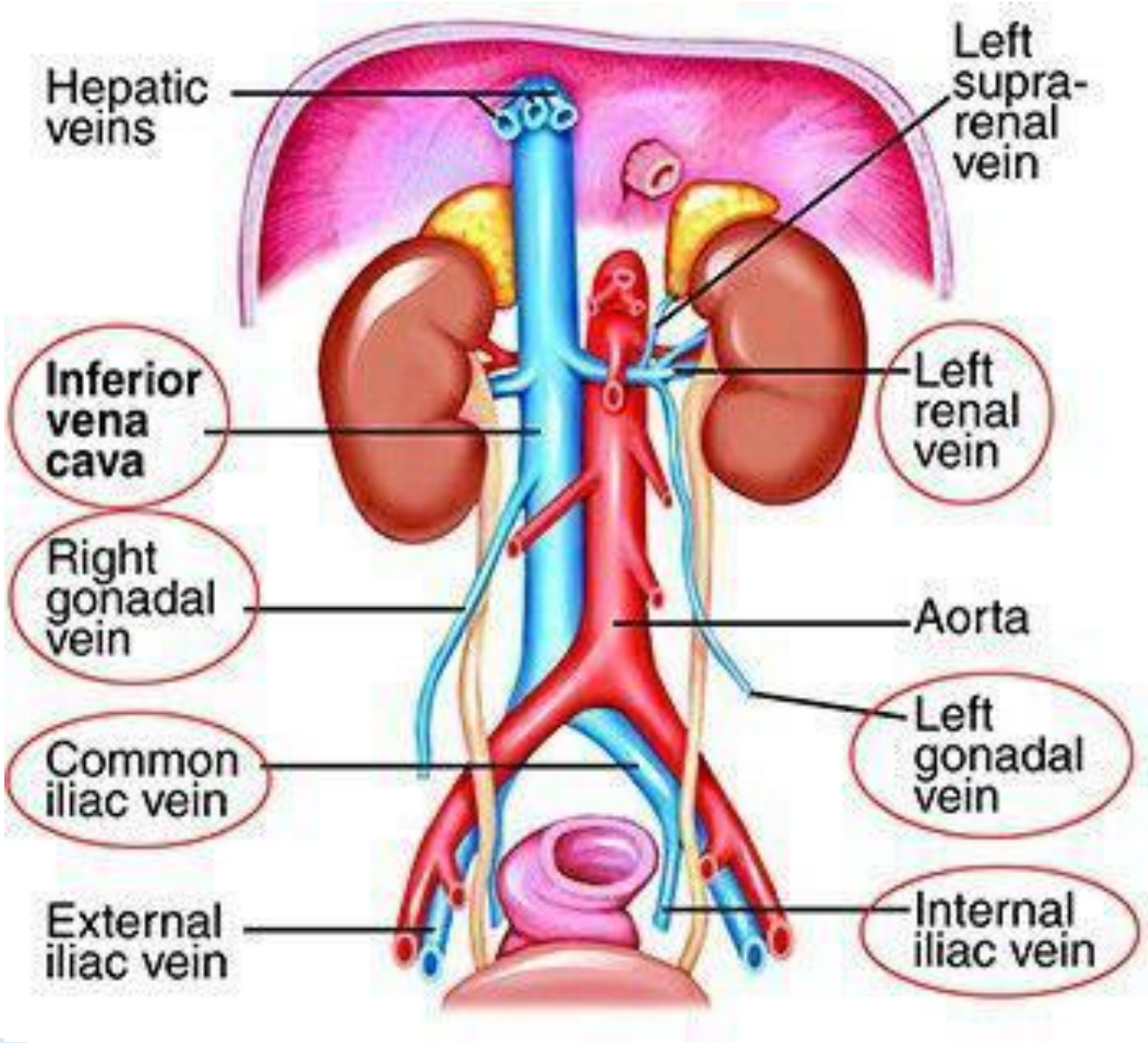
Hepatic veins
Left supra-renal vein
Inferior vena cava
Left renal vein
Right gonadal vein
Aorta
Left gonadal vein
Common iliac vein
External iliac vein
Internal iliac vein

Lymph drainage of the liver & gallbladder

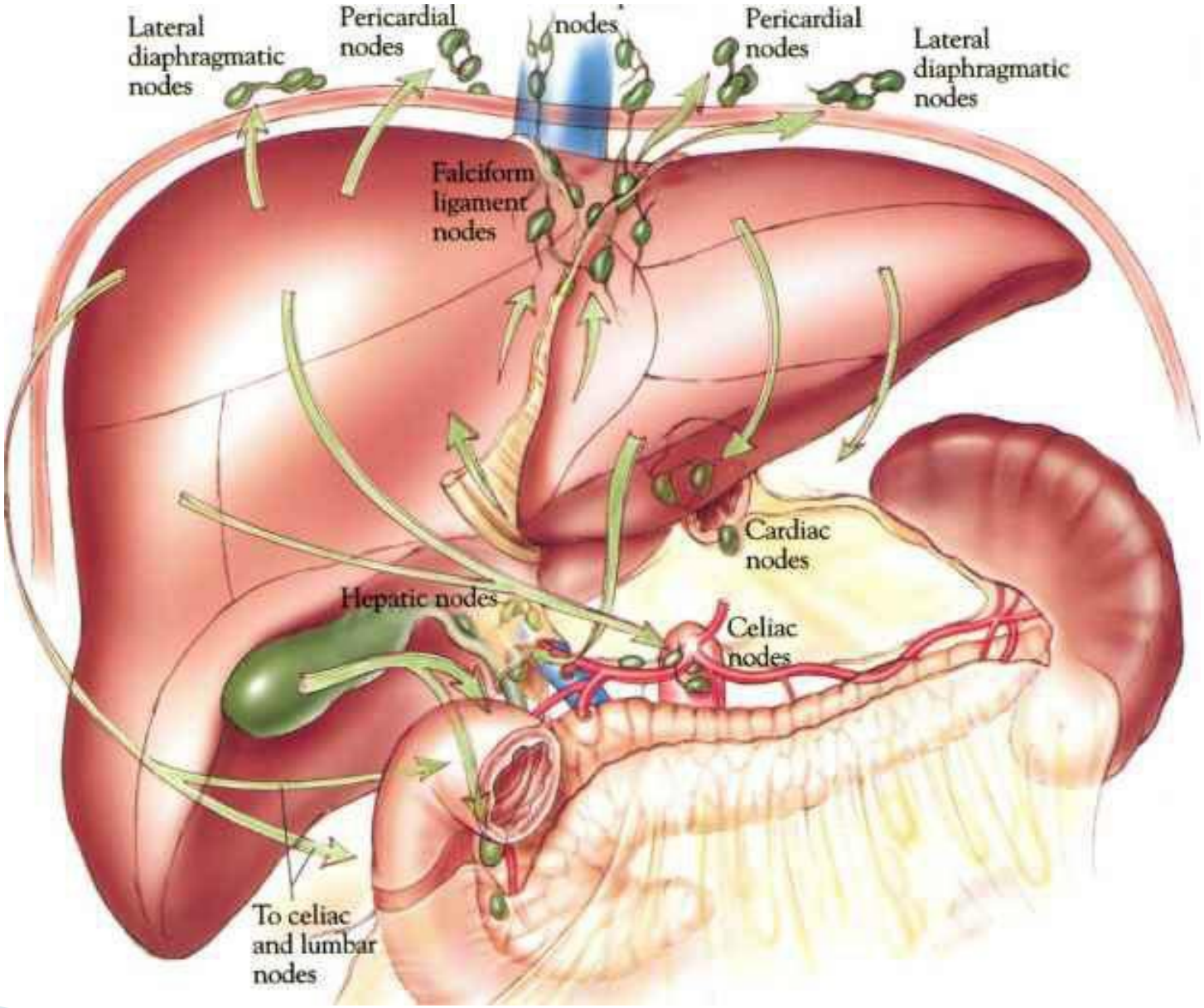
Lateral diaphragmatic nodes
Pericardial nodes
nodes
Pericardial nodes
Lateral diaphragmatic nodes
Falciform ligament nodes
Cardiac nodes
Hepatic nodes
Celiac nodes
To celiac and lumbar nodes

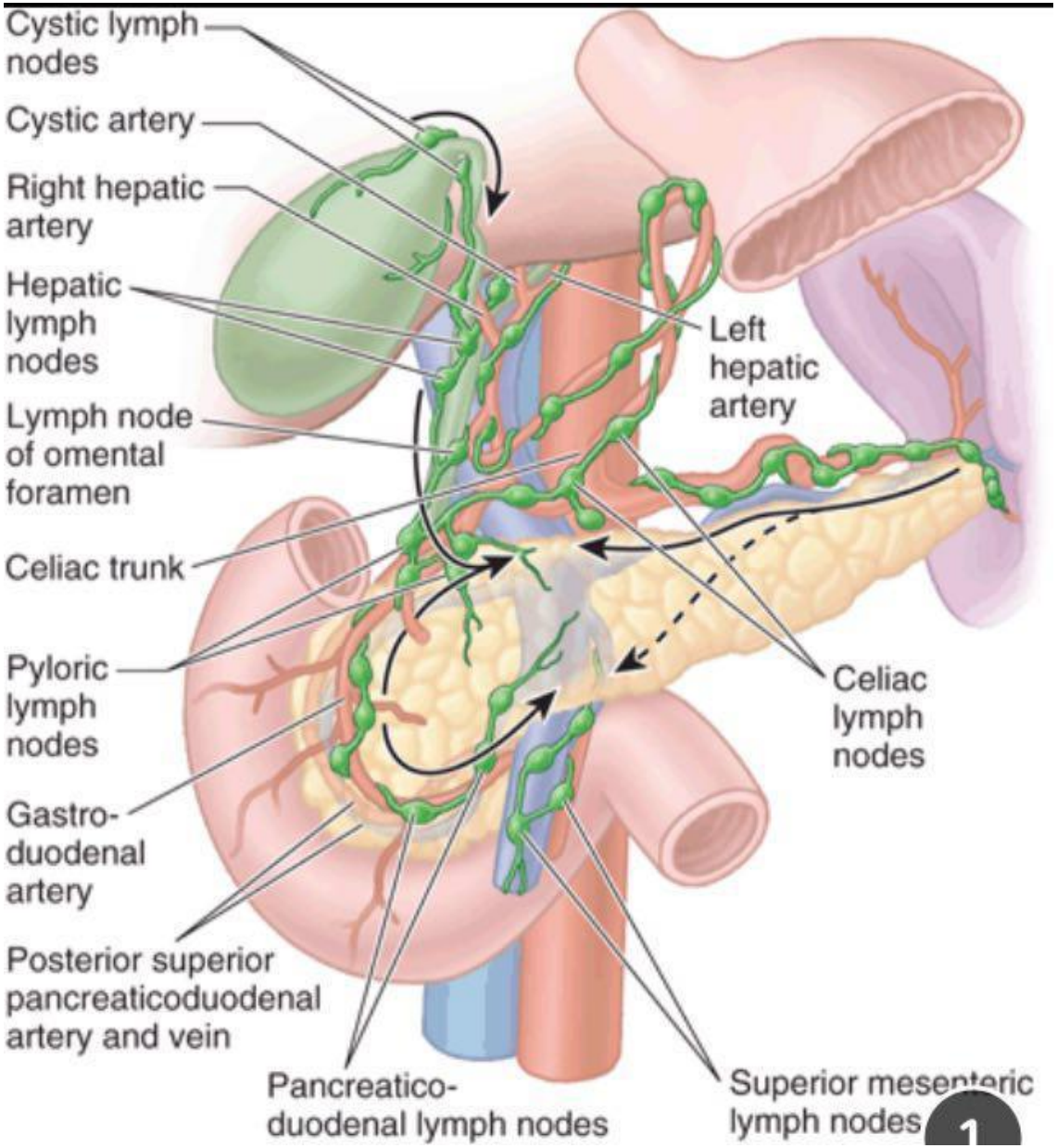
Cystic lymph nodes
Cystic artery
Right hepatic artery
Hepatic lymph nodes
Lymph node of omental foramen
Celiac trunk
Pyloric lymph nodes
Gastro-duodenal artery
Posterior superior pancreaticoduodenal artery and vein
Pancreatico-duodenal lymph nodes
Superior mesenteric lymph nodes
Left hepatic artery
Celiac lymph nodes

Lymph drainage of pancreas & spleen

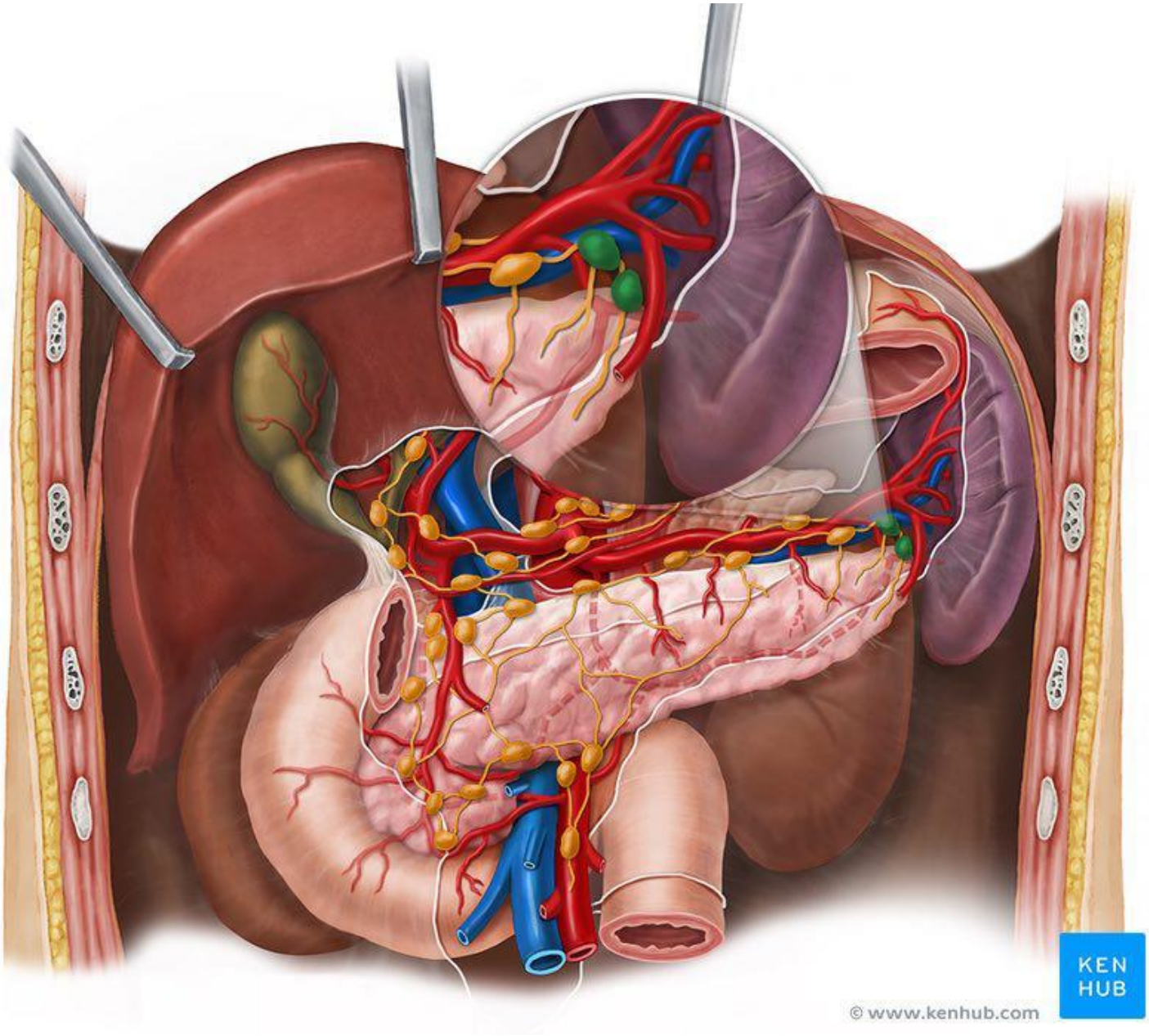
KEN
HUB
© www.kenhub.com

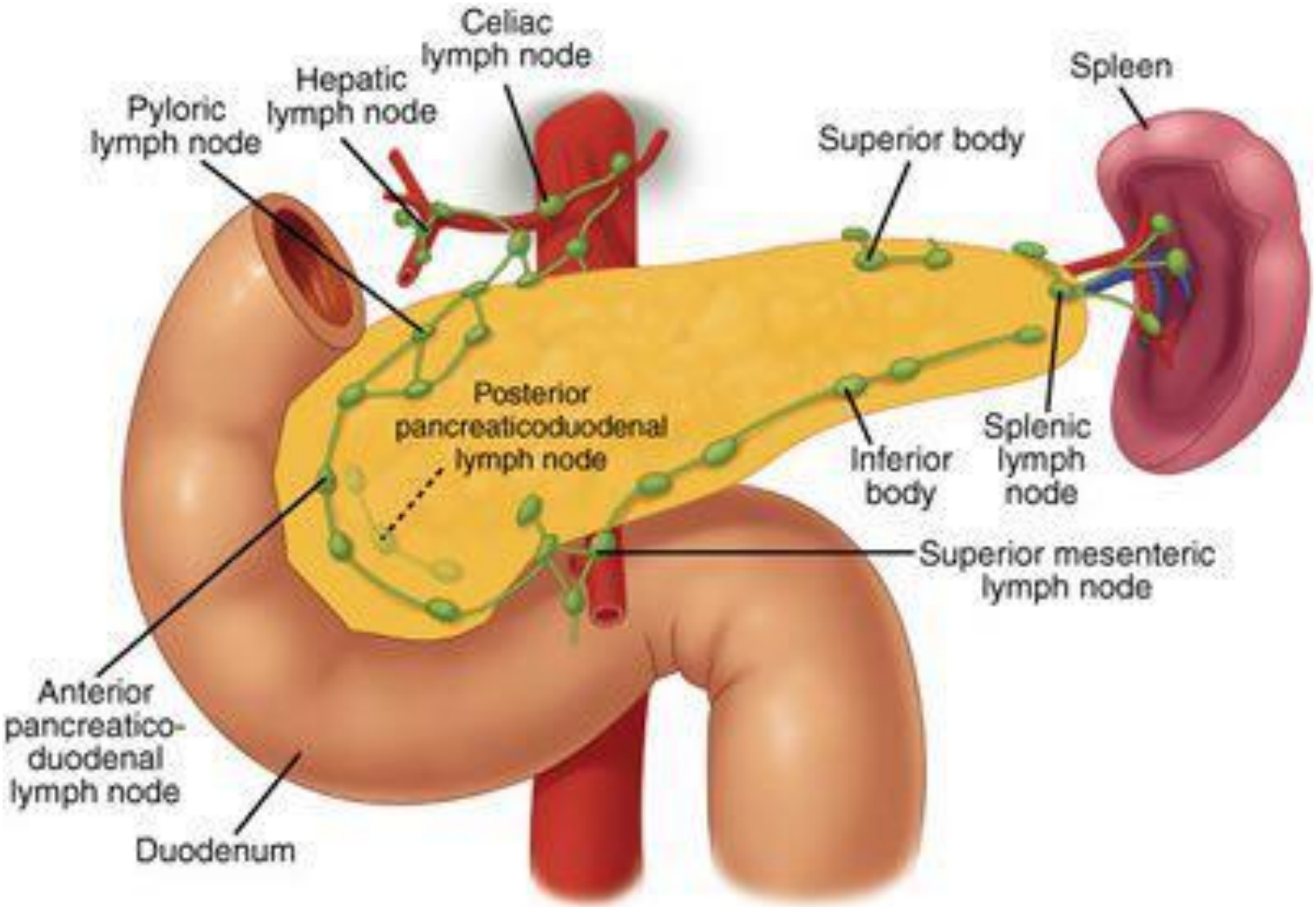

Source: Brunicardi FC, Andersen DK, Billiar TR, Dunn DL, Hunter JG, Matthews JB, Pollock RE: *Schwartz's Principles of Surgery, 9th Edition*: http://www.accessmedicine.com

Copyright © The McGraw-Hill Companies, Inc. All rights reserved.

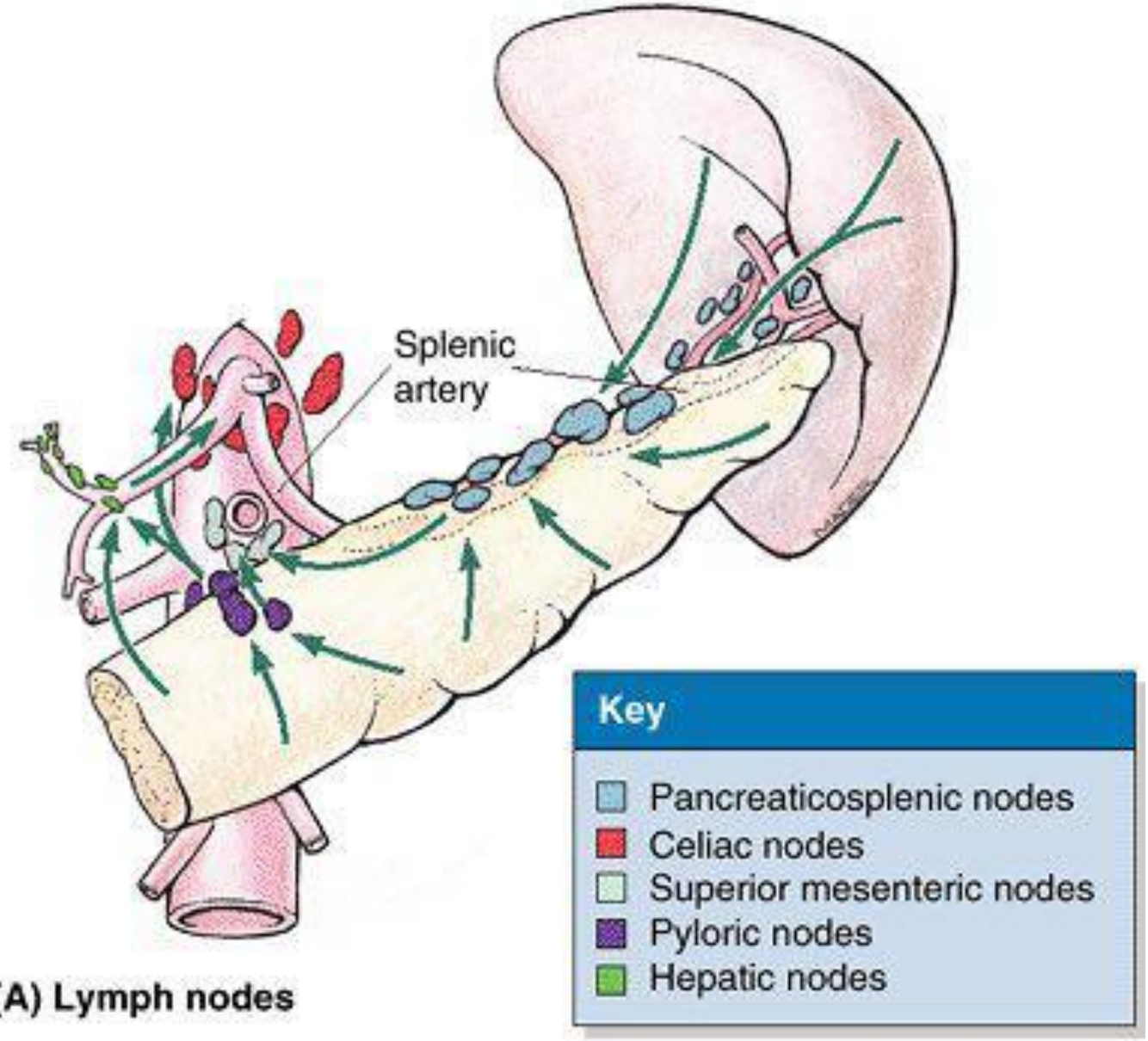

(A) Lymph nodes

The spleen as a lymph organ

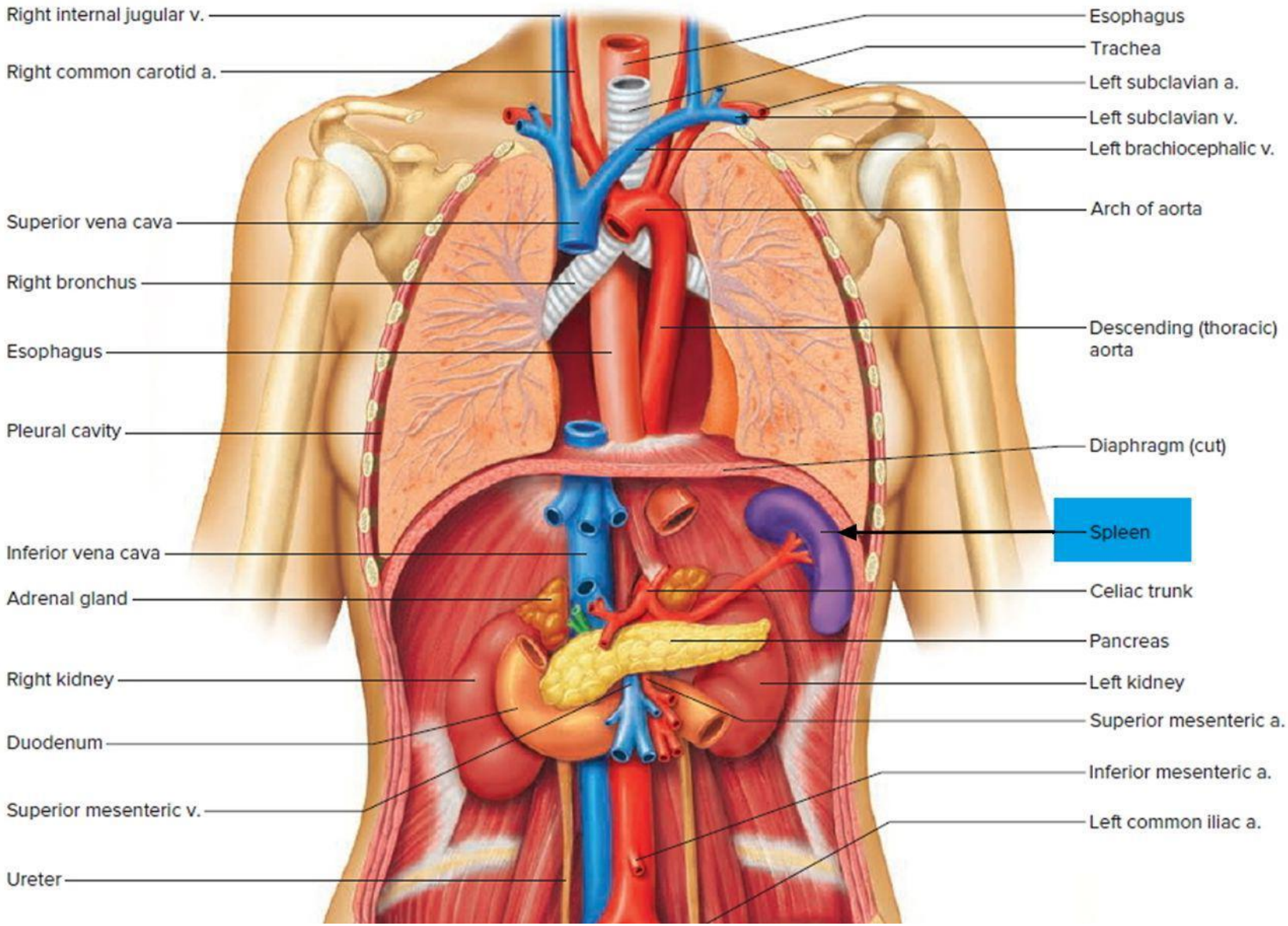
Right internal jugular v.
Right common carotid a.
Superior vena cava
Right bronchus
Esophagus
Pleural cavity
Inferior vena cava
Adrenal gland
Right kidney
Duodenum
Superior mesenteric v.
Ureter
Esophagus
Trachea
Left subclavian a.
Left subclavian v.
Left brachiocephalic v.
Arch of aorta
Descending (thoracic) aorta
Diaphragm (cut)
Spleen
Celiac trunk
Pancreas
Left kidney
Superior mesenteric a.
Inferior mesenteric a.
Left common iliac a.

SPLEEN ANATOMY

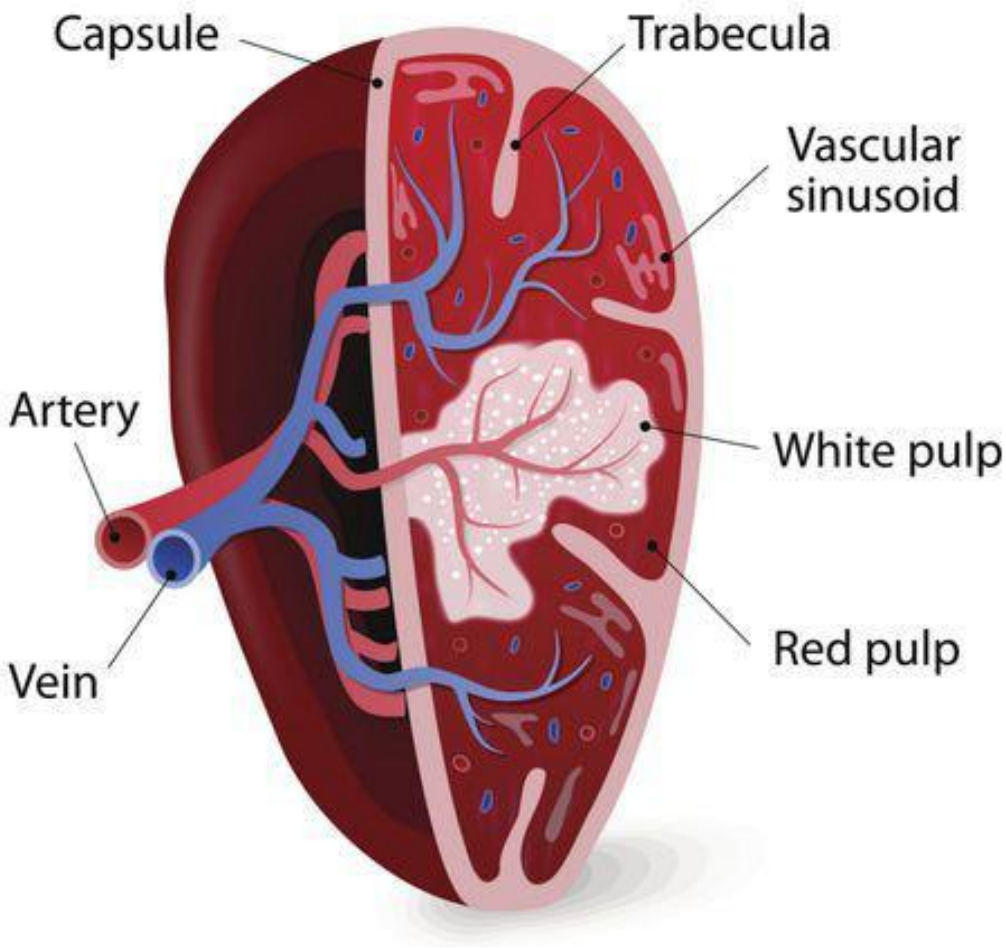

Red & white pulp

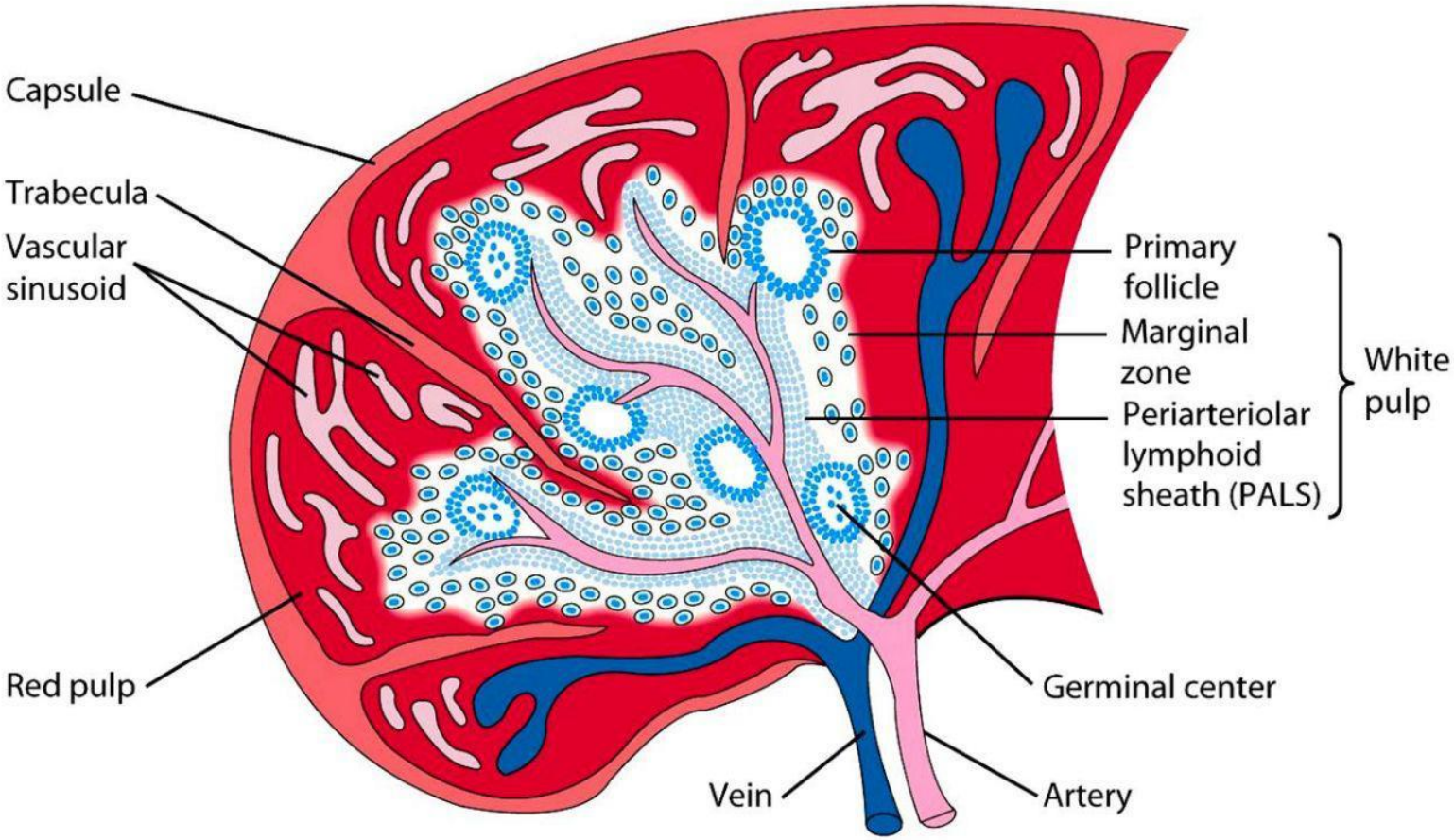

Splenic Cords and Splenic Sinusoids

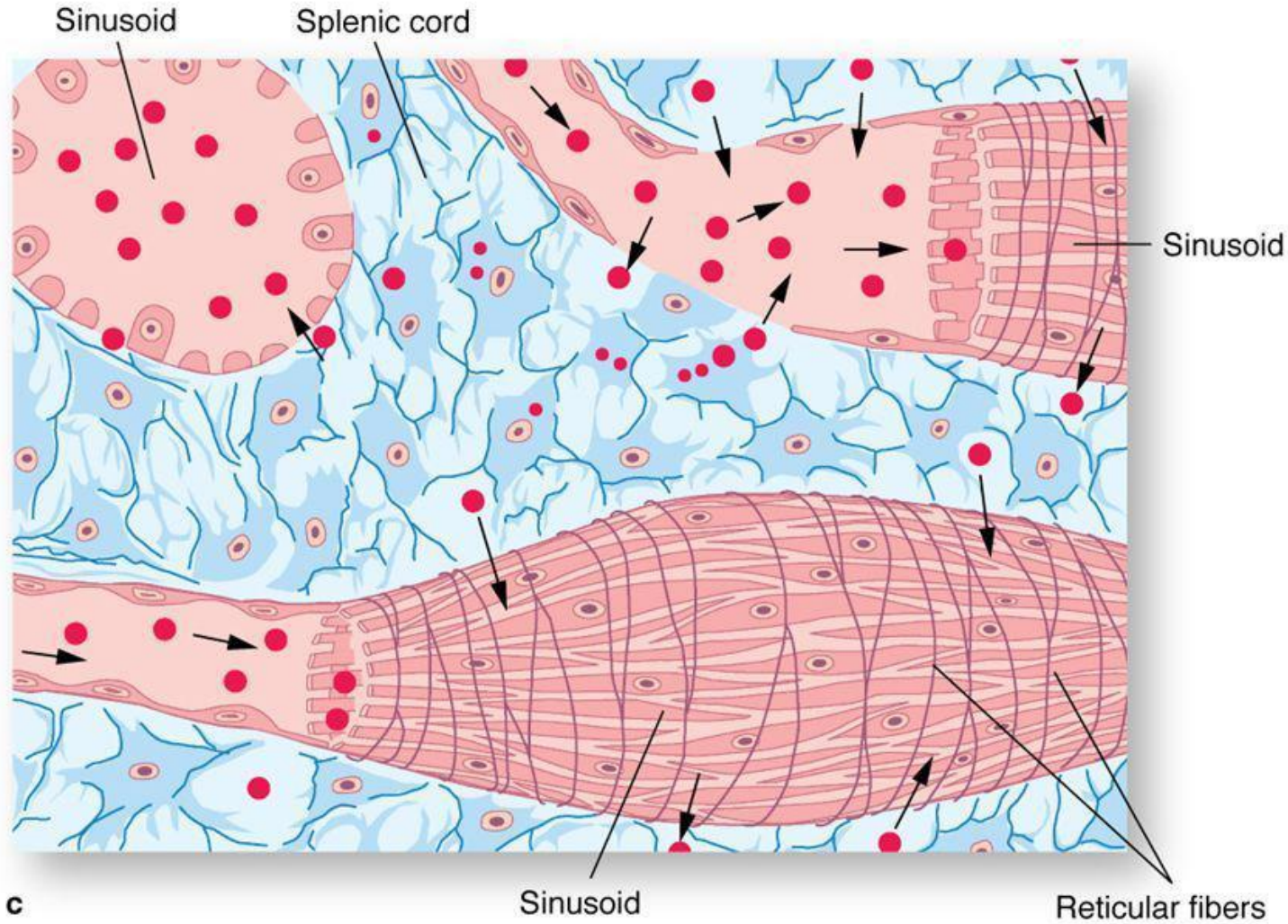

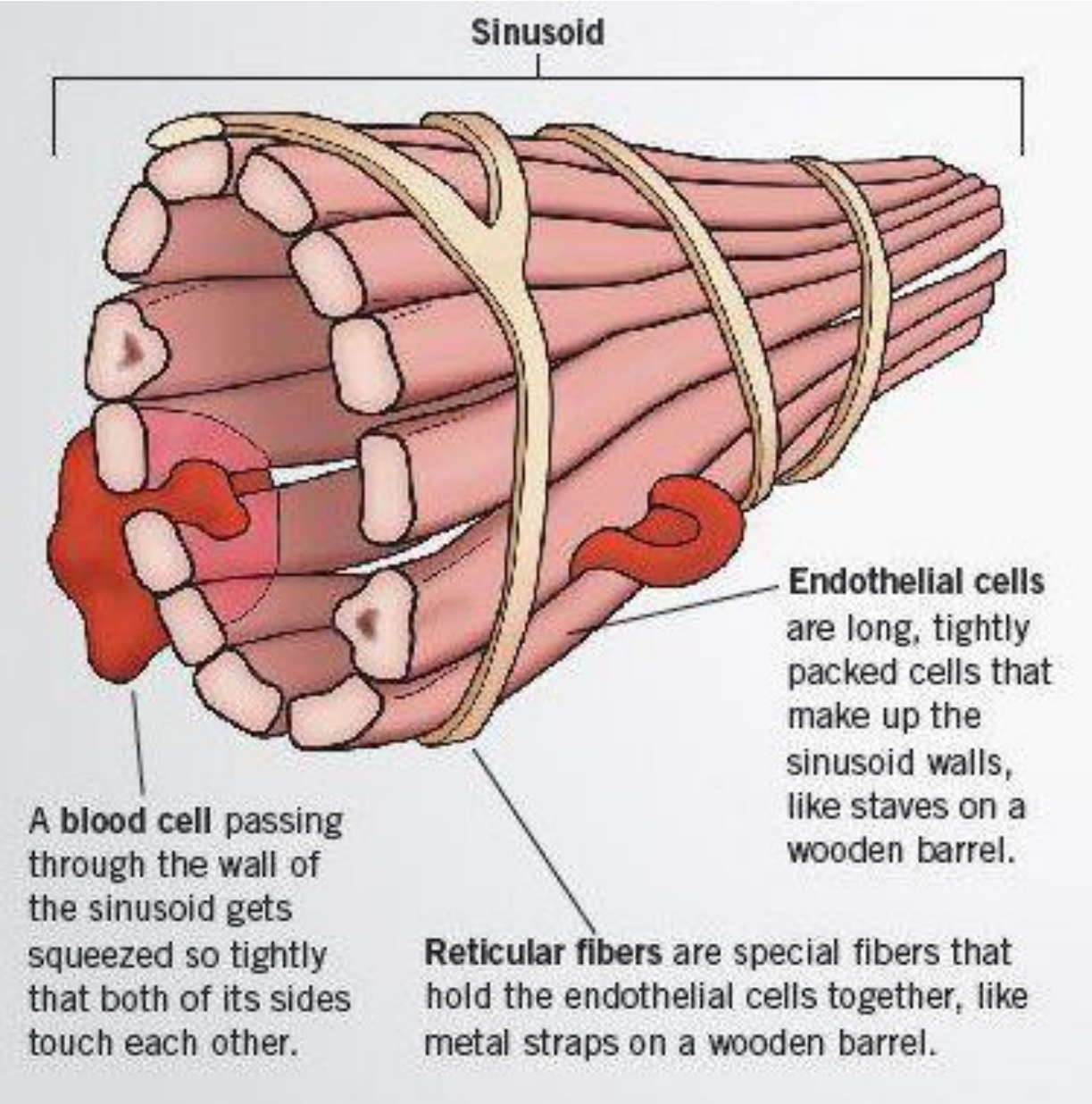
Sinusoid
Endothelial cells are long, tightly packed cells that make up the sinusoid walls, like staves on a wooden barrel.
A blood cell passing through the wall of the sinusoid gets squeezed so tightly that both of its sides touch each other.
Reticular fibers are special fibers that hold the endothelial cells together, like metal straps on a wooden barrel.

Terminal lymphatic vessels

Right lymphatic duct

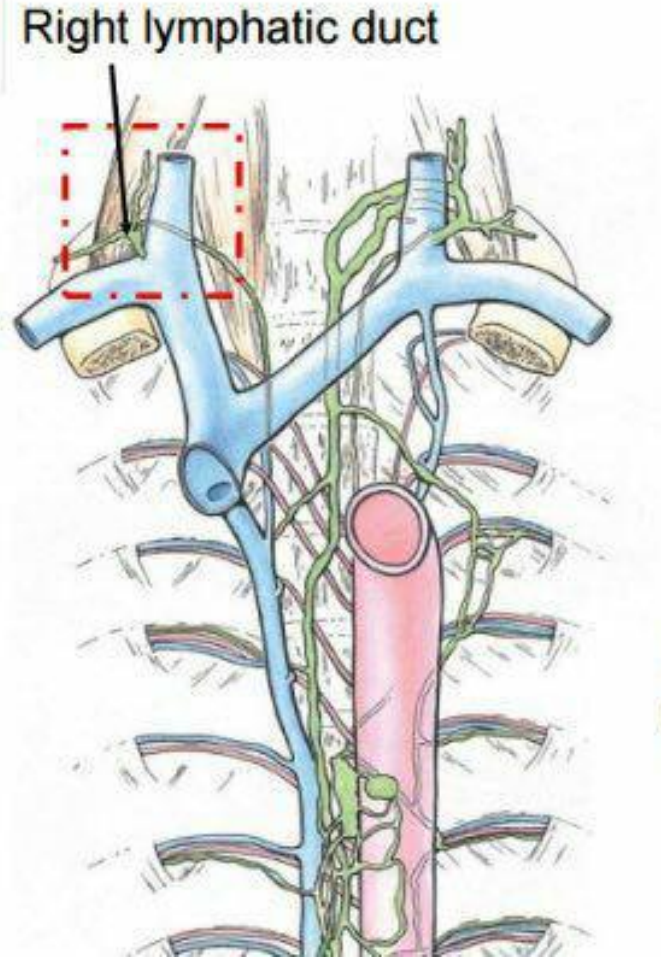

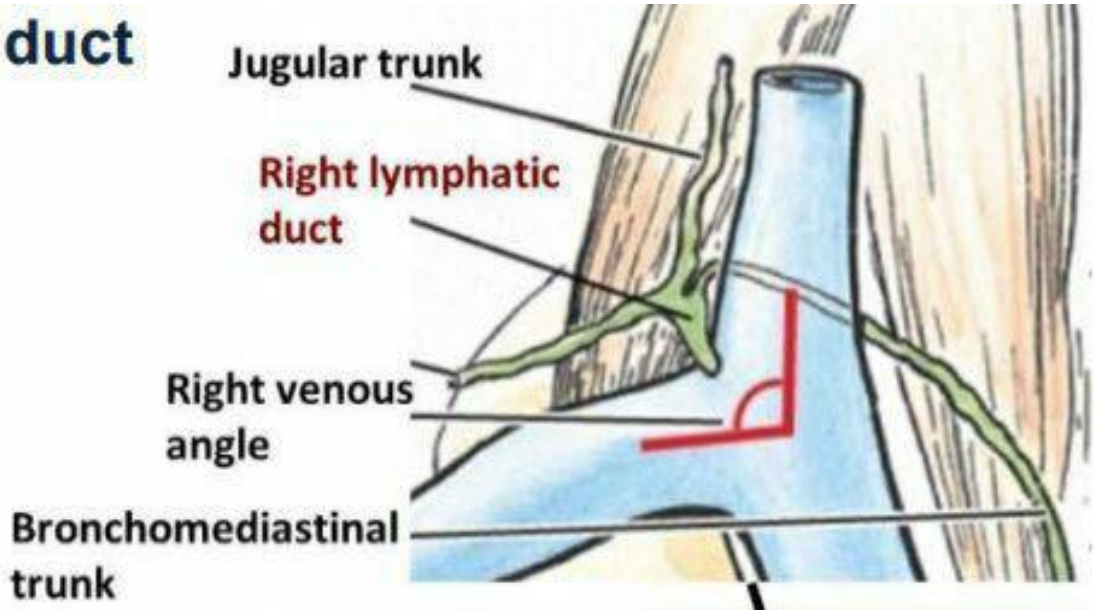

Rt. lymphatic duct drains the Rt. Upper Quadrant

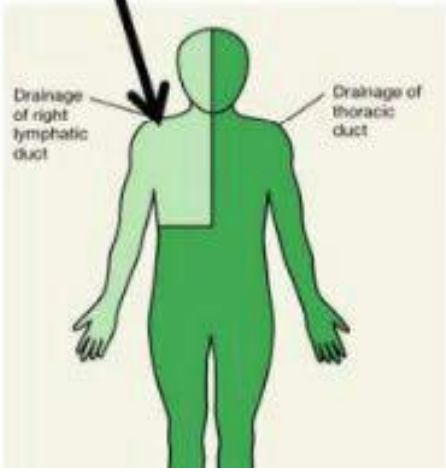

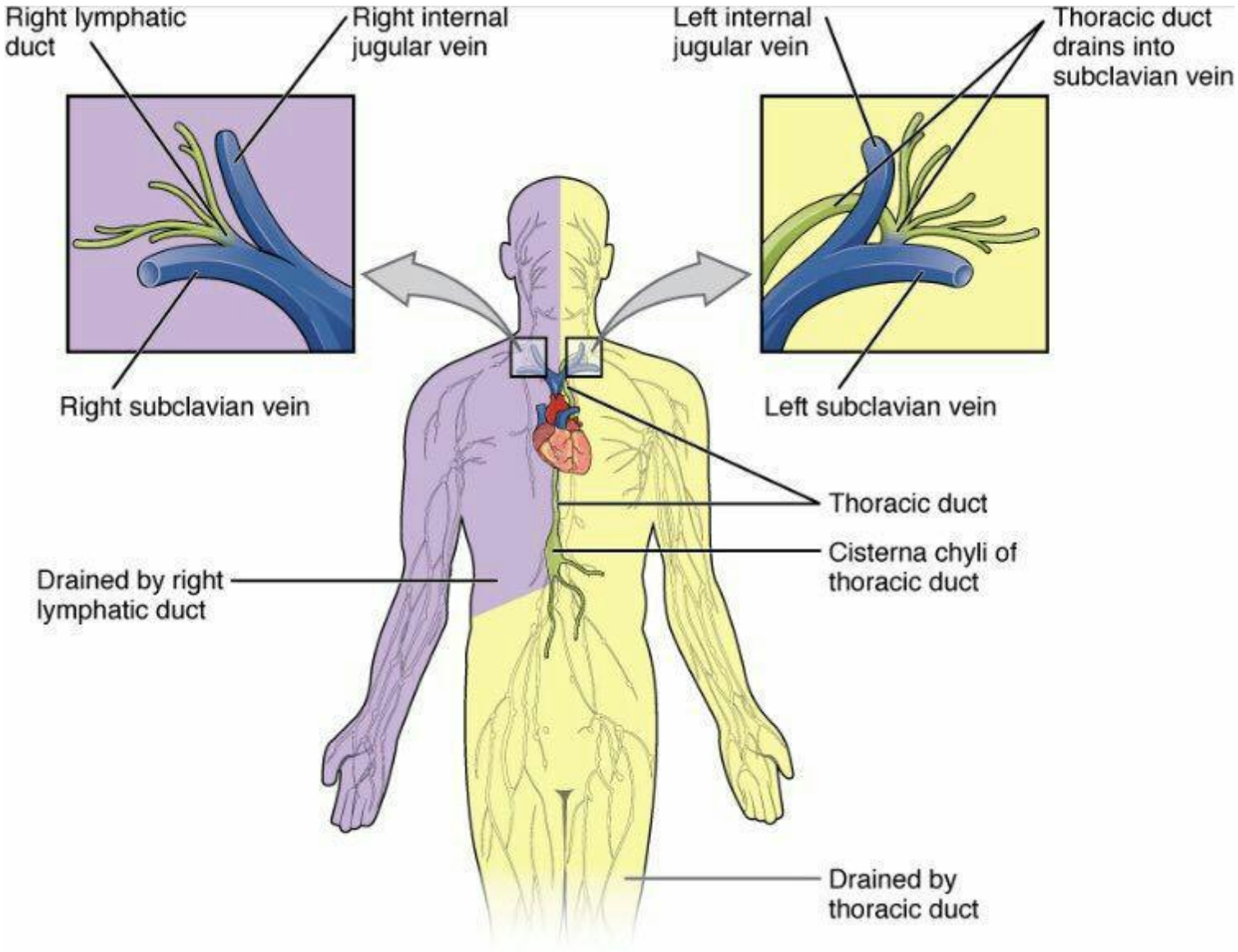
Right lymphatic duct
Right internal jugular vein
Left internal jugular vein
Thoracic duct drains into subclavian vein
Right subclavian vein
Left subclavian vein
Thoracic duct
Cisterna chyli of thoracic duct
Drained by right lymphatic duct
Drained by thoracic duct

Thank you