

# Perineum

---

محمد عصام

محمد داوود

محمد  
إبراهيم

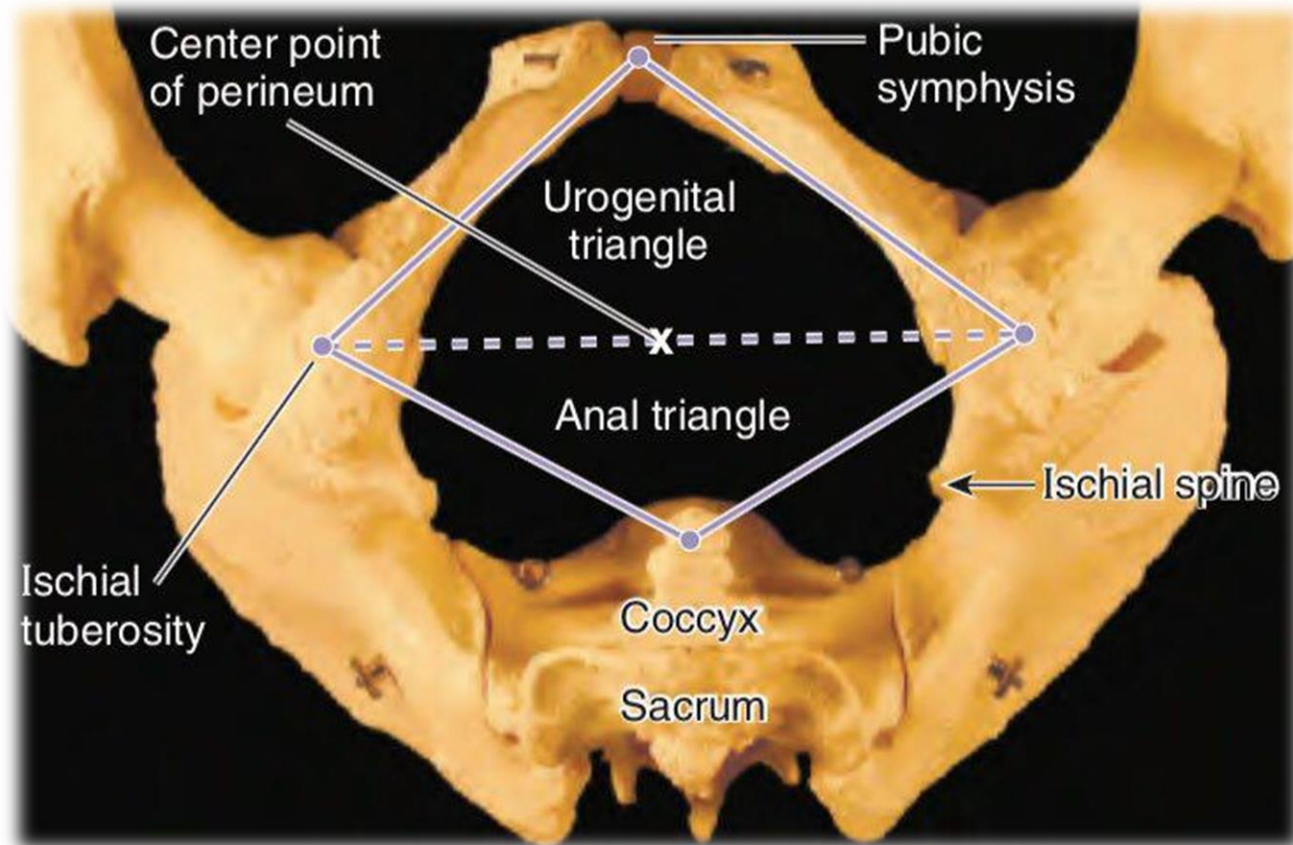
رأفت محمد

محمد علي

وليد غانم

مصطفى  
حسين

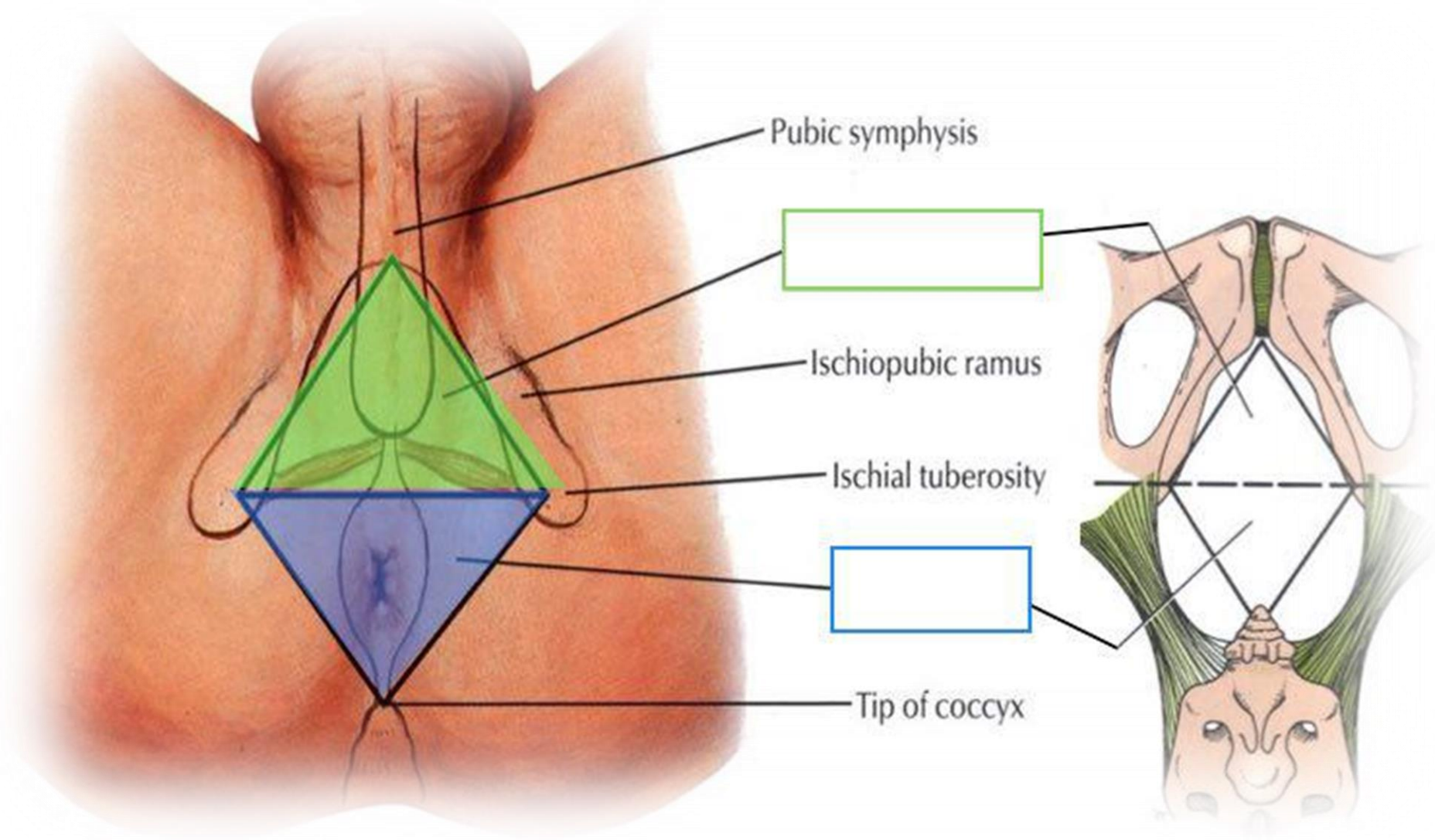
# *Introduction*

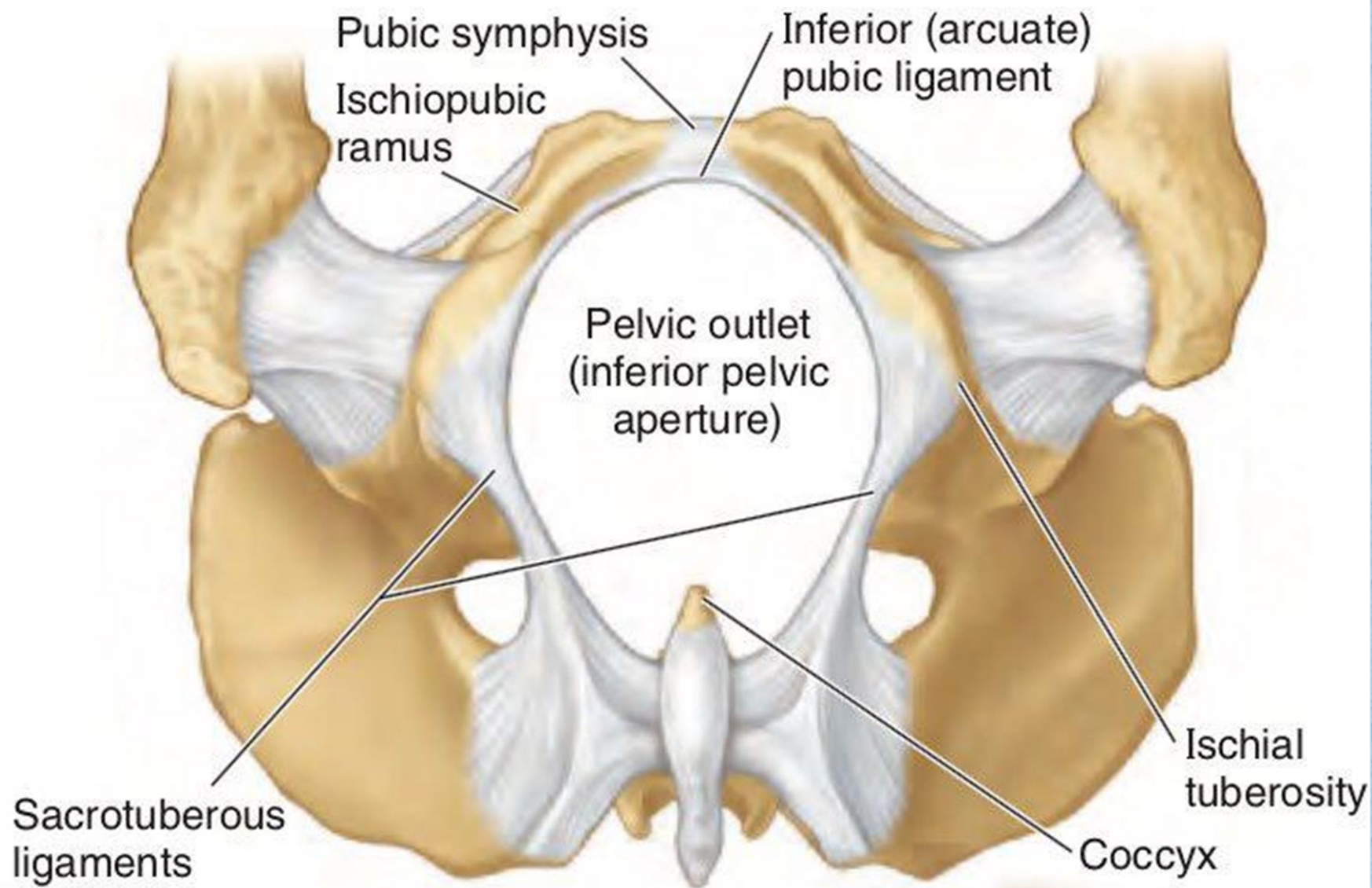


## **The perineal compartment or boundaries**

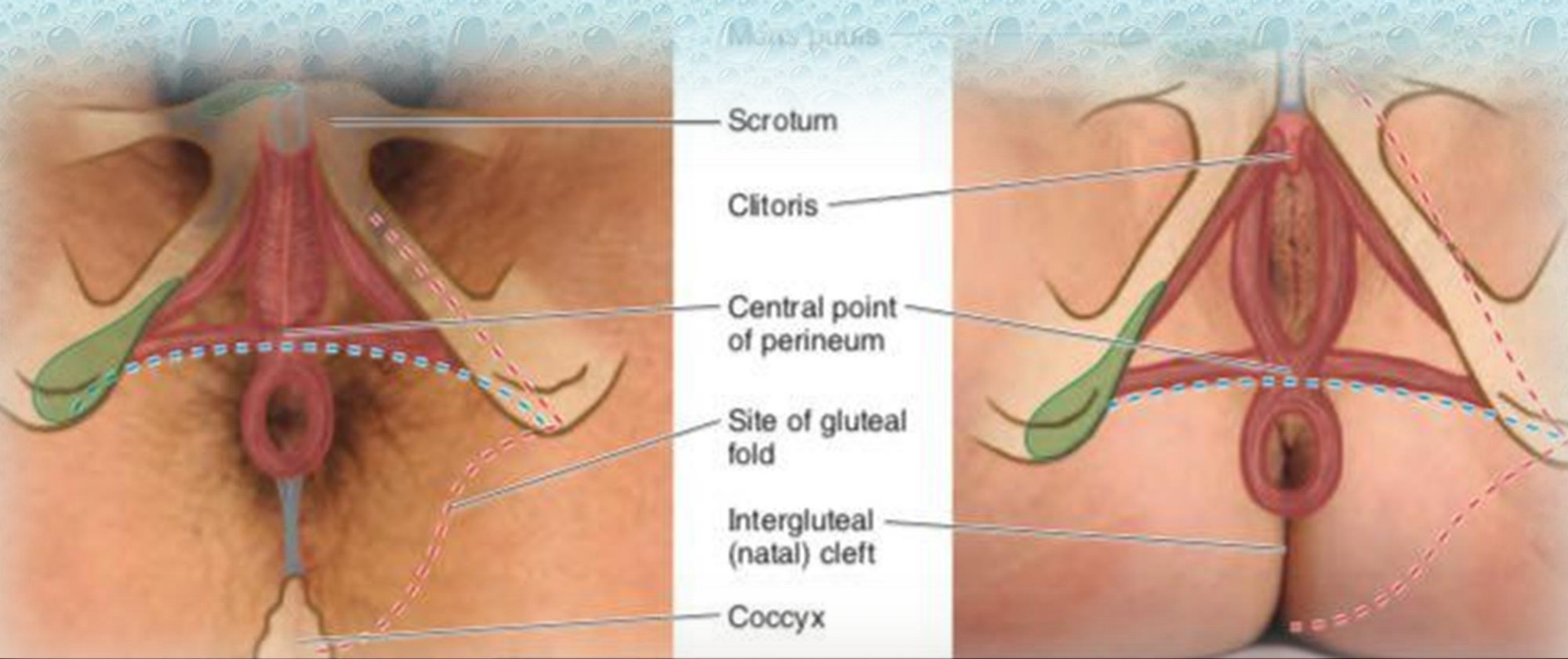

- Pubic symphysis, anteriorly.
- Ischiopubic rami (combined inferior pubic rami and ischial rami), anterolaterally.
- Ischial tuberosities, laterally.
- Sacrotuberous ligaments, posterolaterally.
- Inferiormost sacrum and coccyx, posteriorly.





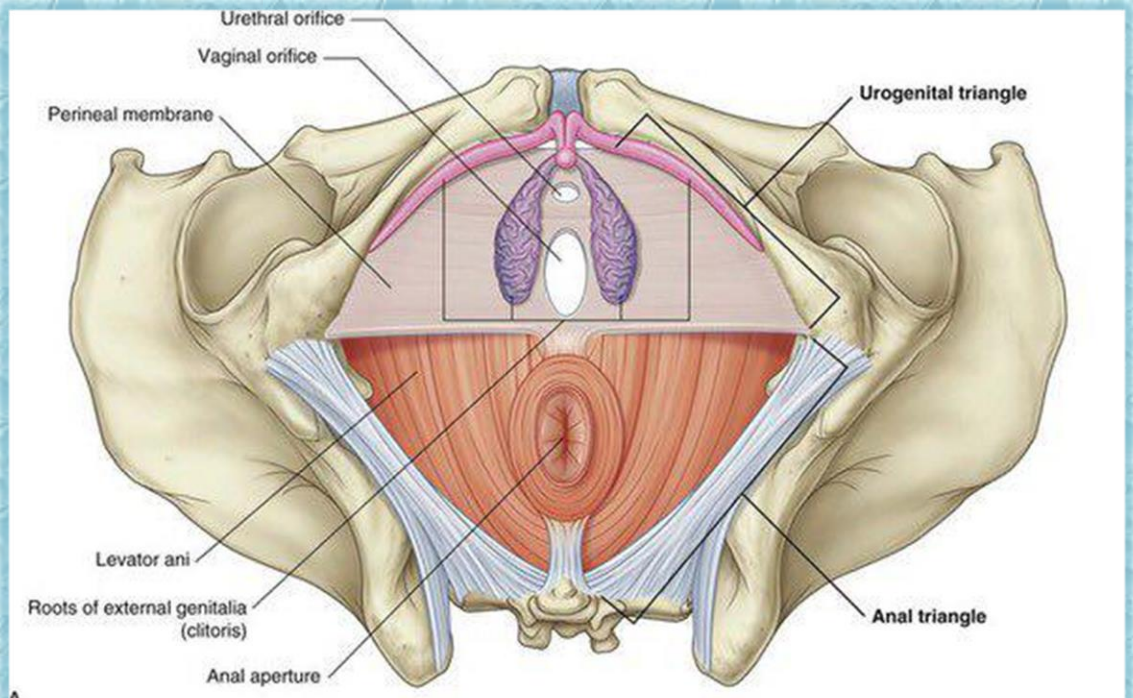




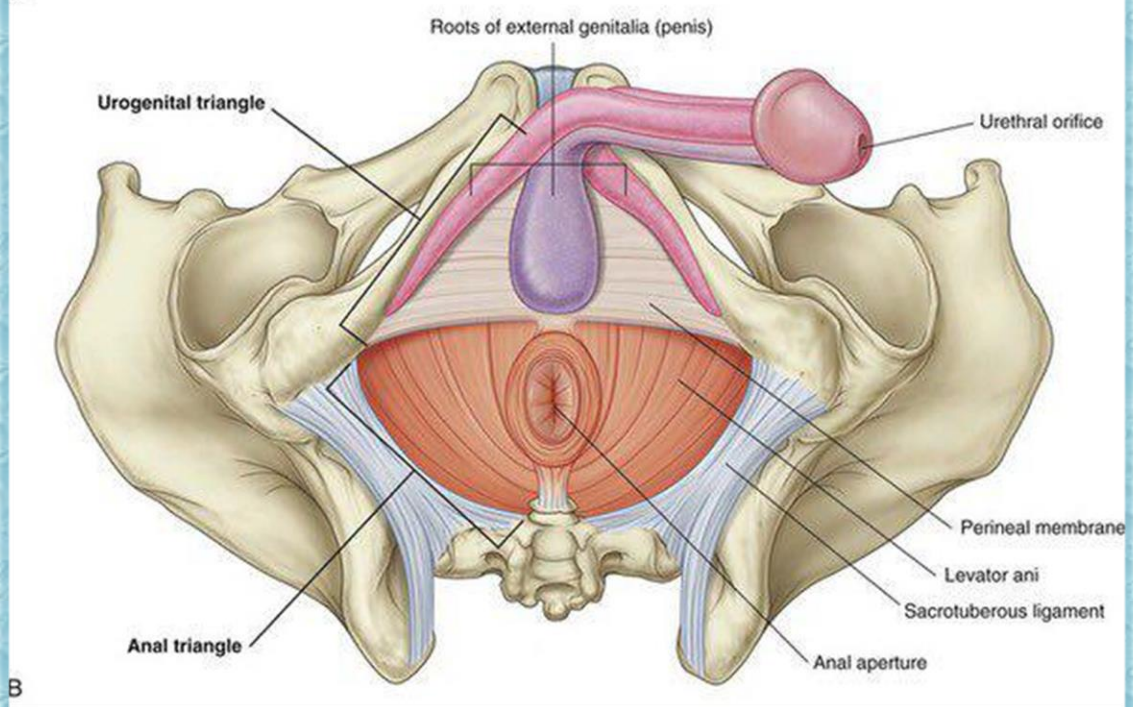


Views (lithotomy position) - - - Line dividing perineal region into urogenital. - - - Outline of perineal region.





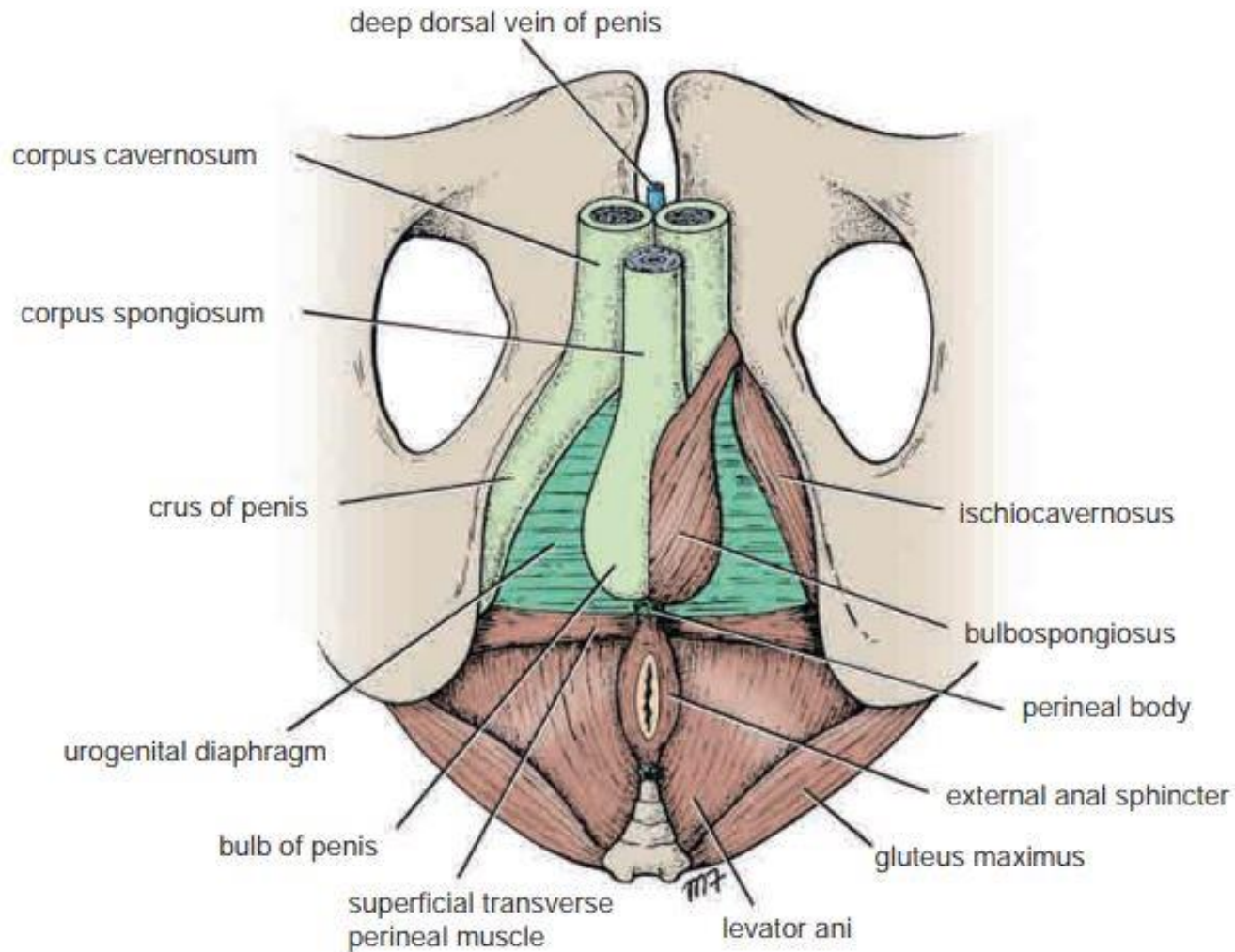
A



B



*Urogenital triangle in  
male and female*



**FIGURE 8.17** Root of penis and perineal muscles.

*Urogenital triangle in male*

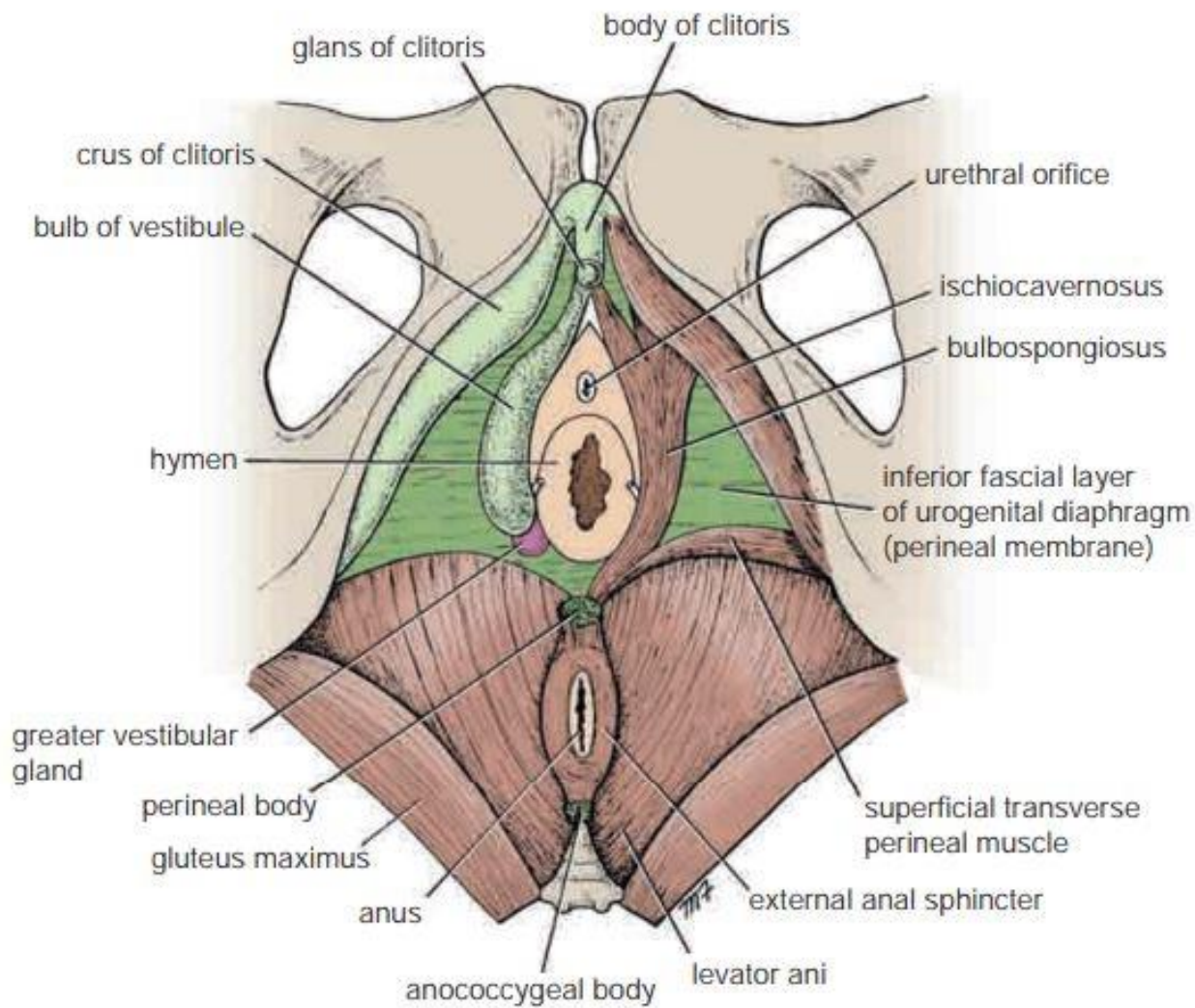
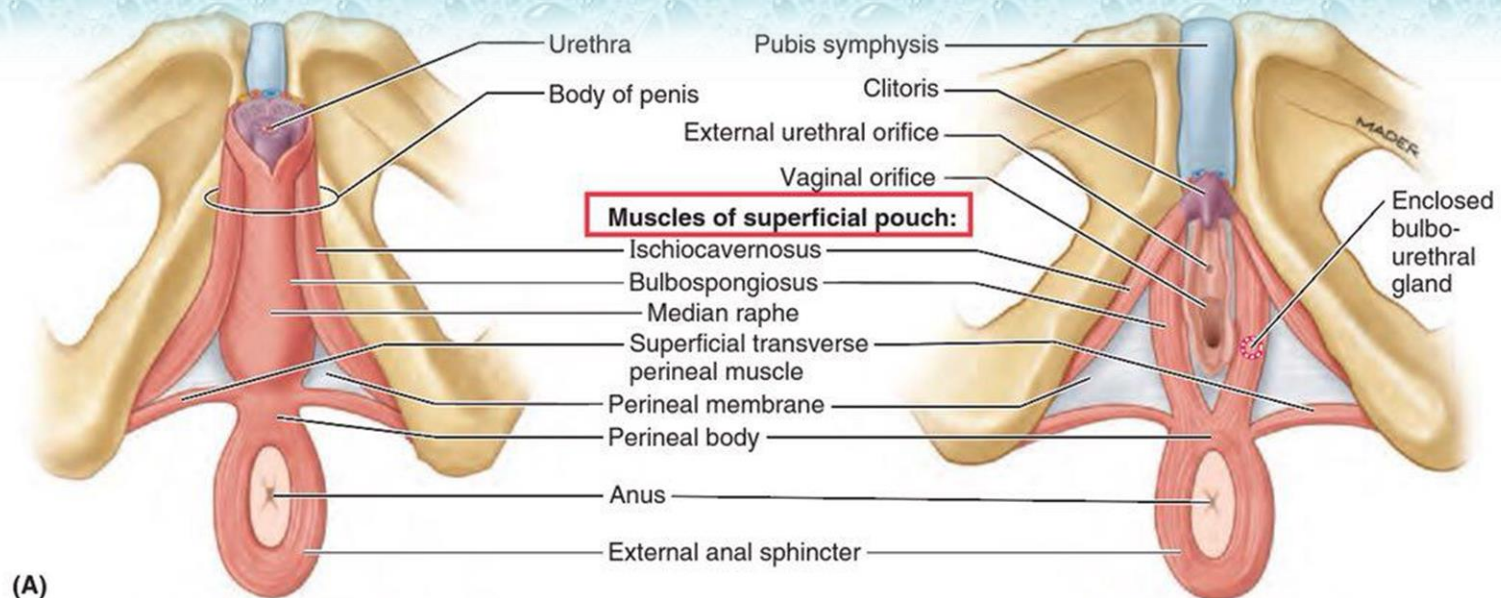


FIGURE 8.18 Root and body of the clitoris and the perineal muscles.

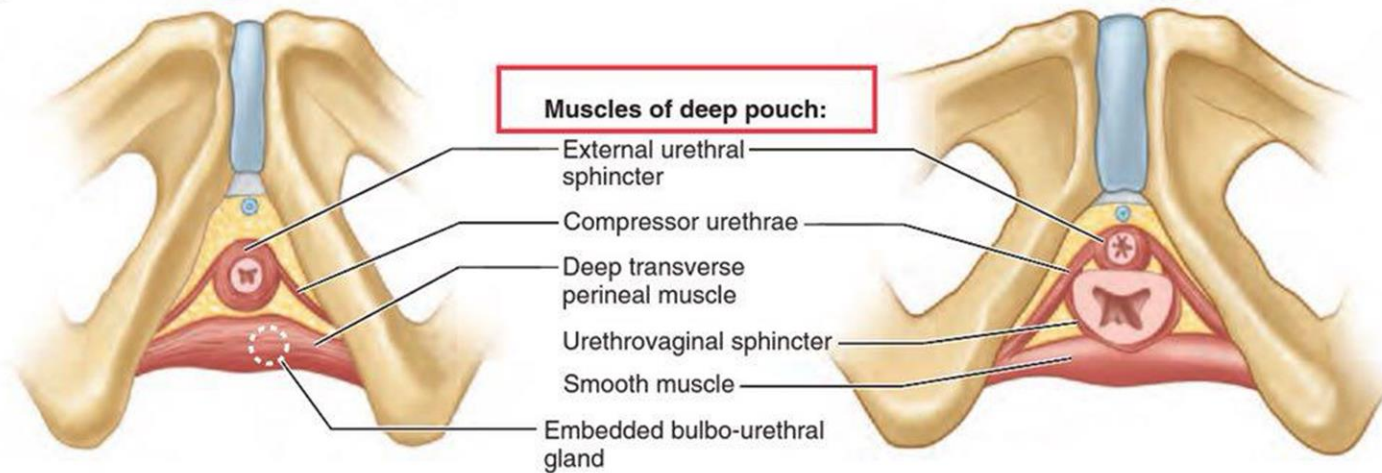
*Urogenital triangle in female*



# **Muscles**



(A)



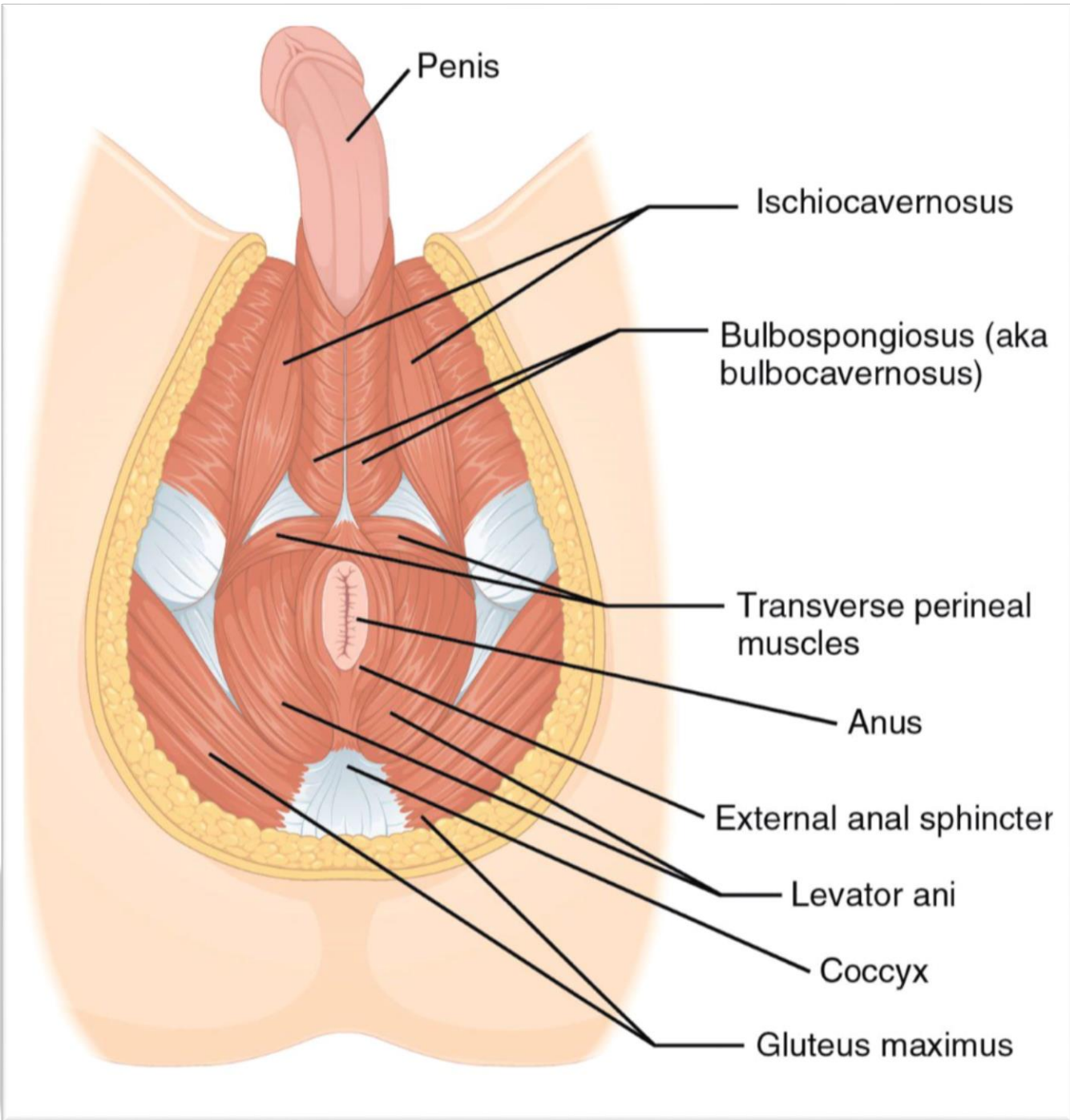
(B)

Male

Inferior views

Female

**FIGURE 3.66.** Muscles of perineum. A. Muscles of superficial perineal pouch. B. Muscles of deep perineal pouch.



Penis

Ischiocavernosus

Bulbospongiosus (aka bulbocavernosus)

Transverse perineal muscles

Anus

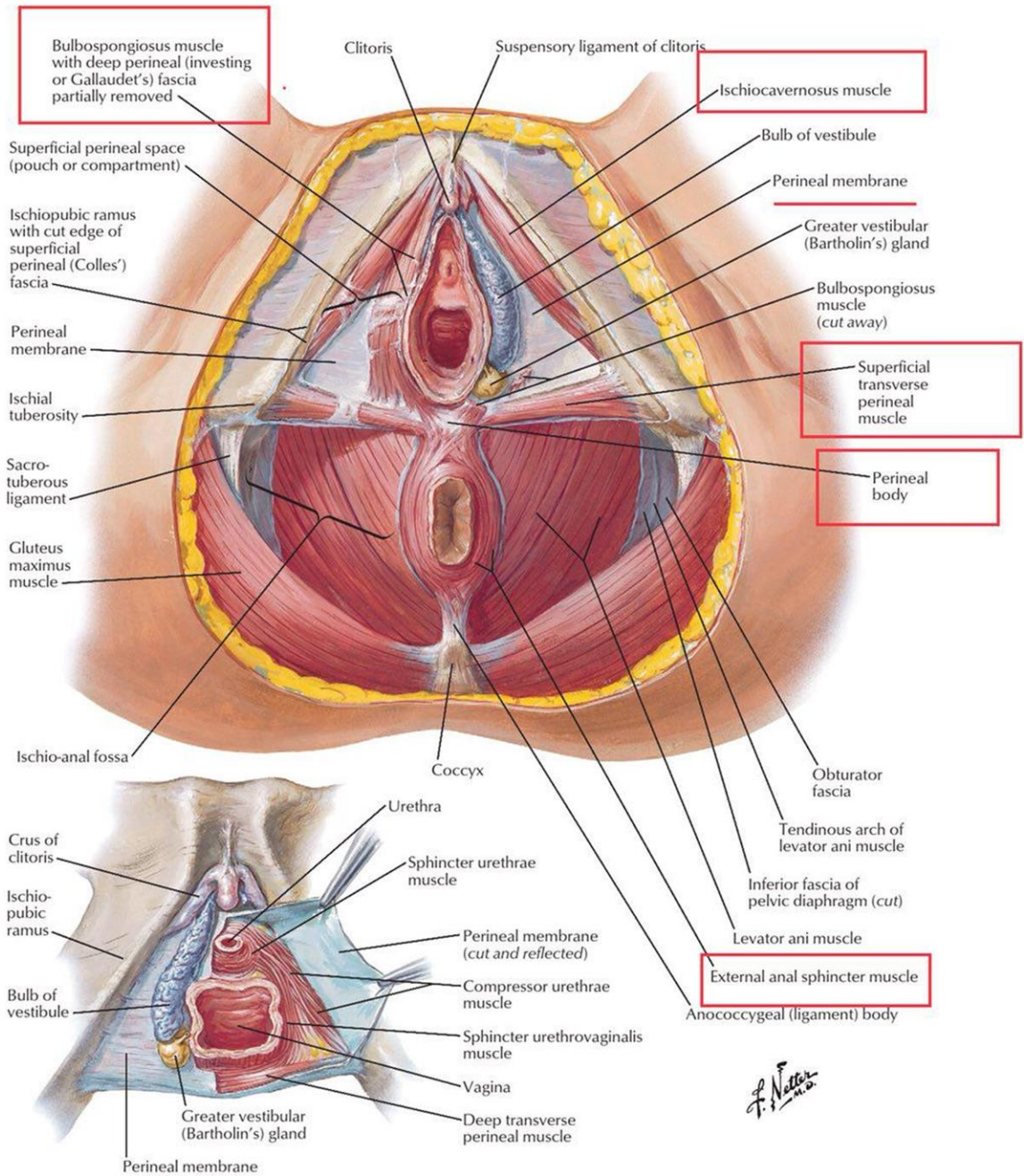
External anal sphincter

Levator ani

Coccyx

Gluteus maximus





# Superficial Pouches



# Urinary Bladder of Male

## Frontal Section

Superior layer of urogenital membrane

Inferior layer of urogenital membrane

Deep perineal fascia

Superficial perineal fascia

**DEEP PERINEAL POUCH**

**SUPERFICIAL PERINEAL POUCH**

Corpus spongiosum and bulbospongiosus muscle

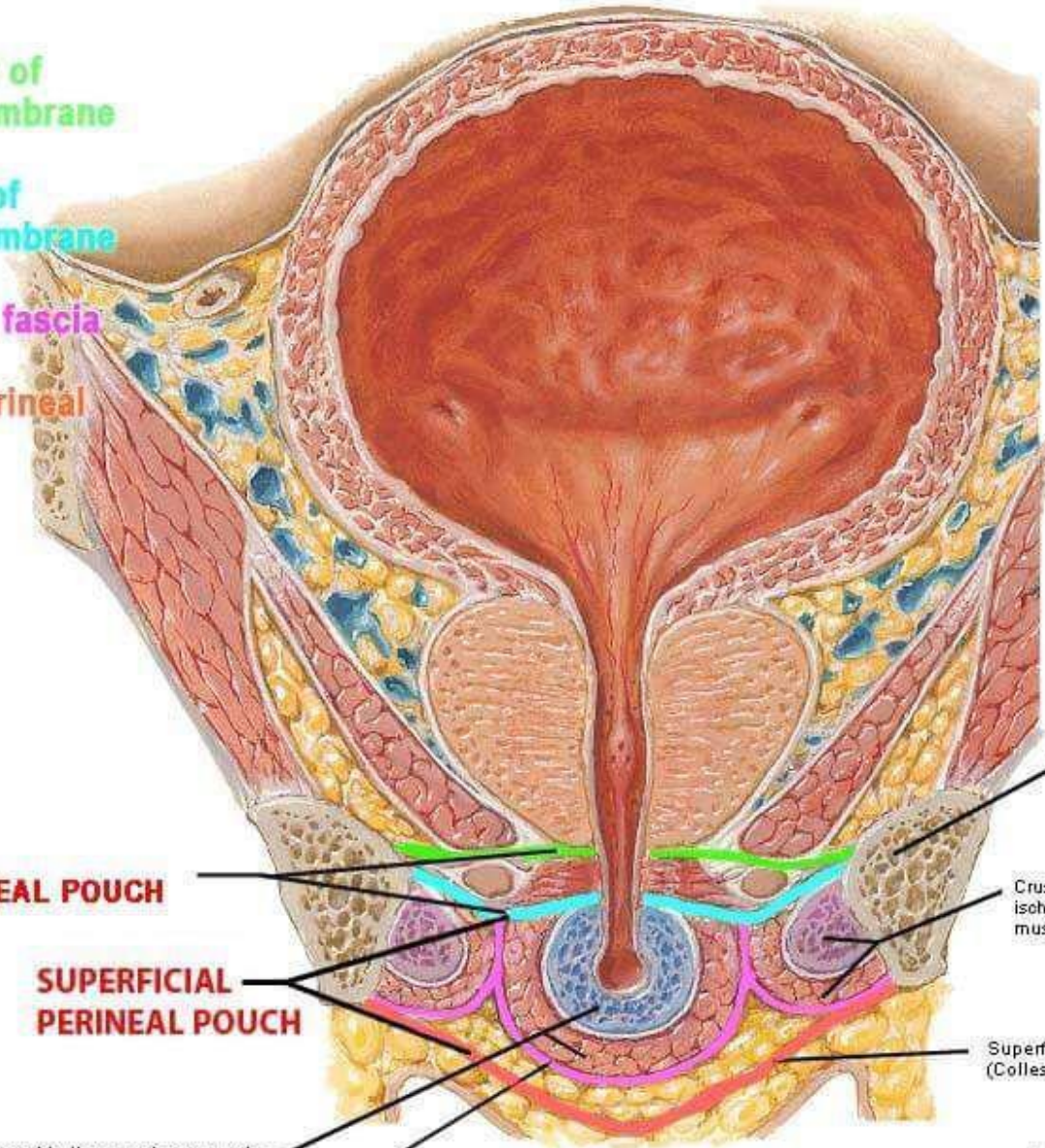
Deep perineal (investing or Gallaudet's) fascia

Inferior pubic ramus

Crus of penis and ischio-cavernosus muscle

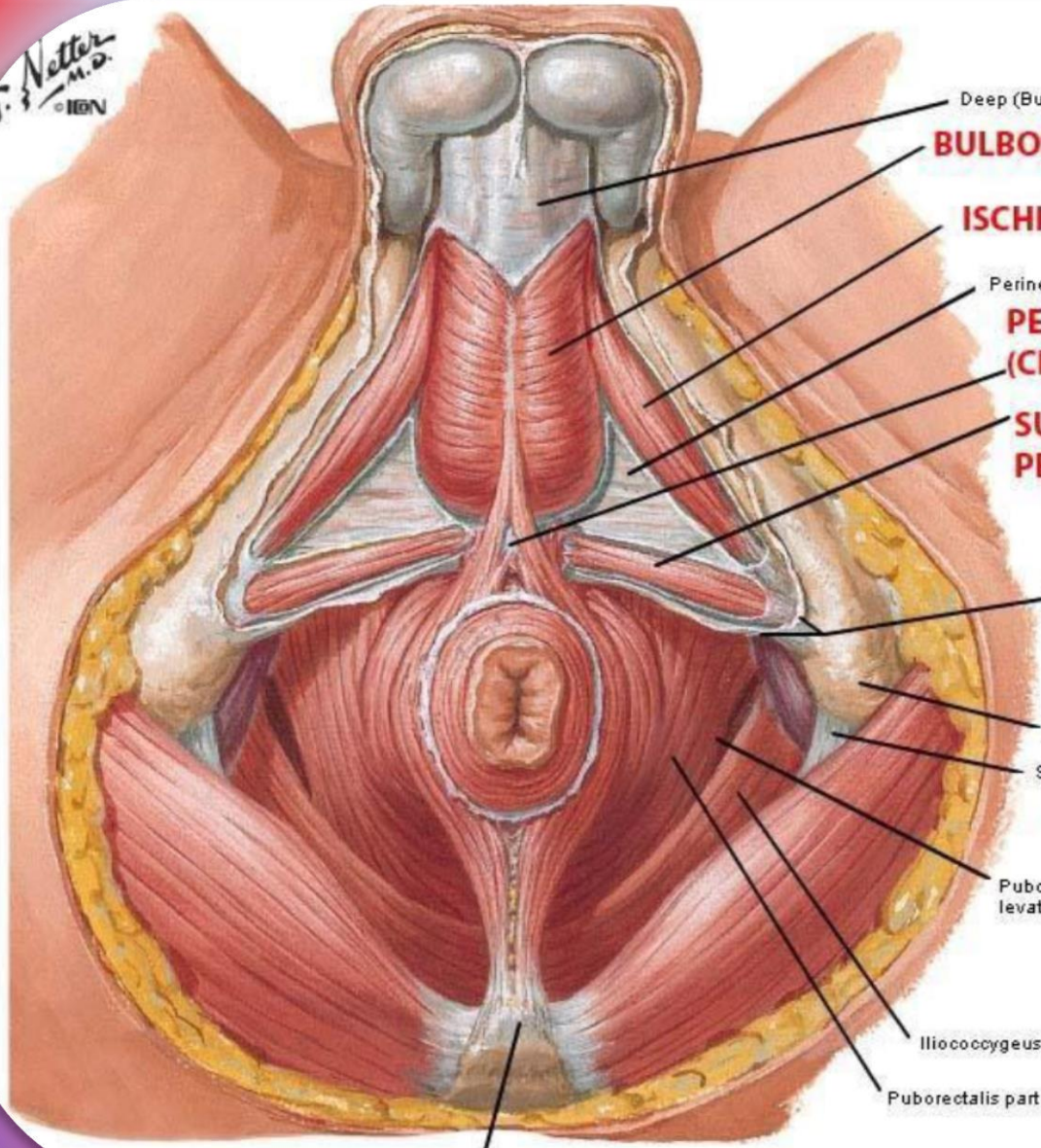
Superficial perineal (Colles') fascia

*F. Netter M.D.*  
© IEN



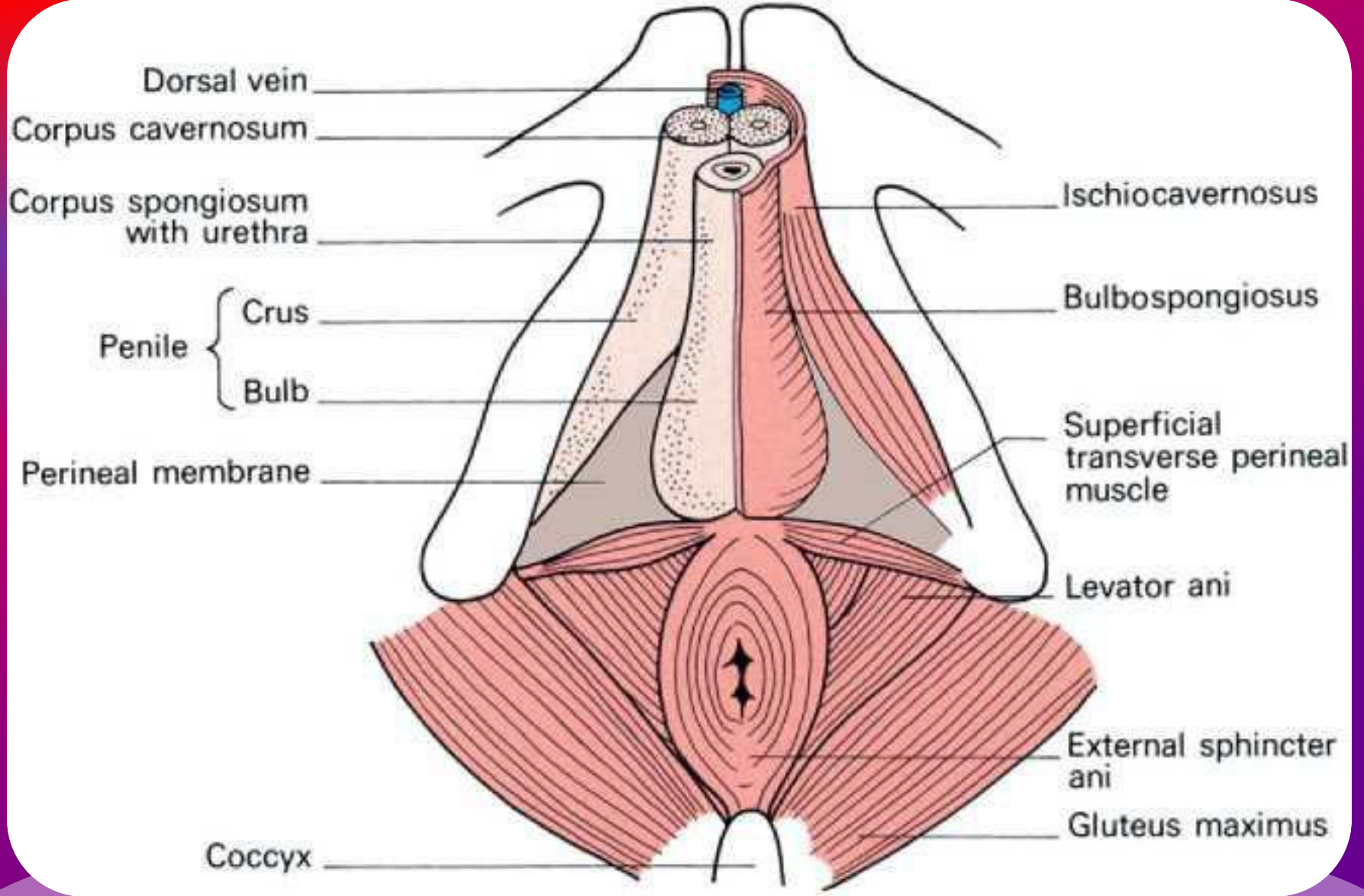


T. Netter  
M.D.  
© IBN



- Deep (Buck's) fascia of penis
- BULBOSPONGIOSUS**
- ISCHIOCAVERNOSUS**
- Perineal membrane
- PERINEAL BODY (CENTRAL TENDON)**
- SUPERFICIAL TRANSVERSE PERINEAL MUSCLE**
- Superficial perineal (Colles') fascia (cut edges)
- Ischial tuberosity
- Sacrotuberous ligament
- Pubococcygeus part of levator ani muscle
- Iliococcygeus part of levator ani muscle
- Puborectalis part of levator ani muscle

Tip of coccyx





**Superficial perineal space - between Colle's fascia and the inferior fascia of the urogenital diaphragm**  
**Deep perineal space - between the superior and inferior fascia of the urogenital diaphragm**

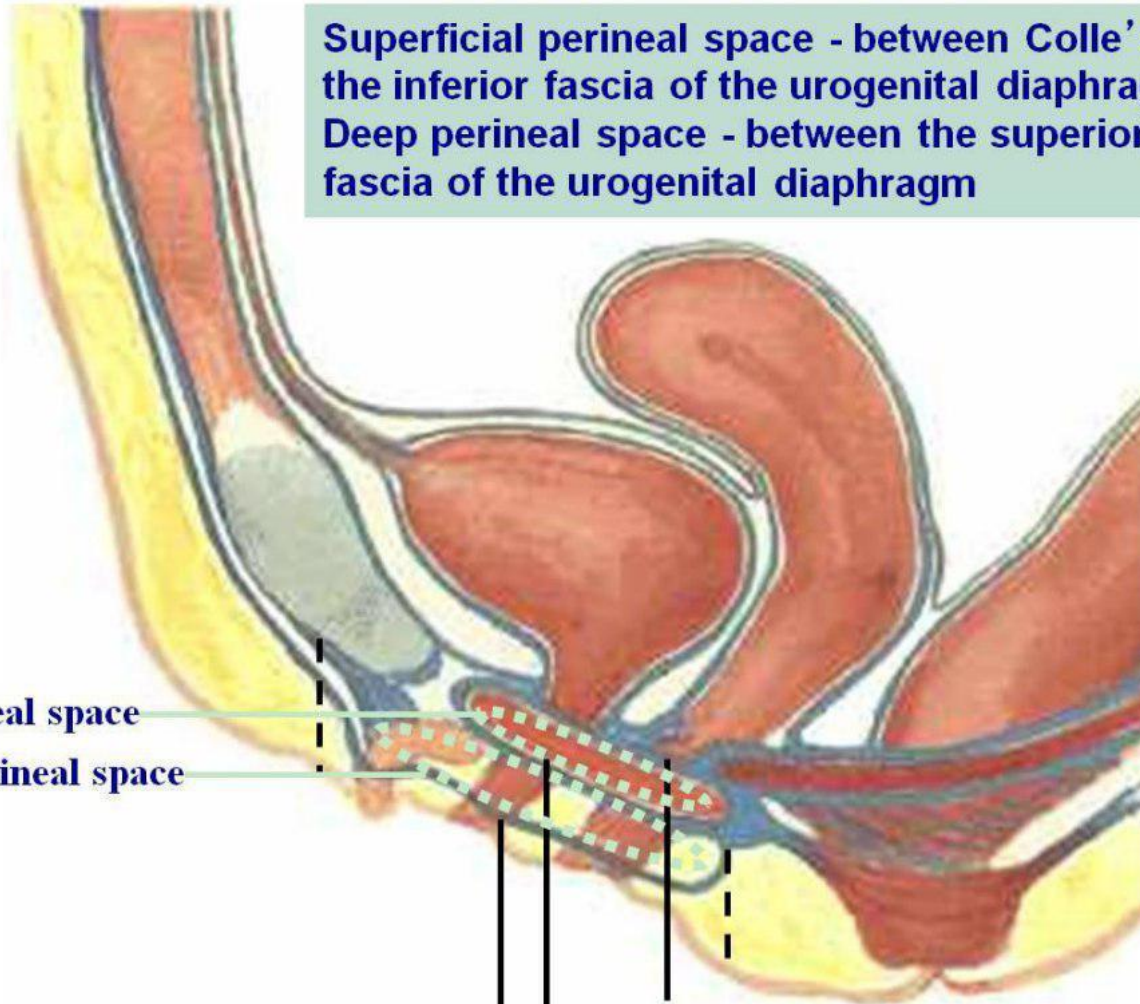
**deep perineal space**

**superficial perineal space**

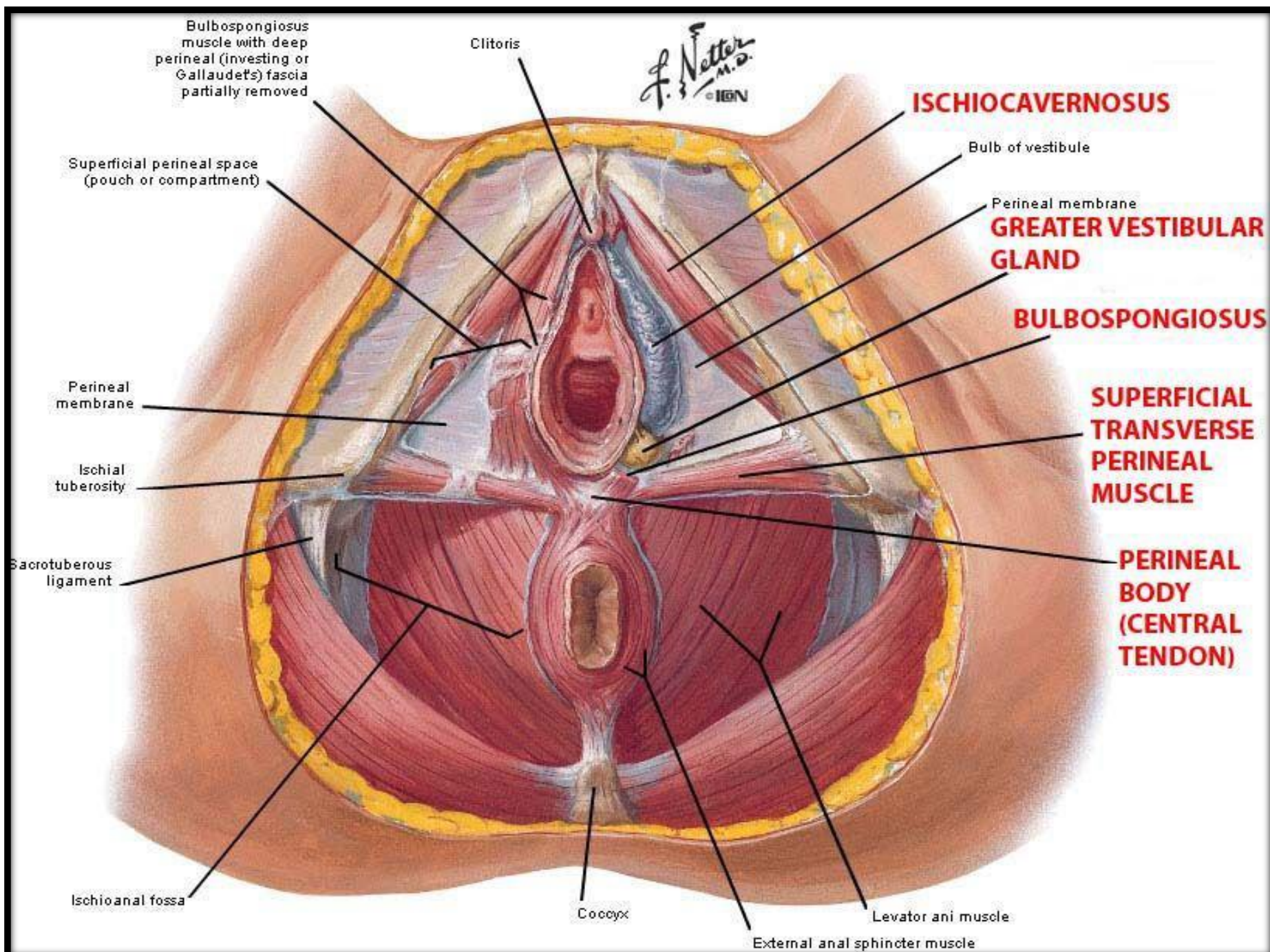
**membranous layer of superficial fascia  
(Colles' fascia)**

**superior fascia of urogenital diaphragm**

**inferior fascia of urogenital diaphragm**







Bulbospongiosus muscle with deep perineal (investing or Gallaudet's) fascia partially removed

Clitoris

F. Netter M.D. © IGM

**ISCHIOCAVERNOSUS**

Superficial perineal space (pouch or compartment)

Bulb of vestibule

Perineal membrane

**GREATER VESTIBULAR GLAND**

**BULBOSPONGIOSUS**

Perineal membrane

**SUPERFICIAL TRANSVERSE PERINEAL MUSCLE**

Ischial tuberosity

**PERINEAL BODY (CENTRAL TENDON)**

Sacrospinous ligament

Ischioanal fossa

Coccyx

Levator ani muscle

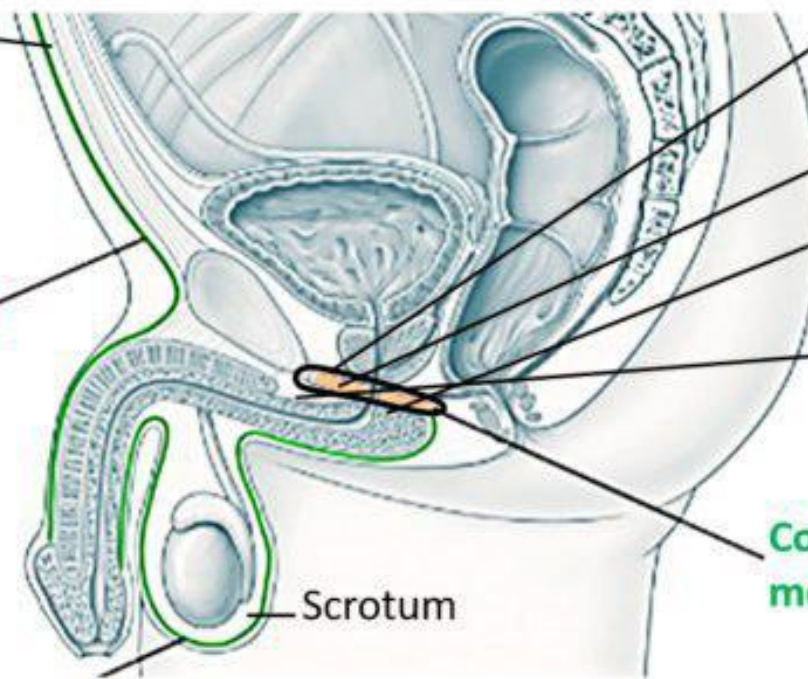
External anal sphincter muscle

# Deep Pouches

Anterior abdominal wall

Scarpa's fascia

Dartos muscle



Superior fascia of urogenital diaphragm

Deep perineal pouch

Perineal membrane

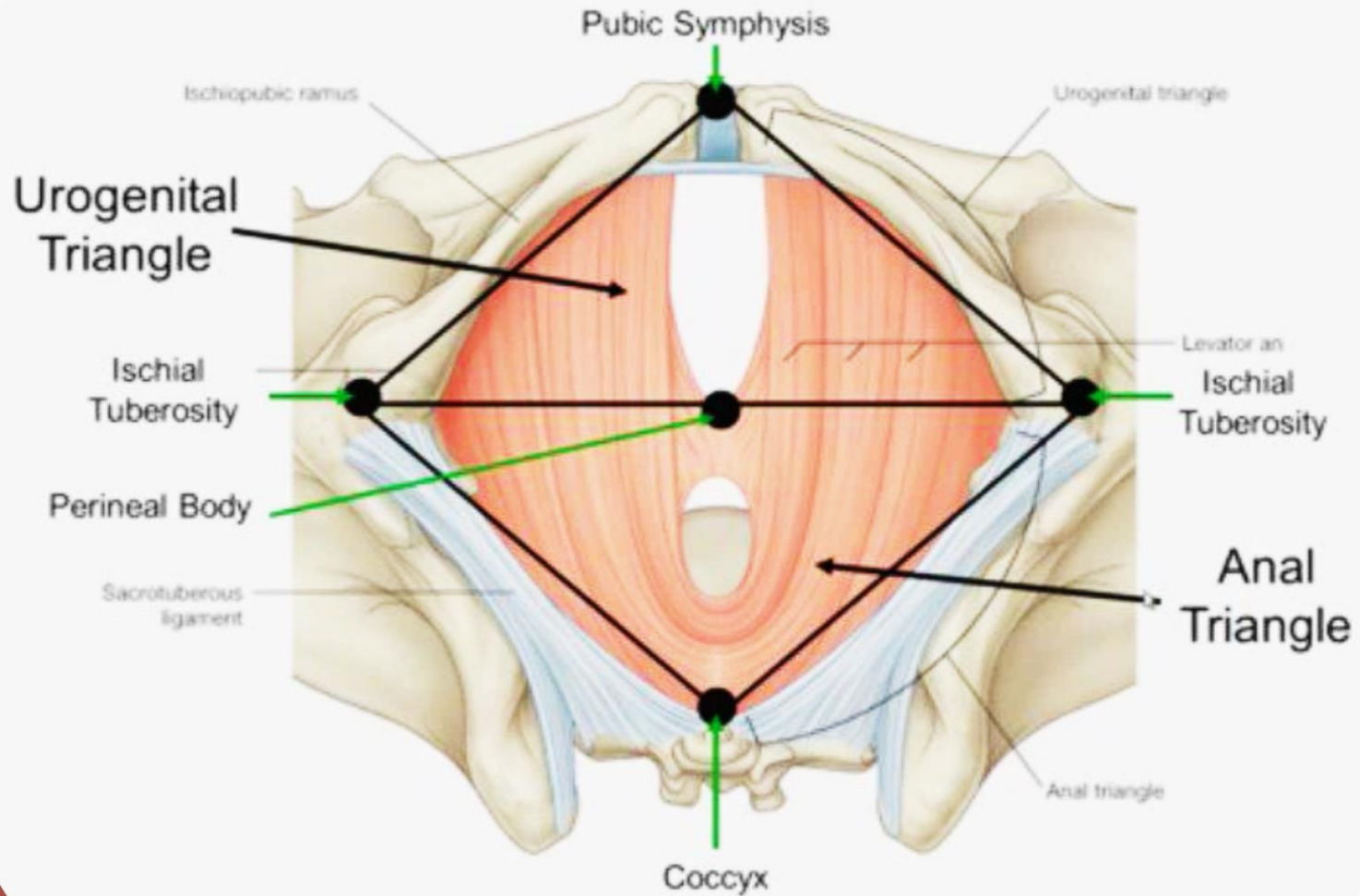
Superficial perineal pouch

Colles fascia fused with perineal membrane

Scrotum



# Perineum – Ischioanal Fossa

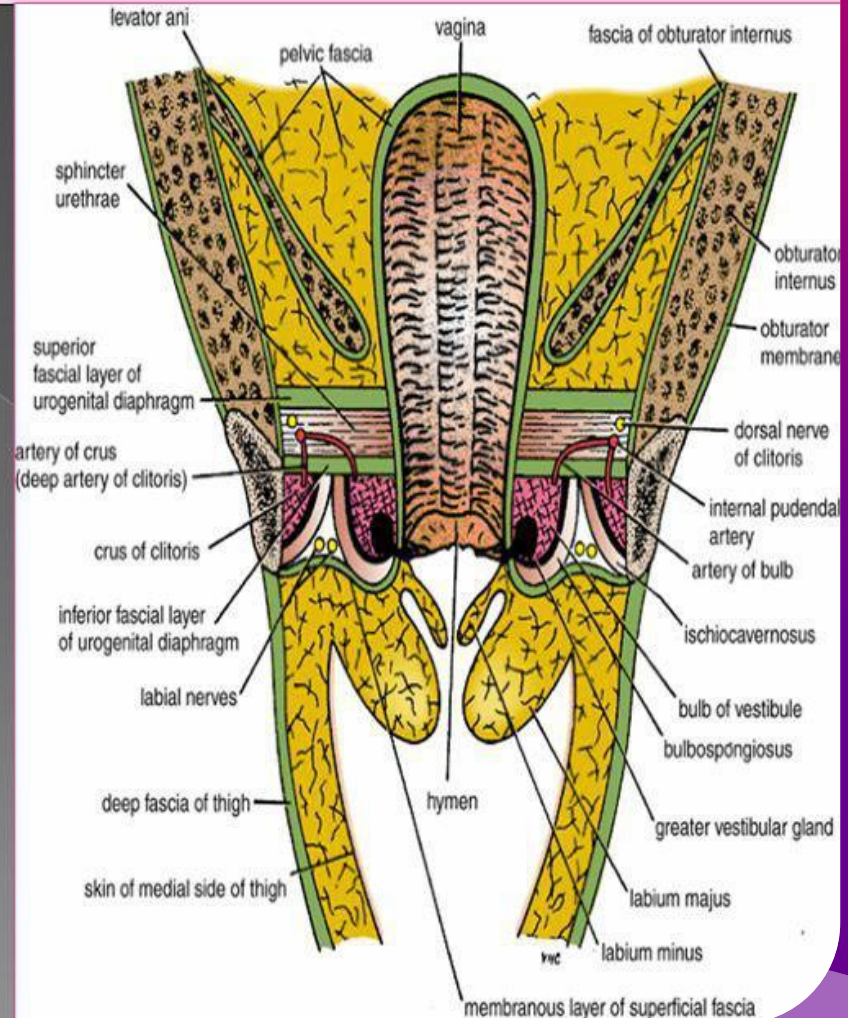


# Deep Perineal Pouch

- It is a completely closed space deep to the perineal membrane.

## BOUNDARIES:

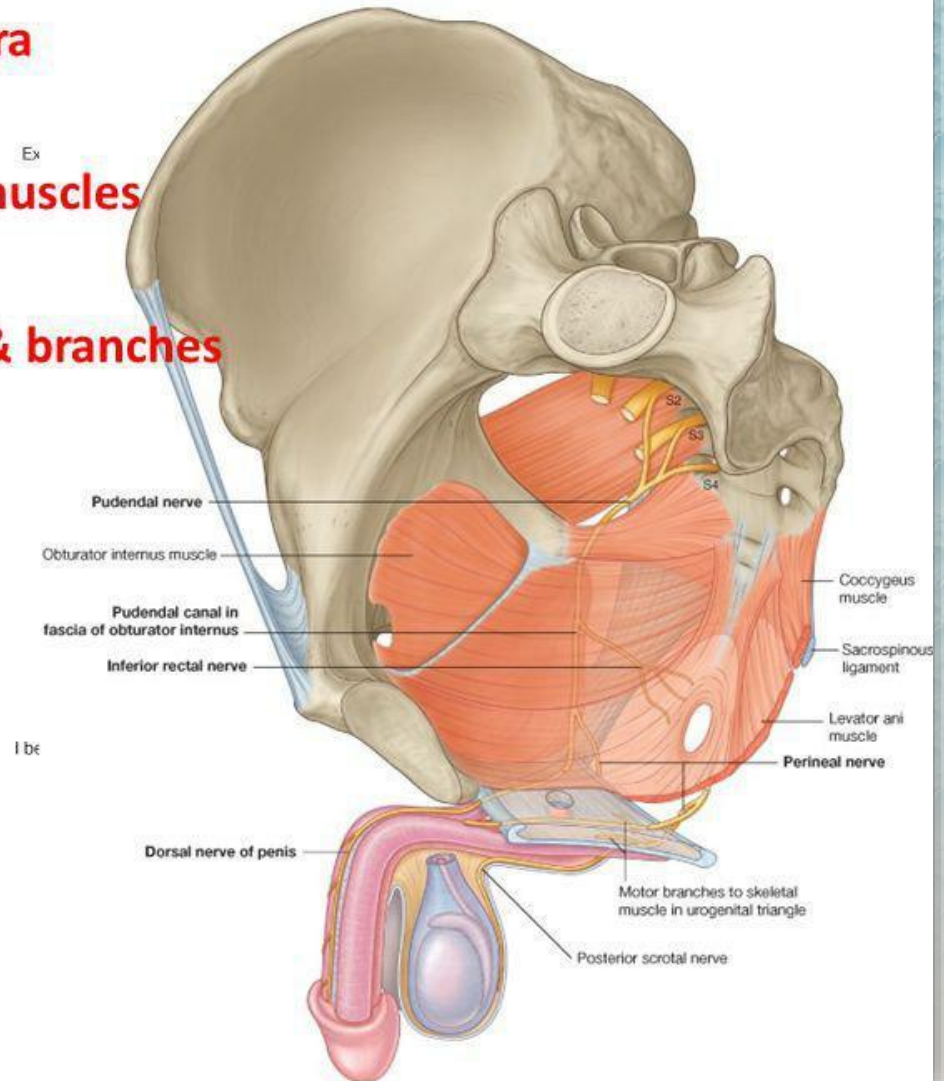
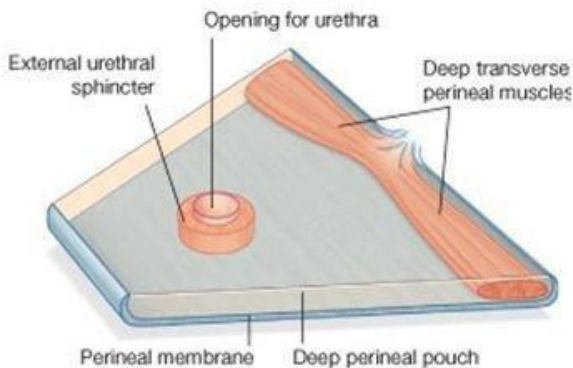
- Inferiorly:** Inferior fascia of the urogenital diaphragm (Perineal membrane)
- Superiorly:** Superior fascia of the urogenital diaphragm
- Laterally:** Inferior portion of obturator internus fascia



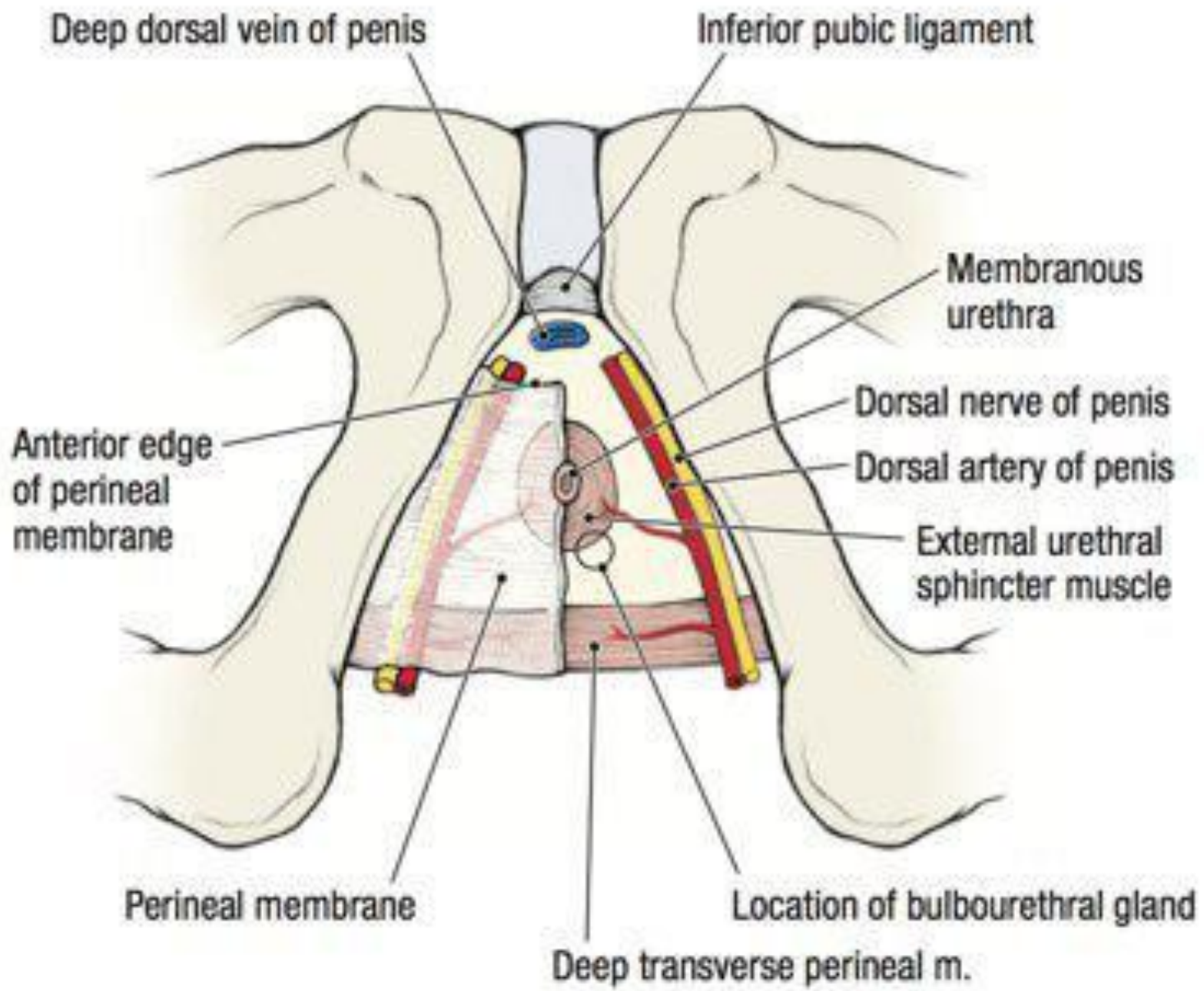


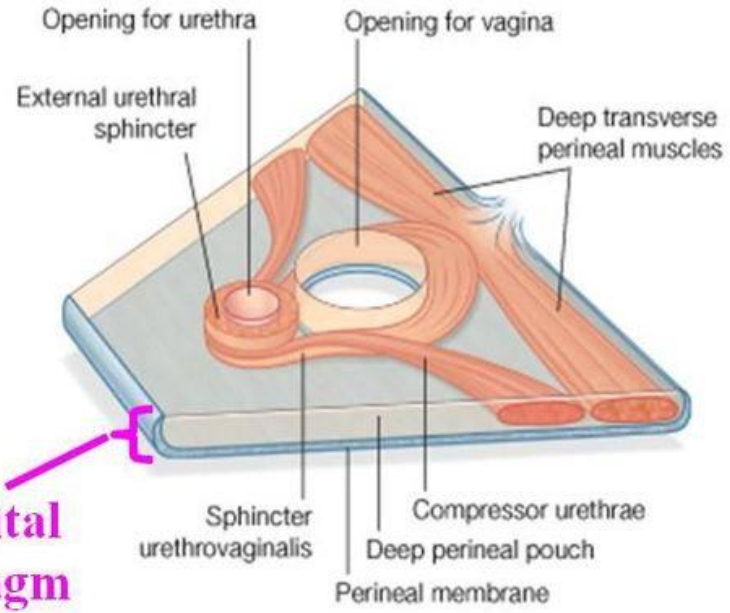
# Deep Perineal Pouch in Male

1. Membranous part of urethra
2. Sphincter urethrae
3. Deep transverse perineal muscles
4. Bulbourethral glands
5. Internal pudendal vessels & branches
6. Dorsal nerves of penis



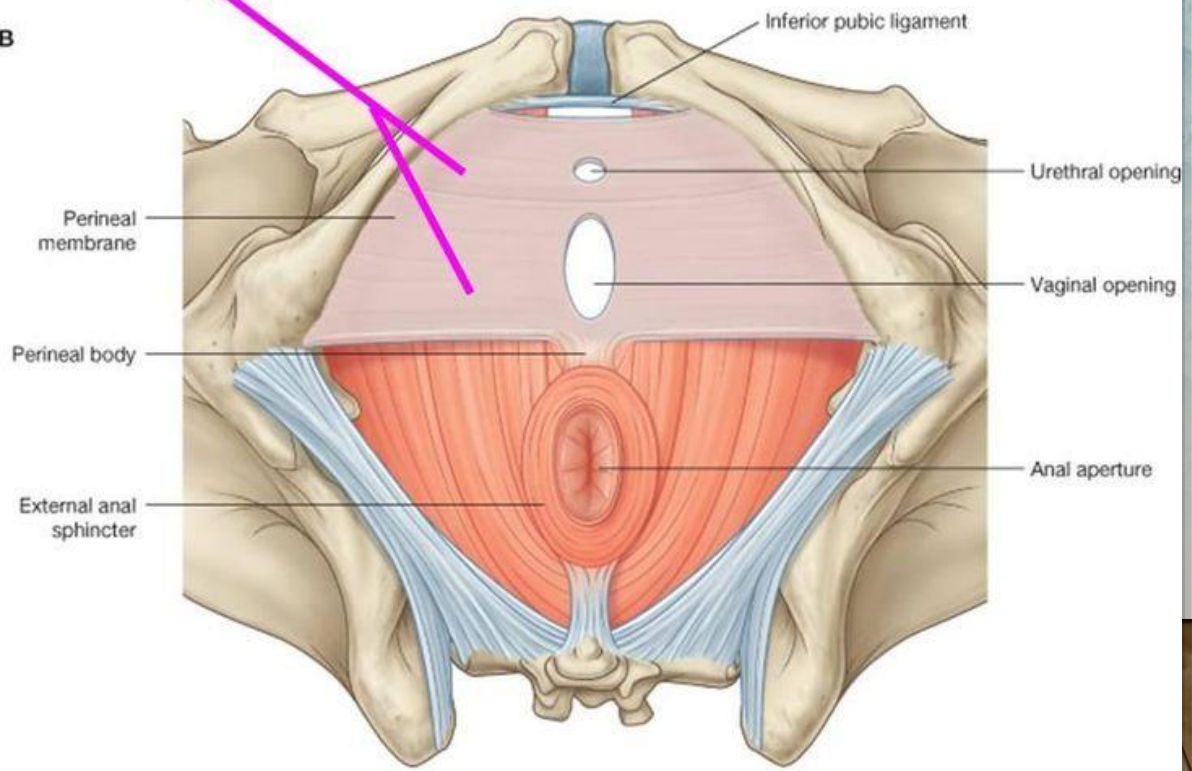






**Urogenital diaphragm**

**B**



*Anal triangle*

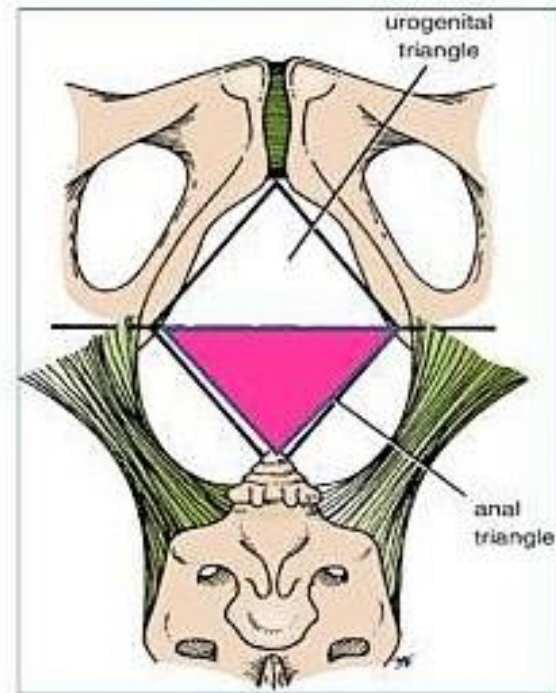


## **Boundaries:**

- **Anteriorly:** Transverse line passing through the 2 ischial tuberosities.
- **Posteriorly :** **coccyx.**
- **Laterally :** **ischial tuberosity & sacrotuberous lig.**

## **Contents:**

- **Lower part of Anal canal**
- **Ano-coccygeal body**
- **Ischiorectal fossa on each side**



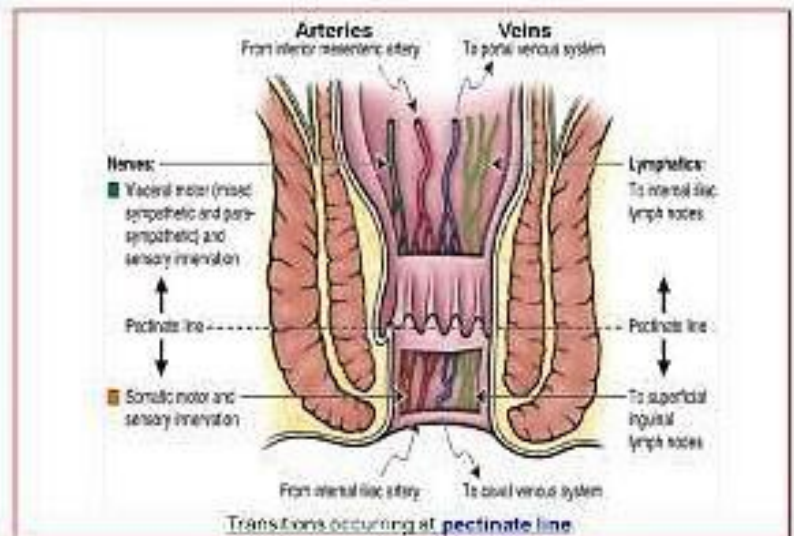
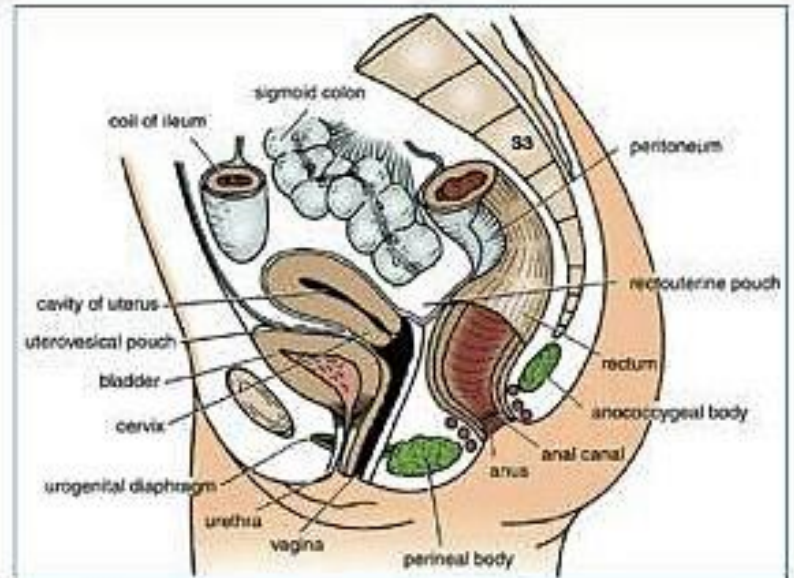
- It is about 1.5 in. long, descending from the **rectal ampulla** to the **anus**.

### **Relations** (In female):

- **Anteriorly:** Perineal body, urogenital diaphragm, and lower part of vagina
- **Posteriorly:** Anococcygeal body.
- **Laterally:** Ischiorectal fossae.

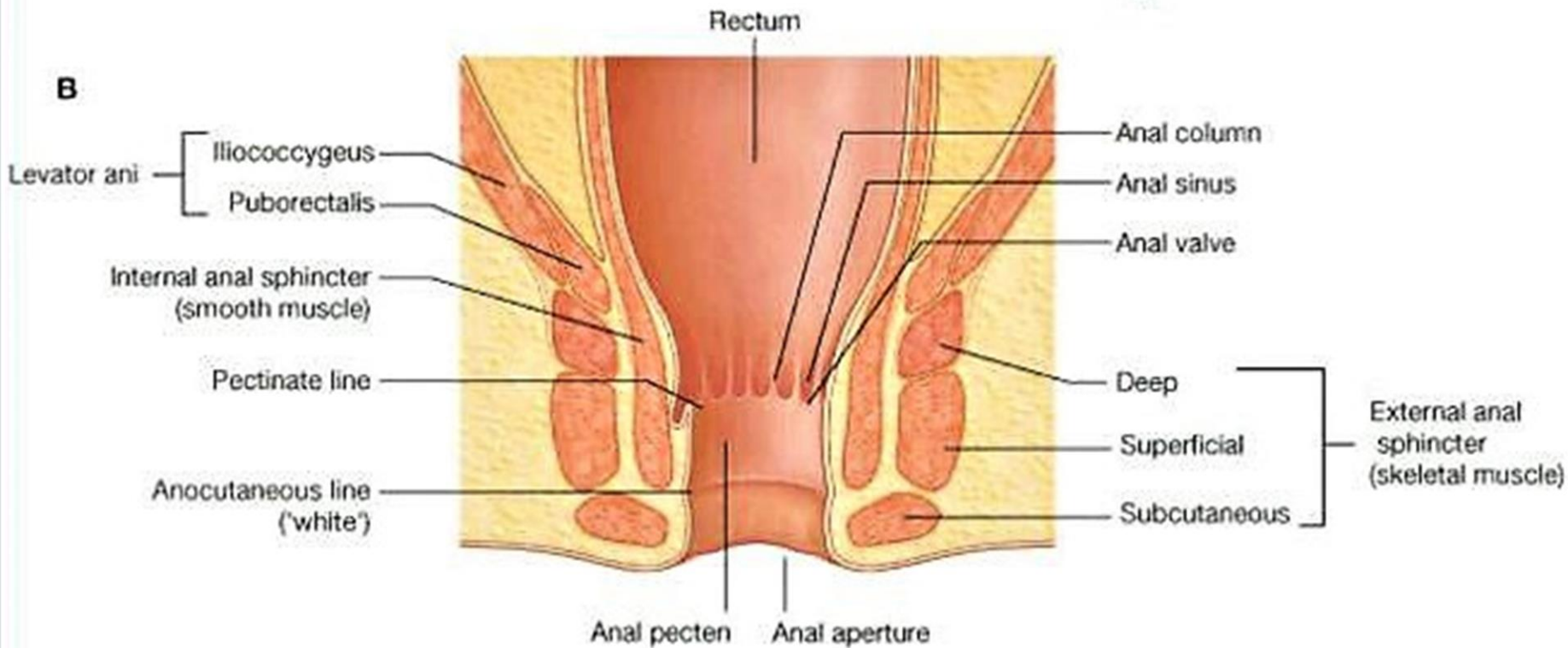
### **Division:** Divided into:

- **Upper half:** derived from hindgut (**endoderm**)
  - **Lower half:** derived from the proctodeum (**ectoderm**)
- The two parts have different blood supply, nerve supply and lymphatic drainage.





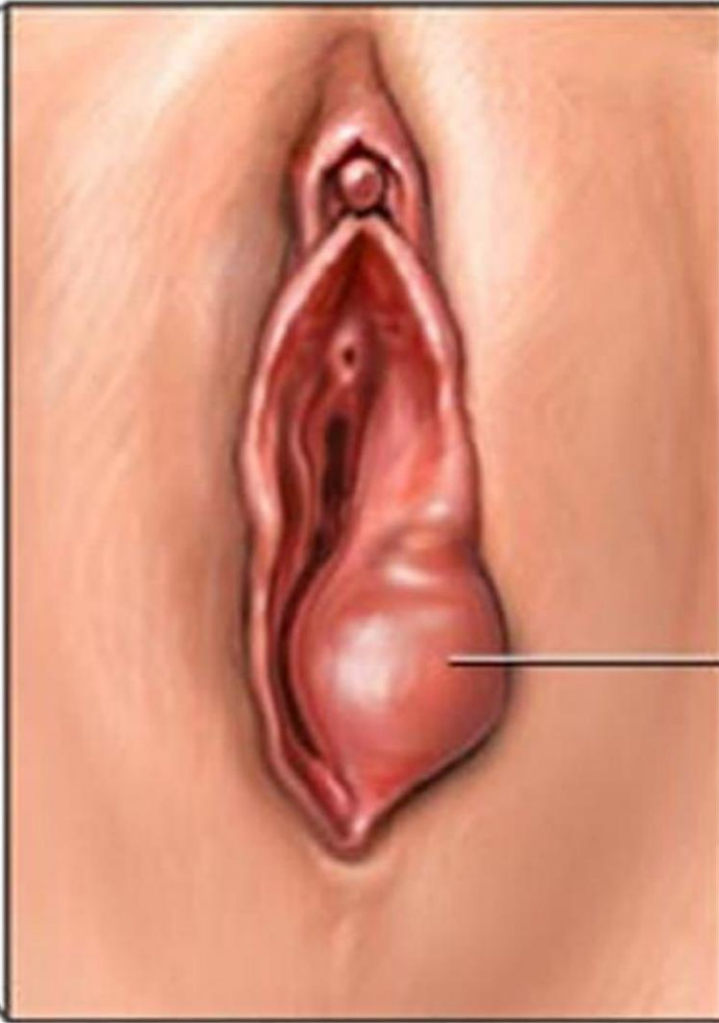
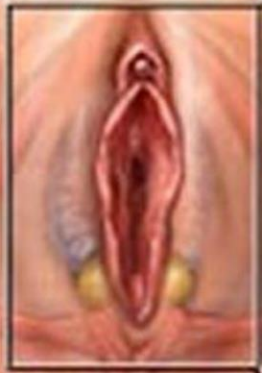# External/Internal Anal Sphincter





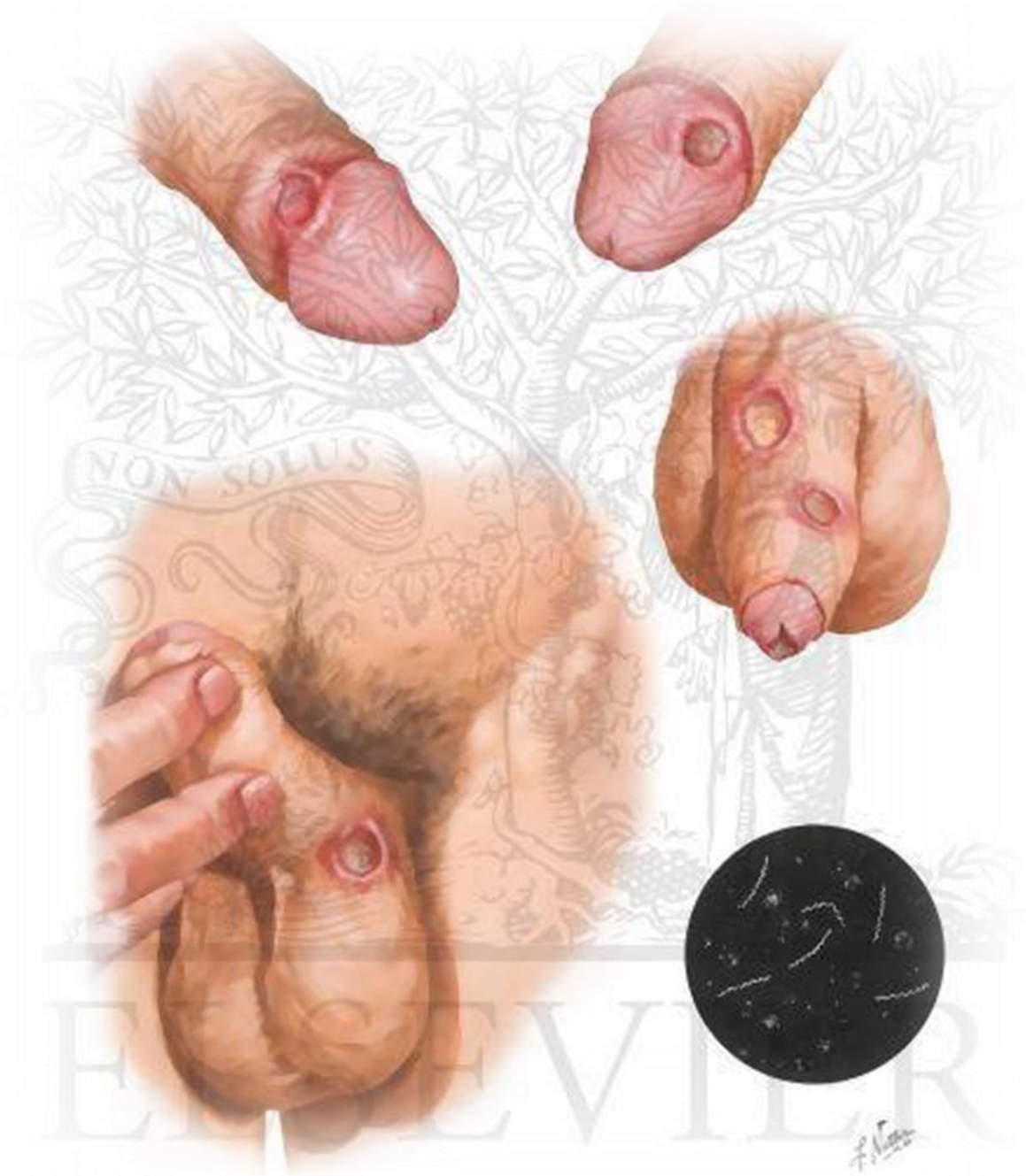
*Clinical  
correlations*

Normal  
anatomy

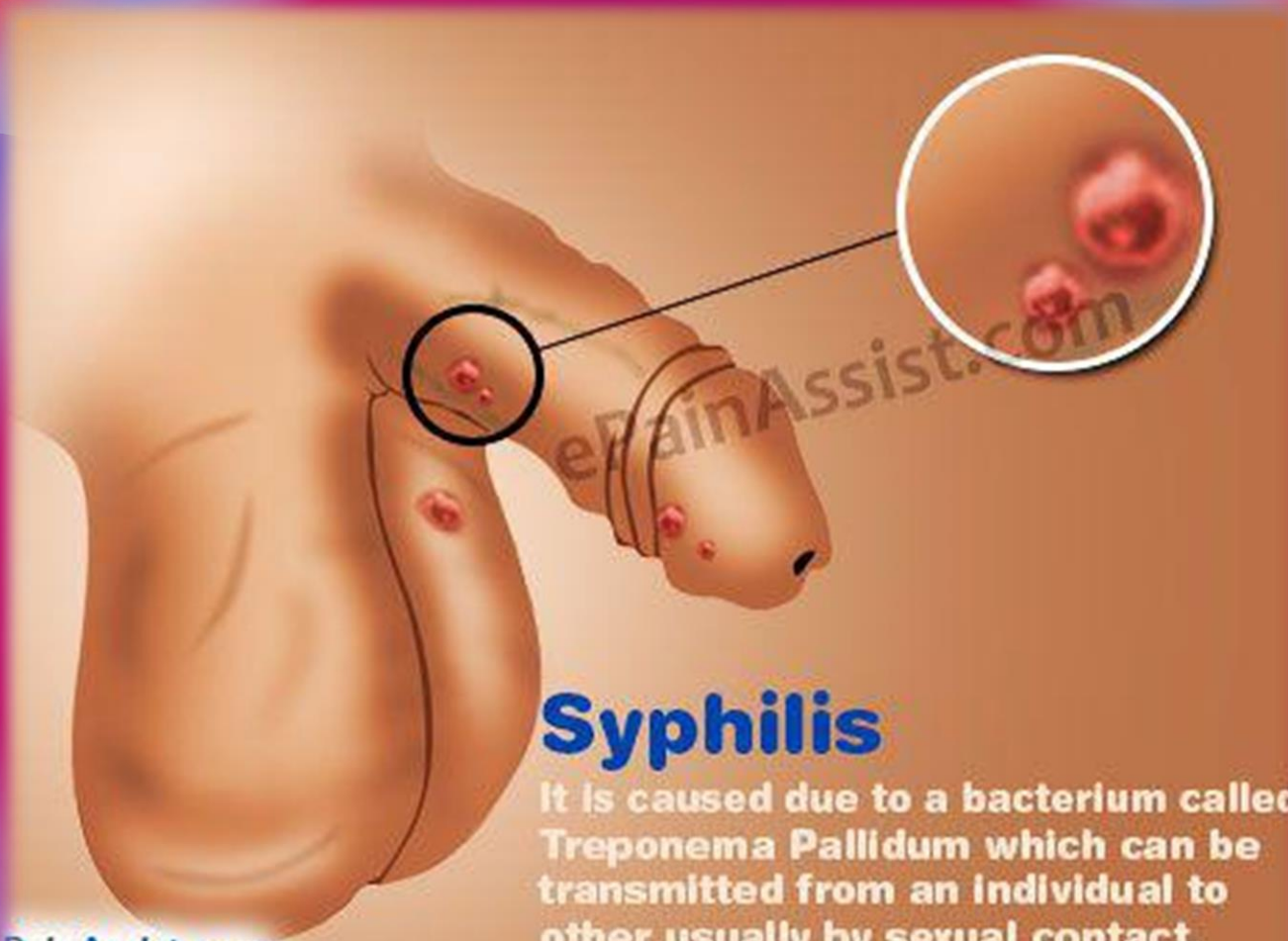

Bartholin  
gland cyst

*Bartholin gland cyst*







## Syphilis

It is caused due to a bacterium called *Treponema Pallidum* which can be transmitted from an individual to other usually by sexual contact.