



2016-2017

# An Introduction to Human Anatomy

Same S. Akkila



AL-MUSTANSIRIYAH UNIVERSITY – COLLEGE OF MEDICINE

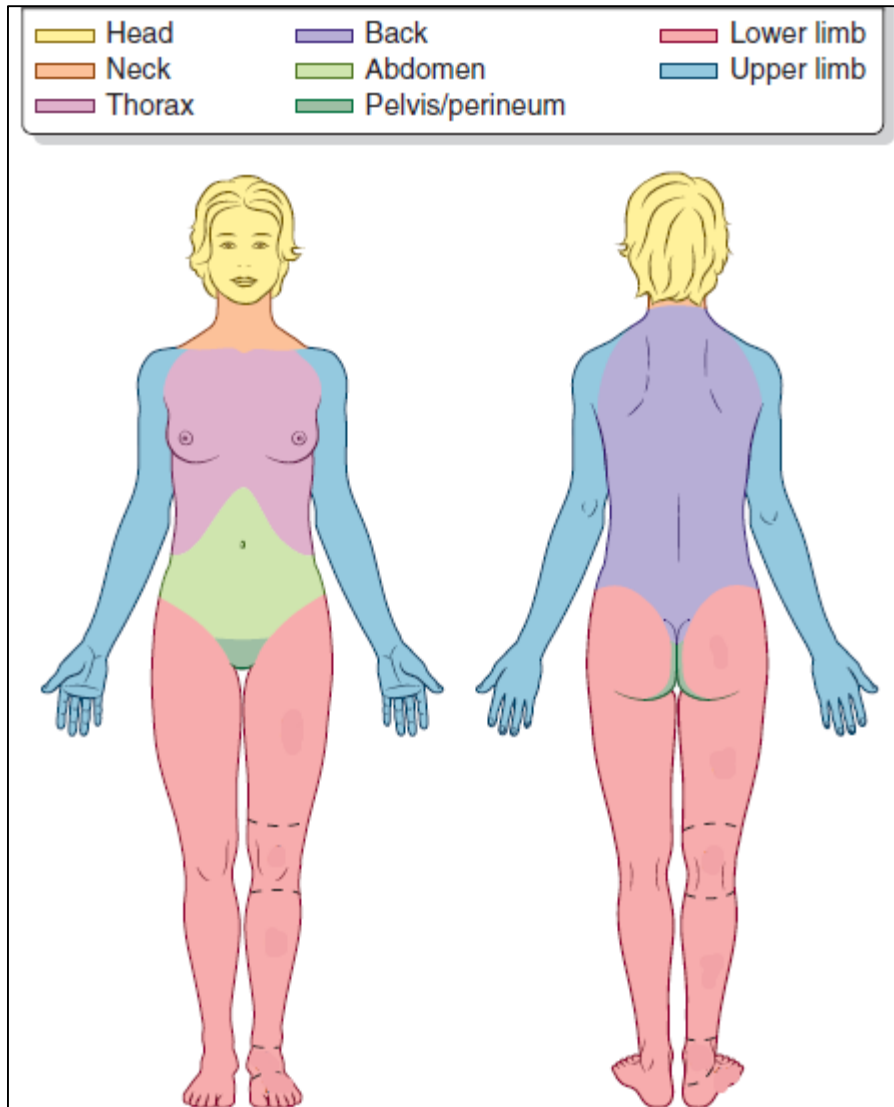
### What is Anatomy?

Anatomy is a descriptive science that studies the structure of living organisms. It includes two major branches: Gross anatomy and Microscopic anatomy.

**A. Gross Anatomy:** is the study of body structures visible to the naked eye. This can be approached in a Systemic Pattern where an entire system (like the respiratory system) is studied at different regions. It may also be studied in a Regional Pattern where the body is divided & studied in regions; each region containing parts of different systems. The study of anatomy in a comprehensive regional pattern is the most useful approach for medical students. For descriptive reasons, the body is divided into the following regions [**figure 1**]:

- The head & neck
- The trunk which consists of:
  1. From behind: The back
  2. From front: a- The thorax (chest)  
b-The abdomen: consisting of the abdomen proper and the pelvis.
- The upper limbs.
- The lower limbs.

## Introduction to Human Anatomy



**Figure 1: Regions of the human body**

Sub-branches of gross anatomy include Surface Anatomy which describes the external body features & relates them to internal structures; and Anatomic Imaging which involves the use of different imaging techniques *e.g.* X-ray to reveal inner structures without dissection.

**B. Microscopic Anatomy** involves the study of tissues (*Histology*) & cells (*Cytology*) with the aid of a microscope.

*Developmental anatomy traces structural changes that occur in the body throughout the life span. **Embryology**, a subdivision of developmental anatomy, concerns developmental changes that occur before birth.*

### Organization of the human body

Anatomy is always linked to *physiology*, the study of biological processes and functions in living organisms. The body is organized in such a way that the cell is the functional unit. Cells form tissues → tissues make up organs → and organs which perform complementary functions form body systems. Body systems may fall in one of three functional categories:

**1. Systems of covering, support and movement:**

- a. Integumentary system (skin)
- b. Musculoskeletal system (Bones, cartilage, Joints and the muscles that move them)

**2. Systems of integration and interaction:**

- a. The nervous system and special senses.
- b. The endocrine system.

**3. Systems of maintenance, defence and continuity:**

- a. The digestive system.
- b. The respiratory system.
- c. The cardiovascular system.
- d. The urinary system.
- e. The immune system.
- f. The reproductive system.

### How to Study Anatomy?

Studying anatomy involves lots of memorization. For instance, the human body contains 206 bones and over 600 muscles. Learning these structures requires time, effort, and good memorization skills. The following tips will help make learning and memorizing body structures easier:

**Know the language.** The most important thing to understand when studying anatomy is the terminology. Using standard anatomical terminology ensures that anatomists have a common method of communicating to avoid confusion when identifying structures.

**Use anatomy study aids.** Anatomy is almost impossible to understand without visual aids. The more pictures, diagrams, flash cards & atlases you study, the more you'll grasp the subject.

## The Language of Anatomy

### (Anatomical Terminology)

#### Terms of Position

The **anatomical position** is a fixed position of the body (cadaver) taken as if the body is standing (erect) looking forward with the upper limbs hanging by the side, the palms facing forwards & the feet kept side by side [figure.2]. The importance of applying this position is to *keep* the position of a certain body structure and its relation to other structures *constant* whether the body is in the anatomical position or any other positions.

#### The other positions are:

- The **prone** position: the body is lying on the face.
- The **supine** position: the body is lying on the back.
- The **lateral decubitus** position: the body is lying on one side.

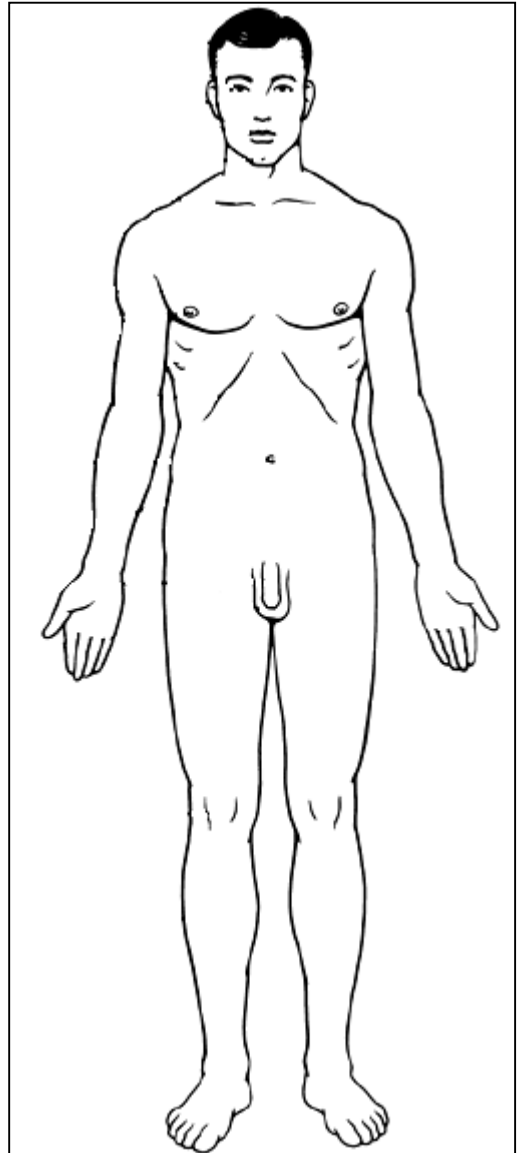


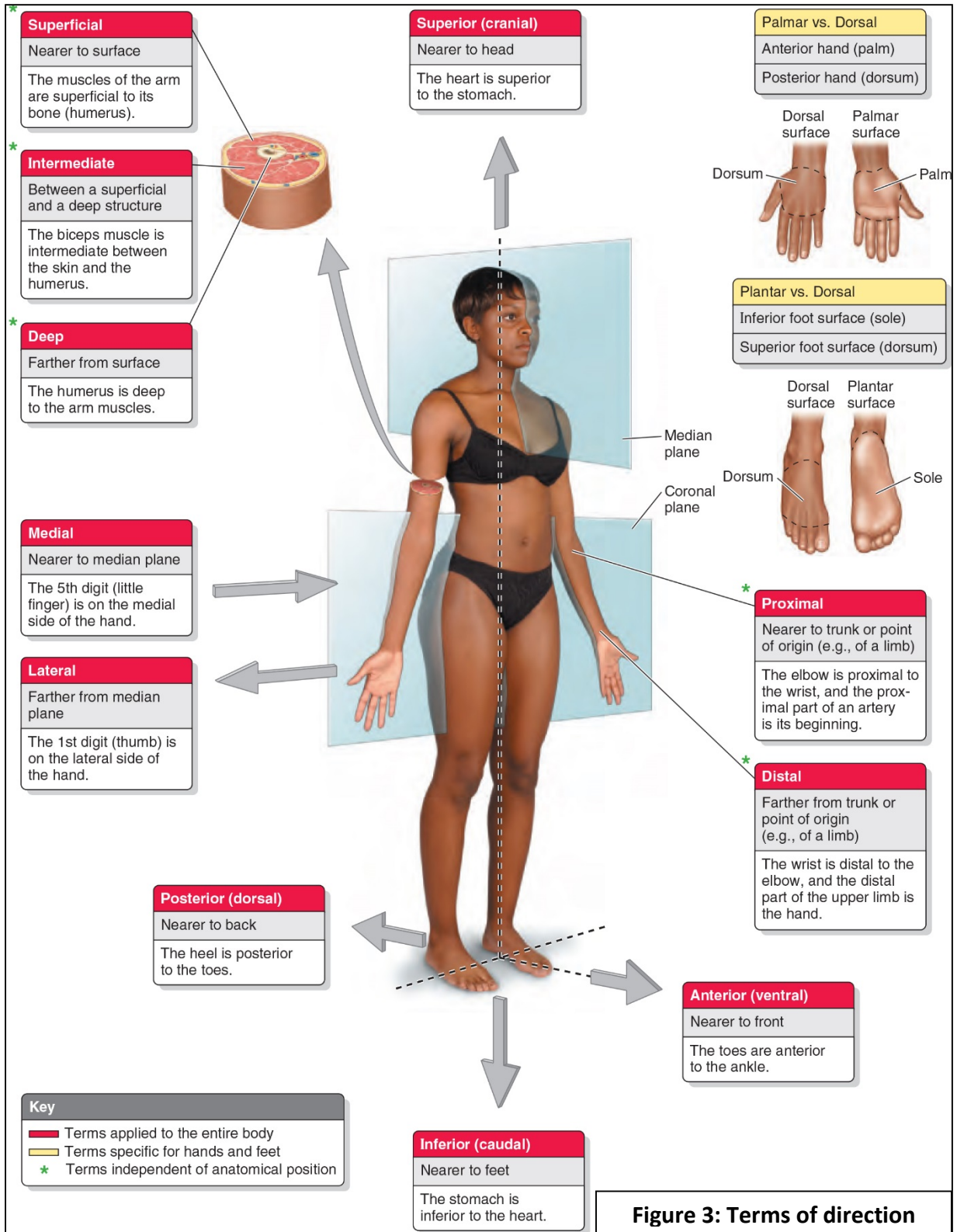
Figure 2: The anatomical position

### Terms of direction, relation & Body Planes

Anatomical directional terms (of relation) are used to describe the position of each body structure & relate it to the positions of other structures. Just like one can argue that the scalp is the uppermost part of the body and it lies above the chin which is below or beneath the nose, it is more appropriate to use scientific terms to avoid the confusion of using adverbs. These terms are:

- **Anterior** is nearer the front of the body. In the trunk it may be replaced by **ventral**. In the hand it is replaced by **palmar**.
- **Posterior** nearer the back. In the trunk & in the hand it is replaced by **dorsal**.
- **Superior** is nearer the head. In the trunk it is replaced by **cephalic or cranial**.
- **Inferior** is nearer the feet. In the trunk it is replaced by **caudal** and in the feet by **plantar**.
- **Proximal** is nearer the root of a structure (usually the root of a limb or vessel) **e.g.** the arm is proximal to the hand.
- **Distal** is away from the root of the structure **e.g.** the hand is distal to the arm.
- **Medial** is nearer the midline of the body. In the forearm it is replaced by **ulnar** and in the leg by **tibial**.
- **Lateral** is away from the midline. In the forearm it may be replaced by **radial** and in the leg by **fibular**.

# Introduction to Human Anatomy



**Figure 3: Terms of direction**



- **Superficial** is nearer the skin.
- **Deep** is away from the skin.
- **Middle (medius)** indicates a position between superior & inferior or anterior & posterior.
- **Intermediate** usually describes a position between medial & lateral
- **Internal & External** are used to describe structures nearer or away from the interior of the body; respectively **e.g.** muscles are internal to the skin but external to bones. The terms are usually used to describe the position of a structure in relation to the wall of an organ, cavity or region **e.g.** internal iliac artery (inside the pelvis).

*Just like the points of the compass, the above terms can be combined e.g. anteromedial, posteroinferior, superolateral.....etc.*

All of these terms, and the terms of movements that will follow, are arranged around the three (imaginary) axis planes that divide the body into its different parts & regions [figure.4]. These body planes are:

- A. The median sagittal plane: is the vertical plane that divides the body into *apparently* 2 equal halves, right & left. (*Apparently*: because some inner structures are not present on both sides of the body). The anterior edge of the plane is the *anterior median line* while its posterior edge is the *posterior median line*. The paramedian (parasagittal) planes are planes running parallel to the median plane

## Introduction to Human Anatomy

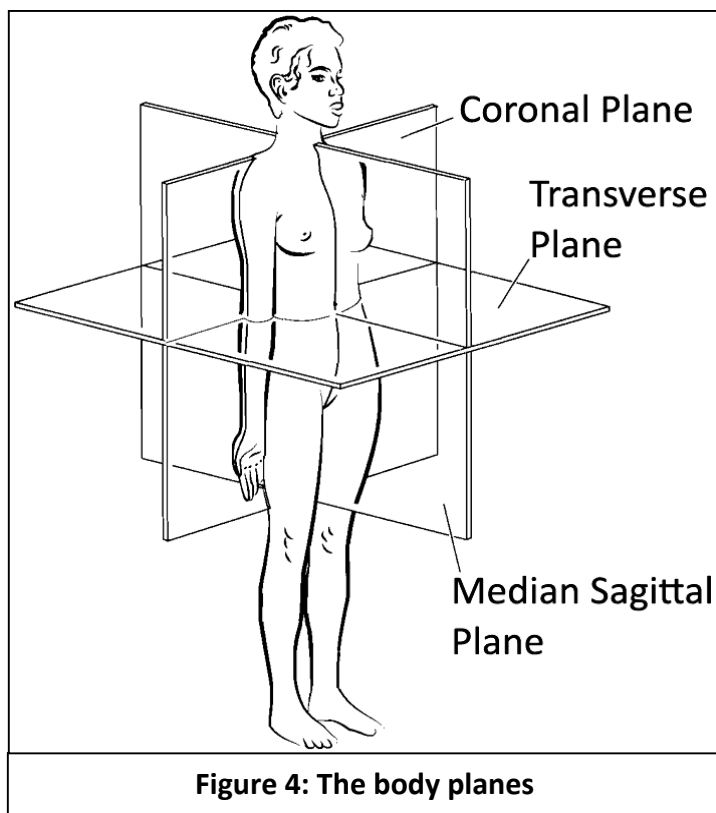
---

(to the right & to the left). Medial, lateral & intermediate are arranged around this plane.

B. The coronal (Frontal) plane: is a vertical plane lying at right angle to the median plane dividing the body into front & back parts. Anterior & posterior are arranged around this plane.

C. The transverse (Horizontal) plane: lies at right angles to both the median & coronal planes and divides the body into upper & lower parts. Superior & inferior are arranged around this plane.

***An oblique plane may be taken through any region at an oblique angle to one or more of the above planes.***



### Terms of Movements

Movements occur around joints and are referred to them **e.g.** Flexion of the shoulder. The following are the anatomical terms of movements:

- **Flexion & Extension:** to flex a joint is to fold it (i.e. decrease the angle) and to extend a joint is to unfold it (i.e. increase the angle). **In the trunk** and neck lateral flexion refers to bending the neck or trunk to the right or left.
  - **Abduction and adduction:** to abduct is to move away from the median plane (increasing the angle) and to adduct is to move towards the median plane (decreasing the angle).
  - **Rotation:** this movement occurs around a longitudinal axis either towards the midline (Medial or Internal Rotation) or away from the midline (Lateral or External Rotation). **In the forearm** medial rotation is substituted by Pronation and lateral rotation by Supination.
  - **Circumduction:** is a conical rotatory movement creating an arc around a longitudinal axis and represents the combination of flexion, abduction, extension & adduction.
- ❖ **Special movements At the wrist & hand:**
- **In the wrist** the term abduction may be replaced by radial deviation and adduction by ulnar deviation.
  - **In the hand**, the axis of the middle finger acts as the midline and to abduct the fingers is to spread them apart from the middle finger. Abduction of the thumb is moving it away from the fingers & palm so

that it makes right angles with the index (pointing finger) and the palm. To adduct the fingers is to bring them together to the line of the middle finger and to bring the thumb beside the index.

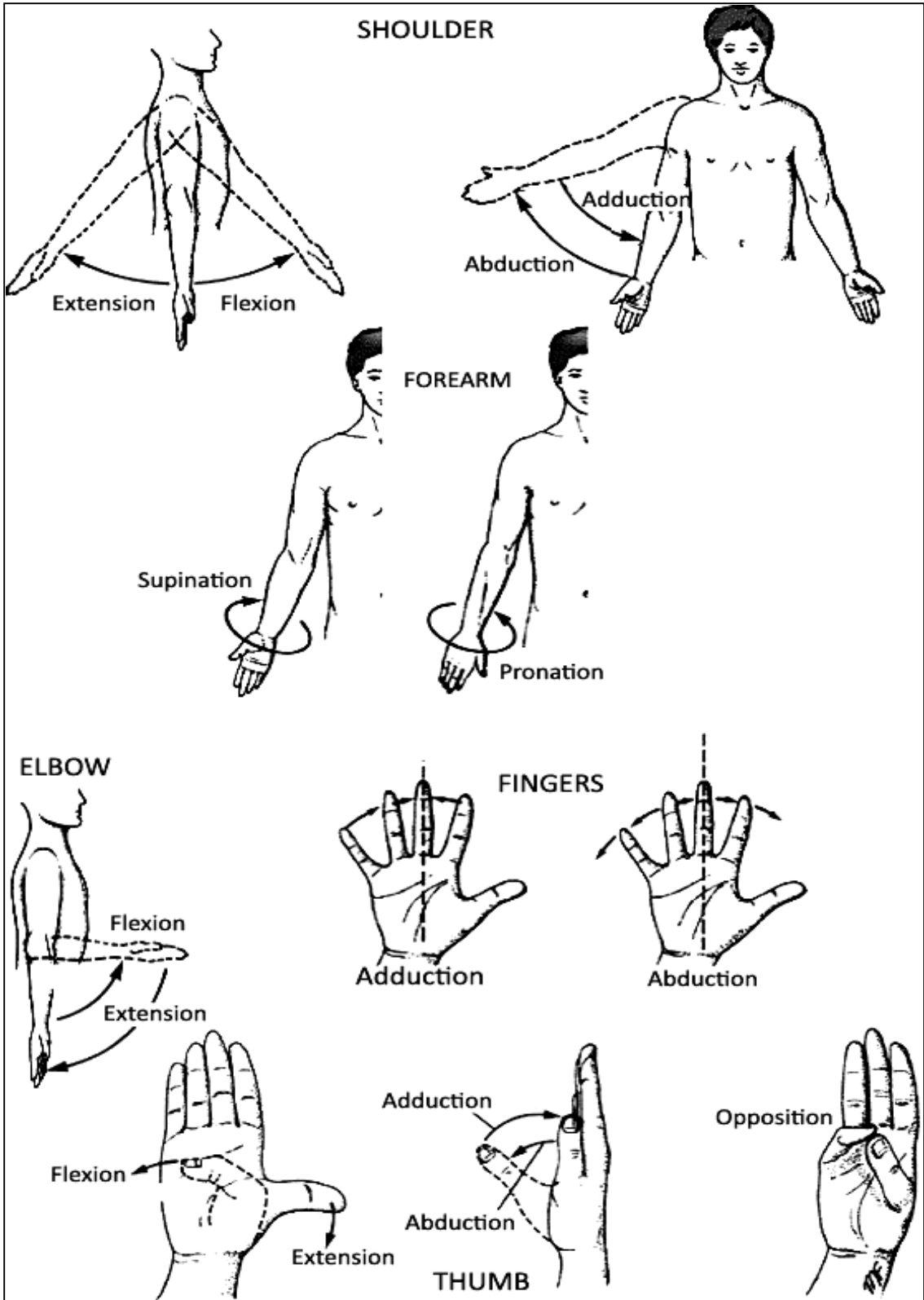
- **In the hand**, to **flex** the **fingers** is to fold them in the palm and to **flex** the **thumb** is to bring it on the palm below the other fingers. To **extend** the **thumb** is to move it away from the palm making a right angle with the index finger but parallel to the palm.
- **Opposition**: is moving the thumb so its tip touches the tips of other fingers. **Reposition** is moving the thumb from opposition back to the neutral position.

### ❖ **Special movements at the ankle:**

- **Flexion** is replaced by **dorsiflexion** and refers to upward movement of the foot while **extension** is replaced by **plantar flexion** and refers to downward movement of the foot (standing on the toes).
- **Adduction** is replaced by **inversion** while **abduction** is replaced by **eversion**. **In the foot** the line of adduction and abduction of the toes is the second toe (the one next to the big toe).

### ❖ **Other movements:**

- **Elevation** (Lifting up), **depression** (Pulling down), **Protraction or Protrusion** (sliding forward) and **Retraction or Retrusion** (sliding backward) occur at the scapula and jaw, respectively.



12  
Figure 5: Some movements of the upper limb

### Basic Anatomical Structures

The basic anatomical structures are structures that are met during dissection in almost every region of the body.

#### The Skin

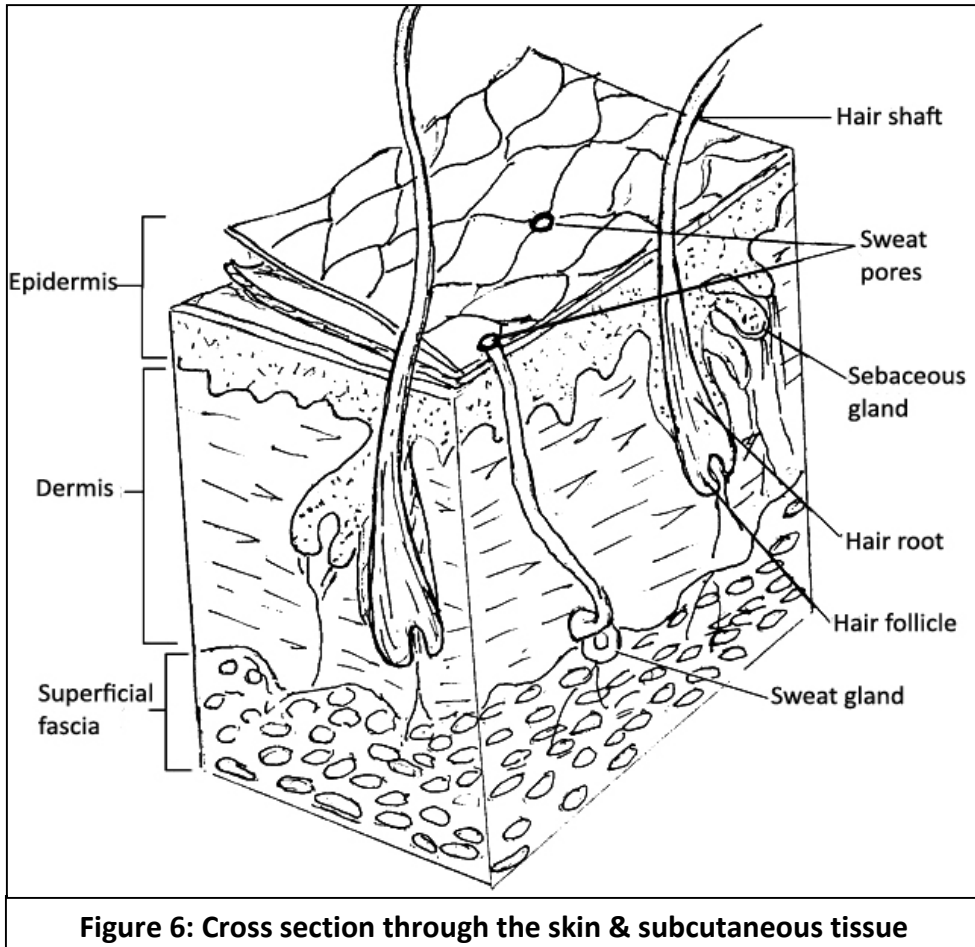
The skin is composed of two layers: the outer epidermis and the inner dermis [figure.6].

- **The epidermis** is an avascular layer (lacking blood & lymphatic vessels) which differs in its thickness from one region of the body to another. At areas where it is subjected to pressure and friction, it becomes thick to withstand the wear and tear *e.g.* palms, soles, back. Elsewhere it tends to be thinner (especially in the lips & eyelids).
- **The dermis** is the thicker inner vascular layer that contains the blood and lymphatic vessels and nerves that supply the skin. It consists of dense fibrous tissue rich with collagen fibers that are arranged in parallel lines known as the tension or cleavage lines (of Langer's). It is important to know the arrangement of these lines in making surgical incisions.
- **The epidermal appendages:** are structures derived from the epidermis but are invaginated into the dermis. They include:
  1. Nails.
  2. Hairs.

## Introduction to Human Anatomy

---

3. Arrector pili muscles (which cause hair erection in response to cold or fear; giving the skin a goose-flesh appearance).
4. Sebaceous glands are related to hairs and secrete an oily material (sebum) that moisturizes hair.
5. Sweat glands secrete excess water & electrolytes from the body.



### Fascia

Fascia is a connective tissue that surrounds the body and all its inner structures & is divided into 2 types:

#### 1) Superficial fascia

This is also called the subcutaneous tissue or hypodermis because it lies immediately deep to the skin but it is NOT part of the skin. It is composed of loose areolar connective tissue rich with fat. It functions to store fat, insulate the body temperature & connect the skin above to the deeper structures below. In the male the superficial fascial fat tends to accumulate at certain areas like the abdomen and thighs but in females it is more evenly distributed.

#### 2) Deep fascia

This is a membranous connective tissue that surrounds and invests inner structures and takes its name according to the structure it surrounds. For example: deep fascia which separates muscles from each other into compartments is the **septum** (pl. septa), at joints deep fascia thickens and extends from one articulating bone to another and is called **ligament**.



### Muscles

There are three types of muscles: skeletal, smooth and cardiac.

#### • Skeletal muscles

These are voluntary striated muscles that have at least one attachment to the skeleton (whether bone or cartilage). Skeletal muscles are made up of bundles of striated fibers. The power of a skeletal muscle depends on the number & diameter of its bundle fibers.

A skeletal muscle is composed of the following parts [figure.7]:

- **Origin:** is the part that moves the least (almost fixed).
- **Insertion:** the part which moves the most (mobile).
- **Belly:** the fleshy part between the origin & insertion.
- **Tendon:** the fibrous band which attaches the muscle to the bone. The tendons of some muscles form a flat sheet called an **aponeurosis** that anchor the muscle to the skeleton.
- **Neurovascular bundle:** is composed of the nerve & vessels that supply the muscle. The nerve reaches the muscle at the neuromuscular junction.

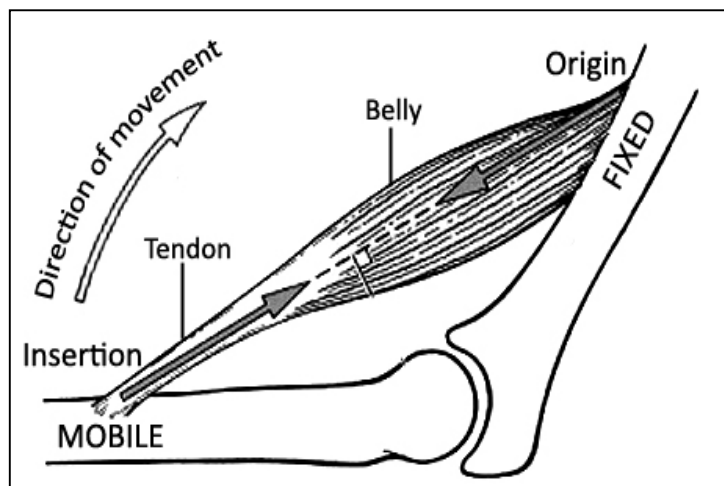


Figure 7: Parts of a skeletal muscle

## Introduction to Human Anatomy

---

In anatomical diagrams, the part of the bone which gives rise to the muscle origin is always colored in red, while the part to which the muscle is inserted is always colored in blue.

Skeletal muscles are named according to different categories. They may be named according to:

- Shape: *e.g.* Teres (round), Deltoid (triangular).
- Size: *e.g.* Minor (small), Major (Large), Longus (Long).
- Position: *e.g.* Brachii (in the arm).
- Depth: *e.g.* Profundus (Deep), Superficialis (Superficial).
- Action: *e.g.* Extensor (Performs extension).
- Nmber of heads: *e.g.* Biceps (two heads).
- Number of bellies: *e.g.* Digastric (two bellies).
- Points of attachments: *e.g.* Brachioradialis.

Many muscles are named in combinations, *e.g.* Abductor Policis Longus (The long abductor of the thumb).

- **Smooth muscles**

These are involuntary non-striated muscles related to internal structures *e.g.* arteries, gut, urinary bladder...etc. & are controlled by autonomic nerves &/or hormones. They're arranged in either of two forms:

- *Circular and longitudinal* fibers producing a combination of constrictive & propulsive action. This action produces *pulsation* in arteries and *peristalsis* in the gut & urinary tubes. Circular smooth

muscles may be thickened at the entrance or exit parts of some organs and form **sphincters** that control the emptying of these organs.

- *Interlacing fibers* in the wall of a hollow viscus **e.g.** uterus, urinary bladder; producing an *evacuatory* function.
- **The cardiac muscle**

This is the involuntary striated muscle of the heart that contracts on its own but under autonomic nervous control.

### Blood Vessels

#### 1. Arteries:

An artery is a blood vessel that carries blood (away) from the heart to all body tissues. Arteries are mostly deep vessels. According to their diameter, arteries may be Large, Medium-sized or small, most of which have rich smooth muscles in their walls making them capable of constriction and dilatation (i.e. *Pulsation*). When the small arteries reach a diameter of <0.1 mm, they are called *arterioles*. All arteries *branch* and re-branch as they run in the body. Eventually, arterioles break up into a *capillary network*. Therefore, each major artery has a point of beginning, a point of ending, a course & a number of branches it gives along its course.

Arteries usually communicate freely with each other through connecting channels called *anastomosis*. Anastomosis provides blood supply for tissues from an alternative path if one or more of the supplying arteries are blocked. This supportive circulation is called *collateral circulation*. Arteries which do not anastomose with each other are called *anatomical*

*end arteries*. Arteries which anastomose with each other but whose connections are too weak to provide a sufficient collateral circulation; are called *functional end arteries*. **In anatomical illustrations, arteries are always colored in red.**

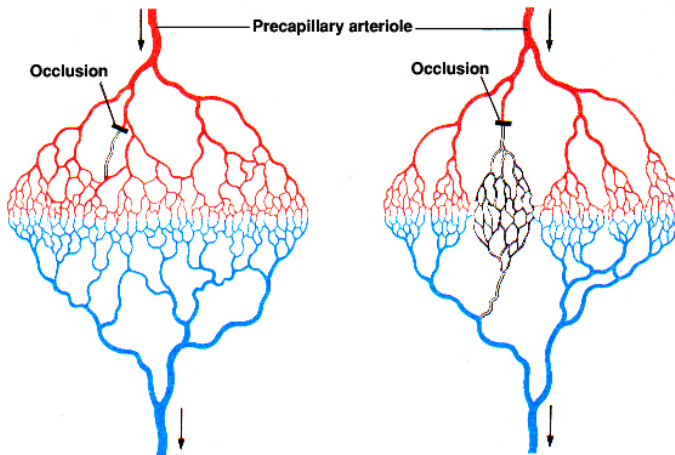
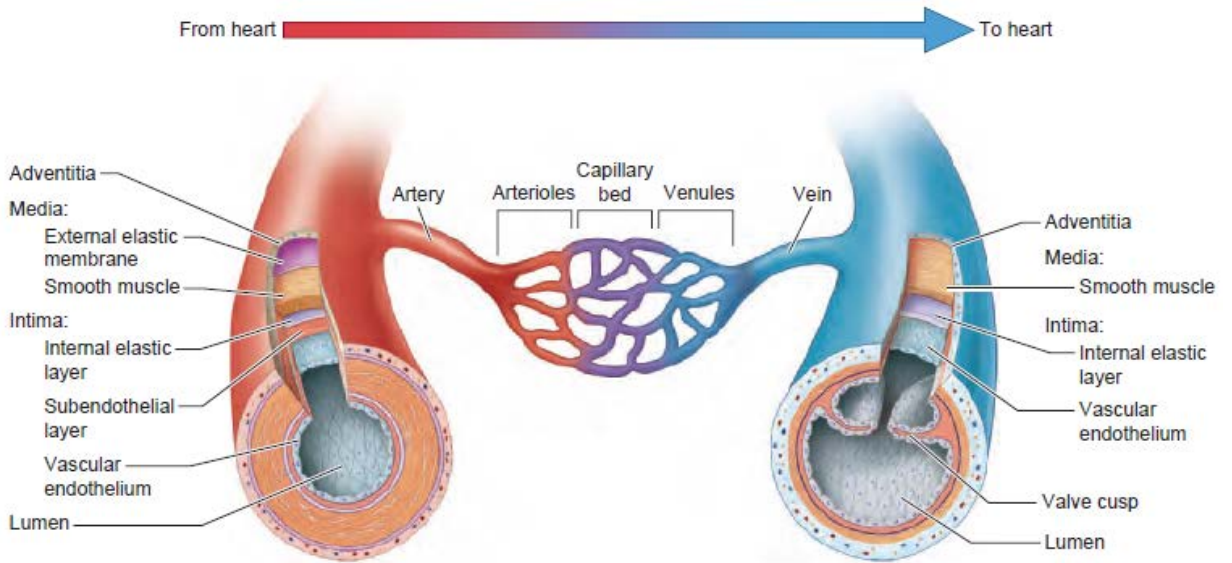
### 2. Capillaries:

Capillaries are microscopical vessels having a diameter of 7-9  $\mu\text{m}$ . They arise from the break up of *pre-capillary arterioles* into capillary network. They're the site of exchange of nutrients, gases and waste products between blood and tissues. After blood has delivered  $\text{O}_2$  & nutrients to the tissues and taken up  $\text{CO}_2$  & other waste products, it is drained from the capillaries by *post-capillary venules*.

### 3. Veins:

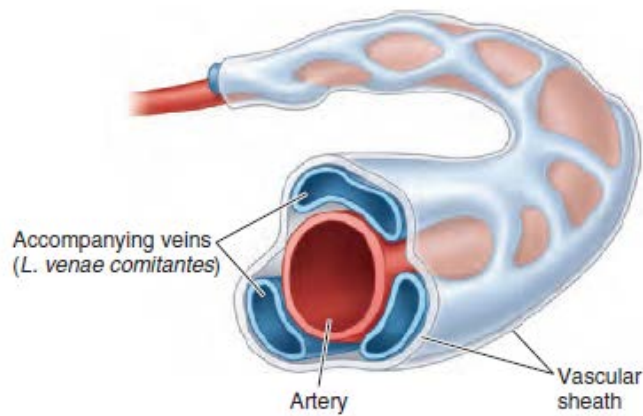
A vein is a blood vessel that drains blood from the tissues towards or back to the heart. The venous side of the circulation starts at the *post-capillary venules* (<0.1 mm) which *join* other venules and receive *tributaries* along the way to form small, medium-sized and finally large veins. Therefore veins begin where arteries end, and end where arteries begin. Veins do not have much smooth muscle in their walls and therefore cannot pulsate. Below the level of the heart this could result in retrograde flow of blood. To prevent this veins are provided with *valves*. Sometimes, a given artery may have more than one accompanying vein. These veins are known as *venae comitantes*. Like arteries, veins communicate with each other through *venous plexuses*. Veins may be *deep* (accompanying the corresponding arteries) or *superficial*. Blood from superficial veins eventually empty their blood into deep veins. **In anatomical illustrations, veins are always colored in blue.**

# Introduction to Human Anatomy



**A- Capillary bed supplied by anastomosing arteries**

**B- Capillary bed supplied by end arteries**



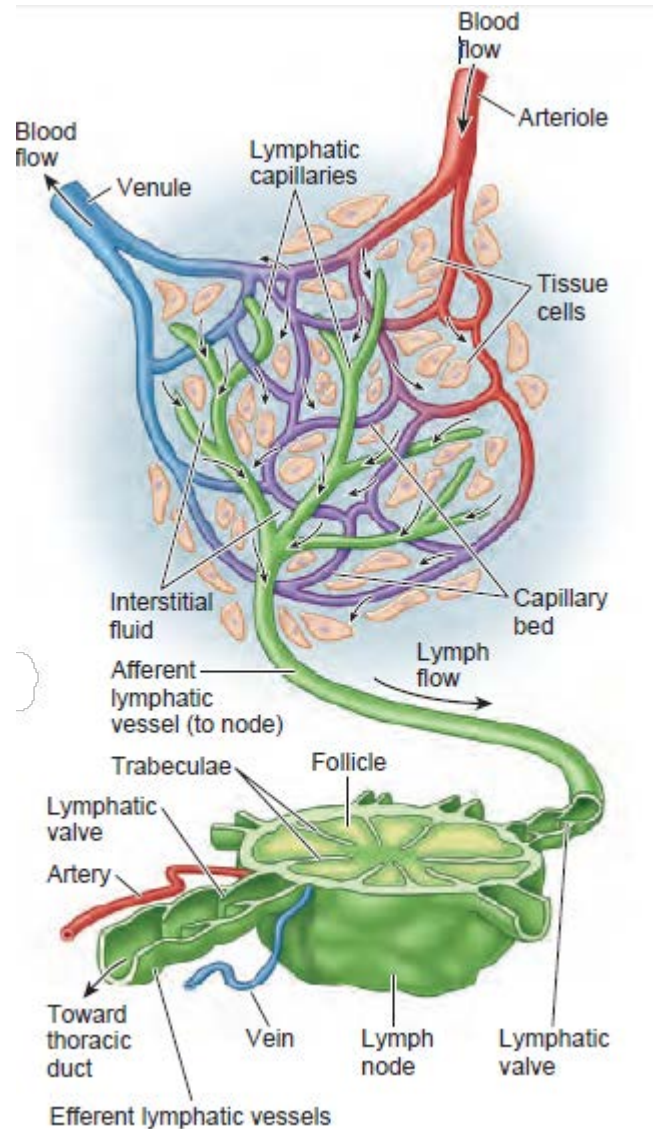
### Lymph and lymph vessels

Plasma is filtered from blood capillaries to the spaces between cells (*interstitial space*) where it becomes the *interstitial fluid*. This fluid exchanges electrolytes, waste products & fats with the surrounding cells. It is then drained into lymphatic vessels as a clear fluid called the *lymph*.

Lymph has to be drained eventually back into the venous side of the circulation.

While in the lymphatic vessels, lymph has to pass through at least one *lymph node* which acts as a check-point that clears the lymph from any foreign bodies or microorganisms before it is returned to the venous circulation.

The lymph vessel which carries lymph towards the lymph node is called an *afferent lymphatic*. That which carries lymph away from the lymph node is called *efferent lymphatic*.



Lymph nodes are scattered throughout the body but they tend to aggregate at the roots of the limbs (*e.g.* axilla), neck and around major blood vessels & internal viscera.

### **Bone**

Bone is composed of connective tissue cells embedded in a calcium phosphate matrix. The connective tissue cells and fibers give bone its resilience while the calcium phosphate matrix gives it its strength & toughness. The deep fascia that surrounds bone is called periosteum. Bone surface is shaped by attachments of muscles & ligaments and surrounding vessels & nerves. It may be elevated, depressed, grooved, perforated or notched. the resulting bone markings are given different terms that are best learned gradually during the regional study of anatomy.

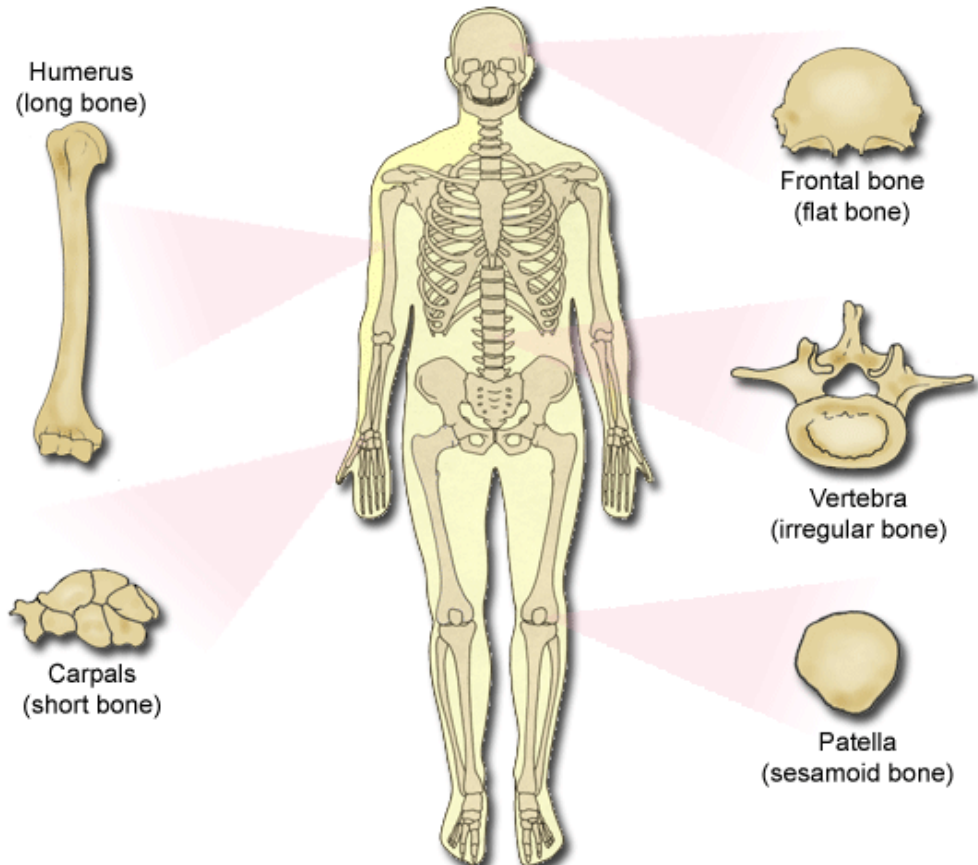
#### ○ ***Histologically, bones are of two types:***

- **Compact (Haversian) bone** is composed of closely adherent dense plates of bone cells with little intervening spaces. In the shafts of long bones, a large *medullary cavity* exists in compact bone containing the *Yellow Bone Marrow*.
- **Spongy (cancellous) bone** is composed of branching meshes of bone cells with many spaces in between (like a sponge). The spaces of spongy bone are filled with the *Red Bone marrow* which is responsible for blood cell formation.

o **Anatomically, bones are classified into 4 types according to their gross appearance:**

- 1. Long bones (e.g. Humerus):** consist of two ends called the *epiphyses* of cancellous bone with a compact bone covering, and a middle tubular *shaft* called the *diaphysis* of compact bone only. The area between the epiphysis and the diaphysis is called the *metaphysis*.
- 2. Flat bones (e.g. Scapula):** consist of a cancellous bone center sandwiched between two plates of compact bone.
- 3. Short bones (e.g. Carpal bones).**
- 4. Irregular bones (e.g. vertebrae).**





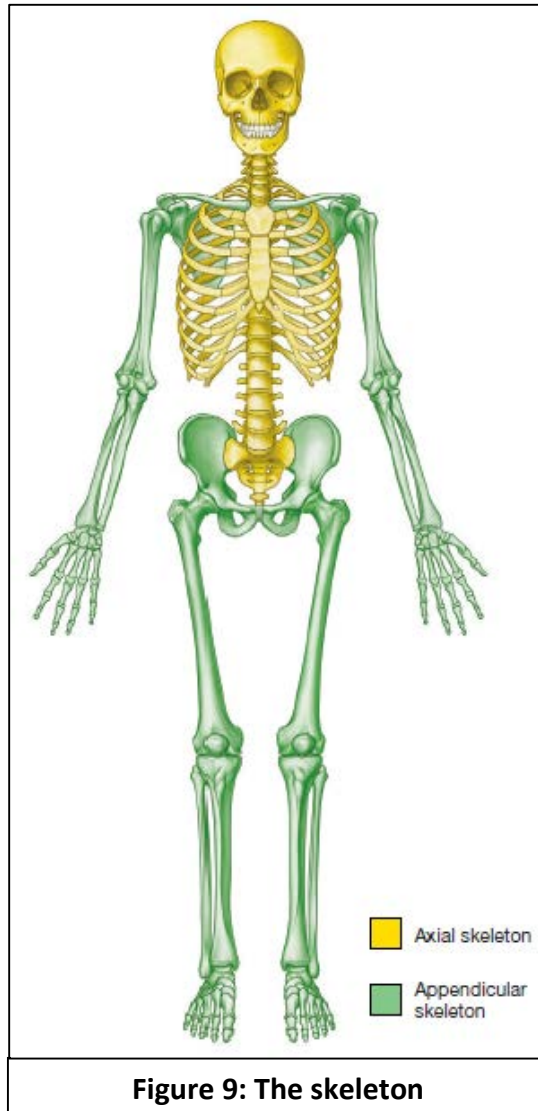
### Cartilage

Cartilage is composed of connective tissue cells & fibers embedded in a gel-like matrix giving it more resilience than bone. There are 3 types of cartilage: *Hyaline cartilage*, *Fibrocartilage* & *Elastic cartilage*.

**Bones and cartilage form the human skeleton [Figure.9] which is divided into two main parts:**

1. The axial skeleton: includes the skull, vertebral column and rib cage.
2. The appendicular system: includes the bones of the upper and lower limbs. The upper limb is attached to the axial skeleton by the shoulder

girdle, while the lower limb is attached to the axial skeleton by the pelvic (hip) girdle.



### Joints

A joint is the area where two or more bones come in contact with each other whether there is movement or not between the bones. Joints are classified according to the presence or absence of a cavity between the articulating bones into two major types: Solid joints and Synovial joints.

articulating bones are linked together in solid joints by connective tissue, while in synovial joints they are separated from each other by a fluid-filled space.

**1. Solid Joints [Figure.10]:** are classified into two categories according to the type of connective tissue that connects the articulating bones together:

- A. **Fibrous joints:** In these joints, a fibrous connective tissue fills the space between the articulating bones allowing little or no movement at all *e.g.* sutures of the skull, gomphose of the teeth and syndesmoses of long bones.
- B. **Cartilaginous joints:** a cartilage fills the area between the articulating bones allowing some movement. If the cartilage is Hyaline the joint is called a Primary cartilaginous joint (Synchondrosis) like the sternomanubrial joint. If the cartilage is fibrocartilage, the joint is a Secondary cartilaginous joint (Symphysis) like the pubic symphysis.

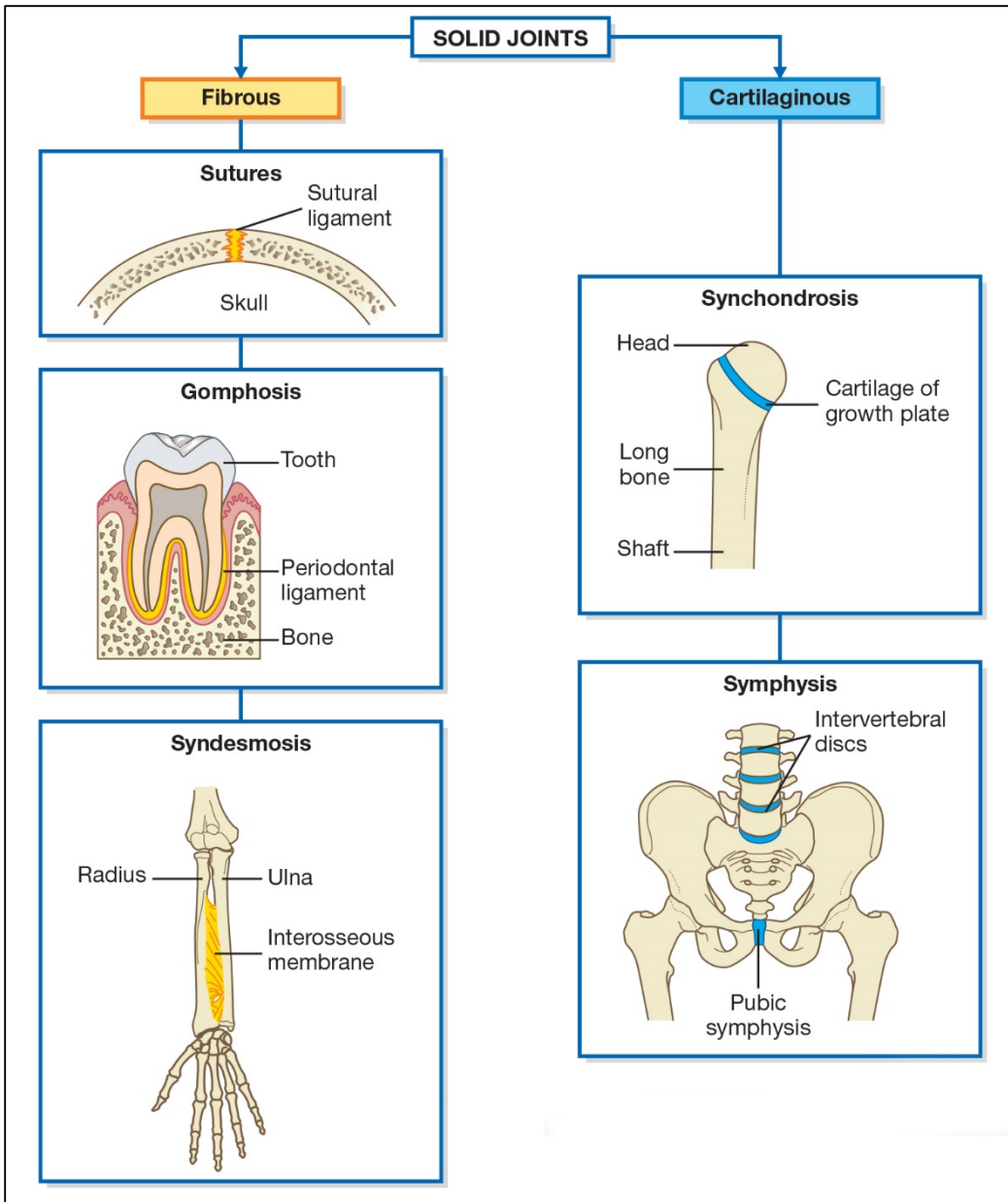


Figure 10: Types of solid joints

2. **Synovial joints [figure.11]** have the greatest range of movement.

The area between the articulating bones is occupied by the synovial cavity which is filled by a clear viscid synovial fluid (to lubricate

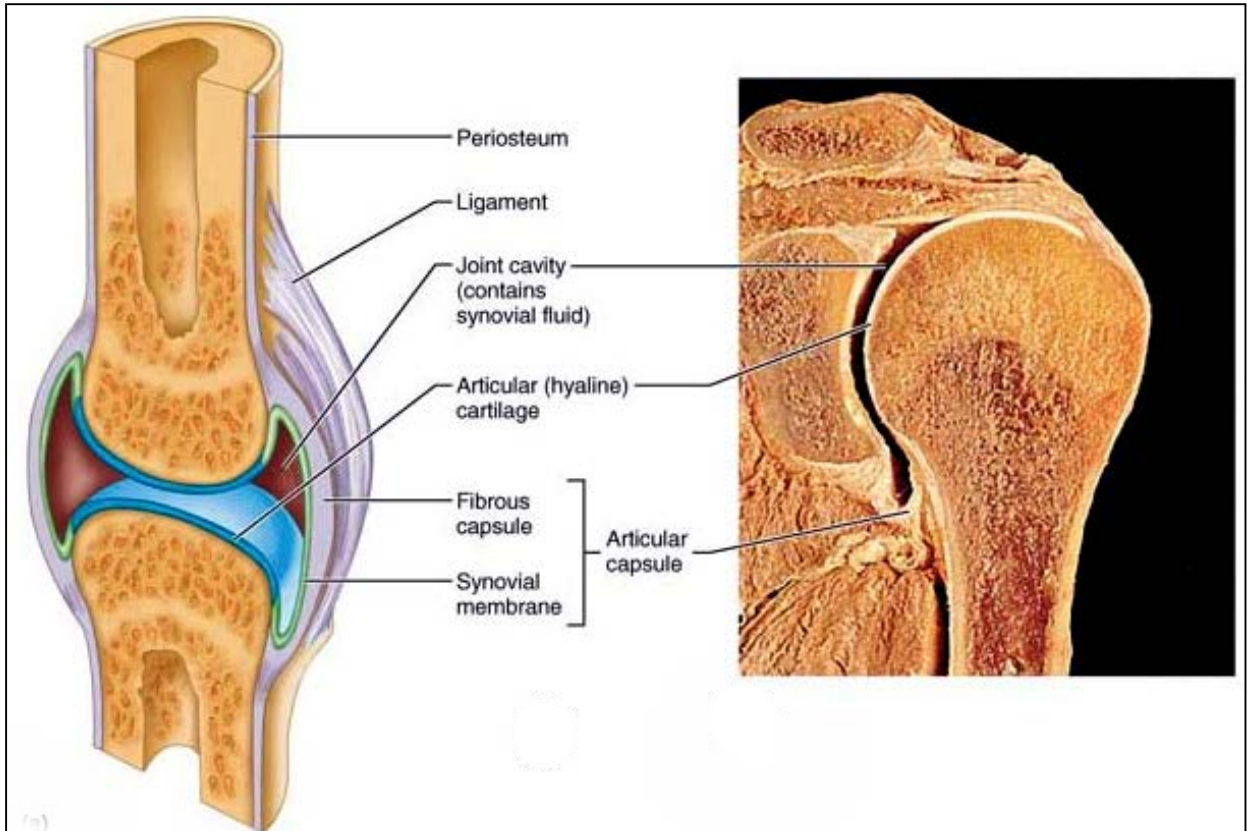


Figure 11: General structure of a synovial joint

movement & reduce friction) and surrounded by a synovial membrane (which produces the fluid). The synovial membrane is attached to the edges of the articular surfaces & is enclosed in a fibrous capsule that covers the whole joint & is continuous with the periosteum of adjacent bones. The synovial membrane & fibrous capsule together form the articular (joint) capsule. The articular surfaces are covered with a thin layer of hyaline cartilage called the articular cartilage.

### **Accessory structures associated with synovial joints [Figure.13]**

There are several accessory structures associated with synovial joints:

- **Bursa (pl. bursae)**: a bursa may be an extension of the synovial membrane or an isolated synovial sac filled with synovial fluid, found at areas where one structure frictions with another to reduce that friction *e.g.* between skin& bone, or muscle tendon & joint...etc.
- **Tendon (synovial) sheath**: is a tubular extension of synovial membrane around muscle tendons which pass within or near the synovial joint cavity. It functions to lubricate the movement of tendons over each other & over boney structures.
- **Ligaments**: are cords of connective tissue holding the articulating bones together & giving support & stability to the joint. Most ligaments are thickenings of the fibrous capsule; some are thickenings of deep fascia around the joint. There are 2 types of ligaments: Fibrous ligaments (rich with collagen fibers with poor stretch & thus prevent excessive movement of the joint) and Elastic ligaments (rich with elastic fibers with good stretch that returns the joint to its resting position after movement).

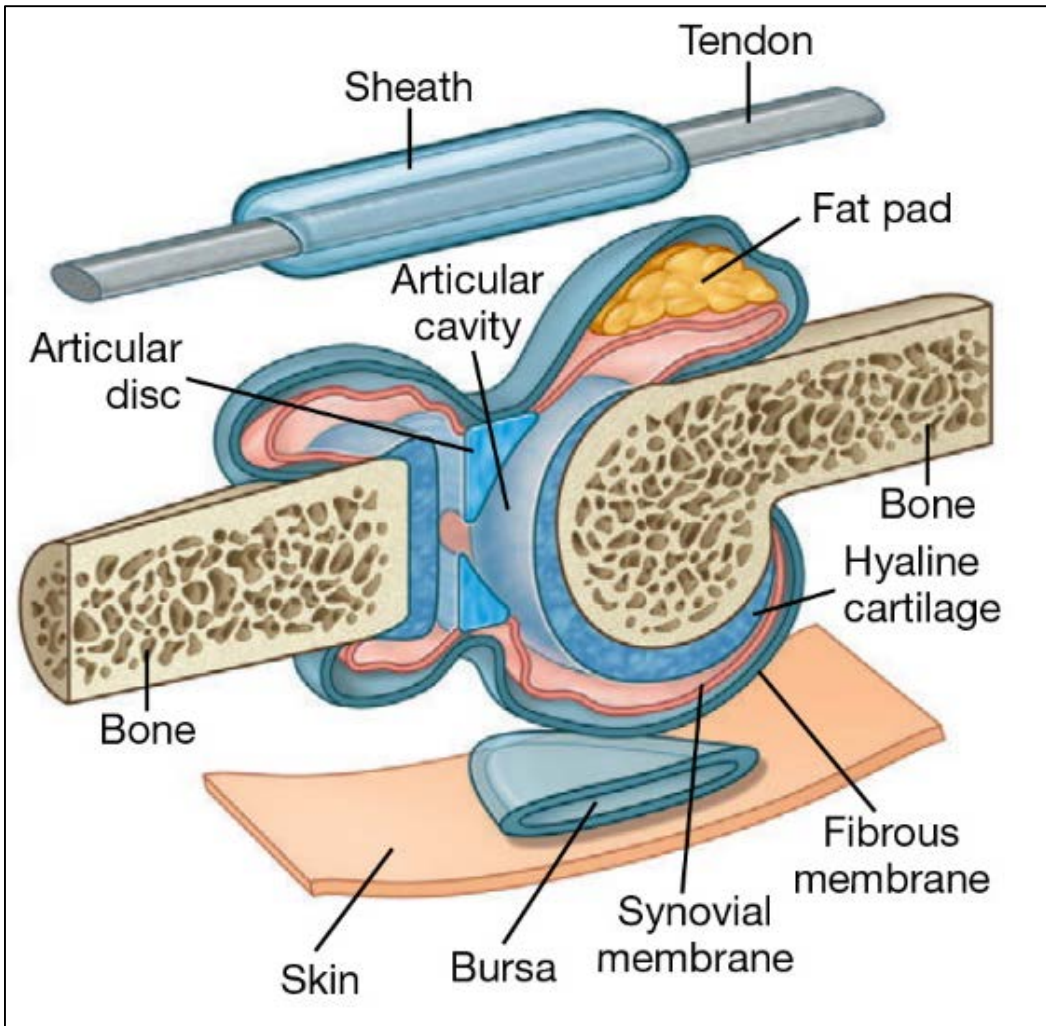


Figure 13: Accessory structures associated with synovial joints

- o **Retinacula:** a retinaculum is a thickening of deep fascia bridged between two or more bones and covering muscle tendons that pass over joints. the function of the retinaculum is to prevent long tendons passing over a joint from being sprung away during movement of that joint.

- **Articular discs:** (usually composed of fibrocartilage) absorb compression forces, adjust to changes in the contours of joint surfaces during movements, and increase the range of movements that can occur at joints.
- **Fat pads:** occur between the synovial membrane and the capsule and move into and out of regions as joint contours change during movement. Their function is to protect the articular cartilage.

### **The stability of any synovial joint depends on three factors:**

1. The shape of the articulating surfaces.
2. The number & strength of the surrounding ligaments.
3. The bulk & tone of the surrounding muscles.

The greater the stability of a synovial joint the less is the range of movement & vice versa.

### **Types of synovial joints [Figure 14]**

- Based on the **shape** of the articulating surfaces, synovial joints are described as plane (flat), hinge, pivot, condylar (ellipsoid), saddle, and ball and socket.
- Based on **movement**, synovial joints are described as uniaxial (movement in one plane), biaxial (movement in two planes), and multiaxial (movement in three planes).



## Introduction to Human Anatomy

---

Type	Shape of articulating bones	Possible movements	Example
<b>Plane (Biaxial)</b>	Flat	Sliding or gliding movements when one bone moves across the surface of another	Intercarpal joints
<b>Ball-and-Socket (Multiaxial)</b>	A spherical end fits a cup shaped cavity	<b>All movements</b> (flexion, extension, abduction, adduction, rotation & circumduction)	Shoulder joint
<b>Hinge (Uniaxial)</b>	A cylinder fits a longitudinal concavity (like a door hinge)	Allow movement around one axis that passes transversely through the joint permitting <b>flexion &amp; extension</b>	Elbow joint
<b>Pivot (Uniaxial)</b>	One bony process rotates in another bony or ligamentous ring	Medial & lateral <b>rotation</b>	Proximal Radio-ulnar joint
<b>Condylar/Ellipsoid (Biaxial)</b>	An oval convex surface fits an oval concave surface	<b>Flexion, extension, abduction, adduction</b> and limited <b>circumduction</b> but no rotation	Wrist joint
<b>Saddle (Biaxial)</b>	A concavo-convex surface in one direction fits a convexo-concave surface in the opposite direction	<b>Flexion, extension, abduction, adduction, circumduction</b> & passive rotation.	Carpometacarpal joint of the thumb

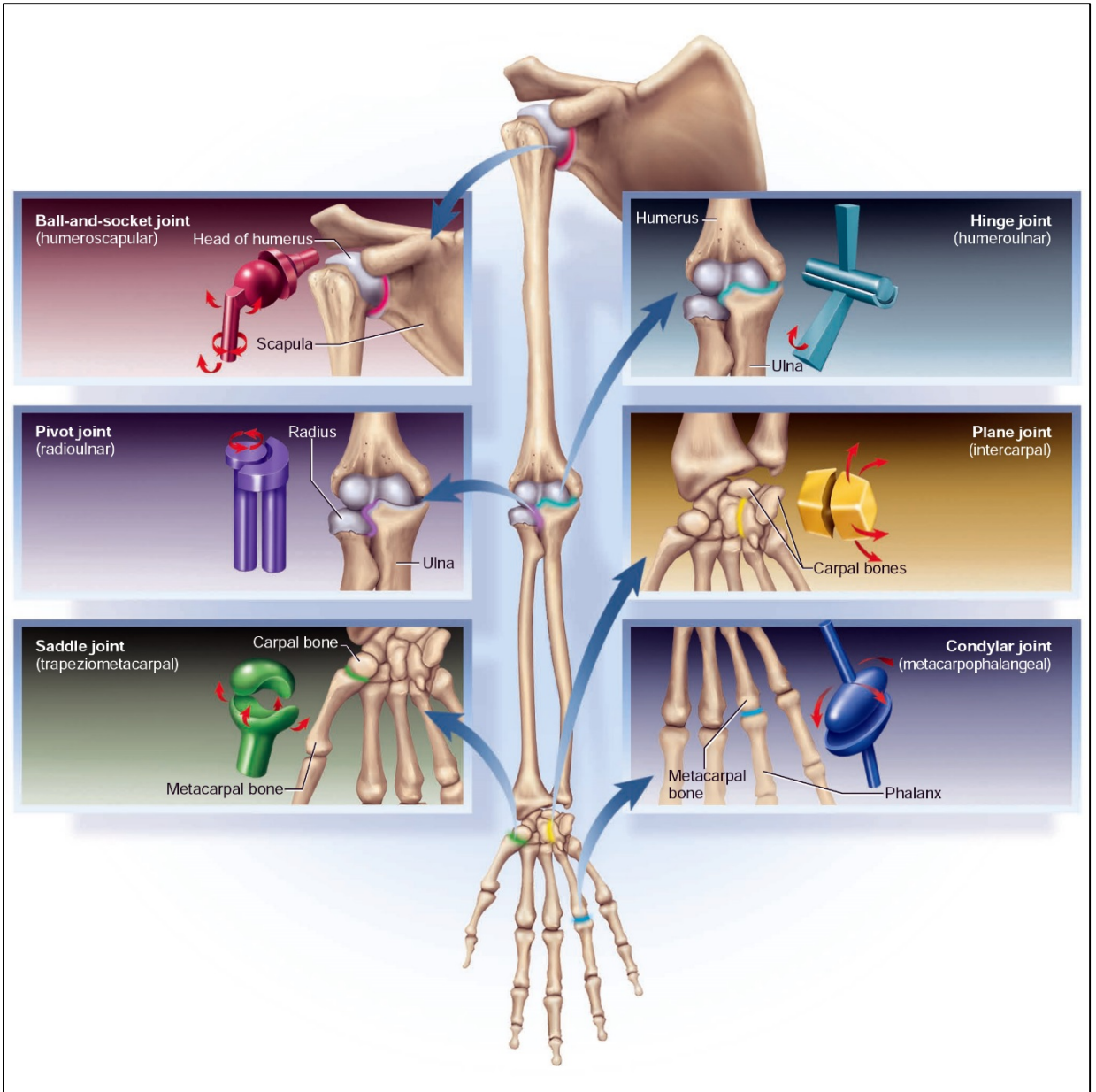


Figure 14: Types of synovial joints with examples from the upper limb

### Glands

Glands are specialized epithelial structures which produce & secrete compounds that regulate different body functions. They are classified into two types:

- **Exocrine glands:** have ducts which deliver the gland secretions either to the outside of the body **e.g.** sweat glands, or the inside of the body cavities **e.g.** mucous glands in the intestine.
- **Endocrine glands:** have no ducts for delivery. Instead, they secrete their products (hormones) directly into the blood stream **e.g.** thyroid gland.

### General arrangement of the nervous system

The nerve cell or *neuron* [figure.15] is the functional unit of the nervous system. It is composed of a large *cell body* that has numerous branches called the *dendrites*. One of these is the longest and is called the *axon*, which ends by further branching into *terminal dendrites*. Nerve signals or impulses always travel from the cell body along the axon towards the terminal dendrites. Nerve cells communicate with each other at their ends by *synapses*. Each axon represents a *nerve fiber*. Most axons are surrounded by special isolating cells called *Schwan cells* that form a *myelin sheath* around the axons. Such axons are called *myelinated nerve fibers* and appear white in color forming *the white matter* of the nervous system. The axons which are not surrounded by myelin sheath are called *unmyelinated or grey nerve fibers*.

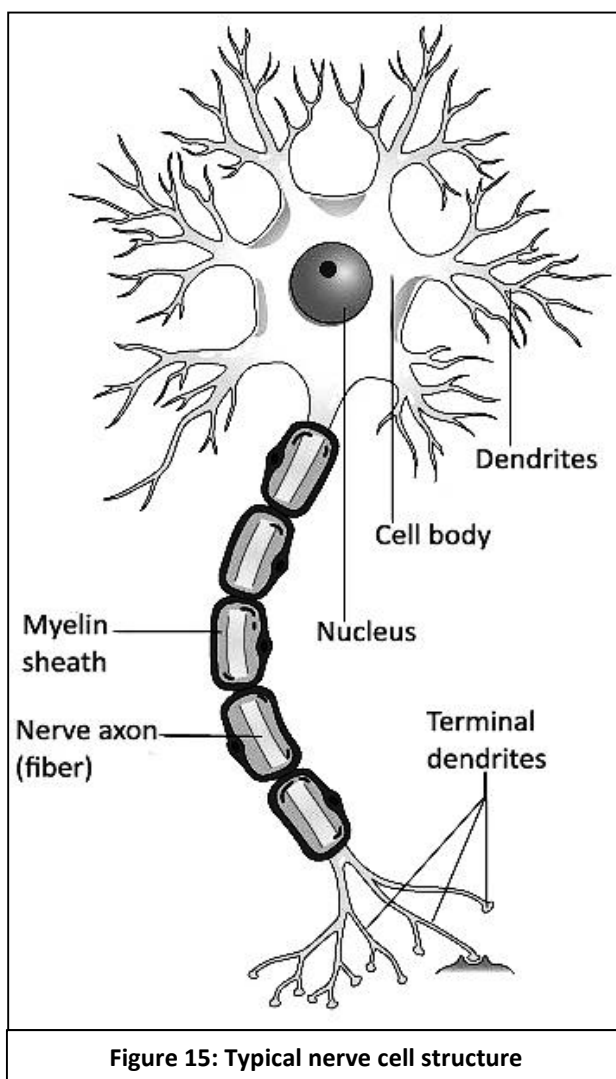


Figure 15: Typical nerve cell structure

Nerve cell bodies are never myelinated. Nerve cell bodies & unmyelinated nerve fibers form *the grey matter* of the nervous system.

A nerve appears as a whitish strong cord that is composed of bundles of nerve fibers (i.e. neuronal axons) embedded in connective tissue and surrounded by deep fascial coverings [**figure.16**].

Each nerve fiber consists of the axon of a nerve cell (which may be myelinated or unmyelinated). This fiber is surrounded by a membrane called *endoneurium*. The fibers are arranged in *bundles* and each bundle (fascicle) is surrounded by a membrane called the *perineurium*. The group of nerve fiber bundles making up the whole nerve cord is surrounded by deep fascial membrane called the *epineurium*.

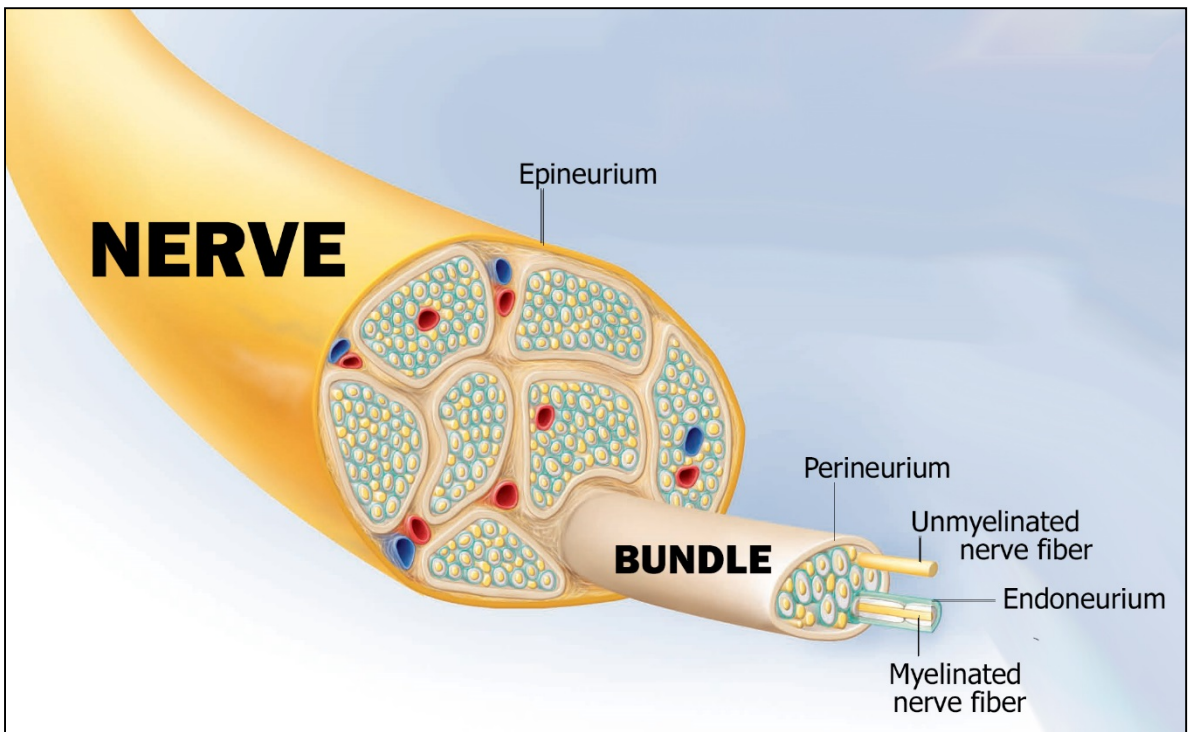


Figure 16: Structure of a nerve

### Anatomical arrangement of the nervous system

**Anatomically**, the nervous system is divided into the *Central Nervous System* (CNS) and *Peripheral Nervous System* (PNS). The CNS consists of the brain (enclosed in the cranium of the skull) and the *spinal cord* (enclosed in the *vertebral canal* of the *vertebral column*). The PNS is composed of 12 pairs of *cranial nerves* (which emerge directly from the brain through openings in the skull) and 31 pairs of *spinal nerves* (which emerge from the spinal cord at the *intervertebral foramina* between each two vertebrae).

Nerves (Spinal or cranial) can be divided into two types according to the direction of the flow of impulses they carry:

- **Afferent nerves:** carry *sensory* impulses from the periphery of the body to the central nervous system. An example is the cutaneous nerves that carry sensory information from the skin.
- **Efferent nerves:** carry *motor / effector* impulses from the central nervous system to different body organs. An example is the motor nerves that supply skeletal muscles.

### The Cranial Nerves

The 12 cranial nerves are given Roman numerics & names related to their function or structure.

Cranial Nerves	
Number	Name
I	Olfactory
II	optic
III	Oculomotor
IV	Trochlear
V	Trigeminal
VI	Abducent
VII	Facial
VIII	Vestibulocochlear
IX	Glossopharyngeal
X	Vagus
XI	Accessory
XII	Hypoglossal

### The Spinal Nerves

The vertebral column is composed of 30 vertebrae divided into five regions:

7 *cervical* [C] (in the neck), 12 *thoracic* [T] (in the chest), 5 *lumbar* [L] (in the abdomen), 5 *sacral* [S] (in the pelvis) and one *coccygeal* [Co] (made up of 3-4 fused small vertebrae but counted as one). The

spinal cord is divided into functional segments that correspond to the vertebrae. Each segment gives rise to one pair of spinal nerves. However, there are 31 spinal segments and 31 pairs of spinal nerves. This is because of the fact that all spinal nerves emerge inferior to their corresponding vertebrae except the cervical nerves which emerge superior to their corresponding vertebrae. The intervertebral foramen between C7 & T1 vertebrae allows the C8 spinal nerve to emerge. Therefore, there are 7 cervical vertebrae but 8 cervical spinal nerves.

A cross section in the spinal cord [**figure. 17**] shows that it is composed of a butterfly-shaped *grey matter* (cell bodies) surrounded by *white matter* (i.e. myelinated fibers). The grey matter has *anterior horn* cells (motor) and *posterior horn* cells (sensory). Each spinal nerve arises from the spinal cord by 2 roots: an *anterior root* composed of pure efferent motor fibers carrying impulses from the anterior horn cells, and a *posterior* root composed of pure afferent sensory fibers carrying impulses to the posterior horn cells. The posterior root shows a swelling called the *spinal (sensory) ganglion* where sensory nerve cell bodies aggregate. The two roots unite to form the *spinal nerve trunk* where there will be mixing of the motor and sensory fibers. The spinal nerve trunk lies at the *intervertebral foramen* & as soon as it leaves the foramen, it divides into *anterior & posterior rami* (i.e. branches). Each ramus consists of mixed afferent & efferent fibers. The anterior ramus is larger, longer and supplies more muscle mass and skin area.

The area of skin supplied by a single spinal nerve is called a dermatome. The muscle mass that is supplied by a single spinal nerve is called a myotome.

At the roots of the upper and lower limbs, the spinal nerves communicate with each other extensively through *Nerve Plexuses* which give rise to many branches to supply the many structures of the limbs **e.g.** Brachial plexus at the root of the upper limb.



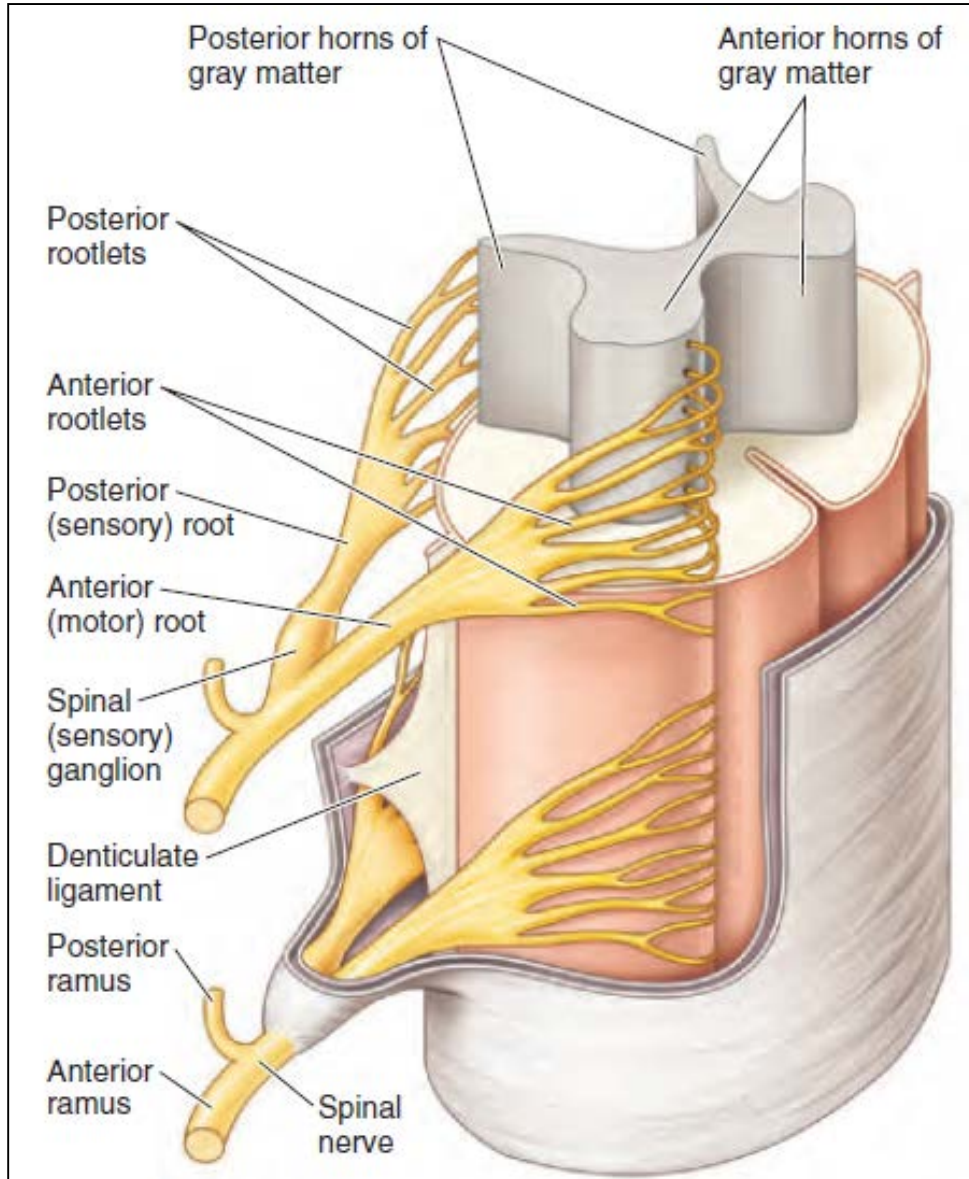


Figure 17: The spinal cord & spinal nerves

### Functional arrangement of the Nervous System

**Functionally**, the nervous system can be divided into *Somatic* nervous system (nerves concerned with sensory skin perception and voluntary motor muscular action) and the *Autonomic Nervous System* (ANS) which include the sympathetic and parasympathetic systems. The ANS is concerned with visceral sensory perception and control of involuntary structures **e.g.** glands, heart.

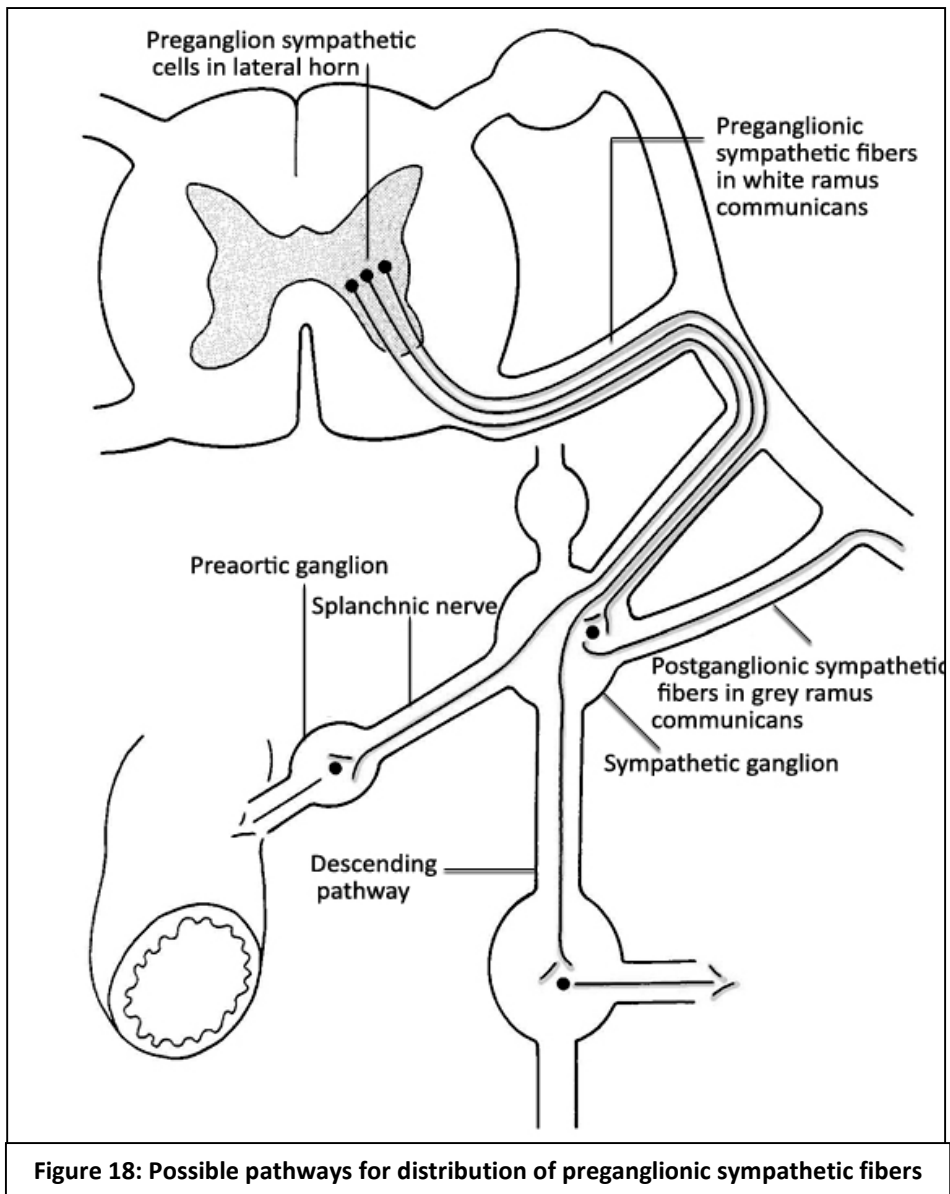
#### The Sympathetic System

The sympathetic system is called the thoracolumbar system, indicating the anatomical origin of its fibers. The fibers of the sympathetic system (which provide control of the CNS over the ANS) arise from the spinal segments between T1 & L2-L3.

These efferent fibers must relay their orders at an adaptor-like structure called the sympathetic ganglion. The sympathetic ganglia are interconnected to form the sympathetic trunk. Thus, the sympathetic trunk may be defined as a row of ganglia connected by nerve fibers extending from the base of the skull to the coccyx on each side outside the vertebral column, in close relation to the anterior rami & trunks of the spinal nerves.

The efferent sympathetic fibers leave the spinal cord and enter the anterior root of each spinal nerve as the myelinated *preganglionic fibers*. Then they pass from the anterior root to the sympathetic ganglion through the *white ramus communicans* [figure.18]. At the ganglion the

efferent fibers synapse with second order neurons which then leave the ganglion as the unmyelinated *postganglionic fibers* through the *grey ramus communicans* to be distributed through the anterior & posterior rami of the corresponding spinal nerve.



Some preganglionic fibers do not synapse in the sympathetic ganglion. Instead they either ascend to ganglia above (i.e. above T1 level) or

descend to ganglia below (i.e. below L3 level) so that all spinal nerves receives postganglionic sympathetic fibers.

Other preganglionic fibers do not synapse in the ganglia & do not ascend or ascend the sympathetic trunk. Instead, they leave the ganglia unchanged to reach & synapse in another smaller chain of ganglia around the abdominal aorta (prevertebral ganglia). These fibers form the three splanchnic nerves (greater, lesser & lowest) which are concerned with visceral gastrointestinal supply.

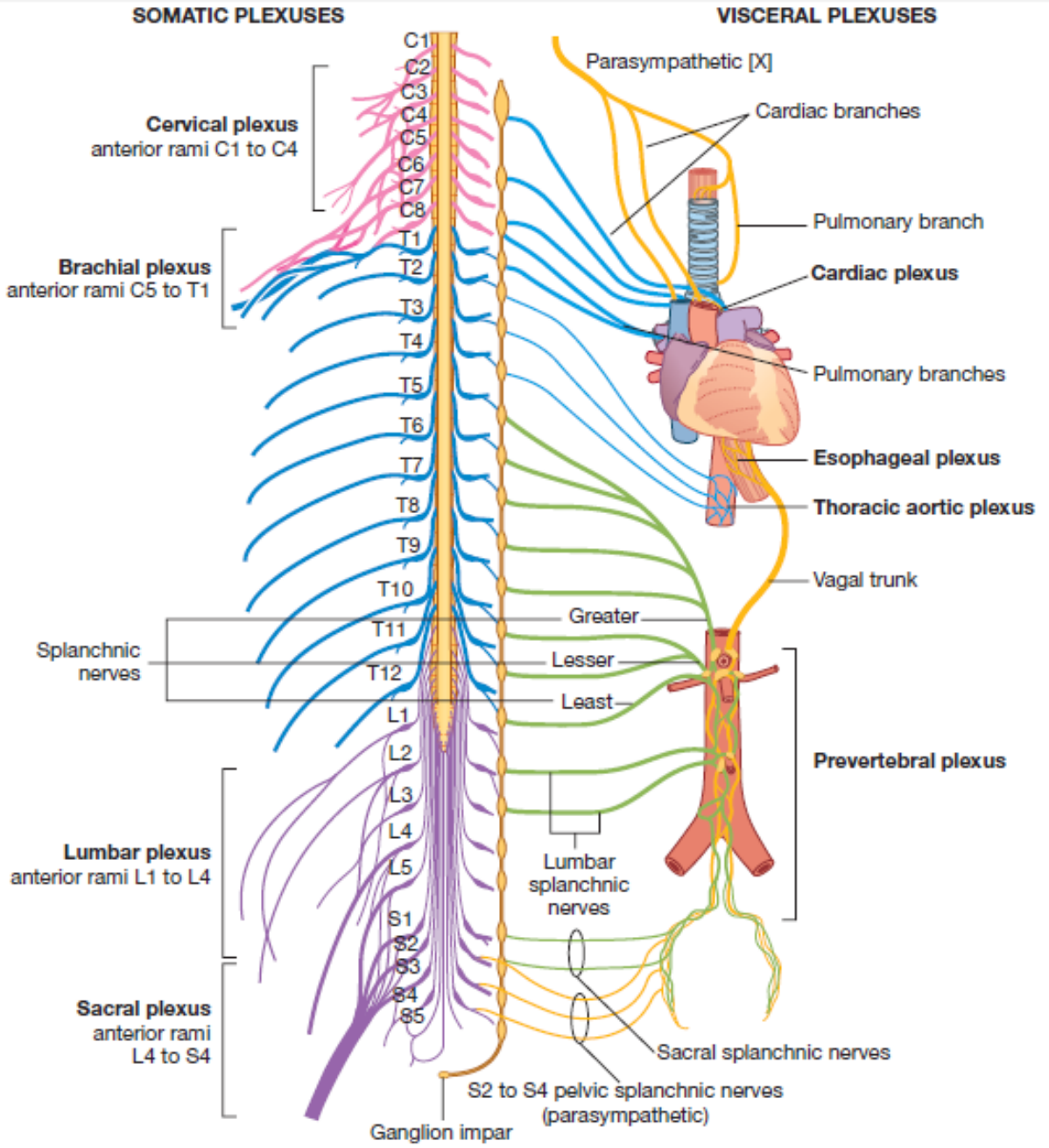
Sympathetic fibers pass to involuntary structures and prepare the body for dangerous situation (causing sweating, contraction of arrector pili muscles & goose-flesh, constriction of blood vessels, rise in blood pressure, increase in heart rate, dilatation of eye pupil...etc.). The sympathetic fibers reach these organs by passing through *all* the spinal nerves, *three* cranial nerves (IX, X, XII) or *around arteries* (as sympathetic plexuses).

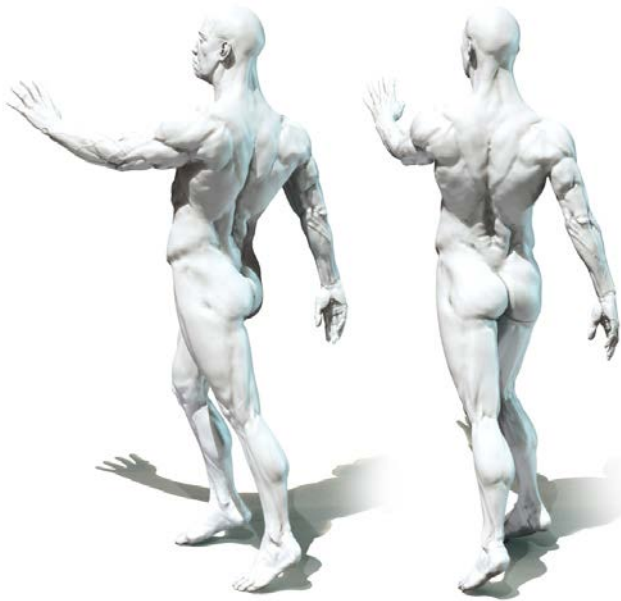### **The Parasympathetic System**

The efferent fibers of this system pass from cell bodies located in the brain and the sacral segments S2, S3, S4 of the spinal cord (therefore it is also called the craniosacral system). The cranial part supplies structures in the head, neck, thorax & upper abdomen while the sacral part supplies structures in the lower abdomen and pelvis. The effects of parasympathetic stimulation are opposite those of sympathetic

stimulation (i.e. dilatation of blood vessels, decrease in blood pressure & heart rate...etc.). The parasympathetic fibers reach their target organs by passing through *four* cranial nerves (III, VII, IX & X) and *three* spinal nerves (S2, S3, S4). They do not travel along arteries. Unlike the sympathetic ganglia, the parasympathetic ganglia are located near the target organs. Therefore, the preganglionic parasympathetic fibers are longer than the postganglionic ones.

# Introduction to Human Anatomy





# ANATOMY OF THE UPPER LIMB

Regional study of the anatomy of the upper limb  
for medical students

Sameh S. Akkila  
2016-2017

## Anatomy of the Upper Limb

### Regions of the upper limb

The upper limb is divided into four main regions and each region is divided into a number of subdivisions as shown in the table below.

Region	Subdivisions	Bones of Region	Joints of Region
Shoulder	Anterior: Pectoral region & breast	Clavicle Scapula	Sternoclavicular Acromioclavicular
	Posterior: scapular region		
	Lateral: axilla		
Arm	Anterior compartment	Humerus	Shoulder (glenohumeral)
	Posterior compartment		
Forearm	Anterior compartment	Radius	Elbow Proximal & distal radio-ulnar
	Posterior compartment	Ulna	
Hand	Wrist (carpus)	Carpal bones (8)	Wrist (radiocarpal)
	Hand proper (metacarpus)	Metacarpal bones (5)	Intercarpal Carpometacarpal
	Fingers (digits)	Phalanges (14)	Metacarpophalangeal Proximal & distal interphalangeal

The upper limb is attached to the trunk via the shoulder girdle. The clavicle is the bony link between the upper limb skeleton and the axial skeleton.

### Bones of the shoulder girdle

#### The clavicle

The clavicle (collar bone) is a long curved bone that articulates medially with the manubrium sterni and first costal cartilage to form the sternoclavicular joint. Laterally it articulates with the acromion of the scapula to form the acromioclavicular joint. It crosses above the coracoid process of the scapula but does *not* articulate with it. It is attached to the coracoid process by the coracoclavicular ligament. The clavicle has superior and inferior surfaces, medial and lateral ends and anterior & posterior borders **[Figure.1]**.

**There are five muscles attached to the clavicle:**

**- Three muscles take origin from the clavicle [Figure.2]**

- **Sternocleidomastoid**; from the superior surface, medially.
- **Pectoralis major**; from the medial ½ of the shaft, anteriorly
- **Deltoid**; from the lateral part of the shaft, anteriorly



### Two muscles are inserted into the clavicle

- **Trapezius**; to the posterior border laterally.
- **Subclavius**; to the inferior surface medially.

#### In the Lab

To determine whether a clavicle is right or left, one should apply three points:

- The medial (sternal) end of the clavicle is round while the lateral (acromial) end is flat.
- The inferior surface is roughened with muscular and ligamentous attachments while the superior surface is smoother. Roughenings on the inferior surface include:
  - Attachment of the costoclavicular ligament medially.
  - The insertion of subclavius muscle in the middle (subclavian groove).
  - Attachment of the trapezoid part of the coracoclavicular ligament laterally along the trapezoid line (ridge).
- The medial  $\frac{2}{3}$  of the shaft is convex anteriorly while the lateral  $\frac{1}{3}$  is concave anteriorly.

The lateral part of the posterior border contains a small round elevation called the conoid tubercle, to which the conoid part of the coracoclavicular ligament is attached.

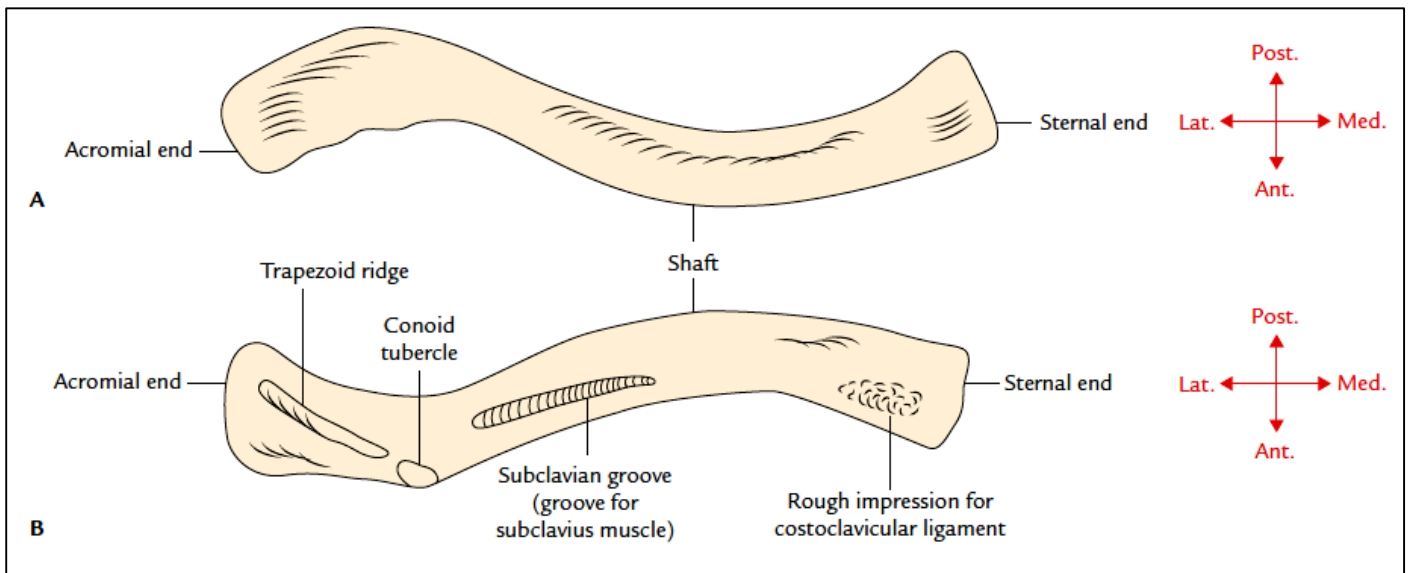


Figure1. Bony features of the right clavicle: (A) Superior view, (B) Inferior view.

## Anatomy of the Upper Limb

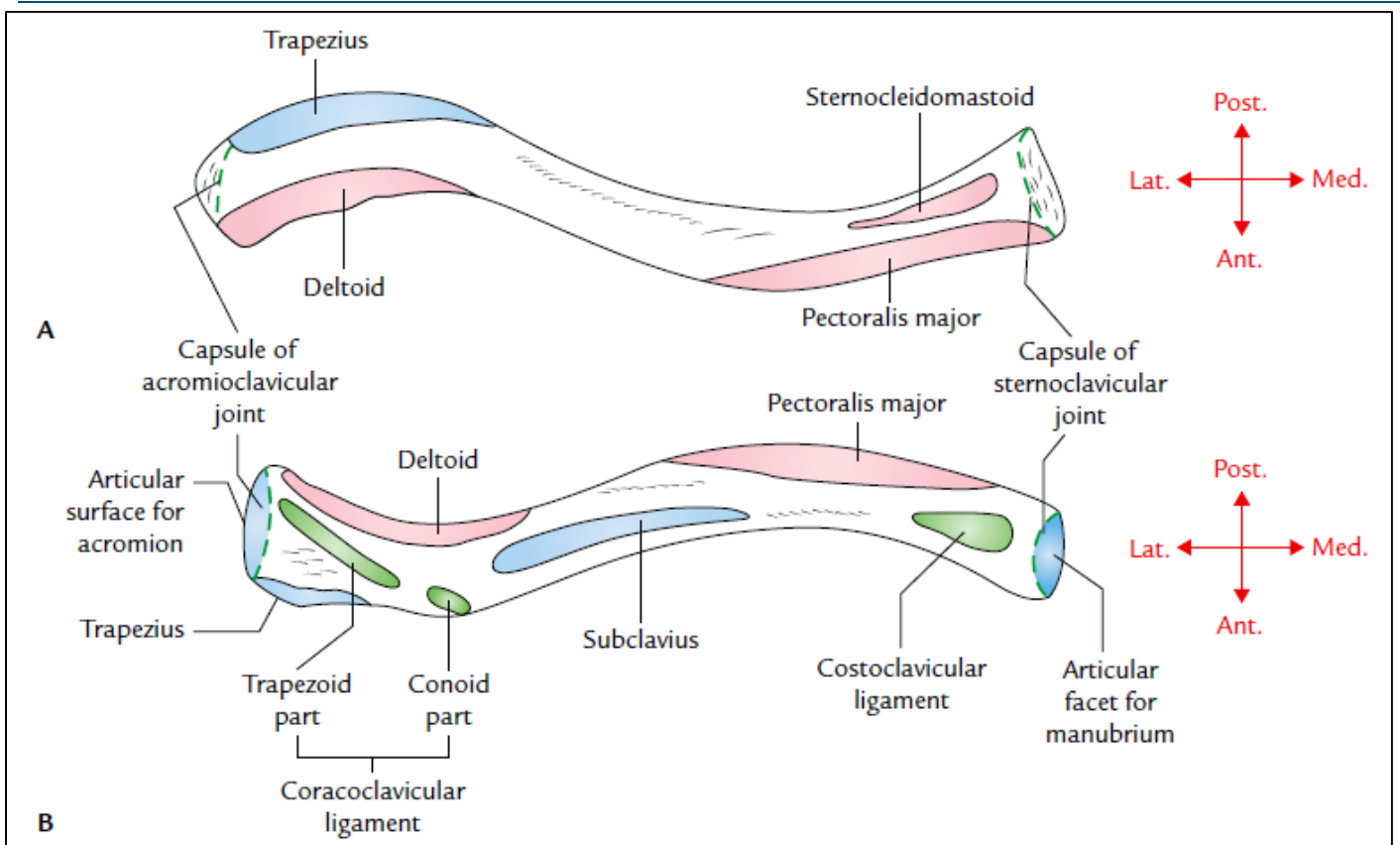


Figure 2. Muscular & ligamentous attachments to the right clavicle: (A) Superior view, (B) Inferior view.

### The scapula

The scapula (shoulder blade) is a roughly triangular bone, flat at its most part. It lies over the upper part of the back of the rib cage extending from the 2<sup>nd</sup> to the 7<sup>th</sup> ribs. The scapula articulates with the clavicle through the acromion forming the acromioclavicular joint, and with the humerus through the glenoid cavity forming the shoulder (glenohumeral) joint.

- **Bony features [Figure.3, 4]**

**The scapula has 3 borders, 3 angles and 2 surfaces;**

- The **superior border** is concave and is separated from the root of the coracoid process laterally by the **suprascapular notch**. In the living this notch is converted by a fibrous band (**suprascapular ligament**) into a **suprascapular foramen** through which the suprascapular nerve passes. The **coracoid process** is a peak-like (finger-like) projection that passes anterolateral to the suprascapular notch.

## Anatomy of the Upper Limb

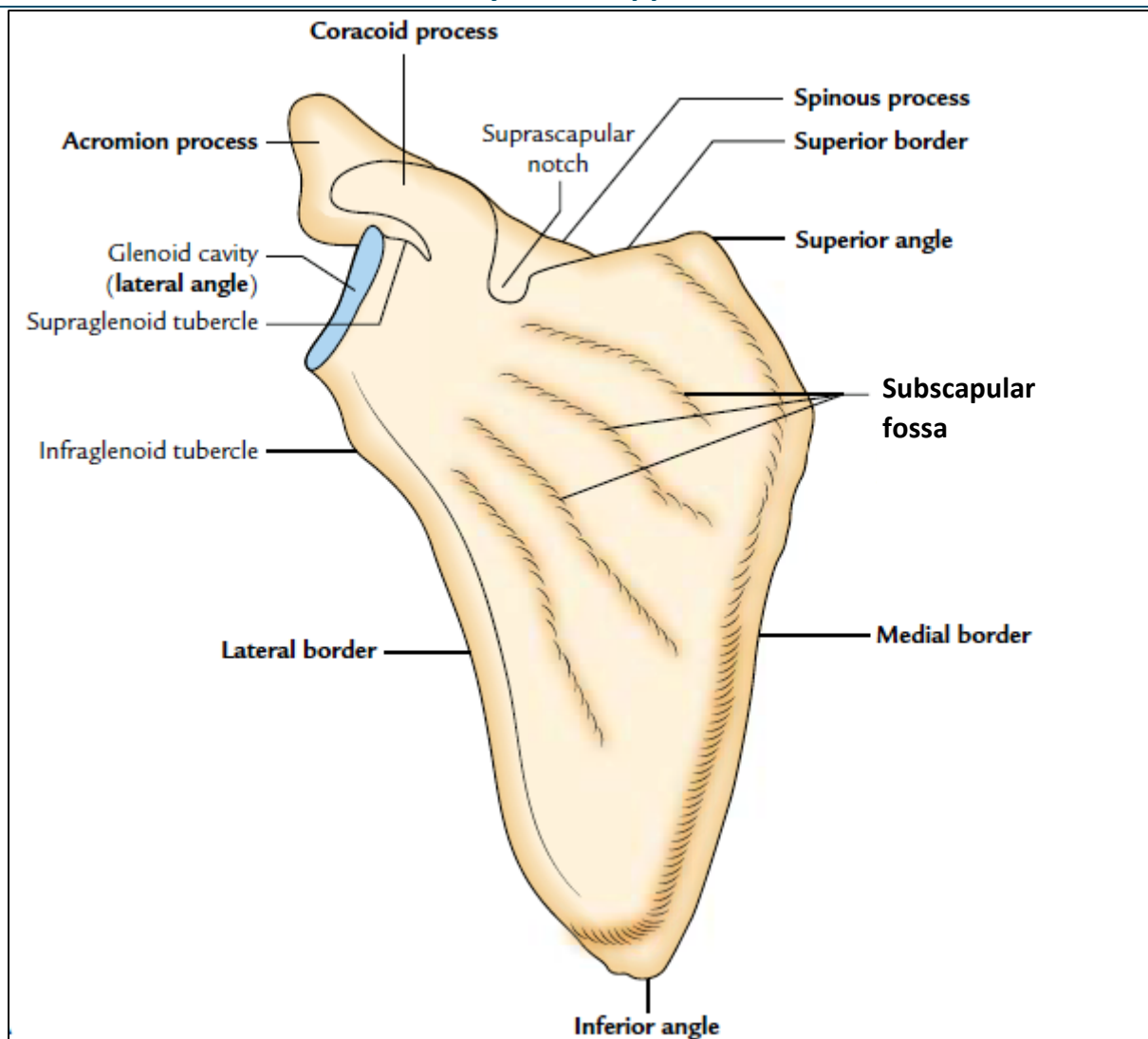


Figure 3. Bony features of the right scapula, anterior view.

- The **medial border** is the thin border that receives the insertion of most muscles originating from the trunk to the scapula.
- The **lateral border** is the thick border that gives origin to some of the muscles passing to the humerus.
- The **medial angle** lies where the superior and medial borders meet opposite T1 vertebral spine.
- The **inferior angle** lies where the medial and lateral borders meet opposite T6 vertebral spine.
- The **lateral angle** is where the lateral and superior borders meet. This angle is modified into a concavity called the **glenoid fossa** (cavity). There are 2 tubercles

## Anatomy of the Upper Limb

related to the cavity; **supraglenoid tubercle** (above) and **infraglenoid tubercle** (below).

- The **anterior (costal) surface** is concaved as the **subscapular fossa**.

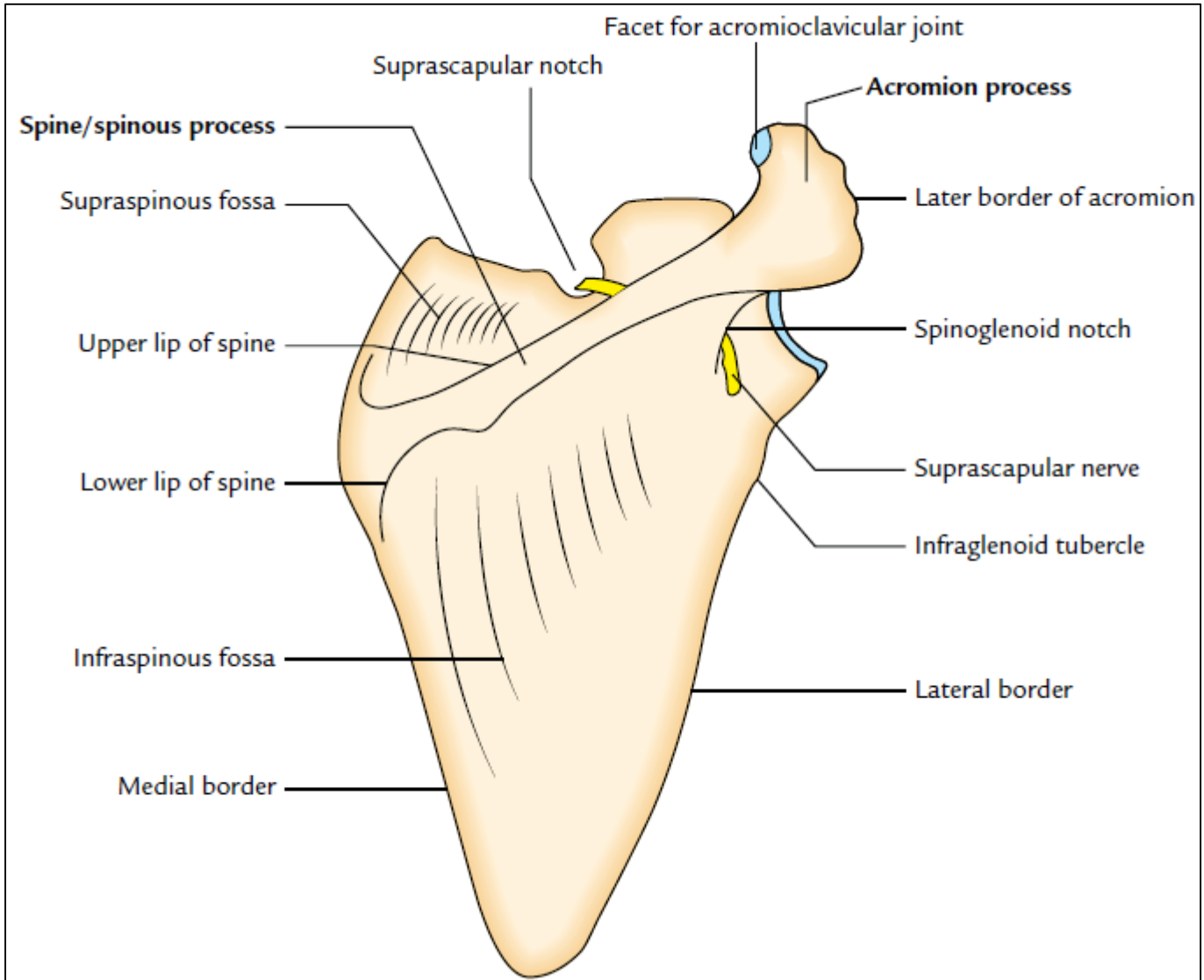


Figure 4. Bony features of the right scapula, posterior view.

- The **posterior (dorsal) surface** is divided by a bony ridge called the **spine of the scapula** into **supraspinous** and **infraspinous fossae**. The root of the spine lies close to the medial border opposite T3 vertebral spine. The spine of the scapula expands laterally as the **acromion** (tip of the shoulder). The area between the glenoid cavity and the lateral part of the scapular spine is the **spinoglenoid notch**, through which the suprascapular nerve and vessels pass. The constriction at the spinoglenoid notch is the **neck of the scapula**.

## Anatomy of the Upper Limb

- **Muscular and ligamentous attachments [Figure 5, 6]**
  - **Muscles inserted into the scapula** (axioscapular muscles) arise from the trunk and are inserted mostly on the medial border of the scapula;
    - ↪ **Serratus anterior, Levator scapulae, Rhomboid minor, Rhomboid major** are inserted to the medial border.
    - ↪ **Trapezius** inserts to the upper margin of the spine and medial border of the acromion.
    - ↪ **Pectoralis minor** is attached to the middle of the coracoid process.

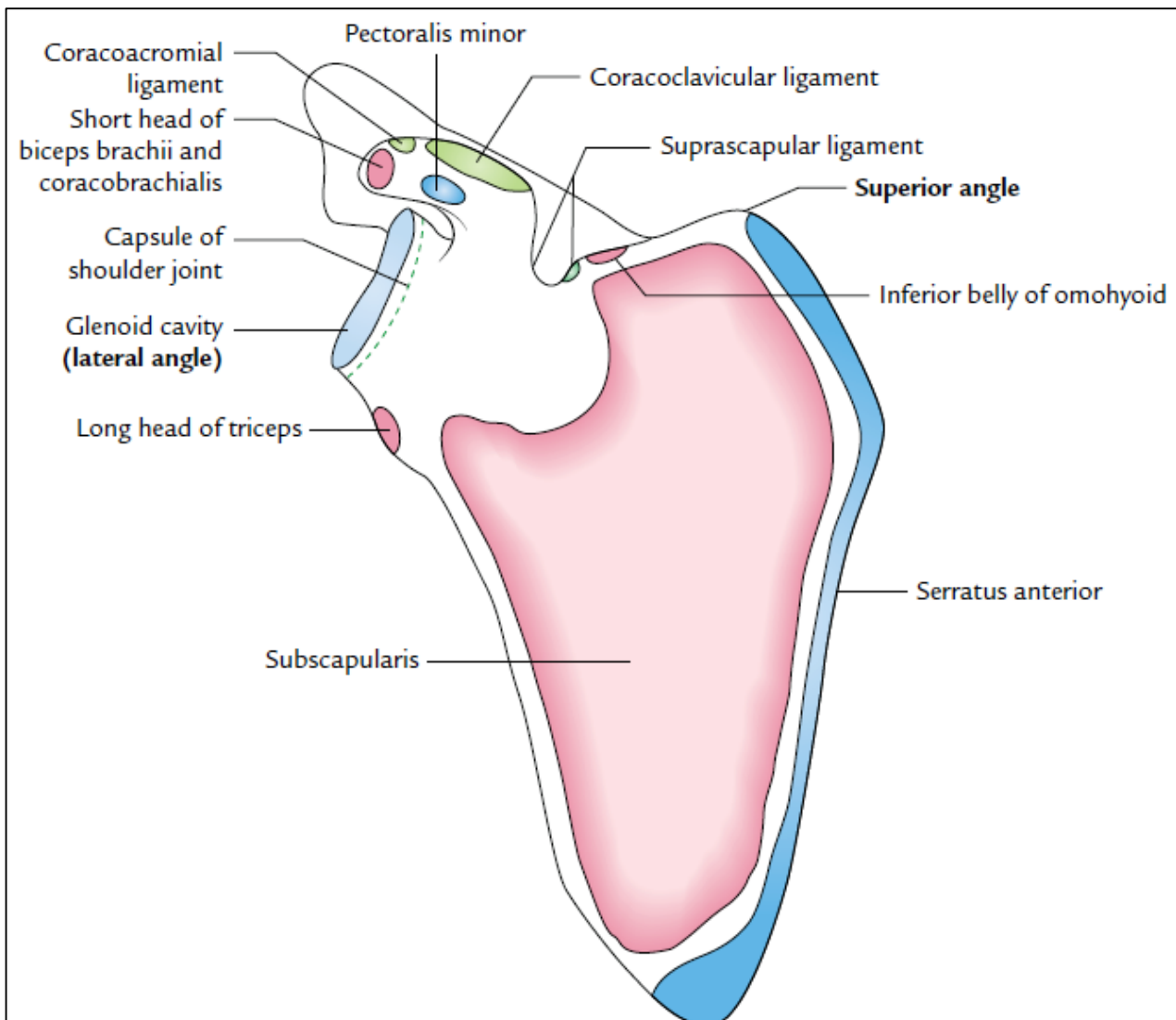


Figure 5: Muscles & ligaments attached to the right scapula, anterior view.

- Most of the **muscles which take origin from the scapula** (scapulohumeral muscles) arise from the surfaces and lateral border;

## Anatomy of the Upper Limb

- ↪ **Subscapularis, Supraspinatus & Infraspinatus** arise from the corresponding fossae.
- ↪ **Teres minor & Teres major** arise from the lateral border.
- ↪ **Long head of biceps**; from the supraglenoid tubercle.
- ↪ **Long head of triceps**; from the infraglenoid tubercle.
- ↪ **Deltoid**; from the lower margin of the spine and lateral border of the acromion.
- ↪ **Coracobrachialis** and **Short head of biceps**; from the tip of the coracoid process.
- ↪ **Omohyoid**; from the superior border just medial to the suprascapular notch.

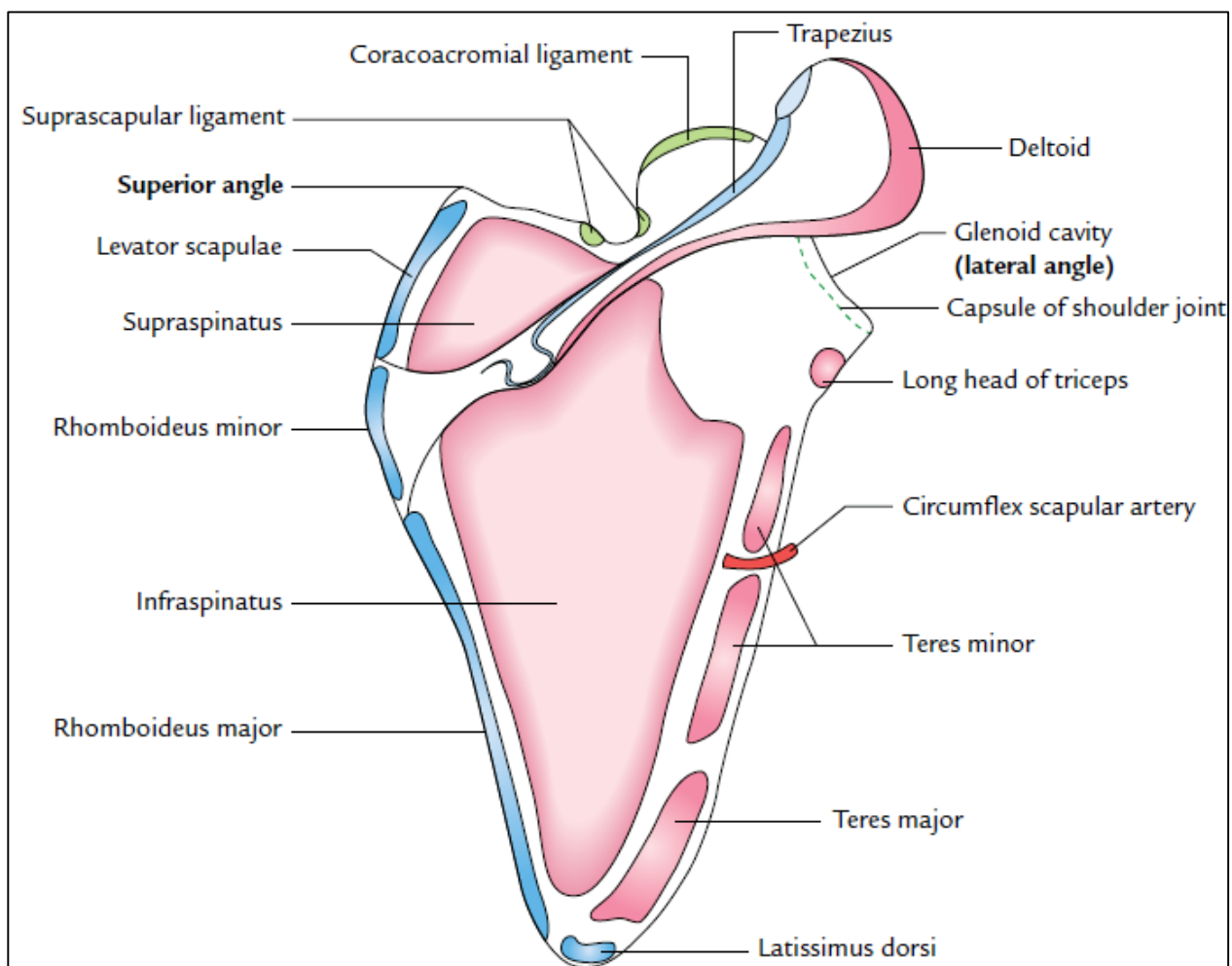


Figure 6: Muscles & ligaments attached to the right scapula, posterior view.

- **Ligaments attached to the scapula** include;
  - ↪ **Coracoclavicular ligament**; from the base of the coracoid process to the lateral end of the clavicle.
  - ↪ **Glenohumeral & coracohumeral ligaments**; pass to the humerus.
  - ↪ **Coracoacromial ligament**; between the base of the coracoid process and acromion.
  - ↪ **Spinoglenoid & suprascapular ligaments** bridge the corresponding notches.

### The Humerus

- **Bony features [Figure.7]**

The humerus (arm bone) is a long bone with proximal and distal ends and a shaft. It articulates with the scapula proximally to form the shoulder joint, and with the Radius and Ulna distally to form the elbow joint.

- **The proximal end**

The proximal end is expanded into a hemispherical articular **head** which is separated from the rest of the bone by a shallow groove (sulcus) called the **anatomical neck** of the humerus. The head is directed superomedially.

Lateral to the head lies a large bony process called the **greater tubercle** (or tuberosity) extending anteriorly laterally and posteriorly. The **lesser tubercle** is directed anteriorly and lies inferomedial to the head. The area between the two tubercles is the **intertubercular (bicipital) groove** or sulcus that extends inferiorly over the shaft. The greater tubercle extends inferiorly as the **crest of the greater tubercle (lateral lip of the bicipital groove)** while the lesser tubercle extends as the **crest of the lesser tubercle (medial lip of the groove)**. The attachment of the proximal end of the humerus to the shaft is the **surgical neck** of the humerus (a common site for fractures).

## Anatomy of the Upper Limb

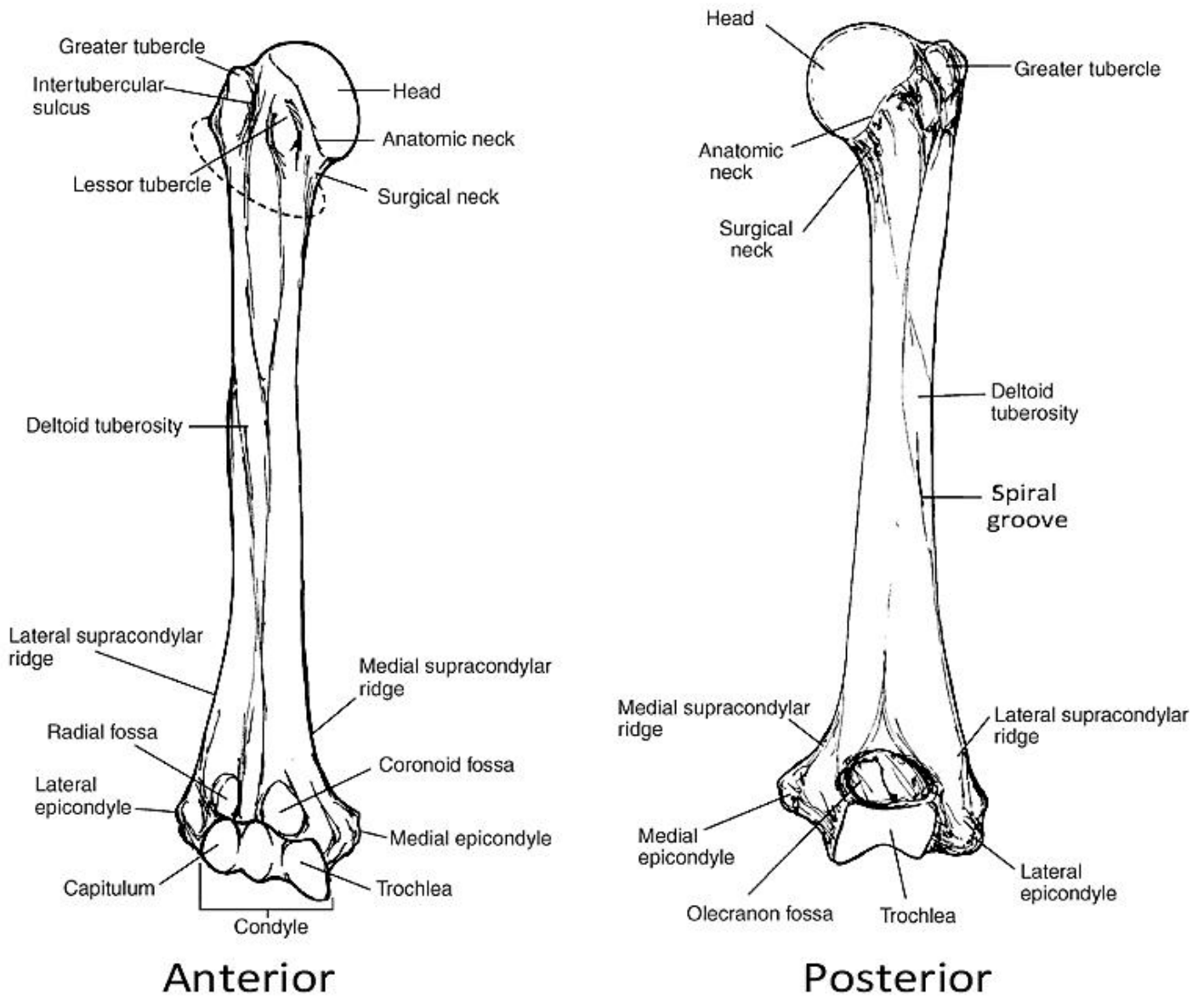


Figure 7: Bony features of the right humerus

### ➤ The shaft

The lateral part of the upper aspect of the shaft shows a large V-shaped prominence called the **deltoid tuberosity** (site of insertion of deltoid muscle). The **radial groove** winds around the shaft spirally marking the course of the radial nerve and profunda brachii vessels. The lower end of the shaft expands transversely and its medial and lateral margins (**supracondylar ridges**) end in 2 prominences called the **medial and lateral epicondyles**, respectively.



### ➤ The distal end

The articular surface of the distal end of the humerus is composed of 2 parts. The medial condyle is the **trochlea** which articulates with the **trochlear notch of the ulna** and is related by the **coronoid fossa** proximally which receives the **coronoid process** of the ulna during elbow flexion. The lateral condyle is the **capitulum** which articulates with the **head of the radius** and is related proximally by the **radial fossa** which receives the radial head during elbow flexion. Posteriorly, both the trochlea and capitulum are related proximally by the large **olecranon fossa** which receives the **olecranon process of the ulna** during elbow extension.

### • Muscular attachments [Figure.8]

#### ➤ Muscles inserted into the humerus are attached to its proximal half and include;

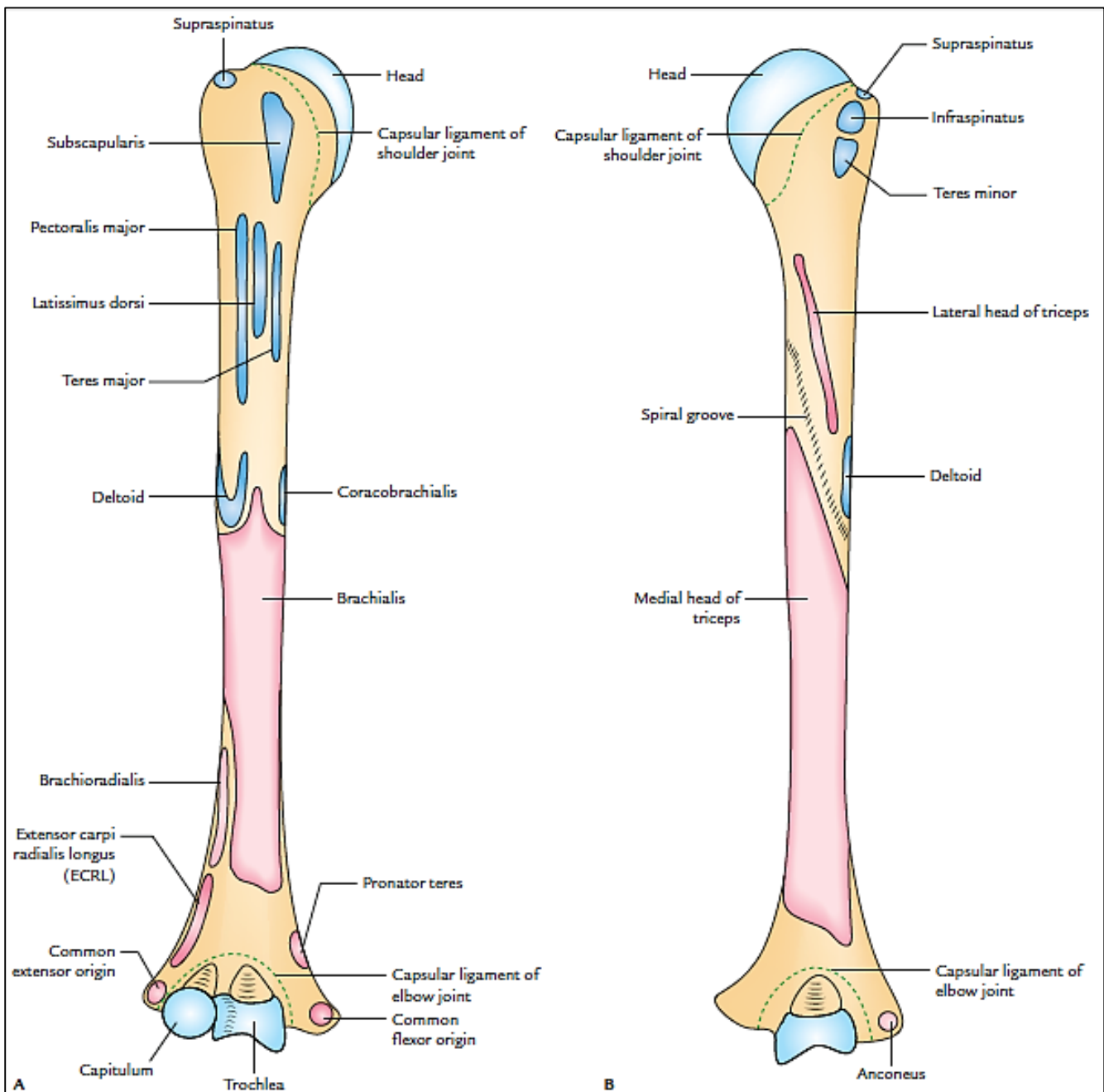
- ↪ **Supraspinatus**; to the greater tubercle (superiorly).
- ↪ **Infraspinatus**; ; to the greater tubercle (posteriorly).
- ↪ **Teres minor**; to the greater tubercle (posteroinferiorly).
- ↪ **Subscapularis**; to the lesser tubercle.
- ↪ **Pectoralis major**; to the lateral lip of the bicipital groove.
- ↪ **Teres major**; to the medial lip of the bicipital groove.
- ↪ **Latissimus dorsi**; to the floor of the bicipital groove.
- ↪ **Coracobrachialis**; to the medial part of the middle of the shaft.
- ↪ **Deltoid**; to the deltoid tuberosity.

#### ➤ Muscles which take origin from the humerus do so from its distal half;

- ↪ **Brachialis**; from the lower  $\frac{1}{2}$  of the anterior surface.
- ↪ **Lateral head of triceps**; from the posterior surface above the radial groove.
- ↪ **Medial head of triceps**; from the posterior surface below the radial groove.
- ↪ **Pronator teres**; from the medial supracondylar ridge and medial epicondyle.
- ↪ **Brachioradialis** and **Extensor carpi radialis longus**; from the lateral supracondylar ridge.

## Anatomy of the Upper Limb

- ↪ **Anconeus**; from the lateral epicondyle (posteriorly).
- ↪ **The common flexor tendon**; from the medial epicondyle.
- ↪ **The common extender tendon**; from the lateral epicondyle.



**Figure 8: Muscles attached to the right humerus: (A) anterior view, (B) posterior view.**

### The Pectoral Region and Breast

#### The pectoral region

#### Lines of demarcation & surface anatomy

The following (imaginary) lines are used to describe surface anatomy of the pectoral region & axilla **[Figure.9]**:

1. **Midsternal line** runs vertically in the median plane on the front of the sternum.
2. **Midclavicular line** runs vertically from the midpoint of the clavicle to the midinguinal point.
3. **Anterior axillary line** runs vertically downwards from the anterior axillary fold.
4. **Posterior axillary line** runs vertically downwards from the posterior axillary fold.
5. **Midaxillary line** runs vertically downwards midway between the anterior and posterior axillary folds.

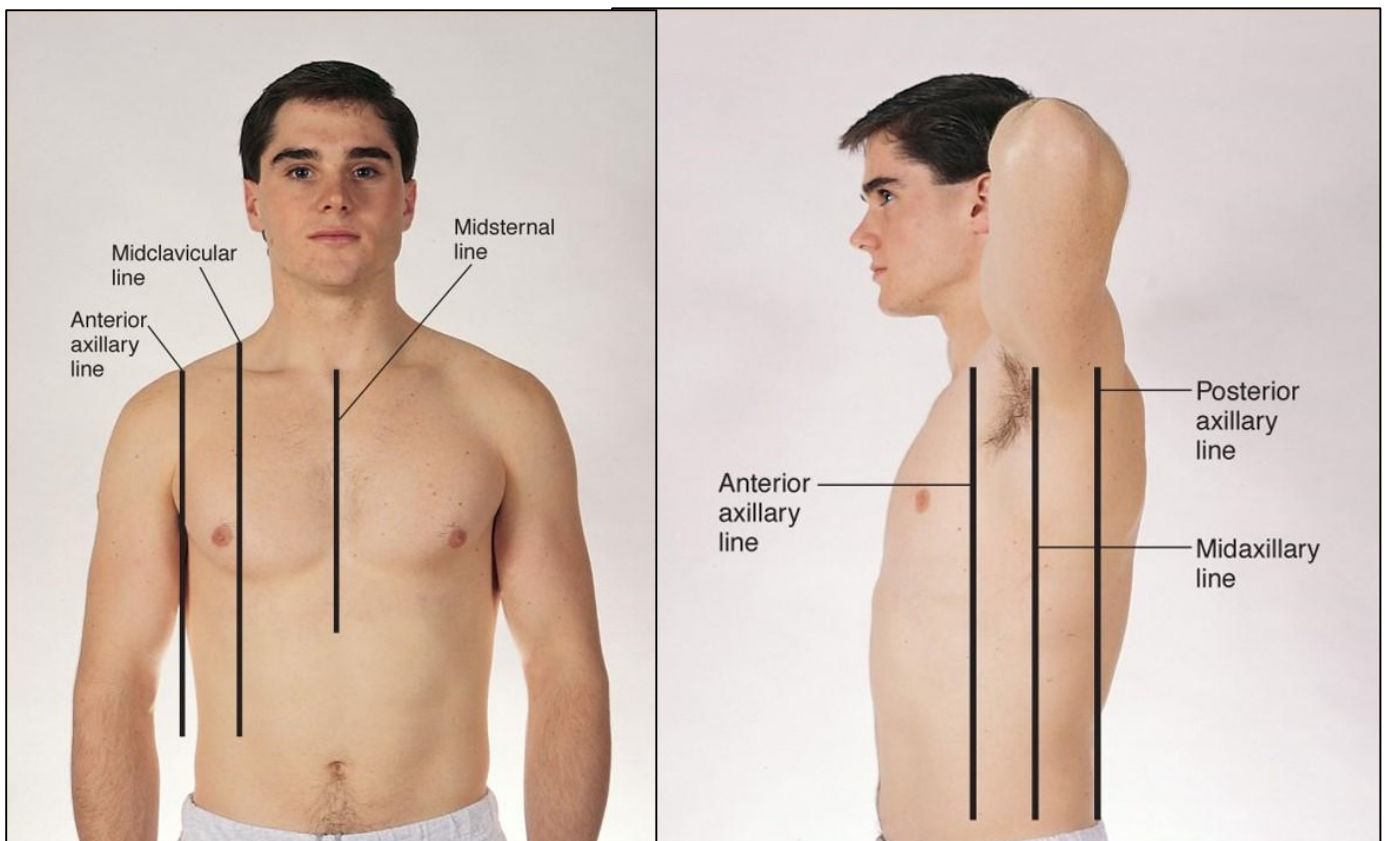


Figure 9: Lines of demarcation of the pectoral region & axilla.

### Surface anatomy (feel it on your body)

The following landmarks can be felt on the surface of the body in the pectoral region [figure.10]:

1. **Clavicle** is palpable along its whole length at the junction of root of the neck and front of the chest.
2. **Suprasternal notch (jugular notch)** is a palpable notch at the upper border of manubrium sterni between the medial ends of two clavicles.
3. **Infraclavicular fossa** is a triangular depression below the junction of middle and lateral third of the clavicle.
4. **Coracoid process:** The tip of coracoid process is felt in the infraclavicular fossa, 2.5 cm below the clavicle.
5. **The acromion:** is the bony prominence at the tip of the shoulder.
5. **Nipple:** Its position varies considerably in the female but in the male, it usually lies in the 4th intercostal space just medial to the midclavicular line.

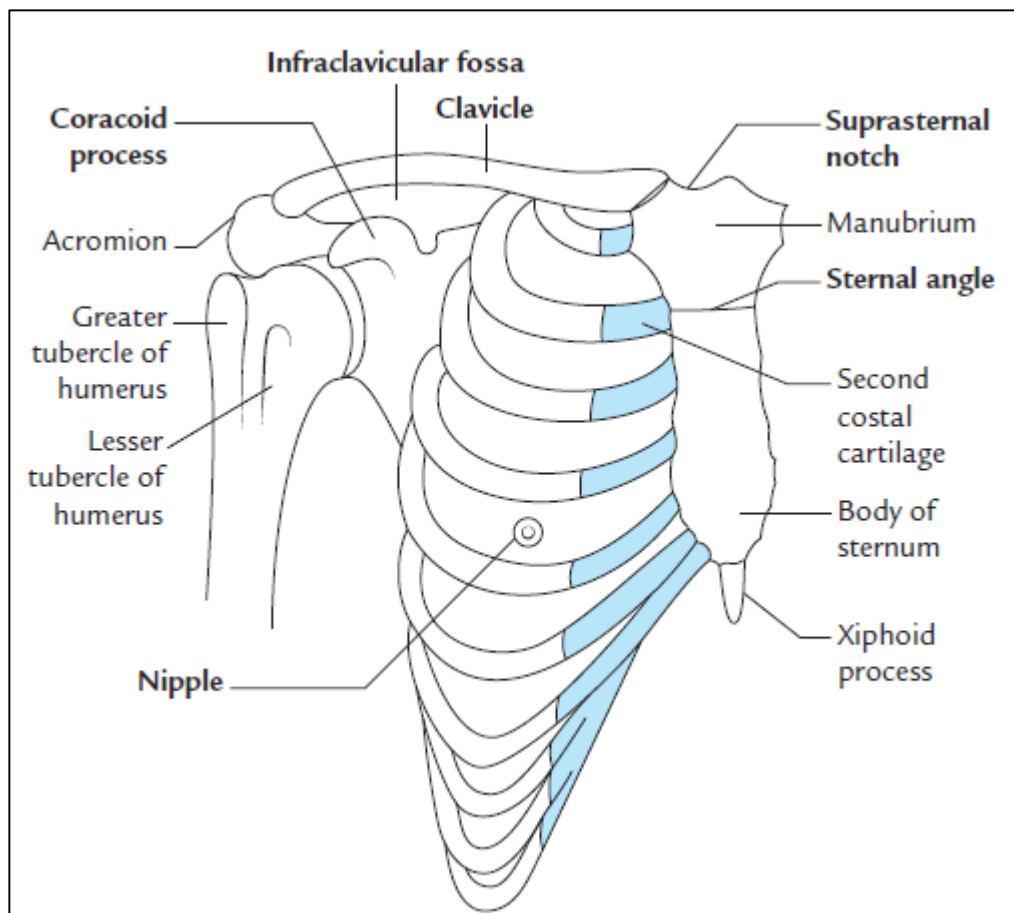


Figure 9: Surface landmarks of the pectoral region.

## Anatomy of the Upper Limb

### Extent & Location

The pectoral region is that part of the trunk extending from the clavicle superiorly to the level of the 7<sup>th</sup> costal cartilage inferiorly and from midsternal line medially to the midaxillary line laterally.

### Cutaneous nerve supply

The skin of the pectoral region is supplied by two sets of nerves:

1. Above the level of the second rib, the skin is supplied by the supraclavicular nerves (C3, C4) from the cervical plexus.
2. Below the level of the second rib, the skin is supplied by the ventral rami of T2-T6 spinal nerves (intercostal nerves).

### Muscles & Fascia

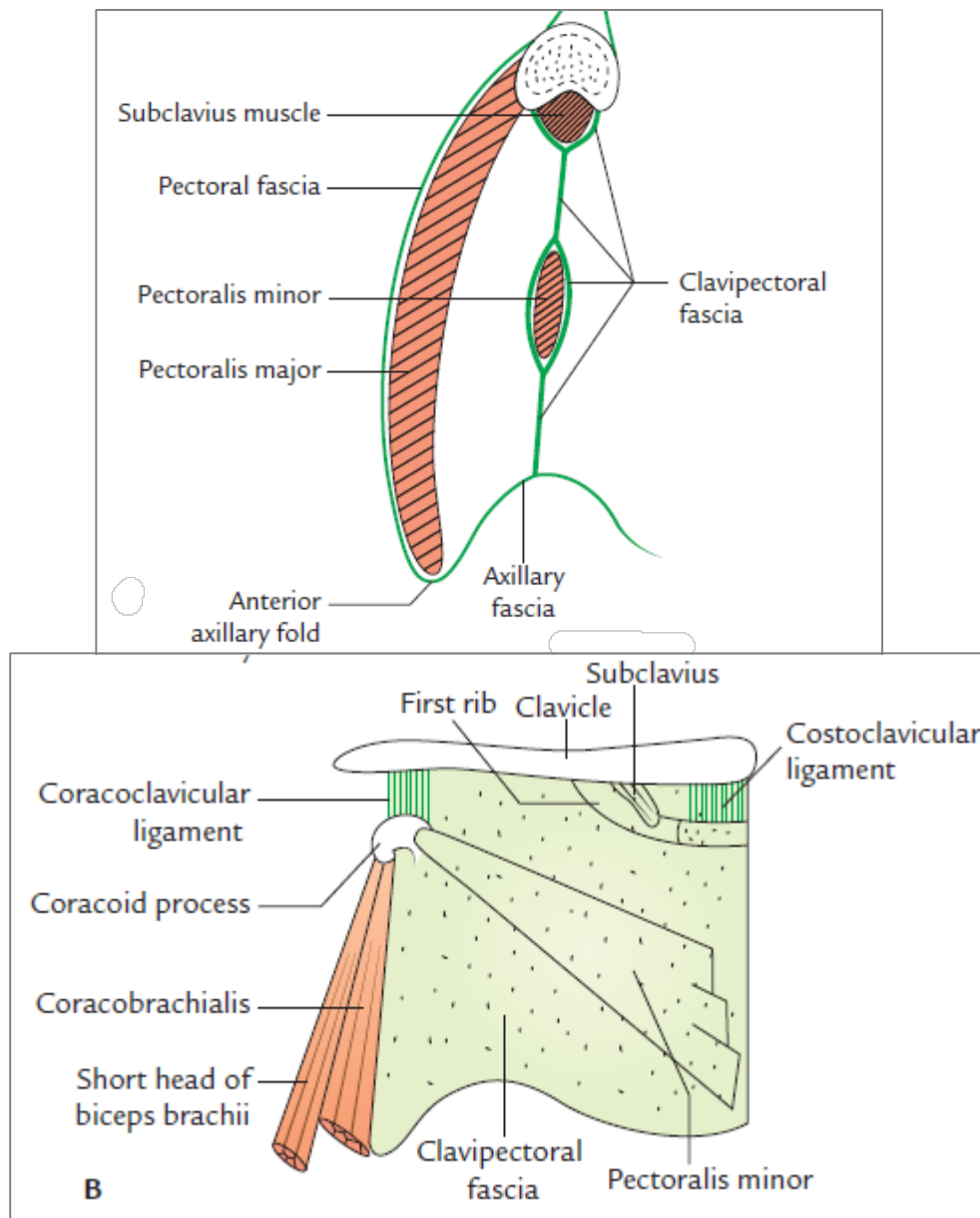
The three muscles of the pectoral region are pectoralis major anteriorly, pectoralis minor & subclavius posteriorly.

#### MUSCLES OF THE PECTORAL REGION

Muscle	Origin	Insertion	Innervation	Action
<b>Pectoralis major</b>	medial ½ of clavicle, anterior surface of sternum, 1 <sup>st</sup> – 6 <sup>th</sup> costal cartilages	Lateral lip of the bicipital groove	Medial and Lateral pectoral nerves	-Adduction, flexion and medial rotation of shoulder -Depression of scapula
<b>Pectoralis minor</b>	3 <sup>rd</sup> – 5 <sup>th</sup> ribs	Coracoid process	Medial pectoral nerve	Depression and medial rotation of the scapula
<b>Subclavius</b>	1 <sup>st</sup> costal cartilage	Inferior surface of clavicle	Nerve to Subclavius	Holds the clavicle to the sternum

The deep fascia of pectoralis major is the **pectoral fascia**. This fascia covers the anterior surface of pectoralis major and extends in four directions: Superiorly; to the clavicle, Superolaterally; to the deltoid fascia, Inferiorly; to the anterior abdominal wall and Inferolaterally to the axillary fascia.

The deep fascia of pectoralis minor & subclavius muscles is the **clavipectoral fascia [Figure 10]**. This thick fascia extends from the outer border of the first rib medially to the coracoid process laterally. Superiorly it is attached to the clavicle from which it descends to enclose subclavius muscle and passes as one layer that splits again to surround pectoralis minor muscle, and then the two layers unite again and thicken to be connected to the axillary fascial floor as the **suspensory ligament of the axilla**. The upper part of the clavipectoral fascia (from subclavius and pectoralis minor and from the first rib to the coracoid process) is thickened as the **costocoracoid membrane (ligament)**.



**Figure.10: The clavipectoral fascia in lateral (above) and anterior (below) views.**

The clavipectoral fascia is perforated by the following structures [Figure 12]:

1. The thoracoacromial artery.
2. The cephalic vein.
3. The lateral pectoral nerve.
4. The lymphatic vessels of the breast passing to the apical axillary lymph nodes.

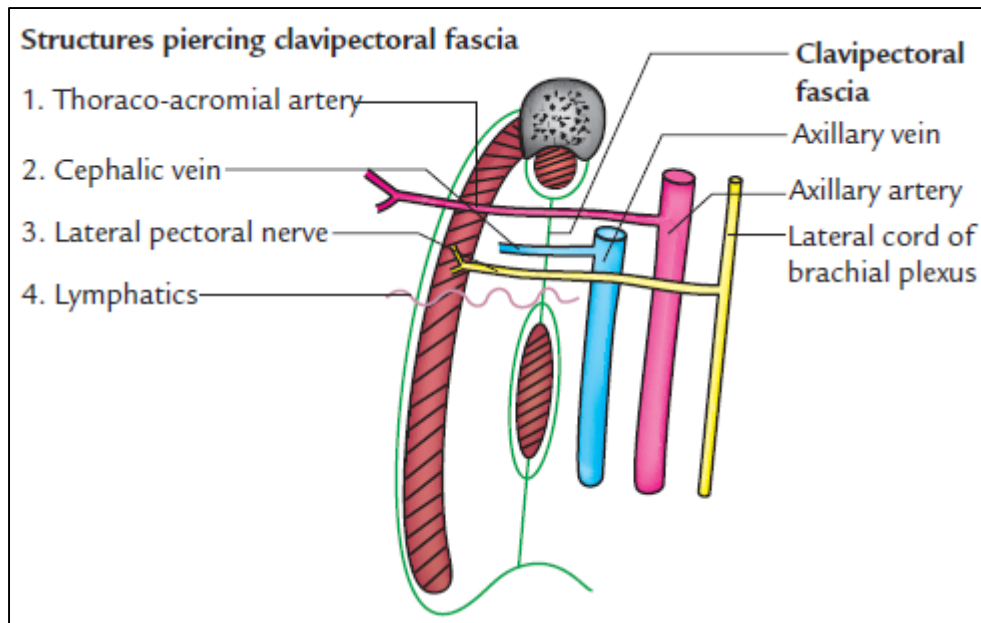


Figure.12: Structures perforating the clavipectoral fascia (lateral view).

### The Breast [Figure.13]

The breast is that part of the pectoral region extending from the 2<sup>nd</sup> to the 6<sup>th</sup> ribs and from the lateral edge of the sternum medially to the midaxillary line laterally. An **axillary tail** arises from the upper lateral quadrant of the breast and extends posterolaterally to the axilla over the 2<sup>nd</sup> and 3<sup>rd</sup> ribs deep to pectoralis major muscle. The breast is located in the superficial fascia of the pectoral region, except its tail which passes deep to the deep fascia. The breast is composed of skin, stroma and parenchyma.

### Skin

The skin of the breast is characterized by the presence of two features:

1. **The nipple:** is a conical projection near the center of the breast. The nipple contains 2 layers of smooth muscles, a longitudinal layer that flattens the nipple and a circular layer that erects it. It's highly sensitive to touch.

## Anatomy of the Upper Limb

**2. The areola:** is the circular area of pigmented skin surrounding the base of the nipple. It contains large number of modified sebaceous glands. They produce oily secretion, which lubricates the nipple and areola, and thus prevents them from drying and cracking.

### Stroma

The stroma of breast consists of connective tissue and fat. It forms the supporting framework of the breast. The fat forms the most of the bulk of the breast. It is distributed all over the breast except beneath the areola and the nipple.

The connective tissue condenses to form fibrous strands called **suspensory ligaments of Cooper**. They connect the dermis of the overlying skin to the ducts of the breast and pectoral fascia. The ligaments of the Cooper maintain the protuberance of the breast.

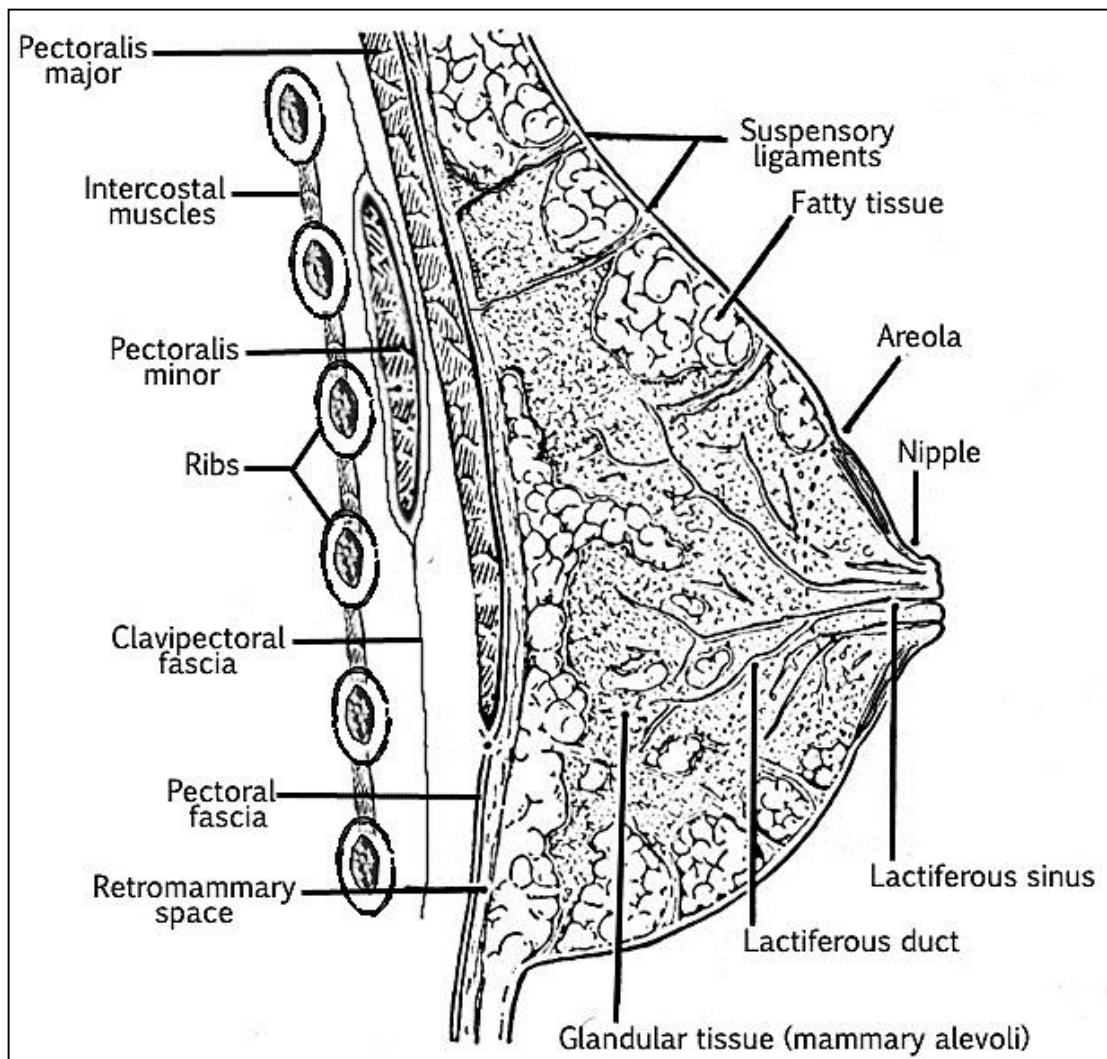


Figure 13: Structure of the lactating female breast on sagittal section.



### Parenchyma

The parenchyma of the breast is the glandular tissue represented by the mammary gland. The mammary gland is modified sebaceous gland that secretes milk instead of sebum. It consists of about **15–20 lobes** arranged in a radial fashion and converge towards the nipple. Each lobe consists of **milk alveoli** drained by **lactiferous (milk) ducts**. The ducts are dilated near the nipple as the **lactiferous sinuses (ampullae)** which narrow again to open separately on the apex of the nipple.

### Variations in breast structure

The breast structure is constant but its size and maturity depend on age and sex:

- **In the male;** the mammary gland is **rudimentary**, there is little fat in the superficial fascia, the nipple is small, the areola is surrounded by hair and the whole breast is stretched by the pectoralis major muscle.
- **In the non-lactating female;** the breast is composed mainly of fatty superficial fascia, the mammary gland is not fully mature, the nipple and areola are small and light (pink) colored and the whole breast tends to stand forward.
- **In the pregnant and lactating female [figure 18];** the mammary gland is fully developed taking the place of many of the fatty tissue and becoming functional in milk formation and secretion. The nipple and areola enlarge and become darker.
- **In post-menopausal women,** the breast tends to sag due to atrophy of the ligaments of cooper.

### Posterior relations of the breast [Figure.13]

The structures lying posterior to the breast include;

- The pectoralis major muscle and its (pectoral) fascia. The muscle is separated from the breast by a very thin space filled with loose areolar tissue called the **retromammary space**.
- Pectoralis minor muscle and its (clavipectoral) fascia.
- The serratus anterior and external oblique muscles (inferolaterally).
- The 2<sup>nd</sup> to the 6<sup>th</sup> ribs and intercostal spaces and muscles.

### Arterial supply of the breast

The breast is supplied by **branches** from the following arteries:

- Internal thoracic artery (medially).
- Lateral thoracic artery (Laterally).
- Anterior intercostal arteries (posteriorly).
- Thoracoacrmial artery. (superolaterally)
- Posterior intercostal arteries (inferolaterally).

### Lymphatic drainage of the breast [Figure.14]

The lymphatics draining the breast are divided into two groups: (a) superficial and (b) deep.

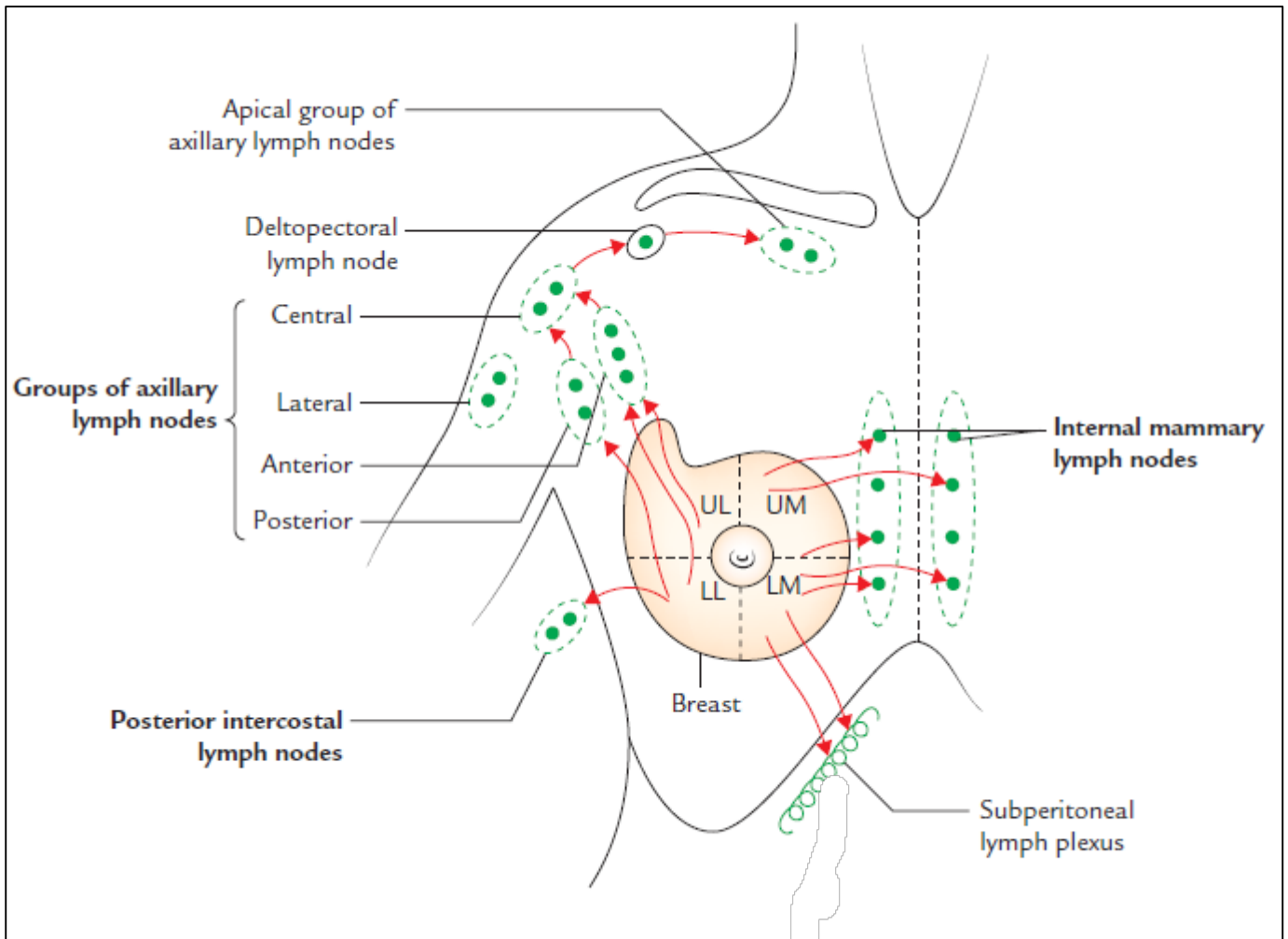
**Superficial lymphatics** drain the skin of the breast except that of nipple and areola.

**Deep lymphatics** drain the parenchyma of the breast, and skin of the nipple and areola. A plexus of lymph vessels deep to the areola is called **subareolar lymph plexus**. The breast is commonly divided into four quadrants: two medial (upper & lower) and tow lateral (upper & lower). About 75% of the lymph from the breast is drained into axillary nodes, 20% into internal mammary lymph nodes, and 5% into the posterior intercostal lymph nodes as follows:

1. The lymph from lateral quadrants of the breast and the subareolar plexus is drained into *anterior axillary lymph nodes*.
2. The lymph from medial quadrants is drained into *Parasternal (internal mammary) lymph nodes*.
3. A few lymph vessels from the lower lateral quadrant of the breast drain into posterior intercostal nodes.
4. The few lymph vessels from the lower medial quadrant of the breast pierce the anterior abdominal wall to deeper abdominal nodes.
5. The lymph vessels from the deep surface of the breast pierce pectoralis major and clavipectoral fascia to drain into the *apical group of axillary lymph nodes*

## Anatomy of the Upper Limb

*The superficial lymphatics of the breast of one side communicate with those of the opposite side. Consequently, the unilateral malignancy may become bilateral.*



**Figure 14: Mode of lymphatic drainage of the breast.**

### The Scapular Region

#### Lines of demarcation & Surface anatomy

The following lines are used to describe the surface anatomy of the scapular region & back

[Figure.15]:

1. **The midvertebral line:** is the posterior median line that runs vertically along the spines of the vertebrae.
2. **The paravertebral line:** runs vertically along the transverse processes of the vertebrae.
3. **The scapular line:** runs vertically downwards through the inferior angle of the scapula.

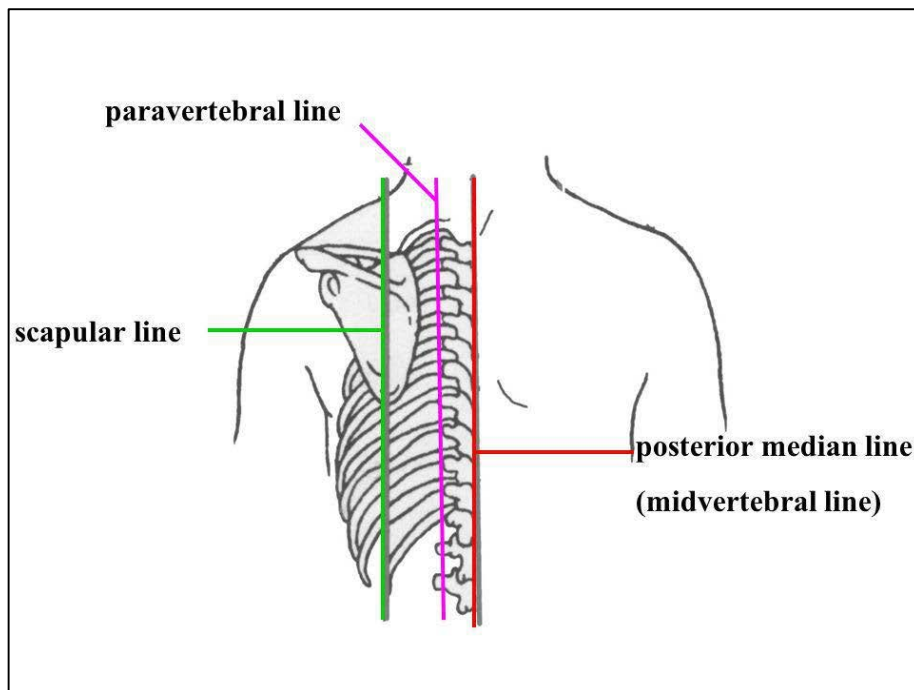


Figure 15: Lines of demarcation of the back & scapular region.

#### Surface anatomy (feel it on your partner's body)

The following landmarks can be felt on the surface of the body in the scapular region & back [figure.16]:

1. **The occiput** is the bone of the back of the skull.
2. **The nuchal furrow** is the depression in the flesh of the middle of the back of the neck. It overlies the ligamentum nuchae which covers the upper 6 cervical spines.
3. **C7 spine** is the first spine felt on the back of the neck. Other vertebral spines are counted downwards from it.
4. **The spine of the scapula** is felt from the acromion laterally to the medial border of the scapula medially. Its root ( at the medial border) lies opposite T3 spine.

### Surface anatomy (feel it on your partner's body)

5. **The medial border of the scapula** is felt from the superior angle (opposite T2 spine) to the inferior angle (opposite T7 spine).
6. **The iliac crest:** is felt by placing the hands on the waist.

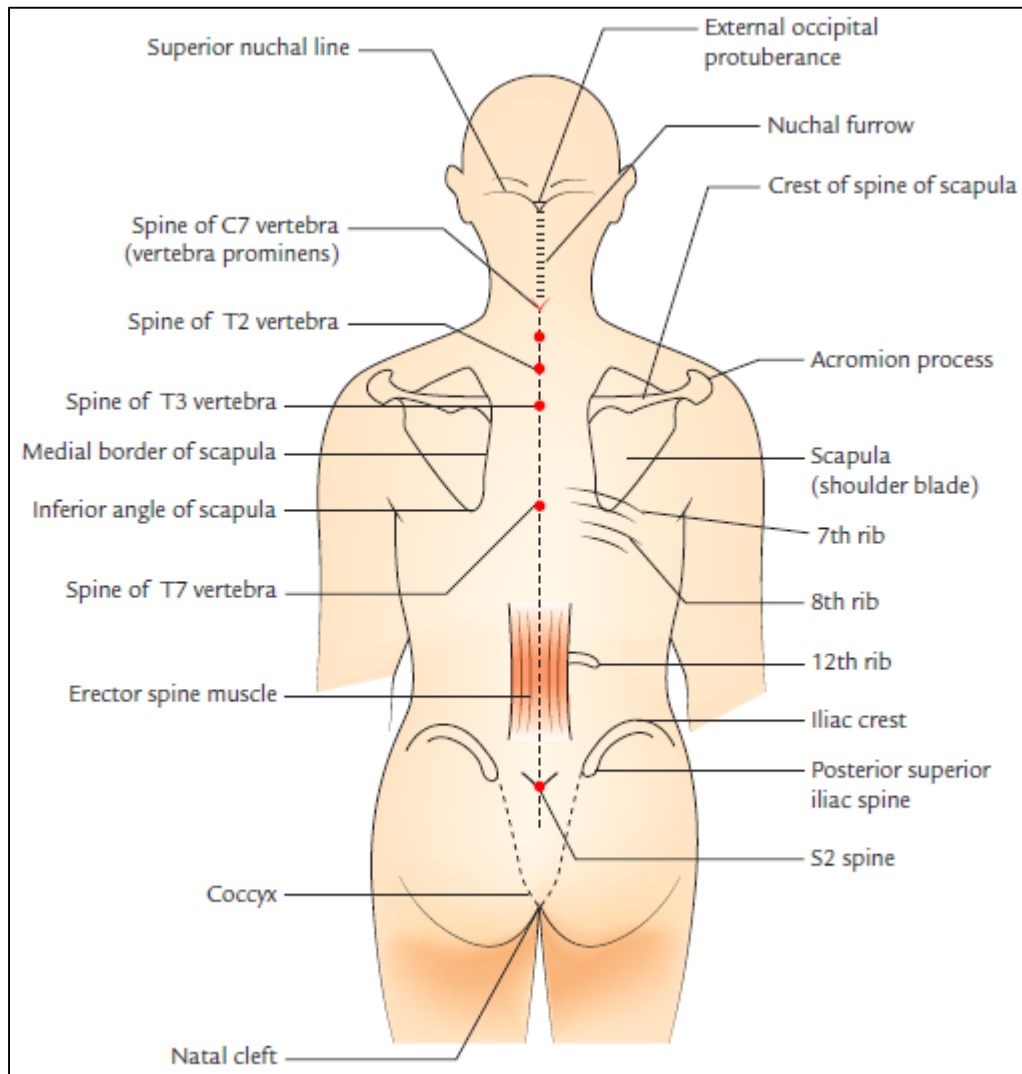


Figure 16: Surface landmarks of the back & scapular region.

### Muscles

Muscles attached to the scapula are divided into 2 groups [Figure 17]:

- **The axio-scapular muscles:** are seven muscles which arise from the trunk to be inserted to the scapula and move it. The posterior five muscles represent the superficial group of the back muscles. The anterior two muscles pass from the front and sides of the trunk to the scapula.

## Anatomy of the Upper Limb

- **The scapula-appendicular muscles:** are nine muscles that originate from the scapula to the arm or forearm to move the shoulder or elbow. One muscle; omohyoid; passes up the neck to depress the hyoid bone.

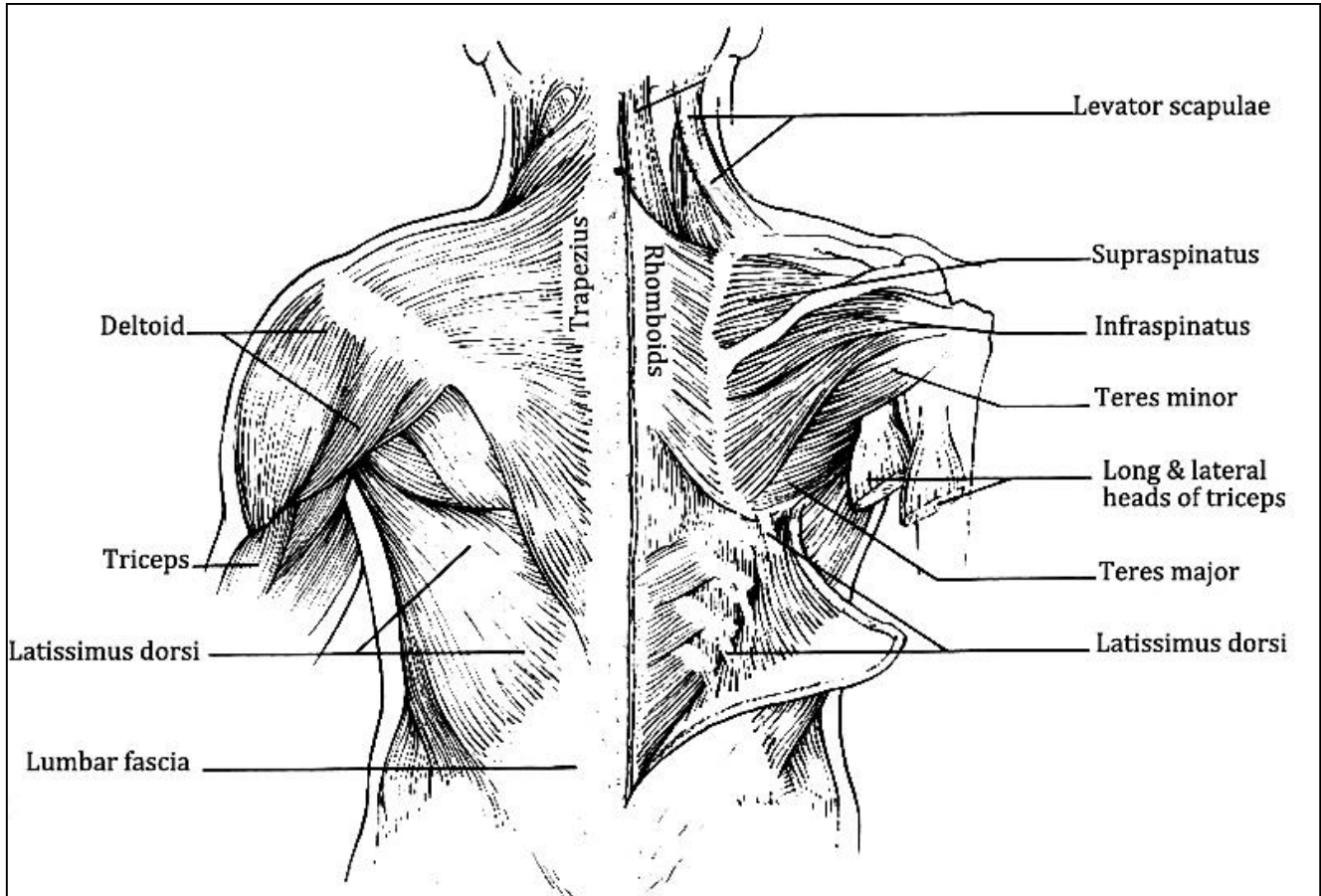


Figure 17: Muscles attached to the scapula.

## Anatomy of the Upper Limb

### The axio-scapular muscles

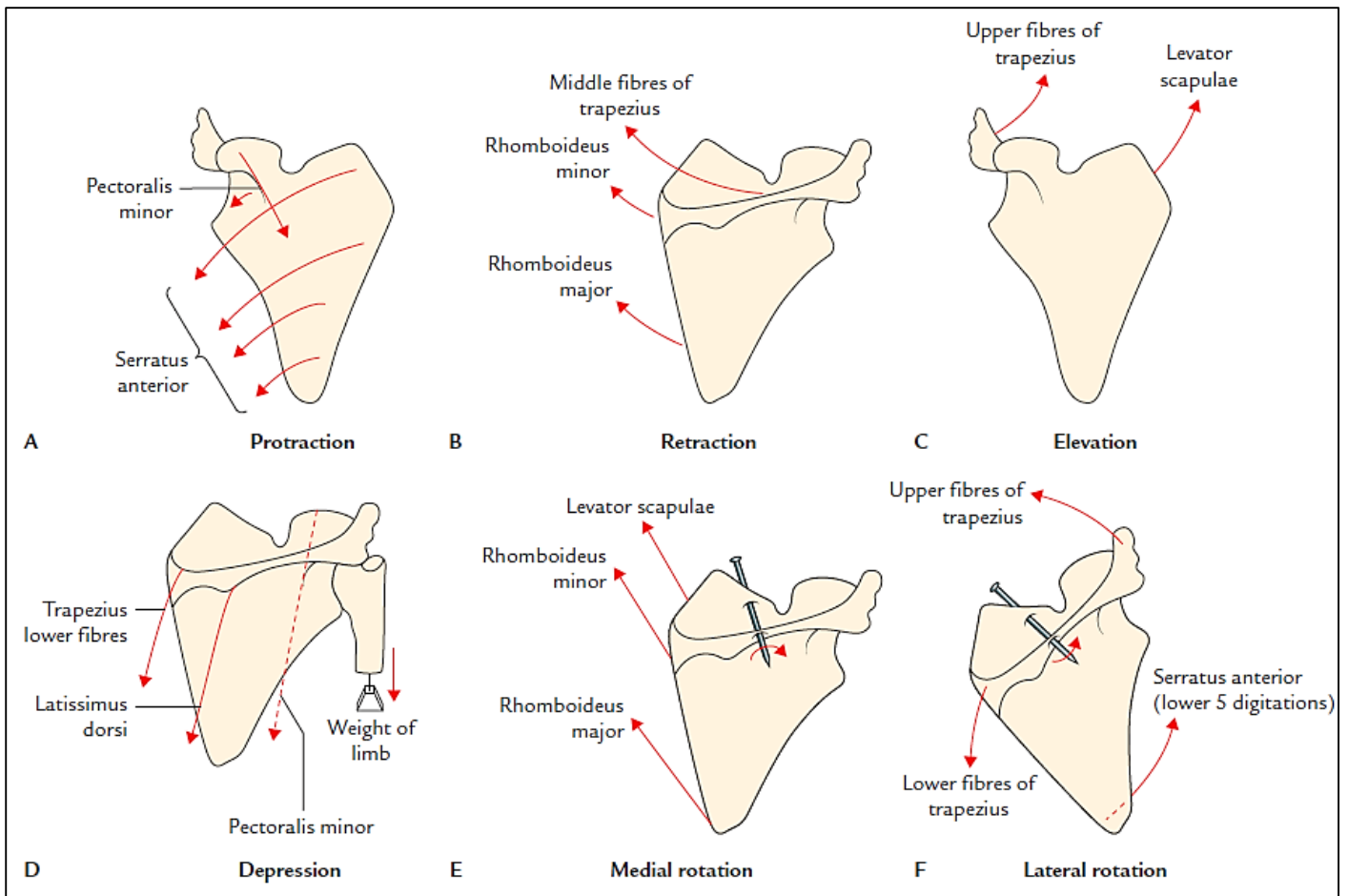
THE AXIO-SCAPULAR MUSCLES (MUSCLES INSERTED TO THE SCAPULA)				
Muscle	Origin	Insertion	Innervation	Action
<b>Trapezius</b>	Back of skull, ligamentum nuchae, spines of C7 to T12	Posterior border of lateral one-third of clavicle, inner margin of acromion, upper edge of spine of scapula	Accessory nerve (CN XI)	Upper fibers elevate, middle fibers retract, and lower fibers depress scapula; Upper+lower fibers cause lateral rotation of the scapula during abduction of shoulder above the horizontal plane
<b>Latissimus dorsi</b>	Spines of T6 to L5 and sacrum, iliac crest, ribs 10 to 12	Floor of bicipital groove of humerus Deep fibers: to inferior angle of scapula	Thoracodorsal nerve	Extends, adducts, and medially rotates shoulder; deep fibers depress & medially rotate the scapula
<b>Levator scapulae</b>	Transverse processes of C1 to C4	Medial border of scapula opposite the supraspinous fossa	Dorsal scapular nerve	Elevates & medially rotates scapula
<b>Rhomboid minor</b>	Lower portion of ligamentum nuchae, spines of C7 and T1	Medial border of scapula opposite the spine of scapula	Dorsal scapular nerve	Retracts and elevates scapula
<b>Rhomboid major</b>	Spines of T2 to T5	Medial border of scapula opposite the infraspinous fossa	Dorsal scapular nerve	Retracts & elevates scapula
<b>Pectoralis minor</b>	Anterior surfaces and superior borders of 3 <sup>rd</sup> -5 <sup>th</sup> ribs	Coracoid process of scapula	Medial pectoral nerve	Depresses & protracts scapula
<b>Serratus anterior</b>	Lateral surfaces of upper 8 ribs	Medial border of the costal surface of the scapula	Long thoracic nerve	Protraction & lateral rotation (lower 5 digits) of the scapula; keeps medial border and inferior angle of scapula opposed to thoracic wall

### *Movements of the scapula*

The scapula forms a **physiological joint** with the rib cage; the **scapulothoracic joint**; that permits the bone to slide on the thorax. Movements of the scapula **[Figure 18]** are produced by all the muscles inserted into it and by the sternocostal part of pectoralis major which depresses the clavicle and moves the scapula along.

## Anatomy of the Upper Limb

In **rotation**, the scapula rotates around an antero-posterior axis that passes through the center of the spine, if the inferior angle moves laterally the movement is lateral rotation, if it moves medially the movement is medial rotation.



**Figure 18: Movements of the scapula & the muscles producing them.**

MOVEMENTS OF THE SCAPULA			
Movement	Muscles	Movement	Muscles
<b>Elevation</b>	Levator scapulae Upper fibres of trapezius Rhomboid major Rhomboid minor	<b>Retraction</b>	Rhomboid major & minor Middle fibres of trapezius Latissimus dorsi
<b>Depression</b>	Pectoralis minor Lower fibres of trapezius Latissimus dorsi Sternocostal part of pectoralis major	<b>Lateral rotation</b>	Lower 5 digitations of serratus anterior Upper + lower fibres of trapezius
<b>Protraction</b>	Serratus anterior Pectoralis minor Sternocostal part of pectoralis major	<b>Medial rotation</b>	Rhomboid major & minor Levator scapulae Pectoralis minor Lower sternocostal part of pectoralis major Latissimus dorsi



## Anatomy of the Upper Limb

### The scapula-appendicular muscles

MUSCLES ORIGINATING FROM THE SCAPULA				
Muscle	Origin	Insertion	Innervation	Action
<b>Deltoid</b>	Lower edge of the spine of the scapula, outer margin of the acromion, anterior border of lateral one-third of clavicle	Deltoid tuberosity of humerus	Axillary nerve	Major abductor of shoulder; anterior fibers flex & medially rotate the shoulder; posterior fibers extend & laterally rotate the shoulder
<b>Supraspinatus</b>	The supra-spinous fossa of the scapula	Upper part of the greater tubercle of the humerus	Suprascapular nerve	Rotator cuff muscle; initiation of abduction of shoulder to 15°
<b>Infraspinatus</b>	The infra-spinous fossa of the scapula	Middle part on posterior surface of the greater tubercle of humerus	Suprascapular nerve	Rotator cuff muscle; lateral rotation of the shoulder joint
<b>Subscapularis</b>	Subscapular fossa of the scapula	Lesser tubercle of the humerus	Upper & lower subscapular nerves	Rotator cuff muscle; medial rotation of the shoulder joint
<b>Teres minor</b>	Upper two-thirds of the lateral border of the scapula	Lower part on the posterior surface of the greater tubercle of the humerus	Axillary nerve	Rotator cuff muscle; lateral rotation the shoulder joint
<b>Teres major</b>	Lower one-third of the lateral border of the scapula	Medial lip of the bicipital groove	Inferior subscapular nerve	Medial rotation and extension of shoulder joint
<b>Long head of triceps brachii</b>	Infraglenoid tubercle on scapula	Common tendon of insertion with medial and lateral heads on the olecranon process of ulna	Radial nerve	Extension of the elbow joint; accessory adductor and extensor of the shoulder, long head stabilizes shoulder
<b>Long head of biceps brachii</b>	Supraglenoid tubercle on scapula	Common tendon of insertion with short head on the radial tuberosity	Musculocutaneous nerve	Stabilizes shoulder, and with the short head it flexes elbow & supinates forearm in elbow flexion
<b>Coracobrachialis</b>	The tip of the coracoid process	The medial part of the humeral shaft tendon	Musculocutaneous nerve	Flex the shoulder joint

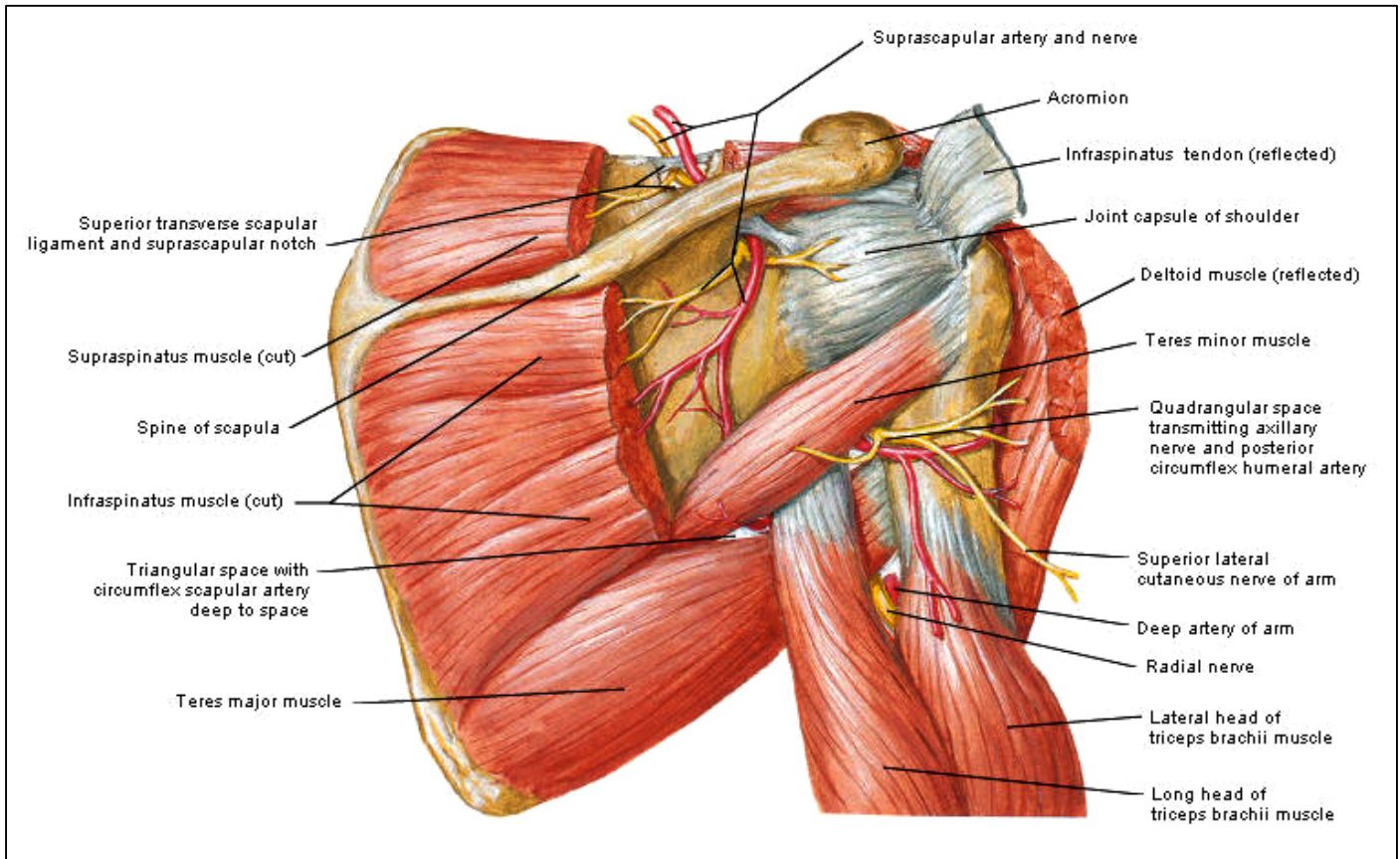
### *Spaces among the scapula-appendicular muscles [Figure.19]*

There are two spaces among the scapula-appendicular muscles:

- The **triangular space**; is bound by the long head of triceps laterally, teres minor superiorly and teres major inferiorly. It transmits the circumflex scapular artery.

## Anatomy of the Upper Limb

- The **quadrangular space**; lies lateral to the triangular space and is bound by the lower border of subscapularis (and teres minor) superiorly, the long head of triceps medially, teres major inferiorly and the surgical neck of the humerus laterally. It transmits the posterior circumflex humeral artery and the posterior division of the axillary nerve.



**Figure 19: Spaces among the scapula-appendicular muscles.**

### *The rotator cuff muscles*

The rotator cuff is the name given to the tendons of supraspinatus, infraspinatus, teres minor, and subscapularis which are fused with the underlying capsule of the glenohumeral joint. Tendon of supraspinatus fuse superiorly, tendons of infraspinatus and teres minor fuse posteriorly, and that of subscapularis fuse anteriorly. This cuff plays an important role in stabilizing the shoulder joint. *The primary function of rotator cuff muscles is to grasp the relatively large head of humerus and hold it against the smaller, shallow glenoid cavity*

### The Axilla

#### Shape & Boundaries

The axilla (armpit) is a fat-filled pyramidal space at the root of the upper limb created by the convergence of muscles from the anterior surface of the thorax and from the scapula towards the humerus leaving the axilla between the muscle groups and the lateral thoracic wall. When the arm is adducted the axilla is a narrow space but it increases in size as the arm is abducted. The axilla serves as a passage way (cervico-axillary canal) for structures passing between upper limb and neck.

Considered a 4-sided pyramid, the axilla has an apex, base and 4 walls [**Figure 20**]:

- The **apex** is bound by the clavicle anteriorly, the outer border of the first rib medially and the upper border of the scapula laterally.
- The **base** (floor) is formed by the skin stretched between the anterior and posterior axillary folds. The **anterior axillary fold** is formed by the lower border of pectoralis major muscle while the **posterior axillary fold** is formed by the lower border of teres major and the tendon of latissimus dorsi.
- The **anterior wall** is formed by the pectoralis major, pectoralis minor and subclavius muscles with their enclosing fascia.
- The **posterior wall** is formed by the lateral border of the scapula with subscapularis, teres major and latissimus dorsi muscles.
- The **medial wall** is formed by the convexity of the upper 5 ribs and their intercostal spaces covered by the upper digitations of serratus anterior muscle.
- The **lateral wall** is formed by the humerus with biceps brachii and coracobrachialis muscles.

## Anatomy of the Upper Limb

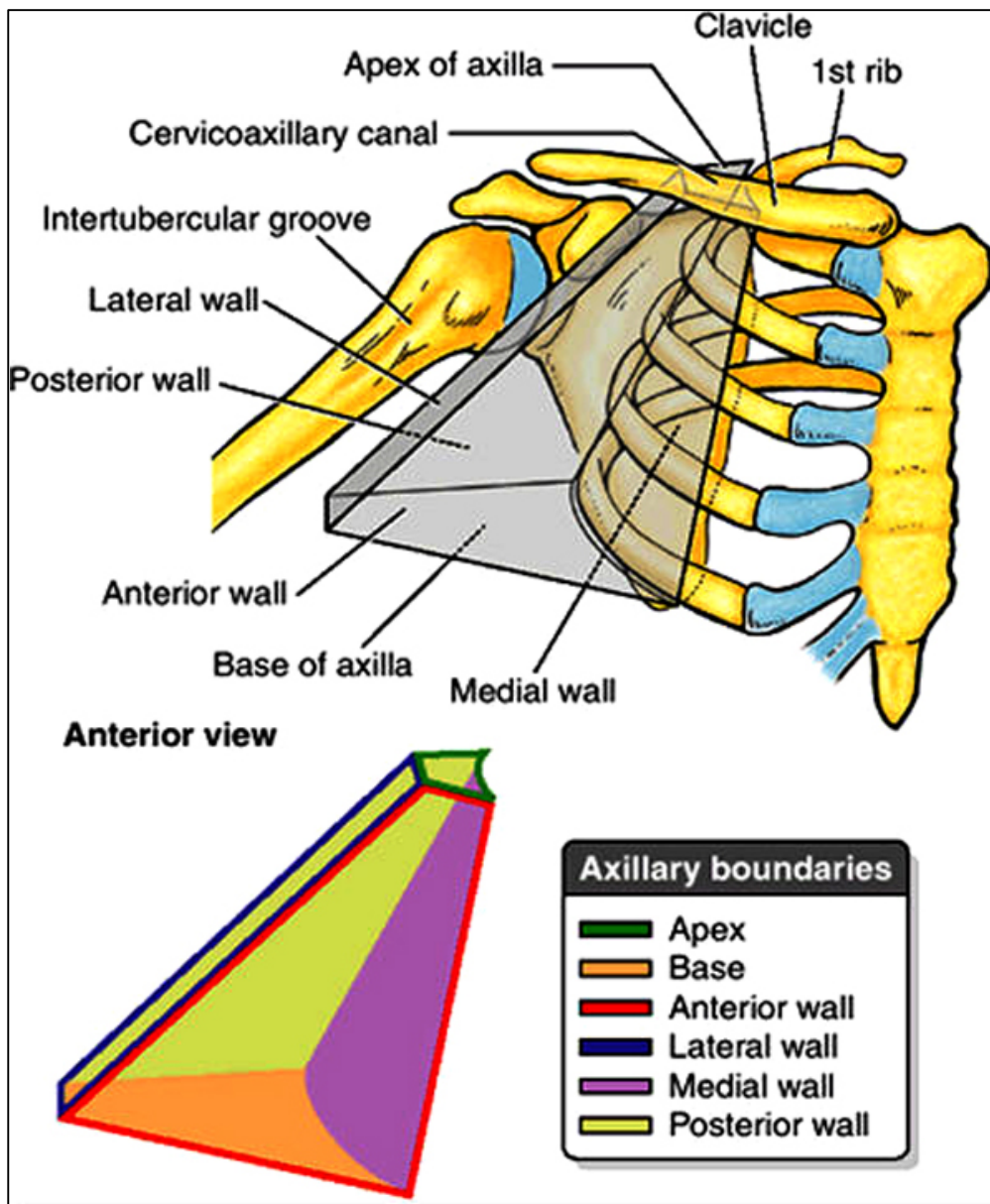


Figure 20: Boundaries of the axilla.

### Contents of the axilla

1. The axillary vessels.
2. The cords and branches of the brachial plexus.
3. The axillary lymph nodes.
4. Axillary fascia and fatty tissue.

## Anatomy of the Upper Limb

### The axillary artery [Figure.21]

#### Course

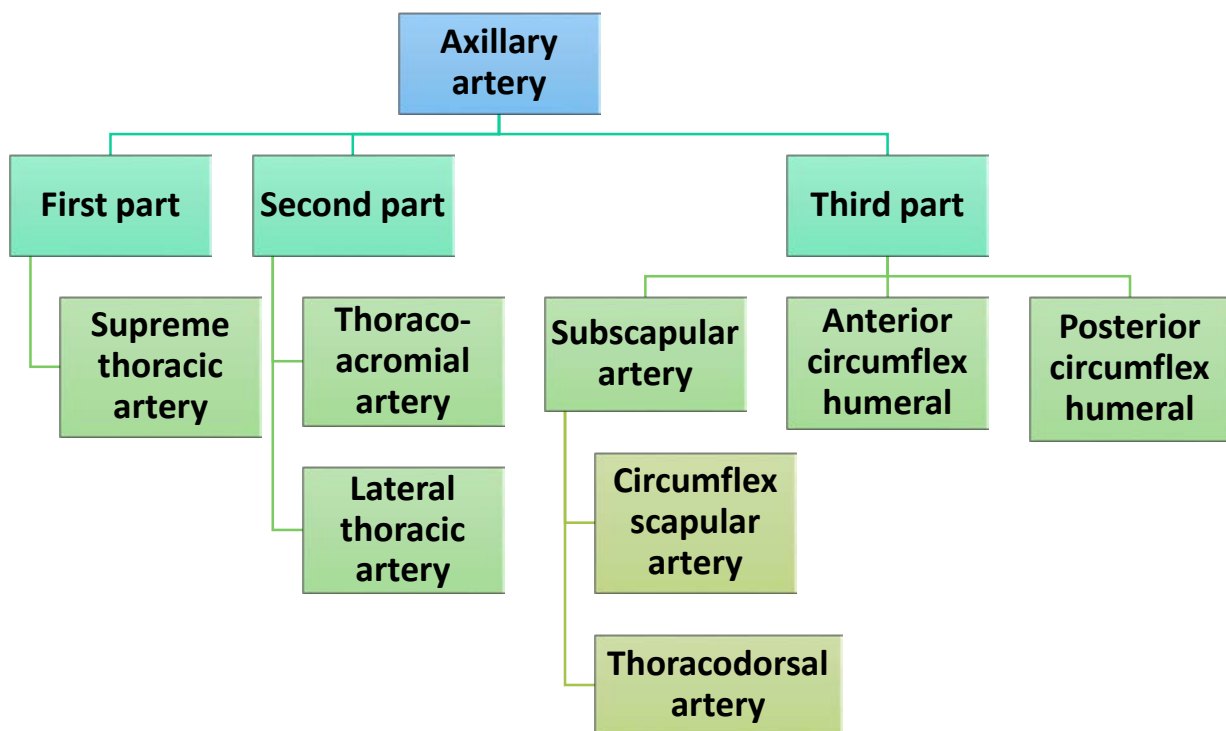
The axillary artery begins at the outer border of the first rib as the continuation of the subclavian artery and passes through the axilla to end at the lower border of teres major muscle and become the brachial artery. For descriptive reasons it is divided by the pectoralis minor tendon into 3 parts. The first part lies between the outer border of the first rib and the upper border of pectoralis minor muscle. The second part lies behind pectoralis minor. The third part lies between the lower border of pectoralis minor and lower border of teres major muscles.

#### Important relations

- Pectoralis minor lies anterior to the second part while pectoralis major covers the whole artery anteriorly.
- The axillary vein lies along the medial side of all parts.
- The cephalic vein crosses the first part anteriorly.
- The cords of the brachial plexus arrange around the 2<sup>nd</sup> part according to their names.

#### Branches

The first part gives one branch, the second gives two and the third part gives three branches;



### In the lab

To identify the branches of the axillary artery remember that:

- ✓ The supreme thoracic artery arises from the axillary artery proximal to pectoralis minor.
- ✓ The thoracoacromial & lateral thoracic arteries arise posterior to pectoralis minor but, the thoracoacromial appears on its proximal border while the lateral thoracic artery appears on its distal border. The thoracoacromial artery is larger and gives more branches. The lateral thoracic artery is longer.
- ✓ The circumflex scapular artery passes through the triangular space from the dorsal scapular artery while the thoracodorsal artery descends downwards from it.
- ✓ The circumflex humeral arteries encircle the surgical neck of the humerus.

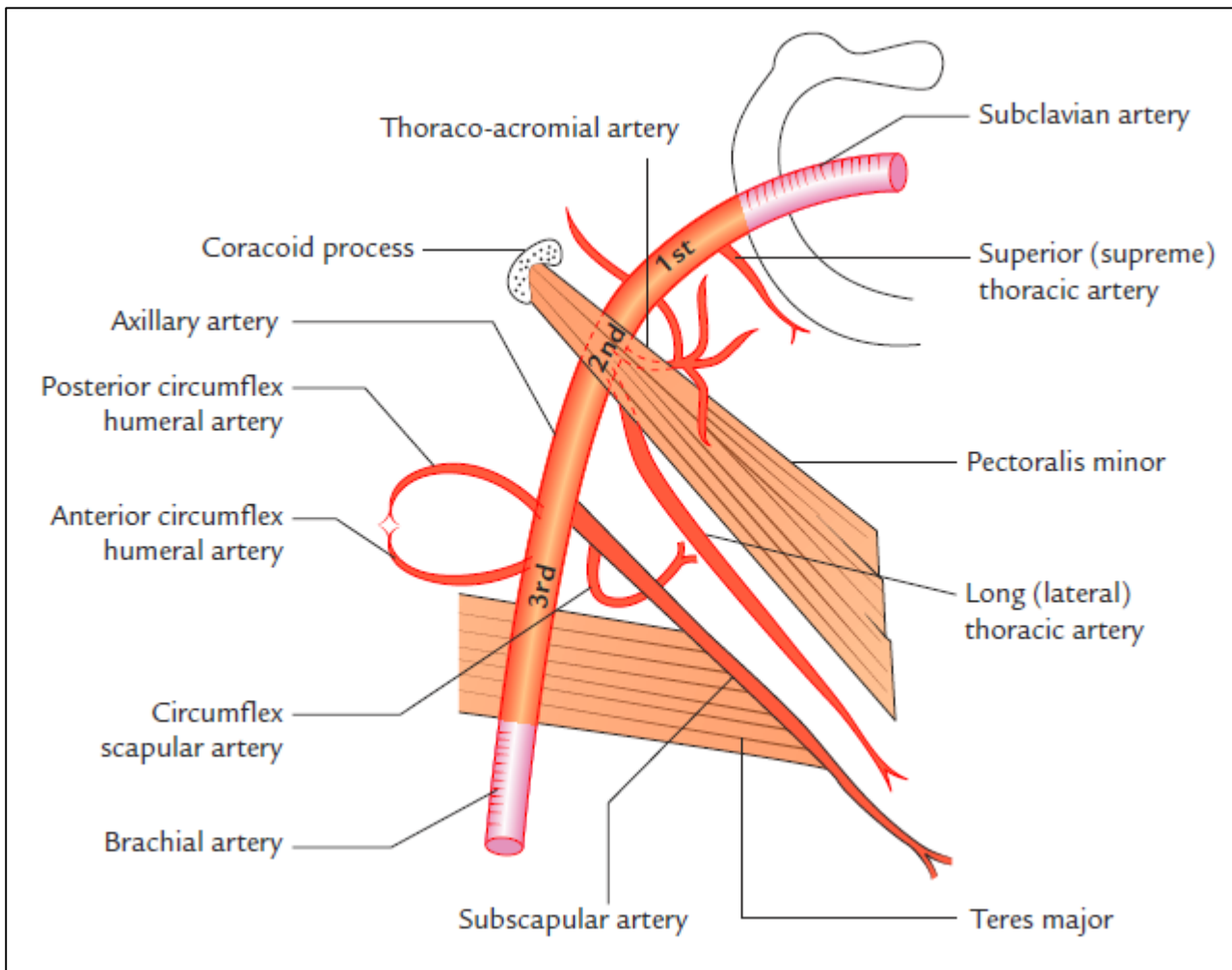


Figure 21: The axillary artery & its branches.

## Anatomy of the Upper Limb

### *Arterial anastomoses around the scapula* [Figure.22]

The scapular anastomosis takes place at two sites: around the body of scapula and over the acromion process of the scapula.

**1. Around the body of scapula:** It occurs between 4 arteries; two from the third part of the axillary artery & two from the first part of the subclavian artery:

(a) suprascapular artery & deep branch of the transverse cervical artery are branches of the thyrocervical trunk from the first part of the subclavian artery,

(b) circumflex scapular & thoracodorsal arteries are branches of the subscapular artery from the third part of the axillary artery.

**2. Over the acromion process:** It occurs between 3 arteries:

(a) acromial branch of the thoraco-acromial artery.

(b) acromial branch of the suprascapular artery.

(c) acromial branch of the posterior circumflex humeral.

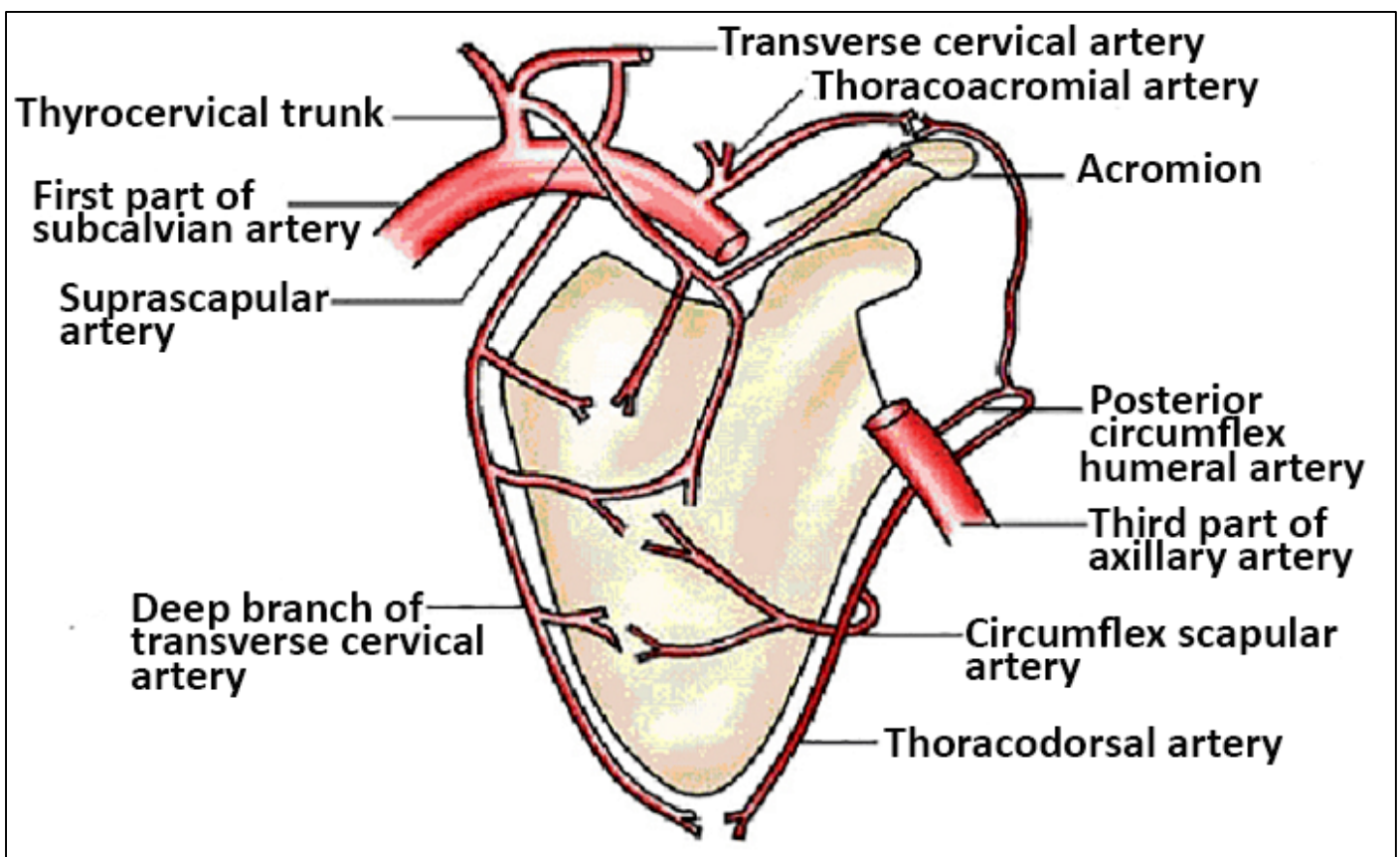


Figure 22: The scapular anastomosis.

## Anatomy of the Upper Limb

### *Arterial anastomoses around the shoulder joint*

This anastomosis formed by the anterior and posterior circumflex humeral branches of the third part of the axillary artery with the suprascapular artery and recurrent branch of the profunda brachii artery around the surgical neck of the humerus. It is responsible for supplying the proximal part of the humerus and surrounding muscles and the shoulder joint.

### The axillary vein

The axillary vein begins at the lower border of teres major muscle by the union of the venae comitantes of the brachial artery with the basilic vein and runs up the axilla along the medial side of the axillary artery to end at the outer border of the 1<sup>st</sup> rib by becoming the subclavian vein. It receives tributaries that correspond to the branches of the axillary artery, but in addition it receives the **cephalic vein** near its end and the **basilic vein** at its beginning.

### The axillary lymph nodes

The axillary lymph nodes are scattered in the fibrofatty tissue of the axilla. Their number varies between 20 and 30. They are divided into 6 groups.

### THE AXILLARY LYMPH NODES

Group	Location	Afferent area	Efferent to
<b>Anterior (Pectoral)</b>	Along the lateral thoracic vein at the lower border of pectoralis minor	Most of the breast, anterolateral part of the chest & the anterior abdominal wall down to the level of (& including) the umbilicus	Central nodes
<b>Posterior (Subscapular)</b>	On the posterior axillary fold along the subscapular vein	The back down to the level of the iliac crest	Central nodes
<b>Lateral (Humeral)</b>	On the upper part of the humerus along the axillary vein	The whole upper limb except superficial vessels draining the lateral side	Central nodes
<b>Central</b>	In the center of the axilla in the axillary fat	Anterior, posterior & lateral groups	Apical nodes
<b>Infraclavicular (Deltopectoral)</b>	Groove between deltoid & pectoralis major, outside the axilla	Superficial vessels draining the lateral side of the upper limb	Apical nodes
<b>Apical</b>	At the apex of the axilla along the axillary vein, on the outer border of the first rib	Upper part of breast & all other groups	Subclavian lymph trunk (right) & thoracic duct (left)



### The brachial plexus [Figure.23]

The brachial plexus is a plait of nerves formed in the neck by the ventral rami of C5, C6, C7, C8 and T1 spinal nerves with small contribution from C4 and T2. The ventral rami represent the roots of the plexus.

C5 and C6 roots unite to form the upper trunk, C7 root continues alone as the middle trunk while C8 and T1 roots unite to form the lower trunk. Each trunk then divides into an anterior and a posterior division.

The anterior divisions of the upper and middle trunks unite to form the lateral cord while the anterior division of the lower trunk continues alone as the medial cord. The posterior divisions of all three trunks unite to form the posterior cord.

Each cord then gives a number of branches which either supply structures in the pectoral region and axilla, or continue down the upper limb to supply its structures (terminal branches).

The root value of any branch can be traced back to its origin by knowing the arrangement of the plexus. Branches may arise from the roots, trunks or cords.

The roots and trunks of the brachial plexus lie in the neck above the level of the clavicle and represent the **supraclavicular part** of the plexus. The divisions are located posterior to the clavicle and represent the **retroclavicular part**. The cords and their branches are the parts of the brachial plexus that lie in the axilla around the axillary artery. They lie below the level of the clavicle and thus represent the **infraclavicular part** of the plexus.

## Anatomy of the Upper Limb

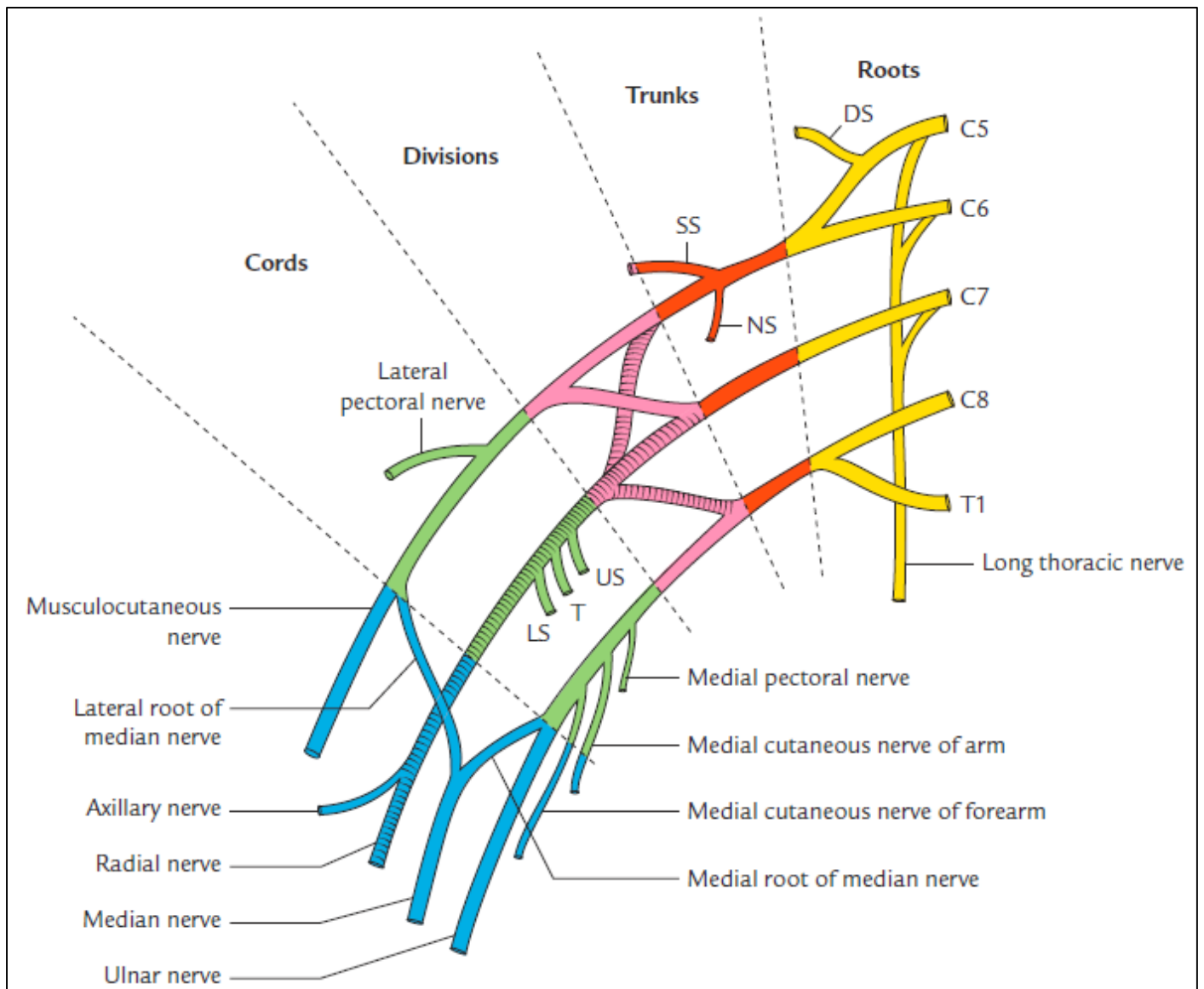
### Branches of the brachial plexus

Source	Branch (nerve)	Root value	Structures supplied by the nerve	
<b>Branches from the roots</b>	Dorsal scapular	C5	Levator scapulae, Rhomboid major & Rhomboid minor	
	Long thoracic	C5,C6,C7	Serratus anterior	
<b>Branches from the upper trunk</b>	Suprascapular	C5,C6	Supraspinatus, Infraspinatus + articular branches to the shoulder & acromioclavicular joints	
	Nerve to subclavius	C5,C6	Subclavius & sternoclavicular joint	
<b>Branches from the Cords</b>	<b>Lateral cord</b>	Lateral pectoral	C5,C6,C7	Pectoralis major
		Musculocutaneous	C5,C6,C7	Biceps, brachialis, Coracobrachialis & continues as the lateral cutaneous nerve of the forearm
		Lateral root of the median nerve	C5,C6,C7	Unites with the medial root to form the median nerve
	<b>Medial cord</b>	Medial pectoral	C8,T1	Pectoralis major & minor
		Medial cutaneous nerve of the arm	C8,T1,T2	Skin of the lower ½ of the medial side of the arm
		Medial cutaneous nerve of the forearm	C8,T1	Skin of medial ½ of forearm
		Ulnar	C7,C8,T1	Skin & small muscles of the hand
		Medial root of the median nerve	C8, T1	Unites with the lateral root to form the median nerve
	<b>Posterior cord</b>	Upper subscapular	C5,C6	Upper fibers of subscapularis
		Lower subscapular	C5,C6	Lower fibers of subscapularis , Teres major
		Thoracodorsal	C6,C7,C8	Latissimus dorsi
		Axillary	C5,C6	Deltoid, teres minor, shoulder joint and skin over the lower ½ of deltoid
		Radial	C5 - T1	Muscles & skin of the posterior aspect of the upper limb

The lateral cutaneous branch of the ventral ramus of T2 spinal nerve is called the intercostobrachial nerve. It communicates with the lower trunk of the plexus to reach the medial cutaneous nerve of the arm. Therefore, the medial cutaneous nerve of the arm has a root value of C8, T1 and T2. The intercostobrachial nerve runs through the central axillary lymph nodes.

The lateral root of the median nerve transmits nerve fibers from the C7 ventral ramus across the medial root of the median nerve to reach the ulnar nerve. That is why the ulnar nerve has a root value of C7, C8 and T1.

## Anatomy of the Upper Limb



**Figure 23: Arrangement of the brachial plexus. (Ds: dorsal scapular, NS: nerve to subclavius, LS: lower subscapular, T: thoracodorsal, US: upper subscapular)**

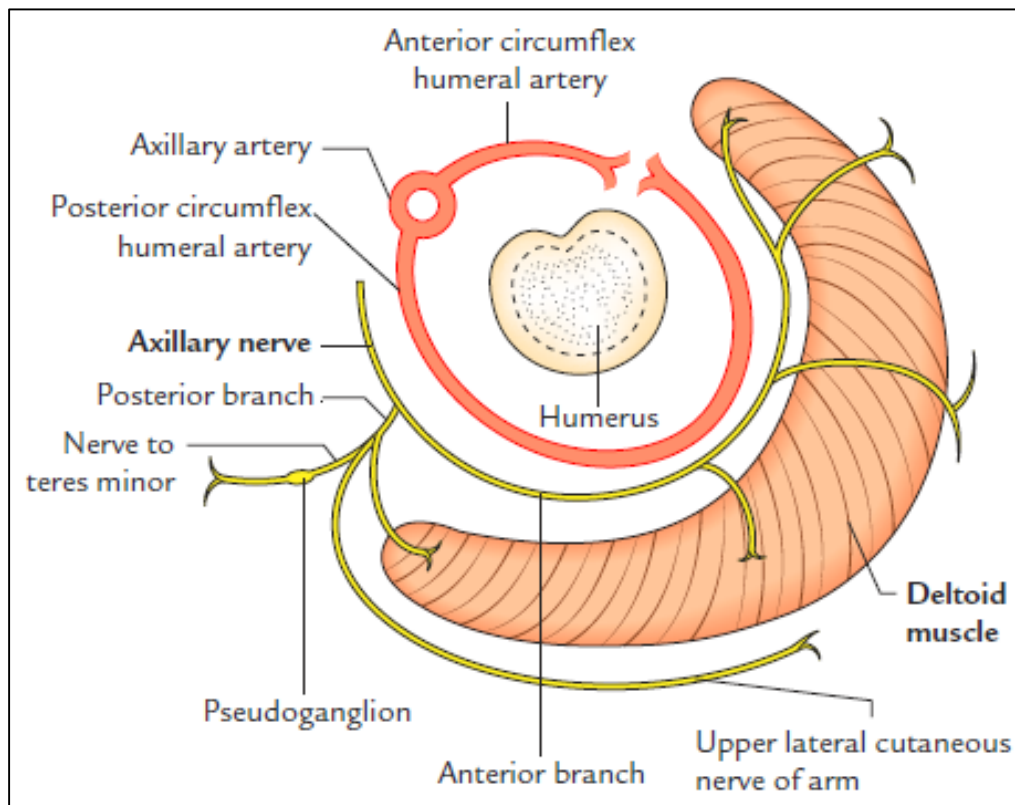
### In the lab

To identify the parts & branches of the brachial plexus remember that:

- ✓ The roots & trunks and their branches lie above the level of the clavicle:
  - The long thoracic nerve is seen running vertically on serratus anterior.
  - The dorsal scapular nerve passes horizontally backwards deep to levator scapulae.
  - The suprascapular nerve passes posterolaterally above the suprascapular ligament to reach supraspinatus, then passes through the spinoglenoid notch towards infraspinatus.
- ✓ The cords of the brachial plexus are arranged around the second part of the axillary artery according to their name.

### In the lab (Contd.)

- ✓ The terminal branches of the plexus can be identified by the  $\Sigma$  shaped arrangement:
  - The upper limb of the  $\Sigma$  is the musculocutaneous nerve piercing coracobrachialis .
  - The center of the  $\Sigma$  is the median nerve formed by the medial & lateral roots. The median nerve runs lateral to the third part of the axillary artery.
  - The lower limb of the  $\Sigma$  is the ulnar nerve running medial to the third part of the axillary artery. The medial cutaneous nerves of the arm & forearm run medial to the axillary vein.
- ✓ The branches of the posterior cord lie behind the axillary artery:
  - The upper & lower subscapular arteries run on the anterior surface of subscapularis but only the lower subscapular artery reaches teres major.
  - The thoracodorsal nerve runs along the lateral border of the scapula on latissimus dorsi.
  - The axillary nerve passes through the quadrangular space close to the surgical neck of the humerus **[Figure.24]**. Here it divides into two branches: the anterior branch runs with the posterior circumflex humeral artery deep to deltoid to supply most of deltoid, the posterior branch supplies teres minor and then continues superficial to deltoid as the upper lateral cutaneous nerve of the arm.
  - The radial nerve is the largest branch of the posterior cord. It runs behind the third part of the axillary artery to the back of the arm



**Figure 24: The axillary nerve as seen in cross section at the level of the surgical neck of the humerus.**

### Joints of the Shoulder Girdle

The shoulder joint complex consists of three anatomical joints and one functional joint. These are the sternoclavicular joint, acromioclavicular joint, shoulder (glenohumeral) joint and the functional scapulothoracic joint.

#### The sternoclavicular joint [Figure.25]

##### Type and articulation

This is a synovial **double plane** joint formed by the articulation between the medial end of the clavicle with the superolateral angle of the manubrium sterni and the upper surface of the first costal cartilage. Its cavity is divided into two parts by the **articular disc**. Though anatomically it is a plane joint, it functions like a ball-and-socket joint because of the double cavity.

##### The fibrous capsule and ligaments

- The **fibrous capsule** is attached to the margins of the articular surfaces.
- The **anterior and posterior sternoclavicular ligaments**; are thickenings of the capsule on the anterior and posterior aspects of the joint.
- The **costoclavicular ligament**; passes from the first costal cartilage to the inferior surface of the medial part of the clavicle.
- The **interclavicular ligament**; lies between and connects the 2 sternal ends of the right and left clavicles.
- The **articular disc**; is a flat, nearly circular fibrocartilagenous plate attached at its margins to the interior of the fibrous capsule. It is also strongly attached to the upper edge of the articular surface of the clavicle superiorly and to the first costal cartilage inferiorly. The disc holds the clavicle down and assists in preventing its upward displacement. It also acts as a cushion or shock absorbent for the clavicle as it hammers against the manubrium sterni with each movement of the upper limb.

##### The synovial membrane

This lines the fibrous capsule and both sides of the articular disc. The articular disc thus separates two synovial cavities.

## Anatomy of the Upper Limb

### Movements

- **Forward gliding** is associated with protraction of the scapula mainly produced by **serratus anterior** muscle.
- **Backward gliding** is associated with retraction of the scapula mainly produced by **trapezius** and the **rhomboid** muscles.
- **Elevation** is produced by **trapezius, sternocleidomastoid, levator scapulae** and the the **rhomboid** muscles.
- **Depression** is produced by **subclavius** and **pectoralis minor** muscles.

### Nerve and arterial supply

- Articular nerve branches arise from the medial pectoral nerve and the nerve to subclavius.
- Arterial branches arise from the internal thoracic and suprascapular arteries.

### Relations

- **Anteriorly**; skin, superficial fascia and some fibers of pectoralis major.
- **Posteriorly**; sternohyoid and sternothyroid muscles and the great vessels of the neck.

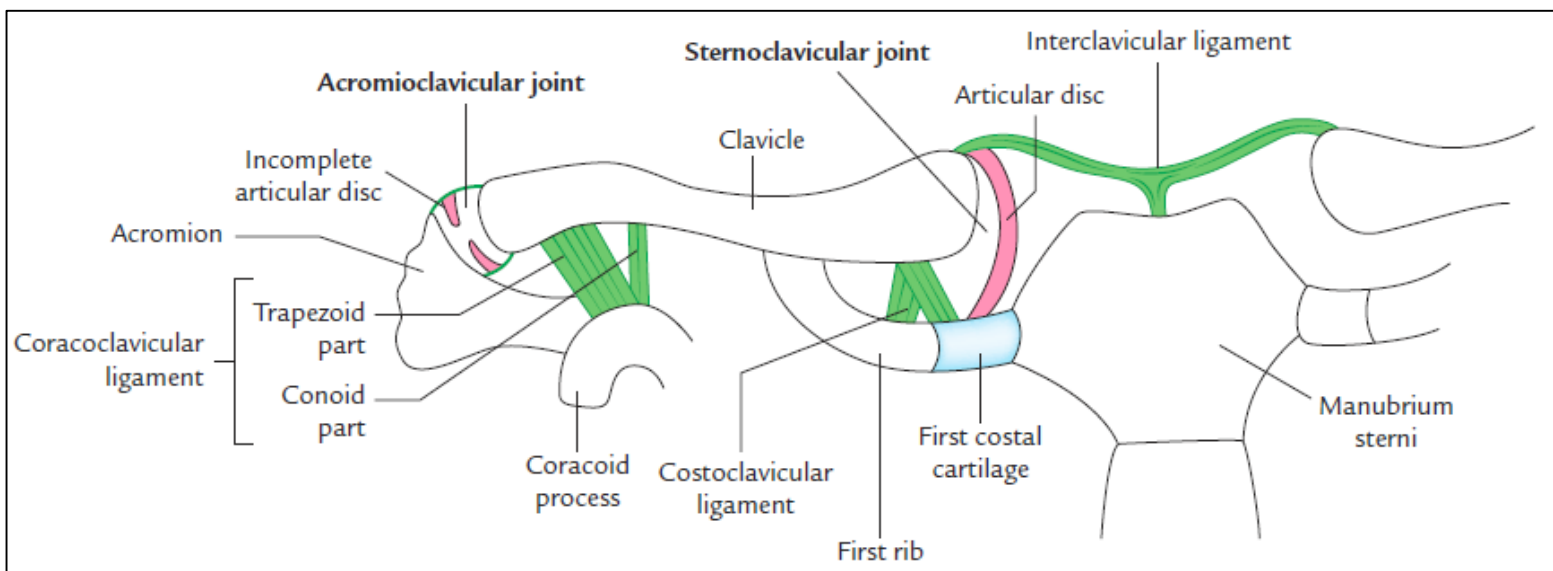


Figure 25: The sternoclavicular & acromioclavicular joints.

### The acromioclavicular joint

#### Type & articulation

The acromioclavicular joint is a plane synovial joint between the medial surface of the acromion and the acromial end of the clavicle. It allows gliding movement in the anteroposterior and vertical planes together with some axial rotation.

## Anatomy of the Upper Limb

---

### The fibrous capsule & ligaments

The fibrous capsule of the joint surrounds the articular surfaces and is reinforced by two ligaments.

- A small **acromioclavicular ligament** superior to the joint; passes between adjacent regions of the clavicle and acromion.
- A much larger **coracoclavicular ligament** which is composed of conoid & trapezoid parts. It is strongest ligament of the upper limb, providing much of the weight bearing support for the upper limb on the clavicle and maintaining the position of the clavicle on the acromion. *Further support to the superior aspect of the acromioclavicular joint is provided by the insertion of trapezius muscle to the clavicle and acromion. The tone of the muscle holds the bones in position and prevents them from falling down under the weight of the upper limb.*

### Movements

The acromioclavicular joint permits the rotation of acromion of scapula at the acromial end of the clavicle. These movements are associated with movements of scapula at the scapulothoracic joint.

### The shoulder (glenohumeral) joint

#### Type & articulation

The shoulder joint is a synovial ball-and-socket joint formed by the articulation between the head of the humerus and the glenoid cavity of the scapula. The joint is relatively made unstable by two factors;

- The **shallowness of the glenoid cavity** in comparison to the large size of the humeral head. This is compensated by the presence of the glenoid labrum which is a fibrocartilaginous rim that is attached to the edge of the glenoid fossa and increases its depth, assuring better fitness of the humeral head into the fossa.
- The **lax articular capsule and weak ligaments**. This is compensated by the presence of the stabilizing muscle bulk around the joint represented by the four rotator cuff muscles (supraspinatus, infraspinatus, teres minor and subscapularis) assisted by the long heads of Biceps and Triceps.

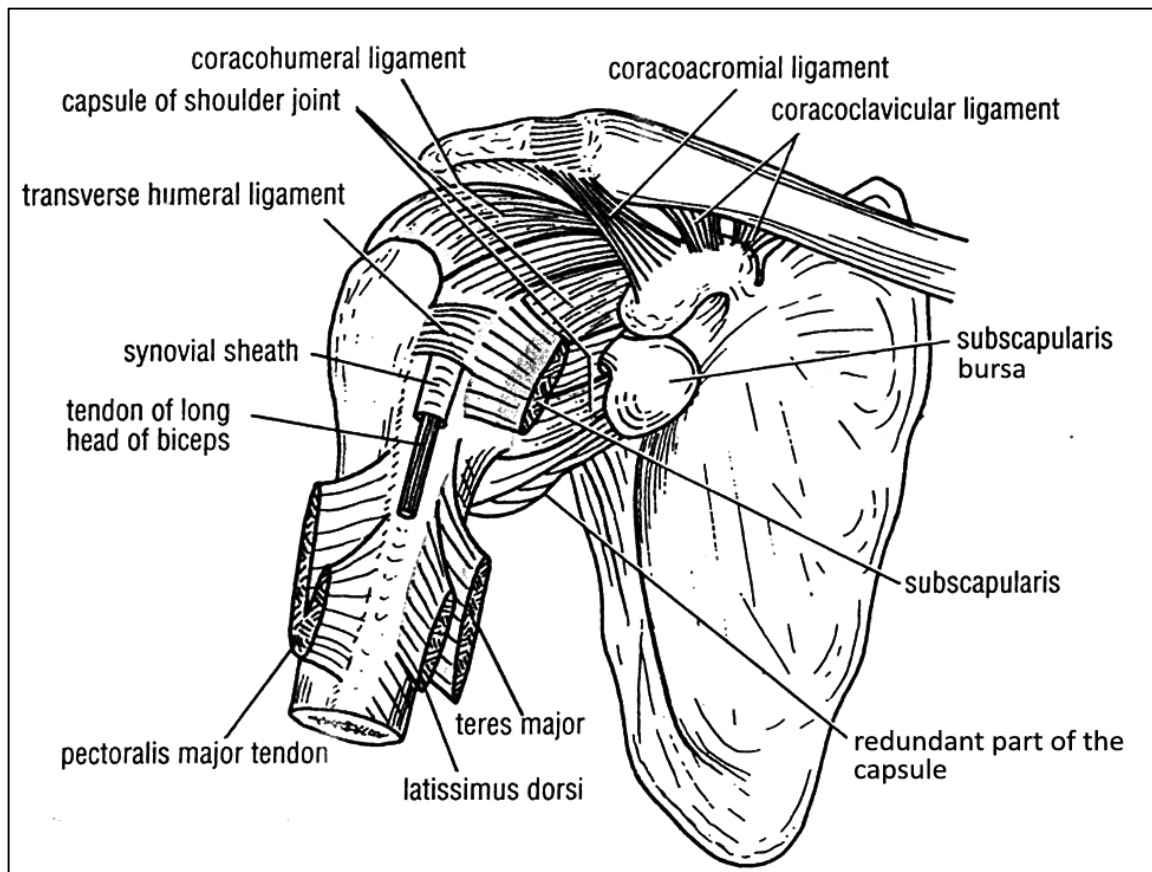


Figure 26: The capsule & ligaments of the right shoulder joint (anterior view)

### The fibrous capsule and ligaments [Figure 26]

- The **fibrous capsule** is attached to the margins of the glenoid cavity medially and the anatomical neck of the humerus laterally. When the shoulder is adducted, the capsule extends inferiorly on the medial aspect of the surgical neck of the humerus for a 1.5 cm distance as the **redundant part**. This part gets stretched during abduction. The capsule has three apertures:
- The **glenohumeral ligaments**, superior; middle and inferior, are three weak thickenings of the anterior surface of the capsule. There is a gap between the superior & middle glenohumeral ligaments.
- The **coracohumeral ligament**; is a strong thickening of the superior surface of the capsule extending from the base of the coracoid process to the greater tubercle of the humerus.
- The **transverse humeral ligament**; is an accessory ligament that bridges the upper part of the bicipital groove between the tubercles, over the long head of biceps as it passes out of the joint.