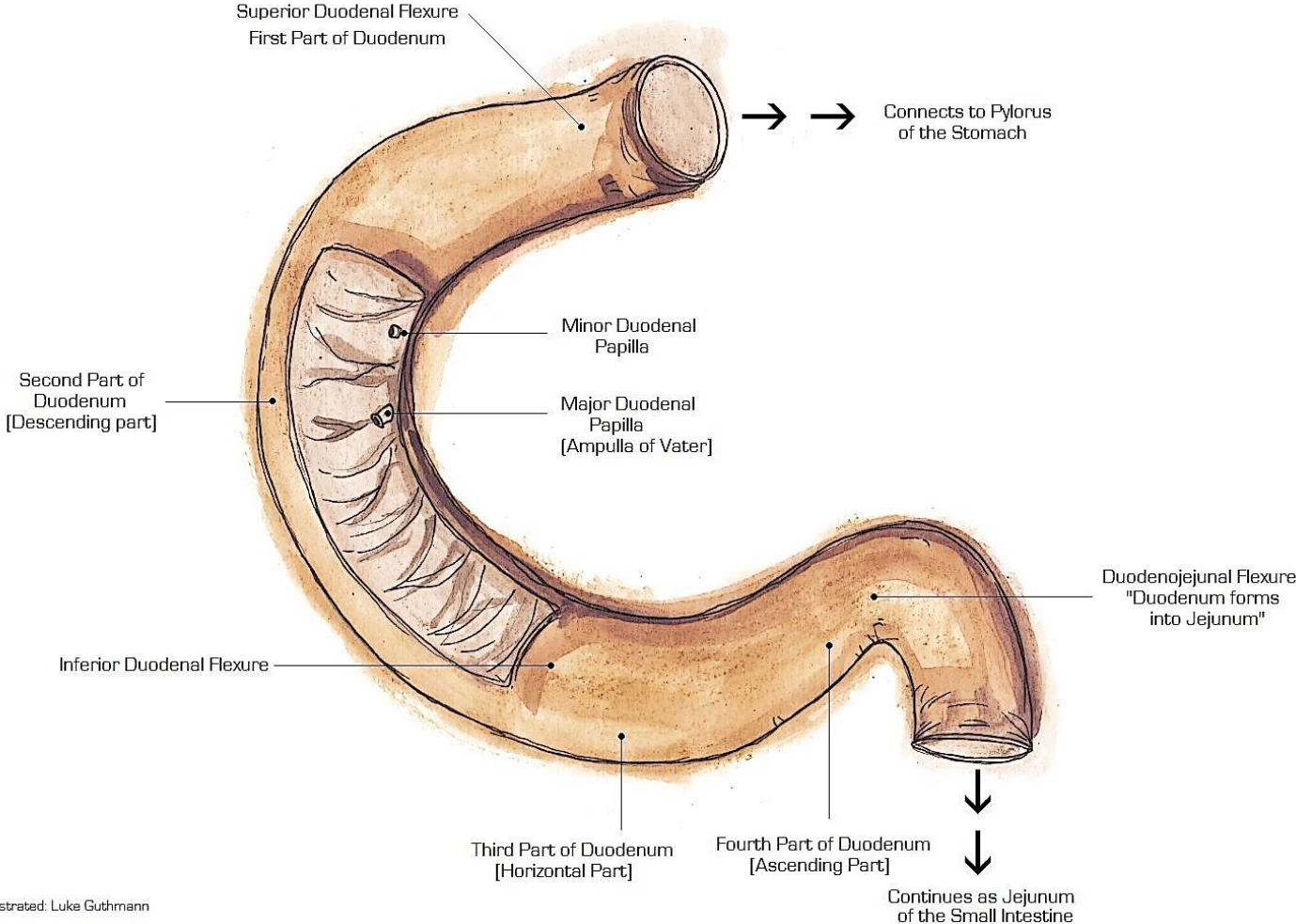


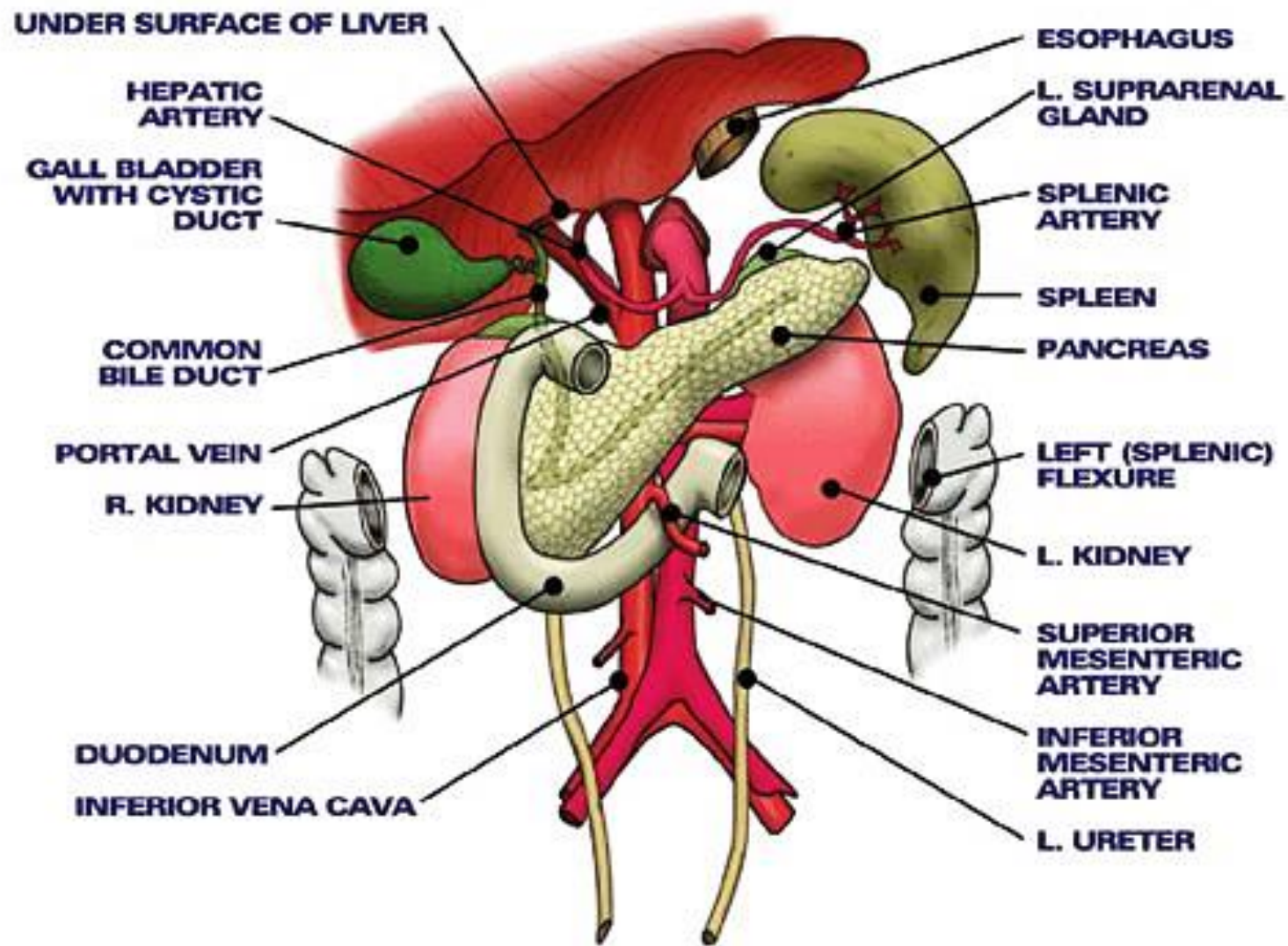
THE INTESTINES

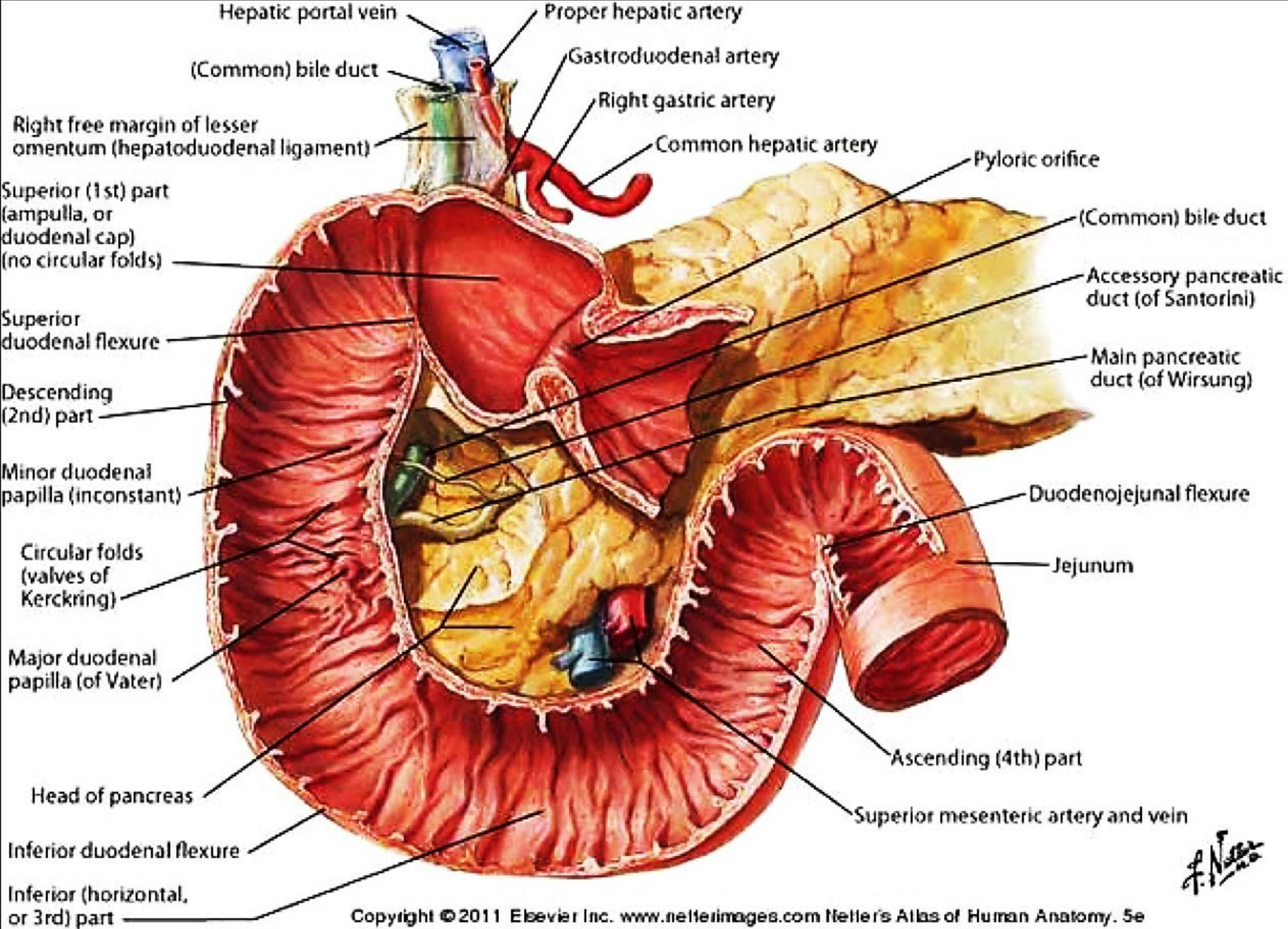
Dr Maan Al-Abbasi, PhD MD

The Duodenum

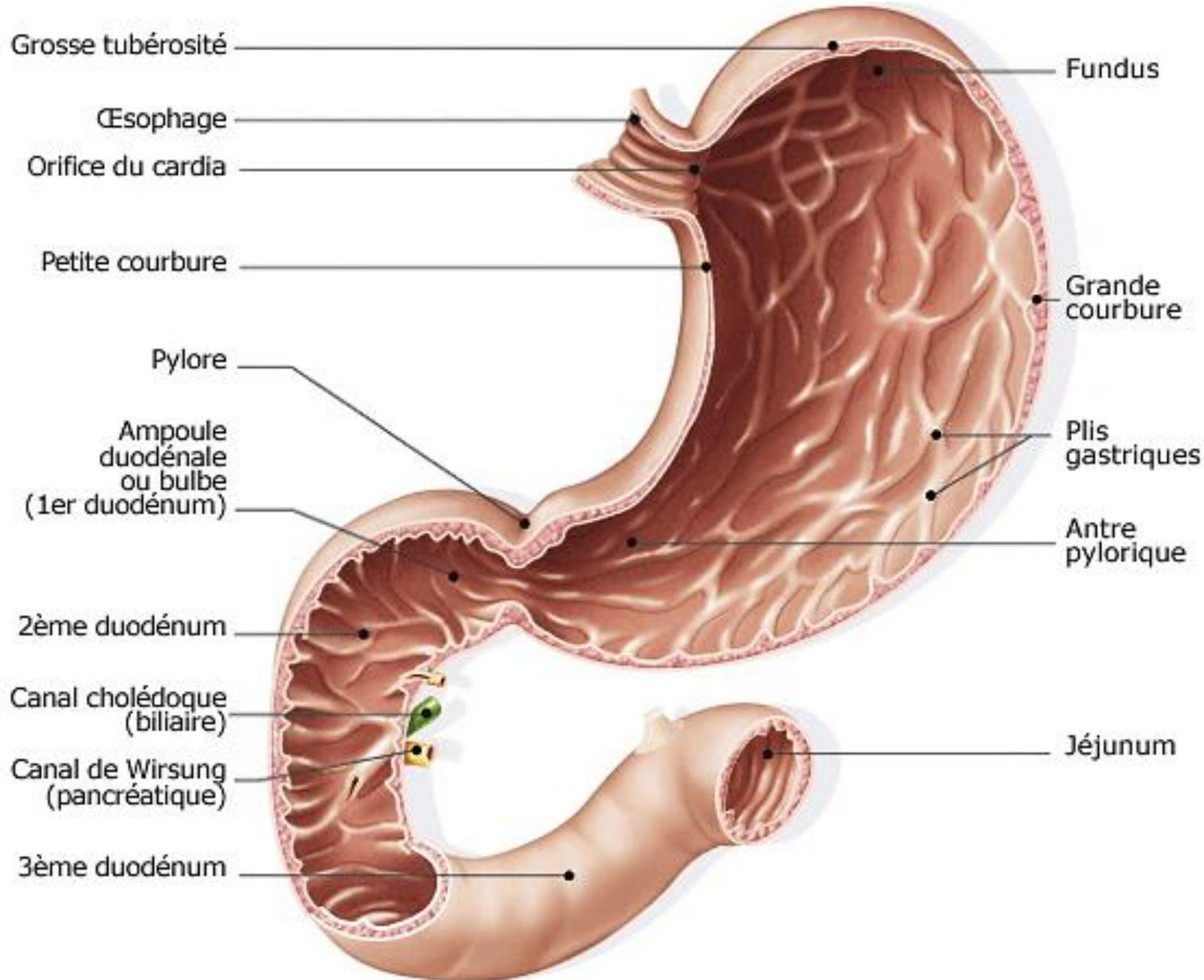


Illustrated: Luke Guthmann





F. Netter M.D.



Second Part of Duodenum - Relations

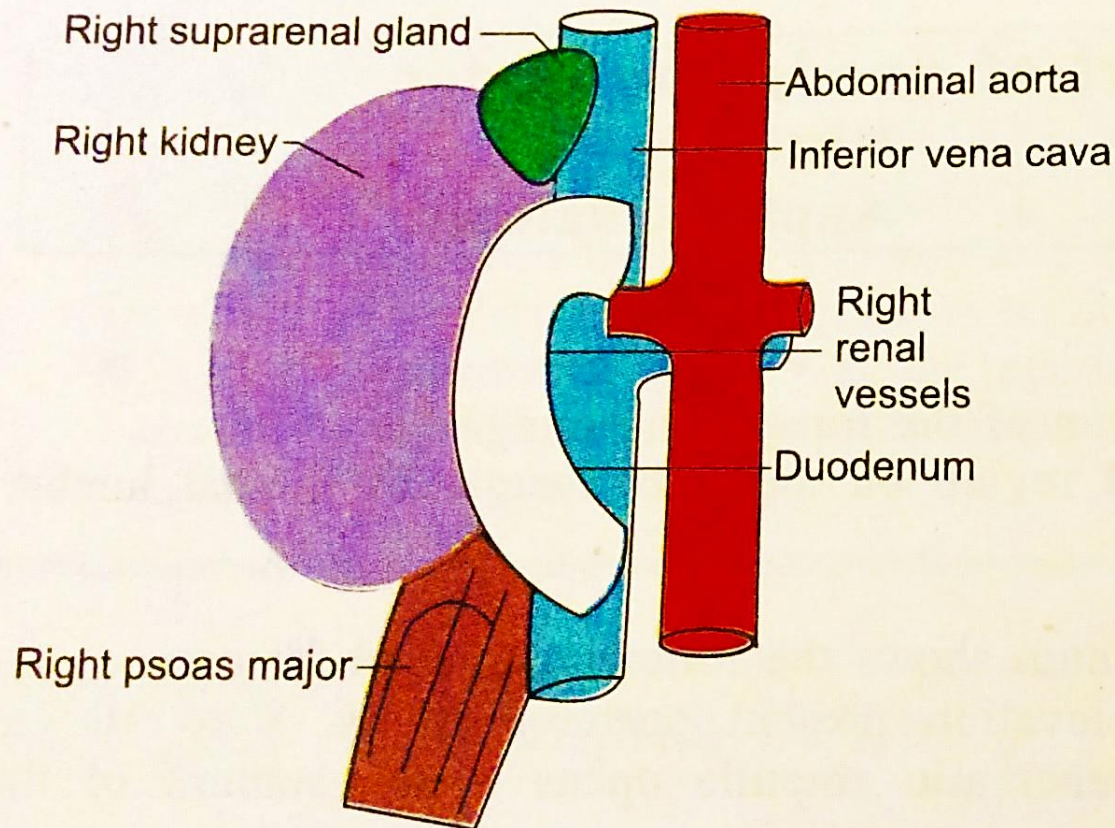


Fig. 2.26 Posterior relations of second part of duodenum

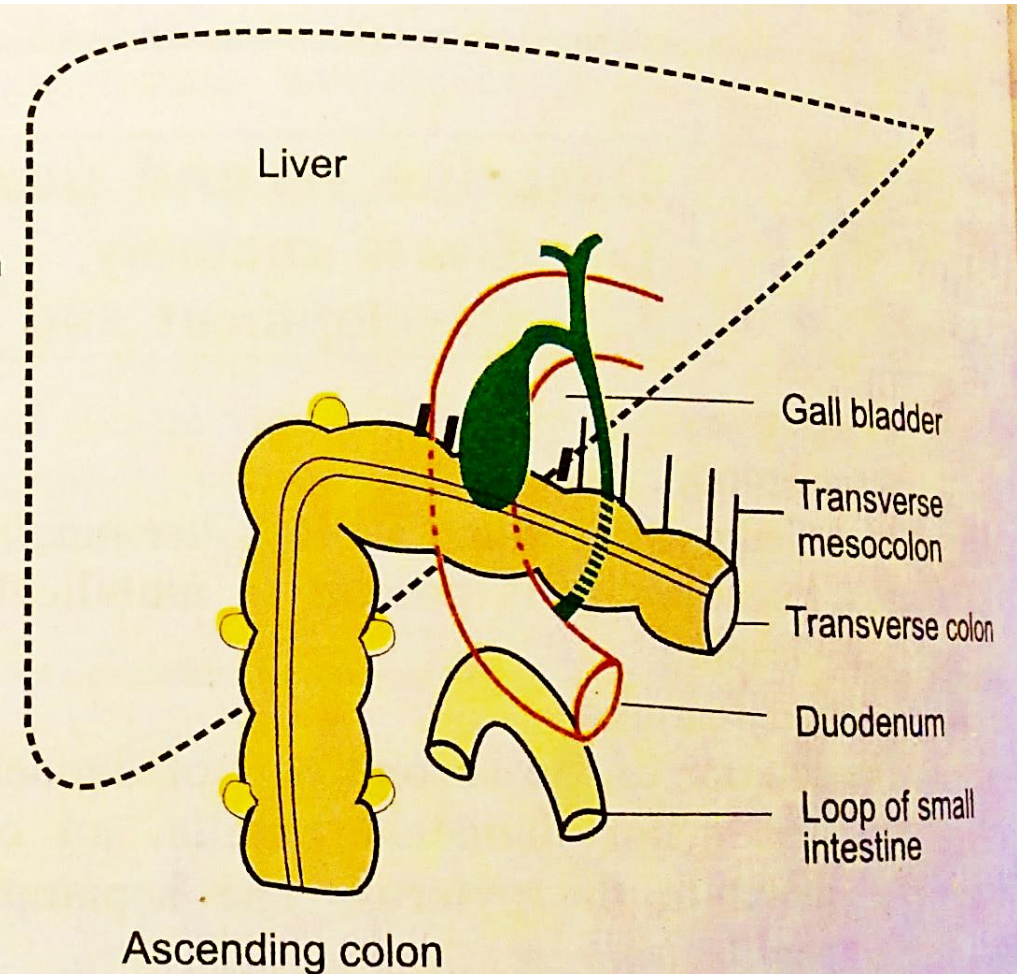
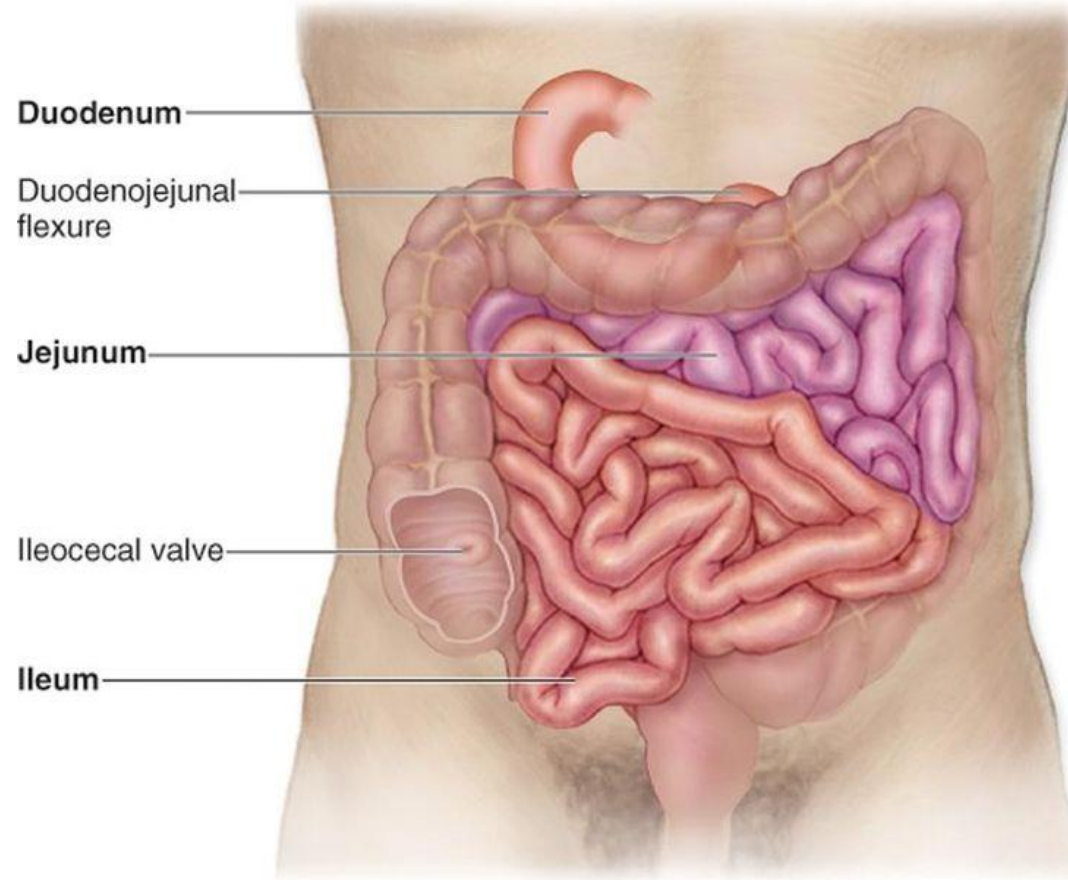


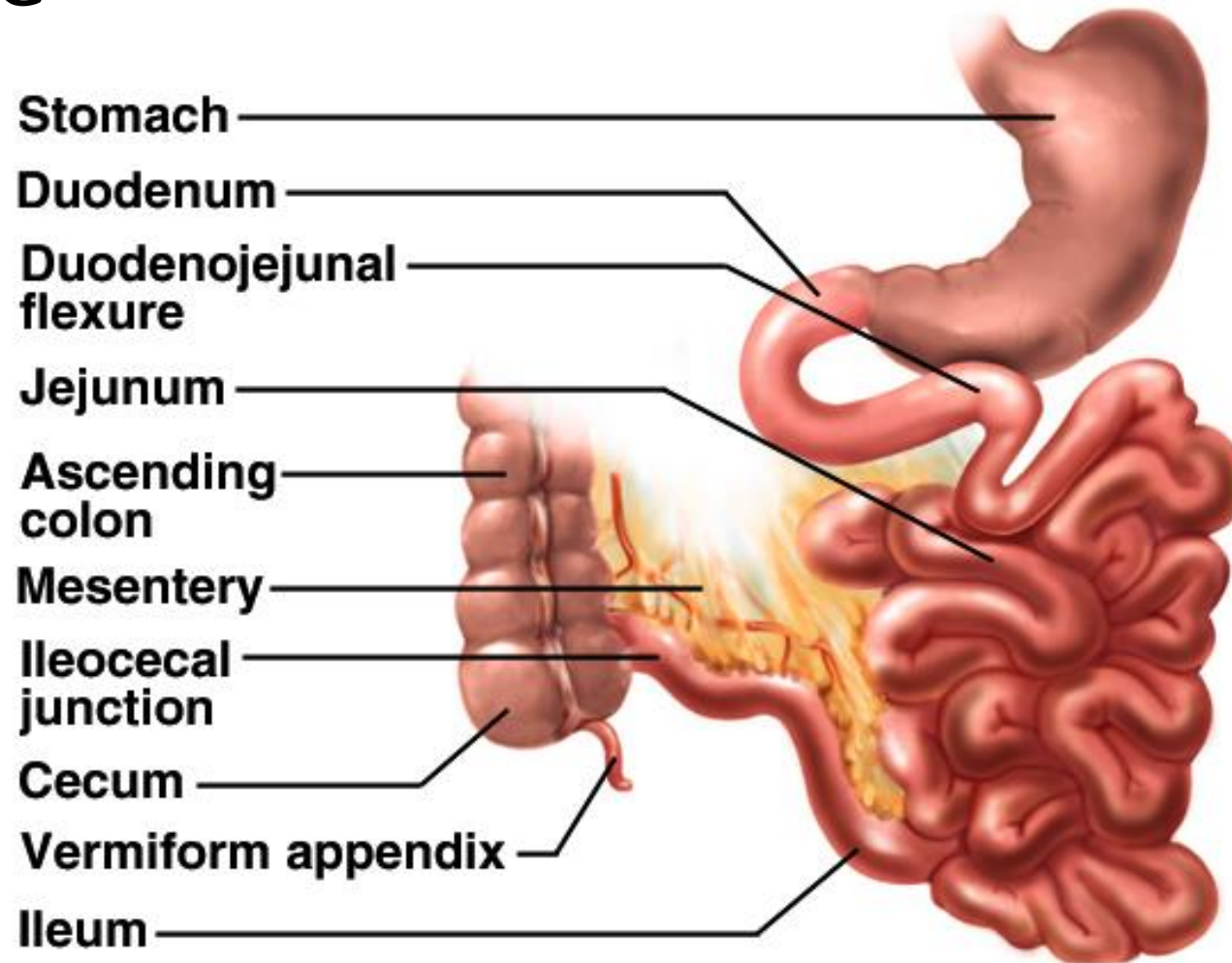
Fig. 2.27 Anterior relations of second part of duodenum

The Small Intestine

Copyright © The McGraw-Hill Companies, Inc. Permission required for reproduction or display.

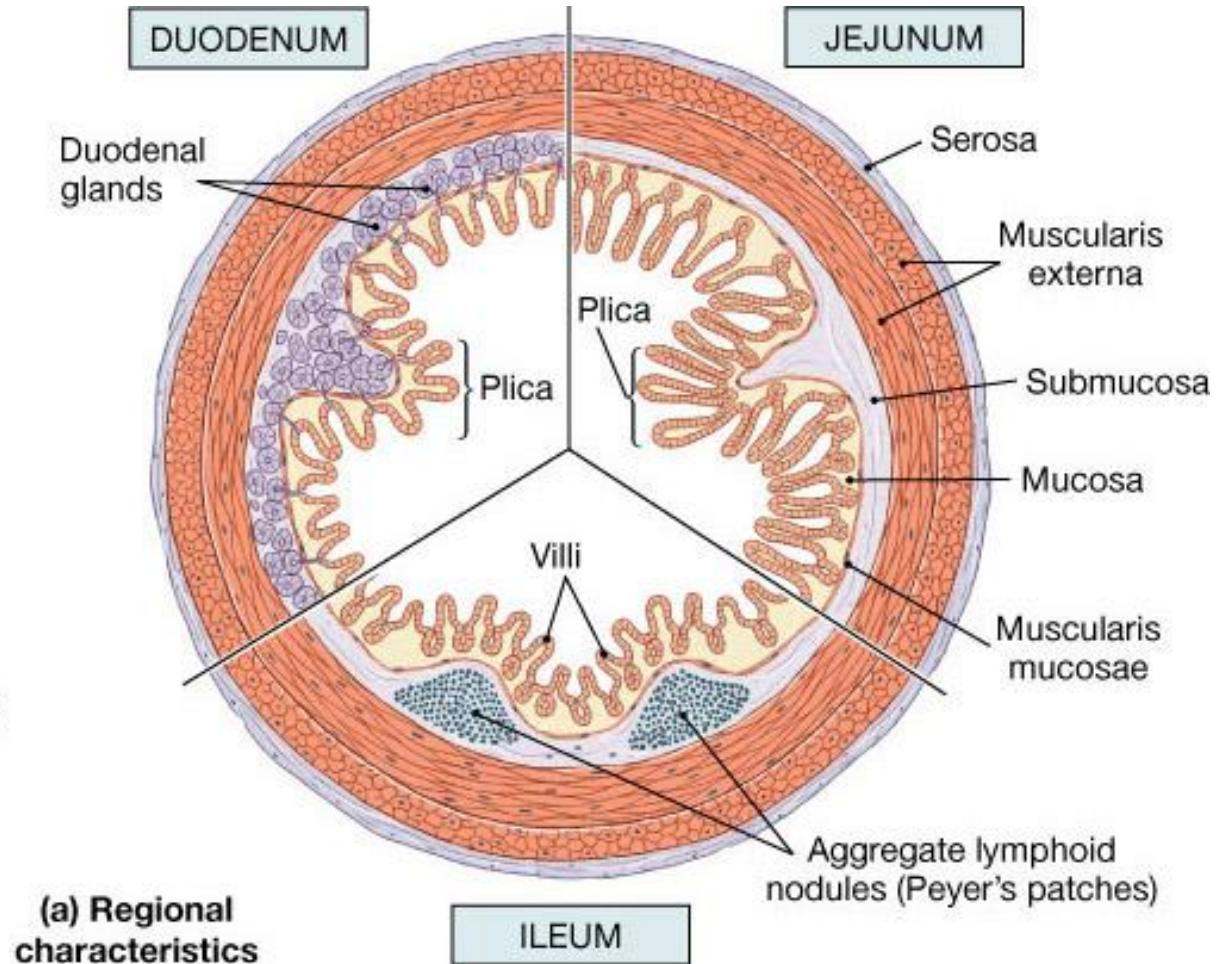
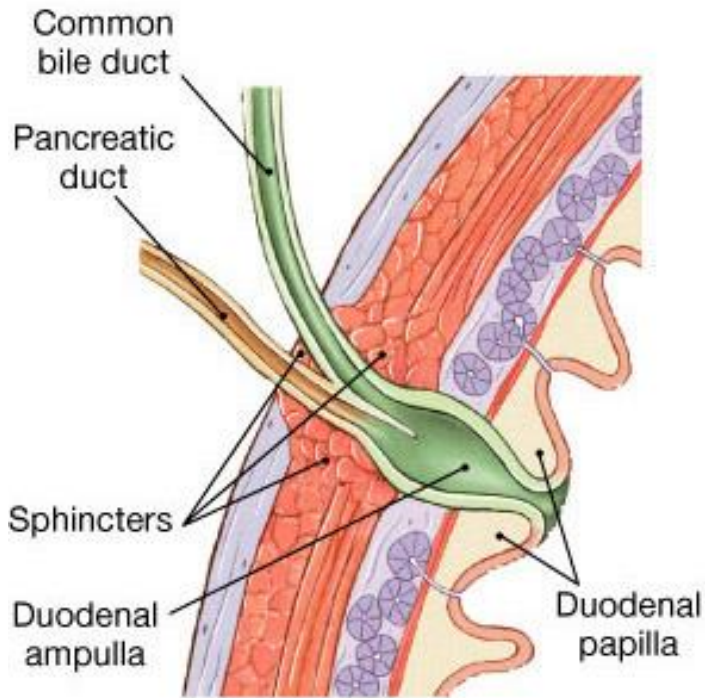


Small Intestine



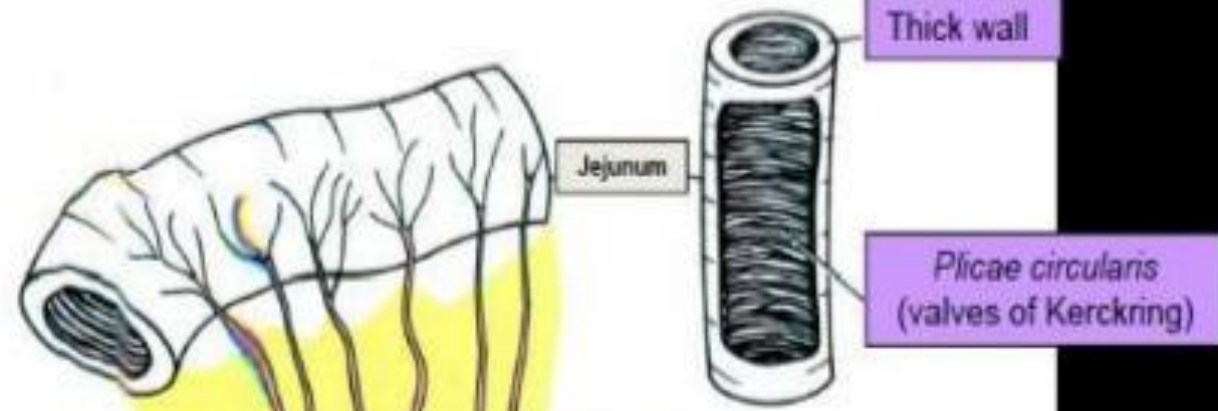
- Nearly all chemical digestion and nutrient absorption occurs in the small intestine

Internal features of Intestines



External and internal differences between jejunum and ileum

Jejunum



Jejunum

Thick wall

Plicae circulares
(valves of Kerckring)

Fat

Arterial arcades

Superior mesenteric artery

Ileum

Thin wall

Peyer's patch

Fat

Ileum

Smooth mucous membrane

Arterial arcades

Superior mesenteric artery

Arterial arcades

Superior mesenteric artery

Ileum

Thin wall

Peyer's patch

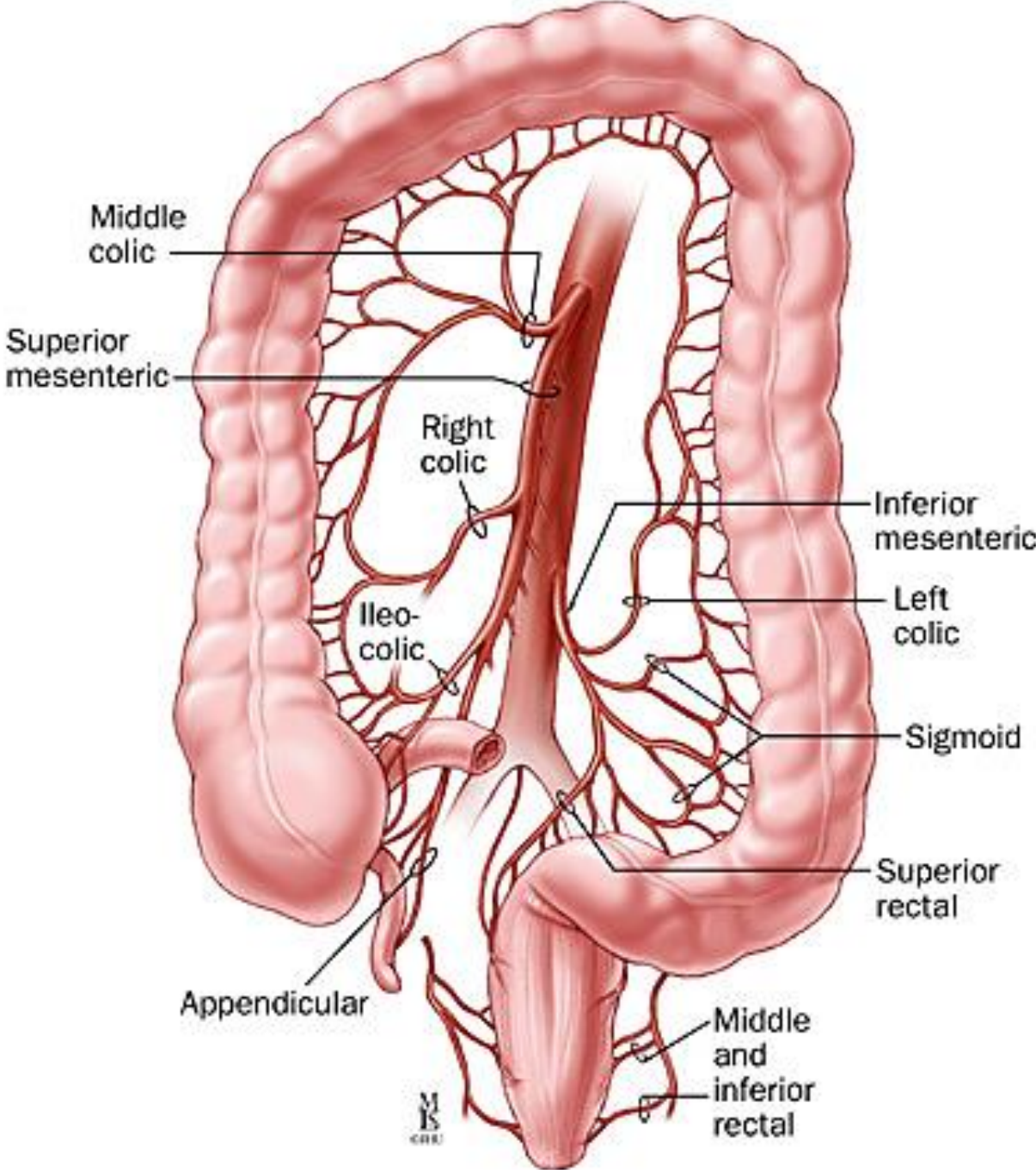
Fat

Smooth mucous membrane

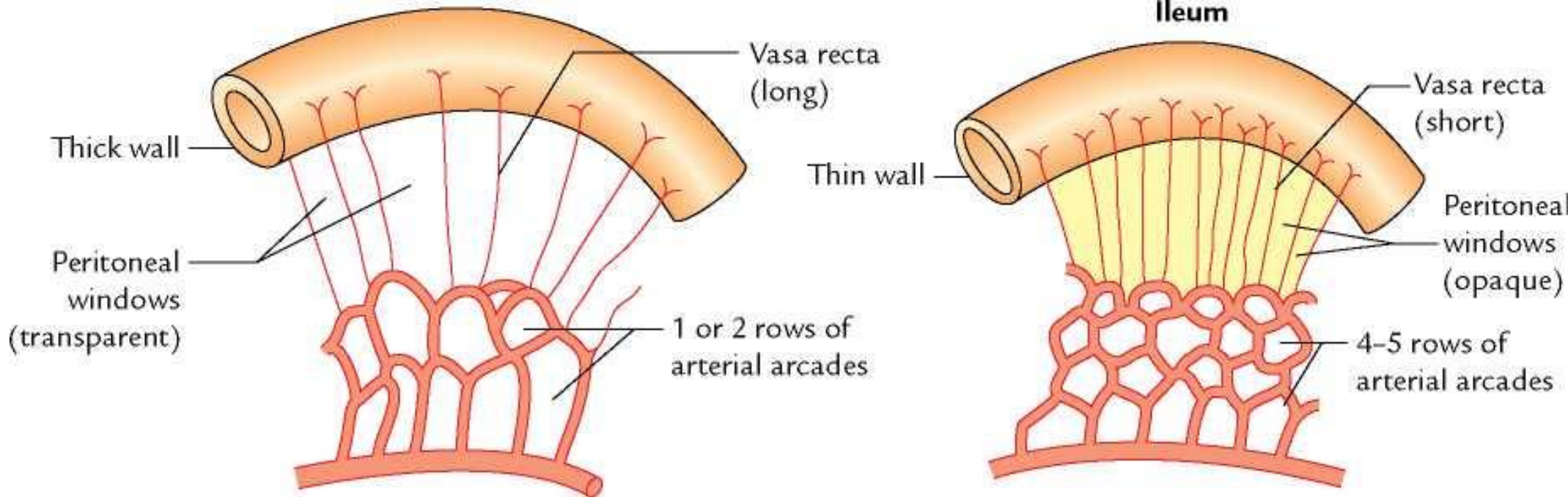
Arterial arcades

Superior mesenteric artery

Blood Supply of Intestines



Blood Supply Differences



Anatomy of Large Intestine

