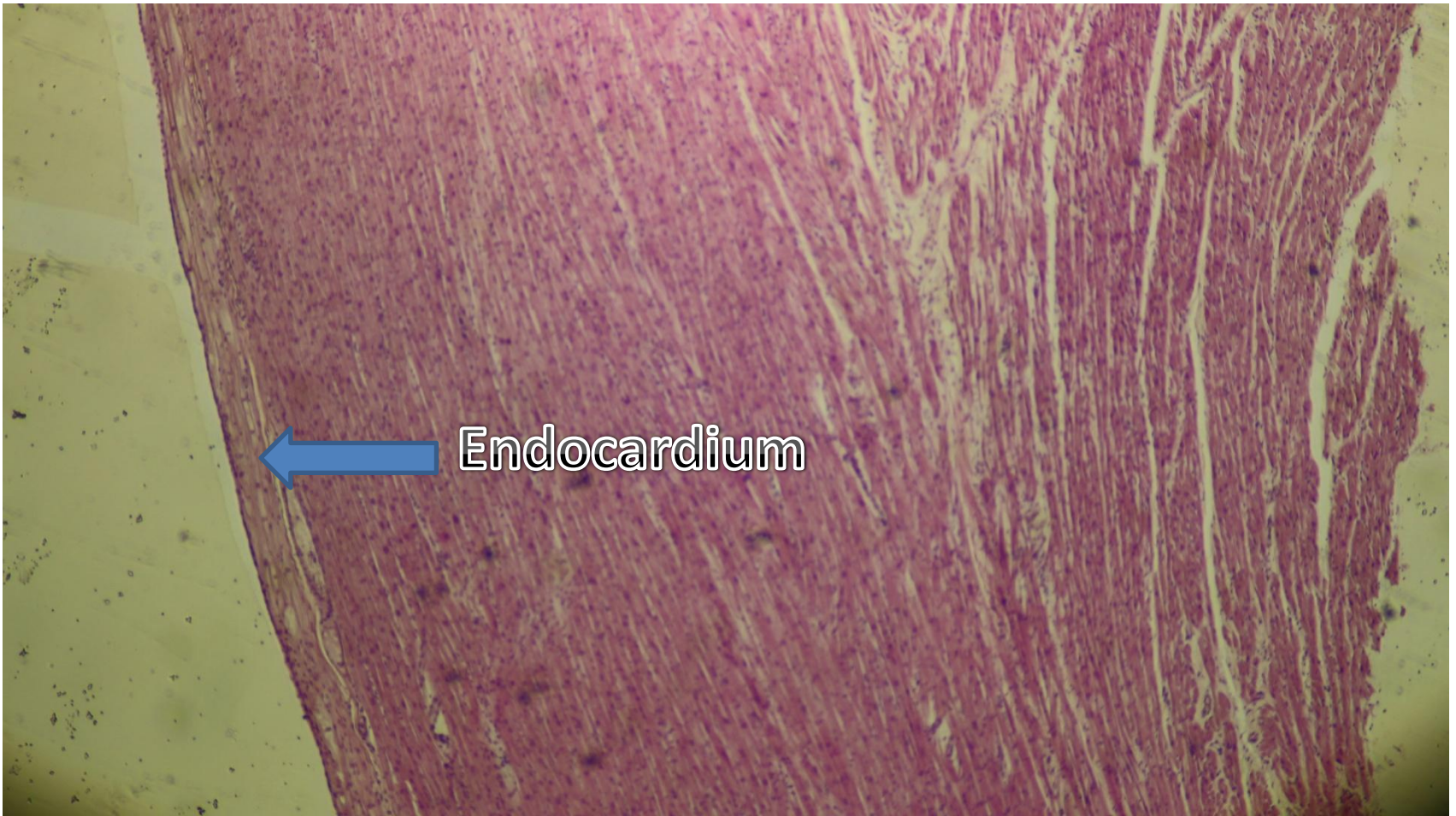



The Heart

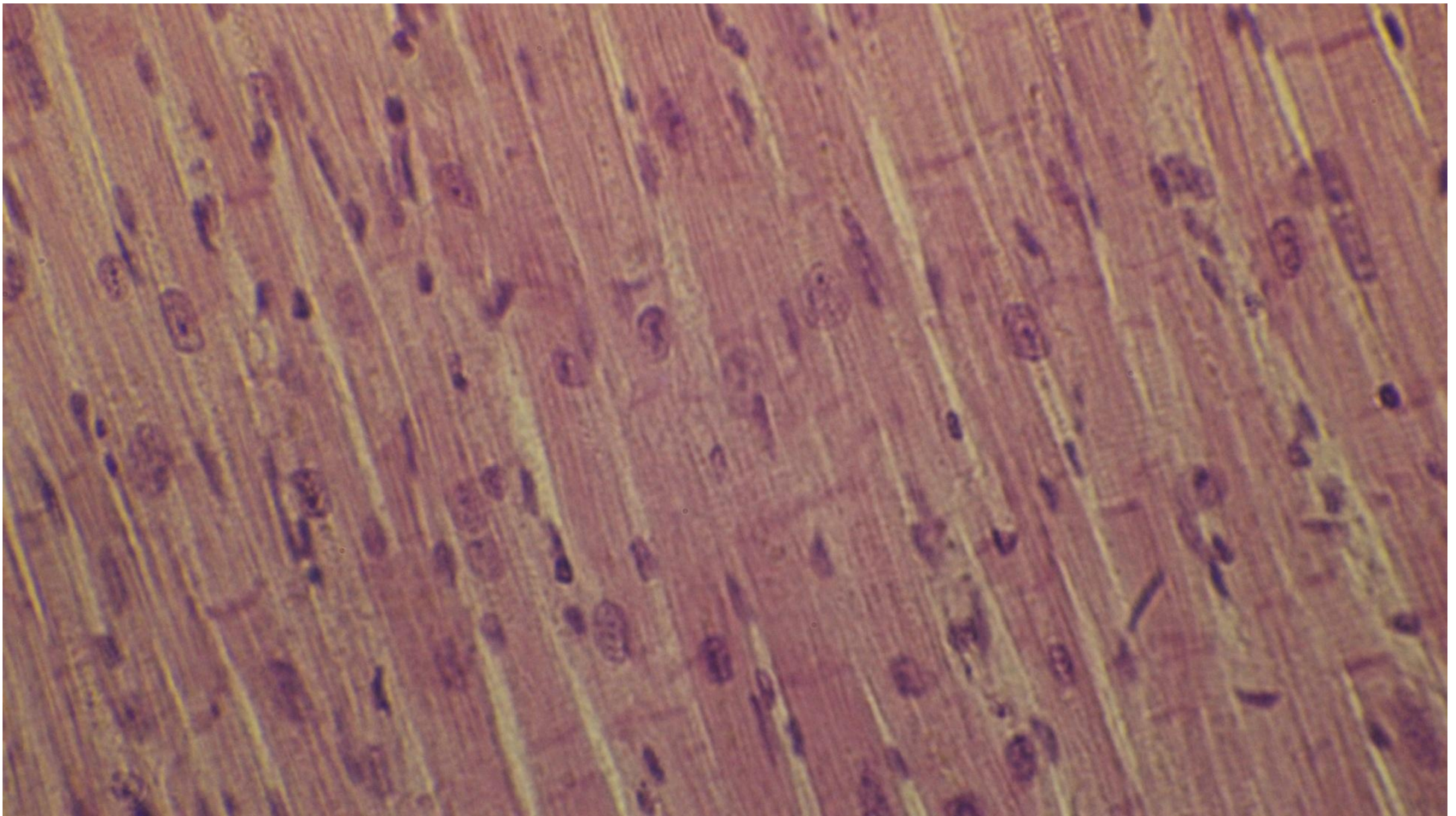




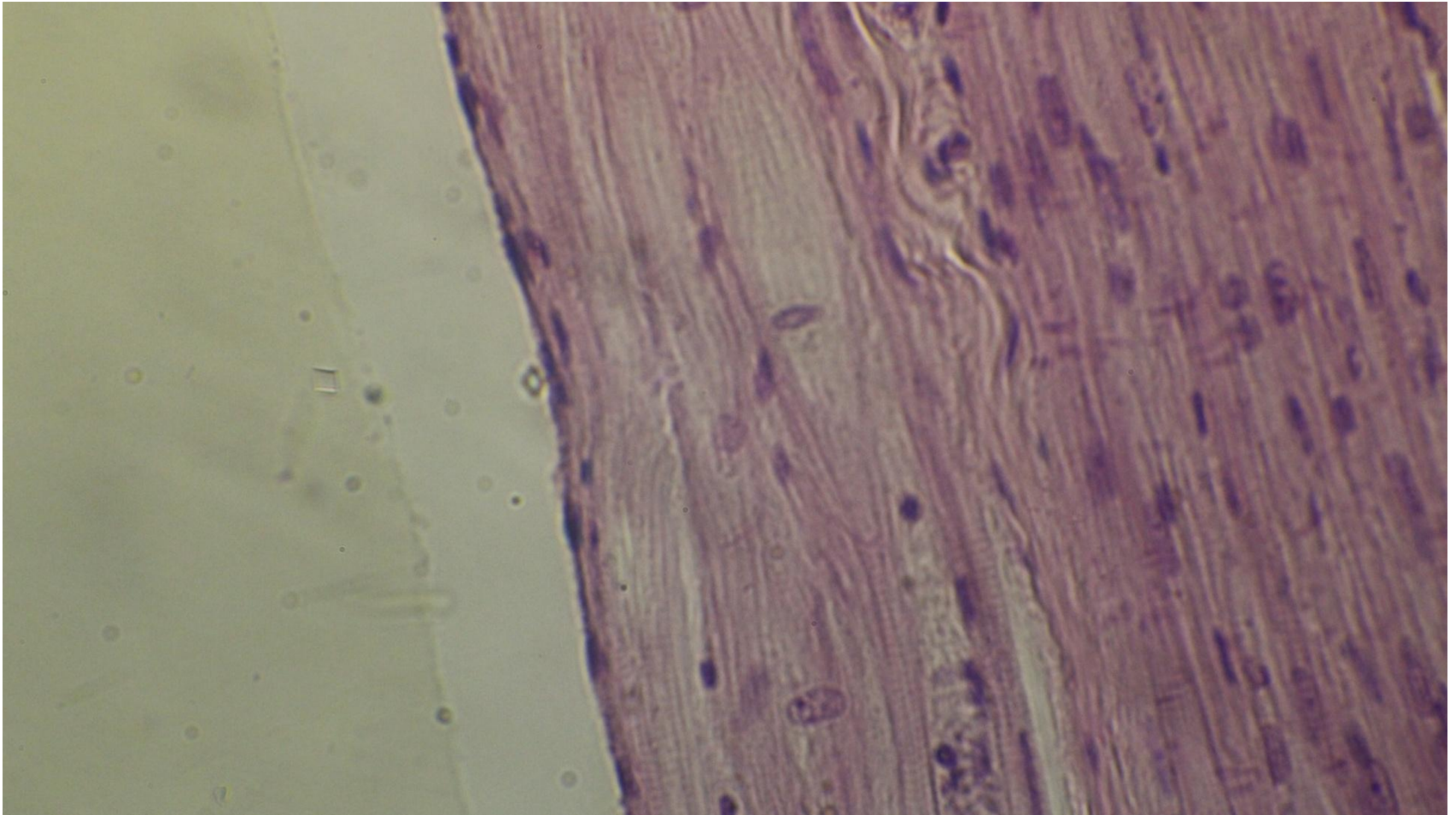
Endo

Myocardium

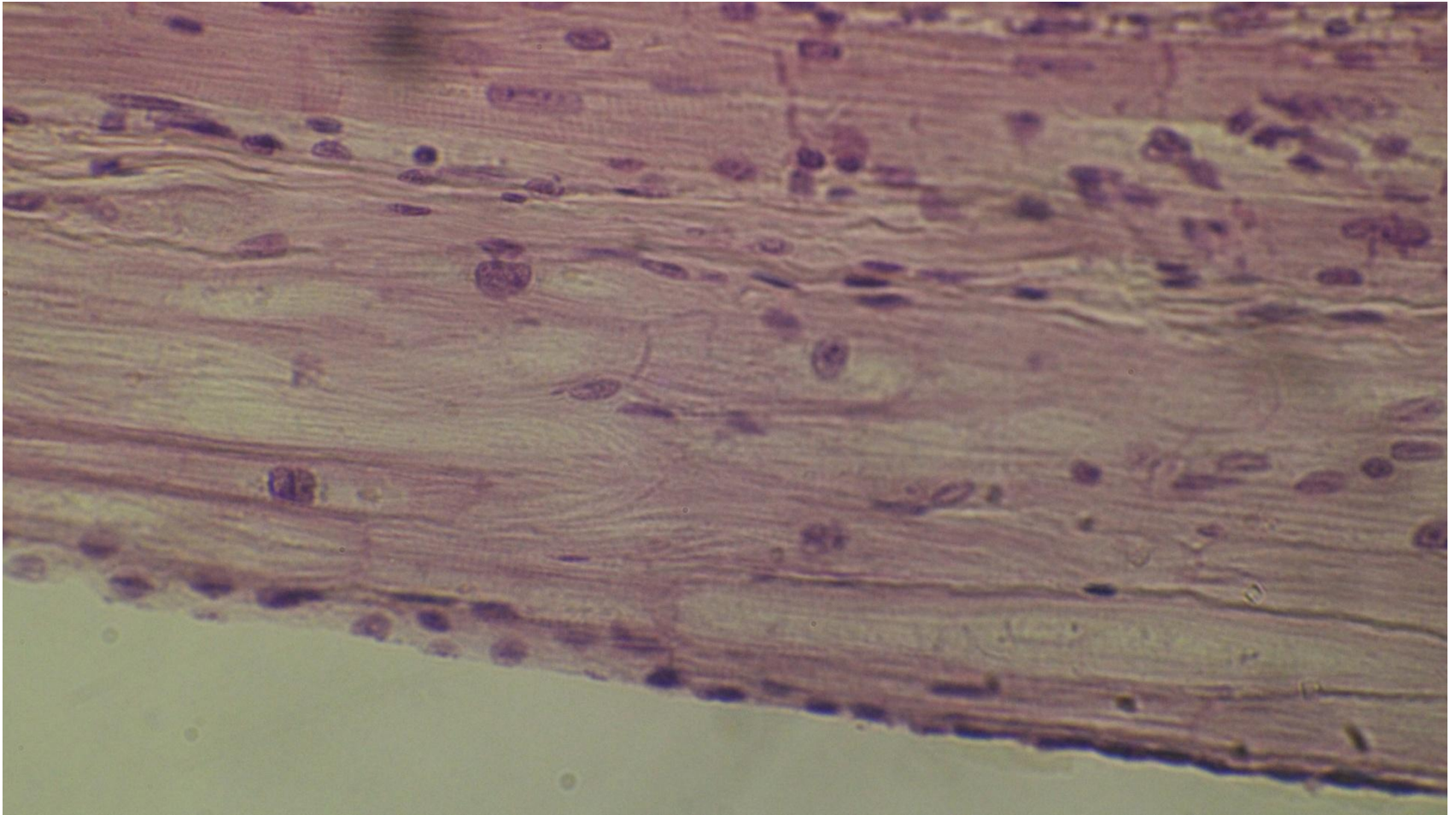
Cardiac muscles, intercalated disc



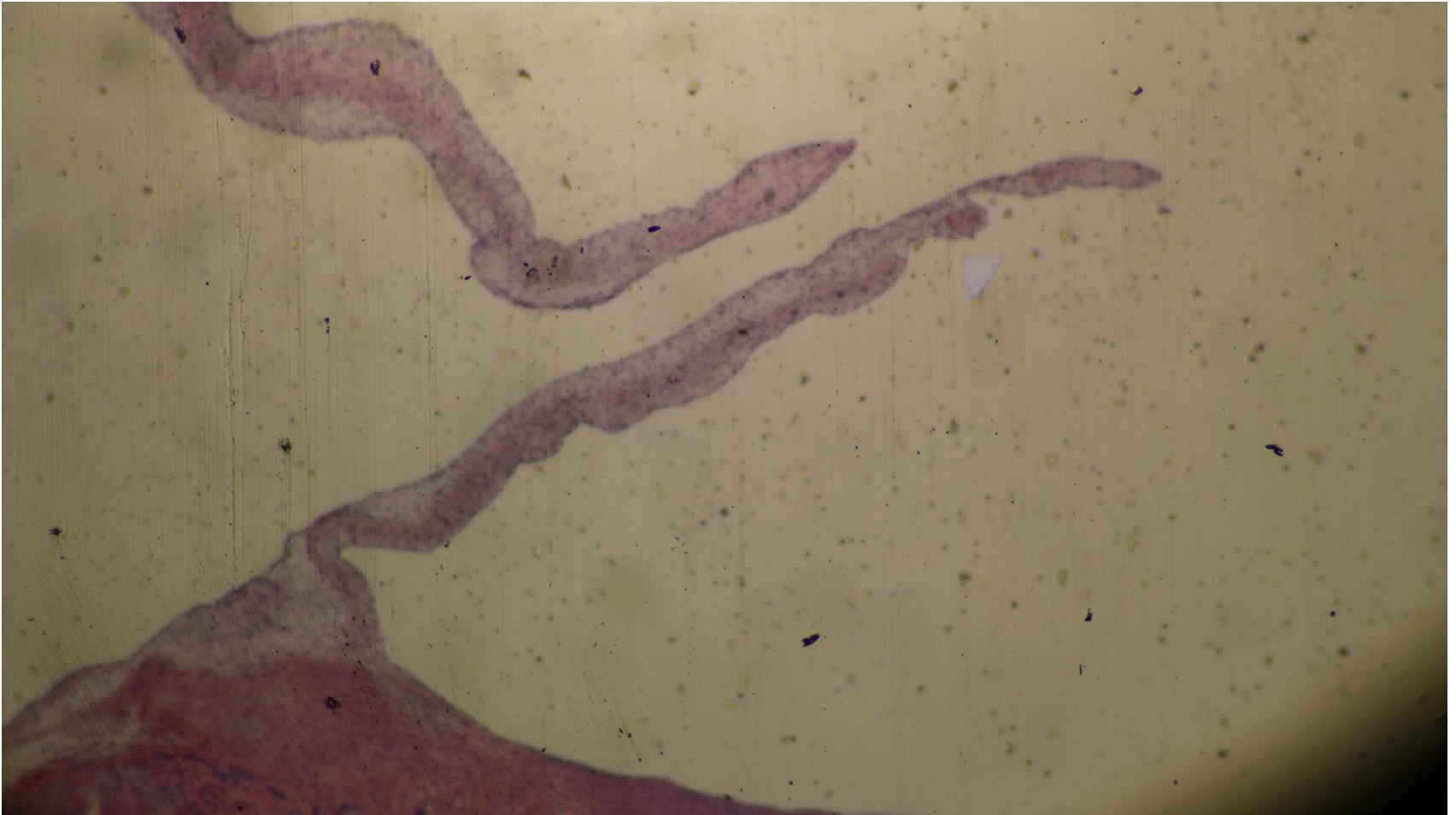
Purkinje cells



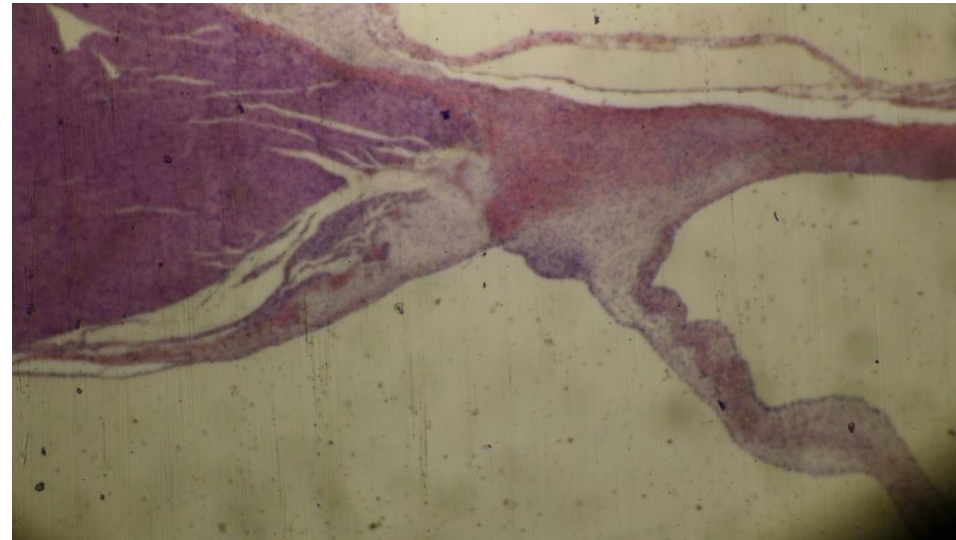
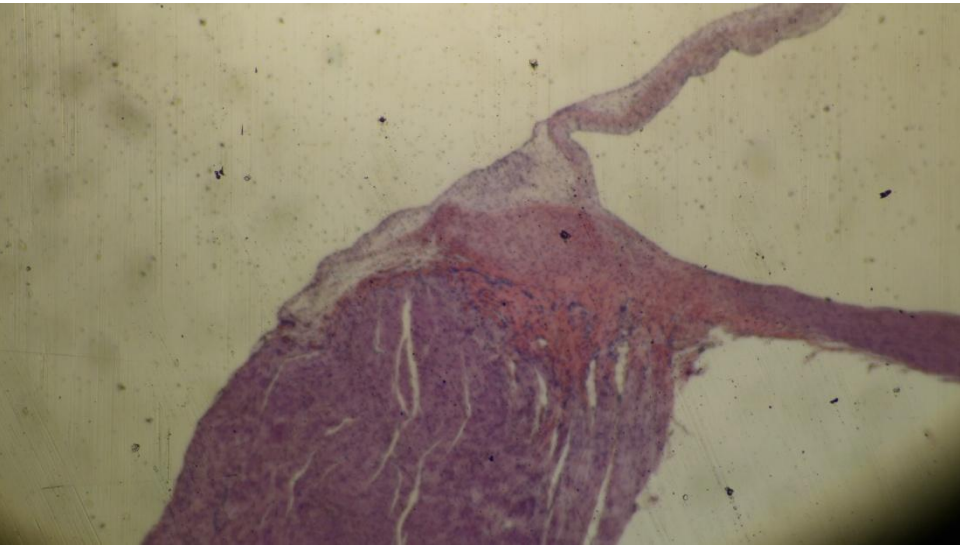
Purkinje cells



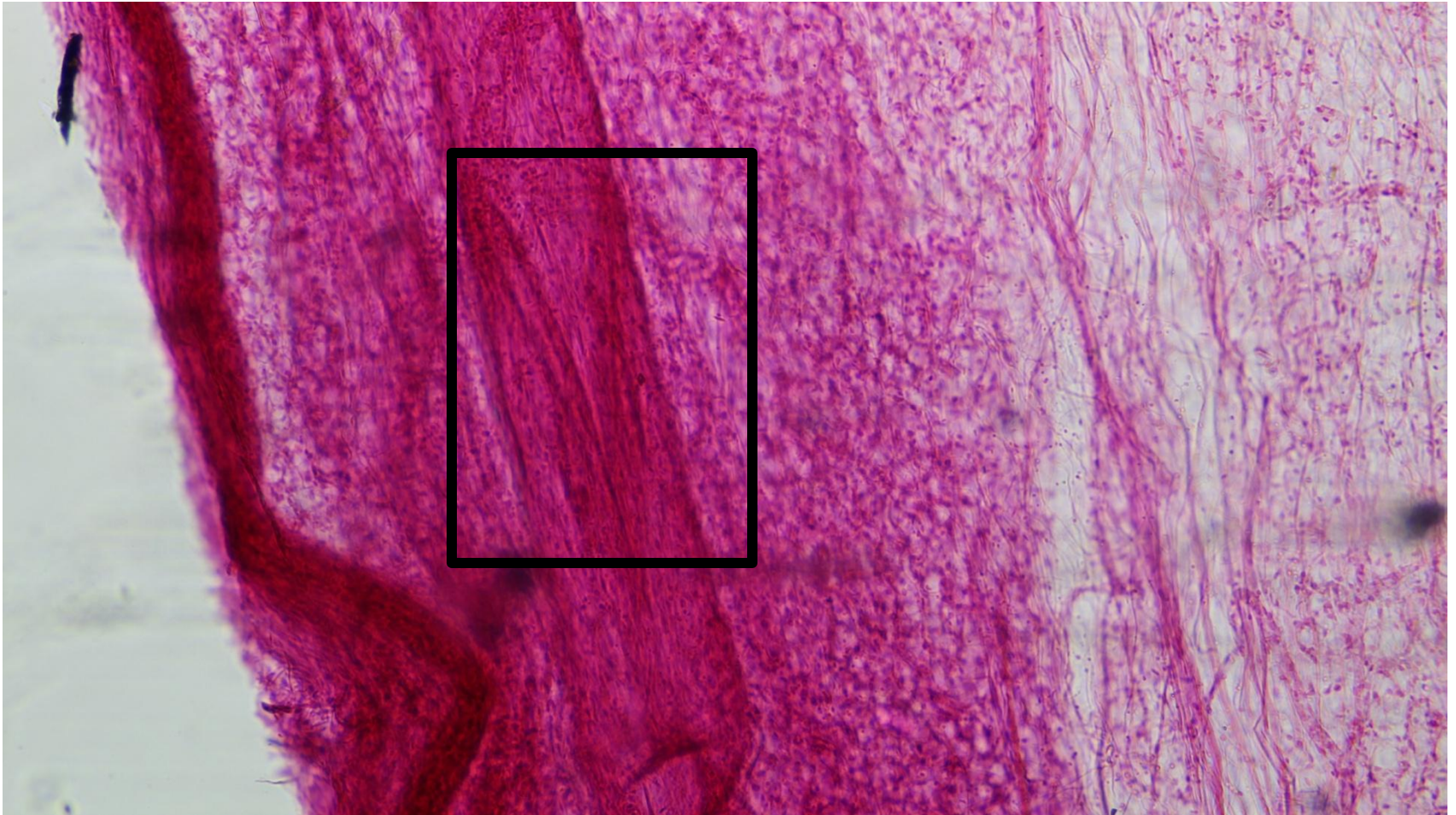
Semilunar valve



Semilunar valve



Lymphatic vessel with valve



Lymphatic vessel with 2 types of valves

