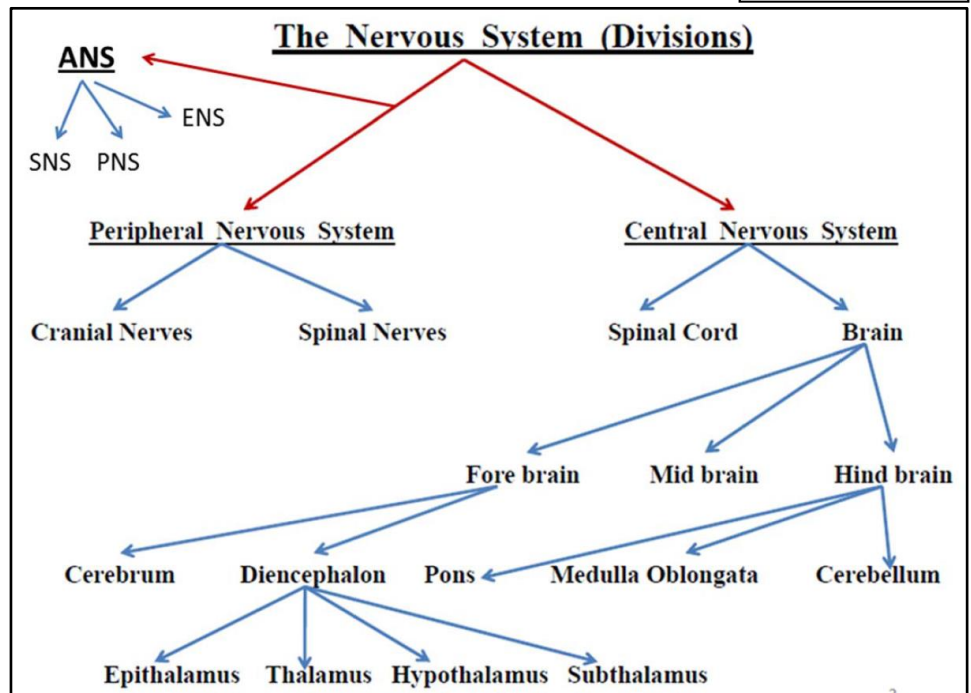


Spinal Nerves

Spinal nerves are the way by which the CNS receives information from, and controls the activities of, the trunk and limbs. There are 31 pairs of spinal nerves (8 cervical, 12 thoracic, 5 lumbar, 5 sacral, 1 coccygeal) which contain a mixture of sensory and motor fibers. They originate from the spinal cord as continuous series of dorsal and ventral nerve rootlets. Adjacent groups of rootlets fuse to form dorsal and ventral roots which then merge to form the spinal nerves proper. Note the following:



- Ventral & dorsal nerve rootlets emerge from the anterolateral & posterolateral aspects of the spinal cord, respectively in all levels.
- Ventral rootlets unite to form the ventral roots of spinal nerves.
- Dorsal rootlets unite to form the dorsal roots of spinal nerves.
- A ventral root joins the corresponding dorsal root to form the spinal nerve, just before exiting the vertebral canal via the intervertebral foramen.
- Ventral root: a bundle made of exclusively efferent (motor) nerve fibers, which are the axons of multipolar neurons. Cell bodies are located in the anterior part of the spinal cord gray matter, & their axons innervate skeletal muscles. Also, the ventral roots of certain spinal levels carry motor fibers (preganglionic, sympathetic or parasympathetic) to innervate smooth muscles, cardiac muscles, or glands. The cell bodies of those fibers are multipolar, & are located in the lateral part of spinal cord gray matter.
- Dorsal root: a bundle made of exclusively afferent (sensory) nerve fibers, which are the central processes of pseudo-unipolar neurons. Cell bodies are located in the dorsal root just proximal to the union with the ventral root, creating a swelling in the root (the dorsal root ganglion). Sensory information reaches the cell bodies in the ganglia via the peripheral processes, then the central processes carry those information to the spinal cord. In the spinal cord, the central process either synapse (in the posterior part of the spinal cord gray matter), or ascends up to higher levels of the CNS.
- Spinal nerves exit from the vertebral canal via their corresponding intervertebral foramina. They then divide to form a large ventral (anterior) ramus and a smaller dorsal (posterior) ramus. In general terms, the ventral ramus innervates the limbs together with the muscles and skin of the anterior part of the trunk. The dorsal ramus innervates the deep group of back muscles and the skin of the back.
- Other branches of the spinal nerves: just after exiting the intervertebral foramen, each spinal nerve gives off 2-4 recurrent meningeal branches, that loop-back to enter the vertebral canal & supply the coverings of the spinal cord (meninges) & the zygapophyseal joints. The anterior rami of T1 – L2 spinal nerves give off white rami communicans (preganglionic sympathetic fibers) to the sympathetic chain ganglia, & receive gray rami communicans (postganglionic sympathetic fibers) to be distributed to the territory of each spinal nerve.
- The nerve fibers within the ventral rami serving the upper and lower limbs are redistributed within brachial and lumbosacral plexuses, respectively.
- C1 – C7 spinal nerves exit the vertebral canal above their corresponding vertebrae. C8 spinal nerve exits below C7 vertebra, & the rest of spinal nerves exit below their corresponding vertebrae.

- Because the spinal cord is significantly shorter than the vertebral canal in adults, the rootlets & roots of spinal nerves attain more & more oblique direction when moving toward the end of the cord, so that the lower lumbar & sacral roots lie almost vertically in the vertebral canal, forming "cauda equina".
- A spinal cord segment is the region of the spinal cord that gives rise to the rootlets of a single spinal nerve.

Spinal Cord Meninges

The meninges (singular: meninx), are 3 concentric layers of tissues that surround the central nervous system (brain & spinal cord) for protection & maintenance of a suitable environment for the delicate nervous tissue. From outside inwards, the meninges are:

1. **Dura mater:** a thick, dense connective tissue layer in the form of a tube. Superiorly, it is continuous with the (inner layer) of the cranial dura mater via the foramen magnum. Inferiorly, it closes at the level of second or third sacral vertebra. When spinal nerves emerge from the vertebral canal, they take a short sleeve of dura-arachnoid mater, this sleeve fuses with the epineurium of the spinal nerve just distal to the intervertebral foramen. Dura mater is highly vascularized, it is separated from the walls of vertebral canal by the epidural space, which is filled with fatty tissue & a rich plexus of veins.
2. **Arachnoid mater:** a thin, highly vascular connective tissue layer that lines the inner surface of dura mater. However, it is not adherent to dura, but there is a potential space between them, the subdural space. Arachnoid mater is separated from the pia mater (the meninx that covers the CNS surface) by the "subarachnoid space", which is filled with a clear filtrate of the plasma, the "cerebro-spinal fluid (CSF)". A huge number of connective tissue bundles or trabeculae extend from the arachnoid mater to the pia mater, these are the "arachnoid trabeculae" that fix the brain & spinal cord in position & act as a shock absorbent. Note: (a) the spinal cord ends at the lower border of L1 vertebra, while the subarachnoid space ends at the lower border of S2 vertebra. (b) blood vessels supplying the surface of the brain & spinal cord run in the subarachnoid space, on the pia mater or suspended in the space by arachnoid trabeculae.
3. **Pia mater:** a very thin layer of stratified squamous epithelium that is adherent to the surface of the CNS, following its bulges & grooves. Pia mater also surrounds even the blood vessels penetrating into the CNS for a short distance. Along the lateral surfaces of the spinal cord, pia mater forms a double-fold ribbon-like structure, the "denticulate ligament". The lateral border of this ligament doesn't reach arachnoid mater, but has many tooth-like processes that attach laterally to the dura mater through arachnoid mater. Denticulate ligament keeps the spinal cord in the center of the subarachnoid space.

From the tip of the lower end of the spinal cord, a bundle of pia mater, "the filum terminale, pial part", descends towards the end of the vertebral canal. At the lower end of the dural sac (S2 level), this bundle becomes surrounded by a dural sheath, & descends down as the "filum terminale, dural part" to be attached to the back of coccygeal vertebrae.

Clinical Applications:

Lumbar cerebrospinal fluid tap:

A lumbar tap (puncture) is carried out to obtain a sample of CSF for examination. In addition, passage of a needle or conduit into the subarachnoid space (CSF space) is used to inject antibiotics, chemotherapeutic agents, and anesthetics. The lumbar region is an ideal site to access the subarachnoid space because the spinal cord terminates between L1 & L2 in the adult. The subarachnoid space extends to the region of the lower border of the S2 vertebra, & there is a large CSF-filled space containing lumbar and sacral nerve roots, but no spinal cord. The patient is placed in the lateral or prone position.

A needle is passed in the midline in between the spinous processes into the extradural space, till it reaches the subarachnoid space. Most needles push the roots away from the tip without causing any symptoms. Once the needle is in the subarachnoid space, fluid can be aspirated. Local anesthetics can be injected into the extradural space (epidural anesthesia) or the subarachnoid space (spinal anesthesia) to anesthetize the sacral and lumbar nerve roots. Such anesthesia is useful for operations on the pelvis and the legs, which can then be carried out without the need for general anesthesia. When procedures are carried out the patient must be in the erect position and not lying on his or her side or in the head-down position.

Arterial Supply of the Vertebral Canal

The spinal cord, spinal nerve roots, & meninges have a rich blood supply.

The spinal cord is supplied by 3 longitudinal arteries, all are derived from the vertebral arteries, as follows:

- **Anterior spinal artery:** which originates within the cranial cavity by the union of two small branches (one from each vertebral artery). The resulting single anterior spinal artery passes along the anterior surface of medulla oblongata & anterior fissure of the spinal cord. At the lower end of the spinal cord, the anterior spinal artery divides into 2 anastomotic loops, each one joins the corresponding posterior spinal artery. The anterior spinal artery gives (1) lateral branches that run on the pia mater covering the spinal cord, forming the "pial arterial plexus" that supplies the superficial regions of the cord, & (2) sulcal (central) branches, that enter the anterior median fissure & supply the deep regions of the cord. The anterior spinal artery supplies the anterior 2/3s of the spinal cord.
- **Posterior spinal arteries:** 2 smaller arteries, each one originates from the corresponding vertebral (or posterior inferior cerebellar) artery in the cranial cavity, & enters the vertebral canal via foramen magnum. Each artery run longitudinally along the posterolateral sulcus of the spinal cord (where the dorsal rootlets join the cord), & terminates at the lower end of the cord by joining the corresponding anastomotic loop. The posterior spinal arteries supply the posterior 1/3 of the spinal cord.
- **Segmental medullary arteries:** at variable vertebral levels, the anterior & posterior spinal arteries receive 8 - 10 booster branches (anterior & posterior segmental medullary arteries) from arteries outside the vertebral canal. Those come from the vertebral & deep cervical arteries in the neck, the posterior intercostal arteries in the thorax, & the lumbar arteries in the lumbar region. Usually, the anterior segmental medullary artery coming from the left first or second lumbar arteries is the largest (called **arteria radicularis magna** or the **artery of Adamkiewicz**), being the main arterial supply of the lower part of the spinal cord.

The spinal nerves & their roots & rootlets receive **segmental spinal arteries** in each spinal segment. Each segmental spinal artery gives off: (a) anterior & posterior **radicular arteries** for the anterior & posterior roots respectively (in all levels), (b) anterior or posterior segmental medullary arteries to boost the anterior & posterior spinal arteries, respectively (in some levels). Segmental spinal arteries arise from: the vertebral & deep cervical arteries in the neck, the posterior intercostal arteries in the thorax, & the lumbar arteries in the lumbar region, & the lateral sacral arteries in the sacral region.

Venous Drainage of the Vertebral Canal

The spinal cord is surrounded by a number of longitudinal veins running in the subarachnoid space, as follows:

- One anterior spinal vein (along the anterior median fissure),
- One posterior spinal vein (along the posterior median sulcus),
- Two small veins anterior & posterior to the attachment line of the rootlets to the spinal cord (so, 8 in total),
- Those veins are connected to anterior & posterior radicular veins in all spinal levels.

The above veins lie inside the meninges. The epidural space contains larger venous plexuses (the anterior & posterior internal venous plexuses), which drain the vertebral bodies via the basivertebral veins. Finally, the vertebral column is surrounded by the external venous plexuses (anterior external: anterior to vertebral bodies, posterior external: posterior to the vertebral arches).

The above venous plexuses drain via the intervertebral veins, to major systemic veins, such as the azygos system in the thorax & deep cervical veins in the neck. The internal vertebral plexus also communicates with intracranial veins.