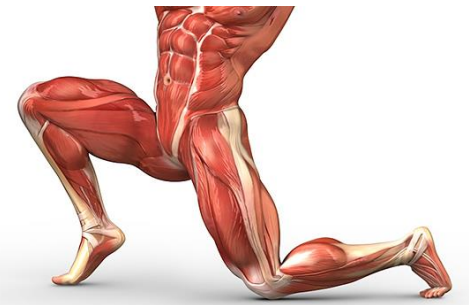

Anatomy of the lower limb

Anterior & medial compartments of the thigh

Dr. Hayder



The fascia lata encloses the entire thigh like a sleeve/stocking. Three intramuscular fascial septa (lateral, medial, and posterior) pass from the inner aspect of the deep fascial sheath of the thigh to the linea aspera of the femur and divide the thigh into three compartments – anterior, medial, and posterior. The *Anterior (extensor) compartment*, lies between lateral and medial intermuscular septa, the *Medial (adductor) compartment*, lies between medial and posterior septa, and the *posterior (flexor) compartment*, lies between posterior and lateral septa. Each compartment contains muscles, nerves, and arteries.

ANTERIOR COMPARTMENT OF THE THIGH

Muscles of the anterior compartment

Muscle	Origin	Insertion	Innervation	Action
Sartorius	Anterior superior iliac spine (ASIS)	Upper part of the medial surface of the shaft of tibia	Femoral nerve	Flexion & lateral rotation of the hip Flexion of the knee
Iliacus	Iliac fossa of iliac bone	Lesser trochanter (iliopsoas tendon)	Femoral nerve	Flexion of the thigh at the hip joint
Psoas major	Transverse processes, bodies & intervertebral discs of T12 & all lumbar vertebrae	Lesser trochanter (iliopsoas tendon)	L2,3	Flexion of the thigh at the hip joint
<u>Quadriceps femoris</u> Rectus femoris	<u>Straight head</u> from anterior inferior iliac spine <u>Reflected head</u> groove above the acetabulum	All four heads unite in one tendon inserted to the patella and continued via the ligamentum patellae into the tibial tuberosity	Femoral nerve	Extension of the leg at the knee joint (rectus femoris assists in hip flexion)
Vastus medialis	Upper end of the shaft of the femur			
Vastus intermedius	Anterior and lateral aspects of the shaft of the femur			
Vastus lateralis	Upper end of the shaft of the femur			
Articularis genus	Anterior surface of the lower part of the shaft of femur	Synovial membrane of the knee joint (suprapatellar bursa)	Femoral nerve	Pulling up the suprapatellar bursa during knee j. extension

Tensor fascia latae	Outer part of the iliac crest & superior aspect of ASIS	Iliotibial tract below the greater trochanter	Superior gluteal nerve	Abduction of hip joint Stabilizing the knee in knee joint extension (with the action of gluteus maximus)
----------------------------	---	---	------------------------	---

Clinical correlation: the quadriceps femoris is innervated by the femoral nerve with main contributions mainly from spinal segments L3 & L4. A tap with a tendon hammer on the patellar ligament can test reflex activity mainly at spinal levels L3 & L4.

Femoral triangle

It is a triangular depression on the front of the upper one-third of the thigh below the inguinal ligament. Its apex is directed downward.

Boundaries:

Lateral: Medial border of sartorius.

Medial: Medial border of adductor longus.

Base: Inguinal ligament.

Apex: It is formed by the meeting point of the medial borders of the adductor longus and sartorius.

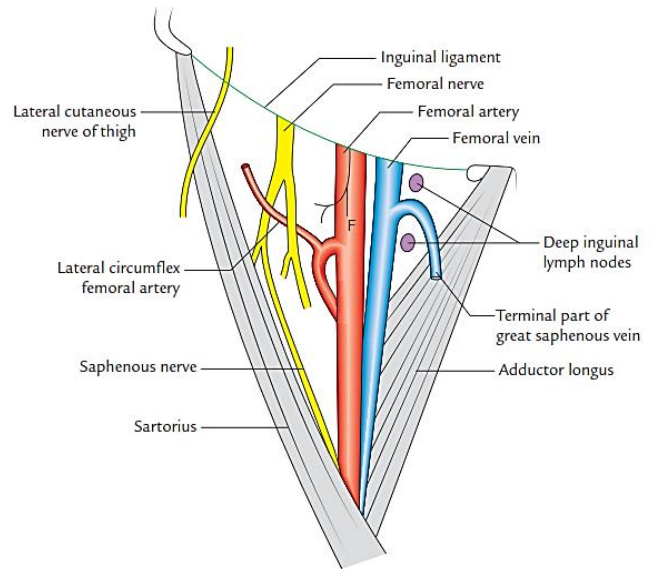
Floor: It is gutter shaped and muscular. From lateral to medial side, the following muscles form it:

1. Iliacus.
2. Psoas major (tendon).
3. Pectineus.
4. Adductor longus.

Roof: It is formed by the fascia lata having saphenous opening. The superficial fascia overlying the roof contains superficial branches of the femoral artery and accompanying veins, upper part of great saphenous vein, superficial inguinal lymph nodes, femoral branch of the genitofemoral nerve, and branches of ilioinguinal nerve.

Contents:

1. Femoral artery and its branches.
2. Femoral vein and its tributaries.
3. Femoral nerve.
4. Deep inguinal lymph nodes.
5. Lateral cutaneous nerve of the thigh.
6. Femoral branch of the genitofemoral nerve.
7. Fibrofatty tissue.



The adductor canal (Subsartorial or Hunter's canal)

It is an intermuscular tunnel formed by the groove between vastus medialis & adductor longus and its roof is formed by the sartorius & its fascial sheath. The canal is bound anteromedially by sartorius and its fascia, laterally by vastus medialis and posteriorly by adductor longus.

It extends from the apex of the femoral triangle, above, to the tendinous opening (adductor hiatus) in the adductor magnus, below. It provides a passage to the femoral vessels from femoral triangle to the popliteal fossa.

Contents of the adductor canal:

1. Femoral artery
2. Femoral vein
3. Saphenous nerve
4. Nerve to vastus medialis
5. Descending genicular artery (br. of the femoral artery)

The femoral vessels leave the canal through the tendinous hiatus in adductor magnus muscle while the saphenous nerve and artery pierce the roof of the canal and continue to descend downwards on the medial side of the thigh.

The femoral artery

The femoral artery is the main artery of the lower limb. It begins posterior to the **midinguinal point** (midpoint between the ASIS and the symphysis pubis) as the continuation of the **external iliac artery**. It enters the lateral compartment of the femoral sheath, runs in the femoral triangle and continues in the adductor canal. It ends by passing through the **tendinous opening in adductor magnus muscle** to become the **popliteal artery**.

Relations

- **Anteriorly**; anterior wall of the femoral sheath, skin and fascia (in the femoral triangle), sartorius muscle (in the adductor canal). It is crossed by the medial cutaneous nerve of the thigh above and by the saphenous nerve below.
- **Posteriorly**; from above downwards it descends on psoas major, pectineus, adductor longus and adductor magnus muscles. The femoral vein intervenes between the artery and the adductors.
- **Medially**; the femoral vein in the upper part (then the vein becomes posterior to it).
- **Laterally**; the femoral nerve and its branches.

Branches:

- ✓ **Three superficial (cutaneous) branches**: all pierce the cribriform fascia and pass through saphenous opening to supply the skin of their corresponding regions:
 - **The superficial circumflex artery**: passes laterally towards the ilium to supply the skin of the groin.
 - **The superficial epigastric artery**: crosses the inguinal ligament upwards to supply the skin around the umbilicus.
 - **The superficial external pudendal artery**: passes medially to supply the skin of the scrotum (or labium majus).
- ✓ **The deep external pudendal artery** runs medially to supply the skin of the scrotum or labium majus.
- ✓ **The Profunda femoris artery**: is the largest branch and the main source of blood supply to the muscles of the thigh. It arises from the lateral side of the femoral artery in the femoral triangle, and then curves medially behind the femoral vessels; it gives rise to medial and lateral circumflex femoral branches. It then curves backwards and descends vertically posterior to adductor longus muscle close to- the shaft of the femur giving 3 perforating branches and continuing as the 4th perforating artery. The profunda femoris artery gives the following branches;
 - **The medial circumflex femoral artery**: gives off muscular brs. to psoas major, pectineus (adductor compartment muscle), the adductors & obturator internus muscles. An acetabular br. to the hip joint & ends by participating in the cruciate anastomosis just posterior to adductor magnus muscle.
 - **The lateral circumflex femoral artery**: is the largest branch of the profunda femoris artery. It passes laterally deep to rectus femoris muscle to divide into 3 branches:

1. Ascending branch: passes deep to tensor fascia latae muscle to the gluteal surface of the ilium giving muscular & articular branches & ends by participation in the trochanteric anastomosis.
 2. Transverse branch: penetrates vastus lateralis muscle posteriorly to participate in the cruciate anastomosis.
 3. Descending branch: runs along the anterior border of the vastus lateralis muscle giving muscular branches & articular branch for the anastomosis around the knee joint.
- **The perforating arteries** turn around the femur towards vastus lateralis muscle, perforating the muscular layers attached to the linea aspera. They supply the muscles of the medial and posterior compartments. The first participates in the cruciate anastomosis. The second and/or third give the nutrient artery of the femur. The fourth represents the continuation of the profunda femoris artery.
- ✓ **The descending genicular artery** is the last branch from the femoral artery. It supplies the adjacent muscles and the knee joint and gives an accompanying branch to the saphenous nerve; the saphenous artery; to the medial side of the knee and leg.

Clinical correlations:

- *The femoral artery can be compressed against the femoral head at the midinguinal point to control the bleeding in the distal part of the limb.*
- *The pulsations of the femoral artery are felt by the clinicians in the femoral triangle just below the midinguinal point.*
- *The profunda femoris artery is of great clinical importance because it is deeply located and lies in close proximity to the femoral shaft; hence, it is prone to injury of fracture of femoral shaft.*
- *The profunda femoris artery is also liable to injury during surgical procedure of fixing metallic screws in the femur by an orthopedic surgeon*

The femoral vein

This vein begins as the continuation of the popliteal vein at the tendinous opening of adductor magnus muscle (adductor hiatus) and ascends in the adductor canal and femoral triangle to enter the middle compartment of the femoral sheath and ends by passing posterior to the midinguinal point medial to the femoral artery to become the external iliac vein. It receives the great saphenous vein and tributaries corresponding to the branches of the femoral artery except the superficial circumflex iliac, superficial epigastric and superficial external pudendal veins which drain to the great saphenous vein. In the lower part of its course, the femoral vein is posterolateral to the artery, then it crosses posterior and finally lies medial to it in the femoral sheath.

The femoral nerve

It is the largest branch of the lumbar plexus (L2,3,4). It enters the thigh posterior to the inguinal ligament and lateral to the femoral sheath. About 4cm distal to the inguinal ligament, it divides into a number of muscular, articular and cutaneous branches that are arranged into anterior and posterior divisions that both enclose lateral circumflex femoral artery between them:

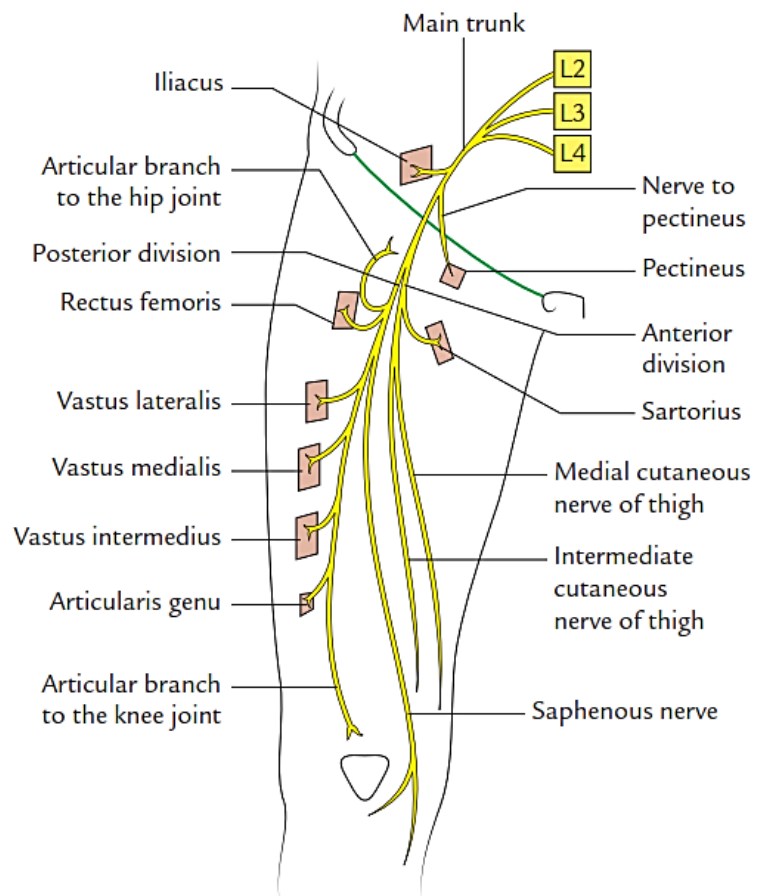
Branches of the Anterior division

- Nerves to pectineus & Sartorius muscles
- Intermediate & medial cutaneous nerves of the thigh

Branches of the Posterior division

- Nerve to rectus femoris supplies the muscle & gives an articular branch to the hip joint.
- Muscular branches to the three vasti supply the muscles & give articular branches to the knee joint.

- The saphenous nerve; is the largest branch of the femoral nerve & represents its continuation. It runs with the femoral vessels in the adductor canal, and pierces the roof of the distal part of the adductor canal to appear on the posterior border of the sartorius muscle medial to the knee joint where it gives off an infrapatellar branch to the patellar plexus of nerves. Then it pierces the deep fascia below the knee to run in the superficial fascia of the leg with the great saphenous vein and ends in the skin of the medial side of the foot. It supplies the skin of the medial side of the knee and leg and the proximal part of the dorsum of the foot along its medial border.



MEDIAL COMPARTMENT OF THE THIGH

Muscles of the medial compartment

Muscle	Origin	Insertion	Innervation	Action
Gracilis	Ischiopubic ramus	Upper part of the medial surface of the shaft of tibia	Obturator nerve	Adduction of thigh at the hip joint Knee flexion Medial rotation of the leg when the knee is extended
Pectineus	Superior pubic ramus	Upper end of linea aspera (pectineal line)	Femoral nerve	Adduction of thigh at the hip joint
Adductor longus	Pubic body medial to the Pubic tubercle	Linea aspera	Obturator nerve	Adduction of thigh at the hip joint
Adductor brevis	Ischiopubic ramus & ischial tuberosity	Linea aspera	Obturator nerve	Adduction of thigh at the hip joint
Adductor magnus	Ischiopubic ramus (adductor part) Ischial tuberosity (Hamstring part)	Linea aspera	Adductor part: Obturator nerve Hamstring part: tibial part of sciatic nerve	Adduction of thigh at the hip joint (adductor part) Extension of the thigh at the hip (Hamstring part)
Obturator externus	Outer surface of the obturator membrane & ischiopubic ramus	Medial surface of greater trochanter	Obturator nerve	Lateral rotation of the hip joint

- There are six muscles in the medial compartment of the thigh. All these muscles are innervated by obturator nerve except; pectineus supplied by femoral nerve & the hamstring part of the adductor magnus supplied by tibial part of sciatic nerve.
- All the muscles of the medial compartment except the obturator externus muscle mainly adduct the thigh at the hip & medially rotate the thigh at the hip, however, obturator externus is a lateral rotator of the hip.
- The hamstrings portion of adductor magnus is cylindrical in shape. The adductor portion is flat and has many **tendinous arches** near its insertion to the linea aspera for the passage of the perforating arteries. The lowest arch is the largest and is called the **tendinous hiatus** or **adductor opening** that permits the passage of the femoral vessels to and from the popliteal fossa

The blood vessels of the medial compartment are mainly derived from the perforating arteries (of the profunda femoris artery) & the obturator artery.

The obturator artery

This is a branch of the **internal iliac artery** in the lesser pelvis. It enters the thigh by passing with the obturator nerve through the obturator canal where it divides into anterior and posterior branches that encircle the obturator membrane deep to obturator externus. The artery gives:

- **Muscular branches** to the upper parts of the muscles of the medial compartment.
- An **articular branch to the hip joint** traverses the acetabular notch and enters the ligament of the head of the femur (ligamentum teres) to supply that part of the bone. The obturator vein receives the corresponding tributaries and drains to the internal iliac vein.

The obturator nerve

The nerve arises from the lumbar plexus (L2, L3 and L4) and enters the thigh through the obturator canal where it divides into anterior and posterior divisions.

- **The anterior division** runs between adductor longus anteriorly and obturator externus and adductor brevis posteriorly, then distal to adductor brevis muscle it enters the adductor canal and communicates with the medial cutaneous nerve of the thigh and the saphenous nerve.

Branches from the anterior division;

1. **Muscular** to **adductor longus, adductor brevis** and **gracilis**.
 2. **Articular** to the **hip joint**.
 3. **Autonomic** to the **femoral artery**.
 4. **Cutaneous** by its communication with other cutaneous nerves in the adductor canal.
- **The posterior division** pierces obturator externus and descends between adductor brevis anteriorly and adductor magnus posteriorly and continues as an articular branch to the knee joint.

Clinical correlation: In diseases of the hip joint, the pain may be referred to the knee joint along the obturator nerve because it supplies both these joints.

Accessory obturator nerve

In about 30% individuals, accessory obturator nerve arises from the lumbar plexus. It is formed by the ventral divisions of the anterior primary rami of L3, L4 spinal nerves. It crosses the superior ramus of pubis deep to pectineus, which it supplies. It gives an articular twig to the hip joint and terminates by communicating with the anterior division of the obturator nerve. If small, it supplies only the pectineus muscle.