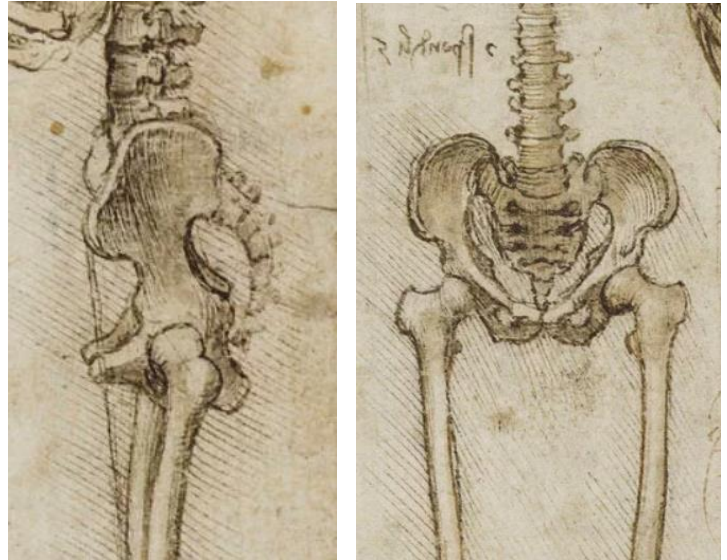


THE HIP JOINT

The hip joint is a ball and socket type of synovial joint between the head of the femur and the acetabulum of the hip bone. It is the largest ball and socket joint in the body. It is multi-axial and permits same movements as shoulder joint in the upper limb. However, its range of movements is more restricted due to its role in weight bearing.



Articular Surfaces

The head of the femur articulates with the cup-shaped acetabulum of the hip bone to form the hip joint. Thus, articular surfaces are provided by the head of the femur and acetabulum of the hip bone as follows:

1. The head of femur forms more than half of a sphere. It is covered by the articular hyaline cartilage except for a small pit—the fovea capitis for ligamentum teres (the ligament of the head of femur).
2. The acetabulum, presents three features: a C-shaped lunate surface, acetabular notch (the "mouth" of the C-shape), and acetabular fossa (the depression in the center of the C-shape, filled with fat).

Out of these, only lunate surface is articular and covered by an articular cartilage. The depth of the acetabulum is increased by the acetabular labrum.

The acetabular labrum is a fibrocartilaginous rim attached to the acetabular margin. It is triangular in cross-section. Inferiorly, the labrum bridges across the acetabular notch as the **transverse acetabular ligament** and converts the notch into a foramen. The labrum deepens the acetabulum (socket) & grasps the head of femur lightly to hold it in position.

The Joint Capsule

The capsule of the hip joint is a strong, dense fibrous sac which encloses the joint. Its attachments are:

1. On the hip bone, it is attached around the acetabular margin, outer surface of the acetabular labrum and transverse acetabular ligament.
2. On the femur, it is attached anteriorly to intertrochanteric line and posteriorly 1 cm medial to intertrochanteric crest.

Note the following:

- The capsule is thicker anterosuperiorly, where the maximal stress occurs, particularly in the standing position. Posteroinferiorly it is thin and loosely attached.
- The capsule is made up two types of fibers—inner circular fibers and outer longitudinal fibers. The inner circular fibers form collar around the femoral neck (zona orbicularis), these fibers are not directly attached to the bones.
- The outer longitudinal fibers are reflected along the neck toward the head to form the "retinacula".

The Synovial Membrane

The synovial membrane lines inner aspect of the fibrous capsule, the intracapsular portion of the femoral neck, the labrum (inner & outer surfaces), transverse acetabular ligament, ligamentum teres, and fat in the acetabular fossa.

The Ligaments

The ligaments of the hip joint are the following:

1. Iliofemoral ligament.
2. Pubofemoral ligament.
3. Ischiofemoral ligament.
4. Transverse acetabular ligament.
5. Ligamentum teres (ligament of the head of femur).

Ligament of the Head of Femur

This ligament is also called round ligament/ligamentum teres. It is a flat triangular ligament with apex attached to the fovea of the head, and its base to the transverse acetabular ligament. It is ensheathed by a sleeve of the synovial membrane. The ligament of the head of femur does not increase the stability of the joint. Instead, it transmits arteries to the head of the femur derived from the acetabular branches of the obturator (and medial circumflex femoral) arteries.

Transverse Acetabular Ligament

It is a part of acetabular labrum, which bridges the acetabular notch; however, it is devoid of cartilage cells. The acetabular notch thus becomes converted into the foramen which transmits the acetabular vessels and nerves to the hip joint.

Iliofemoral Ligament

The iliofemoral ligament is inverted Y-shaped ligament, which lies anterior to the joint and intimately blended with the capsule. Its apex is attached to the area between the anterior inferior iliac spine and the acetabular margin. Its base is attached to the intertrochanteric line. This ligament consists of three parts—a lateral thick band of oblique fibers, a medial thick band of vertical fibers, and a triangular thin portion in between. The iliofemoral ligament is the strongest ligament in the body and prevents the trunk from falling backward in the standing posture.

Pubofemoral Ligament

The pubofemoral ligament is a triangular ligament with base above and apex below. It lies inferomedial to the head & neck of femur, and supports the joint on this aspect. Its base is attached to the iliopubic eminence, superior pubic ramus, and obturator crest. Inferiorly it blends with the anteroinferior part of the capsule and medial band of the iliofemoral ligament

Ischiofemoral Ligament

The ischiofemoral ligament is relatively weak and supports the capsule posteriorly. Above it is attached to the ischium posteroinferior to the acetabulum. From ischium its fibers spiral behind the femoral neck to be attached into the greater trochanter deep to the iliofemoral ligament.

The fibers of the last three ligaments are oriented in a spiral fashion around the hip joint so that they become taut when the joint is extended & loose when the joint is flexed (that's why the range of hip flexion is much larger than hip extension). This stabilizes the joint and reduces the amount of muscle tone required to maintain a standing position.

Stability of the Hip Joint

The stability of the hip joint is provided by the following factors which help to prevent its dislocation:

1. Depth of the acetabulum and narrowing of its mouth by the acetabular labrum.
2. Three strong ligaments (iliofemoral, pubofemoral, and ischiofemoral) strengthening the joint capsule.
3. Strength of the surrounding muscles, e.g., gluteus medius, gluteus minimus, etc.
4. Length and obliquity of the neck of femur.

Relations

Anteriorly:

1. Tendon of iliopsoas (separated from joint by a bursa), pectineus (lateral part), straight head of rectus femoris.
2. Femoral nerve, femoral artery, & femoral vein.

Posteriorly:

1. Deep group of gluteal region muscles, & gluteus maximus.
2. Superior gluteal nerve and vessels above the piriformis.
3. Inferior gluteal nerve and vessels below the piriformis.

4. Sciatic nerve, posterior cutaneous nerve of the thigh, and nerve to quadratus femoris.

Superiorly:

1. Reflected head of rectus femoris medially.
2. Gluteus minimus, gluteus medius, and gluteus maximus laterally.

Inferiorly:

1. Pectineus.
2. Obturator externus.
3. Medial circumflex femoral artery.

Bursae around the Hip Joint

SUBGLUTEAL BURSAE

The subgluteal bursae are six in number, four occur under the gluteus maximus, one under the gluteus medius, and one under the gluteus minimus, as follows:

1. Between gluteus maximus & the ilium (below the origin of the muscle).
2. Between gluteus maximus and the greater trochanter (above the insertion of the muscle). This is the largest bursa around the hip joint.
3. Between gluteus maximus and ischial tuberosity (ischial bursa). In people who sit for long periods, this bursa frequently inflames & swells & becomes painful, this condition is called "weaver's bottom".
4. Between the tendon of gluteus maximus and vastus lateralis (gluteofemoral bursa).
5. Between gluteus medius and upper part of the greater trochanter.
6. Between gluteus minimus and anterior aspect of the greater trochanter.

SUBPSOAS BURSA/PSOAS BURSA

Subpsoas bursa is found between the iliopubic eminence and the psoas tendon. In 10% individuals the psoas bursa communicates with the synovial cavity of the hip joint through a gap in the thin part of the capsule between the iliofemoral and pubofemoral ligaments.

Arterial Supply

The hip joint is supplied by the branches of the following arteries:

- Medial & lateral circumflex femoral arteries.
- Obturator artery.
- Superior gluteal & inferior gluteal arteries.
- First perforating branch of the profunda femoris artery.

The obturator artery gives off the acetabular artery, usually from its posterior branch. The acetabular artery supplies the structures in the acetabular notch, & gives the artery of the ligament of the head of femur, which passes via the ligament to the fovea of the head of femur, supplying a small part of the head.

The two circumflex femoral arteries give many small branches, the "retinacular arteries", to supply the neck & head of femur. Those small arteries are the main blood supply of the femoral head. They pass along the femoral neck beneath the retinacula of the joint capsule, to penetrate into the bone just before the beginning of the hyaline cartilage of the femoral head. Retinacular arteries from the medial circumflex femoral artery (seen on the posterior aspect of the neck) are larger in number & size than those coming from the lateral circumflex femoral artery (which are seen on the anterior aspect of the neck).

Branches from the superior & inferior gluteal, & the ascending branch of the first perforating arteries, participate in the cruciate anastomosis posterior to the femoral neck, which also contributes to the arterial supply of the hip joint. The distal part of the femoral neck also receives arterial supply from the nutrient artery supplying the shaft of the femur.

Nerve Supply

The hip joint is supplied by the following nerves:

1. Femoral nerve via nerve to rectus femoris.
2. A branch from anterior division of obturator nerve.
3. A branch from accessory obturator nerve (if present).
4. A branch from nerve to quadratus femoris.

Movements

The hip joint is a multiaxial joint and permits the following movements:

- Flexion and extension, occurring around the transverse axis. Flexion is very free, it is only limited by contact of the thigh with the trunk. Extension is extremely limited by the iliofemoral ligament (medial fibers).
- Abduction and adduction, occurring around the anteroposterior axis. Abduction is restricted by the pubofemoral ligament, while adduction is restricted by the lateral fibers of the iliofemoral ligament.
- Medial and lateral rotation, occurring around the vertical axis (passing vertically through the center of the femoral head). Medial rotation is limited by the ischiofemoral ligament, while lateral rotation is limited by the pubofemoral ligament & the lateral fibers of the iliofemoral ligament.
- Circumduction (combination of the above movements).

See the table for the muscles producing the hip joint movements.

Clinical Applications:

Dislocation of the hip joint:

(a) Congenital dislocation: The congenital dislocation of the hip joint is more common than any other joint in the body. It occurs due to two reasons:

(i) The joint capsule is loose at birth.

(ii) Hypoplasia (defective development) of the acetabulum and femoral head: In this condition, the head of femur slips upward into the gluteal region because the upper margin of the acetabulum is developmentally deficient.

(b) Acquired dislocation: This is uncommon because this joint is very strong and stable. However, it may occur during car accidents when the hip joint is flexed & adducted as the person is sitting in the car. In this position, the joint is unstable because the femoral head is covered posteriorly by a joint capsule and not by the bone. During the accident, the knee usually strikes the dashboard, & thus the femur is pushed posteriorly against the capsule. The head of the femur is forced out of the acetabulum by tearing the capsule posteroinferiorly to lie on the lateral surface of the ilium. This causes shortening and medial rotation of the affected limb. The dislocation of the hip may be posterior (most common), anterior (less common), or central (least common). The sciatic nerve is injured in posterior dislocation.

Fractures of the neck of the femur:

These fractures are usually common in individuals of more than 60 years of age especially in females because their femoral necks become weak and brittle due to osteoporosis. The fractures of the neck of femur are of two types: intracapsular and extracapsular. The intracapsular fractures are further divided into:

(a) Subcapital (near the head). (b) Cervical (in the middle). (c) Basal (near the trochanters).

The retinacular vessels derived from the medial circumflex femoral artery supply most of the blood to the head and neck of the femur. Their damage often leads to avascular necrosis, such damage is maximum in the subcapital and least in the basal fractures. When the retinacular arteries are cut, the artery of the ligamentum teres cannot replace their blood supply.

The fracture of the neck of the femur often occurs due to indirect violence of the trivial nature. The person falls down and cannot get up. The affected limb is much shortened and rotated laterally.

• *Referred pain of the hip joint: In diseases of the hip joint such as tuberculosis, the pain is referred to the knee joint because of the common nerve supply of these two joints.*

• *Aspiration of the hip joint: It is usually done by putting a needle 5 cm below the anterior superior iliac spine, upward, backward, and medially.*