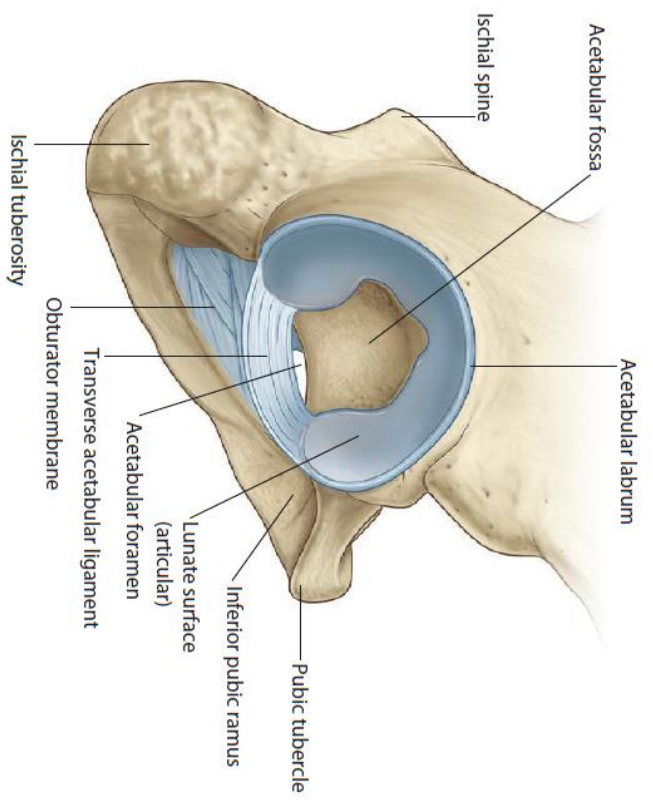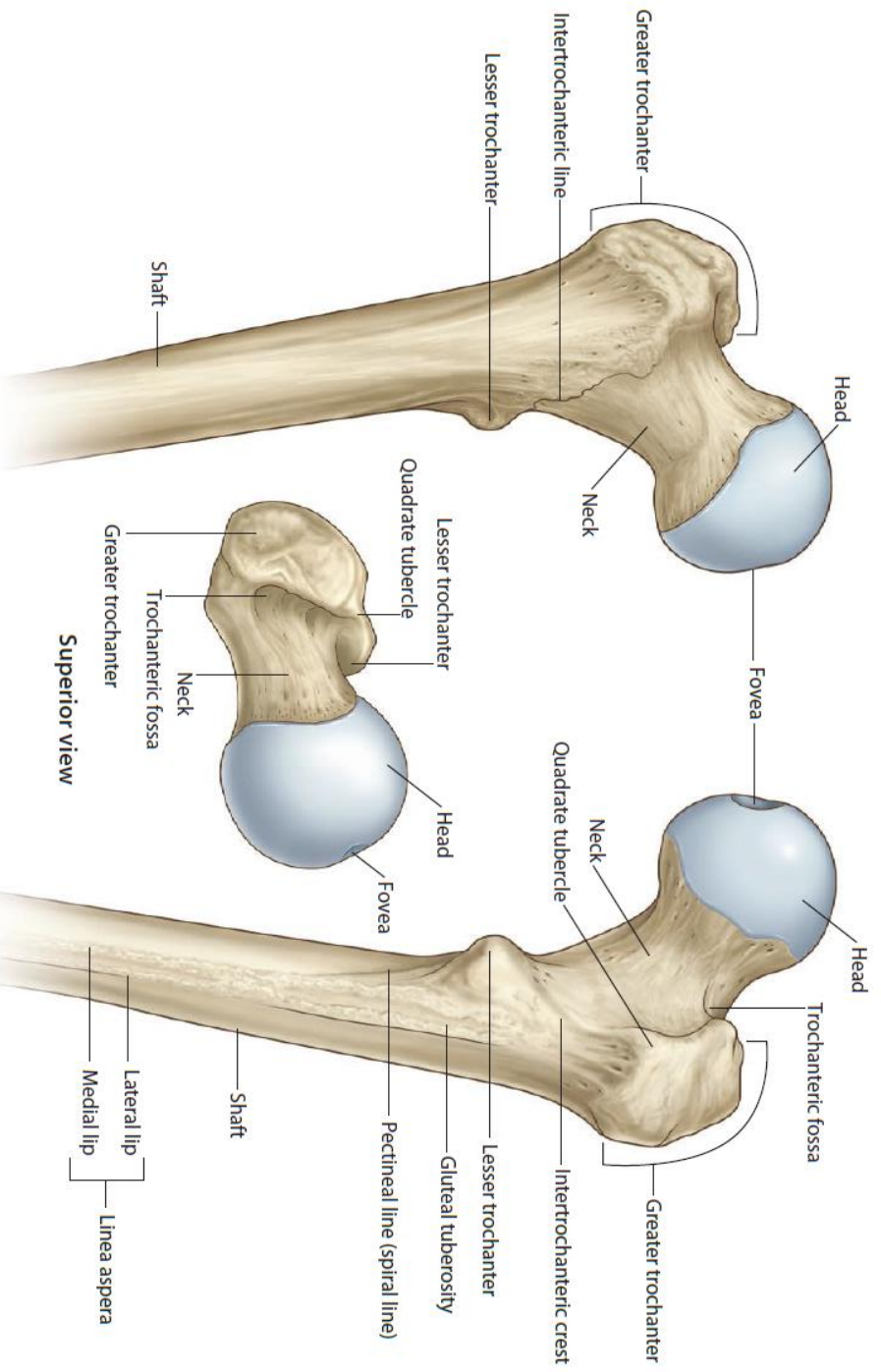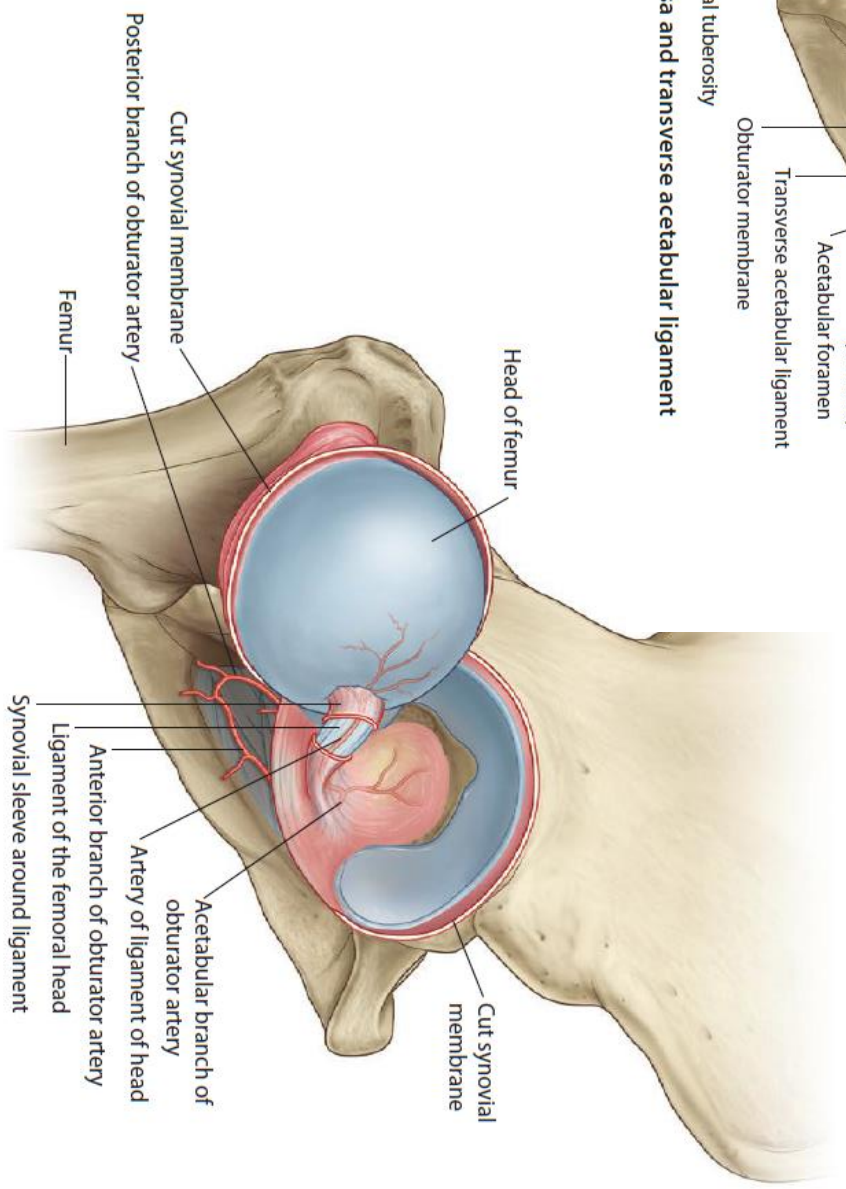
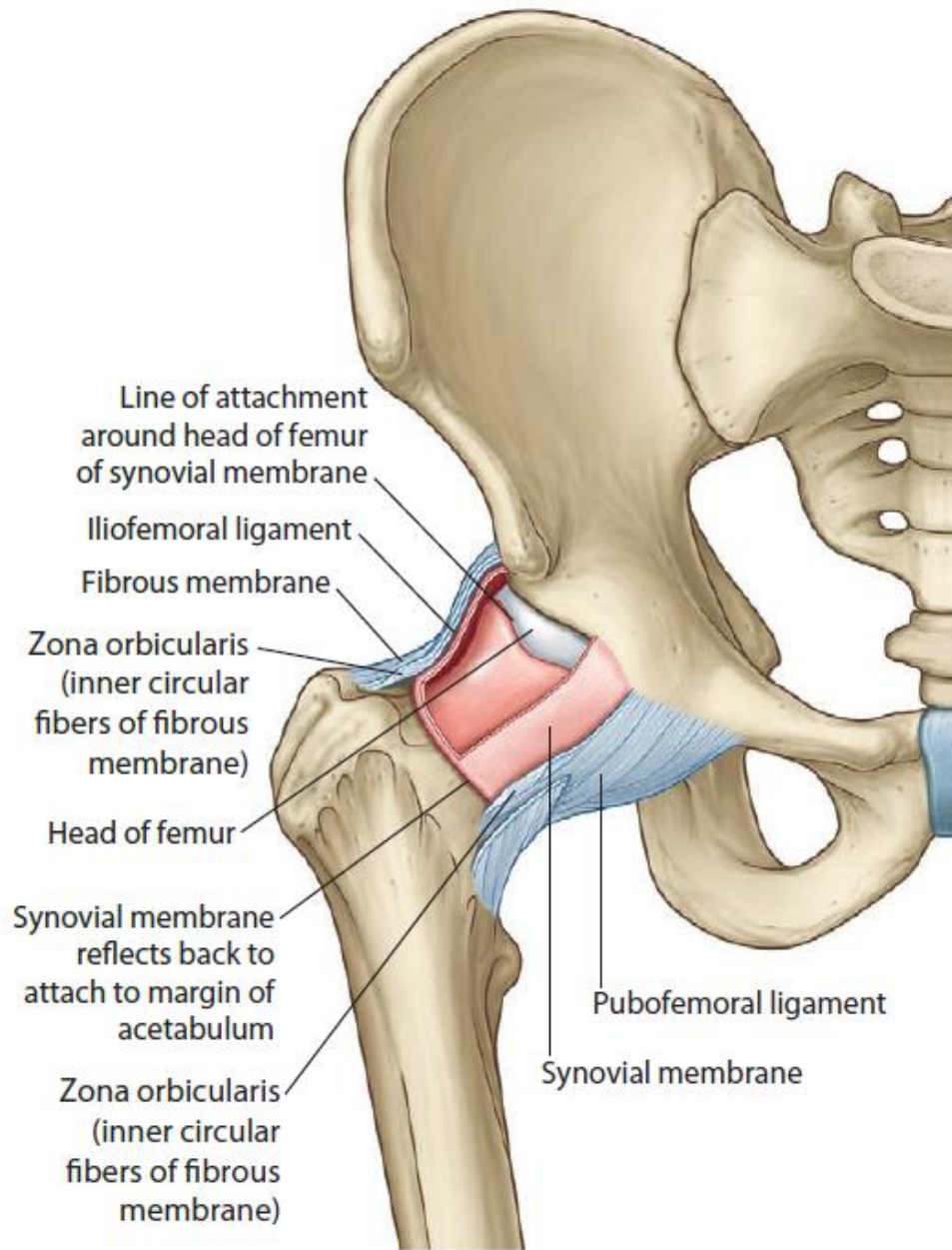


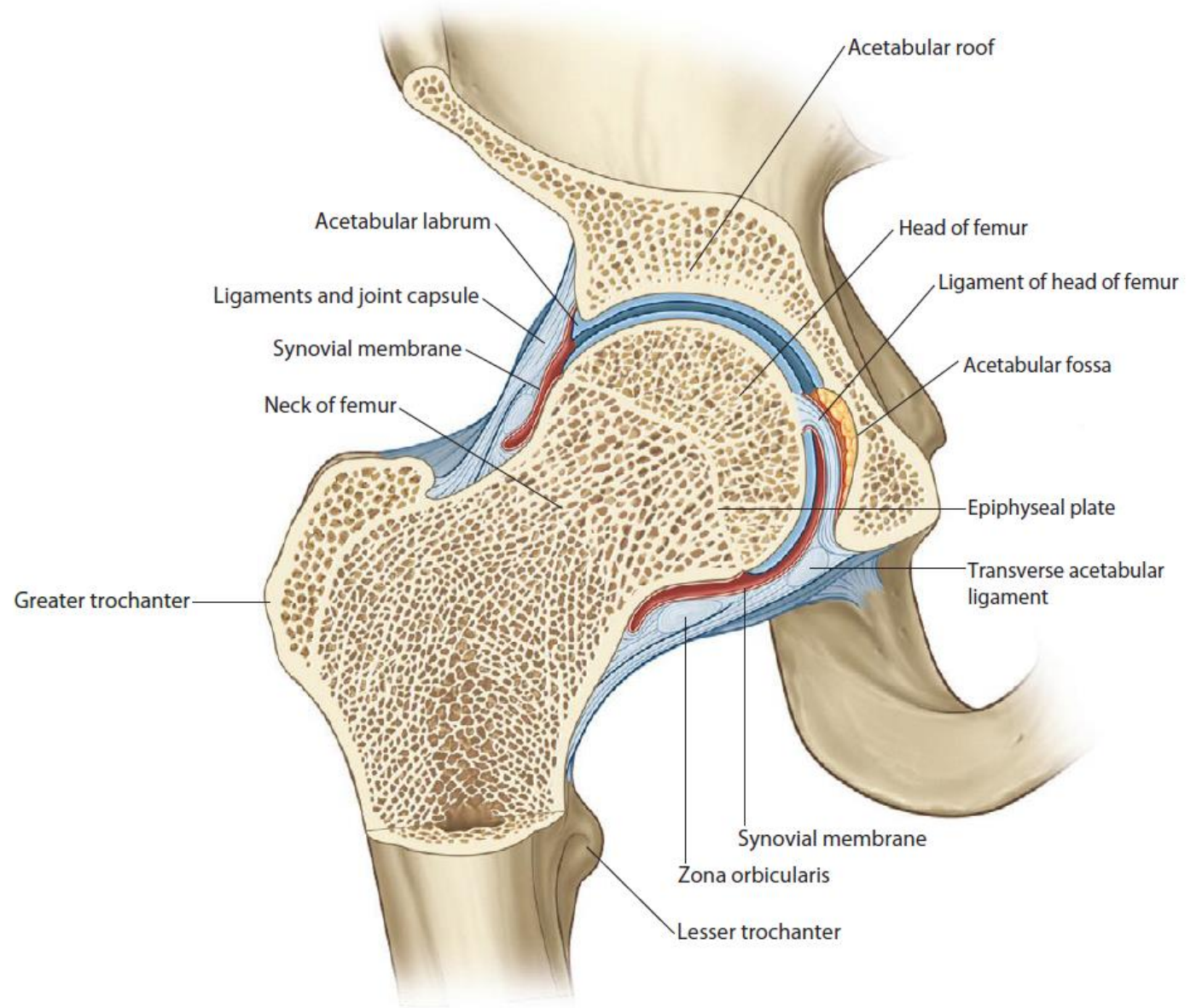
**Acetabular fossa and transverse acetabular ligament**



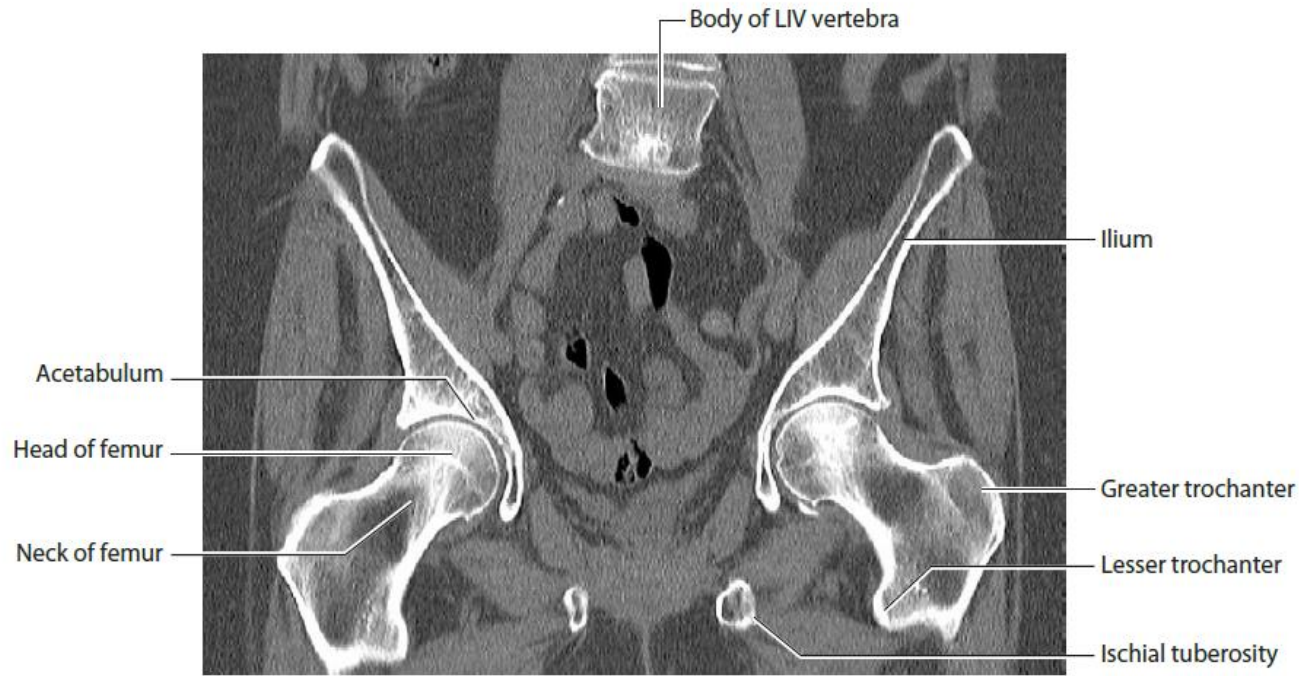




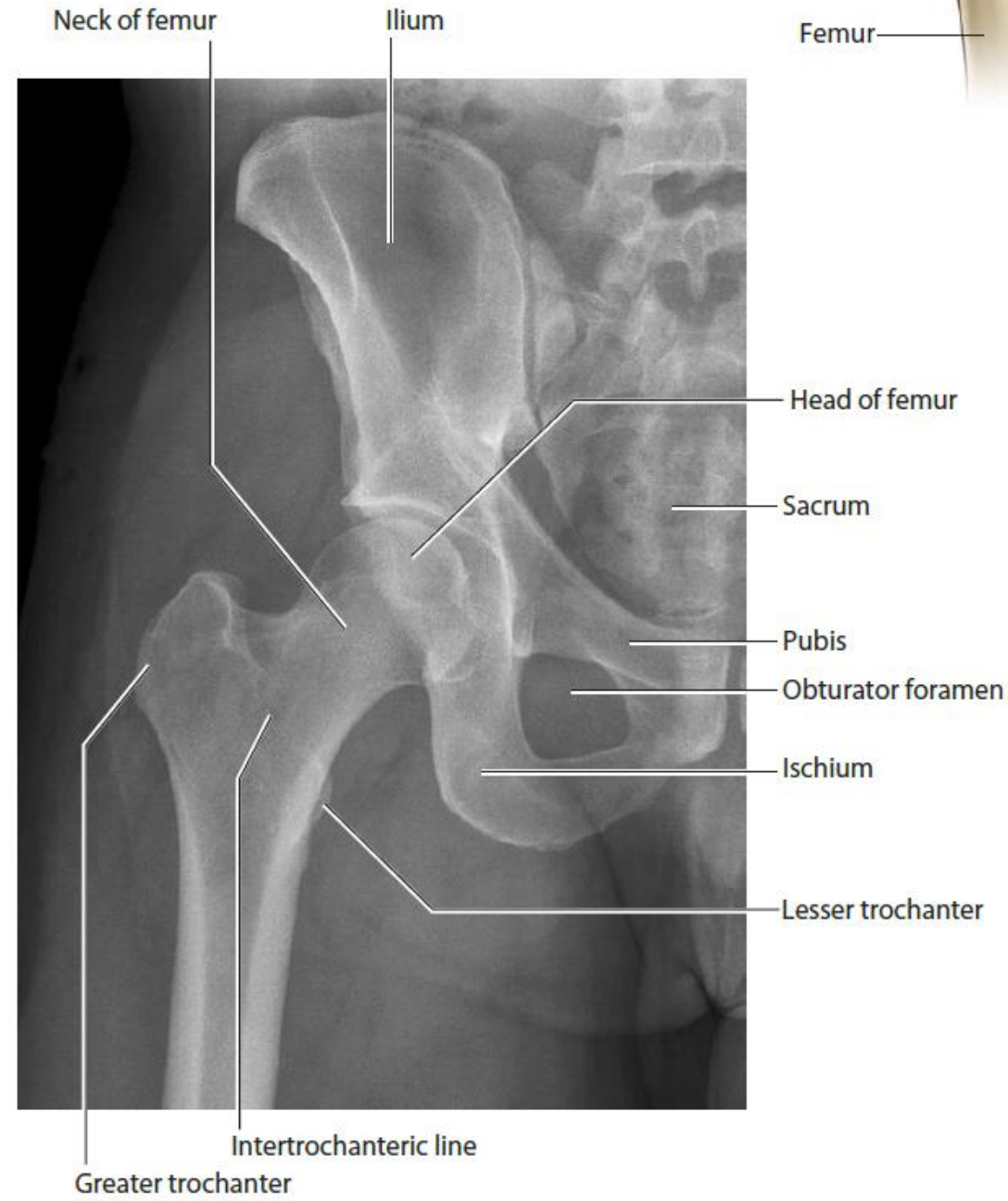
Joint capsule and synovial membrane



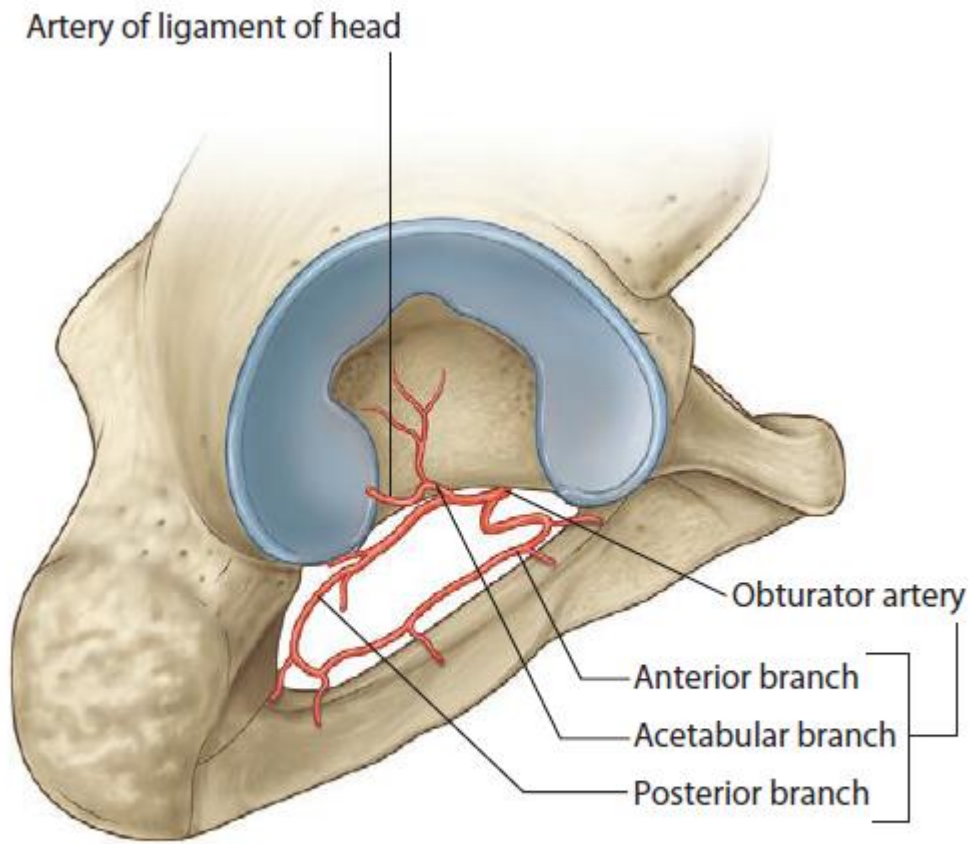
Coronal section through hip joint



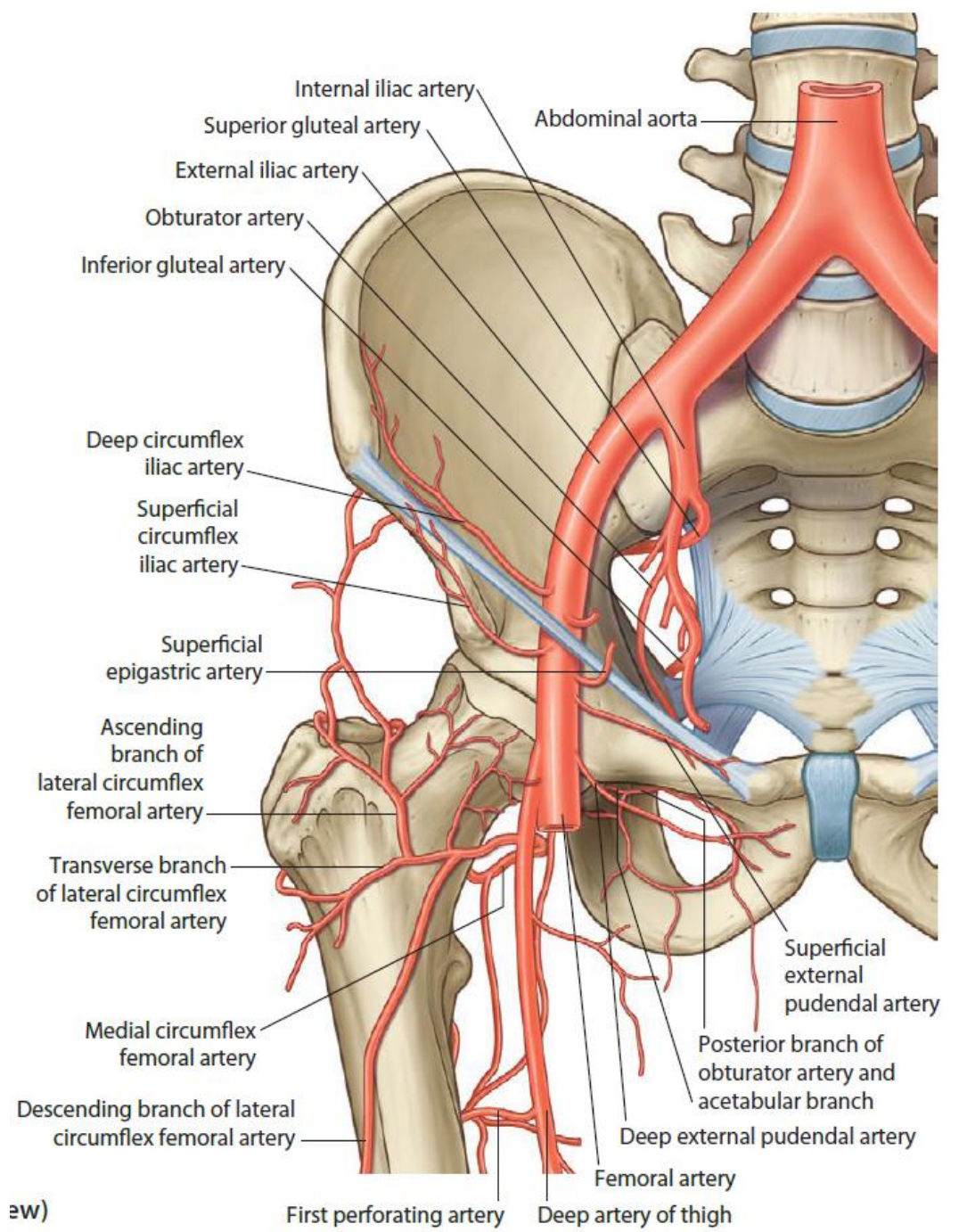
**Hip joints.**  
CT image in coronal plane





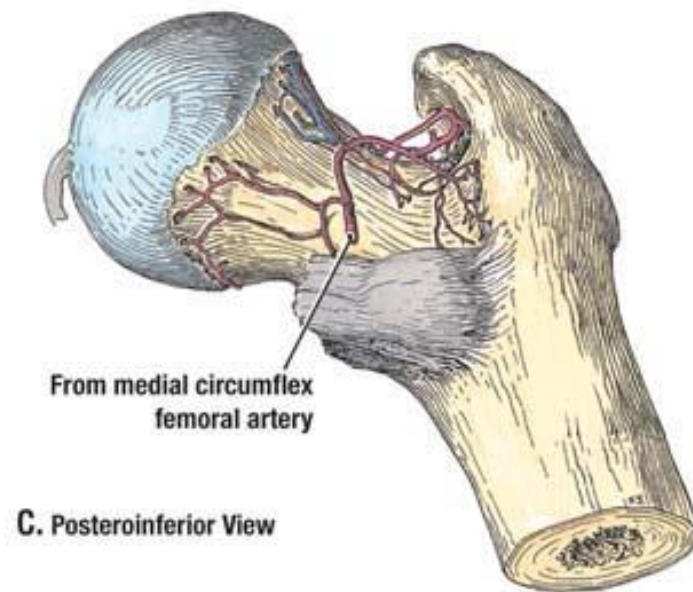
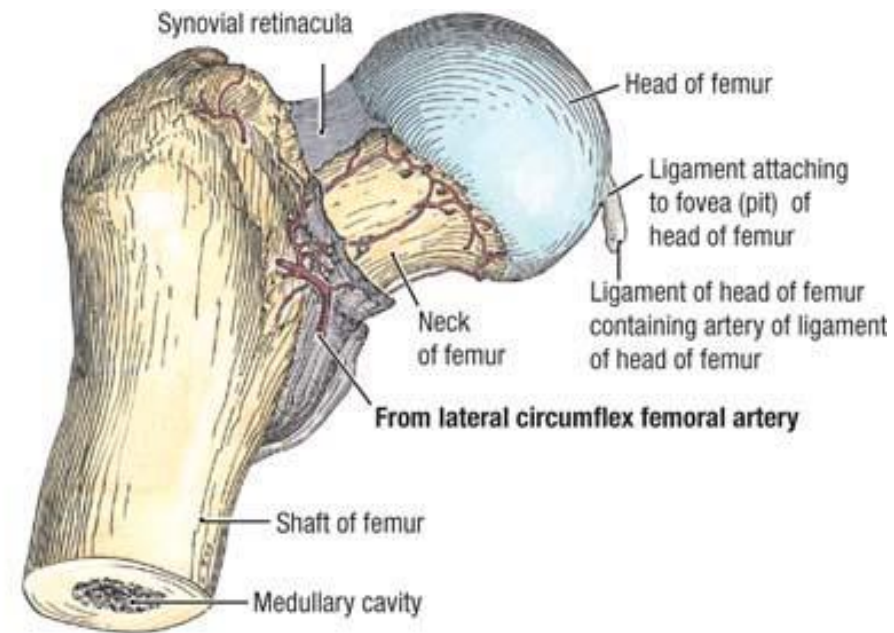
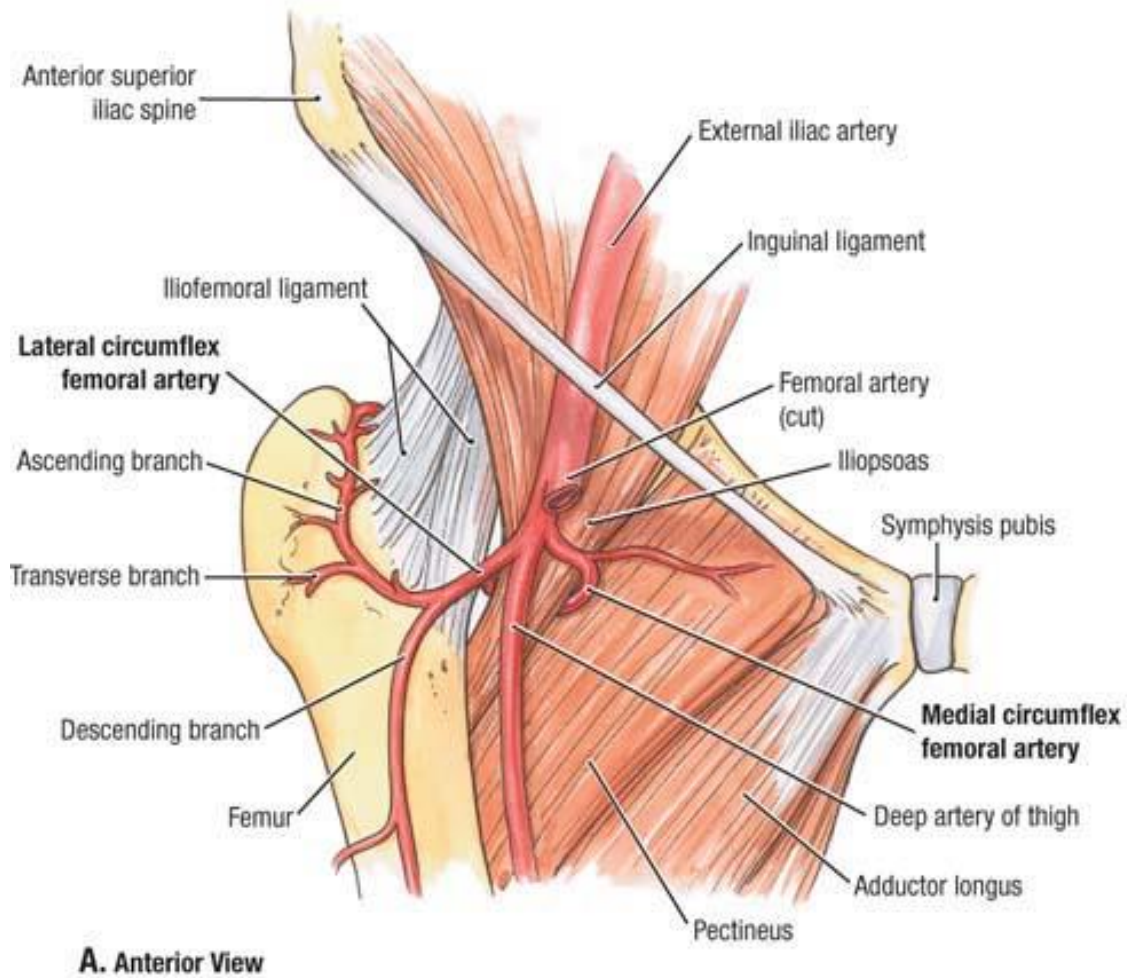


**Obturator artery and branches**



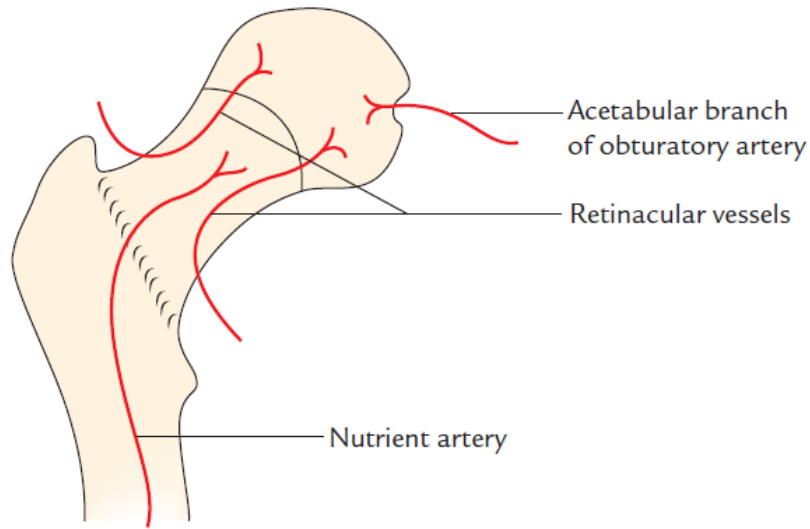
aw)

**Arterial supply of the hip joint**

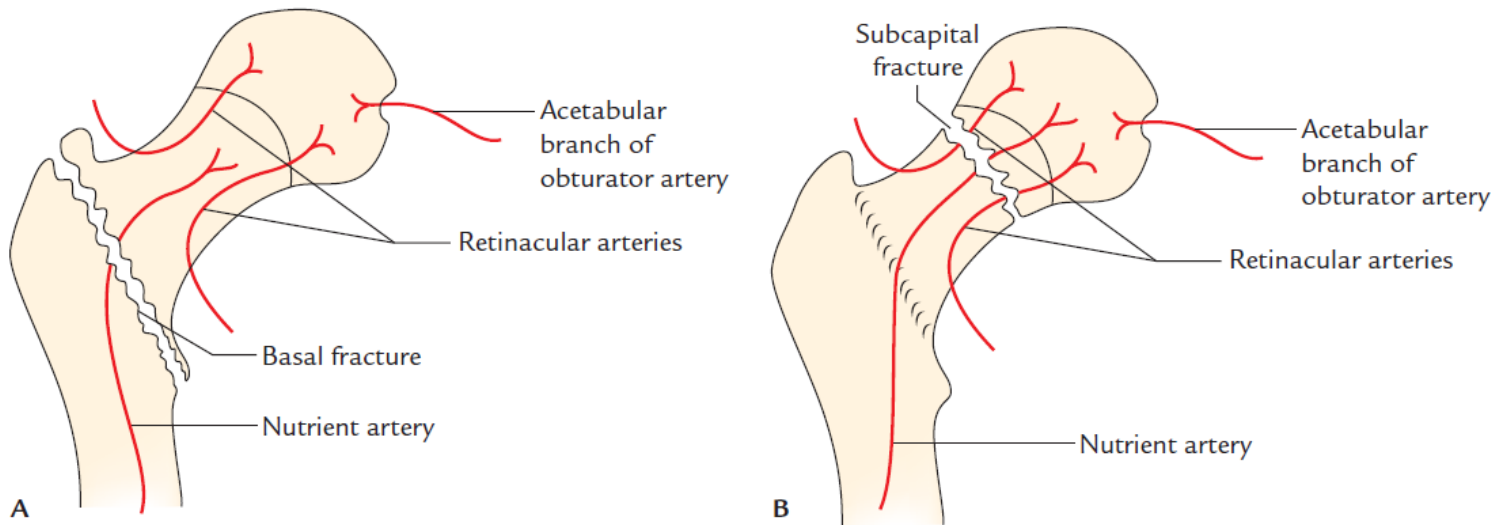
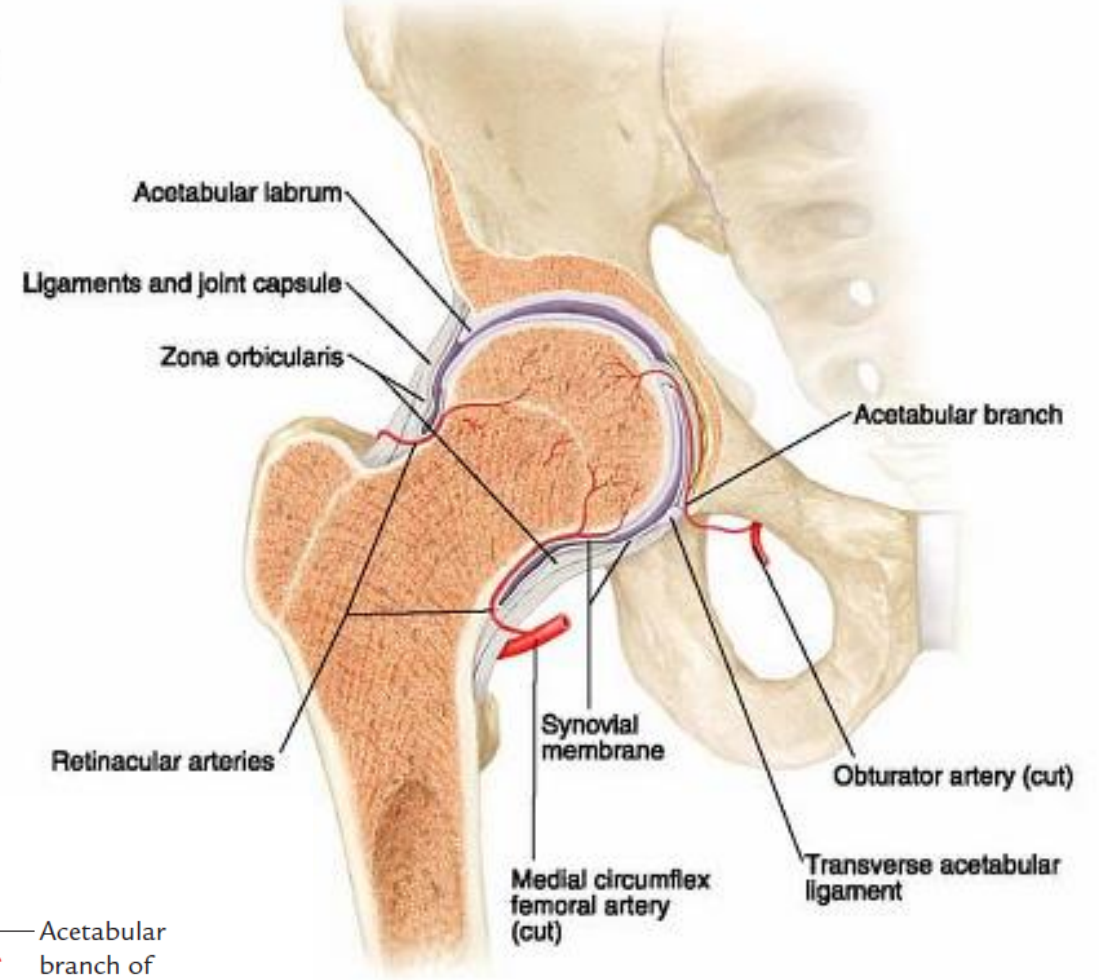




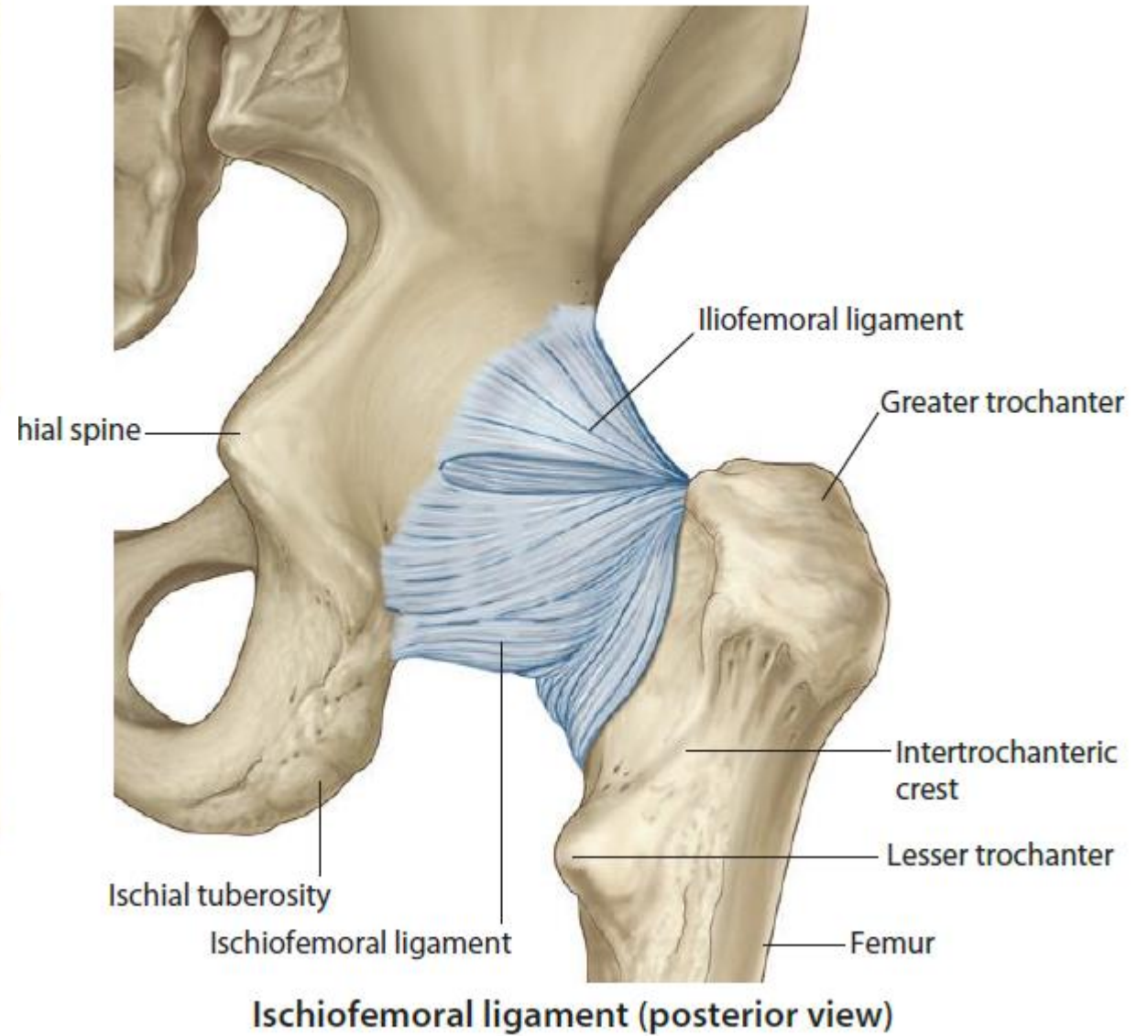
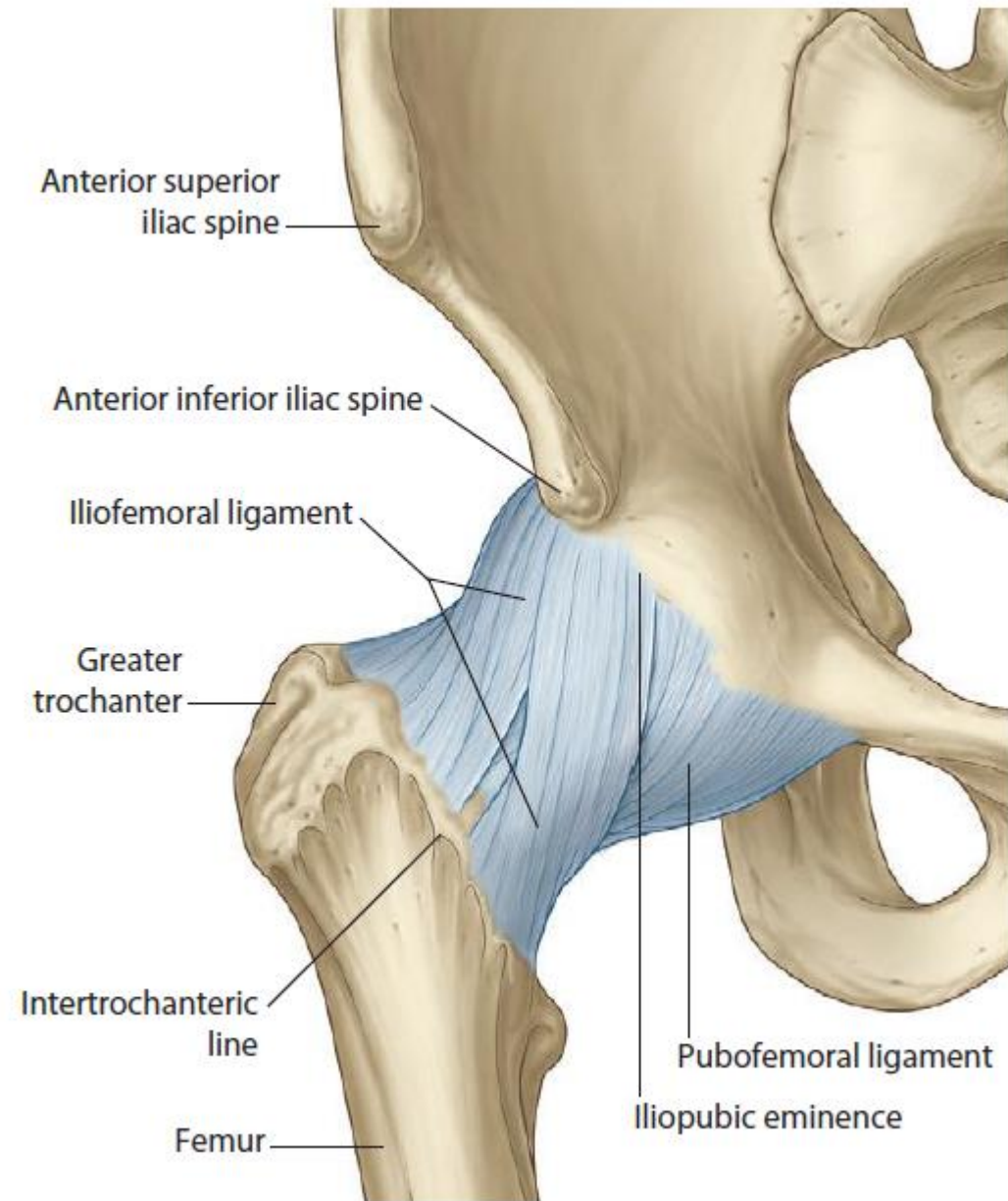
## Blood supply



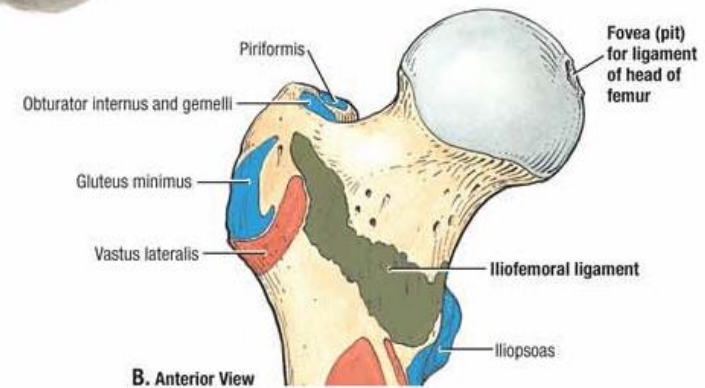
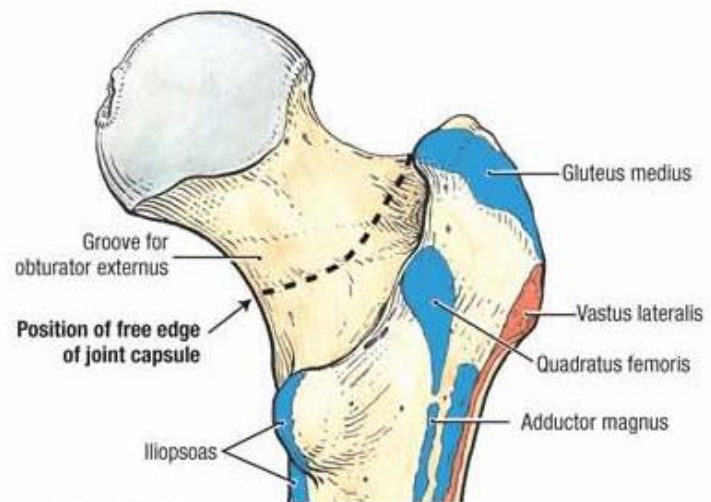
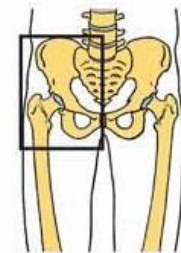
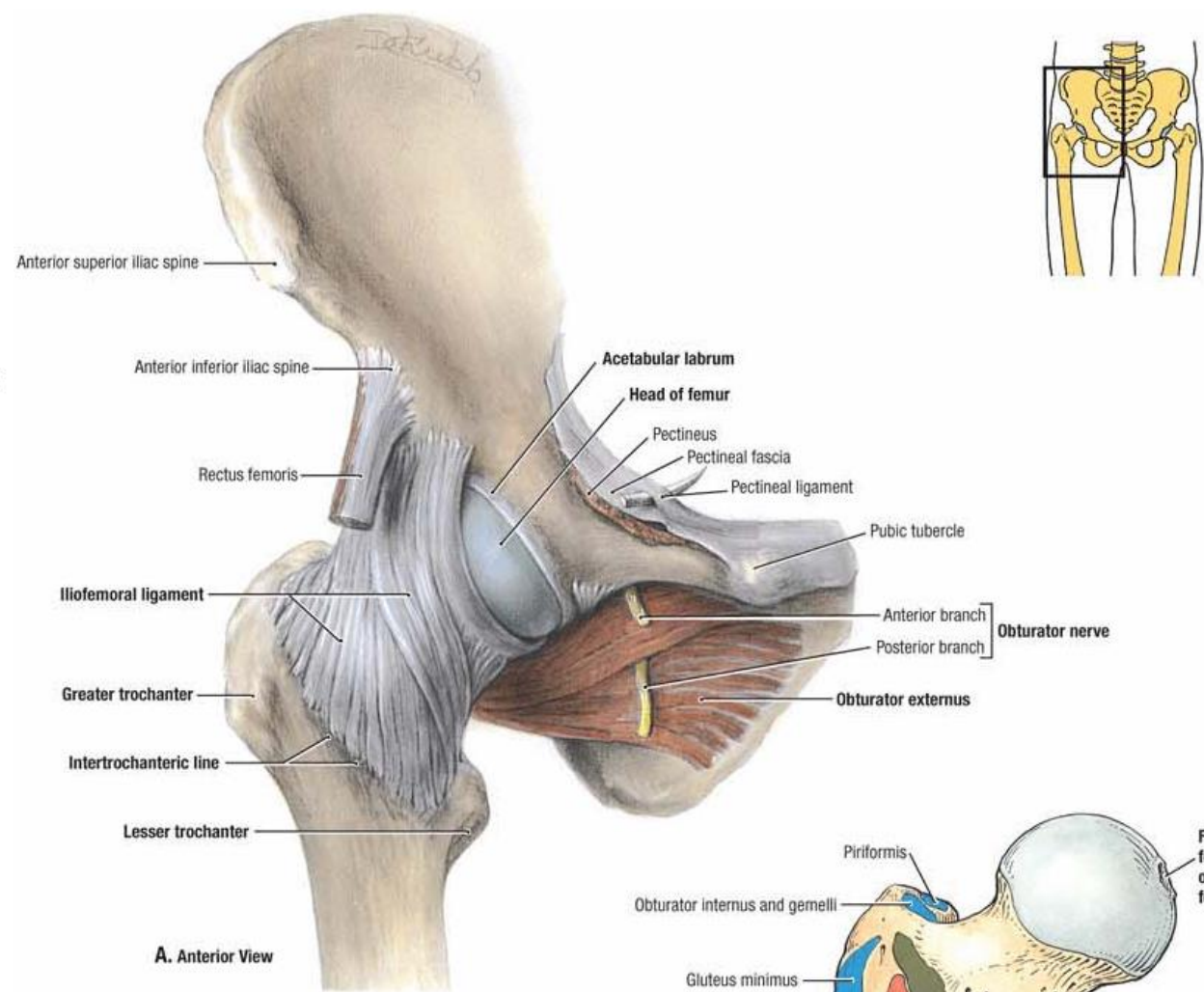
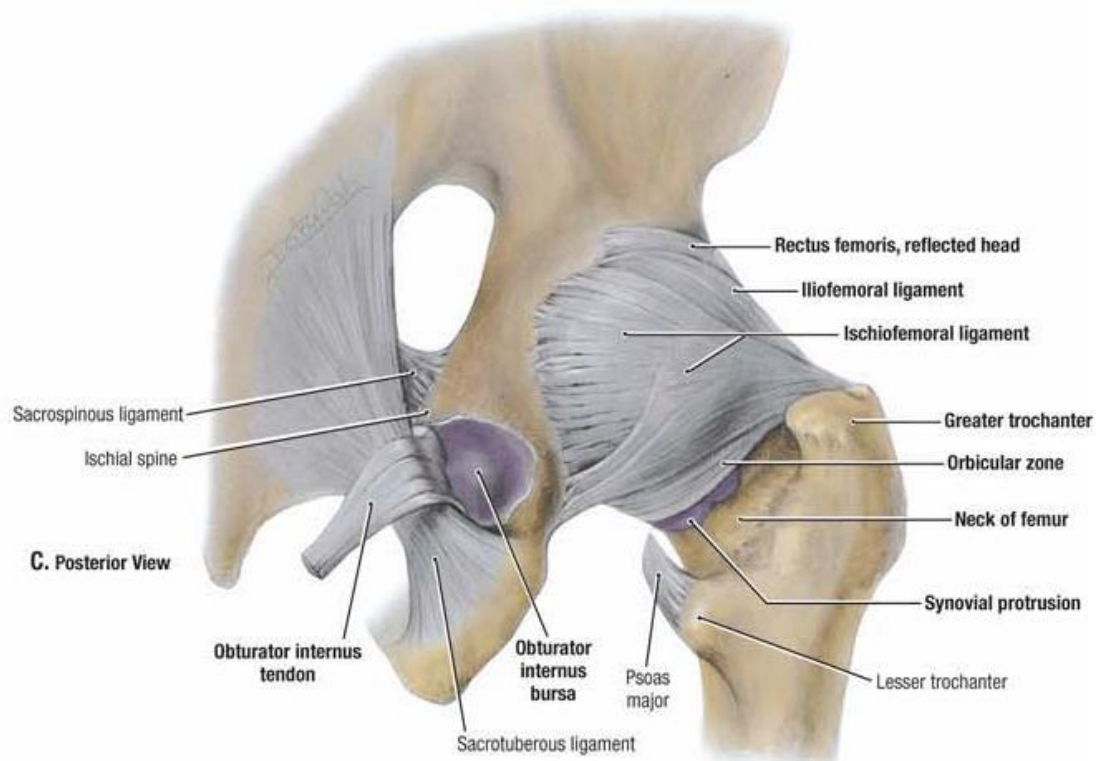
**Fig. 26.10** Arterial supply of the head of femur.



**Fig. 26.11** Involvement of arteries supplying the head of femur: **A**, in basal fracture of the neck of femur; **B**, in subcapital fracture of the neck of femur.



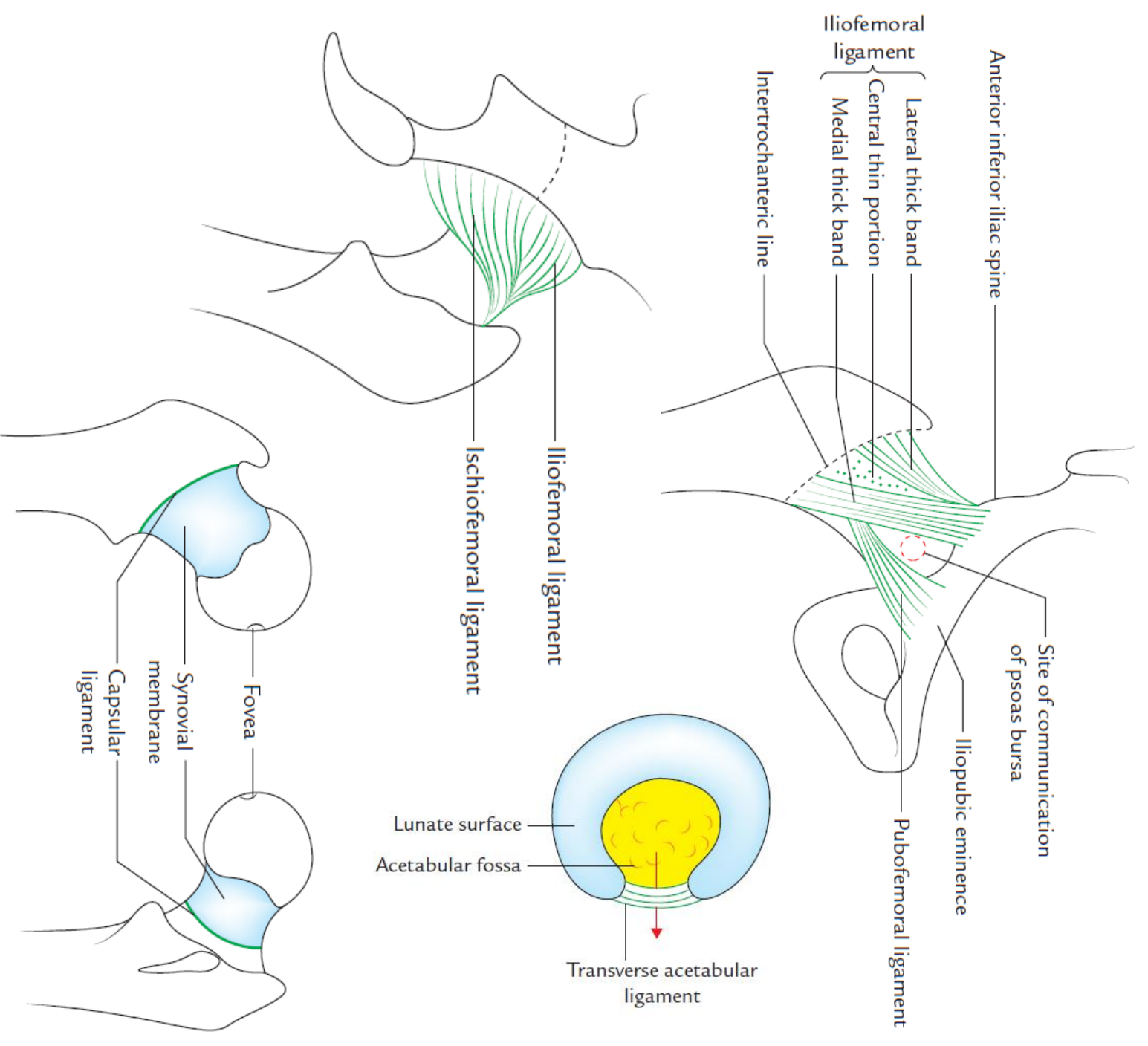




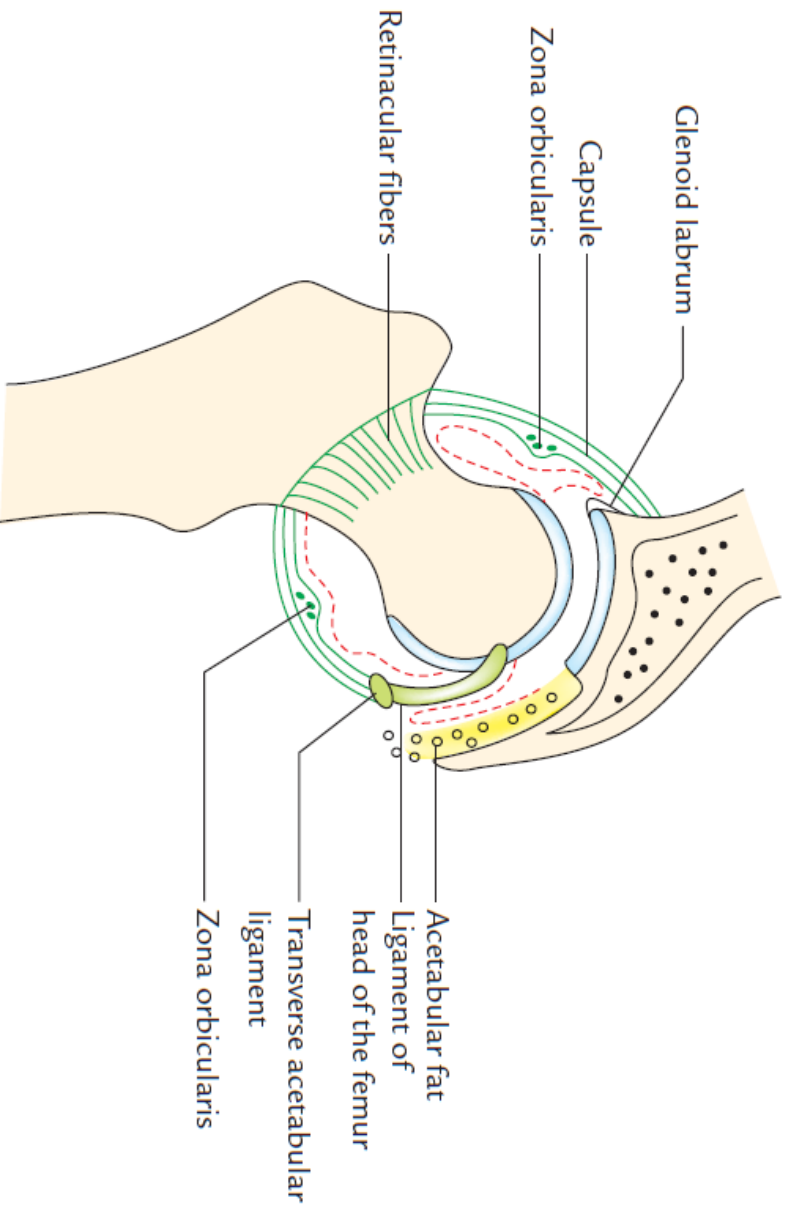
**D. Posterior View**

**A. Anterior View**

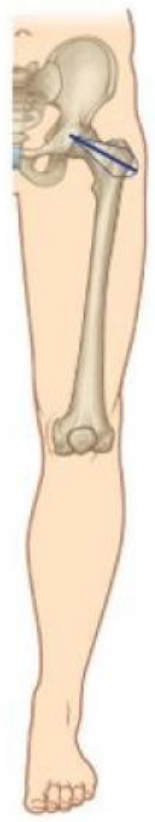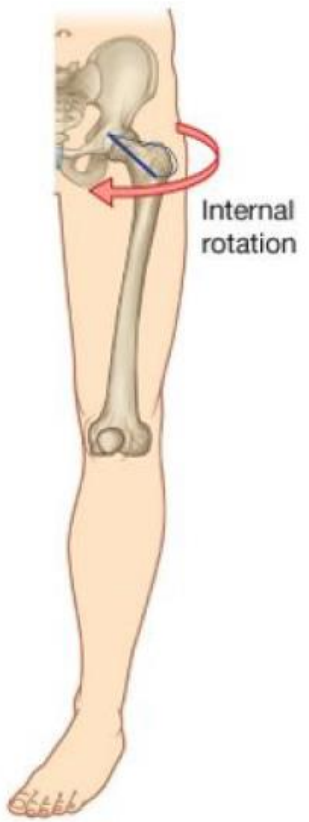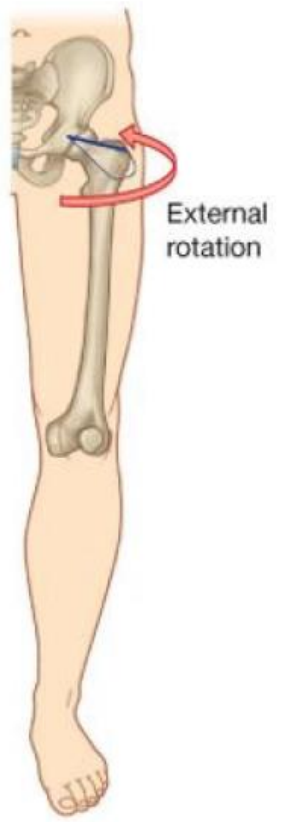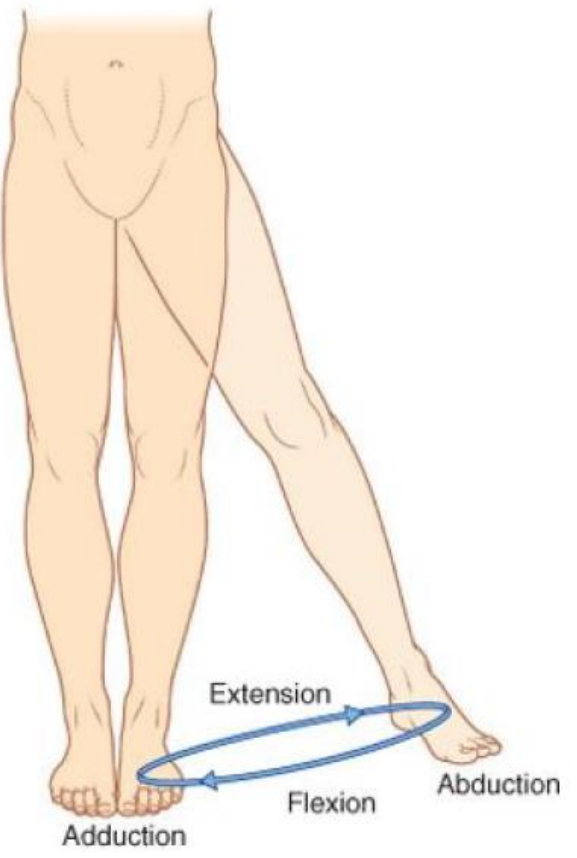
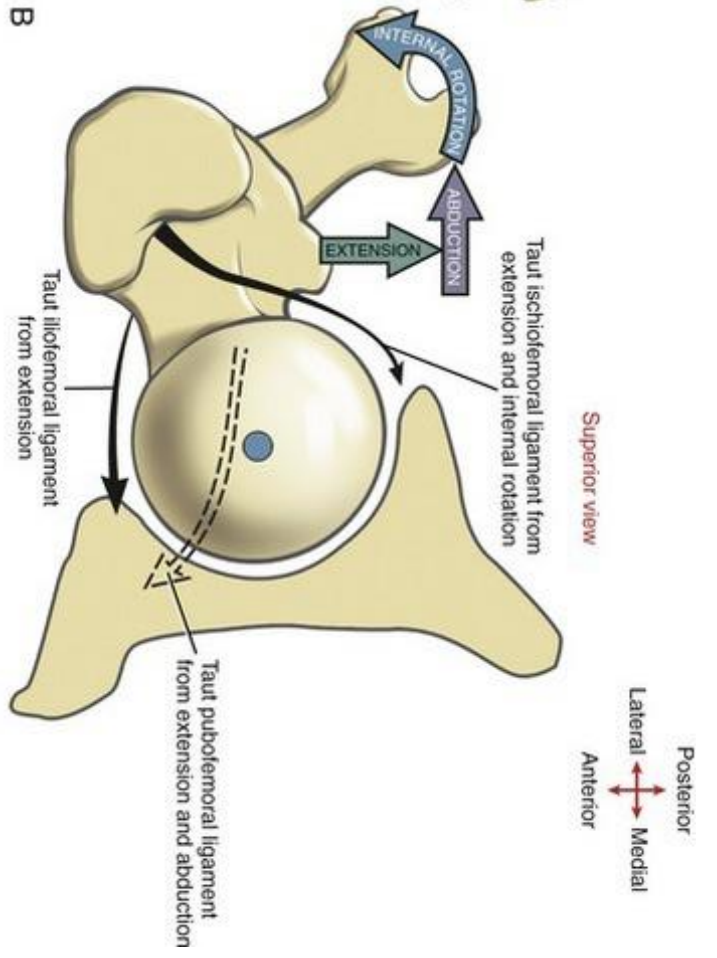
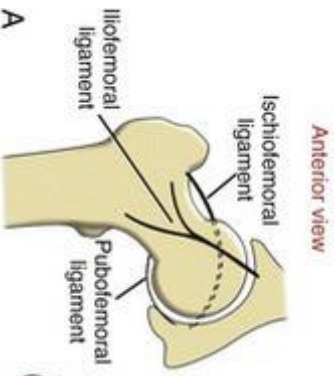
**B. Anterior View**



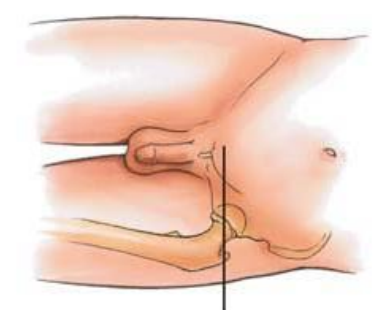
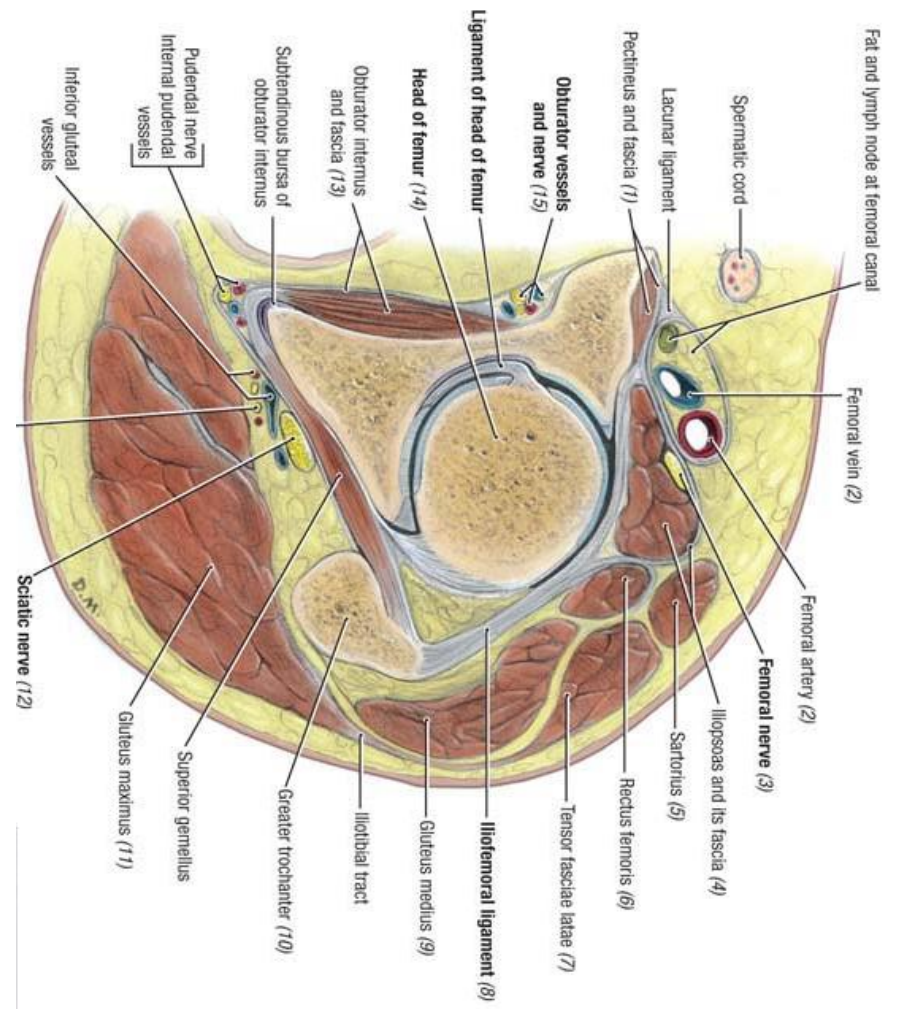
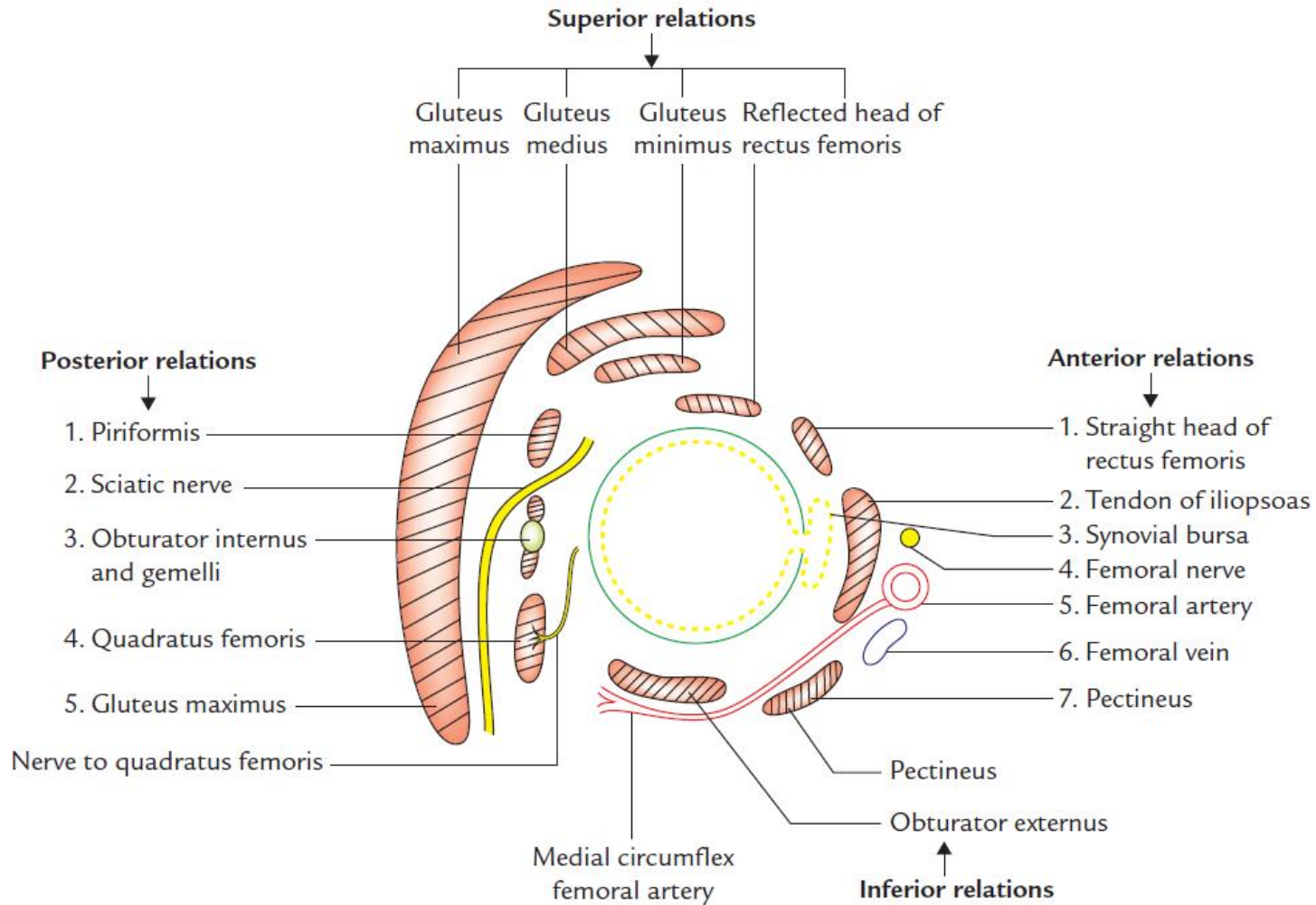
**Fig. 26.3** Attachment of the capsular ligament of hip joint on the femur.



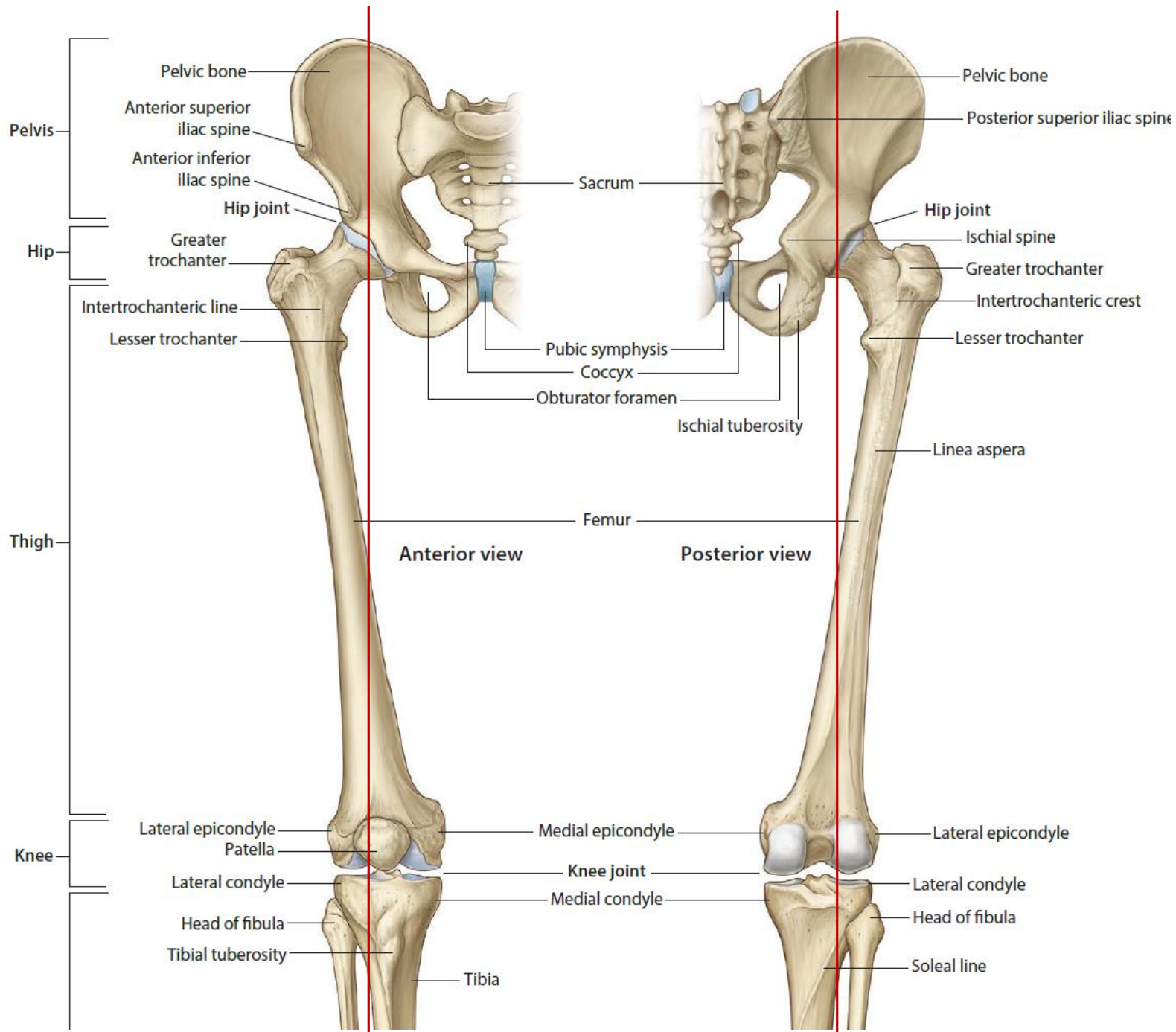




# Relations:







Movement	Main Acting Muscles	Accessory Muscles	Root Value
Flexion	Iliopsoas, rectus femoris, sartorius, tensor fasciae latae	Adductor group of muscles	L1, L2, L3
Extension	Gluteus maximus, hamstring muscles	Posterior (hamstring) part of adductor magnus	L5, S1
Abduction	Gluteus medius, gluteus minimus, tensor fasciae latae		L4, L5
Adduction	Adductor muscles (brevis, longus, & magnus), gracilis, pectineus	Obturator externus	L2, L3
Medial rotation	Anterior parts of Gluteus medius & gluteus minimus, tensor fasciae latae	Adductor muscles (longus, brevis, & magnus)	L4, L5
Lateral rotation	Deep group of gluteal region muscles, obturator externus, gluteus maximus		L5, S1

