

Biology

Dr.Khalida Ibrahim

Muscle Tissue

Classification of skeletal muscle fibers

Muscle fibers are classified into three main categories:

***Type I or slow, red oxidative fibers:** contain many mitochondria and abundant myoglobin, a protein with iron groups that bind O₂ and produce a dark red color. Red fibers derive energy primarily from aerobic oxidative phosphorylation of fatty acids and are adapted for slow, continuous contractions over prolonged periods, as required for example in the postural muscles of the back.

***Type IIa or fast, intermediate oxidative-glycolytic fibers:** have many mitochondria and much myoglobin, but also have considerable glycogen. They utilize both oxidative metabolism and anaerobic glycolysis and are intermediate between the other fiber types both in color and in energy metabolism. They are adapted for rapid contractions and short bursts of activity, such as those required for athletics.

***Type IIb or fast, white glycolytic fibers:** have fewer mitochondria and less myoglobin, but abundant glycogen, making them very pale in color. They depend largely on glycolysis for energy and are adapted for rapid contractions, but fatigue quickly. They are typically small muscles with a relatively large number of neuromuscular junctions, such as the muscles that move the eyes and digits.

Muscles are characterized according to the predominance of the fiber types. Red muscle ("red meat") is dominated by type I fibers. White muscle ("white meat") is dominated by type IIb fibers. Most muscles are a mosaic of all the muscle types. The gross color reflects the differing proportions of the muscle types.

Atypical Striated Muscle

Some striated muscles of the body with typical histological appearance of striated muscle, are involuntary muscles. An example of such involuntary striated muscle is the cremaster muscle (near the spermatic cord).

In some cases striated muscles are not really "skeletal" as they are not attached to the skeleton (e.g. esophageal striated muscle, external urethral sphincter, external anal sphincter).

Practical Summary: Skeletal muscle fibres bear obvious striations, have many peripherally located nuclei, are of the same thickness throughout their length and do not branch.

CARDIAC MUSCLE

Cardiac muscle is also striated, but differs from the striated skeletal muscle in several respects:

- The muscle **fibers branch** (bifurcate) and are arranged in series to form an anastomosing network.
- Each myocyte has one or two **central nuclei** (unlike the many peripheral nuclei of syncytia of skeletal muscle fibers).
- The fibers have more sarcoplasm.
- The mitochondria are larger and better developed.
- **All the fibers are Type I** (red fibers, with abundant myoglobin).
- **Glycogen** may also present.
- The myocytes have specialized areas of contact - the **intercalated disks**.
- **Contractions are rhythmic, spontaneous and involuntary.**

The cross striations have a similar morphology and staining characteristics to those of skeletal muscle fibers, however the contractile tissue is not organized into discrete myofibrils. At the ultrastructural level sarcomeres are found similar to those of skeletal muscle fibers. The large mitochondria are arranged in rows between the strings of sarcomeres. In aged cardiac muscle, **lipofuscin** is also commonly found.

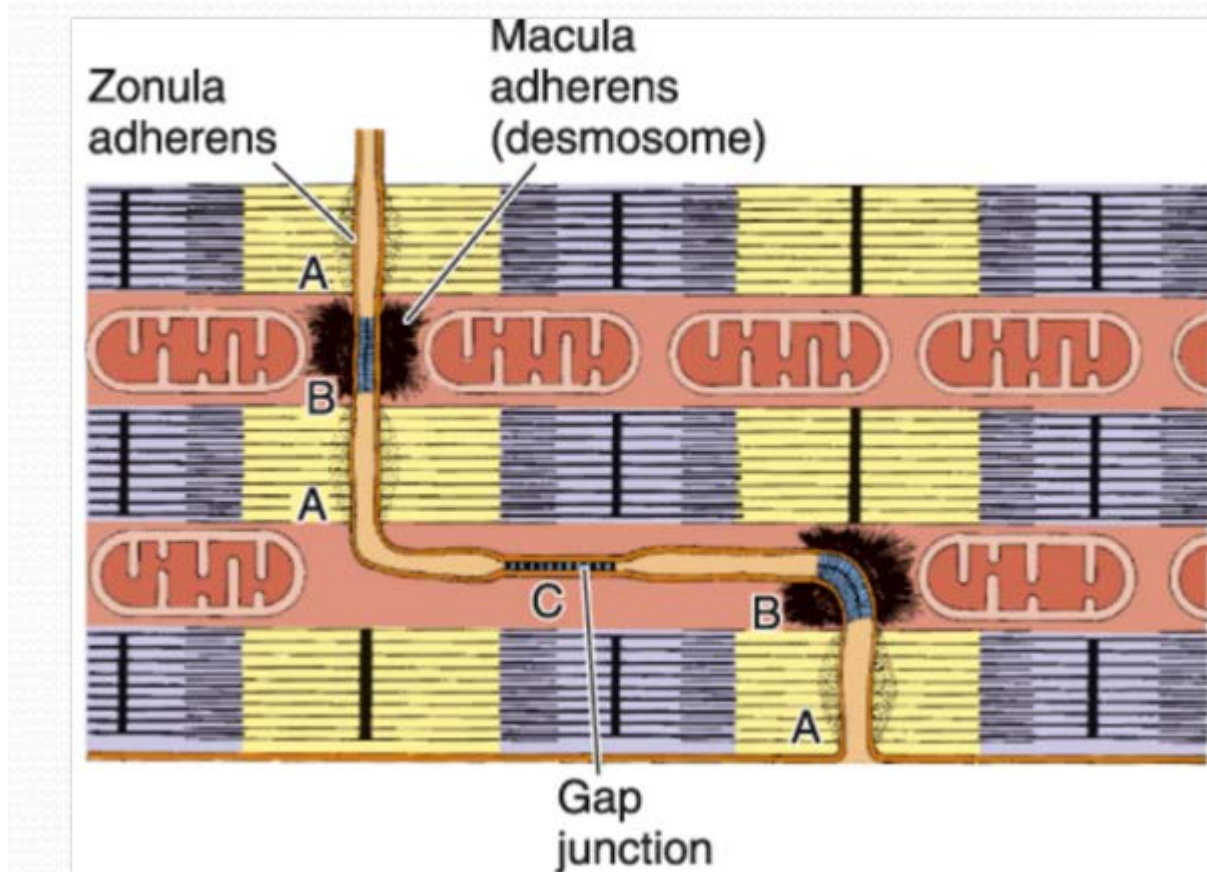
Cardiac myocytes also possess a system of **T-tubules**. These consist of fairly broad tubular sarcoplasmic invaginations (single) so called **diad**, which terminate in the region of the Z-line of the sarcomeres. In general the sarcoplasmic reticulum of cardiac muscle fibers is much less well developed than that of myofibers of skeletal muscle.

Intercalated disks

These are step-like areas of interdigitation between adjacent sarcomeres. At the ultrastructural level the intercalated disks are seen to have two main components:

- **transverse regions (riser)**, rich in desmosomes and fascia adheretes. These are important in providing good cell adhesion between adjacent myocytes.
- **longitudinal regions (step)**, parallel to the direction of the myofilaments. These regions have many gap junctions, which are areas of low electrical resistance and permit the spread of excitation from myocyte to myocyte.

Calcium ions play important roles in the areas of intercalated disks.



SMOOTH MUSCLE

Smooth muscle is also known as "**involuntary muscle**", as contraction is not under conscious control. Smooth muscle is innervated by the **autonomic nervous system**.

Smooth muscle lacks cross-striations (unlike striated and cardiac muscle).

Location of smooth muscle

- Smooth muscle is found in the **walls of the hollow internal organs**
- **walls of blood vessels** (vascular smooth muscle, especially in arterial vessels).
- Smooth muscle is found in the **dermis of the skin** (arrector pili).
- Smooth muscle is found in the eye (**iris diaphragm**, controlling the amount of light reaching the retina).

Structure of smooth muscle fibers

The smooth muscle fibers (**myocytes**) are **spindle-shaped** (fusiform).

The nucleus is in the widest part of the fiber and is elongated, typically with several nucleoli. In cross section, the nucleus will be evident only when the section cuts through the widest part of the myocyte.

The length of the myocytes is very variable in different organs. In some cases, such as in the uterus during pregnancy, the length can reach 500 μ m. In some cases, such as in small arterioles, the length may be only about 20 μ m.

In most organs, the smooth muscle fibers are orderly arranged in layers, strips or bundles. In cross section, the smooth muscle fibers are seen to form an orderly mosaic of circles of varying diameters, with the nuclei being seen only in fibers sectioned at their widest region. After regular staining (H&E) the sarcoplasm is seen to be acidophilic (stained with eosin).

Smooth muscle sheath

Each individual fiber is surrounded by a **sheath** (secreted by the fiber itself). The sheath contains proteoglycans, that stain positively with PAS reaction. A network of **reticular fibers** (shown after silver impregnation techniques) is found in the sheath and provides mechanical support for the fibers. In addition the sheath has **collagen fibrils** and **elastin fibers**.

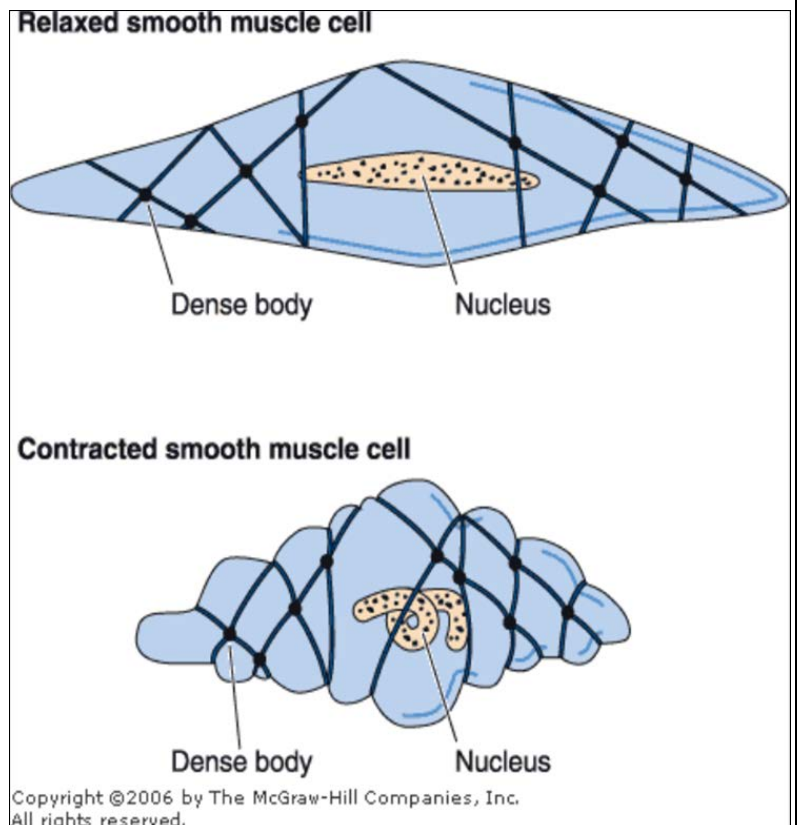
Smooth muscle cells lack an endomysium. The sheath is not the equivalent of an endomysium as in striated muscle. The sheath lacks connective tissue cells and blood vessels.

The ultrastructure of smooth muscle cells shows that the sheath appears somewhat similar to the basal lamina of epithelial cells. The organelles are located close to the nucleus in two distinct poles. The rest of the sarcoplasm is filled with **myofilaments**, though these are not arranged in ordered sarcomeres as in striated muscle. Three types of myofilaments may be seen:

1. **thin myofilaments (actin)** which are the most common type
2. **thick myofilaments (myosin)** which are less common

3. **intermediate filaments (desmin)** These may be grouped as "dense bodies" and are also found in contact with the sarcolemma (attachment plaques of thin and intermediate filaments that are functionally similar to Z disc of skeletal and cardiac muscles). It is thought that these intermediate filaments provide some sort of structural support for the cells.

The contraction mechanism of smooth muscle cells is still not very clear. The actin and myosin do not appear to be regularly arranged. Myosin is present in relatively low amounts. The myocytes lack a T-system, though the sarcolemma has numerous small fixed saccules, known as caveolae. These caveolae may possibly have a role analogous to that of the T-system of striated muscle.



Origin of smooth muscle

Like the other muscle types, smooth muscle is also derived from **mesoderm**. Some researchers believe that smooth muscle has some affiliation to the connective tissue cells derived from mesenchyme, because the fibers synthesize and secrete collagen, elastin and reticulin of the sheath. They consider the smooth muscle fibers as connective tissue cells that have evolved the capacity of contractility.

Some glands of ectodermal origin, such as sweat glands or mammary glands, possess smooth muscle cells surrounding their secretory units (**myoepithelial cells**). These myoepithelial cells are ectodermal in origin.

Some sites of the body show an intermingling of smooth muscle fasciculi, with those of skeletal muscle (e.g. part of the esophagus, anal sphincter, tarsi of eyelids).

Repair and regeneration after injury

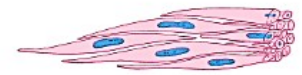
Skeletal muscles: If muscles are used intensively, trained or exercised, they increase in mass as a result of increase in protein synthesis and sarcomere production. This results in **hypertrophy of use** ("Use it or lose it"). On the contrary, limb immobilization (e.g. in plaster casts, or as a result of inactivity due to hospitalization, or lack of gravity) causes loss of muscle mass (**disuse myopathy** or **atrophy**).

Myofibers are syncytial and post-mitotic, with very limited regenerative abilities after trauma. After trauma such as muscle crush, pathological changes occur in muscle and may lead to breakdown of myofibers and release of myoglobin, which can affect renal function and be life-threatening. In the limited repair processes, satellite cells are activated, divide and can form new myotubes and myocytes. In some cases the satellite cells can fuse with existing fibers and contribute to the repair processes.

Cardiac muscles: There is virtually no regeneration of cardiac tissue because the lack of satellite progenitor cells of muscle cells. The coronary arteries supplying blood to the heart are anatomical end arteries and lack collaterals. In the event of blockage of coronary arteries (as a result of a blood clot or atherosclerotic blockage), the cardiac myocytes vascularized by the coronaries cannot receive essential oxygen and the result is infarct. Following infarcts, the remaining heart muscle undergoes compensatory hypertrophy, with subsequent enlargement of the heart, have no ability to regenerate ending with a non-contractile fibrous scar.

Hypertrophied hearts are commonly an indication of underlying pathological disorders, though they may develop in specific cases of training and overload as in athletes.

Smooth muscle: has the ability to undergo hyperplasia and hypertrophy (as in the uterus of pregnant women). Smooth muscle can also regenerate, and this is important in the repair processes of injured blood vessels.

Skeletal**Cardiac****Smooth****Structural features**

Muscle cell	Large, elongate cell, 10–100 μm in diameter, up to 100 cm in length (sartorius m.)	Short, narrow cell, 10–15 μm in diameter, 80–100 μm in length	Short, elongate, fusiform cell, 0.2–2 μm in diameter, 20–200 μm in length
Location	Muscles of skeleton visceral striated (e.g., tongue, esophagus, diaphragm)	Heart, superior and inferior vena cava, pulmonary veins	Vessels, organs, and viscera
Connective tissue components	Epimysium, perimysium, endomysium	Endomysium (subendocardial and subpericardial connective tissue)	Endomysium, sheaths, and bundles
Fiber	Single skeletal muscle cell	Linear branched arrangement of several cardiac muscle cells	Single smooth muscle cell
Striation	Present	Present	None
Nucleus	Many peripheral	Single central, surrounded by juxtannuclear region	Single central
T tubules	Present at A-I junction (triad: with two terminal cisternae), two T tubules/sarcomere	Present at Z lines (diad: with small terminal cisternae), one T tubule/sarcomere	None, well-developed sER, many invaginations and vesicles similar to caveolae
Cell-to-cell junctions	None	Intercalated discs containing 1. Fasciae adherentes 2. Macula adherens (desmosome) 3. Gap junctions	Gap junctions (nexus)
Special features	Well-developed sER and T tubules	Intercalated discs	Dense bodies, caveolae, and cytoplasmic vesicles
Functions			
Type of innervation	Voluntary	Involuntary	Involuntary
Efferent innervation	Somatic	Autonomic	Autonomic
Type of contraction	"All or none" (type I and type II fibers)	"All or none" rhythmic (pacemakers, conductive system of the heart)	Slow, partial, rhythmic, spontaneous contractions (pacemakers of stomach)
Regulation of contraction	By binding of Ca^{2+} to TnC, causes tropomyosin movement and exposes myosin-binding sites on actin filaments	By binding of Ca^{2+} to TnC, causes tropomyosin movement and exposes myosin-binding sites on actin filaments	By phosphorylation of myosin light chain by myosin light chain kinase in the presence of Ca^{2+} -calmodulin complex
Growth and regeneration			
Mitosis	None	None (in normal condition)	Present
Response to demand	Hypertrophy	Hypertrophy	Hypertrophy and hyperplasia
Regeneration	Limited (satellite cells and myogenic cells from bone marrow)	None (in normal condition)	Present