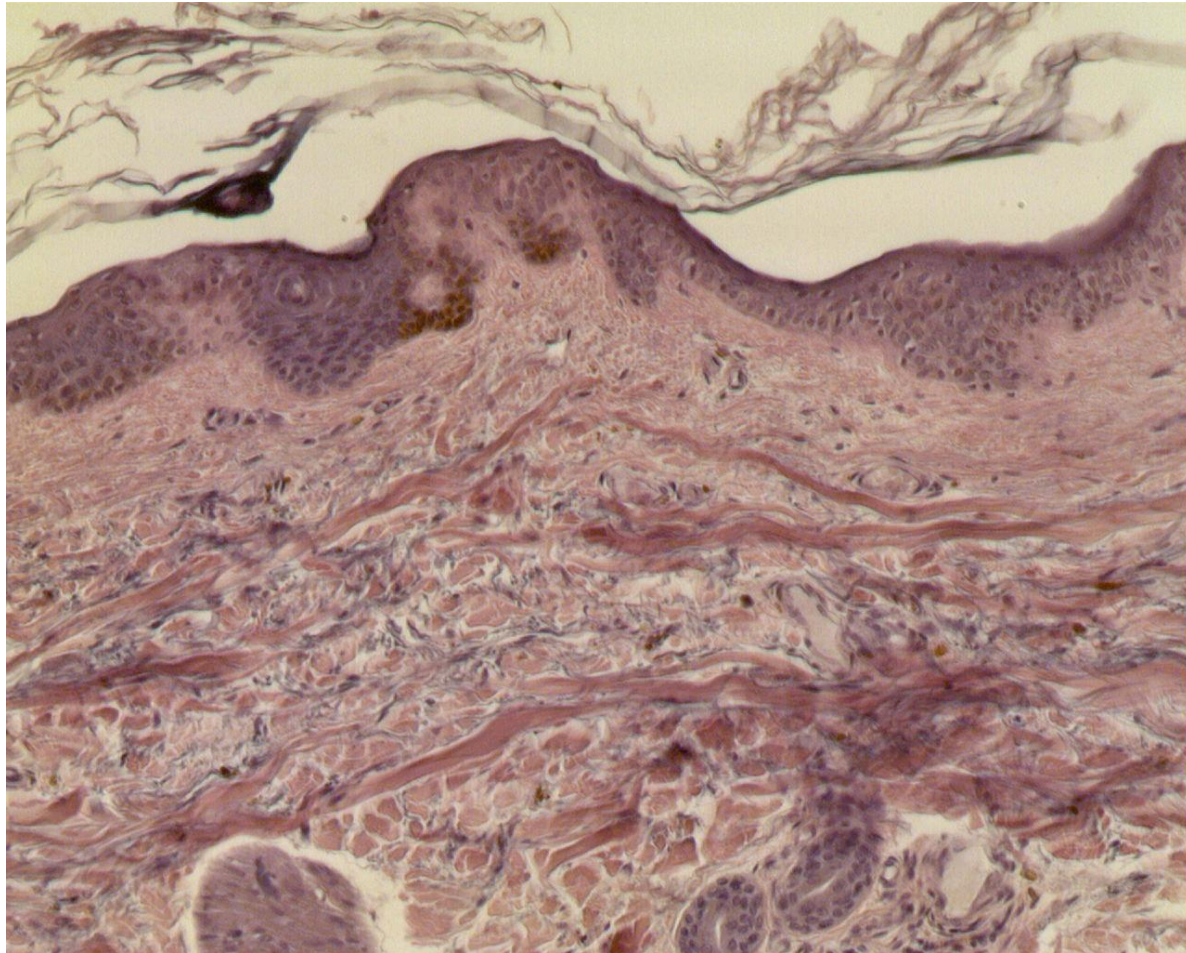
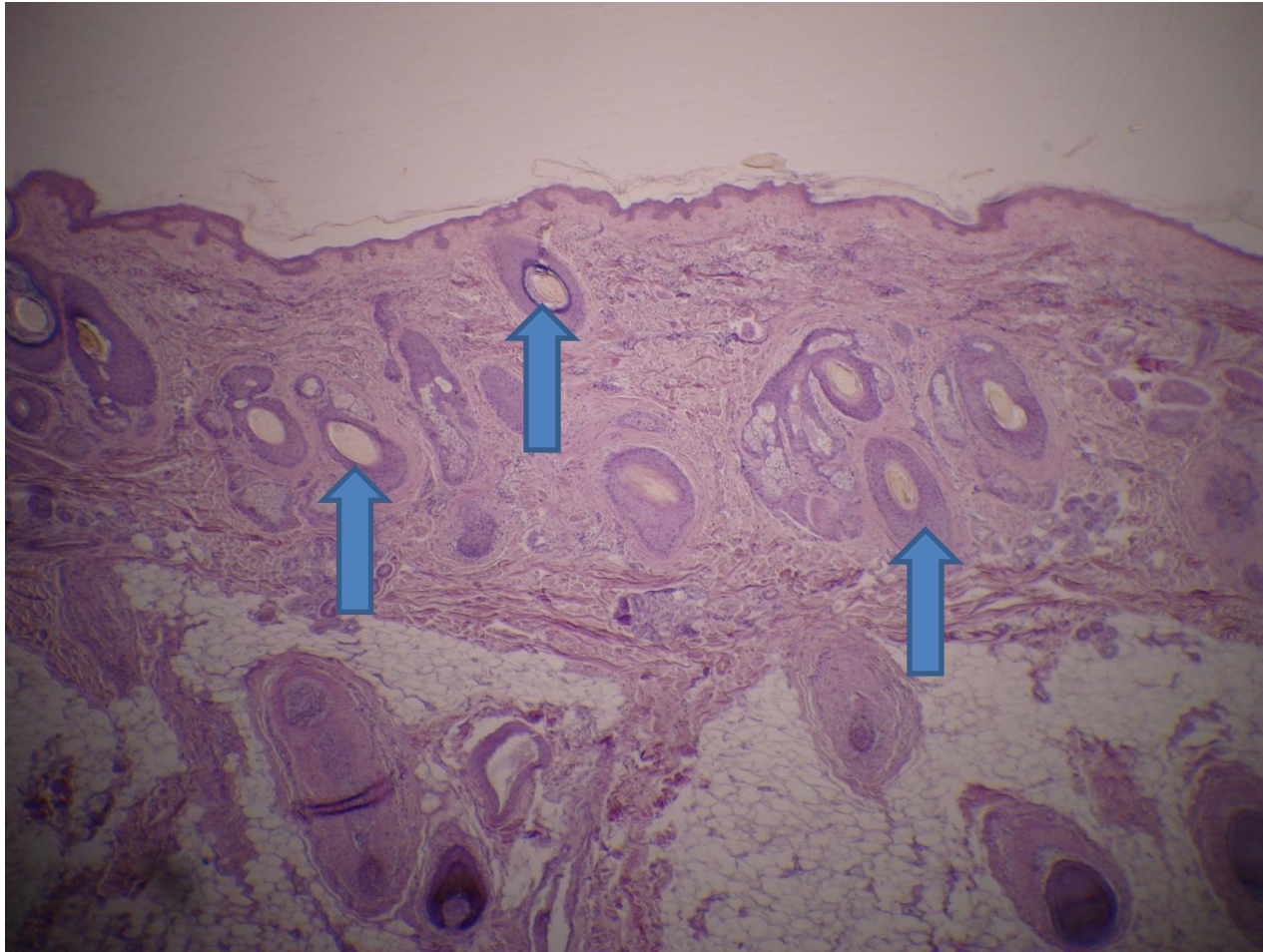


Skin

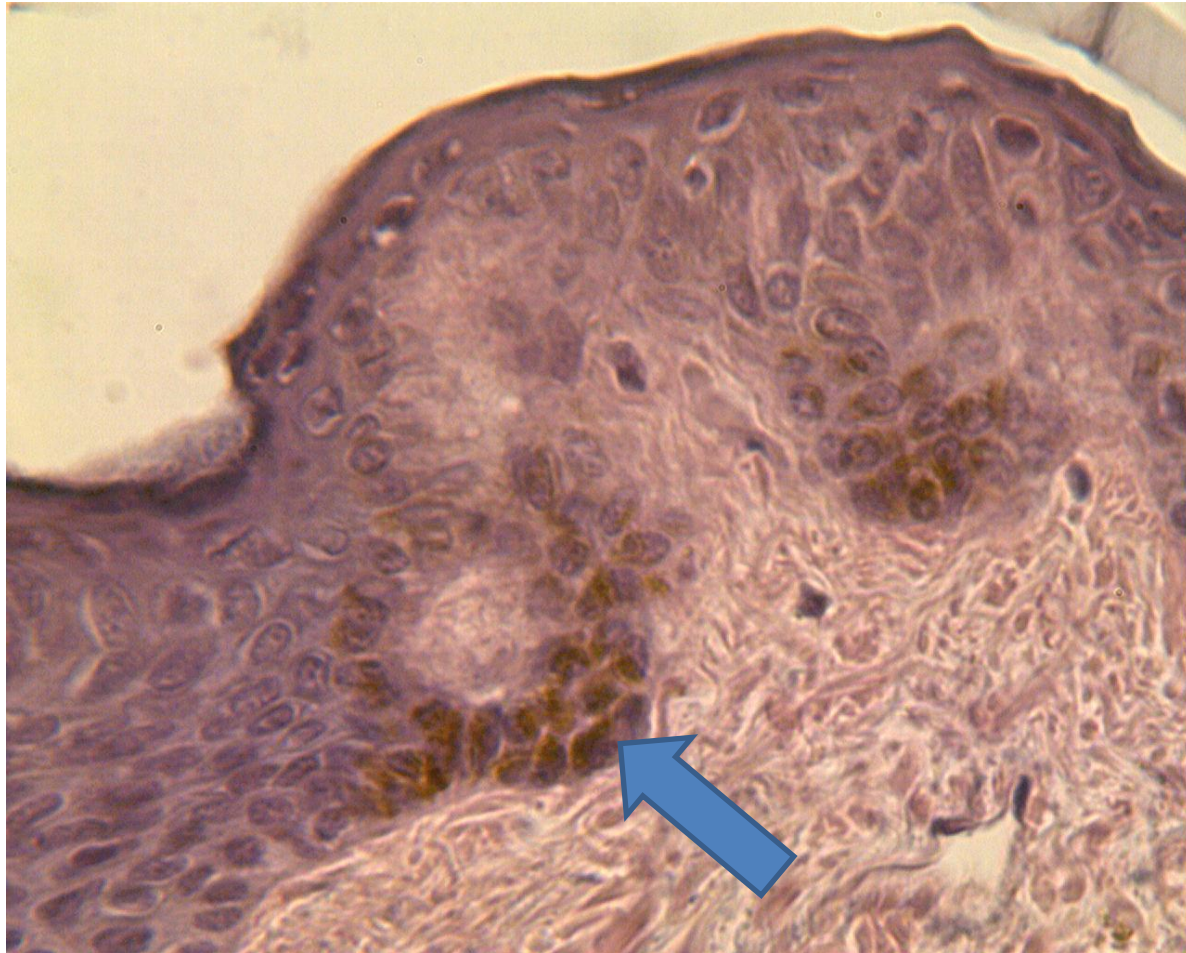
Thin skin



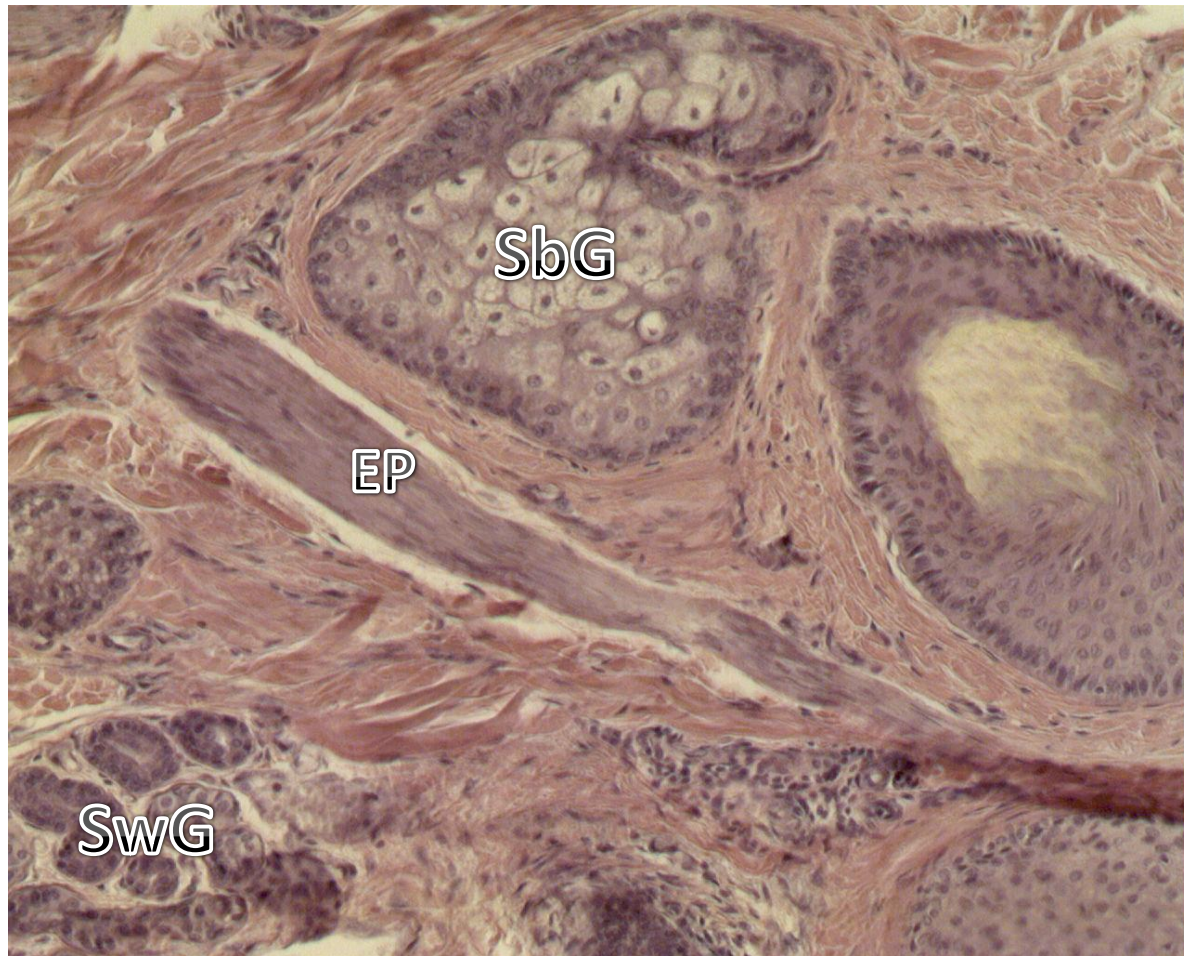
Thin skin, hair follicle (HF)



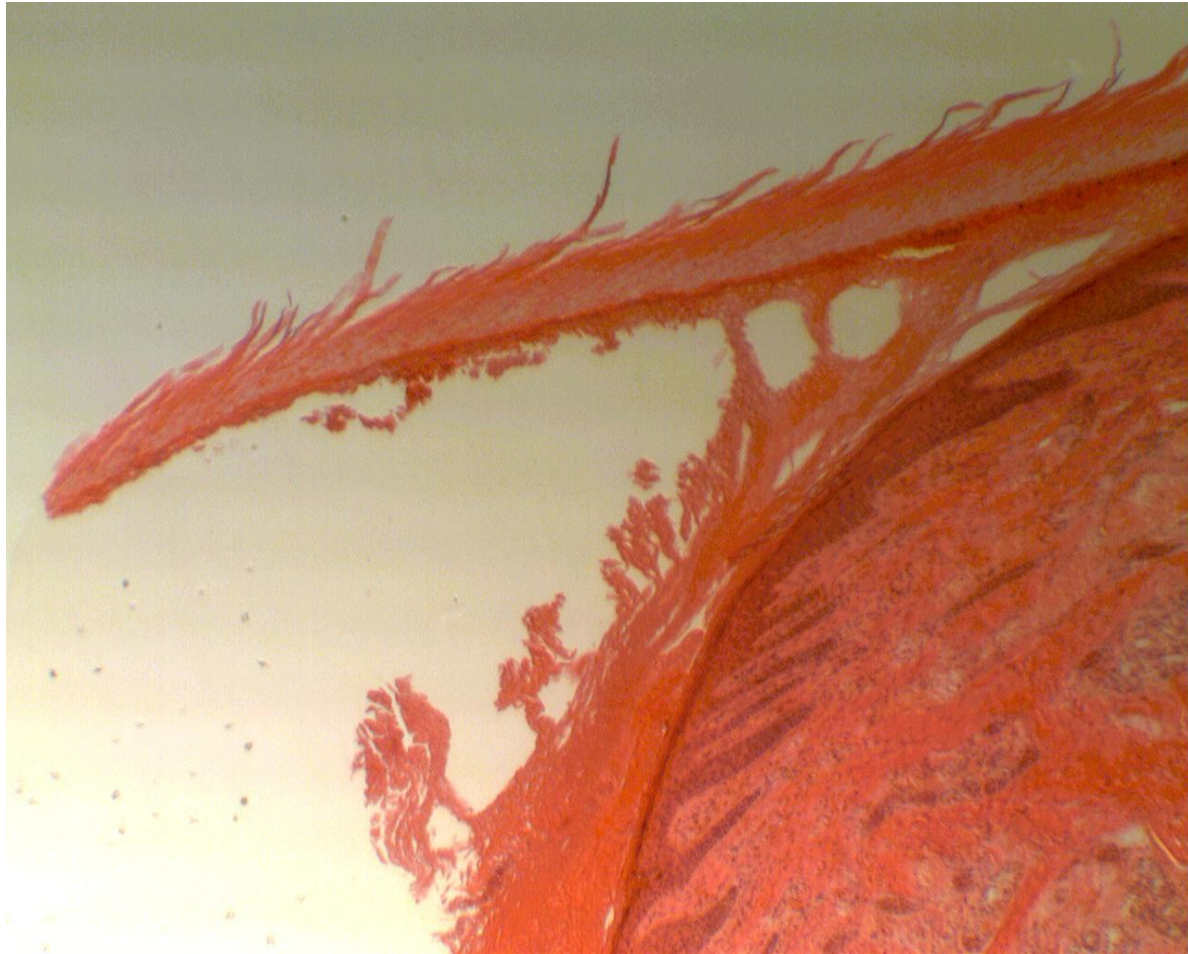
Melanocytes, epidermis



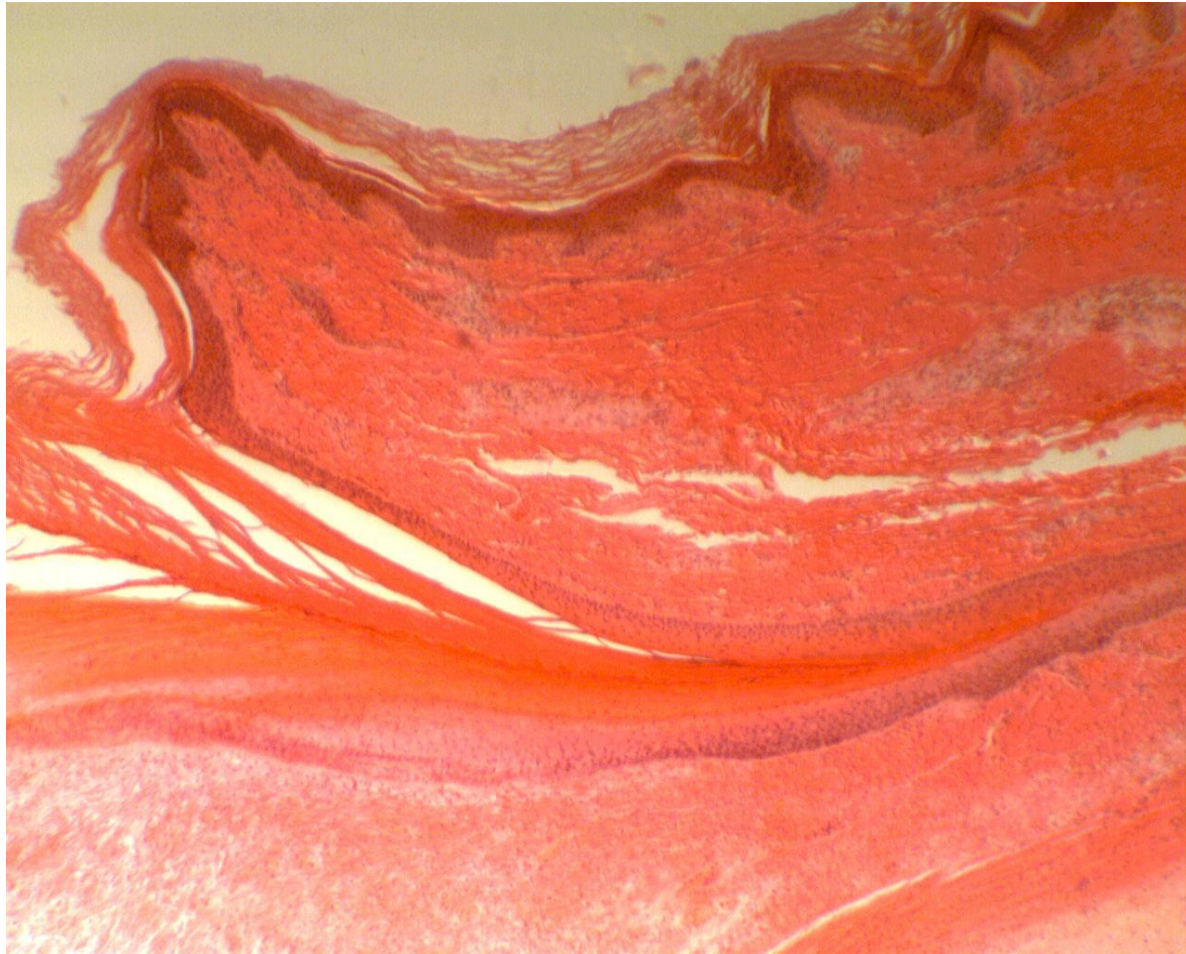
Erector pili muscle (EP), sebaceous gland (SbG), and sweat gland (SwG)



Nail



Nail root



Thank you