

IV. DEFINITION OF LYMPH NODE GROUPS (FIGURE 1)

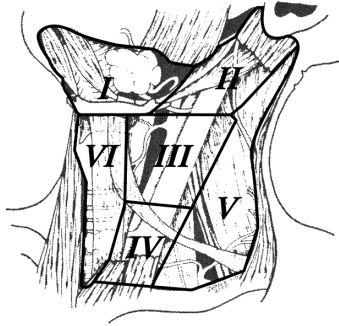
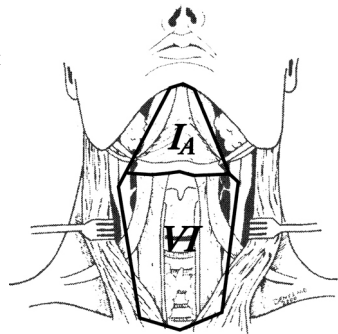


Fig. 1—The level system is used for describing the location of lymph nodes in the neck: Level I, submental and submandibular group; Level II, upper jugular group; Level III, middle jugular group; Level IV, lower jugular group; Level V, posterior triangle group; Level VI, anterior compartment.

Level IA: Submental Group

Lymph nodes within the triangular boundary of the anterior belly of the digastric muscles and the hyoid bone. These nodes are at greatest risk for harboring metastases from cancers arising from the floor of the mouth, anterior oral tongue, anterior mandibular alveolar ridge, and lower lip (Figure 2).

Fig. 2—Dark lines depict the boundaries of the submental (IA) and anterior compartment (VI) lymph nodes.



Level IB: Submandibular Group

Lymph nodes within the boundaries of the anterior and posterior bellies of the digastric muscles, the stylohyoid muscle, and the body of the mandible. Radiographically, the vertical plane at the posterior aspect of the submandibular gland forms a use means of demarcating the posterior aspect of Level IB from IIA. The group includes the pre- and postglandular nodes, and the pre- and postvascular nodes. The submandibular gland is included in the specimen when the lymph nodes within this triangle are removed. These nodes are at greatest risk for harboring metastases from the cancers arising from the oral cavity, anterior nasal cavity, soft tissue structures of the mid-face, and submandibular gland (Figure 3).

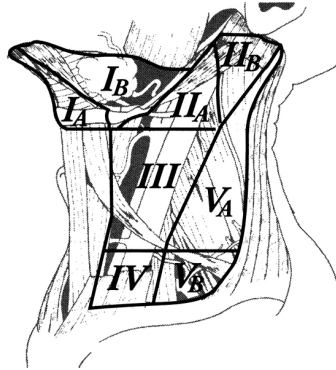


Fig. 3—The boundaries dividing levels I, II, and V into sublevels A and B. See text for details.

Levels IIA & IIB: Upper Jugular Group

Lymph nodes located around the upper third of the internal jugular vein and adjacent spinal accessory nerve extending from the level of the skull base (above) to the level of the inferior border of the hyoid bone (below). The anterior (medial) boundary is the lateral border of the sternohyoid muscle and the stylohyoid muscle (or posterior aspect of the submandibular gland when assessed radiographically), and the posterior (lateral) boundary is the posterior border of the ster-

nocleidomastoid muscle.* Sublevel IIA nodes are located anterior (medial) to the vertical plane defined by the spinal accessory nerve. Sublevel IIB nodes are located posterior (lateral) to the vertical plane defined by the spinal accessory nerve. The upper jugular nodes are at greatest risk for harboring metastases from cancers arising from the oral cavity, nasal cavity, nasopharynx, oropharynx, hypopharynx, larynx, and parotid gland (Figure 3).

Level III: Middle Jugular Group

Lymph nodes located around the middle third of the internal jugular vein extending from the inferior border of the hyoid bone (above) to the inferior border of the cricoid cartilage (below). The anterior (medial) boundary is the lateral border of the sternohyoid muscle, and the posterior (lateral) boundary is the posterior border of the sternocleidomastoid muscle.* (Included in this group is the jugulo-omohyoid node, which lies immediately above the superior belly of the omohyoid muscle as it crosses the internal jugular vein.) These nodes are at greatest risk for harboring metastases from cancers arising from the oral cavity, nasopharynx, oropharynx, hypopharynx, and larynx (Figure 3).

Level IV: Lower Jugular Group

Lymph nodes located around the lower third of the internal jugular vein extending from the inferior border of the cricoid cartilage (above) to the clavicle (below). The anterior (medial) boundary is the lateral border of the sternohyoid muscle, and the posterior (lateral) boundary is the posterior border of the sternocleidomastoid muscle.* These nodes are at greatest risk for harboring metastases from cancers arising from the hypopharynx, cervical esophagus, and larynx (Figure 3).

Levels VA & VB: Posterior Triangle Group

This group is comprised predominantly of the lymph nodes located along the lower half of the spinal accessory nerve and the transverse

cervical artery. The supraclavicular nodes are also included in the posterior triangle group. The superior boundary is the apex formed by a convergence of the sternocleidomastoid and the trapezius muscles, the inferior boundary is the clavicle, the anterior (medial) boundary is the posterior border of the sternocleidomastoid muscle,* and the posterior (lateral) boundary is the anterior border of the trapezius muscle. Sublevel VA is separated from Sublevel VB by a horizontal plane marking the inferior border of the arch of the cricoid cartilage. Sublevel VA includes the spinal accessory nodes, and Sublevel VB includes the nodes following the transverse cervical vessels and the supraclavicular nodes. (The Virchow is located in Level IV.) The posterior triangle nodes are at greatest risk for harboring metastases from cancers arising from the nasopharynx and oropharynx (Sublevel VA), and the thyroid gland (Sublevel VB) (Figure 3).

*The surgical landmark that defines the lateral boundary of Levels II, III, and IV and the corresponding medial boundary of the posterior triangle (Level V) is the plane that parallels the sensory branches of the cervical plexus.

Level VI: Anterior (Central) Compartment Group

Lymph nodes in this compartment include the pre- and paratracheal nodes, the precricoid (Delphian) node, and the perithyroidal nodes, including the lymph nodes along the recurrent laryngeal nerves. The superior boundary is the hyoid bone, the inferior boundary is the suprasternal notch, and the lateral boundaries are the common carotid arteries. These nodes are at greatest risk for harboring metastases from cancers arising from the thyroid gland, glottic and subglottic larynx, apex of the piriform sinus, and cervical esophagus (Figure 2).

V. CONCEPTUAL GUIDELINES FOR NECK DISSECTION CLASSIFICATION

A. Radical Neck Dissection

Radical neck dissection (Figure 4) is considered to be the standard basic procedure for cervical lymphadenectomy. All other procedures represent one or more alterations of this procedure. Radical neck dissection refers to the removal of all ipsilateral cervical lymph node groups extending from the inferior border of the mandible superiorly to the clavicle inferiorly, from the lateral border of the sternohyoid muscle, hyoid bone, and contralateral anterior belly of the digastric muscle medially, to the anterior border of the trapezius muscle laterally. Included are all lymph nodes from Levels I through V. The spinal accessory nerve, internal jugular vein, and sternocleidomastoid muscle are also removed. Radical neck dissection does not include removal of the suboccipital nodes, periparotid nodes (except infraparotid nodes located in the posterior aspect of the submandibular triangle), buccinator nodes, retropharyngeal nodes, and midline visceral (anterior compartment) nodes.

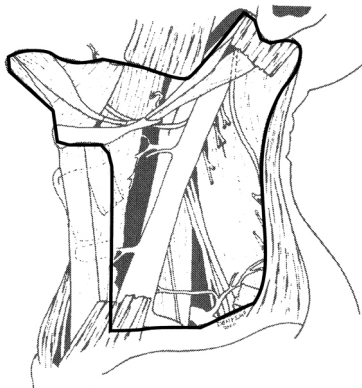


Fig. 4—Radical neck dissection.

B. Modified Radical Neck Dissection

Modified radical neck dissection (Figure 5a–c) refers to the excision of all lymph nodes routinely removed by the radical neck dissection, with preservation of one or more nonlymphatic structures: i.e., spinal accessory nerve (SAN), internal jugular vein (IJV), and sternocleidomastoid muscle (SCM). The structure(s) preserved should be specifically named—e.g., “modified radical neck dissection with preservation of the spinal accessory nerve.”

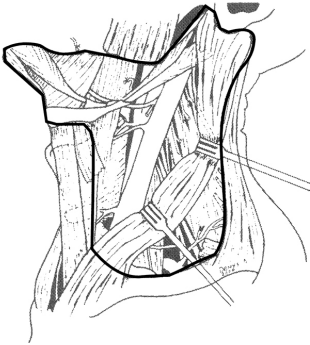


Fig. 5a—Modified radical neck dissection with preservation of SCM, IJV, and SAN.

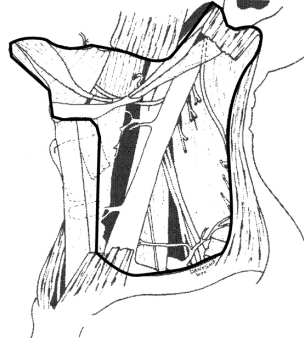


Fig. 5b—Modified radical neck dissection with preservation of IJV and SAN.

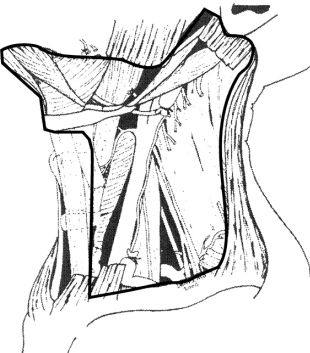


Fig. 5c—Modified radical neck dissection with preservation of SAN.

C. Selective Neck Dissection

Selective neck dissection (SND) refers to a cervical lymphadenectomy in which there is preservation of one or more of the lymph node groups that are routinely removed in the radical neck dissection. The lymph nodes groups removed are based on the patterns of metastases that are predictable relative to the primary site of disease. For oral cavity cancers, the lymph nodes at greatest risk are located in Levels I, II, and III. The lymph nodes at greatest risk for oropharyngeal, hypopharyngeal, and laryngeal cancers are located in Levels II, III, and IV, and for thyroid cancer, are in Level VI.

Specific variations of the selective neck dissection include:

Anterior Neck Dissection—This includes Level VI (Figure 6).

Supraomohyoid Neck Dissection—This includes Levels IA & IB, Level IIA or Levels IIA & IIB, Level III (Figure 7).

Lateral Neck Dissection—This includes Level IIA or Levels IIA & IIB, Level III, and Level IV (Figure 8).

Posterolateral Neck Dissection—This includes Levels II, III, IV, & V, the post-auricular nodes, suboccipital nodes, and the external jugular nodes (Figure 9).

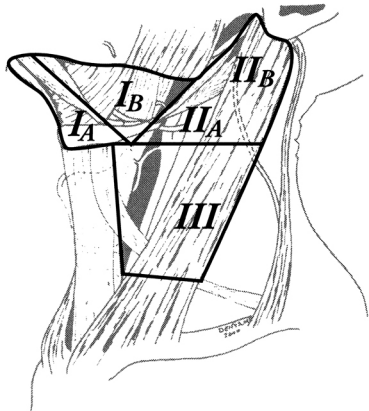


Fig. 6—SND (Levels I–III) or supraomohyoid neck dissection.

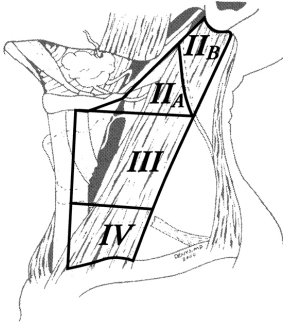


Fig. 7—SND (Levels II–IV) or lateral neck dissection.

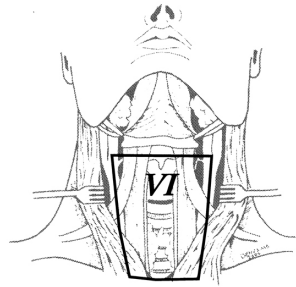


Fig. 8—SND (Level VI) or anterior neck dissection.

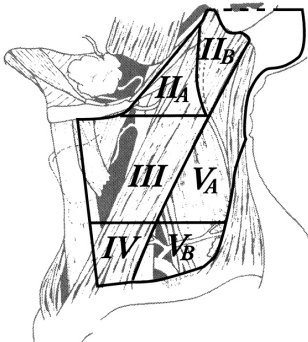


Fig. 9—SND (Levels II–V), postauricular, suboccipital, external jugular, or posterolateral neck dissection.

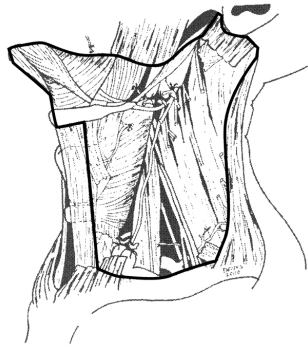


Fig. 10—Extended radical neck dissection with removal of the common carotid artery or ERND (common carotid artery).

Since there is variation of levels and sublevels associated with the names given to the various types of SND, it is recommended to use the term “selective neck dissection” or “SND,” followed by the levels and/or sublevels removed—e.g., SND (Levels IB, IIA and III).

D. Extended Radical Neck Dissection

Extended radical neck dissection (ERND) refers to the removal of one or more additional lymph node groups or nonlymphatic structures, or both, not encompassed by the radical neck dissection (Figure 10). Examples of such lymph node groups include the parapharyngeal (retropharyngeal), superior mediastinal, perifacial (buccinator), and paratracheal lymph nodes. Examples of the nonlymphatic structures include the carotid artery, overlying skin, hypoglossal nerve, vagus nerve, and paraspinal muscles. The additional lymphatic or nonlymphatic structure(s), or both, should be identified.

NOTES

NOTES

NOTES

