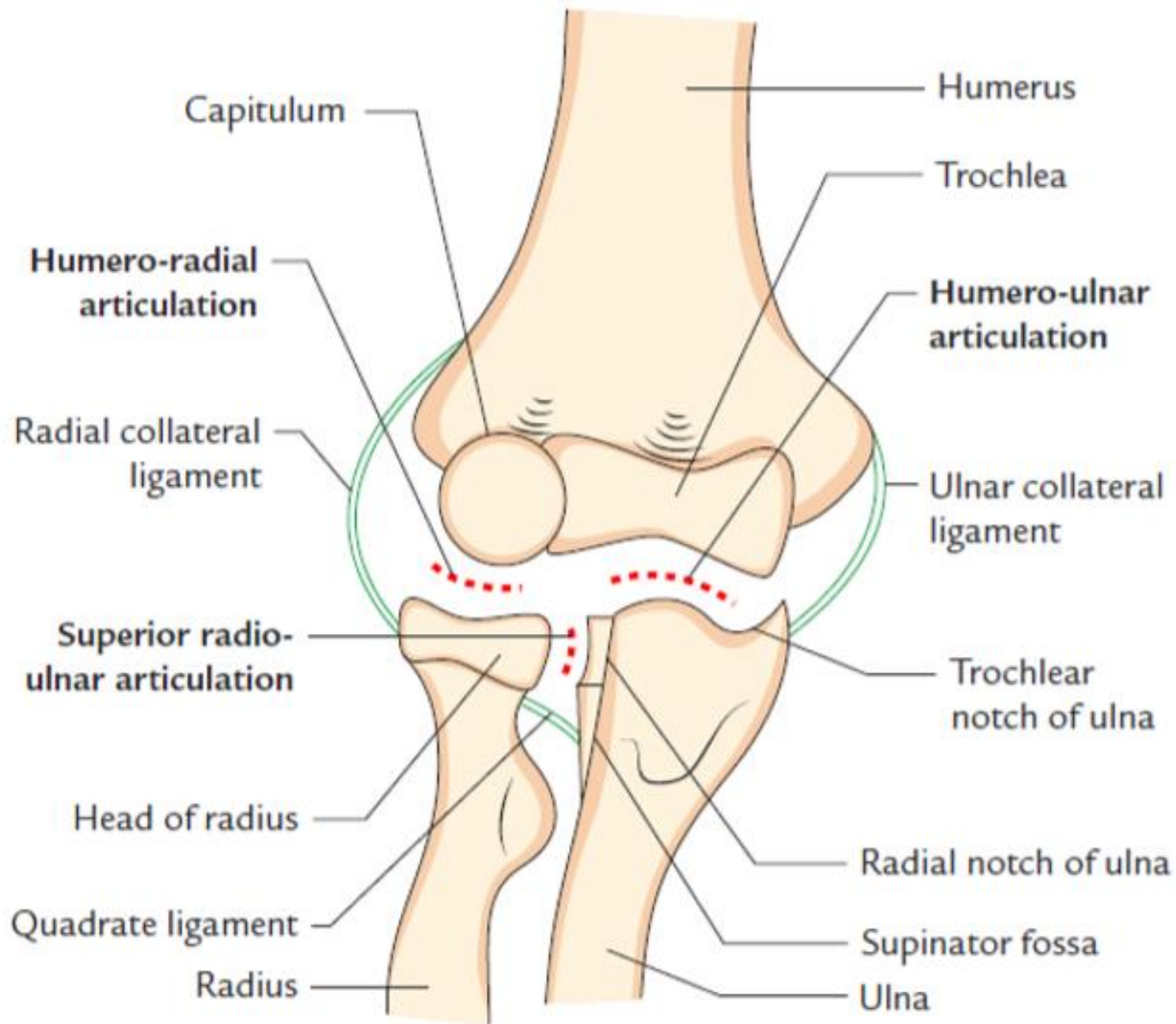
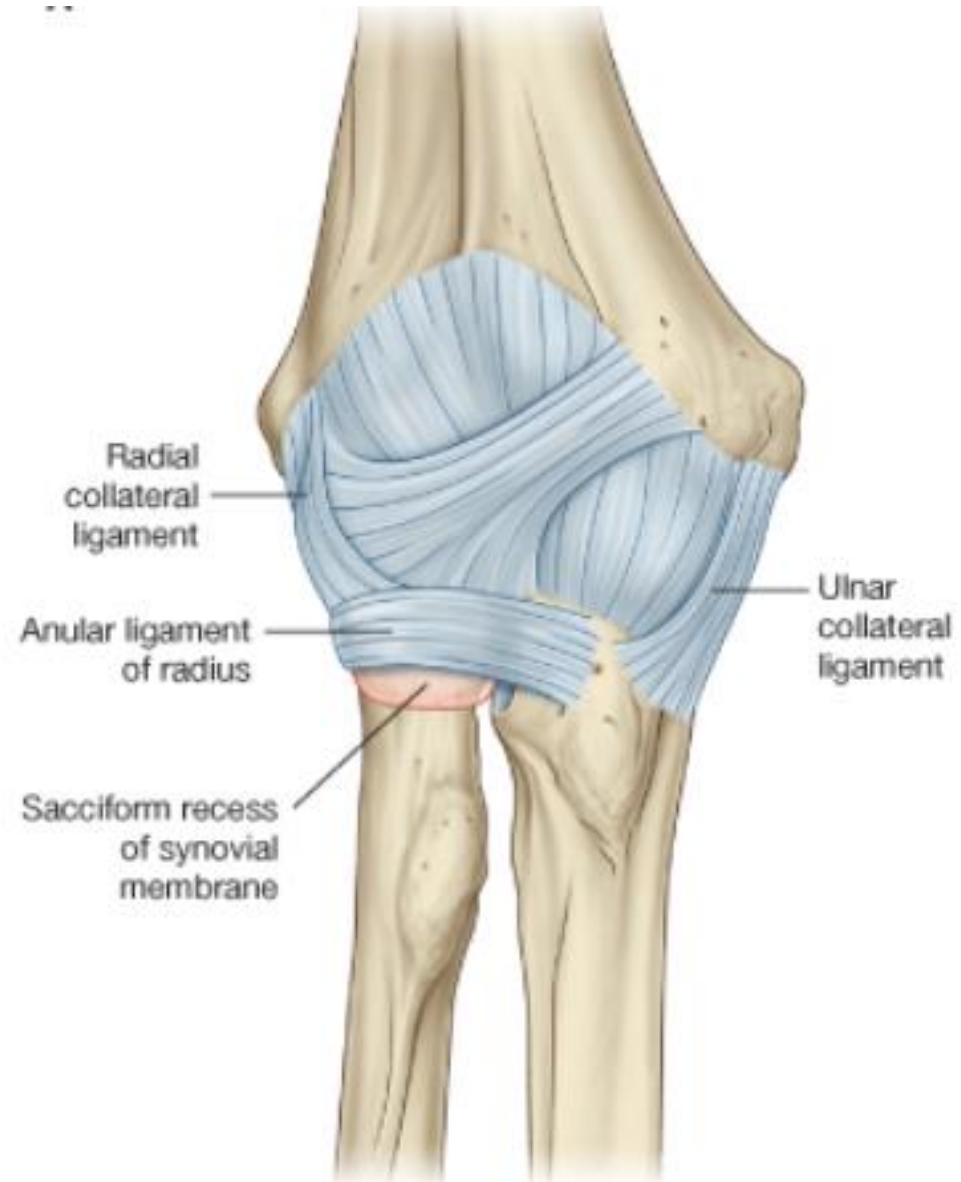
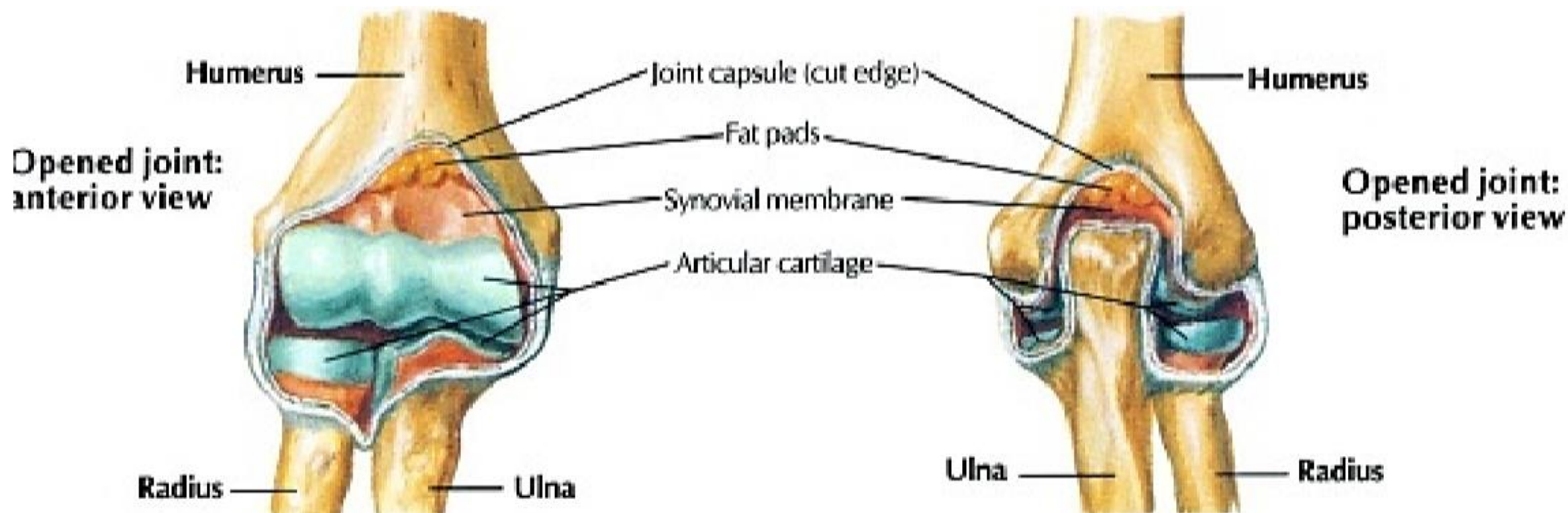


Elbow joint & distal joints of  
upper limb

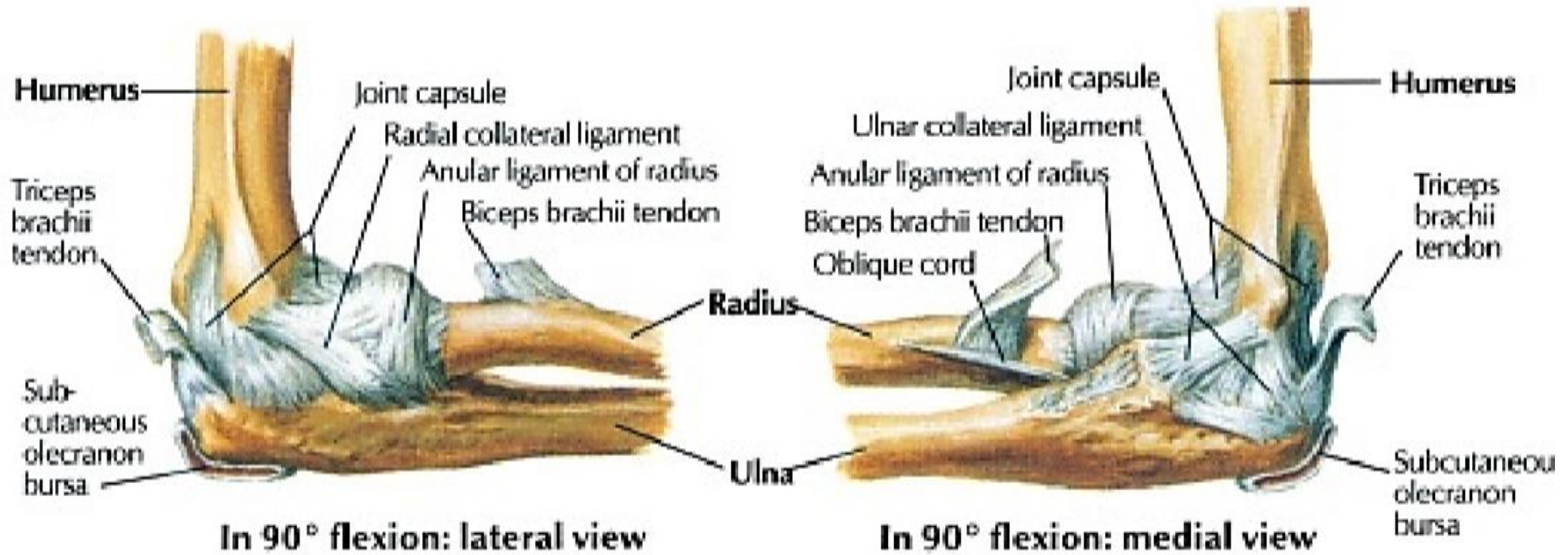


capsule



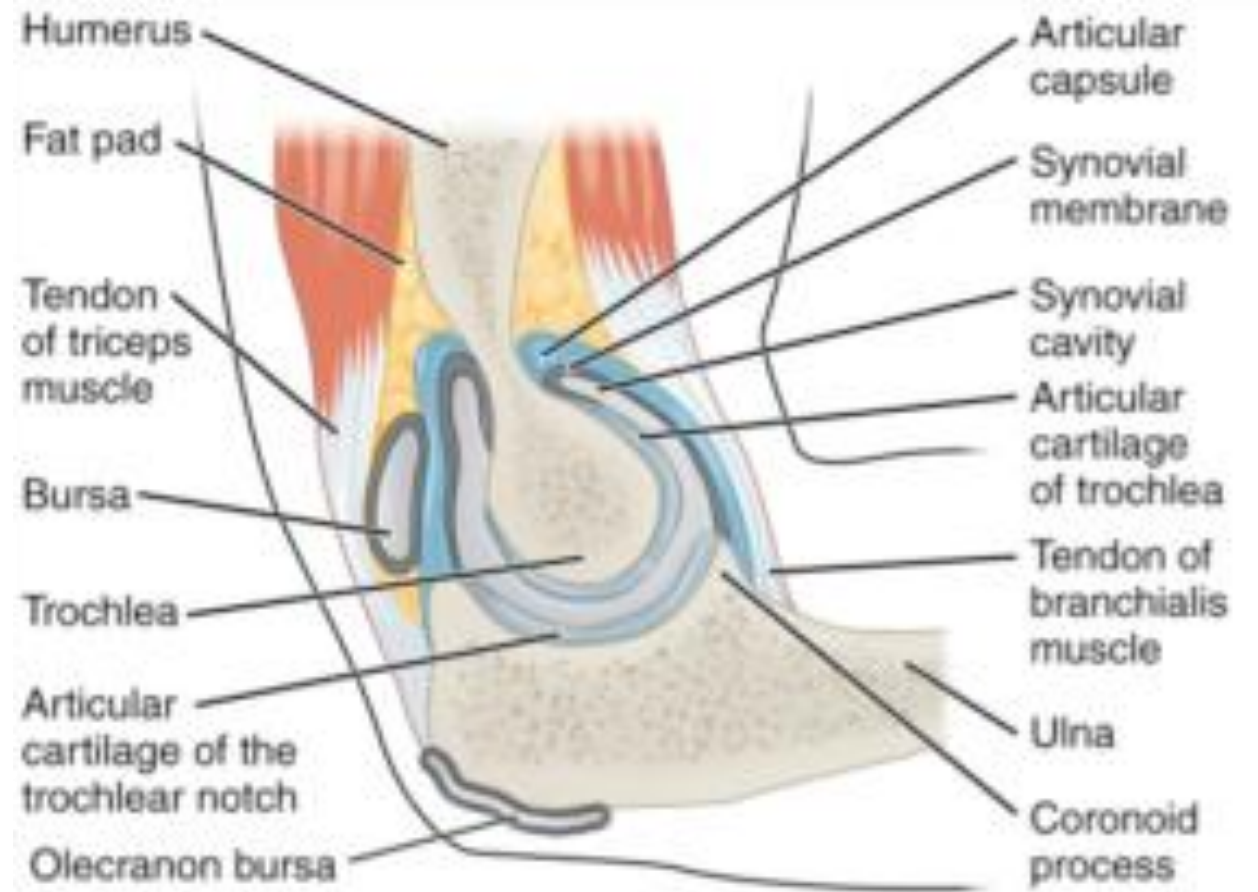


# ligaments



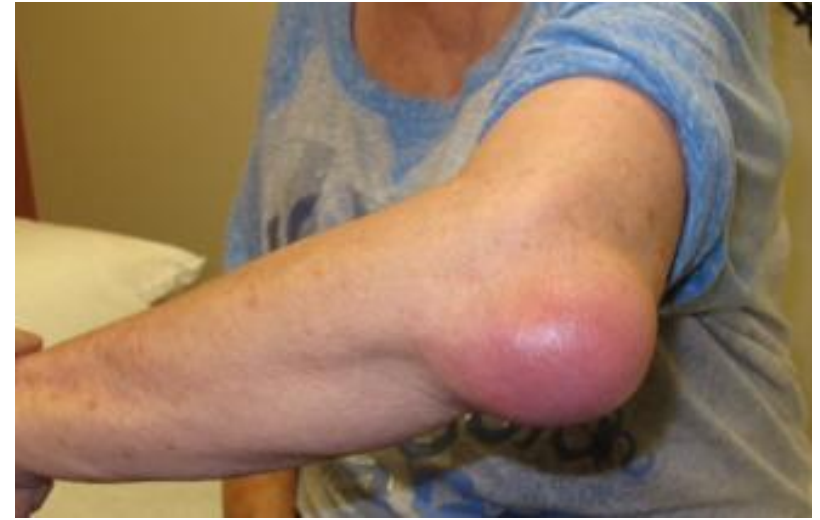# Synovial bursae

- Subcutaneous olecranon bursa
- Subtendinous triceps bursa



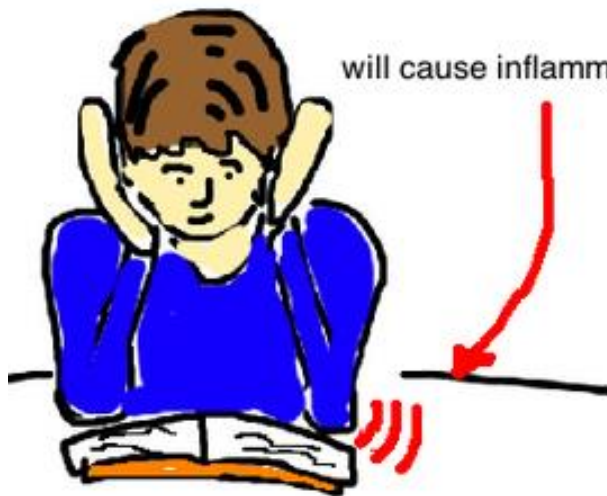(a) Medial sagittal section through right elbow (lateral view)

# Olecranon bursitis (Student's elbow)



Irritation over the elbow, after a long time

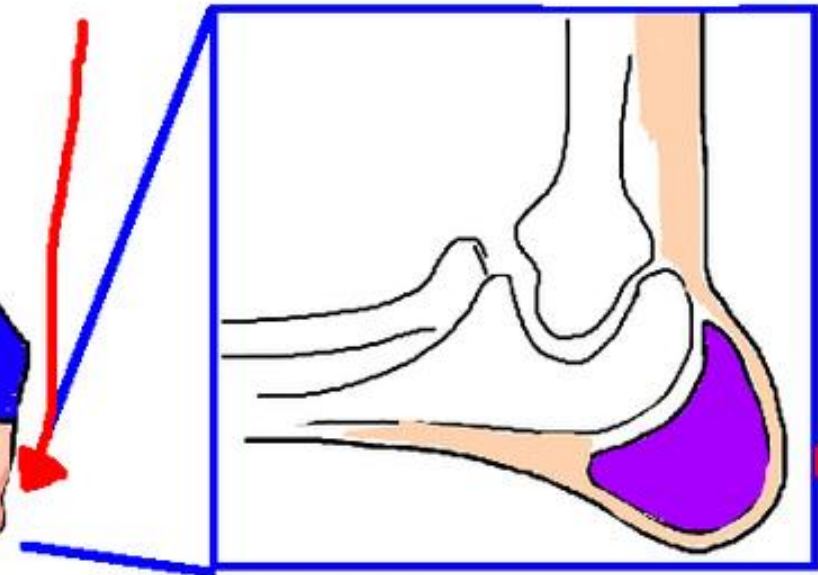
Like after a medical student is cramming for an exam



will cause inflammation of the elbow bursa

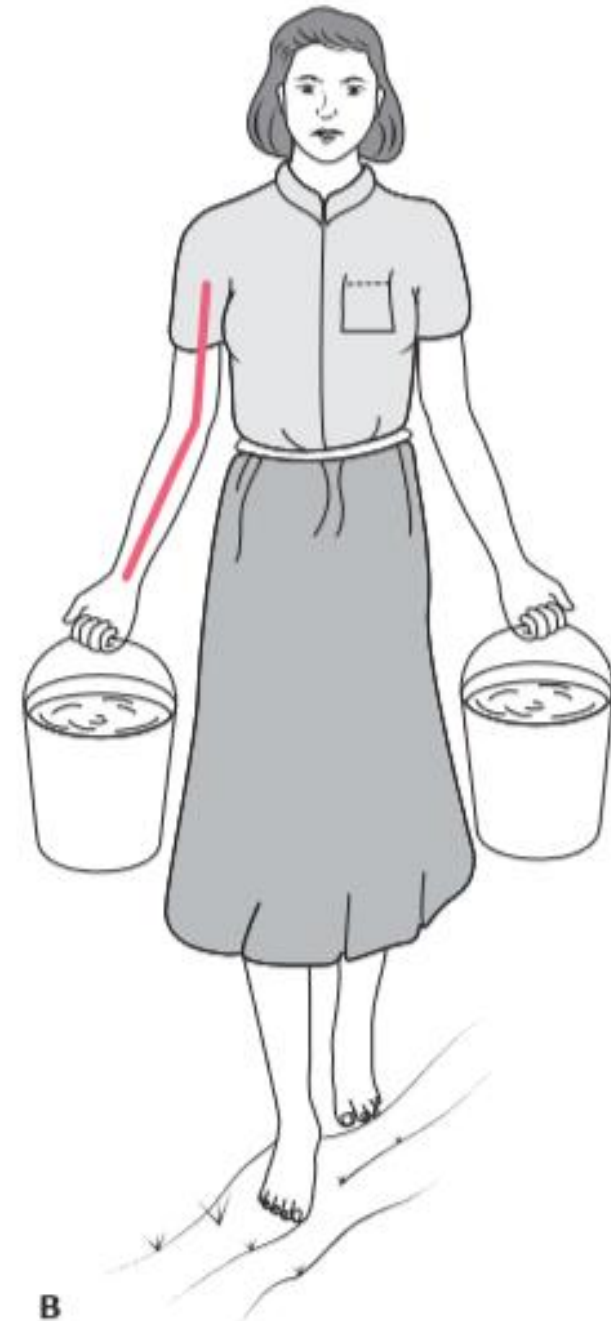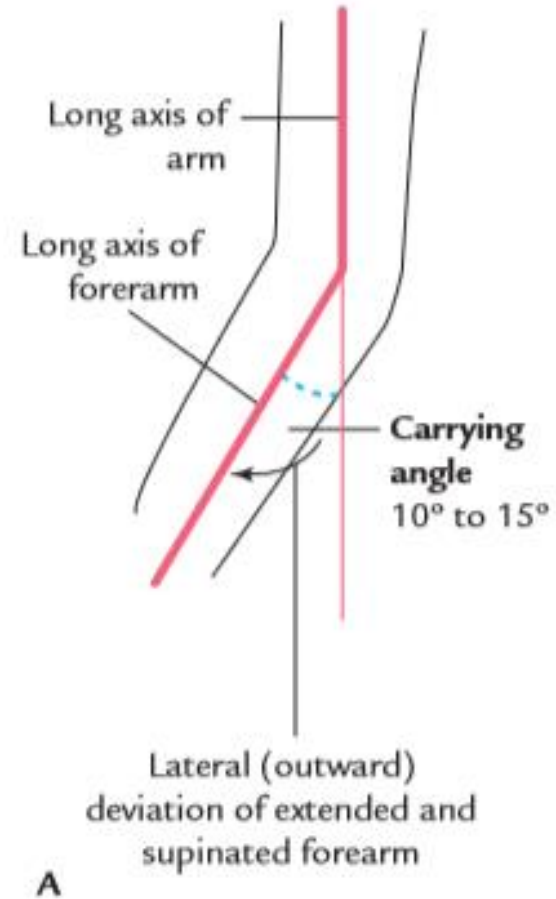
this can cause an elbow bursitis

the bursa is now swollen


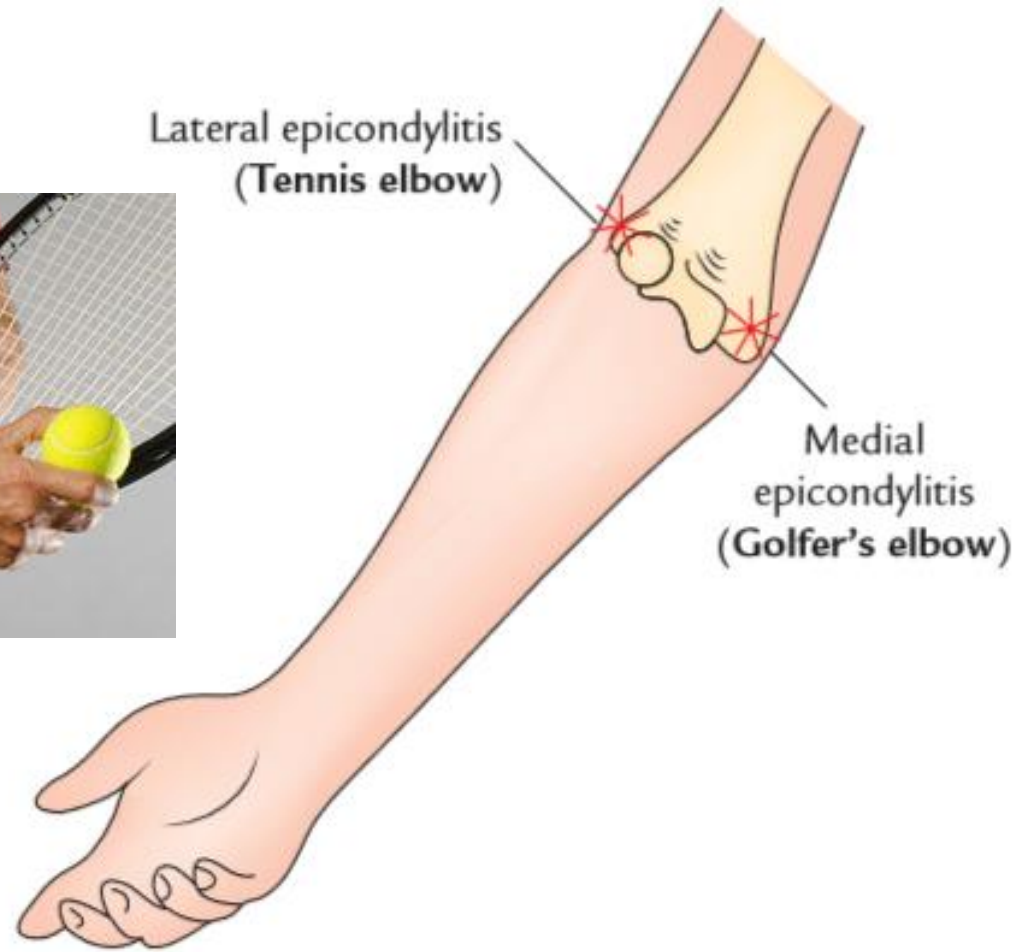


and its very visible over the elbow

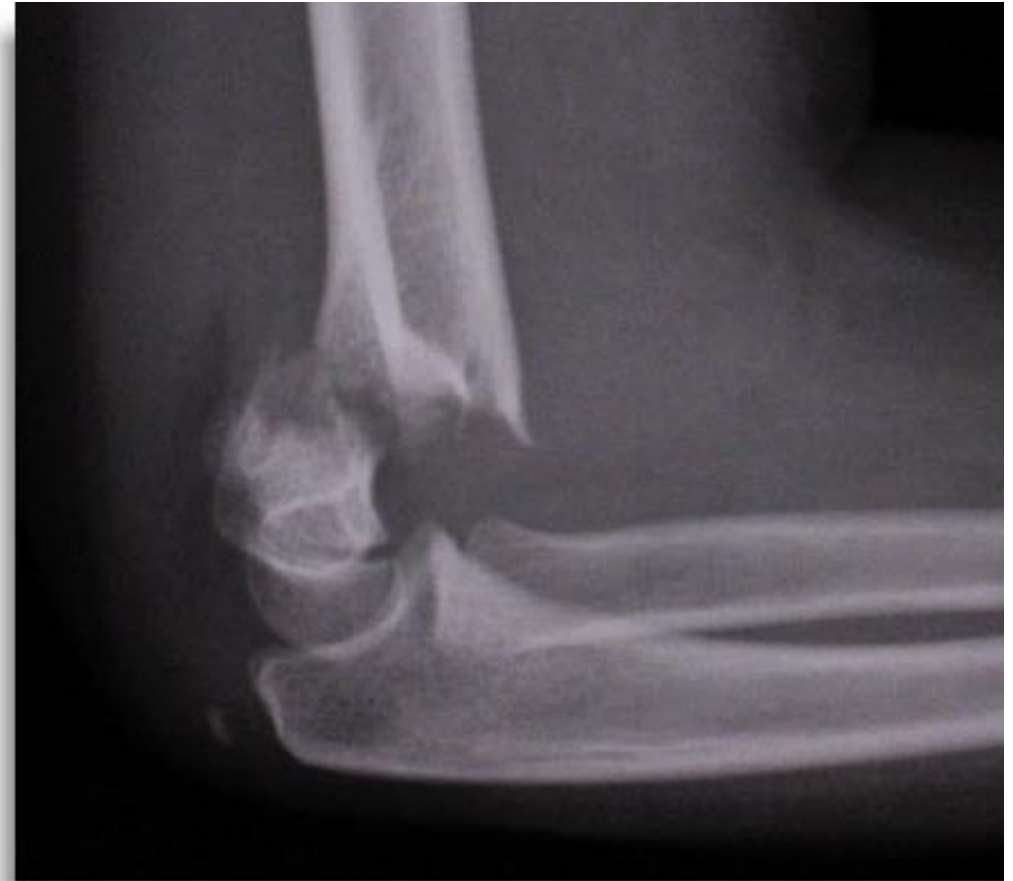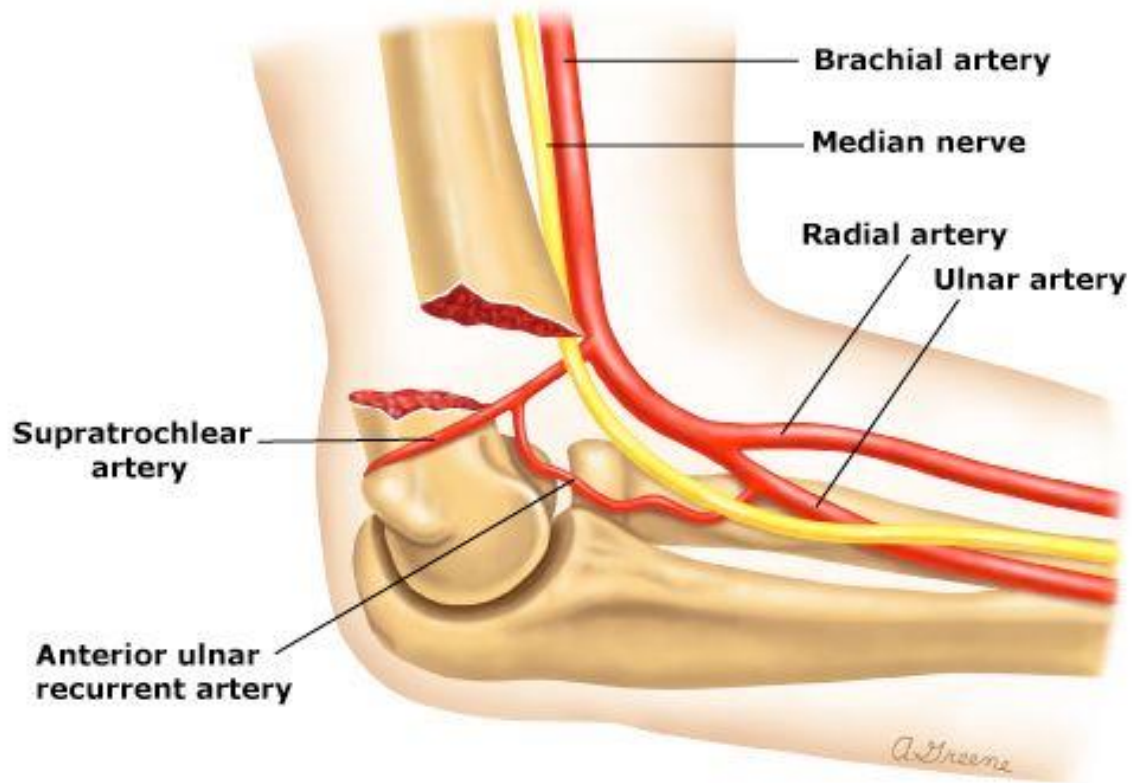
# Carrying angle



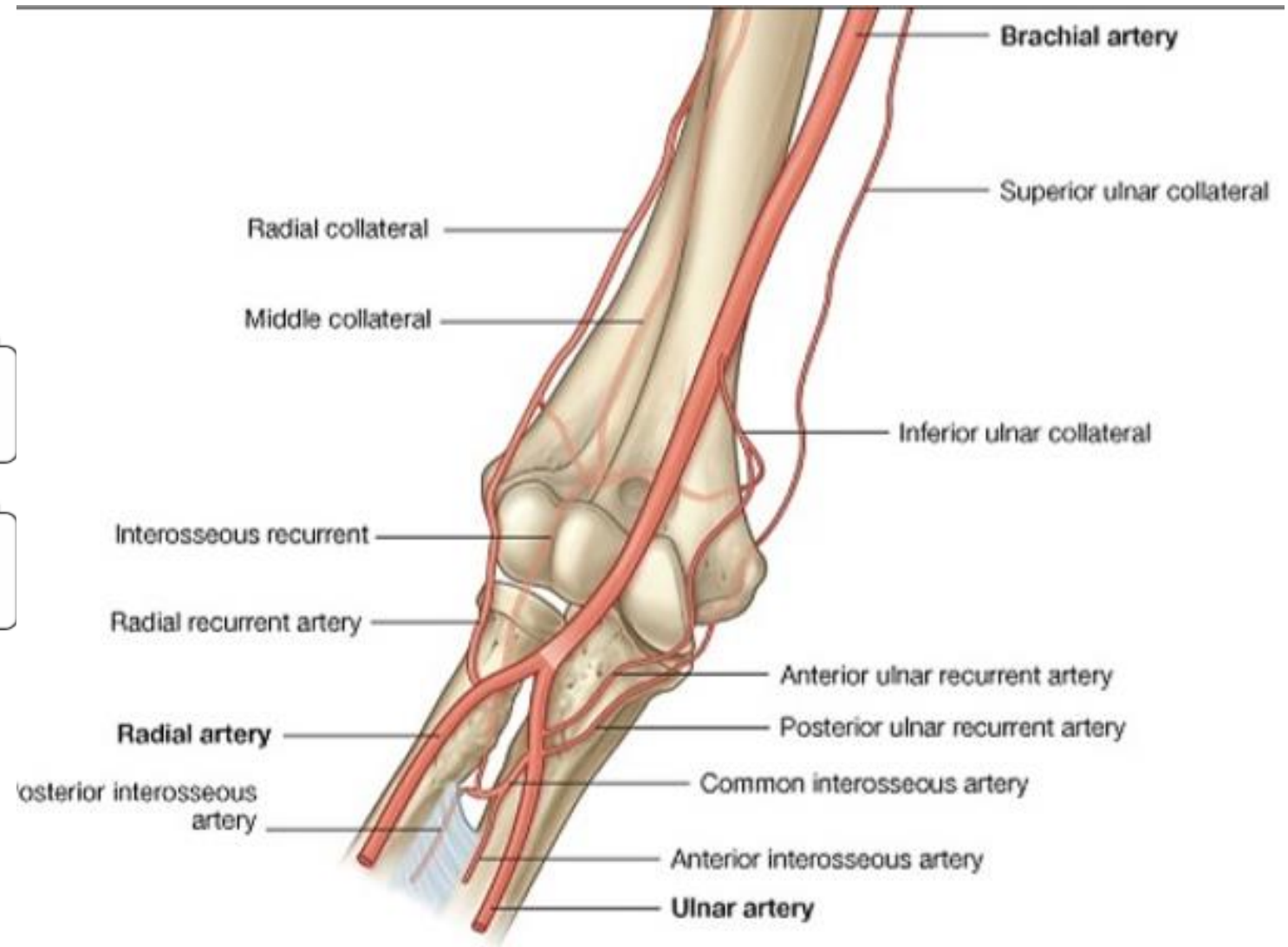
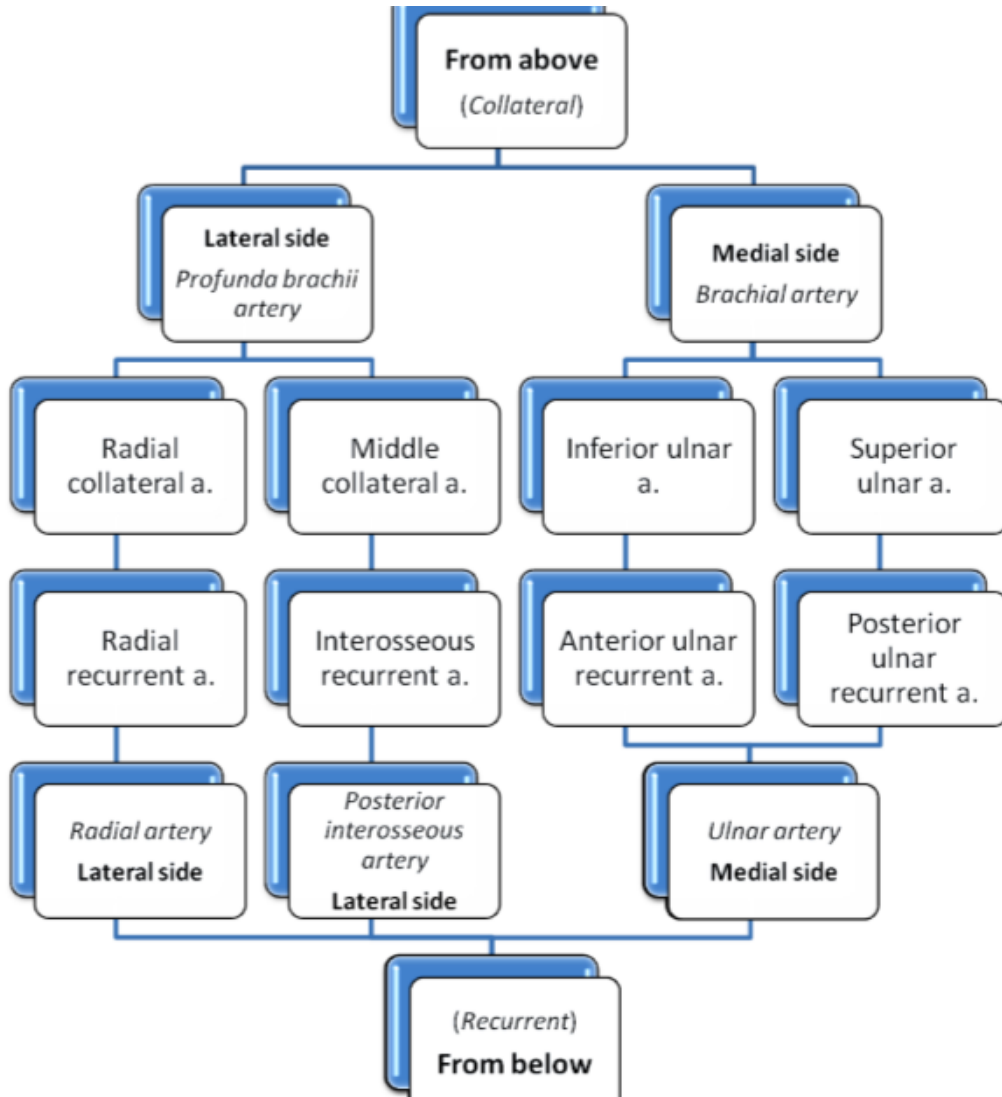




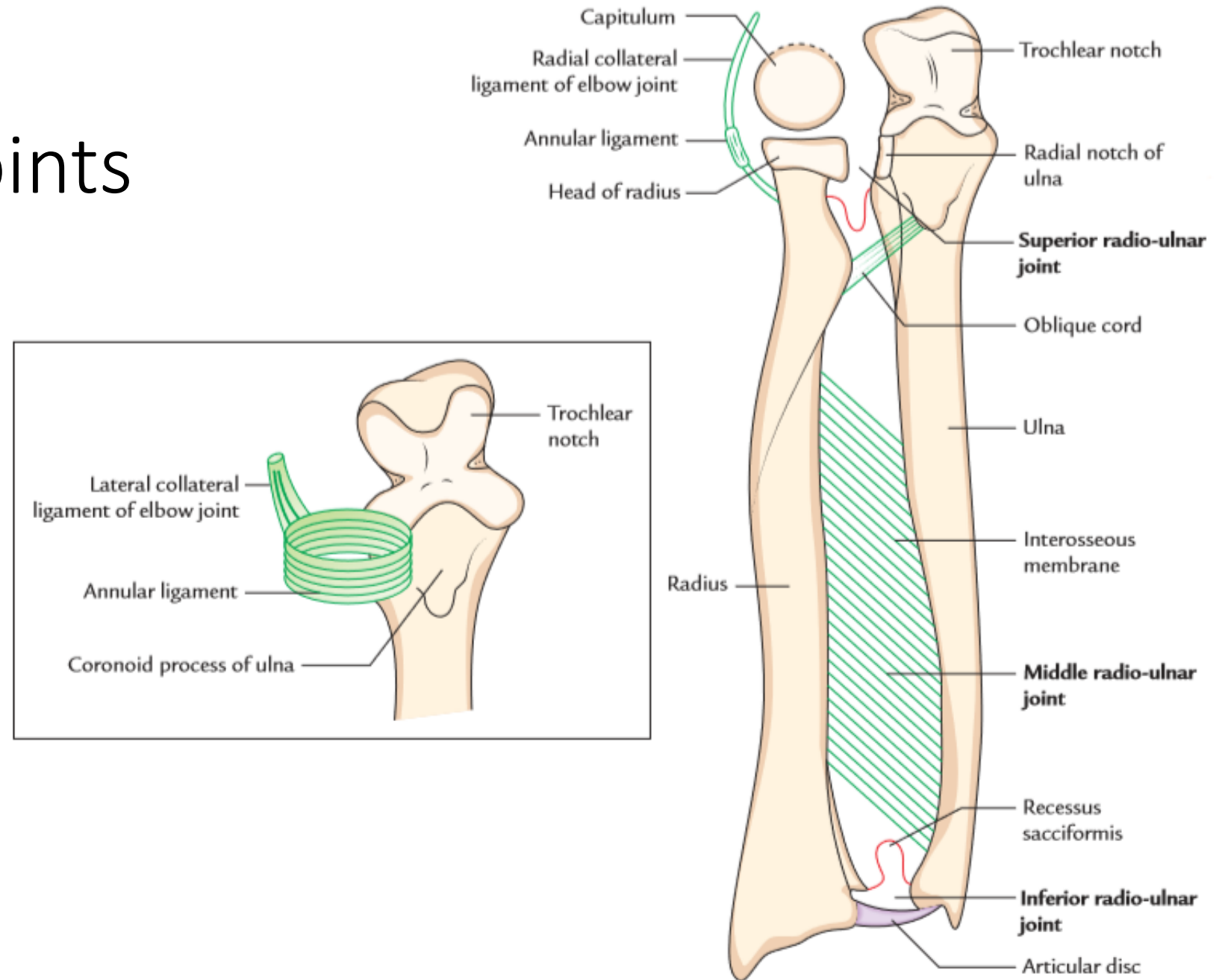
# Supracondylar fracture



# Anastomosis around elbow

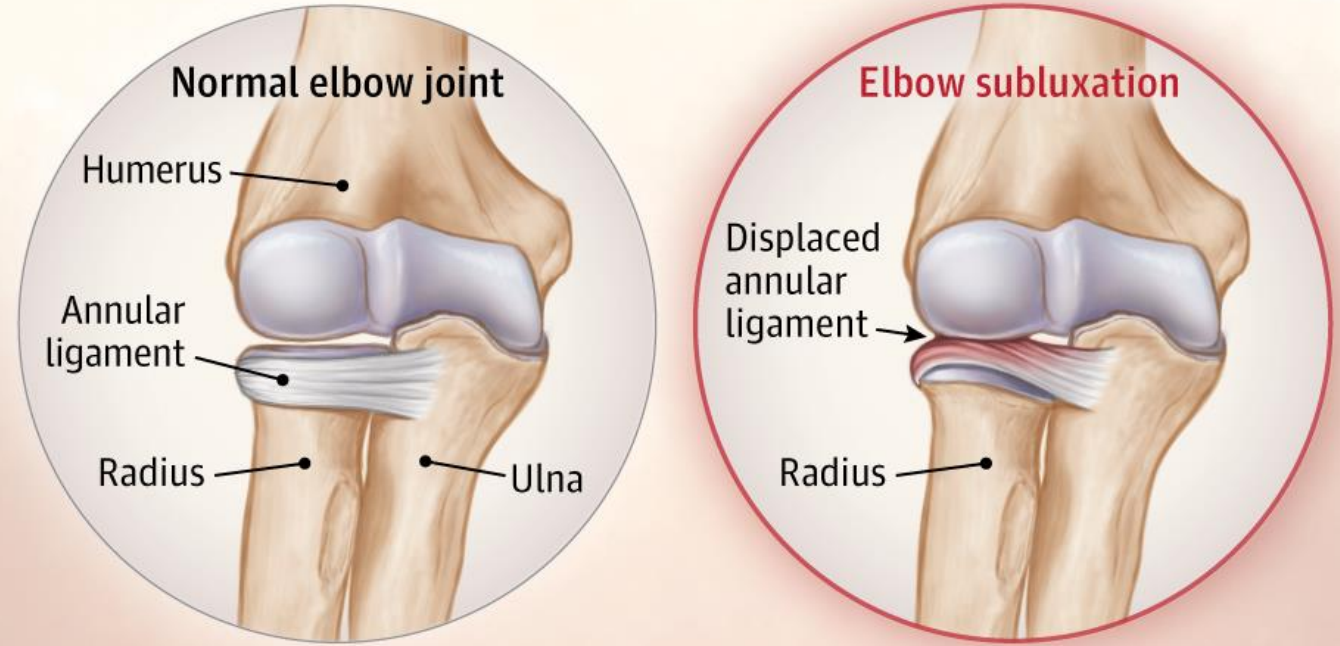


# Radio-ulnar joints



# Nursemaid's elbow

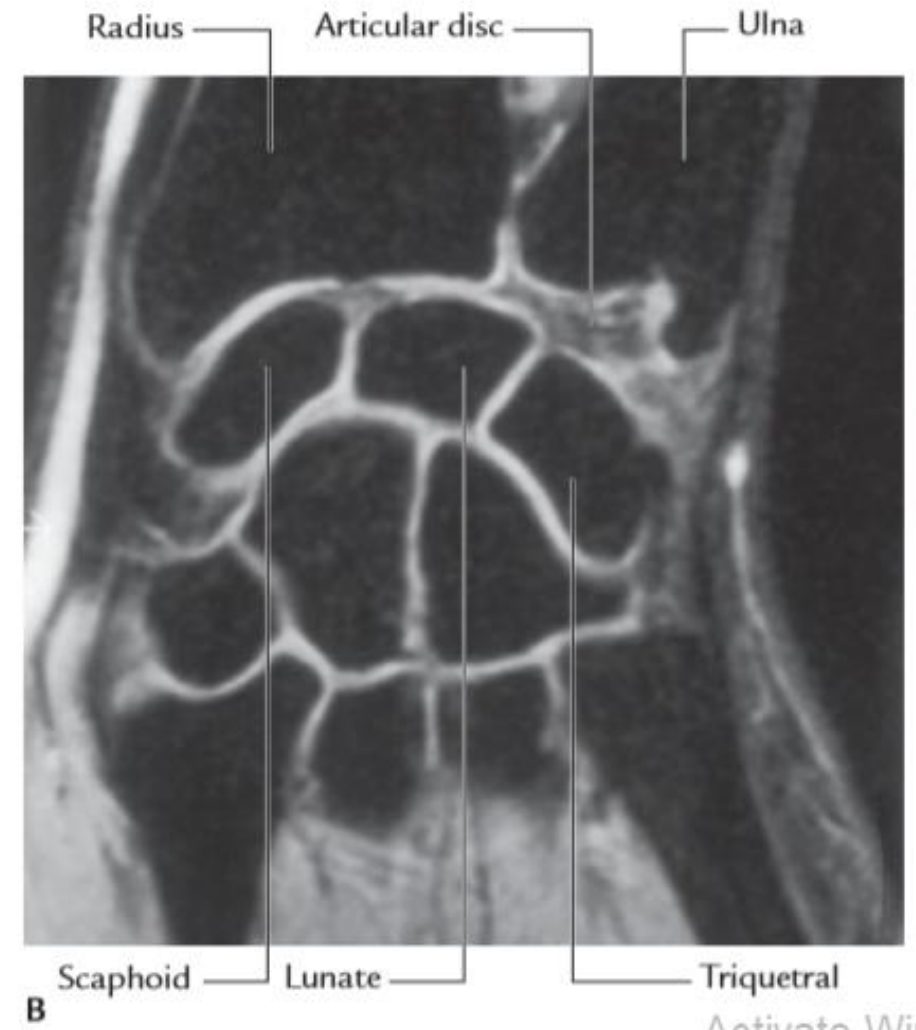
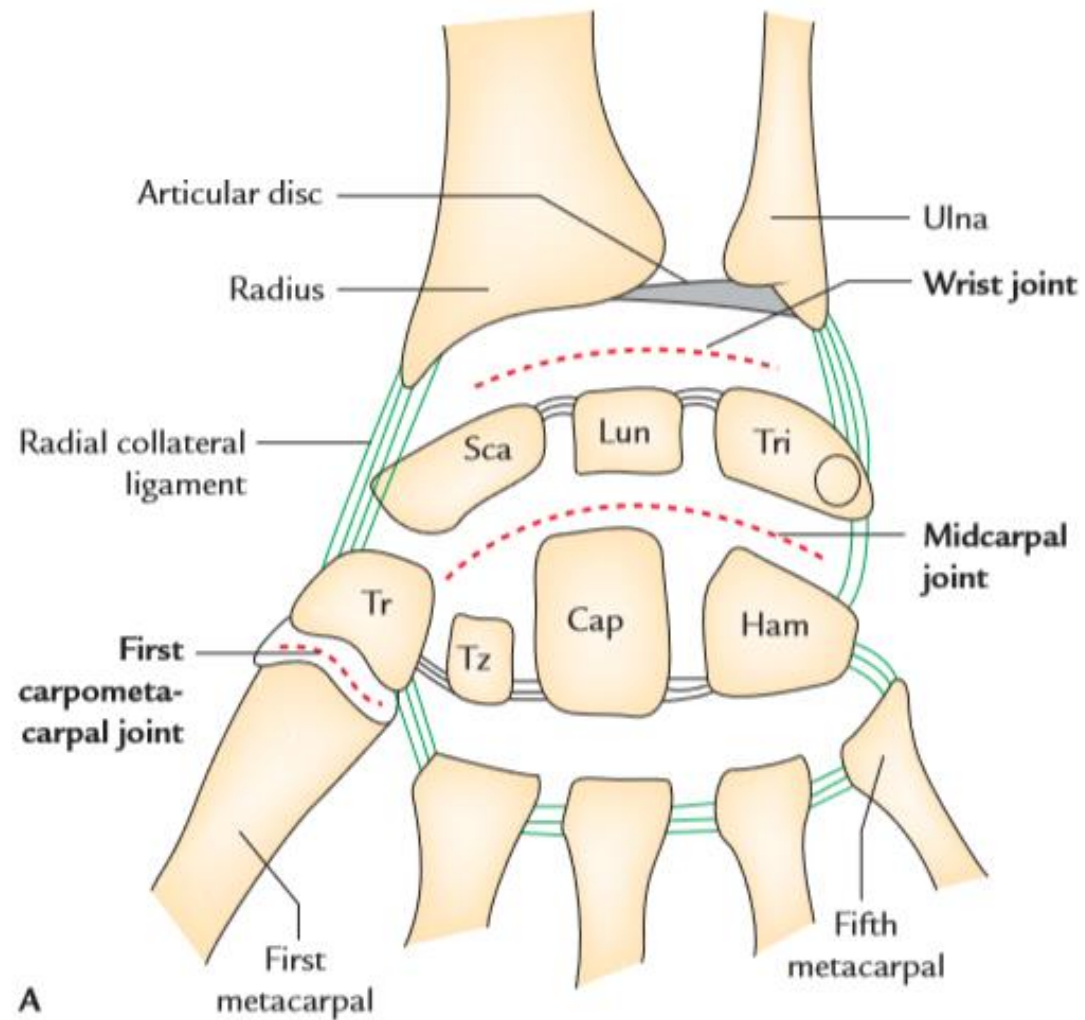
## Nursemaid's elbow (elbow subluxation)

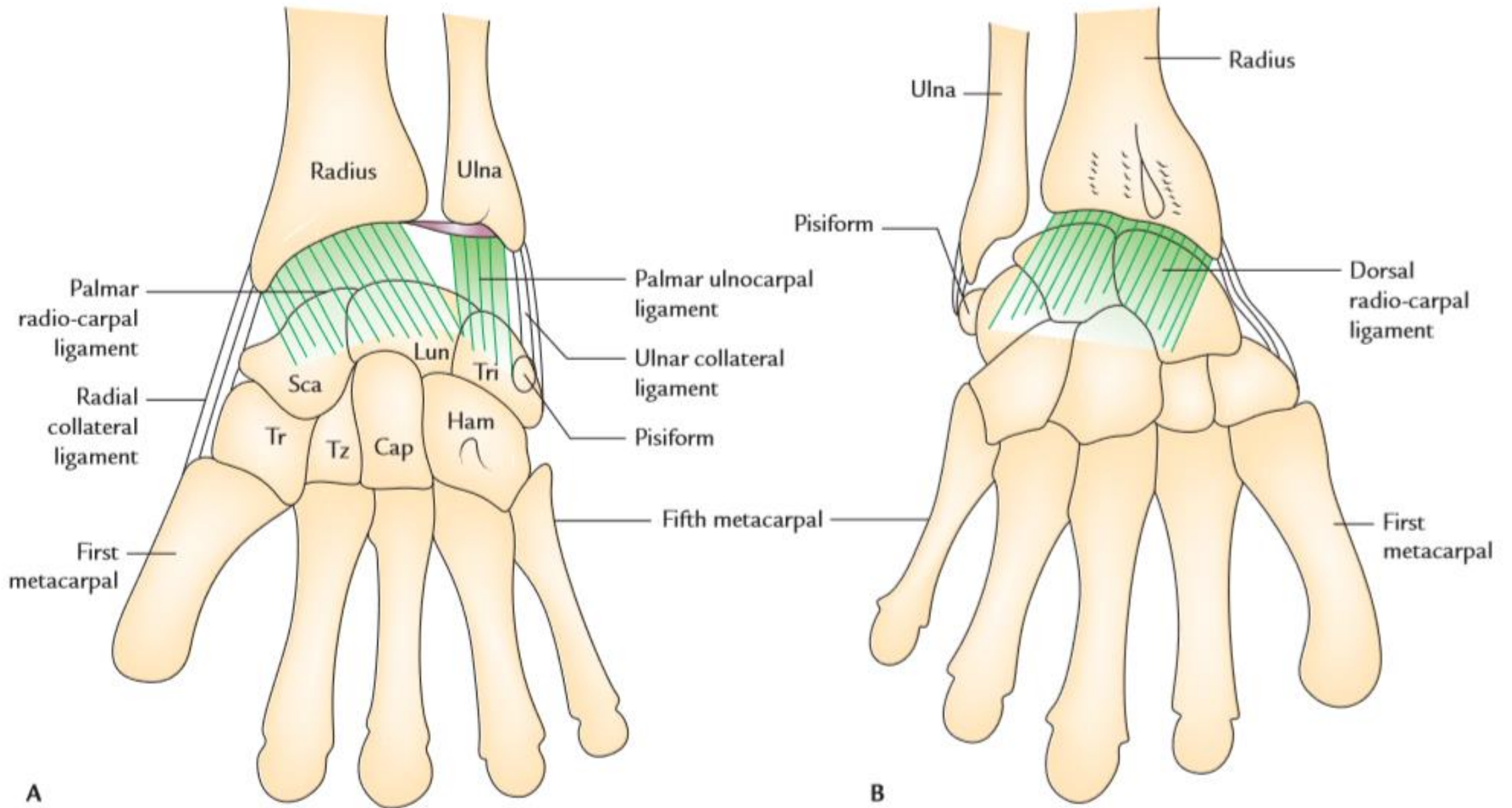


**!** To prevent elbow subluxation, avoid



# Wrist joint





# Scaphoid fracture

