

By the Name of ALLAH the Most Gracious the Most Merciful



Abdominal Wall, Hernias & Umbilicus L4

Dr. AHMED OSAMA HASSEN

Specialist in General Surgery, Laparoscopic and Bariatric Surgery

الأحد ١٧ / ١٠ / ٢٠٢١

Bailey & Love's Short Practice of Surgery, 27th Edition . CH 60 .

Browse's Introduction to The Symptoms and Signs of Surgical Disease , 4th Edition.

Ventral Hernias

- Umbilical–paraumbilical
- Epigastric
- Incisional
- Parastomal
- Spigelian
- Lumbar
- Traumatic

Rare external hernias

- Perineal hernia.
- Obturator hernia.
- Gluteal and sciatic hernias.

Paraumbilical Hernia

- Congenital umbilical hernia is usually hemispherical and overlies an easily palpable defect in the abdominal wall.
- Paraumbilical hernia is crescent and with palpable defect in the abdominal wall.
- History : Risk factors.
- Size.
- Content.
- Reducibility.
- Expansile cough impulse.
- Complication (large hernias: dermatitis, Intestinal obstruction, strangulation & gangrene).
- Large hernias are often multiloculated and there may be strangulated bowel in one component when other areas are clinically soft and a non-tender hernia.

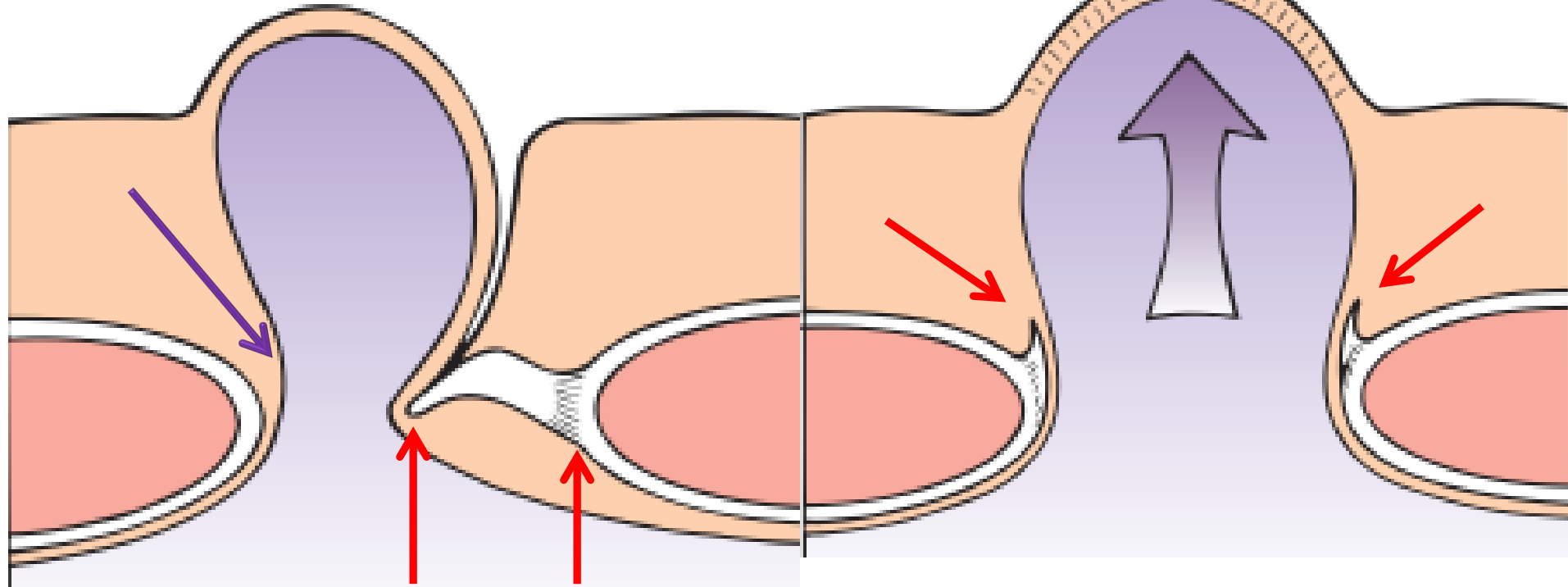
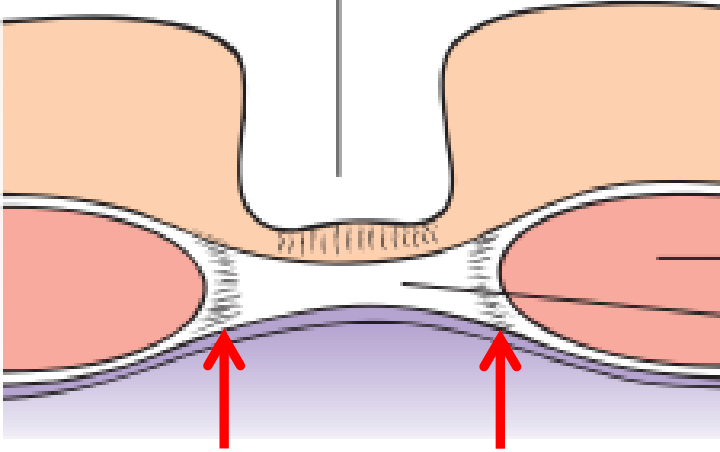
Skin dimple

The normal umbilicus

Rectus abdominis muscle

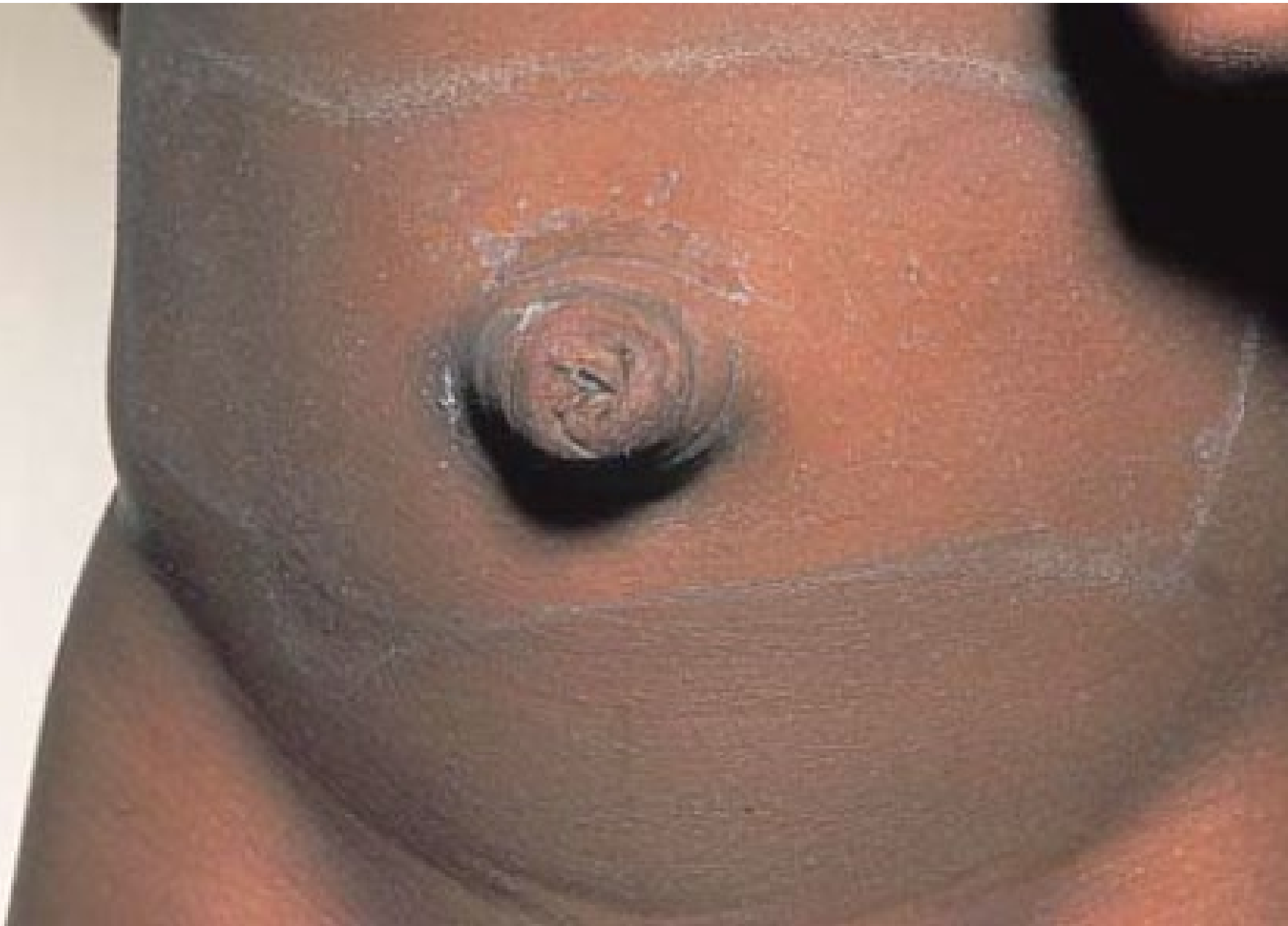Scar in linea alba tethered to the skin

Umbilical Disc

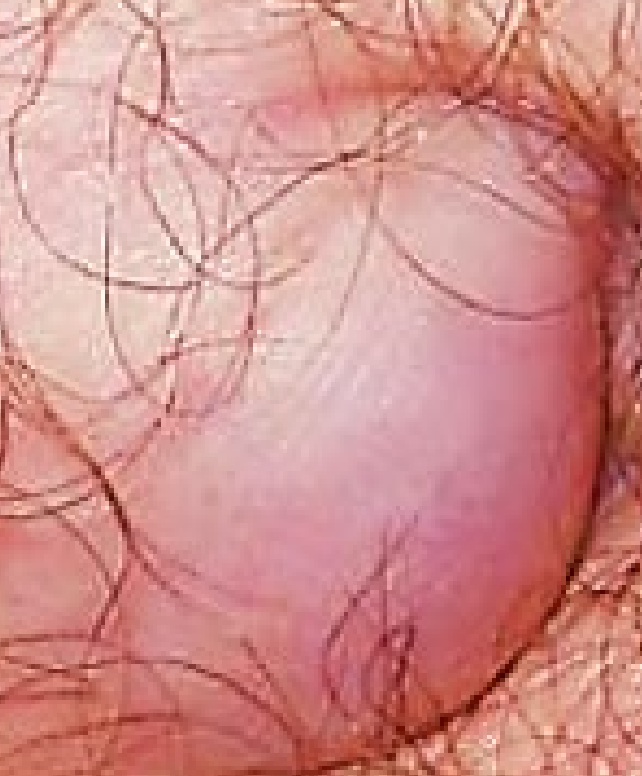

Para-Umbilical Hernia

Umbilical Hernia



R



- Umbilical hernia :95% will resolve spontaneously. If the hernia persists beyond the age of 2 years it is unlikely to resolve and surgical repair is indicated.
- Paraumbilical hernia: Defects up to 2 cm in diameter may be sutured primarily with minimal tension, although, the larger the defect, the more tension and the more likely it is that mesh reinforcement will be beneficial.

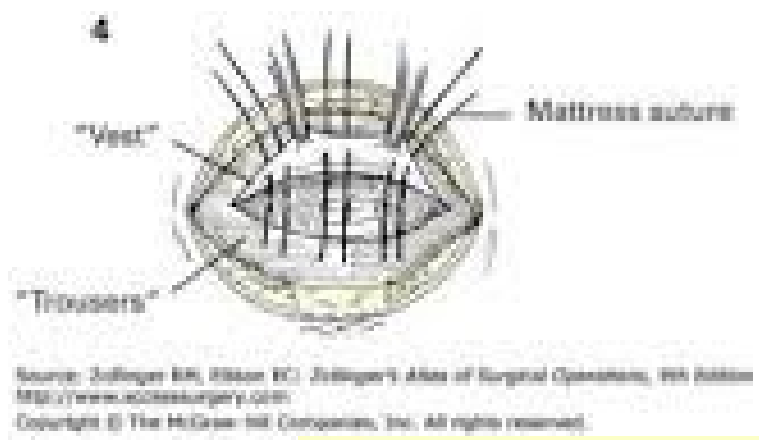
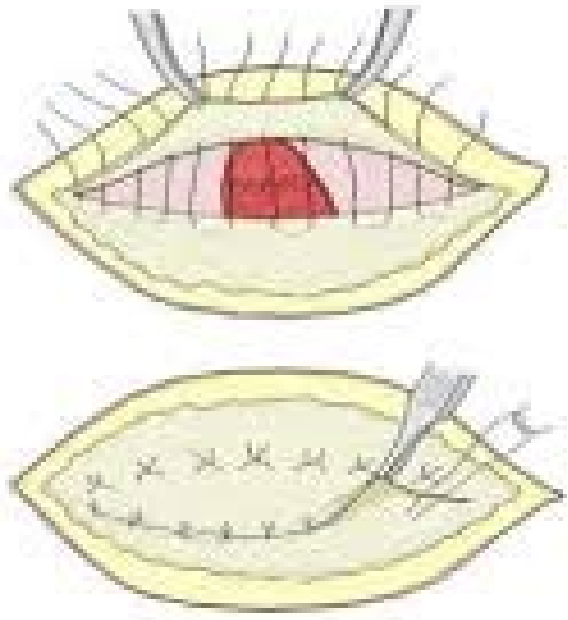
- OPEN UMBILICAL HERNIA (Mayo) REPAIR .

The lower flap is then inserted beneath the upper flap and sutured to it, with the upper flap being brought downwards over it so that the tissue is two layered (double breasted). Non absorbable sutures are used.

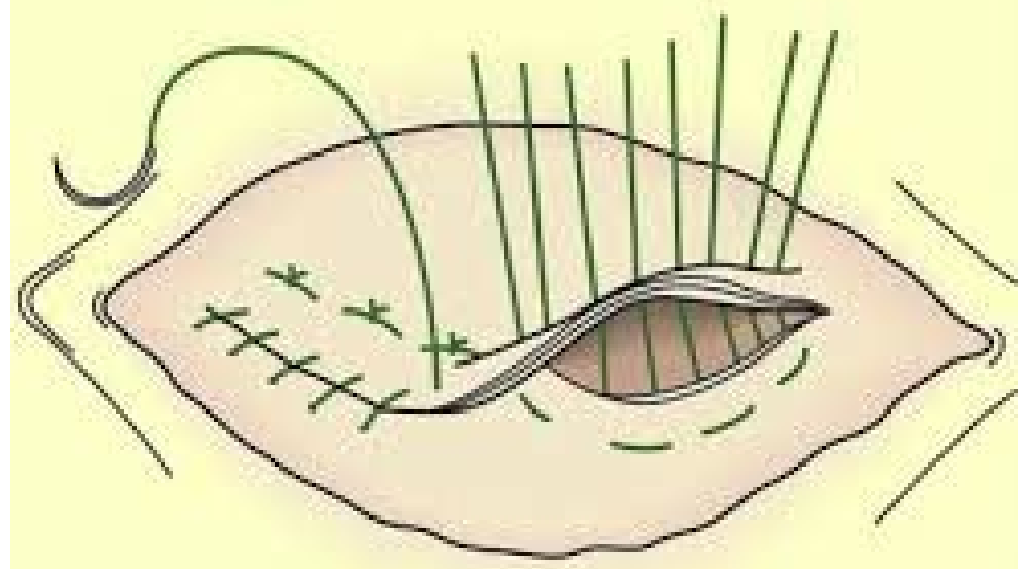
- LAPAROSCOPIC UMBILICAL HERNIA REPAIR (Mesh)

- EMERGENCY REPAIR OF UMBILICAL HERNIA

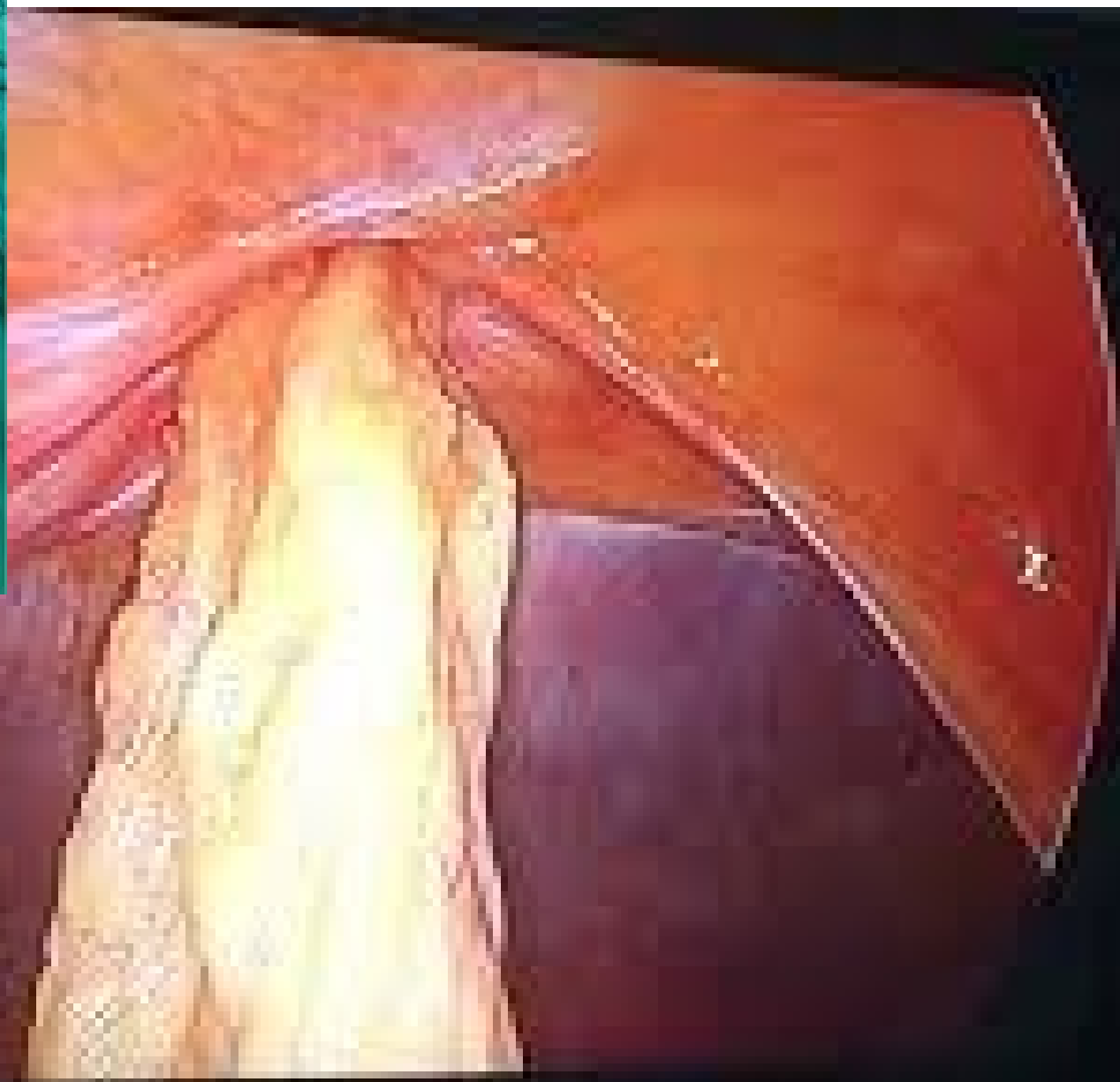
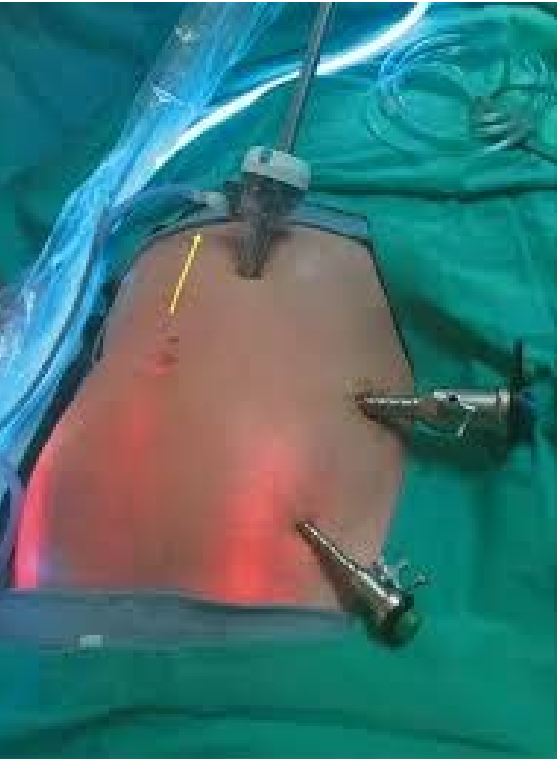Incarceration, bowel obstruction and strangulation

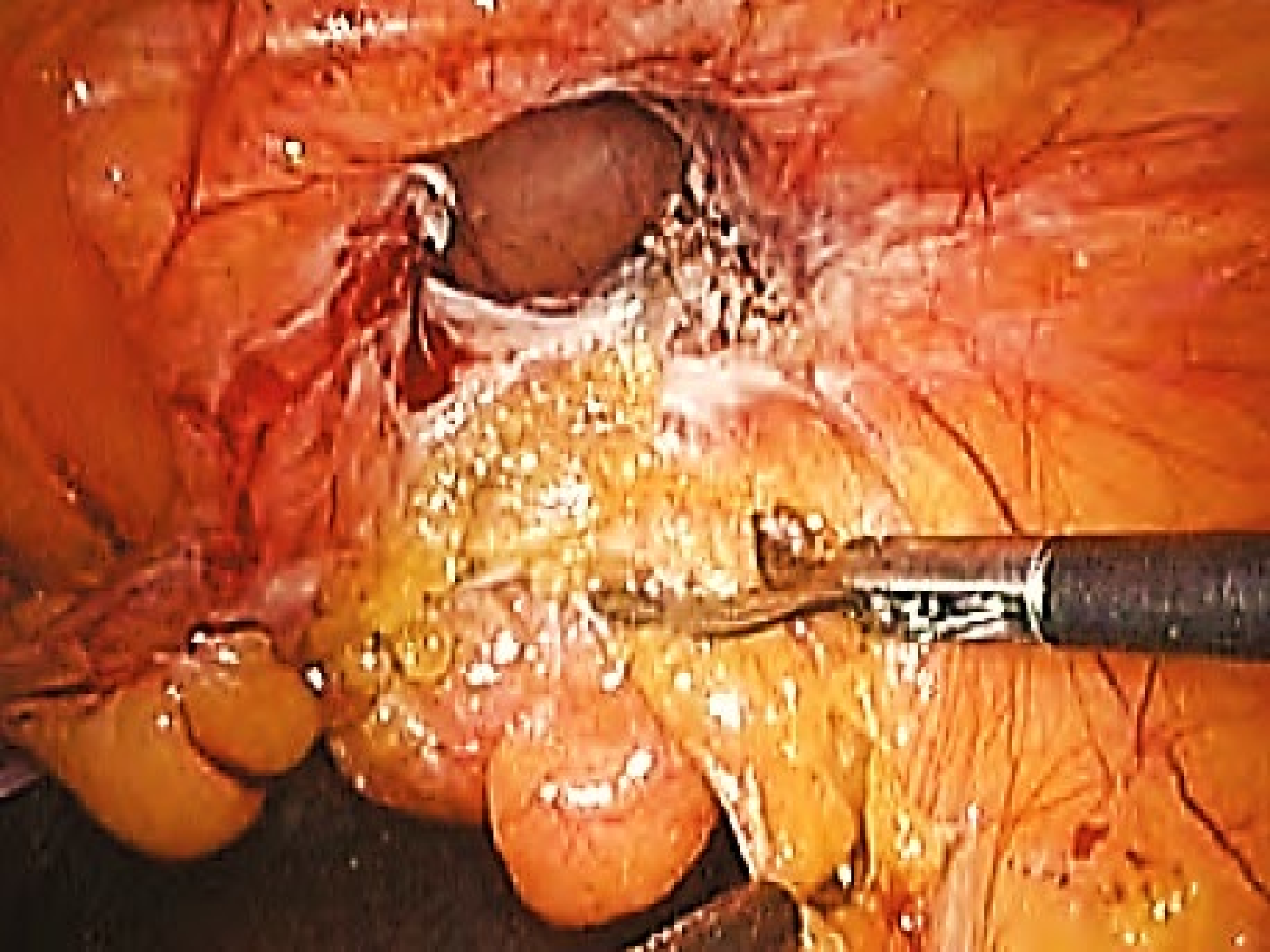


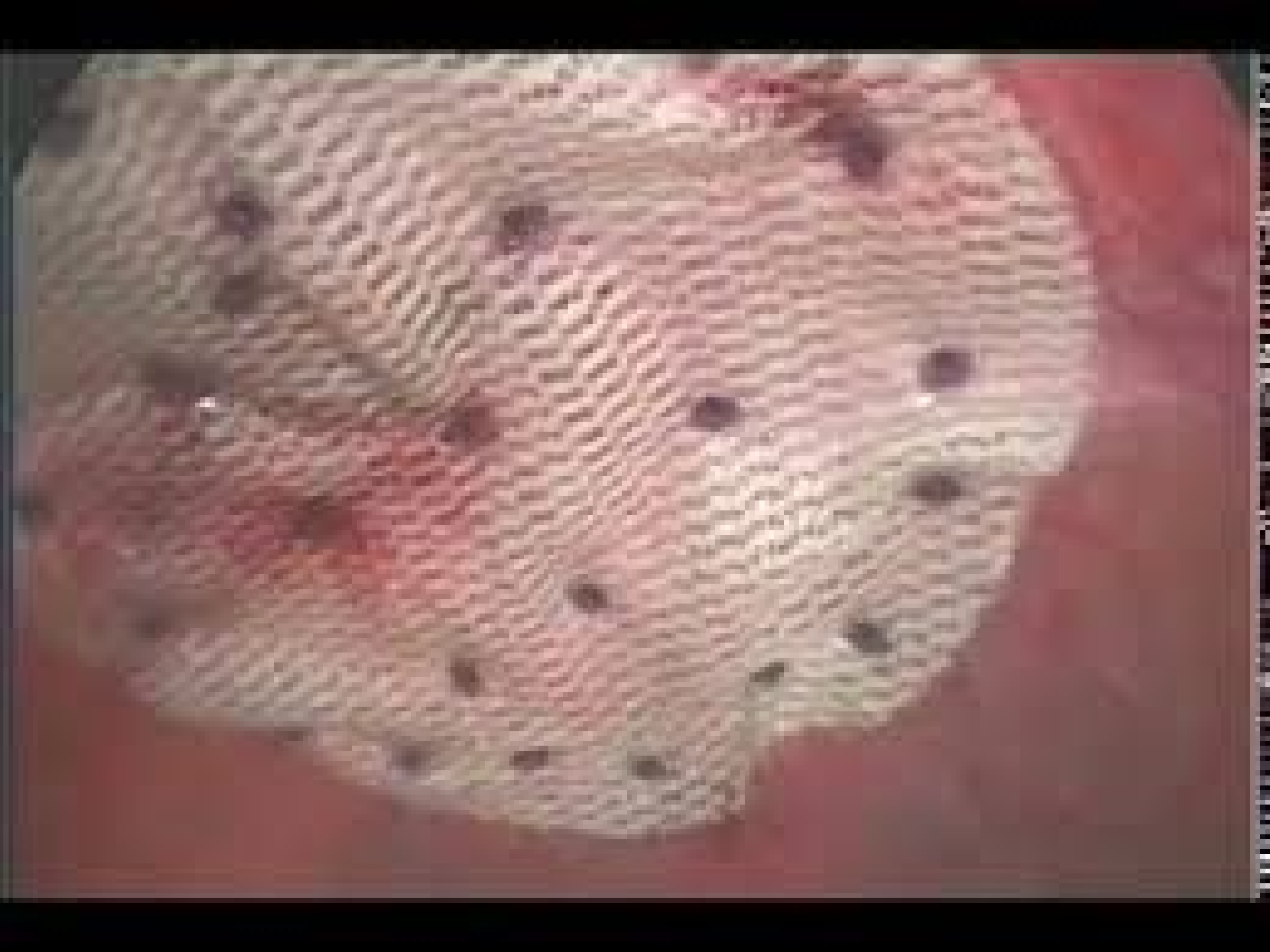Mayo repair

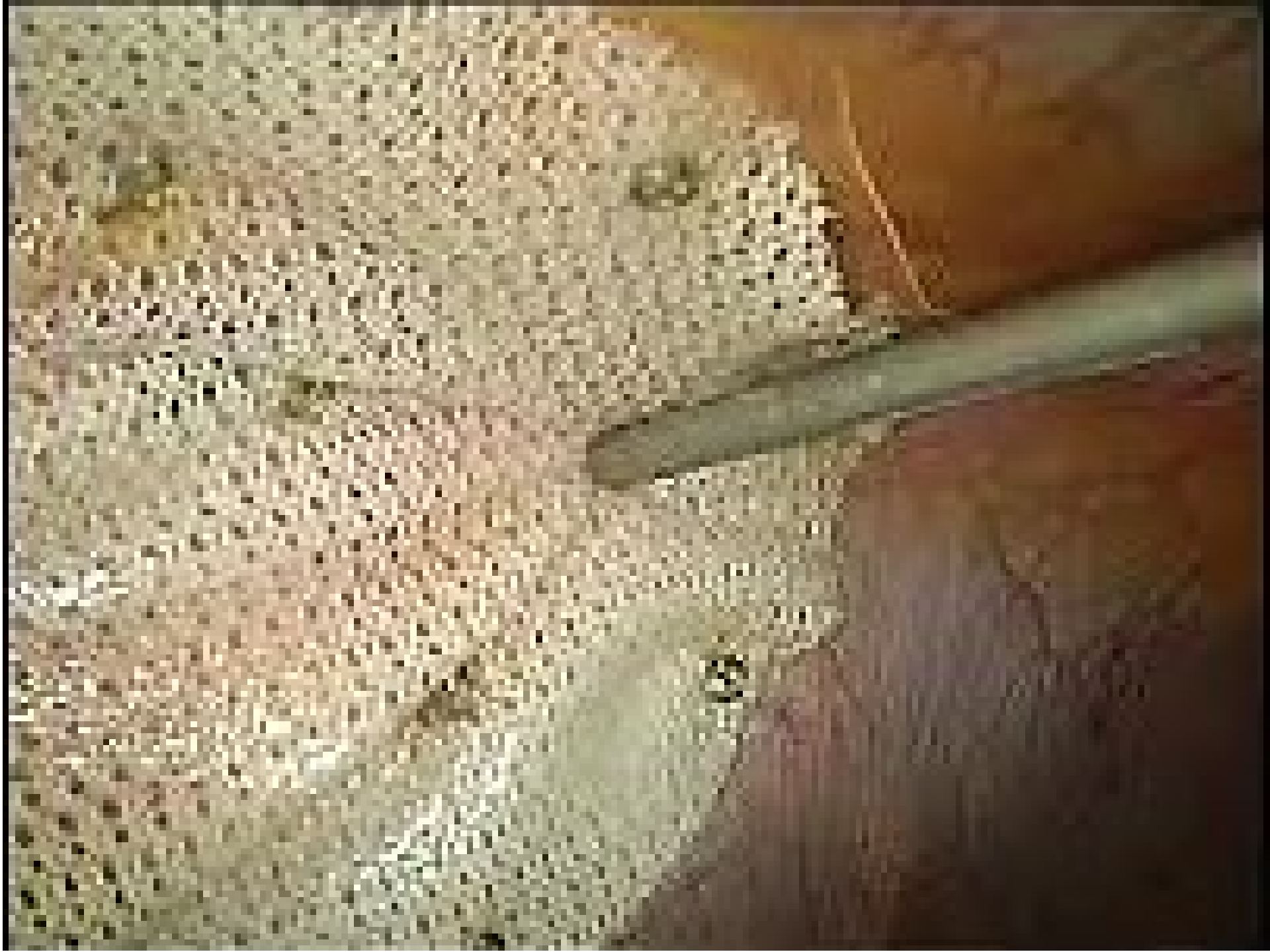

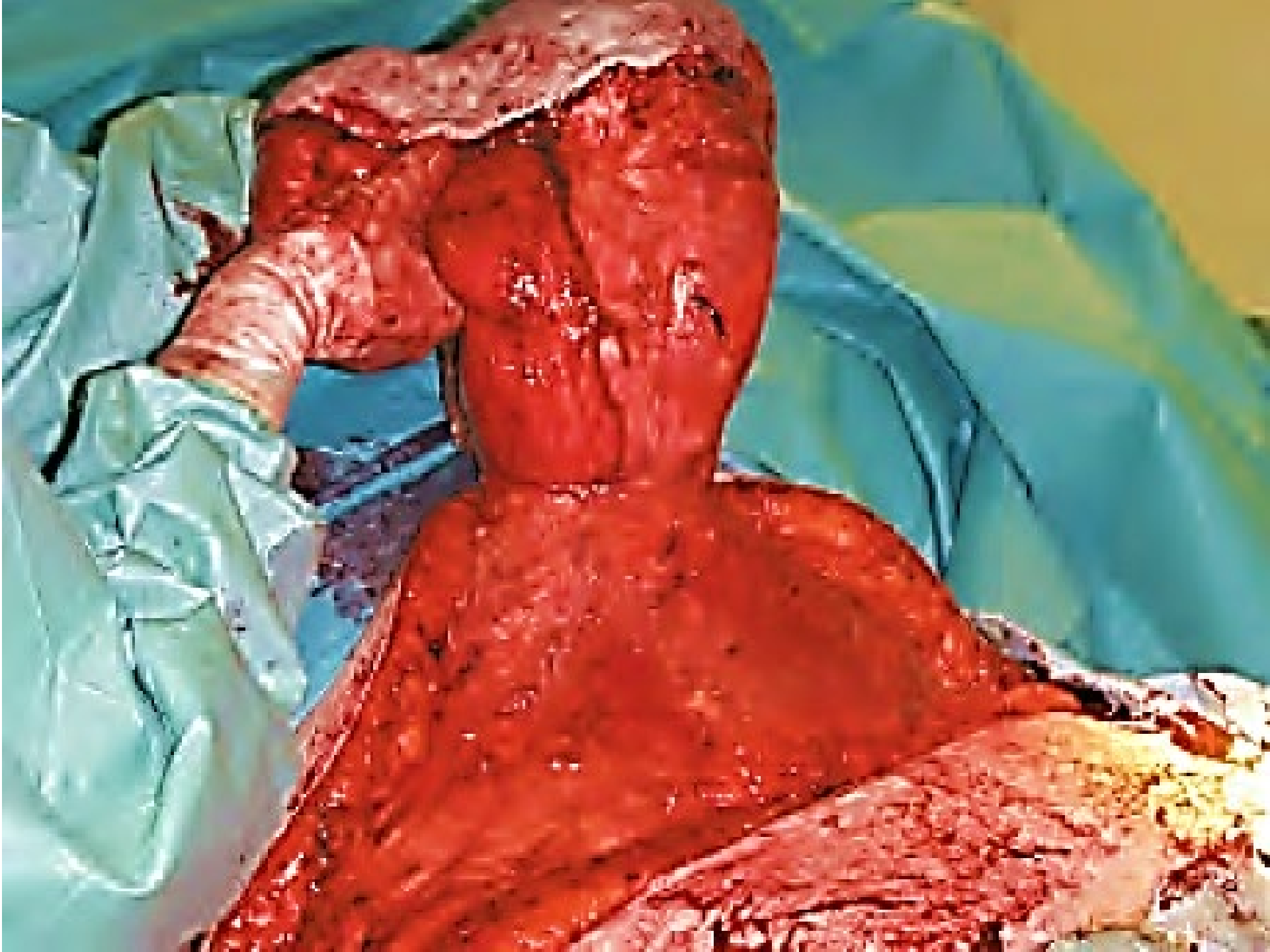
Mayo's Repair





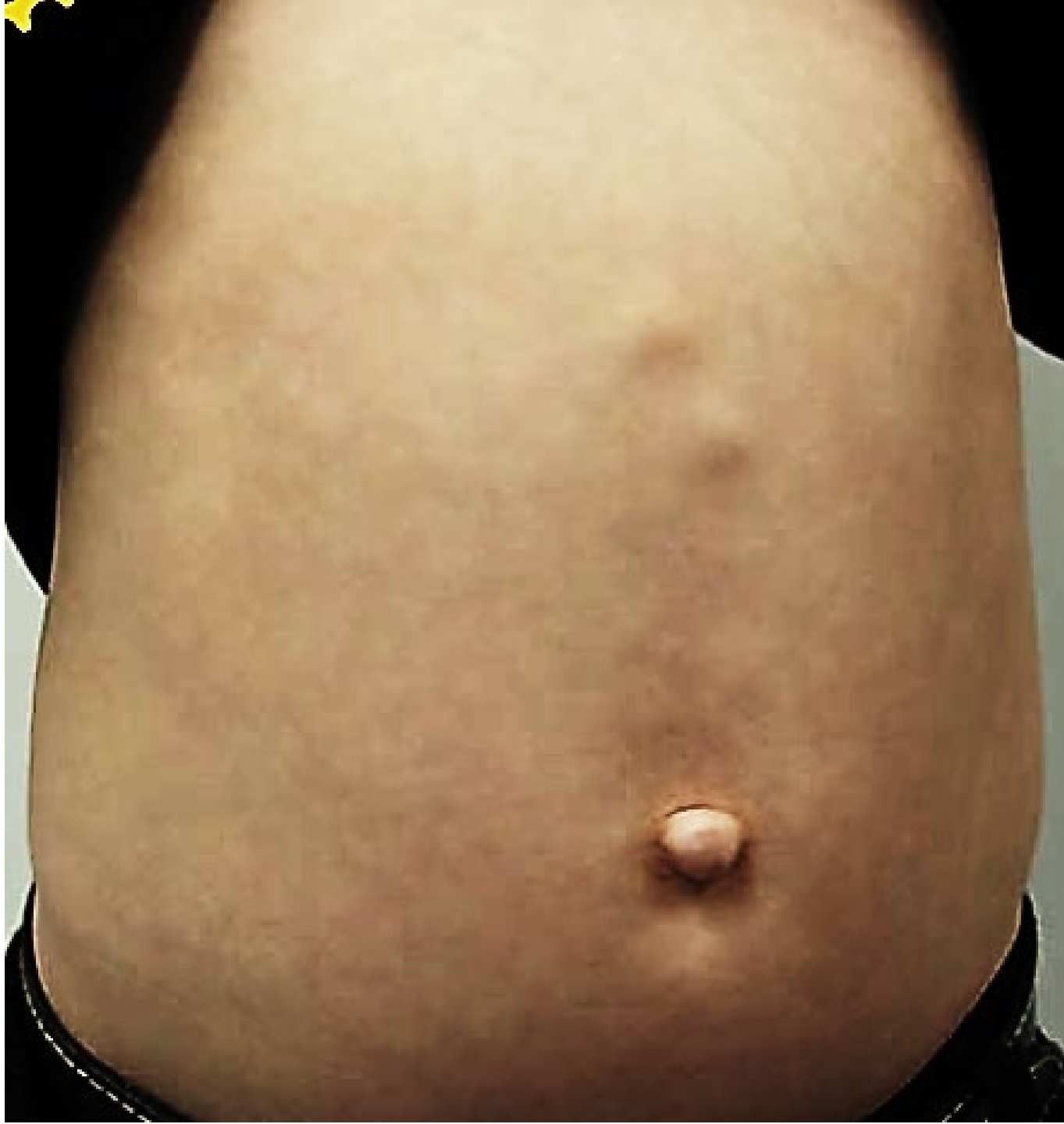


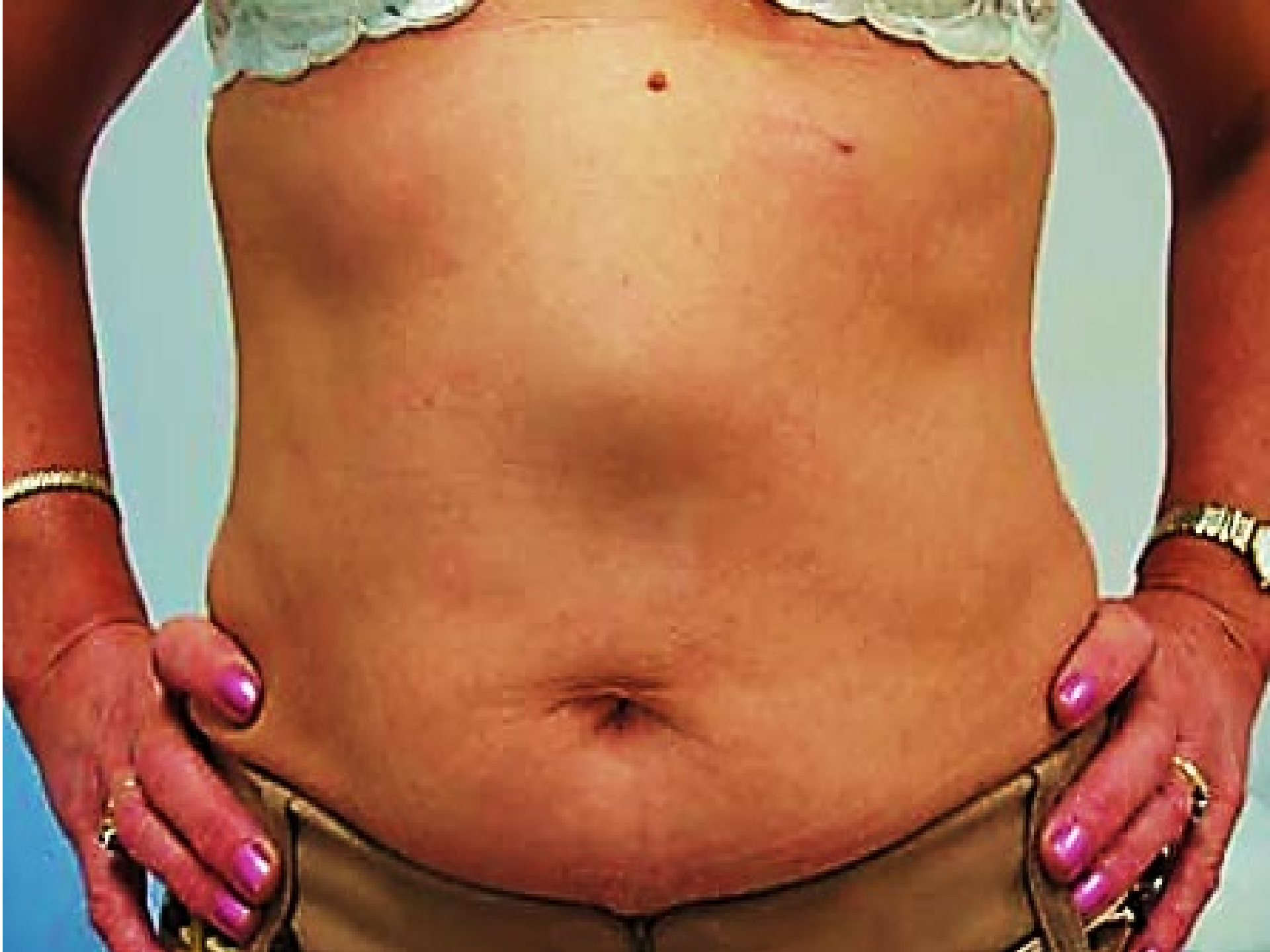


Epigastric Hernia

- Midline defect of the linea alba in the upper abdomen (any where between the xiphoid process and the umbilicus, usually midway).
- Weaknesses due to abnormal decussation of aponeurotic fibers related to heavy physical activity
- It is more common in men.(Insidious).
- The defect is usually less than 1 cm in size.
- This is typically a protrusion of extraperitoneal fat only.
- Frequently is irreducible (resemble the shape of a mushroom).
- Less commonly, there is a larger defect with a true peritoneal sac, which typically contains only the greater omentum with no bowel involvement .
- Firm, tender nodule that typically has no cough impulse.
- DDX :Lipoma, peptic ulcer and post-prandial dyspepsia, possibly due to the gastric distension pushing on the hernia.
- The most common cause of ‘recurrence’ is failure to identify a second defect at the time of original repair.





Treatment :

- Deferrable.
- SURGERY.
- Open / Laparoscopic

Open

- The defect in the linea alba is closed with non-absorbable sutures in adults and absorbable sutures in children.
- In larger hernias and when a peritoneal sac is present, the surgical approach is similar to an umbilical mesh repair.

Laparoscopic repair by mesh

Incisional hernia

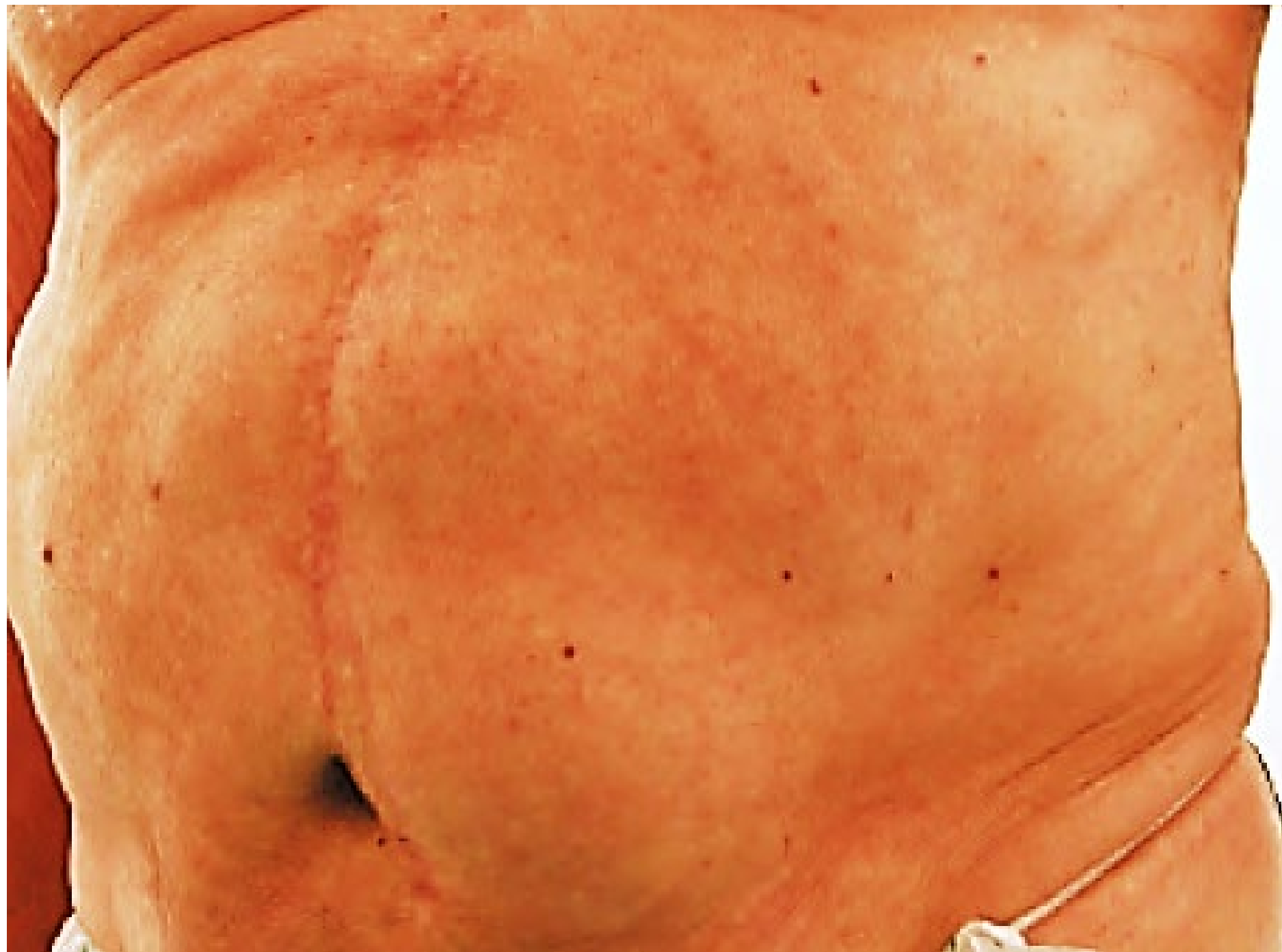- These arise through a defect in the musculofascial layers of the abdominal wall in the region of a postoperative scar .
- 10–50% of laparotomy incisions and 1–5% of laparoscopic port-site incisions.
- Factors predisposing to their development are patient factors (obesity, general poor healing due to malnutrition, immunosuppression or steroid therapy, chronic cough, cancer), wound factors (poor quality tissues, wound infection) and surgical factors (inappropriate suture material, incorrect suture placement).

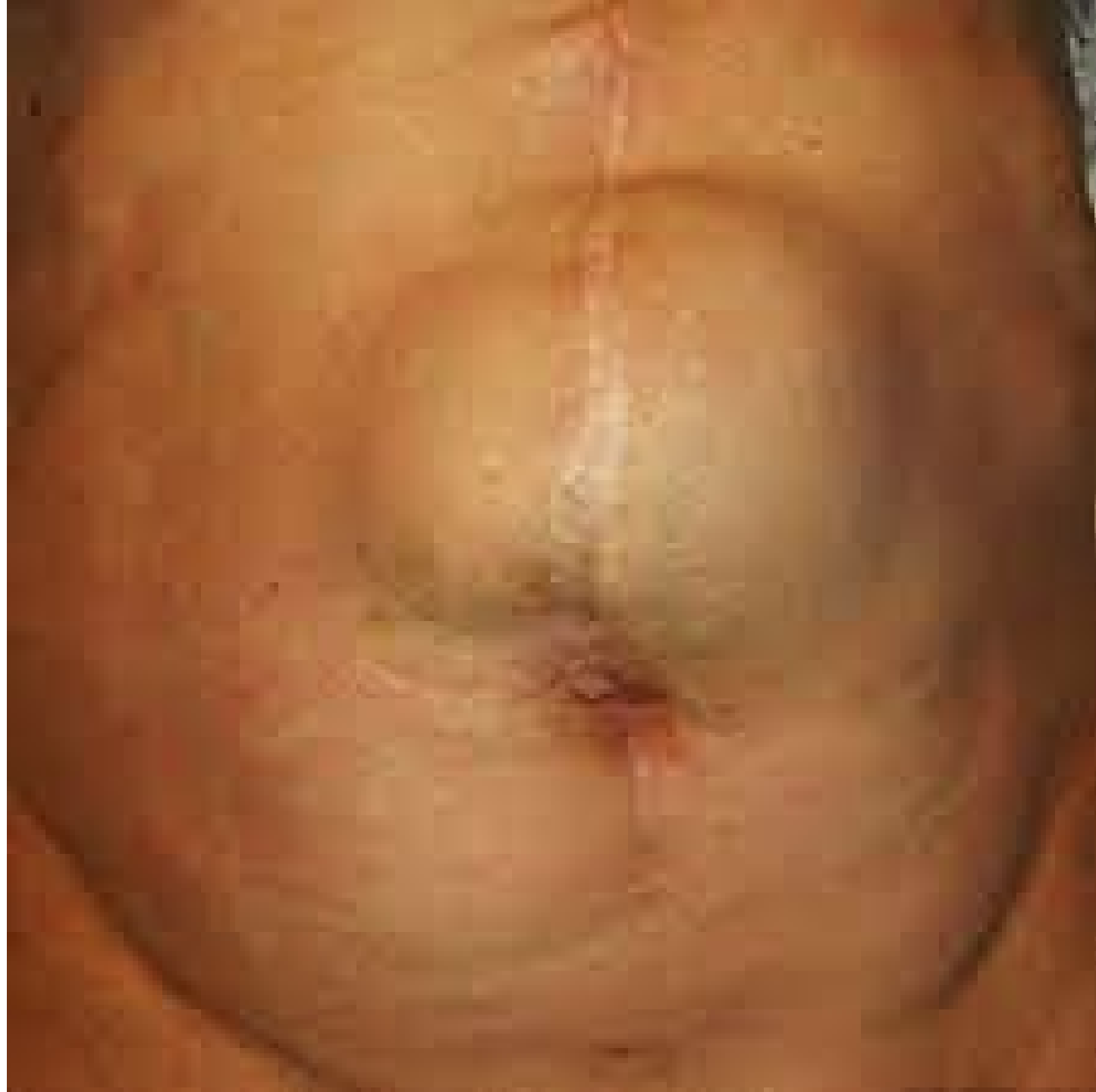The classic sign of wound disruption is a serosanguineous discharge.

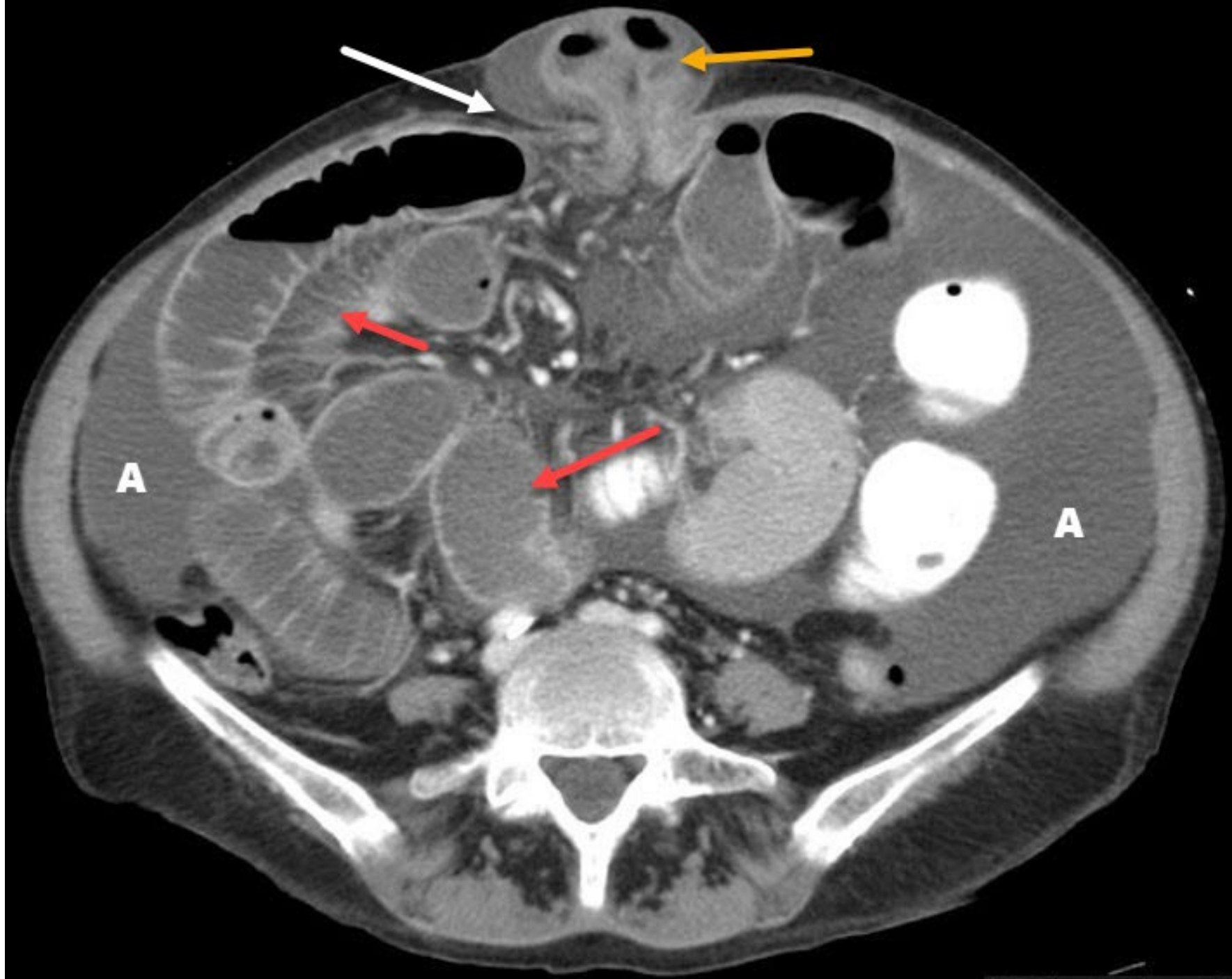
- Laparoscopic key hole.

Clinical Features

- Localised / diffuse bulging under the scar of previous surgical site incision.
- Incisional hernias tend to increase steadily in size with time.
- The skin overlying large hernias may become thin and atrophic so that peristalsis may be seen in the underlying intestine.
- Attacks of partial intestinal obstruction are common (coexisting internal adhesions).
- Most incisional hernias are broad-necked and carry a low risk of strangulation.







Treatment

- Approximation of the musculofascial layers should be done with minimal tension and prosthetic mesh should be used to reduce the risk of recurrence.
- Mesh may be contraindicated in a contaminated field.
- Appropriate systemic antibiotics should be used.

- OPEN REPAIR with retromuscular sublay repair.
- LAPAROSCOPIC REPAIR with the use of a tissue-separating mesh is essential (dual mesh).
- Ramirez's component separation technique, which incorporates relaxing incisions in the external oblique aponeurosis and/or the posterior sheath

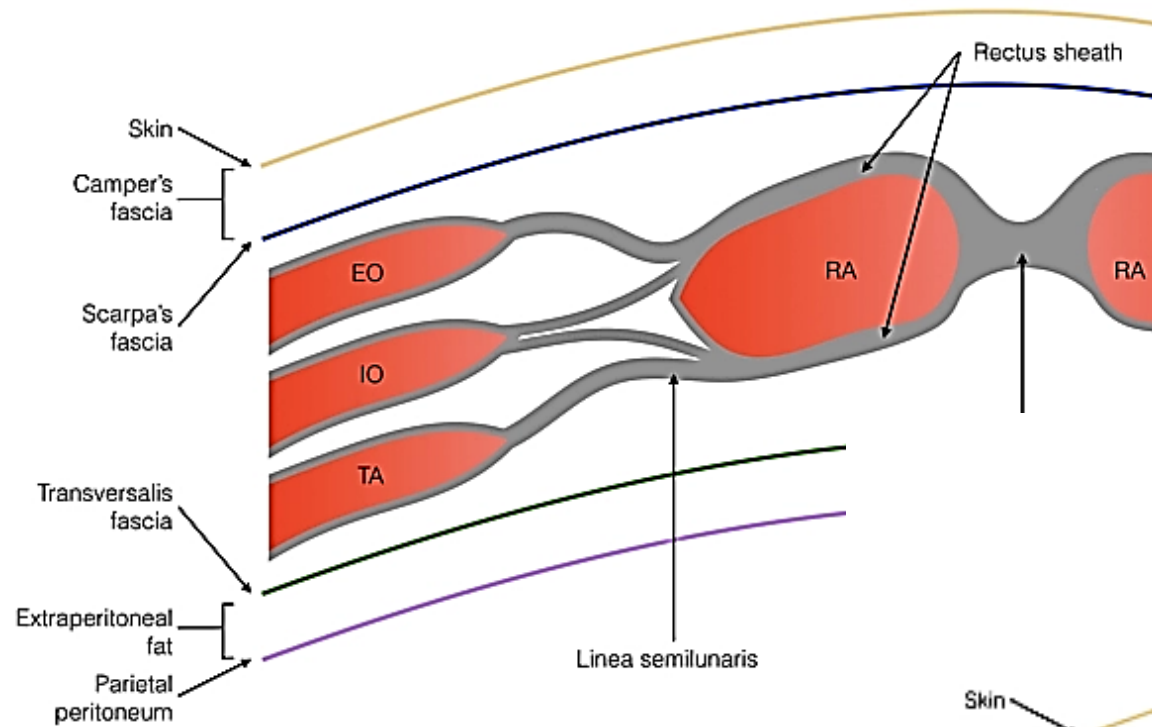
Prevention of recurrence

- Risk factors (nutrition, obesity, general conditions)
- Drains should be brought out through separate incisions and not through the wound itself because this leads to hernia formation.

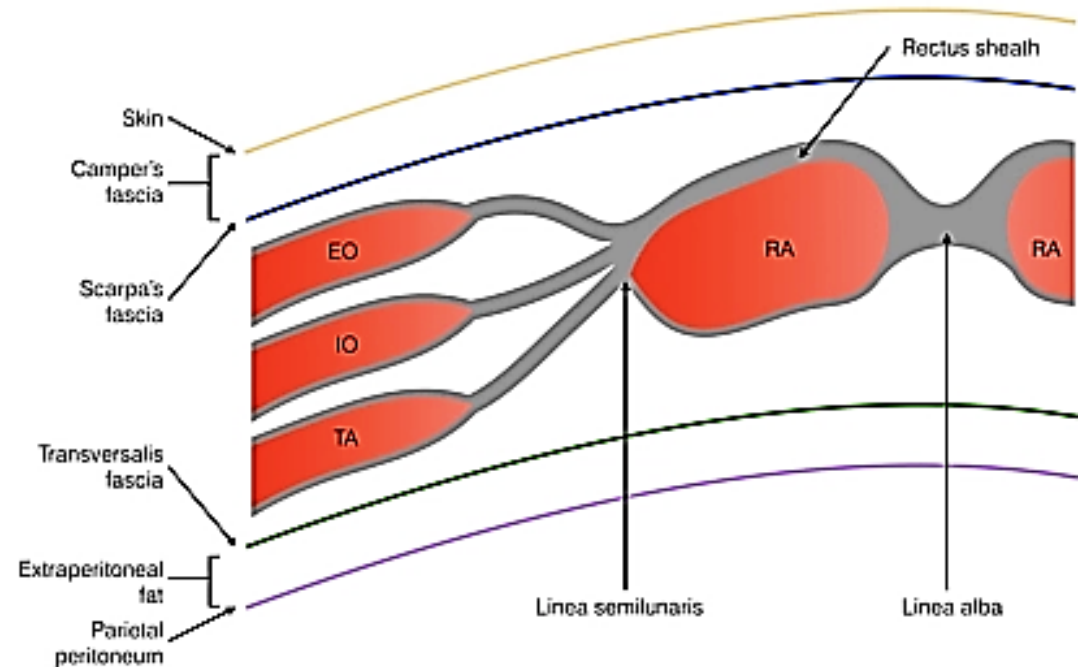
Spigelian Hernia

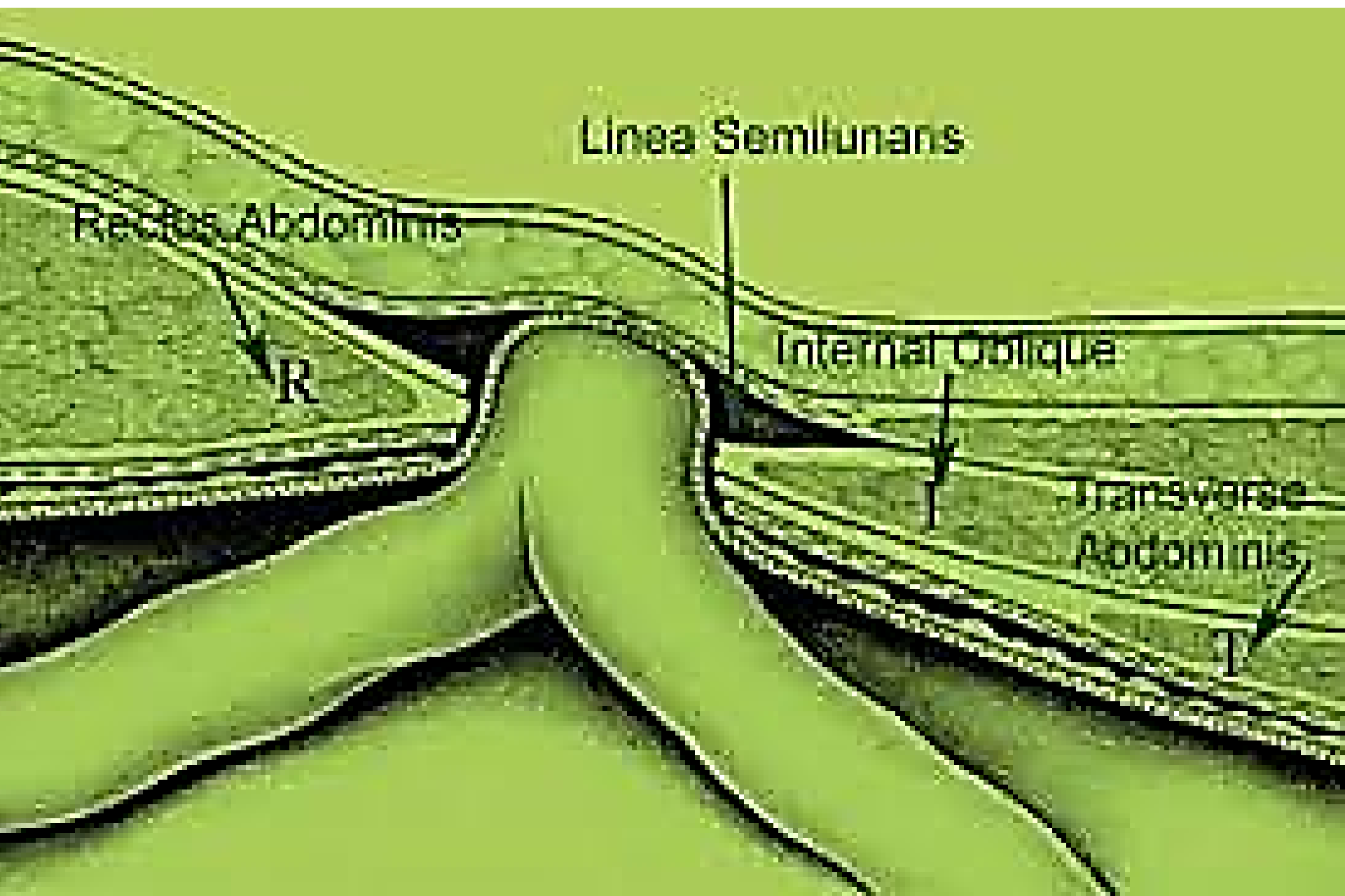
- These hernias are uncommon and occur at any age.
- In young patients they usually contain extraperitoneal fat only but in older patients there is often a peritoneal sac and they can become very large indeed.
- They arise through a defect in the spigelian fascia, which is the aponeurosis of transversus abdominis. Often these hernias advance through the internal oblique as well and spread out deep to the external oblique aponeurosis. The spigelian fascia extends between the transversus muscle and the lateral border of the rectus sheath from the costal margin to the groin, where it blends into the conjoint tendon.
- Most spigelian hernias appear below the level of the umbilicus near the edge of the rectus sheath, but they can be found anywhere along the spigelian line (linea semilunaris).
- Are uncommon although are probably underdiagnosed. They affect men and women equally and can occur at any age, but are most common in elderly people.

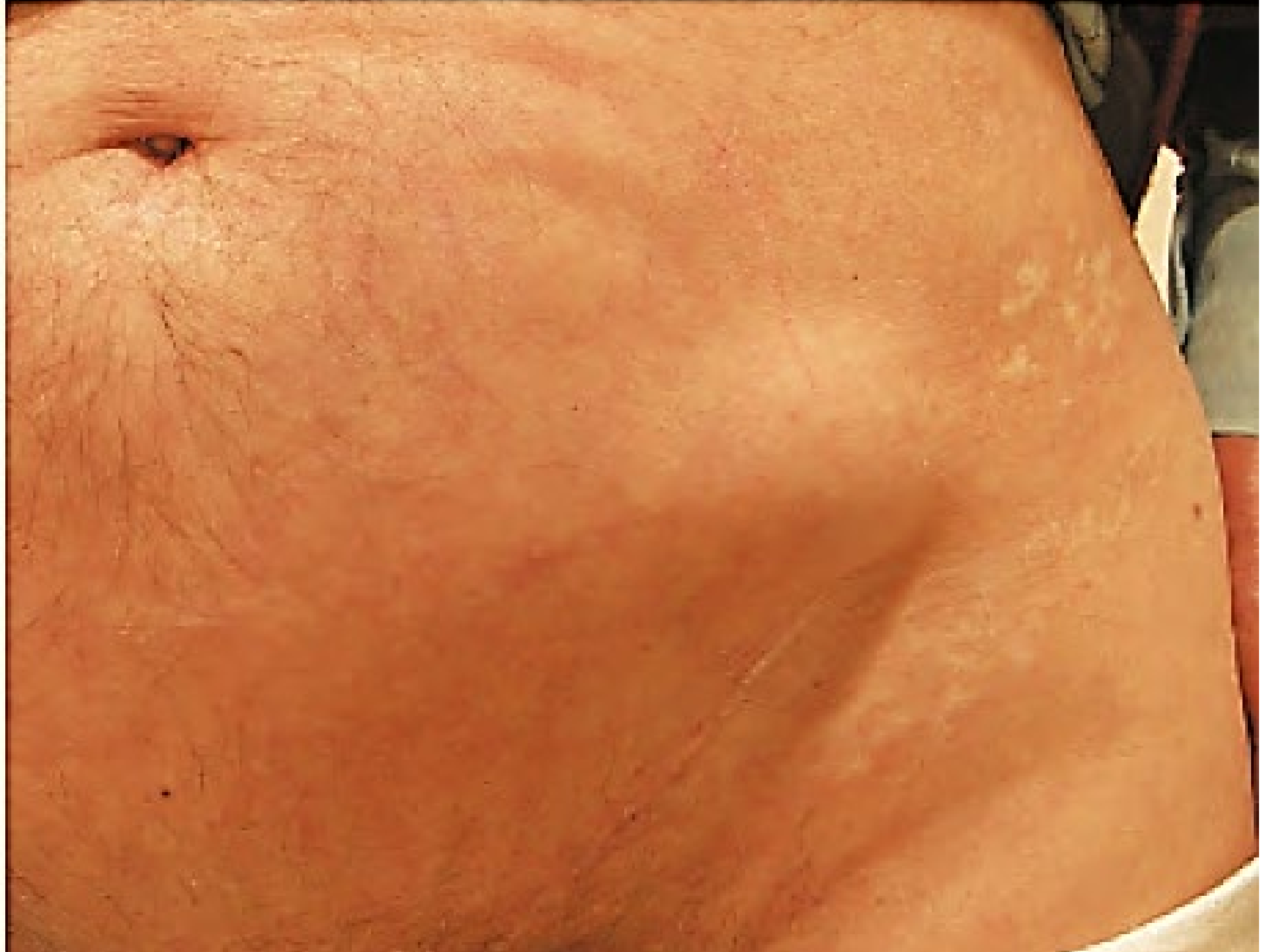Rectus sheath above arcuate line



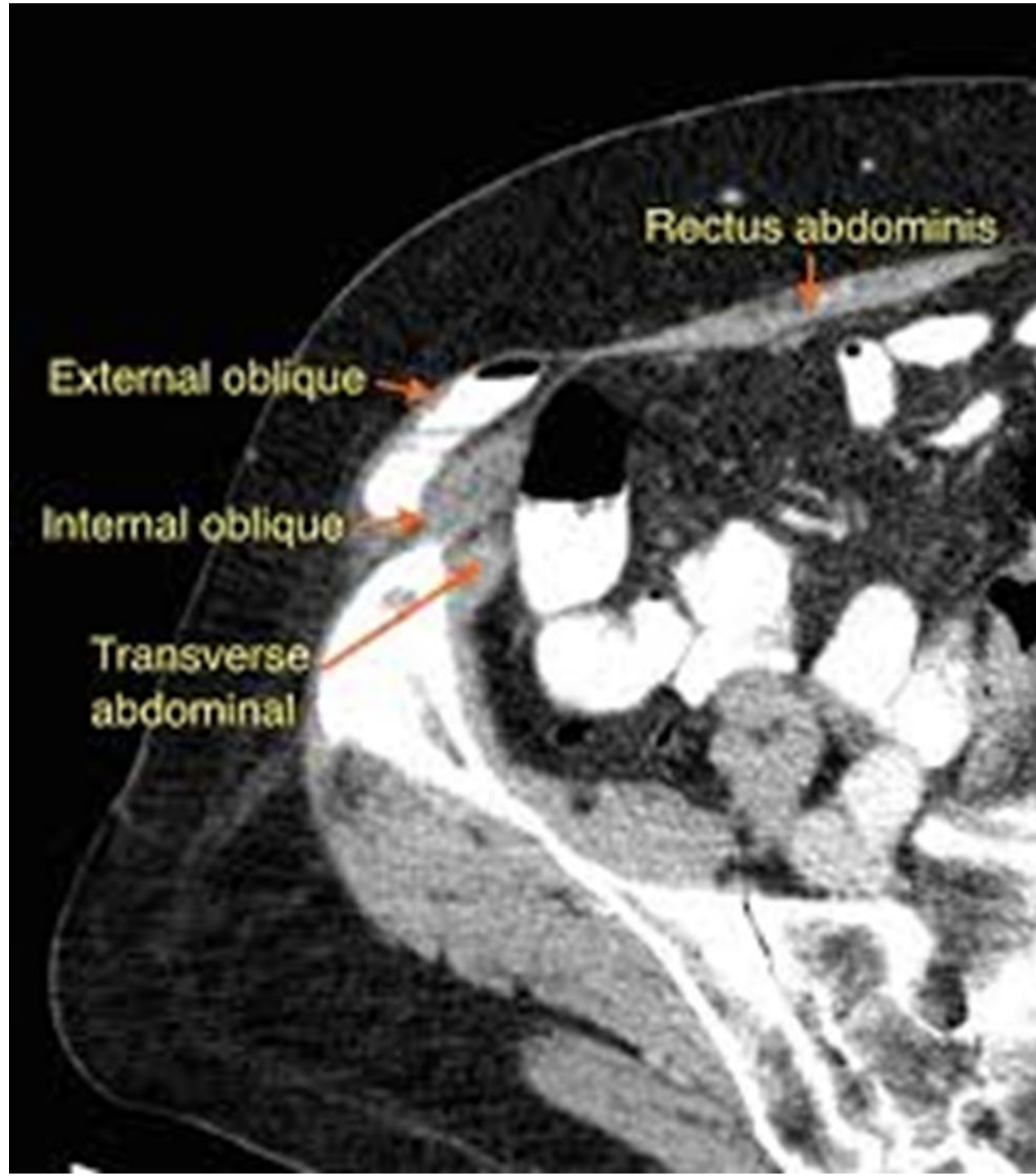Rectus sheath below arcuate line







- Rare, often misdiagnosed, high risk of complications
- The diagnosis should be suspected because of the location of the symptoms and is confirmed by CT. Ultrasonography has the advantage that it can be performed in the upright patient because no defect may be visible with the patient lying down.

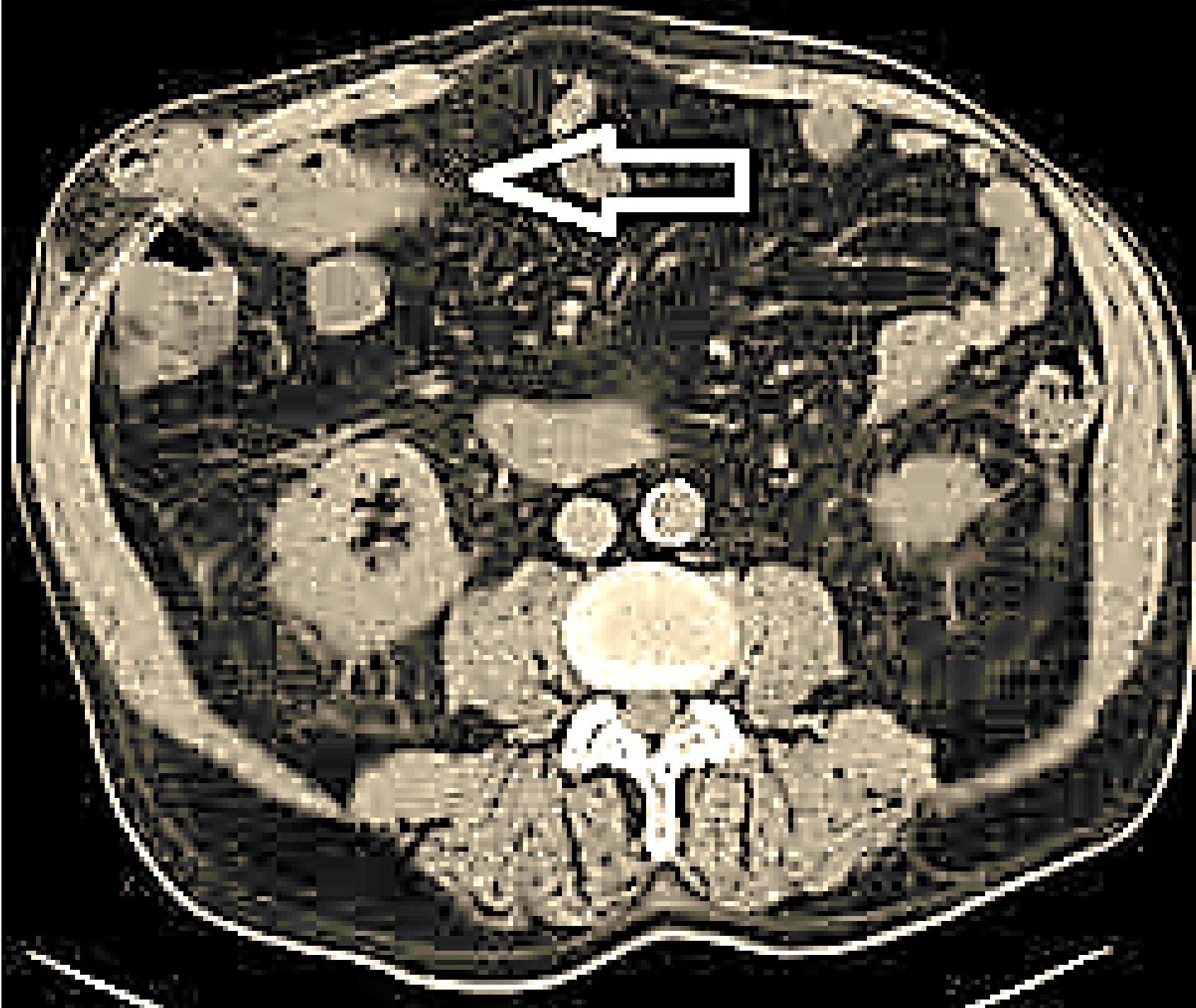

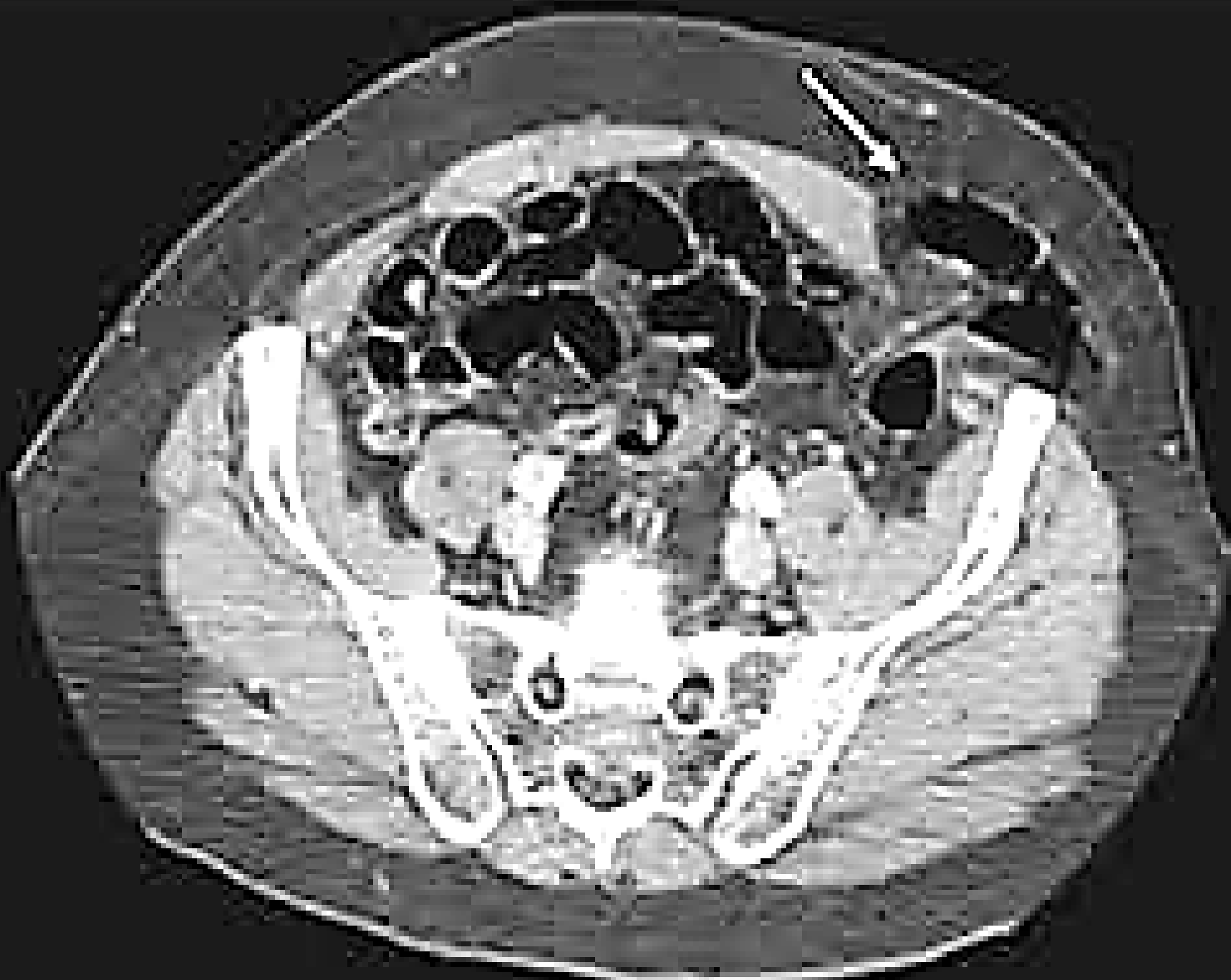
Rectus abdominis

External oblique

Internal oblique

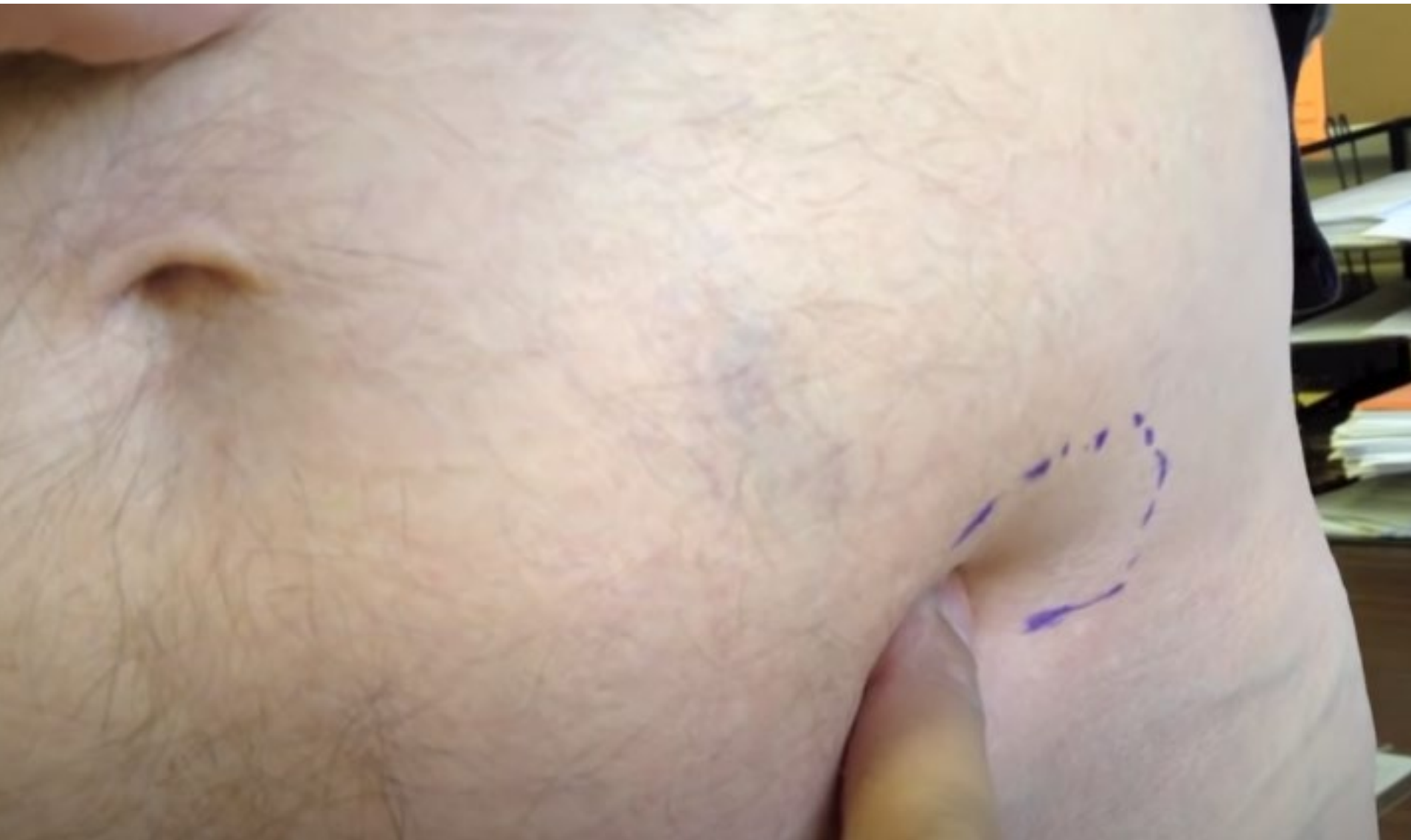Transverse abdominal

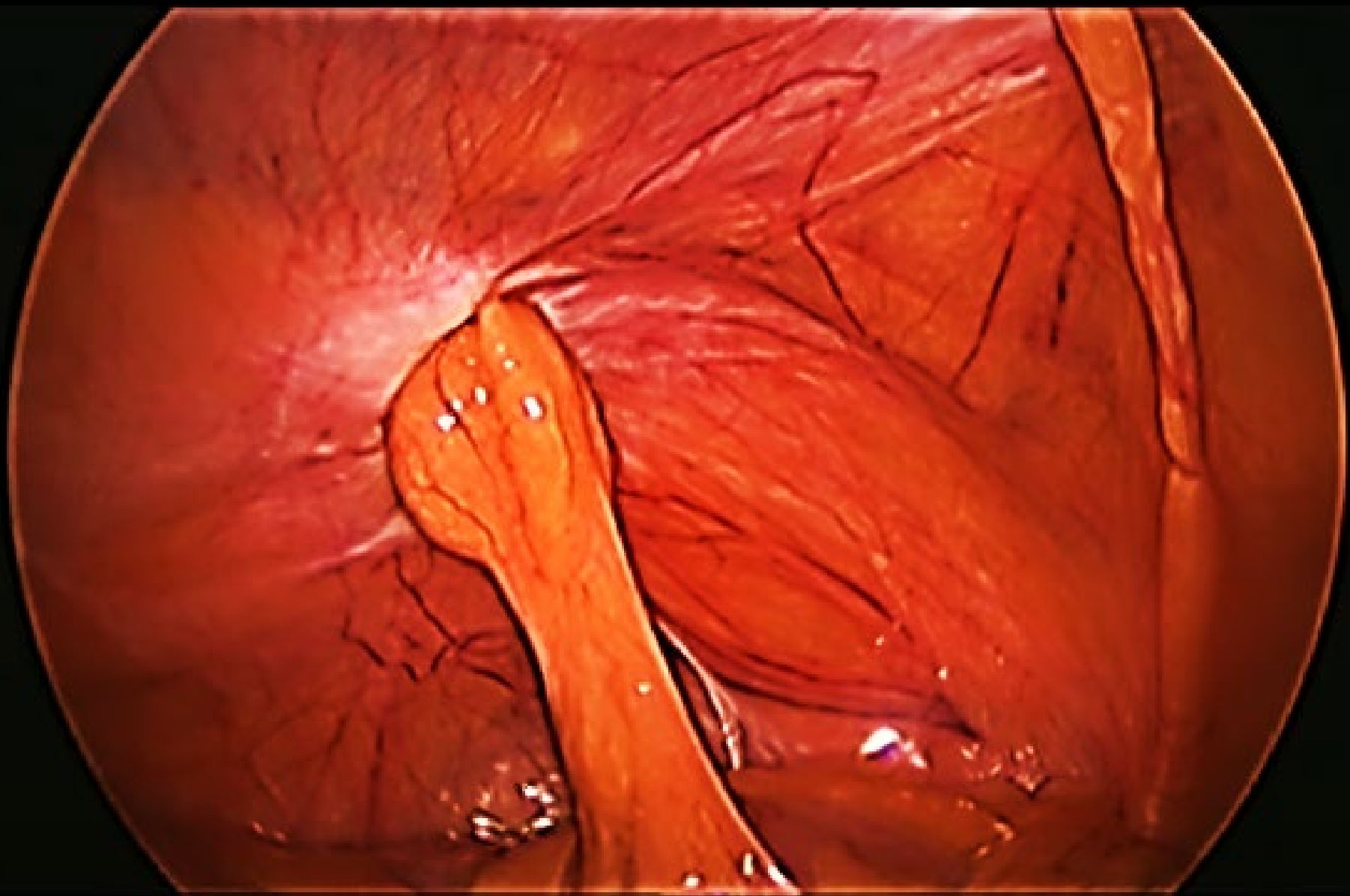

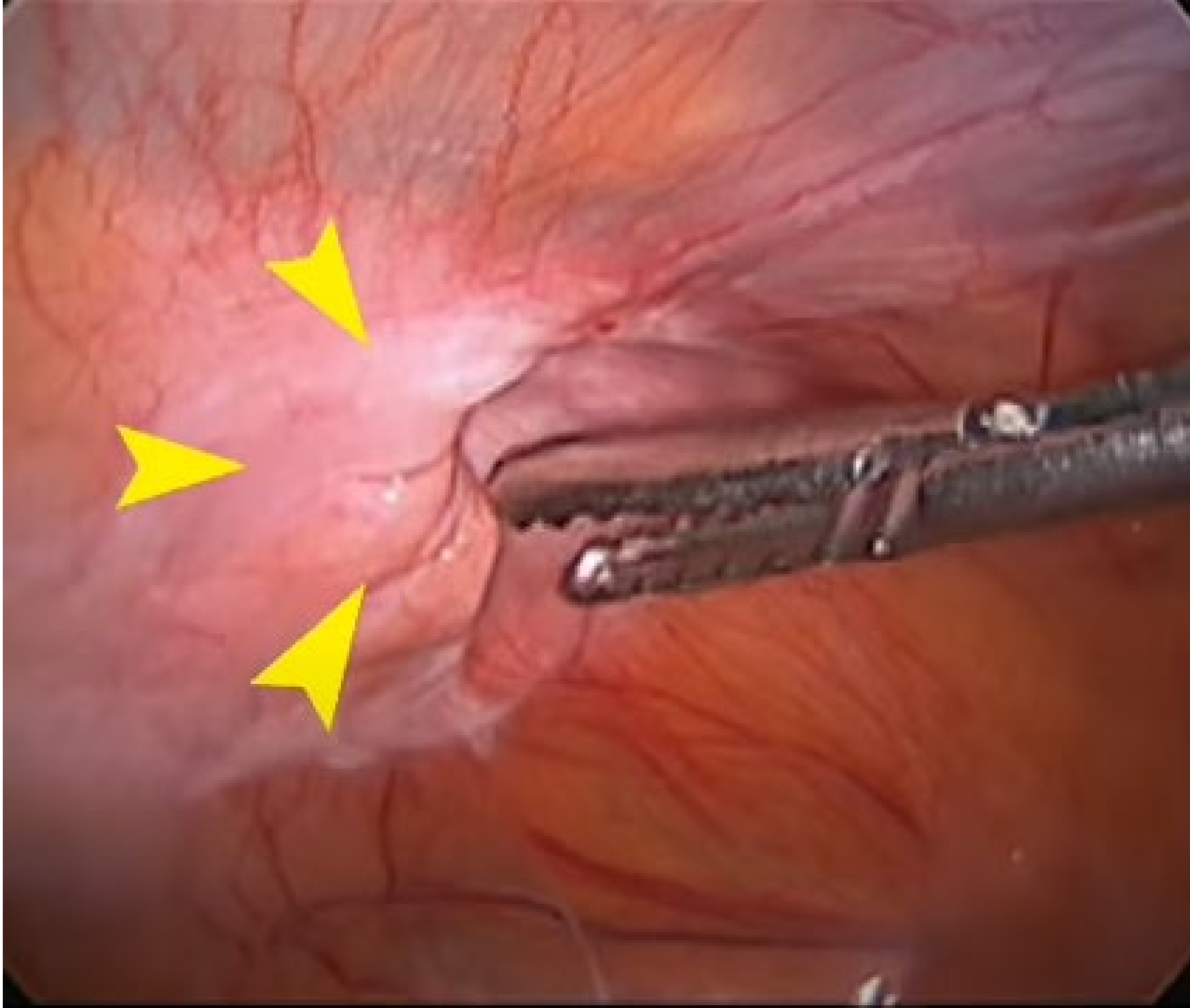


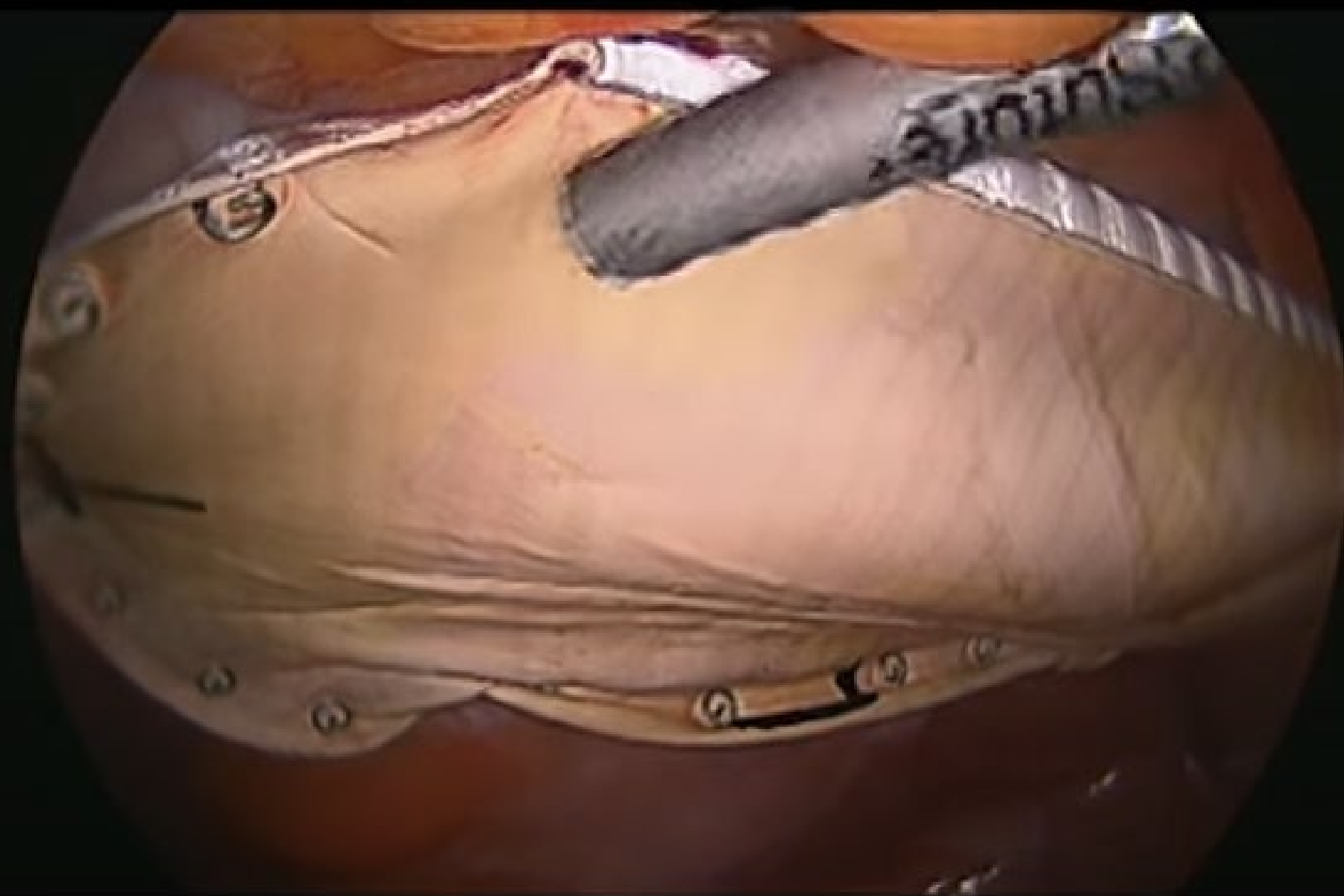Treatment

- Open repair with Mesh (Herniotomy and hernioraphy).
- Laparoscopic repair
 - TEP (only extraperitoneal fat).
 - Intraperitoneal onlay of mesh (IPOM) or TAPP technique (intraperitoneal sac is present).



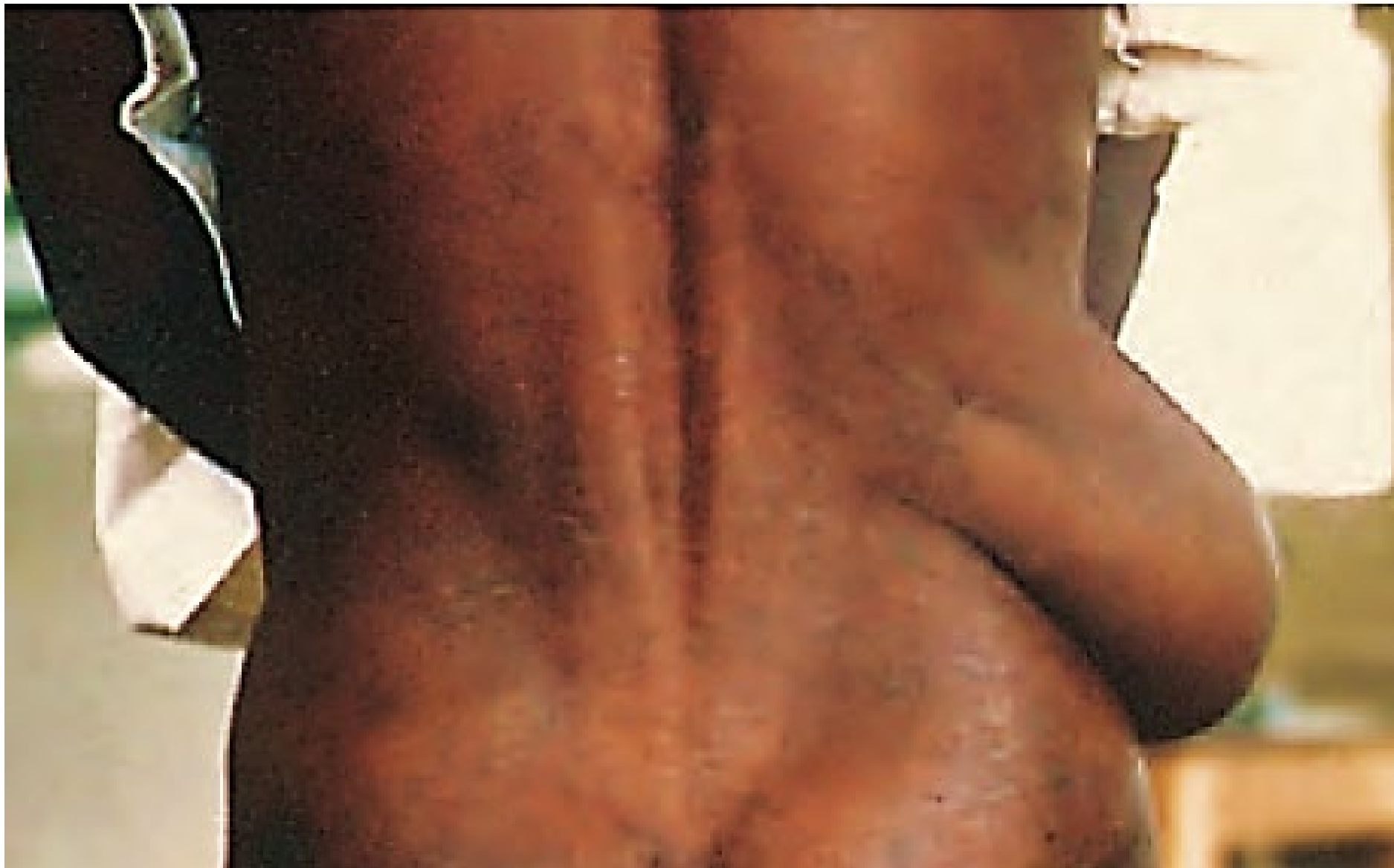





Lumbar Hernia

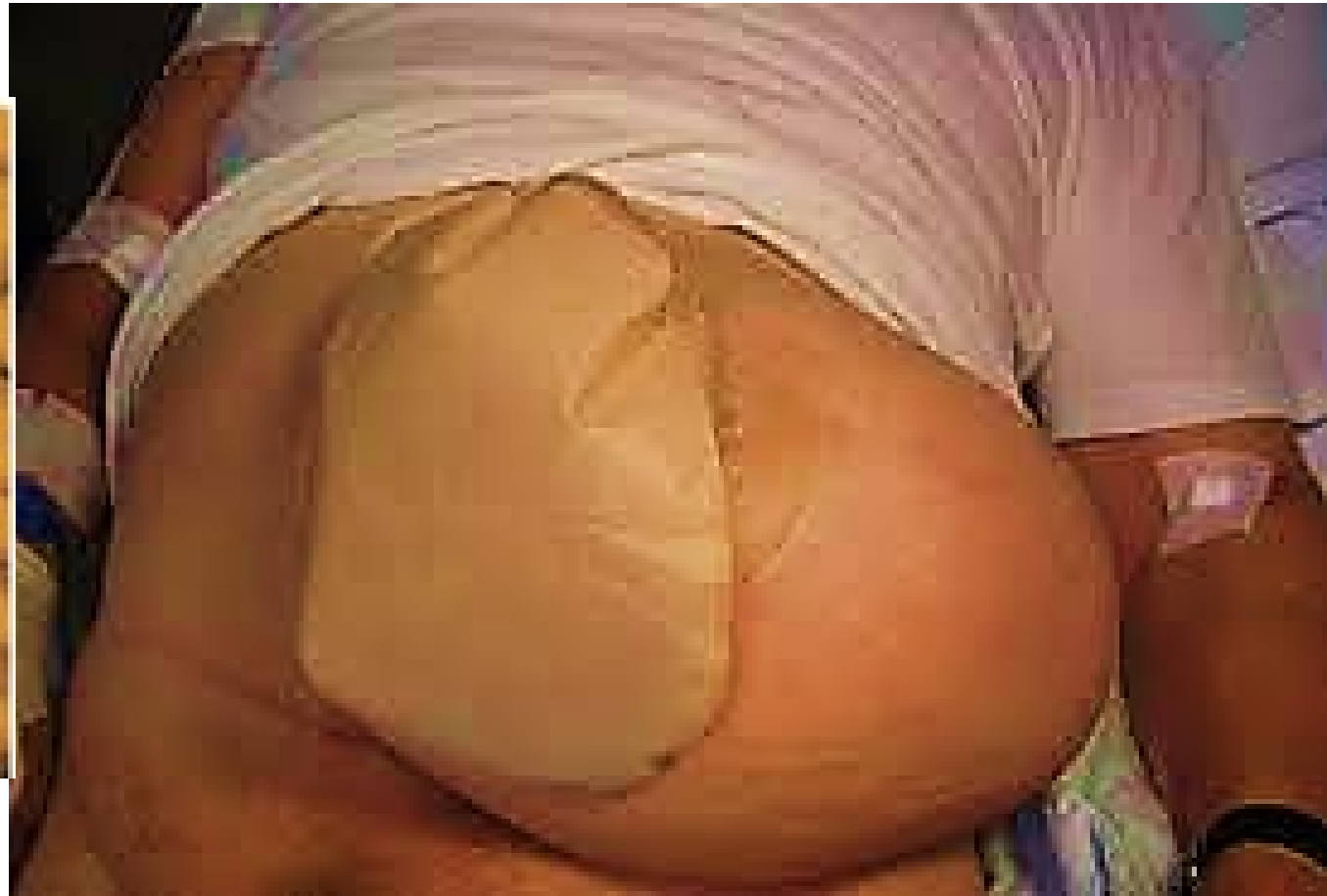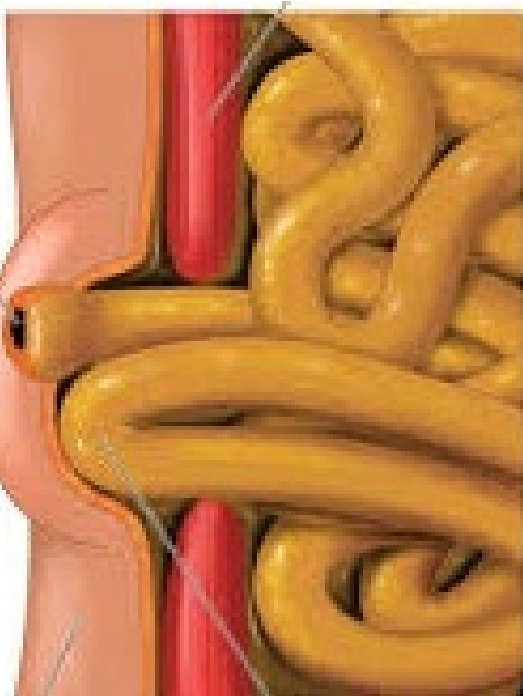
- Inferior lumbar triangle of Petit > Superior lumbar triangle .
- Primary lumbar hernias are rare, but may be mimicked by incisional hernias arising through flank incisions for renal operations, or through incisions for bone grafts harvested from the iliac crest.
- A lumbar hernia must be distinguished from, a lipoma; cold (tuberculous) abscess and pseudo-hernia due to local muscular paralysis (injury to the subcostal nerve during a kidney
- Operation) .
- Lumbar hernias can be approached by open or laparoscopic TAPP approach surgery. The defects can be difficult to close with sutures and mesh is recommended.

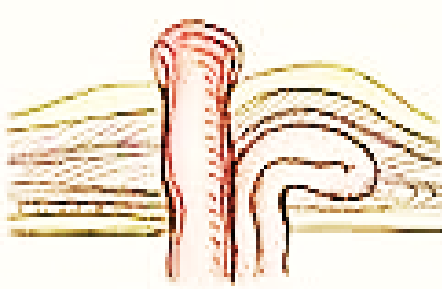
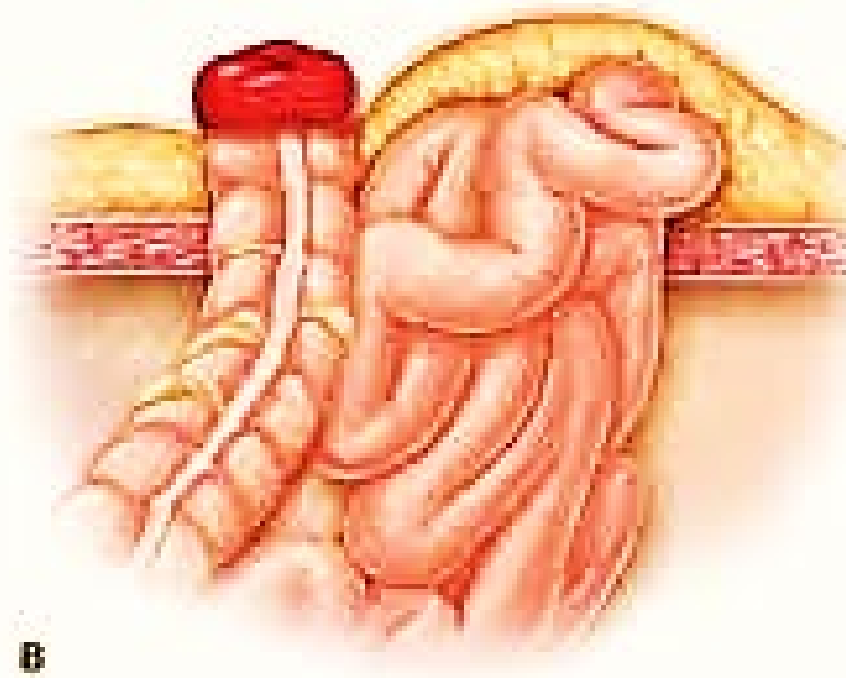
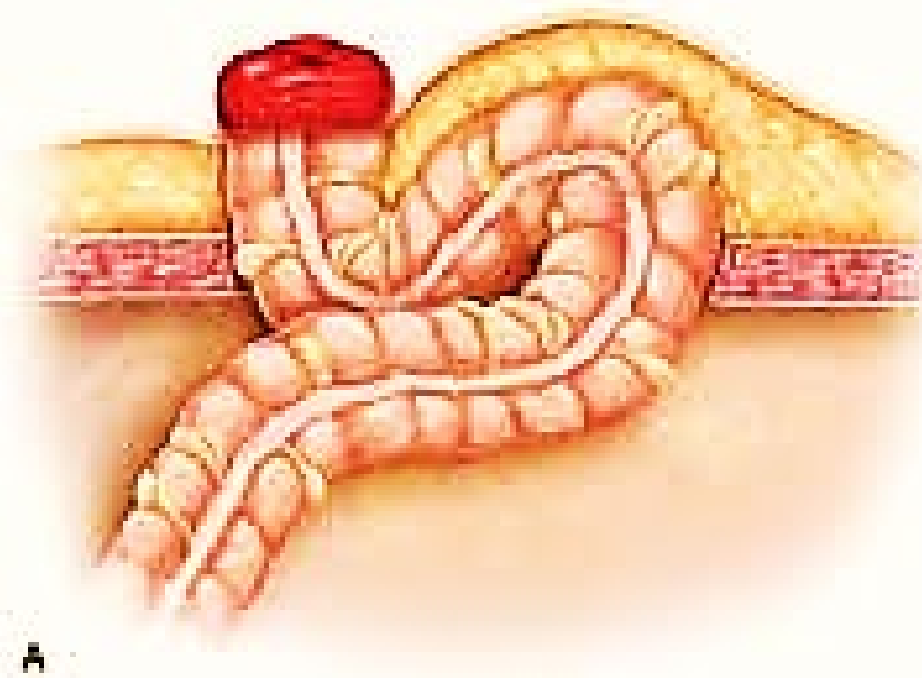


Inferior lumbar hernia, which contained caecum, appendix and small bowel

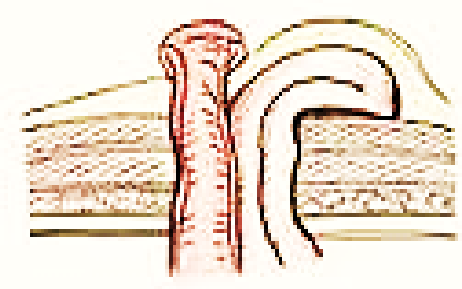
Parastomal Hernia

- The muscle defect created during a stoma formation, such as a colostomy or ileostomy, tends to increase in size over time and can ultimately lead to massive herniation around the stoma. The rate of parastomal hernia is over 50%.

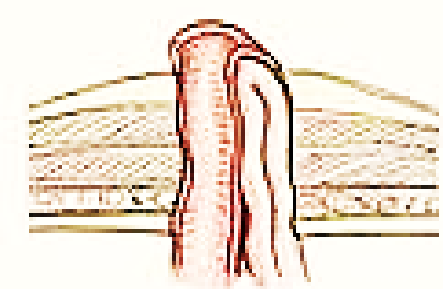




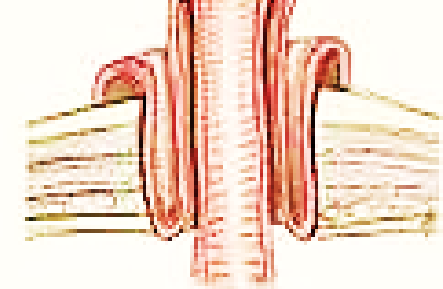
Interstitial hernia



Subcutaneous



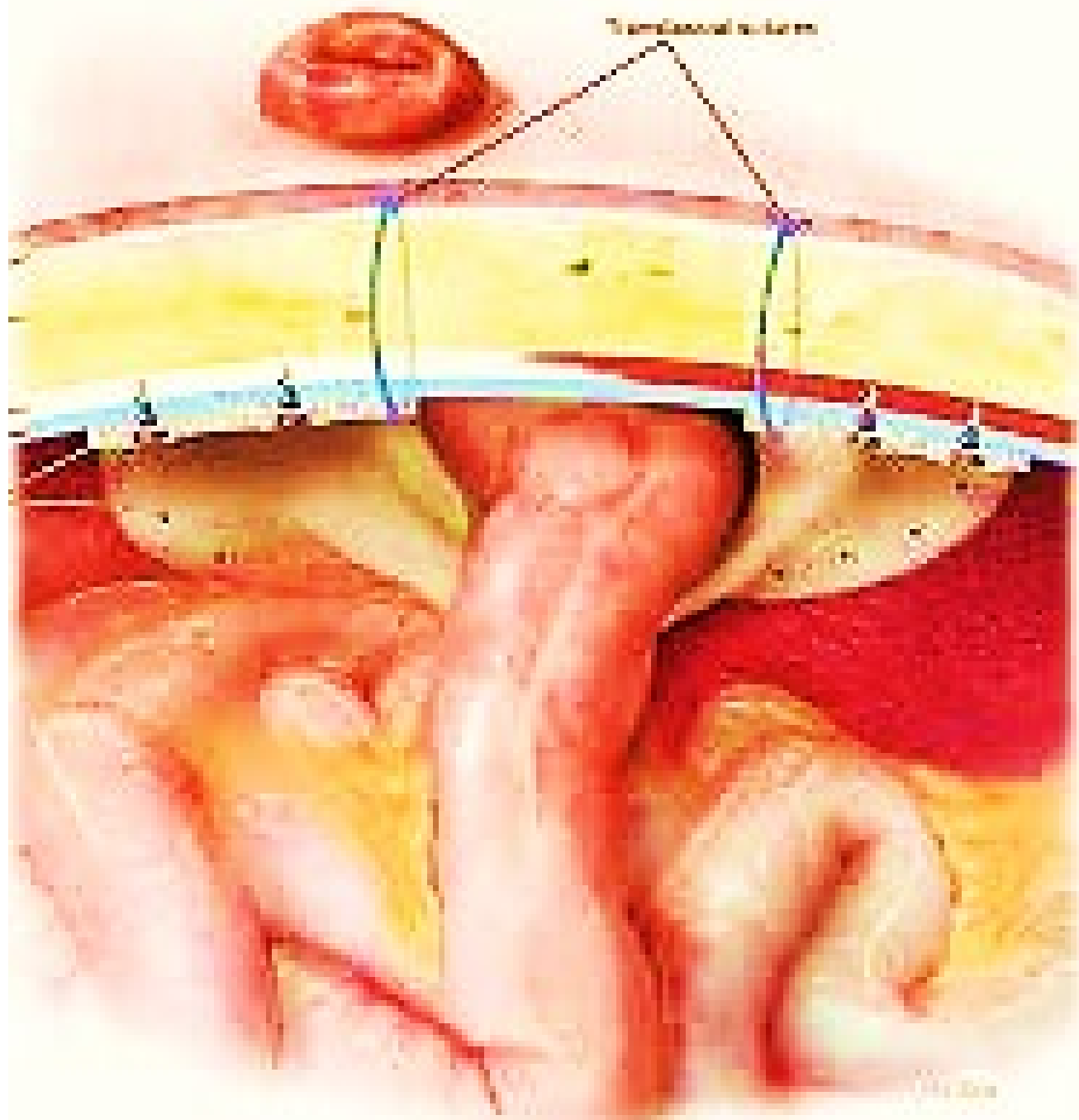
Intrastomal



stomal prolapse

Treatment

- Open suture and mesh techniques placed in the retromuscular space.
- Laparoscopic repair is also possible using a large mesh with a central hole. It can be positioned around the bowel onto the parietal peritoneum.
- A prophylactic lightweight, polypropylene mesh is inserted in the retromuscular space so that the bowel passes through a hole in the mesh center.



Traumatic hernia

These hernias arise through non-anatomical defects caused by injury:

- Stab wound sites.
- Hernias protruding through splits or tears in the abdominal muscles after blunt trauma.
- Abdominal bulging secondary to muscle atrophy that occurs as a result of nerve injury or other traumatic denervation (pseudo-hernia).
- Treatment (open / laparoscopic repair).

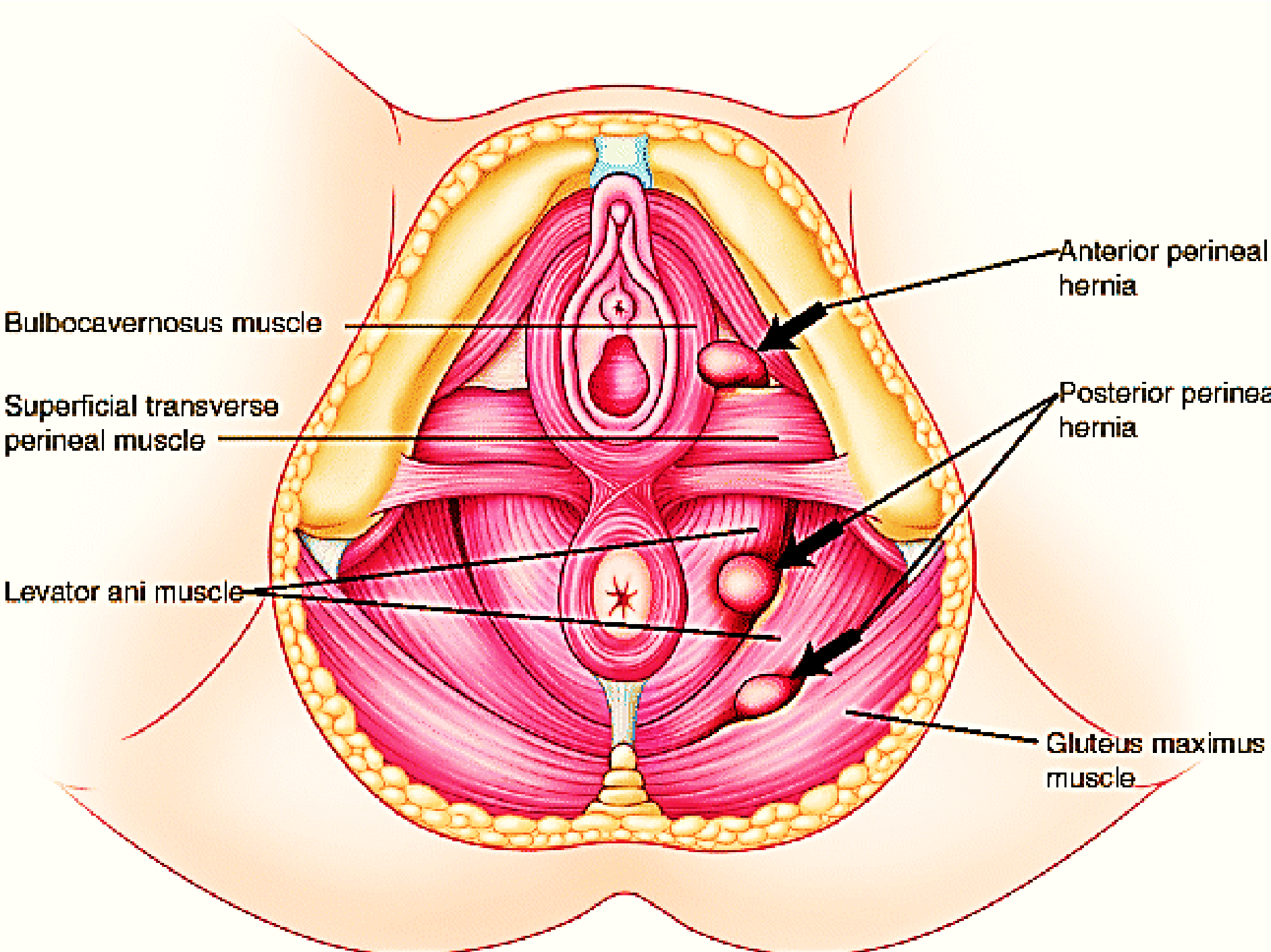
Rare external hernias

- Perineal hernia.
- Obturator hernia.
- Gluteal and sciatic hernias.

Perineal hernia

This type of hernia is very rare and includes:

- Postoperative hernia through a perineal scar, which may occur after excision of the rectum;
- Median sliding perineal hernia, which is a complete prolapse of the rectum;
- Anterolateral perineal hernia, which occurs in women and presents as a swelling of the labium majus.
- Posterolateral perineal hernia, which passes through the levator ani to enter the ischiorectal fossa.



Bulbocavernosus muscle

Superficial transverse perineal muscle

Levator ani muscle

Anterior perineal hernia

Posterior perineal hernia

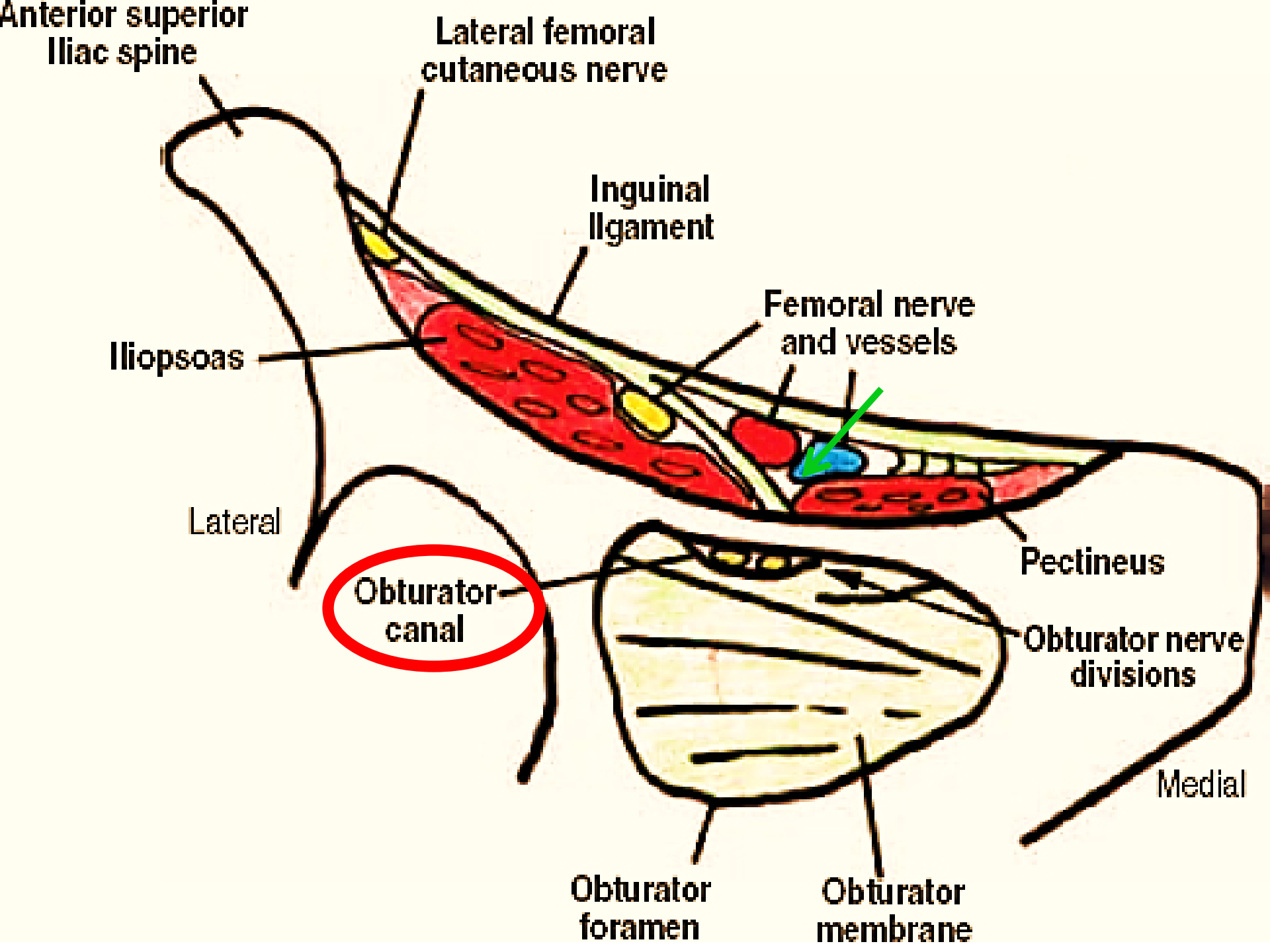
Gluteus maximus muscle

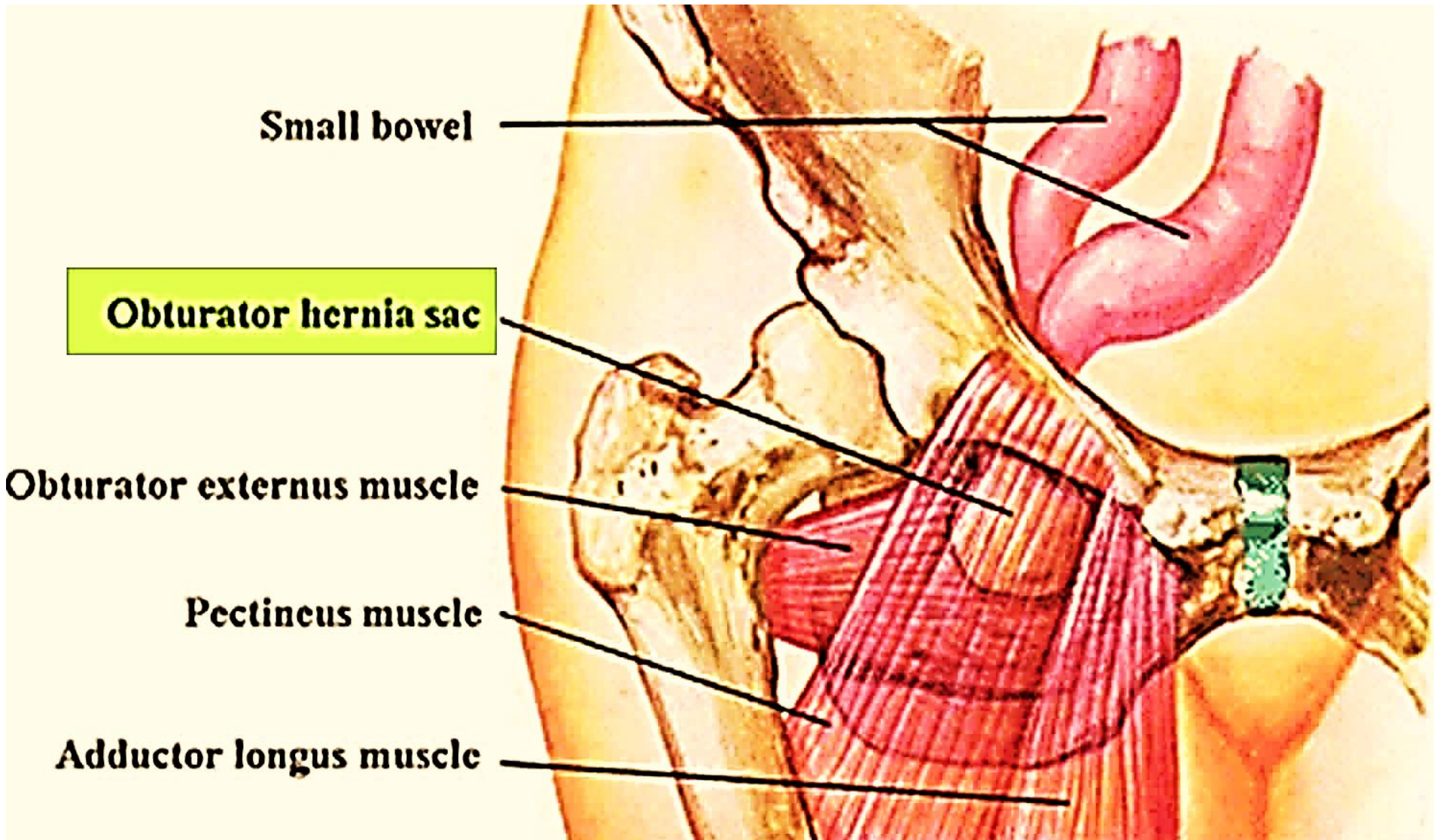
TREATMENT

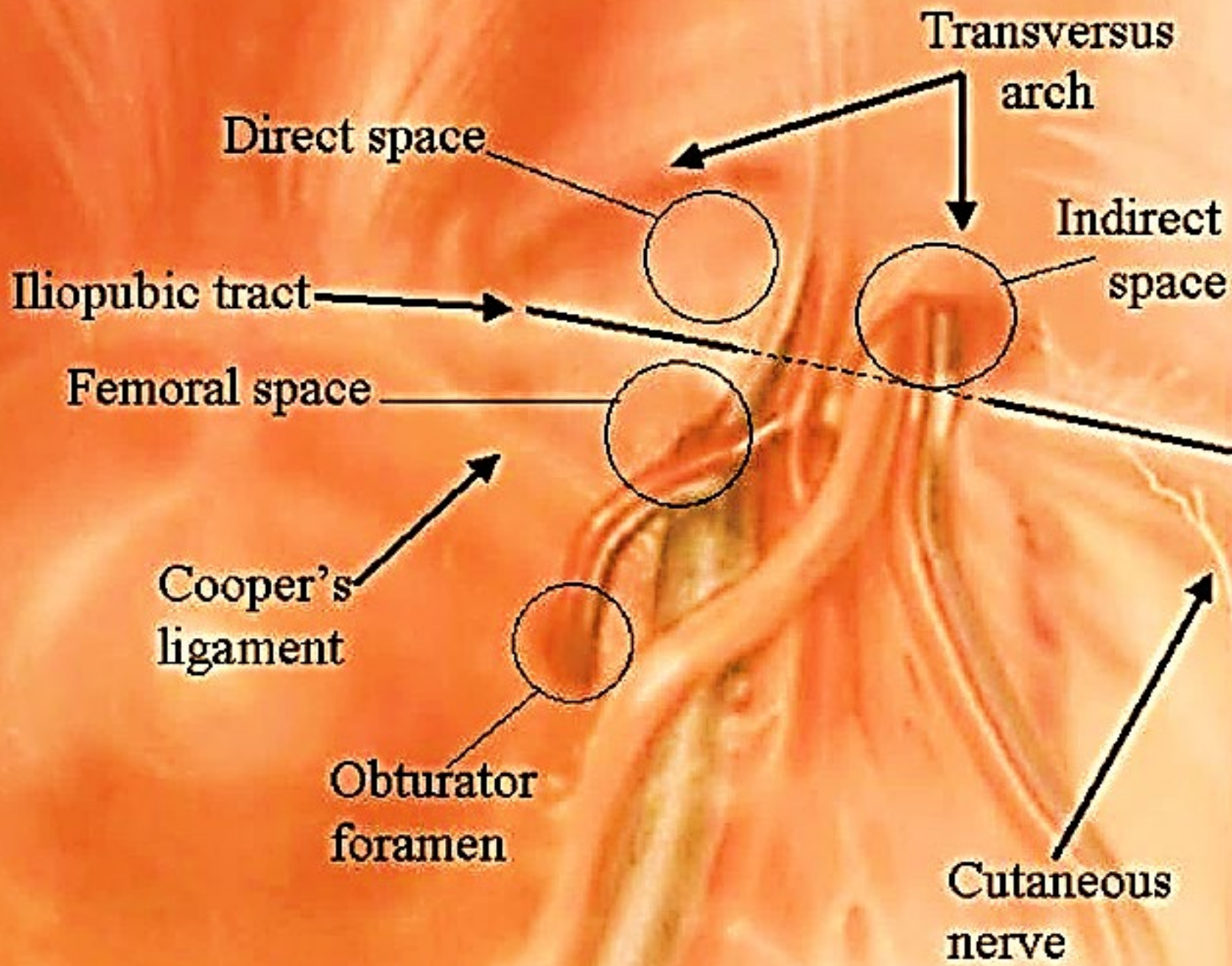
- A combined abdominoperineal operation is generally the most satisfactory for the last two types of hernia.
- Either laparoscopically or at open surgery,
- Pelvic floor repaired.
- Prosthetic mesh.

Obturator hernia

- Passes through the obturator canal .
- Most patients are aged >60 years and occurs six times more frequently in women than in men.
- The leg is usually kept in a semiflexed position and movement increases the pain.
- More than 50% of cases of strangulated obturator hernia, pain is referred along the obturator nerve by its geniculate branch to the knee.
- The swelling is liable to be overlooked because it is covered by pectineus.
- On vaginal or rectal examination the hernia can sometimes be felt as a tender swelling in the region of the obturator foramen.
- These hernias have often undergone strangulation, frequently of the Richter type, by the time of presentation.
- Open repair with mesh.
- Laparoscopic TAPP repair may also be performed again using a mesh.







Gluteal and Sciatic hernias

- Both of these hernias are very rare. A gluteal hernia passes through the greater sciatic foramen, either above or below piriformis.
- A sciatic hernia passes through the lesser sciatic foramen.
- Diagnosed by CT scan but, if in doubt, they should be explored by operation.

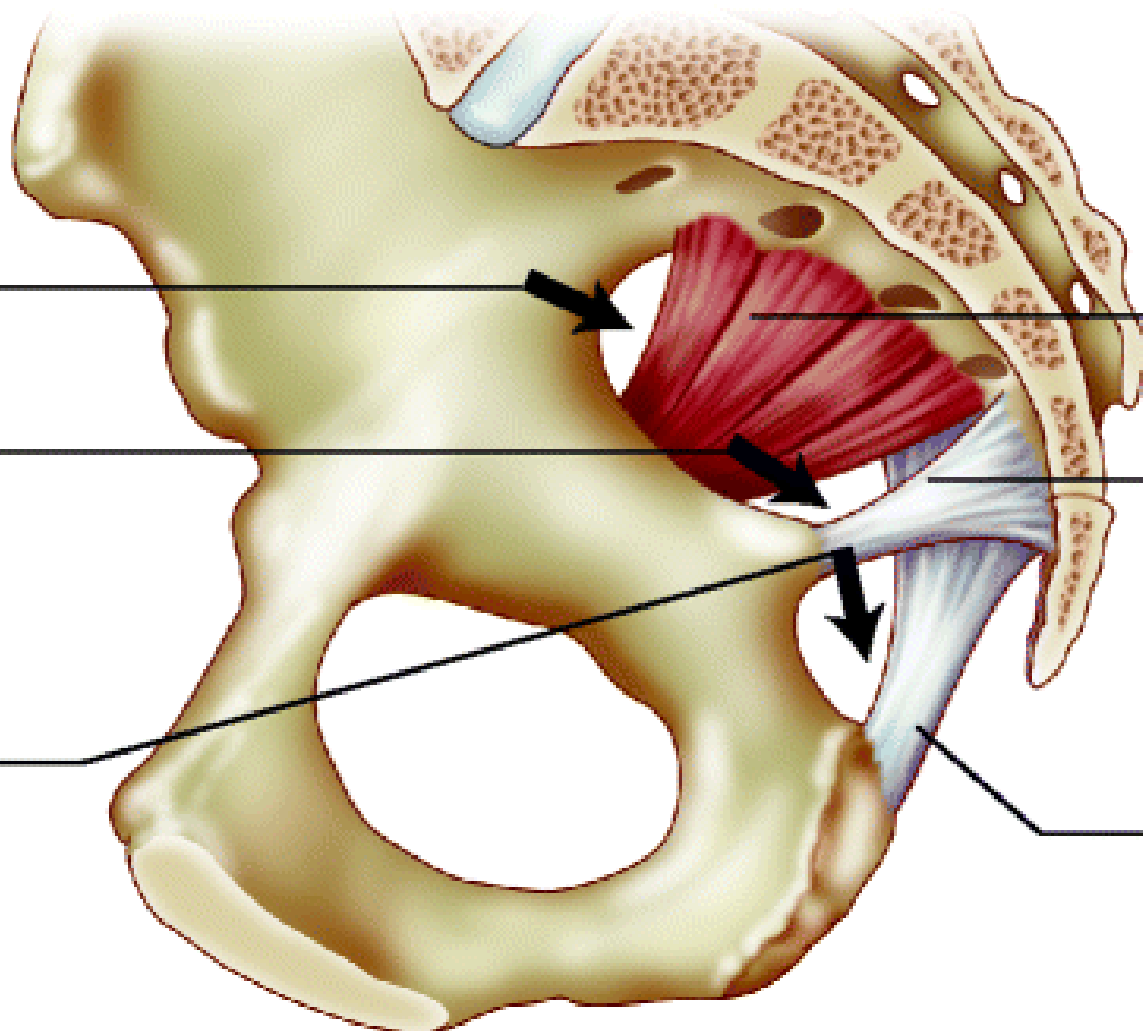
Differential diagnosis must be made between these conditions :

- Lipoma or other soft tissue tumour beneath gluteus maximus.
- Tuberculous abscess;
- Gluteal aneurysm.

Suprapiriformis
hernia site

Infrapiriformis
hernia site

Subspinous
hernia site



Piriformis muscle

Sacrospinous
ligament

Sacrotuberous
ligament

نعم بتوفيق الله