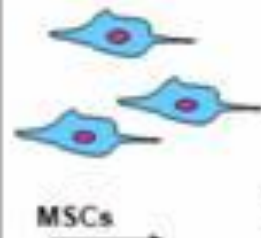
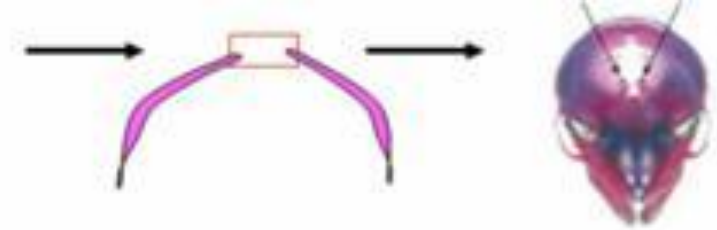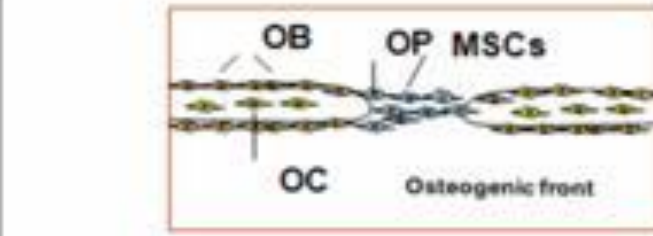




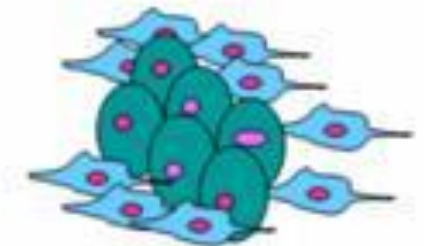
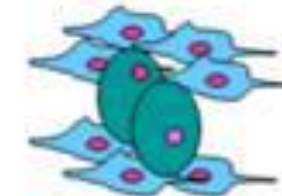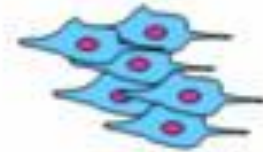
Medical Biology

Osteogenesis

Intramembranous
Ossification

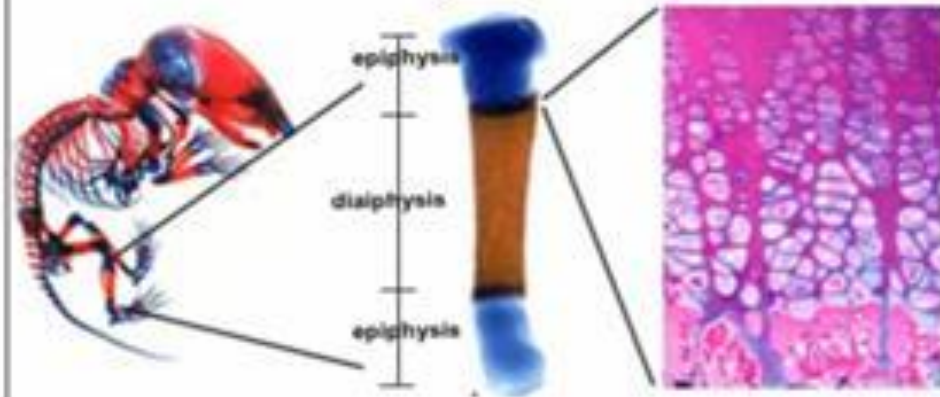


Chondensing Mesenchym



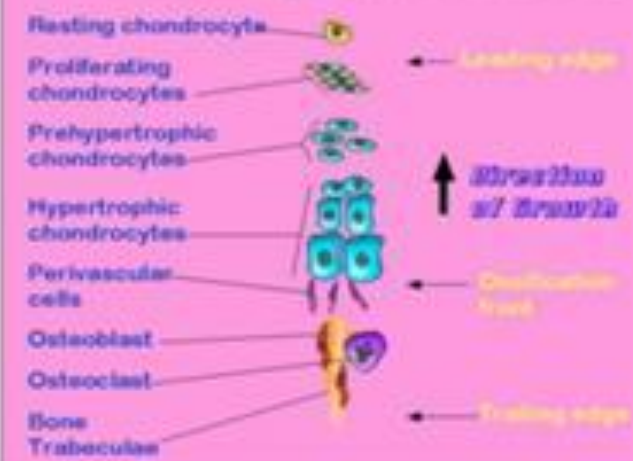Endochondral
Ossification

Lonituial Growth

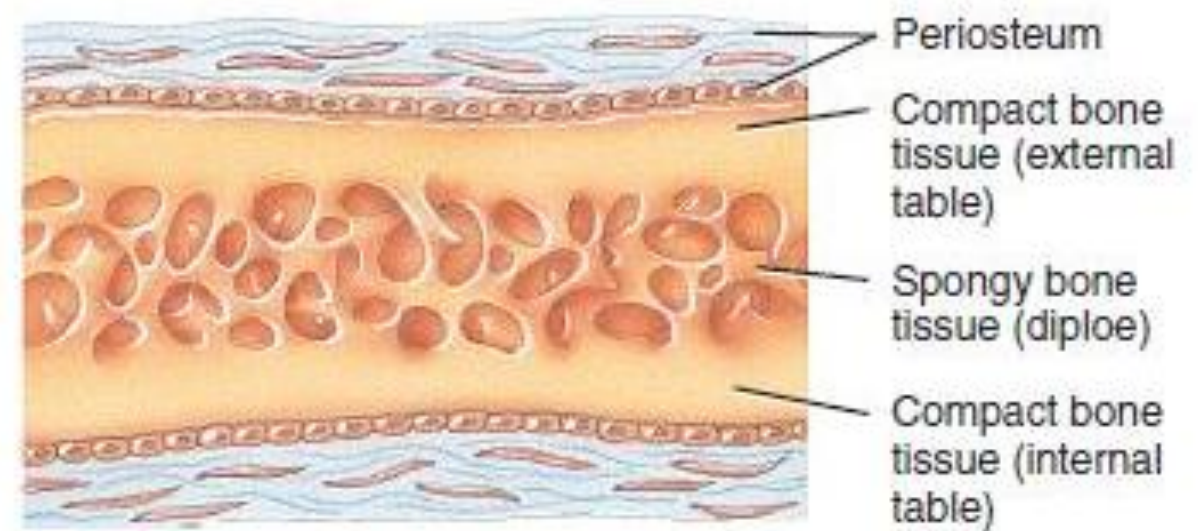
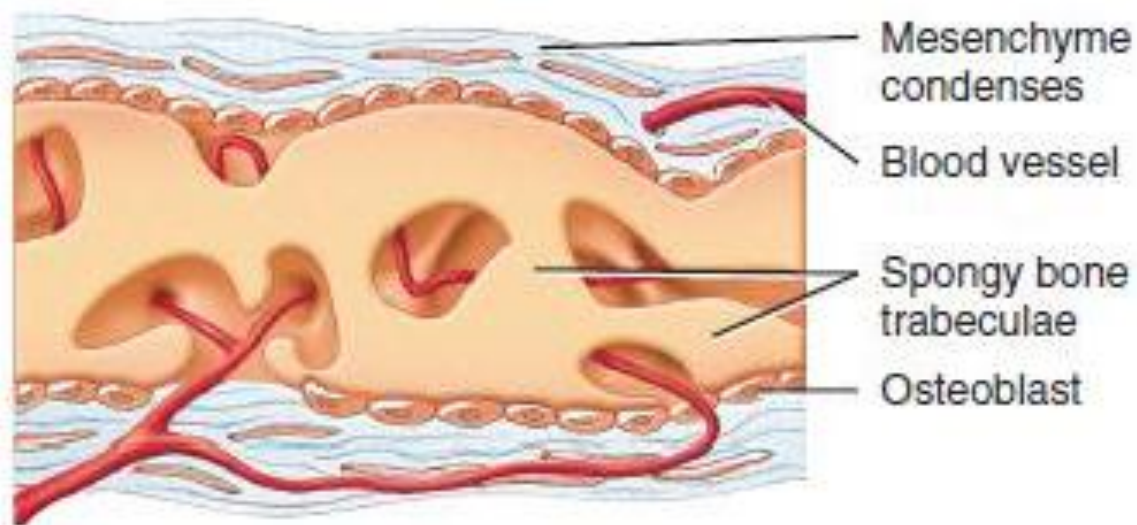
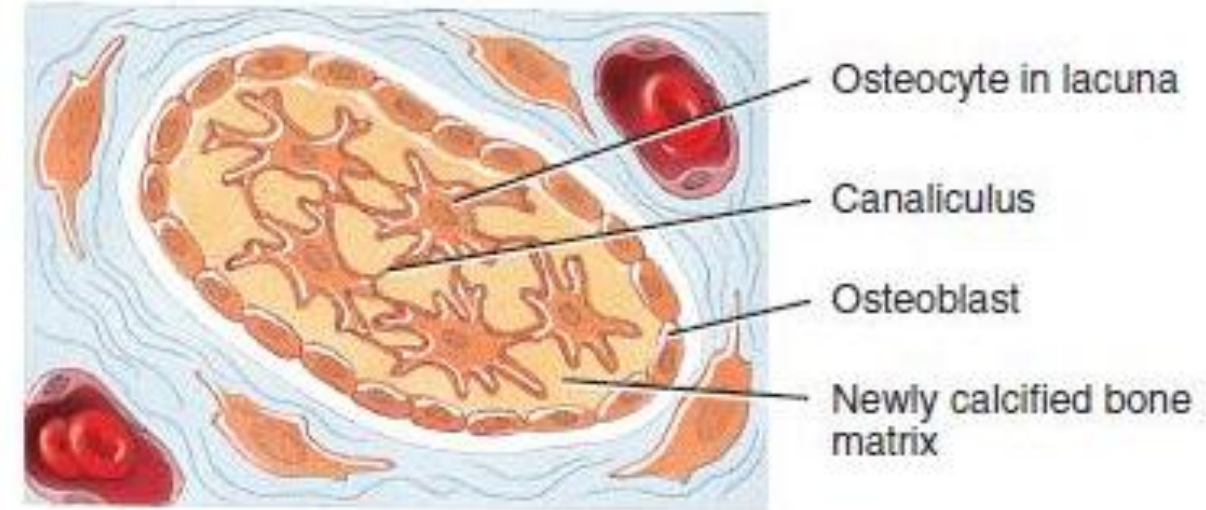
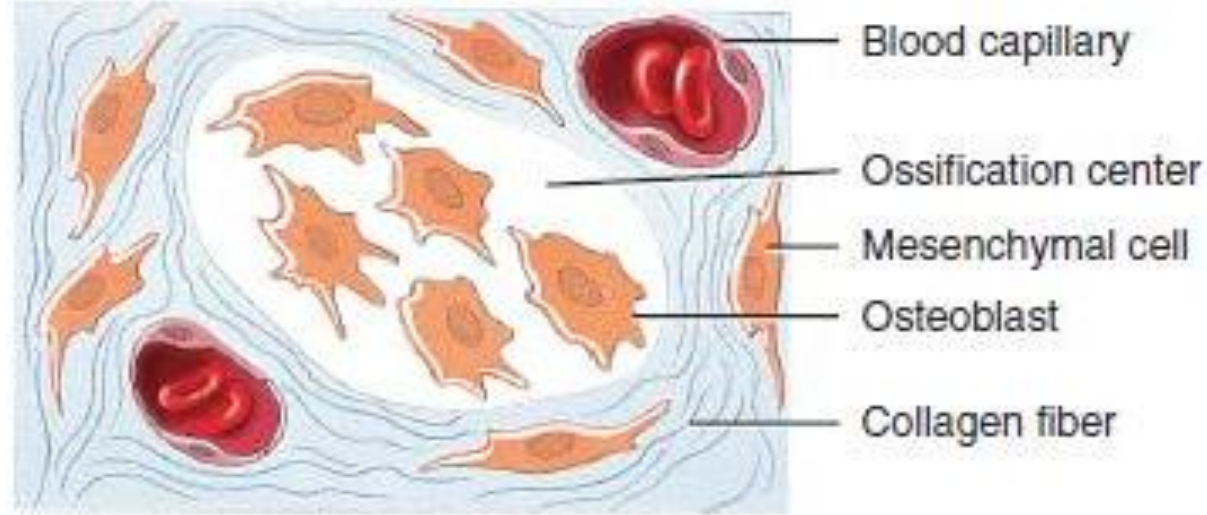


Growth Plate

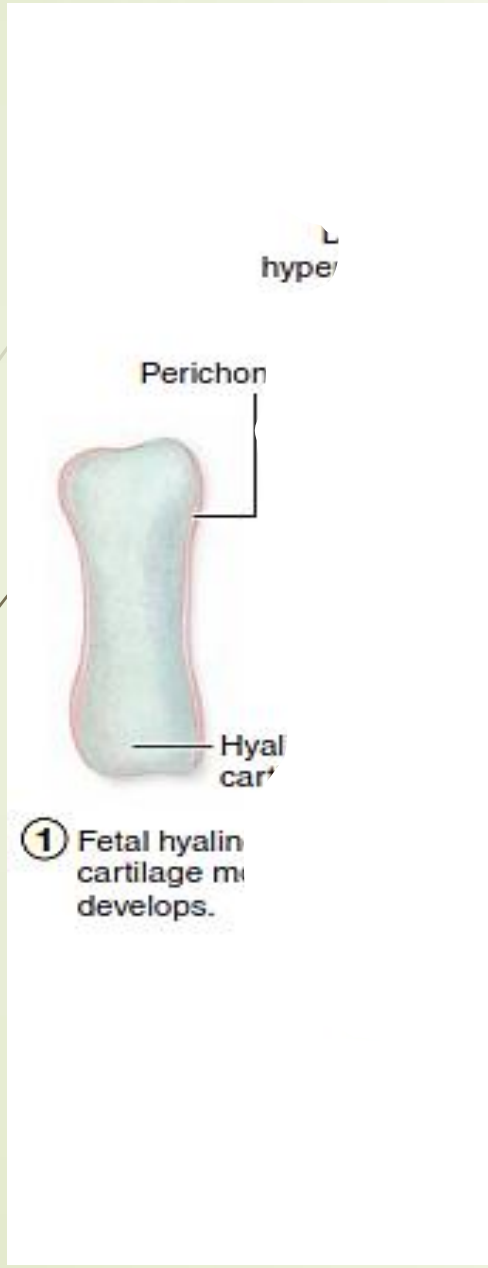ANATOMY OF GROWTH PLATE

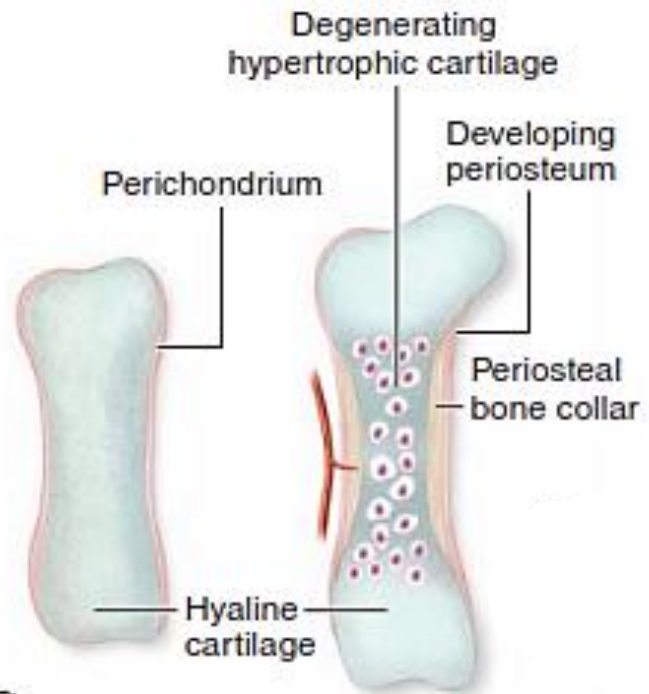


Intramembranous Ossification

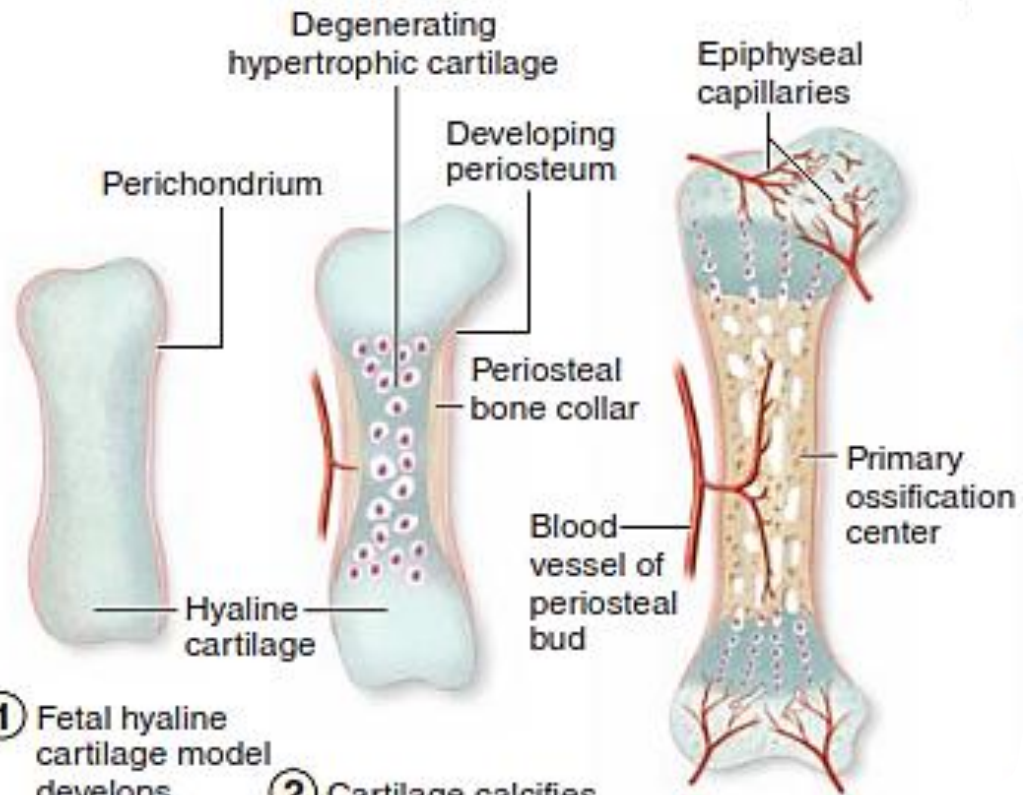


Endochondral ossification



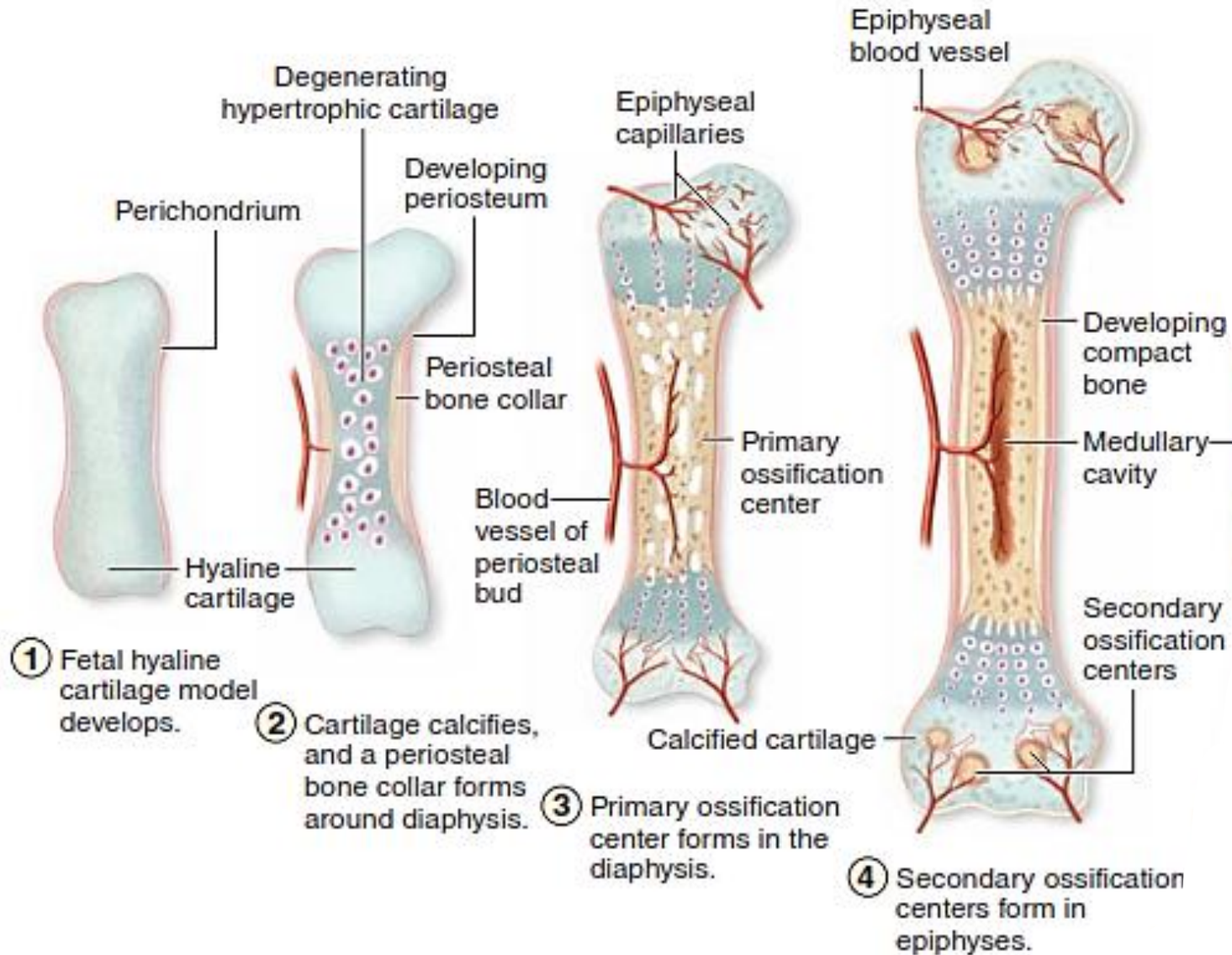


- ① Fetal hyaline cartilage model develops.
- ② Cartilage calcifies, and a periosteal bone collar forms around diaphysis.

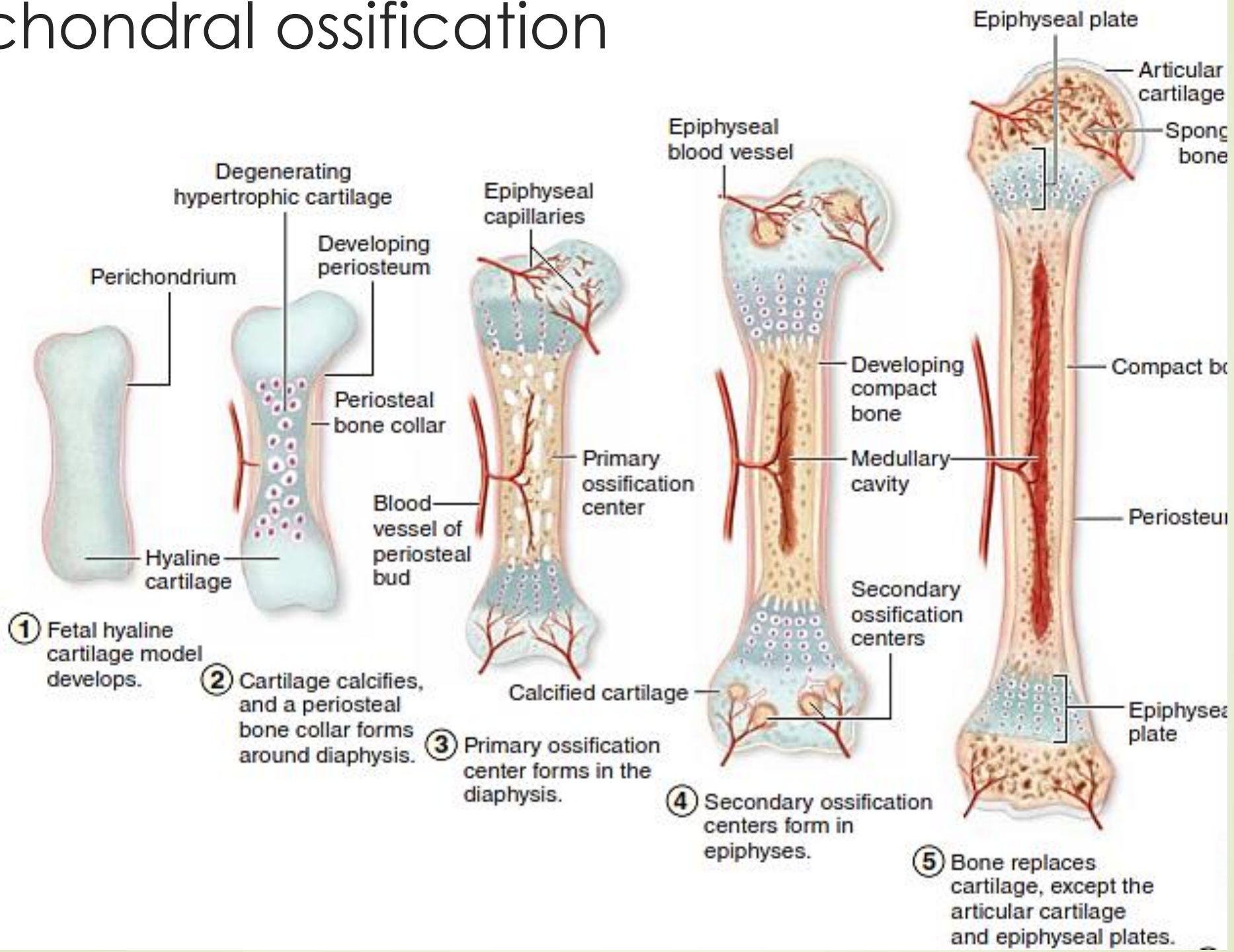


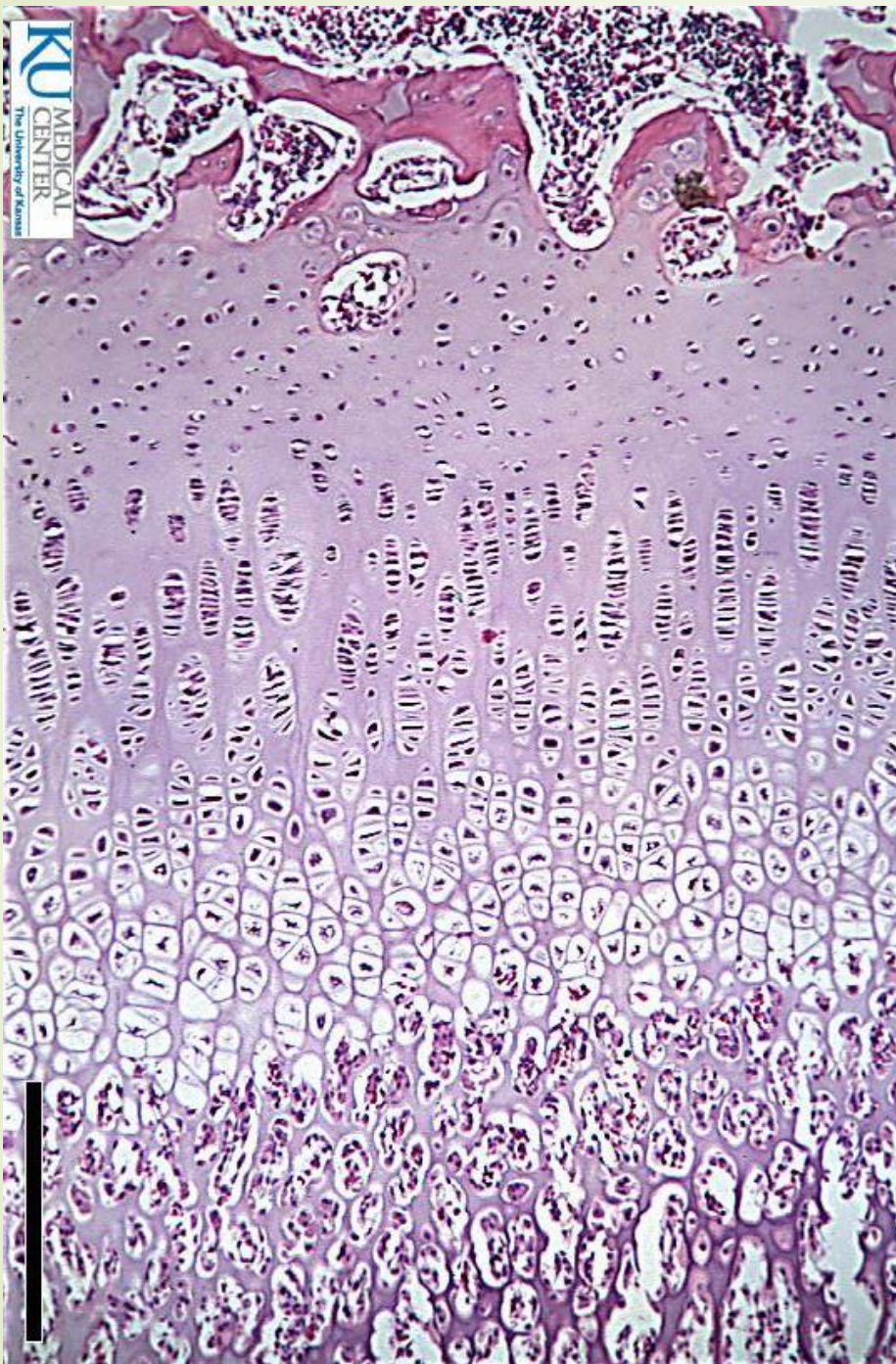
- ① Fetal hyaline cartilage model develops.
- ② Cartilage calcifies, and a periosteal bone collar forms around diaphysis.
- ③ Primary ossification center forms in the diaphysis.

Endochondral ossification

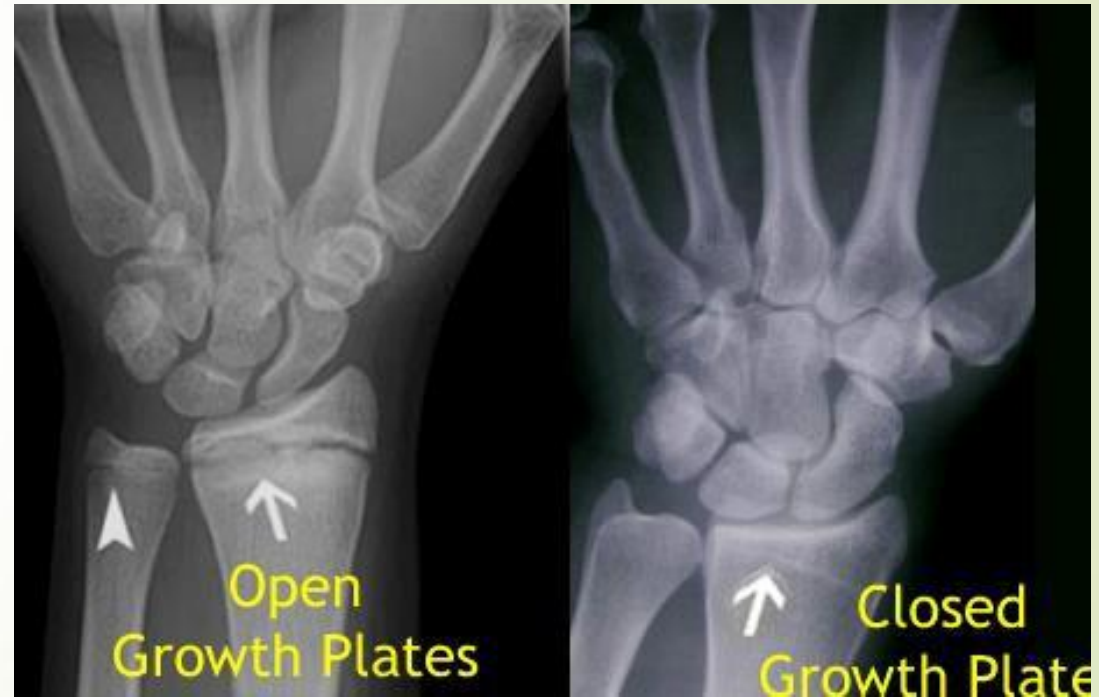

Endochondral ossification

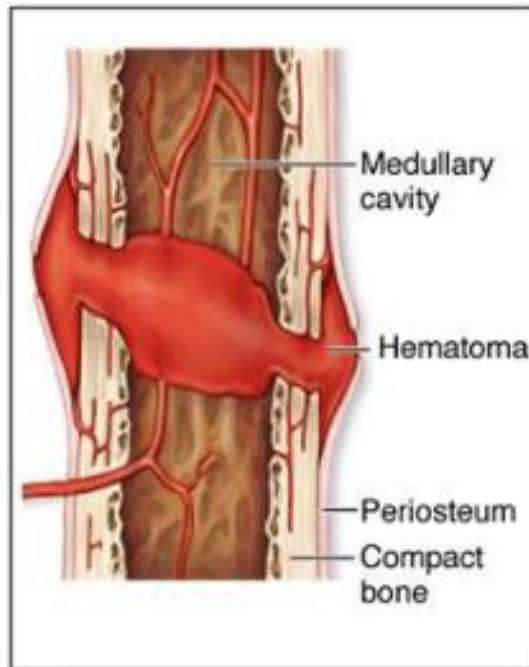
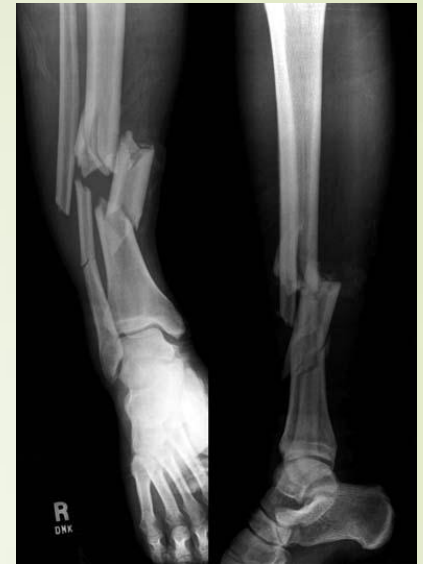



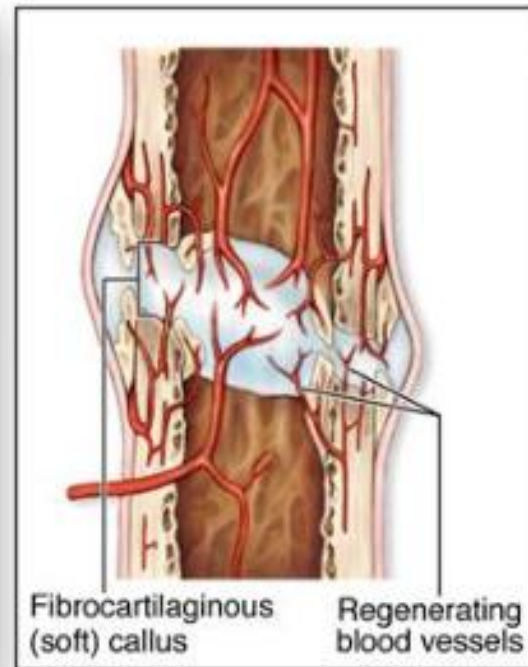
EPIPHYSEAL CARTILAGE (GROWTH PLATE)



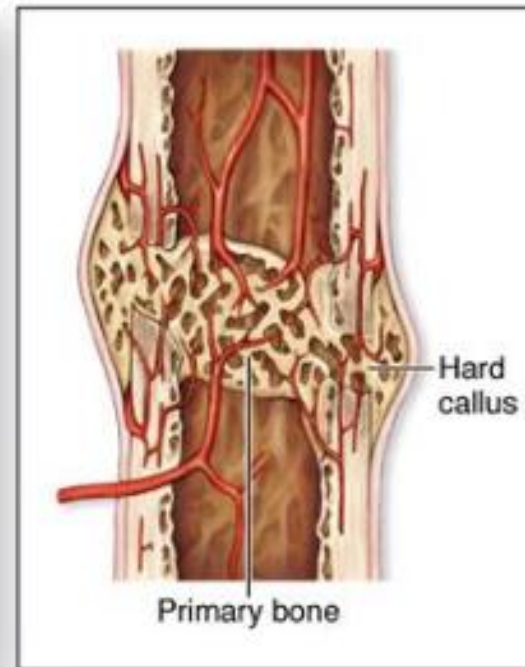
Fracture Repair



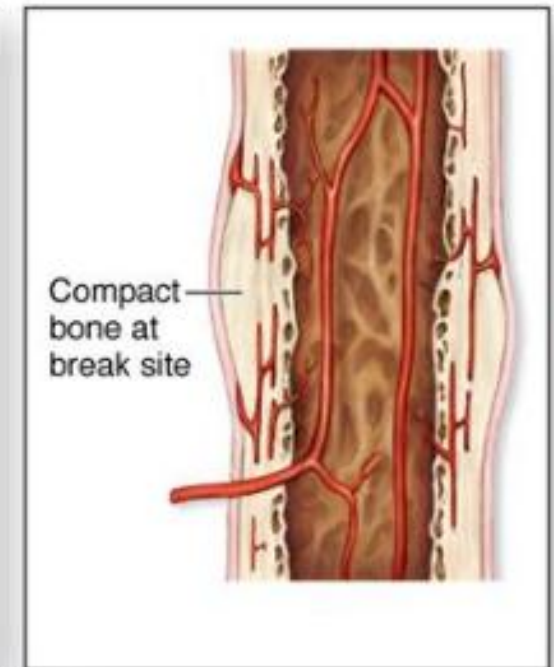
① A fracture hematoma forms.



② A fibrocartilaginous (soft) callus forms.



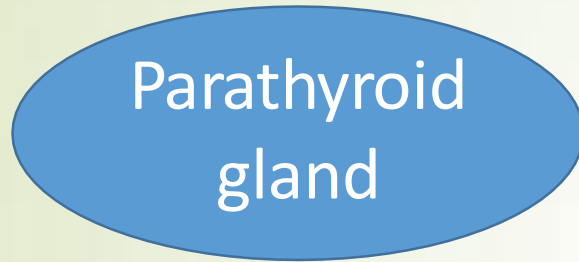③ A hard (bony) callus forms.



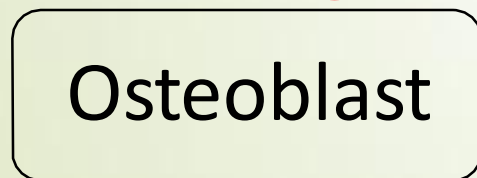

④ The bone is remodeled.

METABOLIC ROLE OF BONE

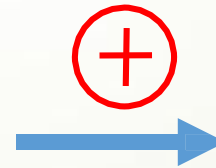
↓ Blood Ca level



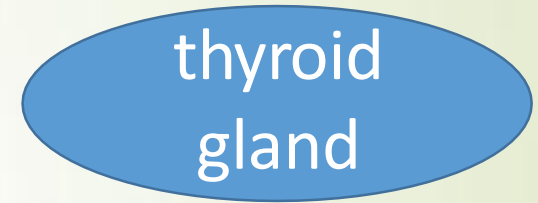
PTH



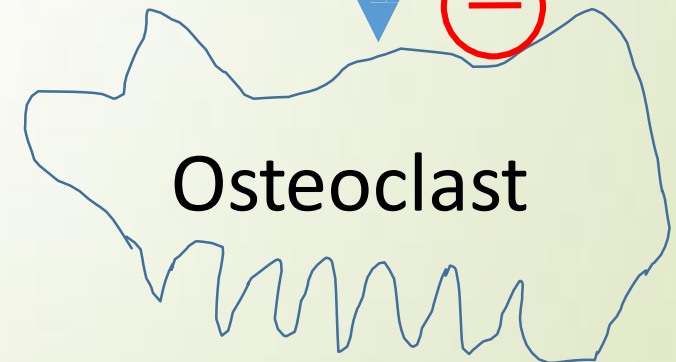M-CSF, RANKL



↑ Blood Ca level

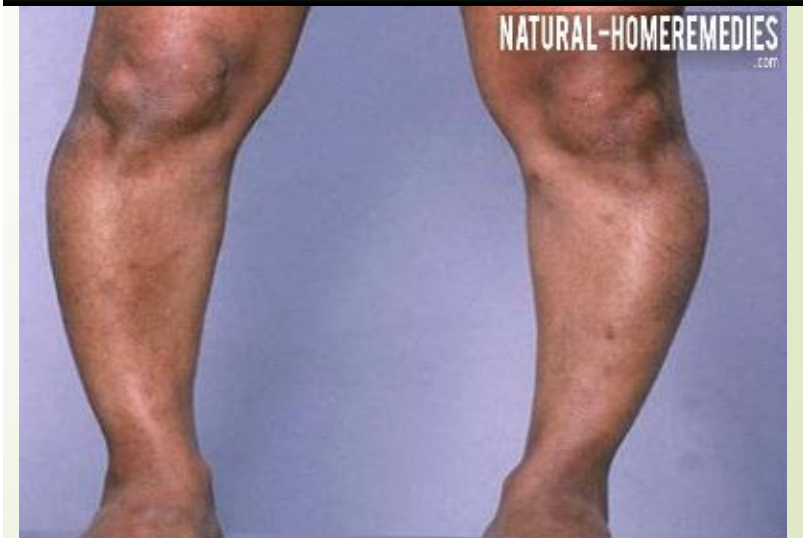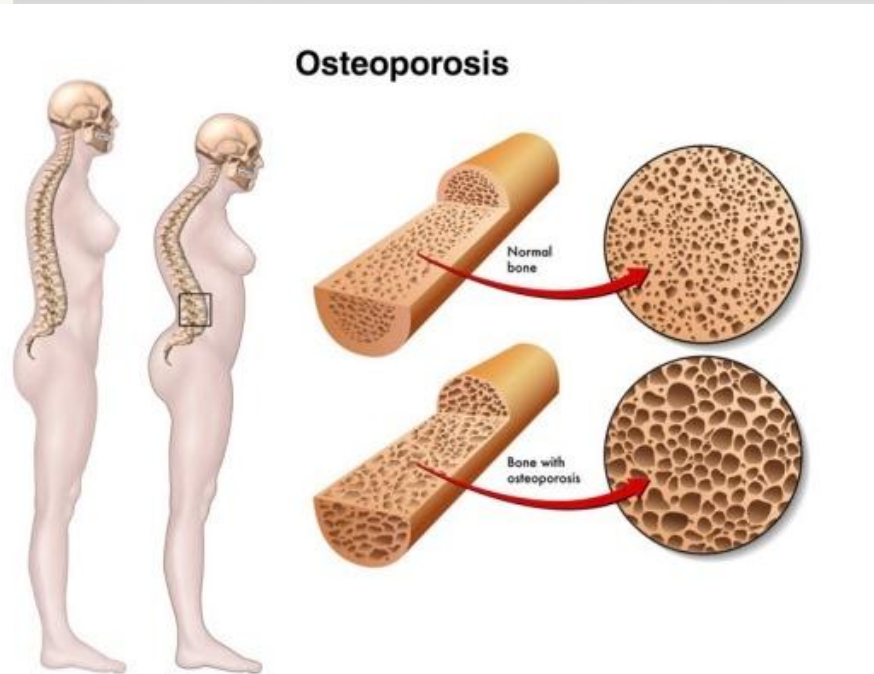
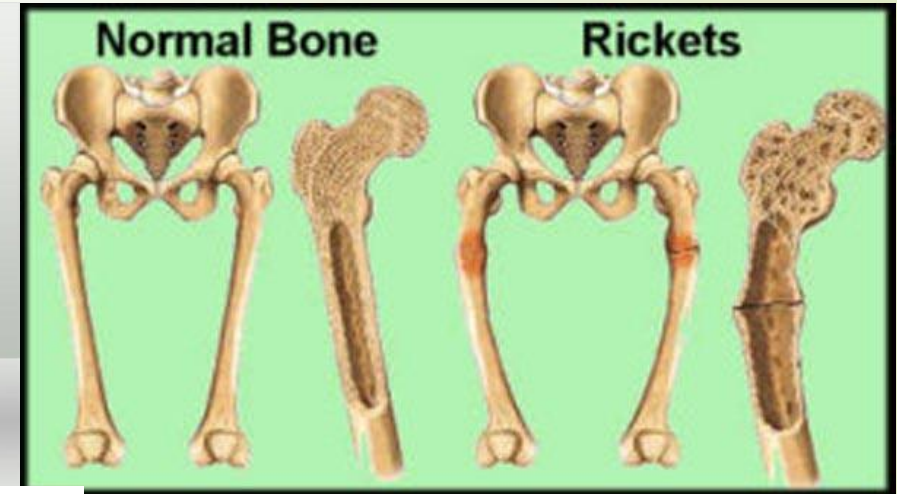

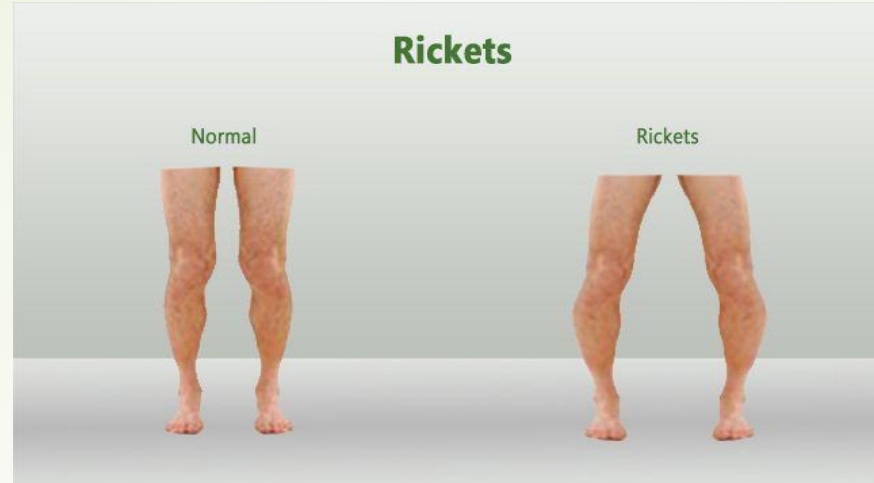
Calcitonin



Clinical notes: Nutritional Deficiencies and Bone Remodeling

- Rickets
- Osteomalacia
- osteoporosis



Osteomalacia is softening of bones caused due to the deficiency of vitamin D

THANK YOU