

NASAL CAVITY & PARANASAL SINUSES

Dr Maan Al-Abbasi
PhD, MBChB, MD



11/2/2022

Dr Maan AlAbbasi PhD MBChB MD

1

ملاحظة مهمة!

ننصح ان تكون قراءة الموضوع بتفصيله وللاستزادة
من المعلومات من الكتاب المنهجي

**We advice our students to read this lecture
note in your recommended textbook**

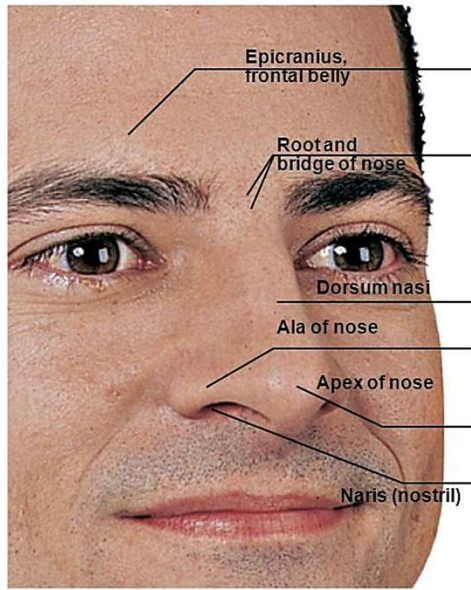
References that you can depends on:

- Gray's Anatomy for Students. By: Richard Drake, A. Wayne Vogl, Adam Mitchell
- Snell's Clinical Anatomy by Regions. By Dr. Lawrence E. Wineski PhD

We are going to discuss:

1. Regions of nasal cavity
2. External nose, nares & choanae
3. Features of lateral & medial walls of nose
4. Gateways of nasal cavity
5. Blood supply & innervation of nose
6. Paranasal sinuses - anatomical features & relations

Figure 22.2a The external nose.



- The Nose - Two regions:
external nose & nasal cavity

- External nose-root, bridge, dorsum nasi, and apex
 - **Philtrum**-shallow vertical groove inferior to apex
 - **Nostrils (nares)**-bounded laterally by *alae*

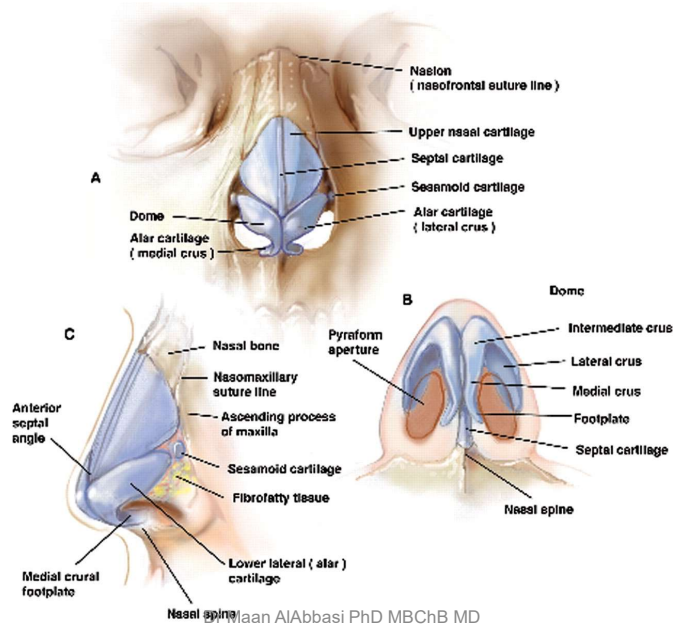
(a) Surface anatomy

11/2/2022

Dr Maan AlAbbasi PhD MBChB MD

4

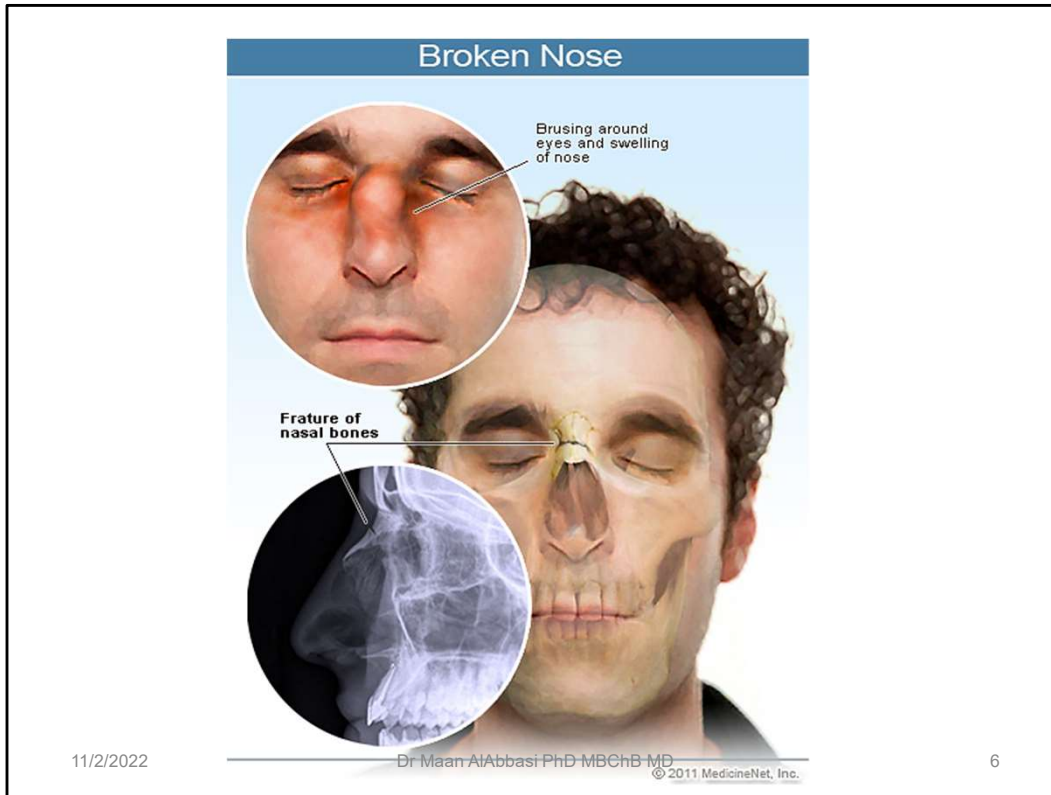
The Nose - Exterior



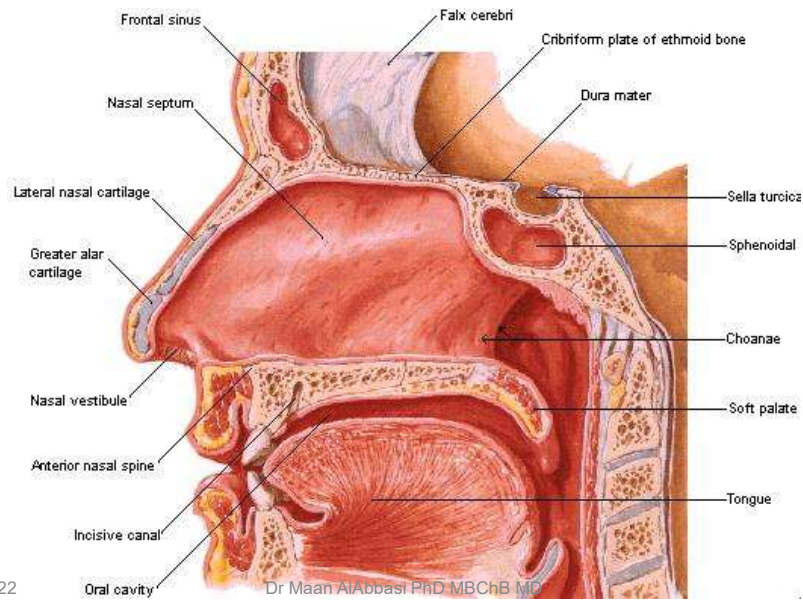
11/2/2022

Maan AlAbbasi PhD MBChB MD

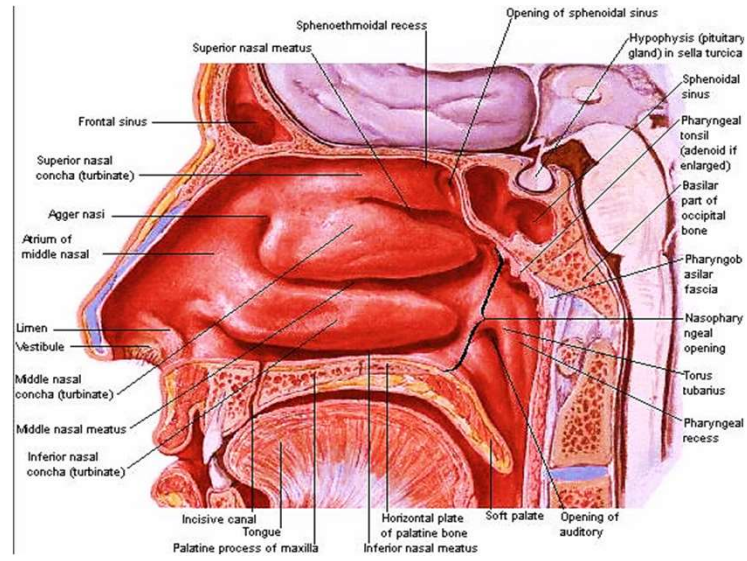
5



Nose - Boundaries



Nasal Cavity

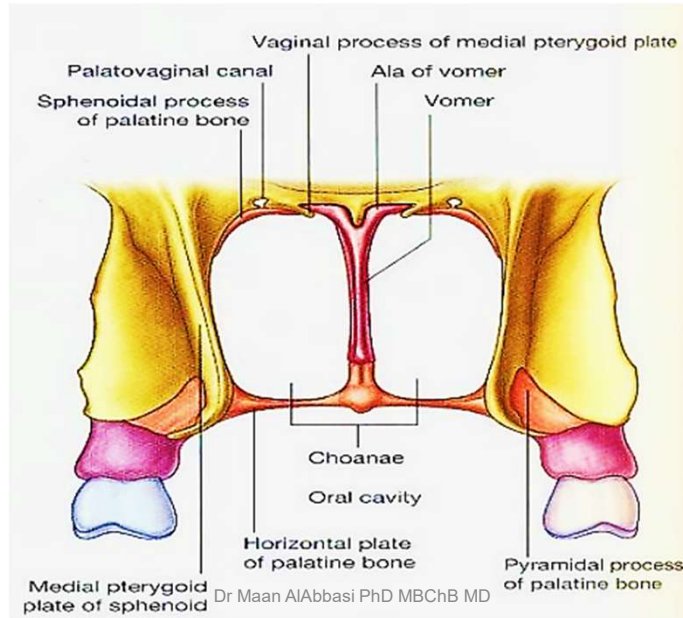


11/2/2022

Dr Maan AlAbbasi PhD MBChB MD

8

Choanae (posterior view)

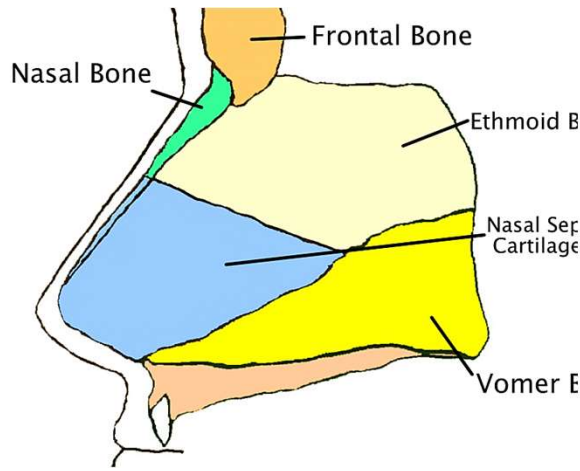


11/2/2022

Dr Maan AlAbbasi PhD MBChB MD

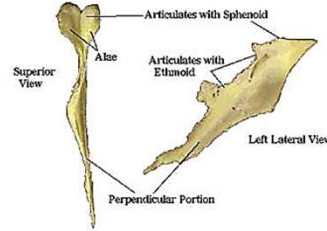
9

Nasal Septum

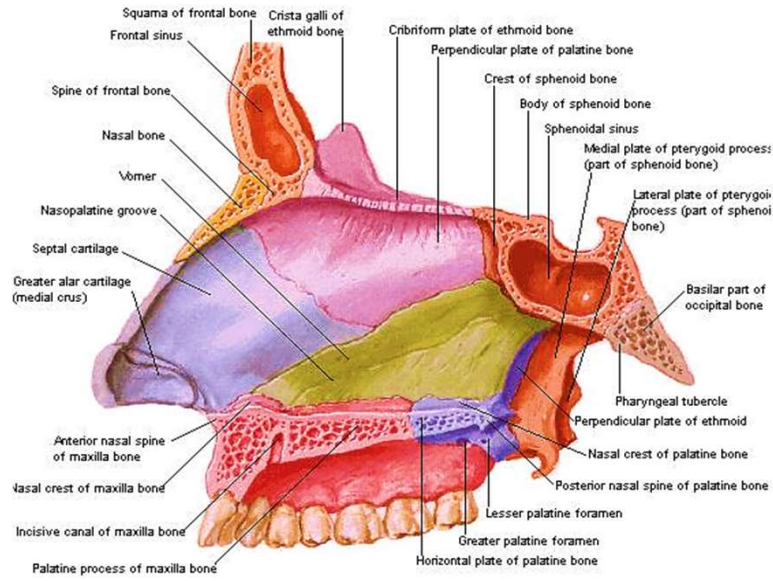


Vomer

- Forms inferior (bottom) portion of nasal septum
- Articulates with maxillae and palatine bones



Medial wall of the Nose

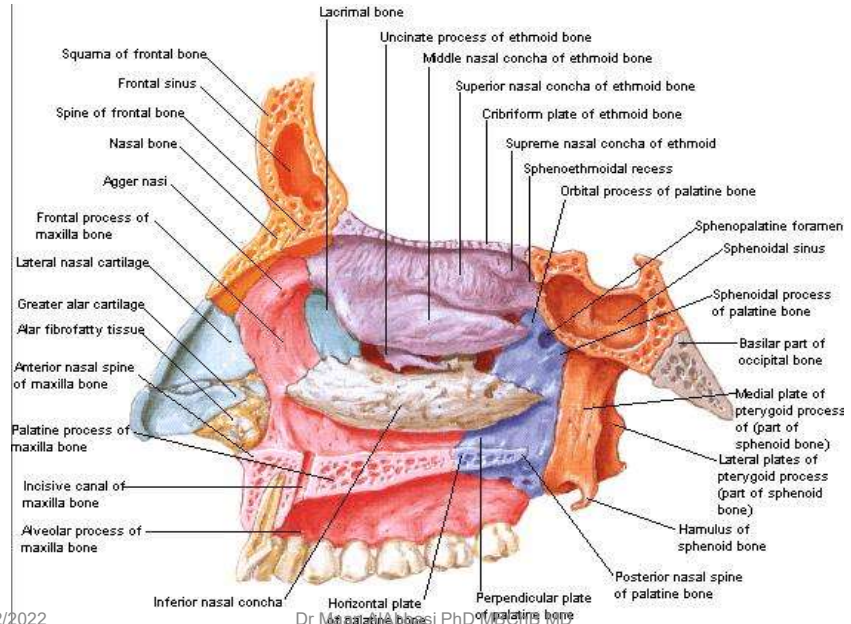


11/2/2022

Dr Maan AlAbbasi PhD MBChB MD

11

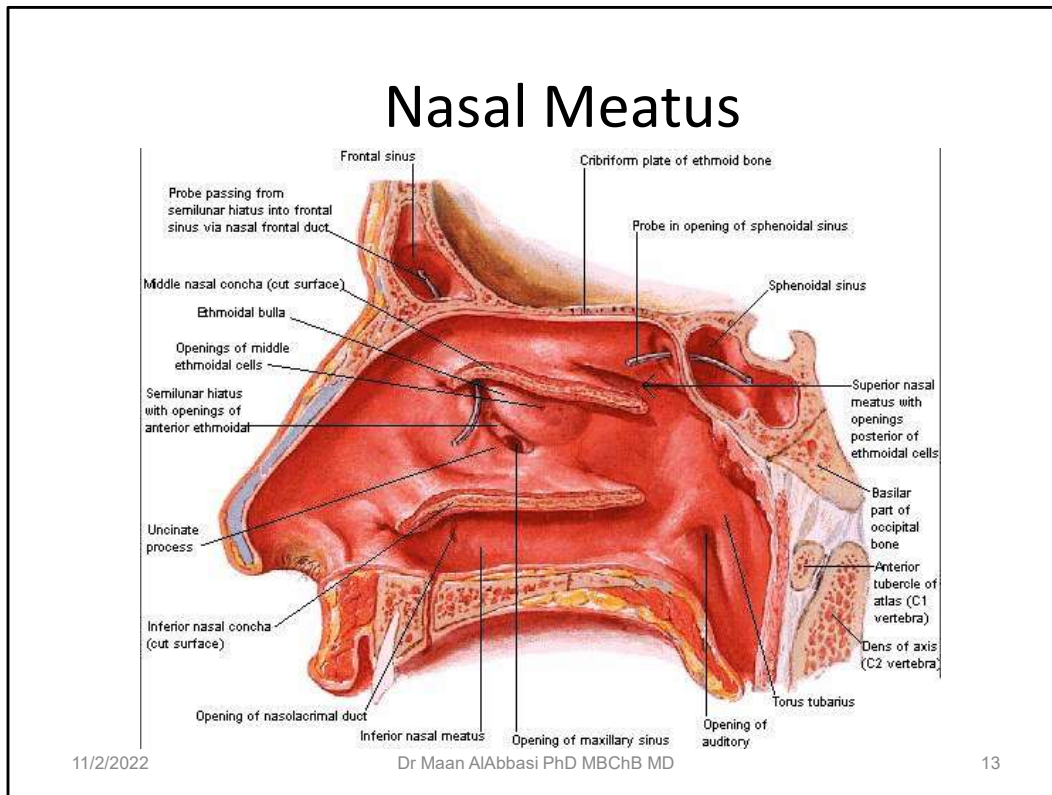
Lateral Wall of the Nose



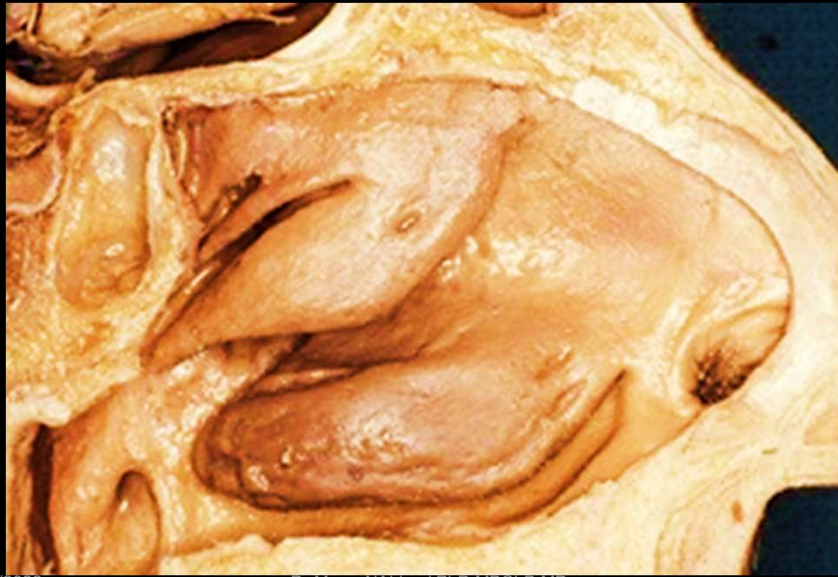11/2/2022

Dr Maan Abbasi PhD MBChB MD

12



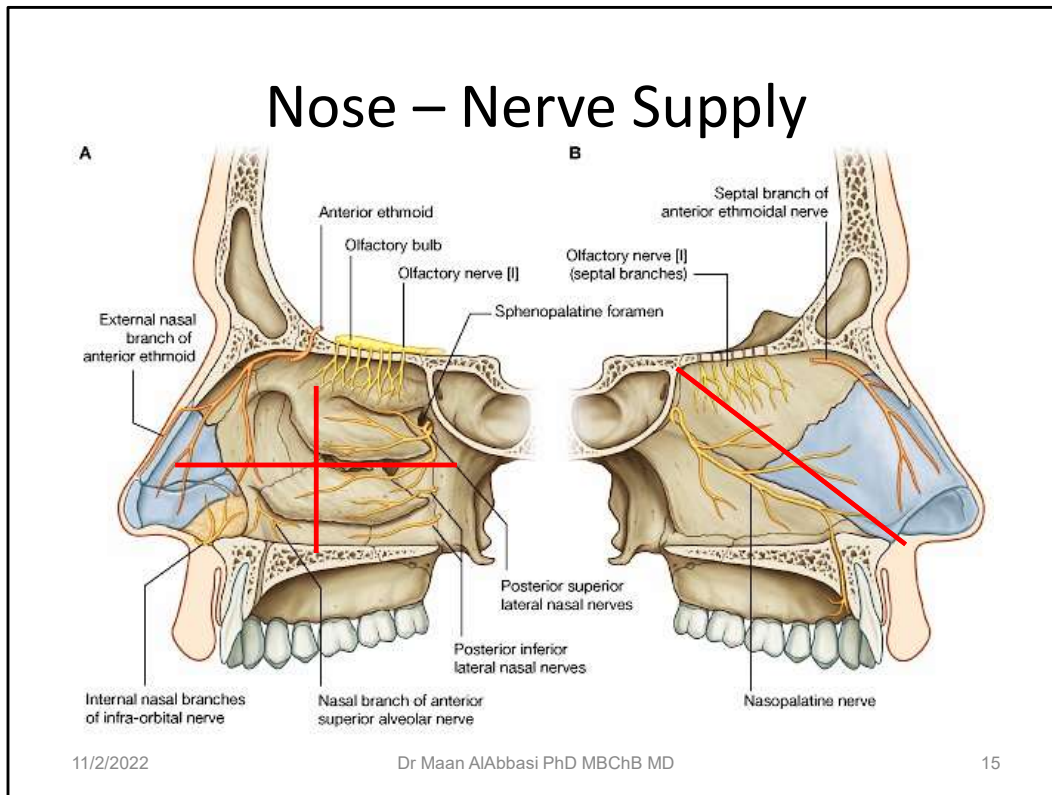
Nasal Meatus



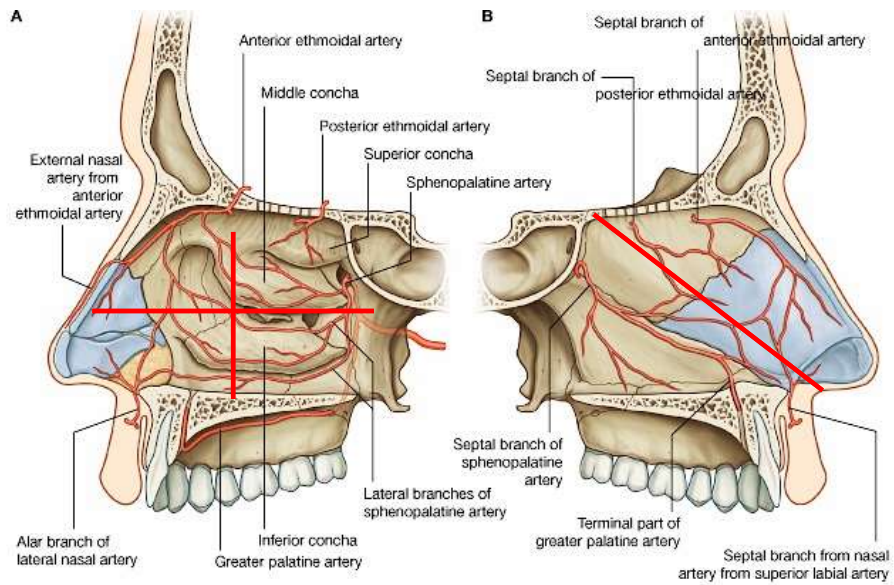
11/2/2022

Dr Maan AlAbbasi PhD MBChB MD

14



Nose – Blood Supply

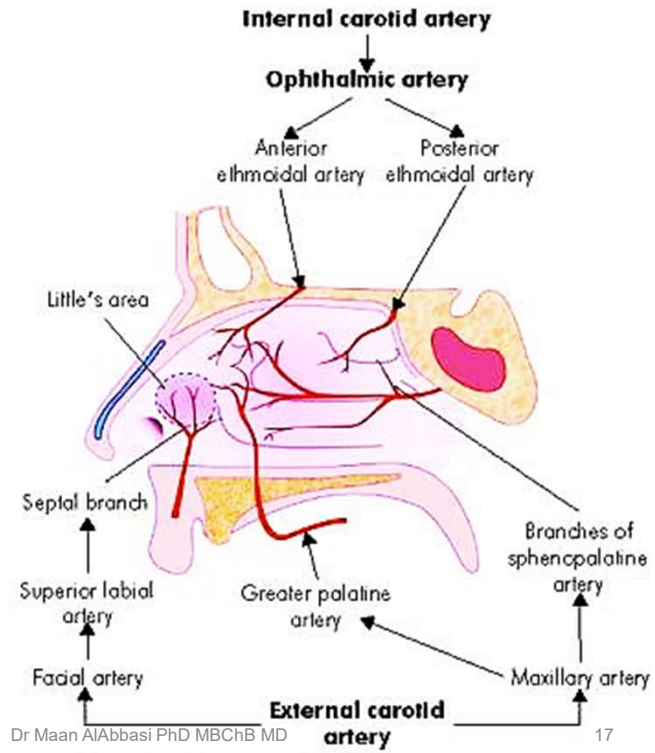


11/2/2022

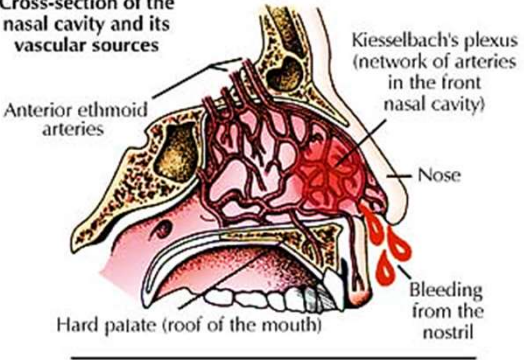
Dr Maan AlAbbasi PhD MBChB MD

16

Blood Supply of Nasal Septum



Cross-section of the nasal cavity and its vascular sources



Anterior ethmoid arteries

Kiesselbach's plexus (network of arteries in the front nasal cavity)

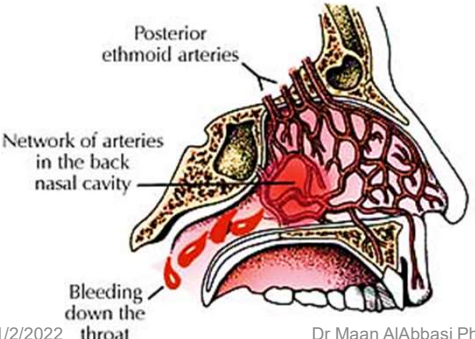
Nose

Hard palate (roof of the mouth)

Bleeding from the nostril

Kesselbach's Plexus/Little's Area:

- Superior Labial A (Facial)
- Anterior Ethmoid (Oph)
- Greater Palatine (Max)
- Sphenopalatine A (Max)



Posterior ethmoid arteries

Network of arteries in the back nasal cavity

Bleeding down the throat

Woodruff's Plexus:

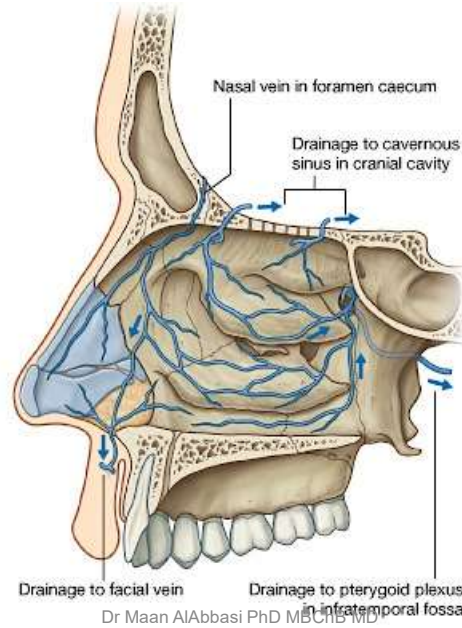
- Pharyngeal & Post. Nasal AA of Sphenopalatine A (Max)

11/2/2022

Dr Maan AlAbbasi PhD MBChB MD

18

Nose – Venous Drainage

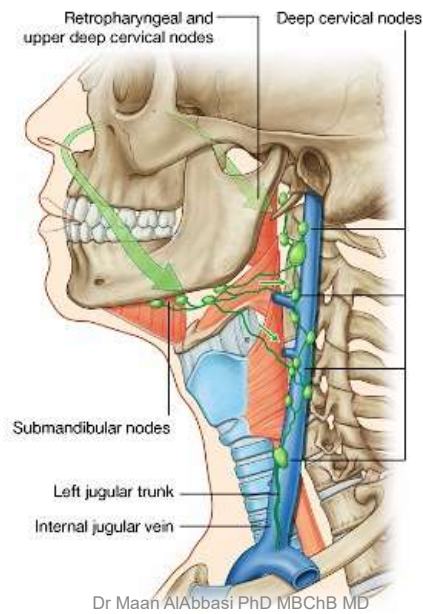


11/2/2022

Dr Maan AlAbbasi PhD MBChB MD

19

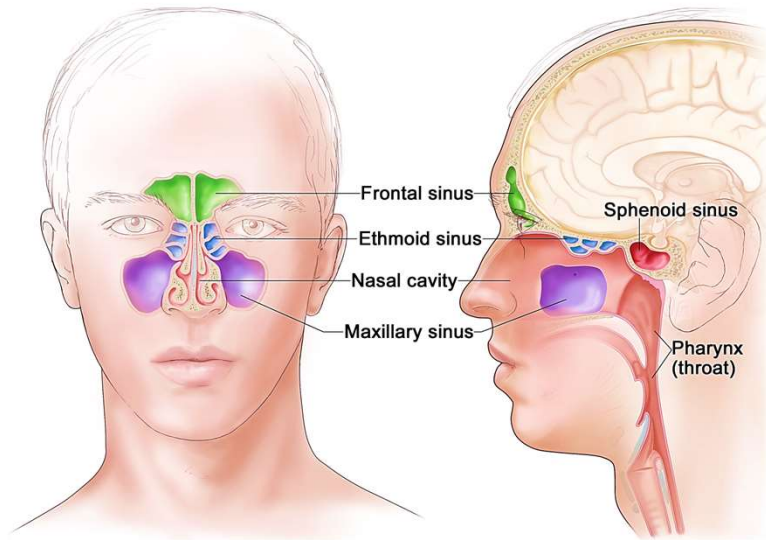
Lymph Drainage



11/2/2022

20

Paranasal sinuses



11/2/2022

Dr Maan AlAbbasi PhD MBChB MD

21

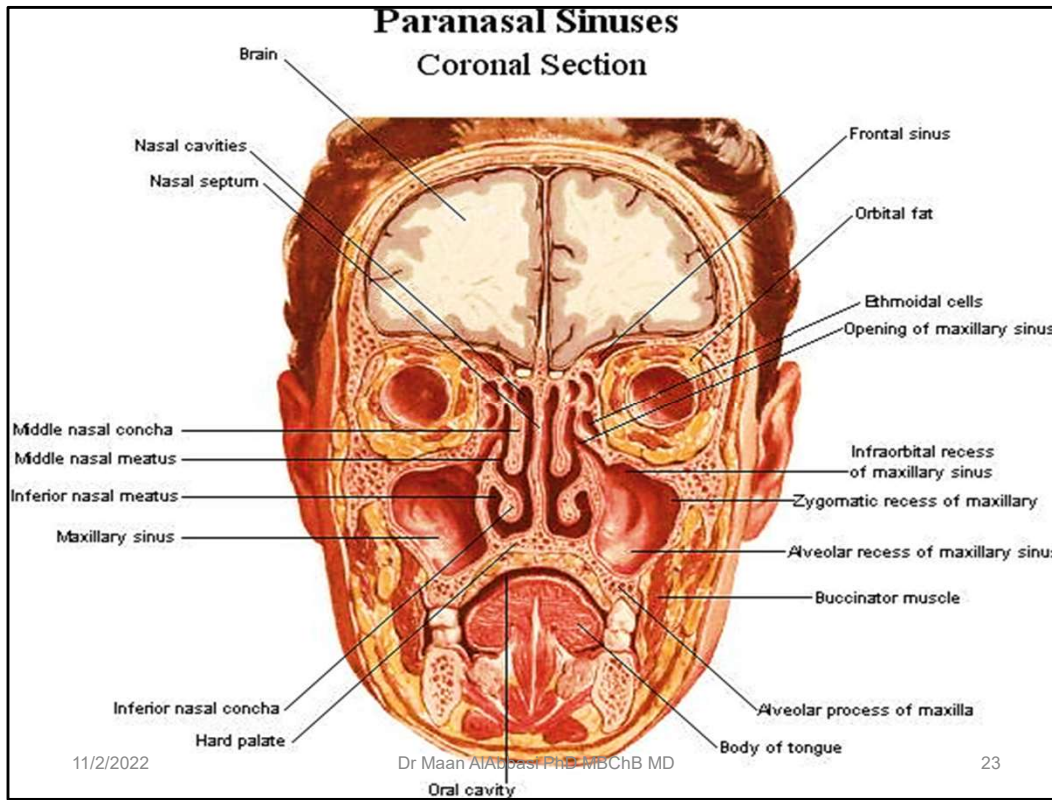
Paranasal Sinuses

- The paranasal sinuses are cavities found in the interior of the maxilla, frontal, sphenoid, and ethmoid bones
- They are lined with mucoperiosteum and filled with air
- They communicate with the nasal cavity through relatively small apertures
- The maxillary and sphenoidal sinuses are present in a rudimentary form at birth
- They enlarge appreciably after the eighth year and become fully formed in adolescence

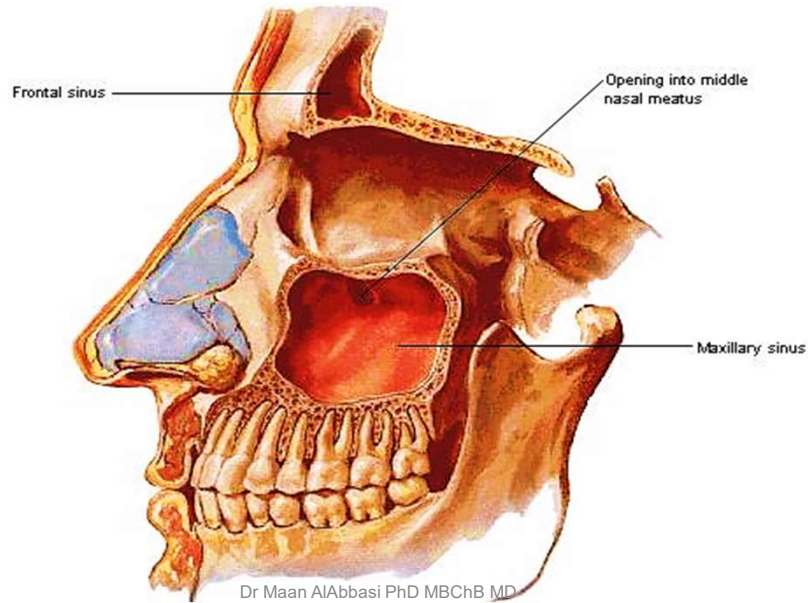
11/2/2022

Dr Maan AlAbbasi PhD MBChB MD

22



Maxillary air sinus

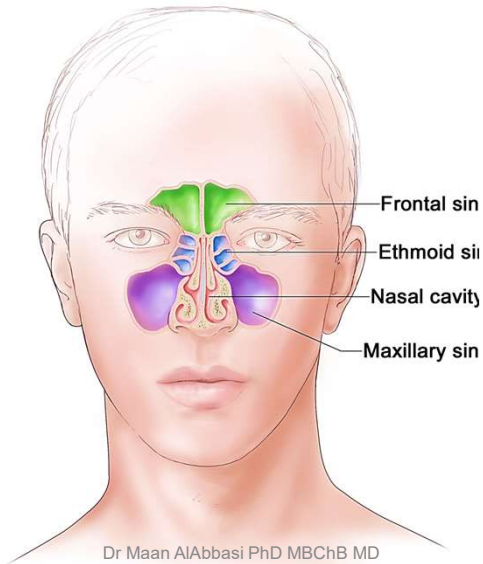


11/2/2022

Dr Maan AlAbbasi PhD MBChB MD

24

Frontal air sinus

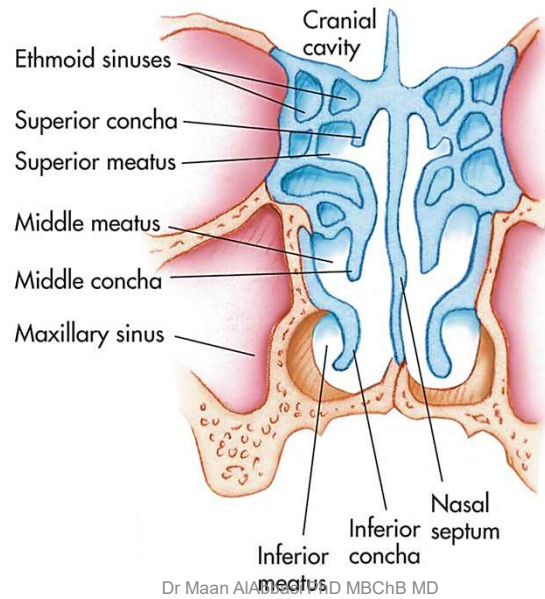


11/2/2022

Dr Maan AlAbbasi PhD MBChB MD

25

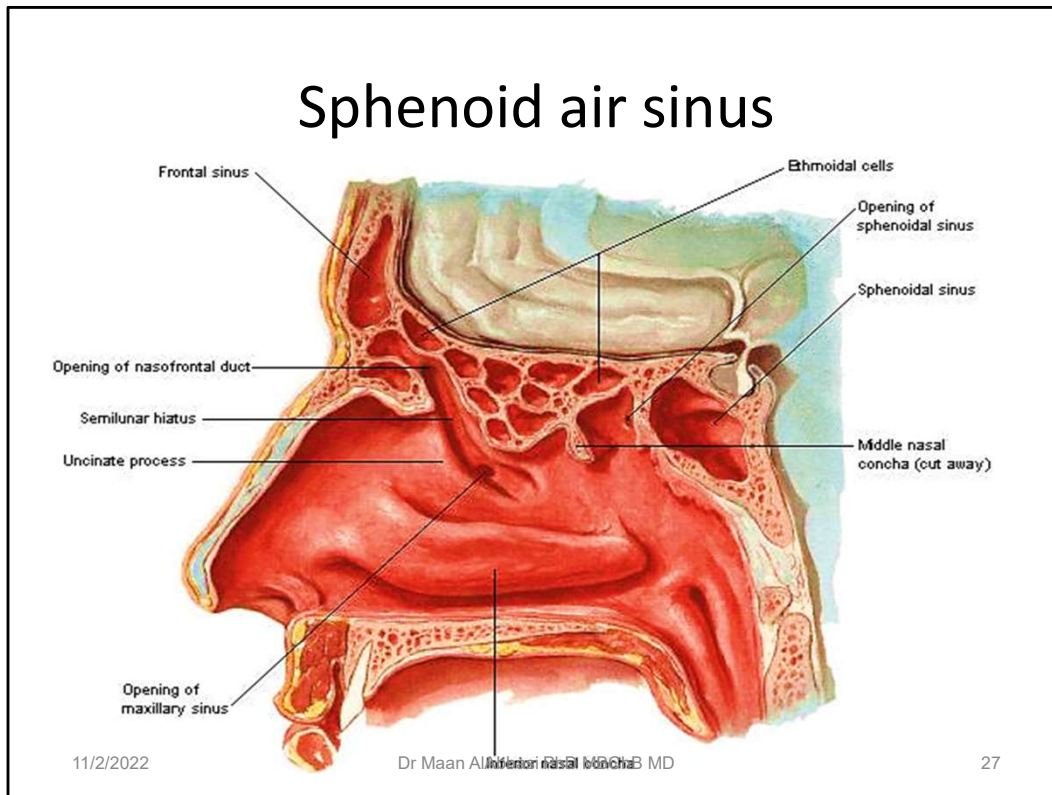
Ethmoid air sinus

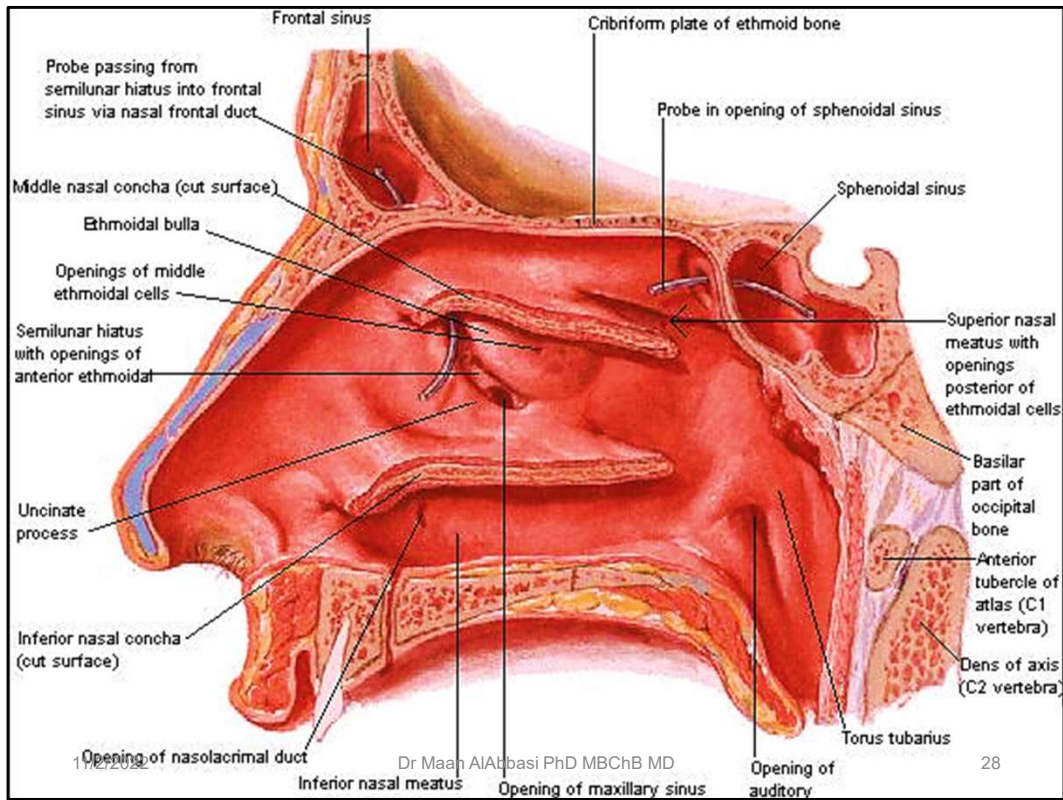


11/2/2022

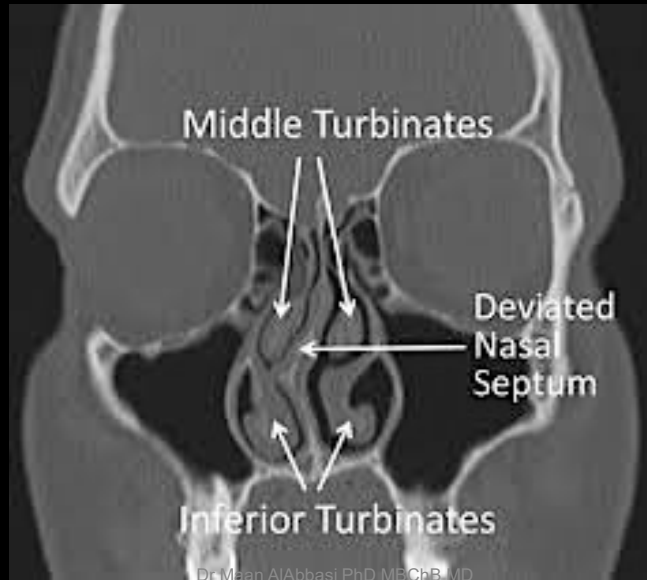
Dr Maan AIAbbasi PhD MBChB MD

26





Paranasal air sinuses -radiology

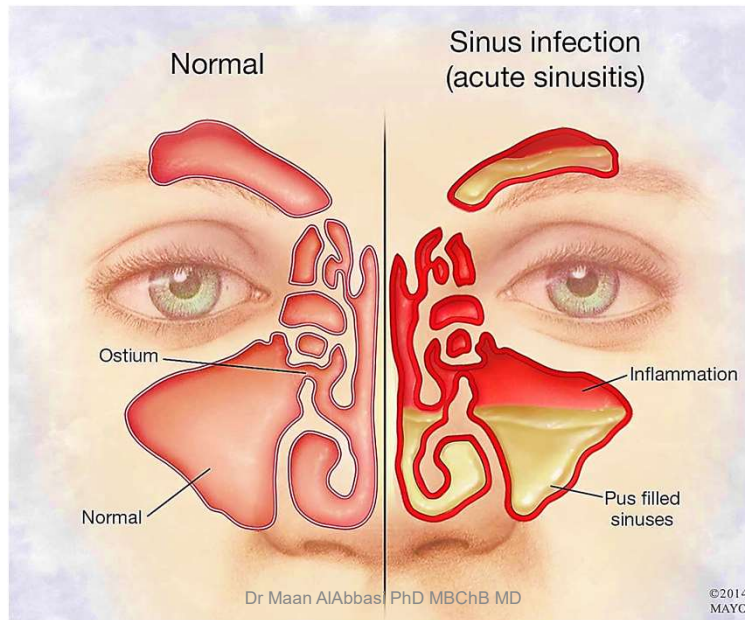


11/2/2022

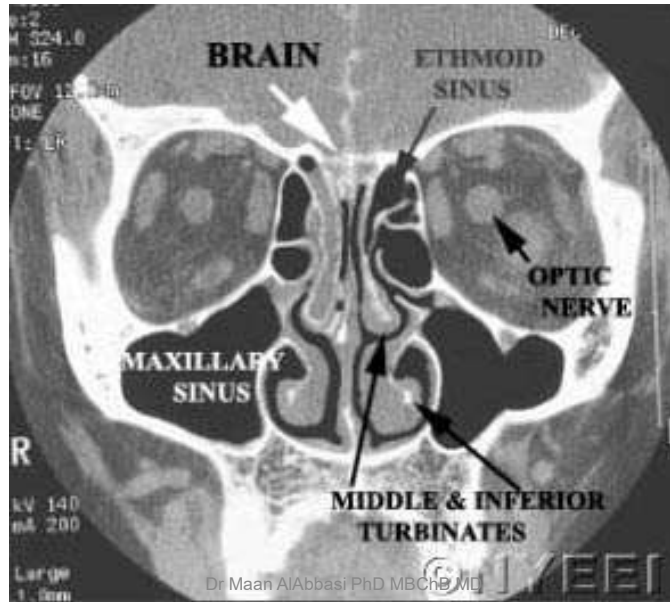
Dr Maan AlAbbasi PhD MBChB MD

29

Sinus Infection (sinusitis)



Ethmoid

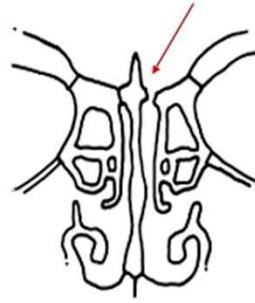
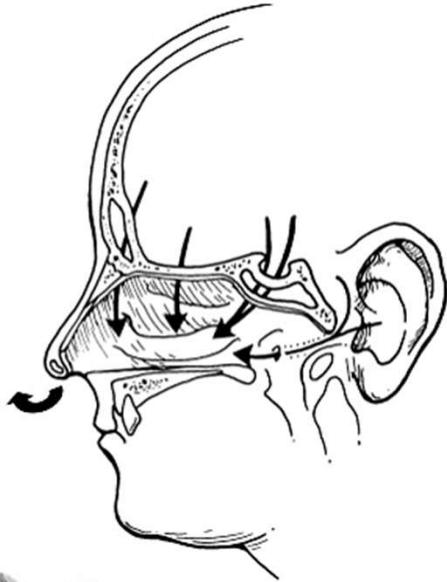


11/2/2022

Dr Maan AlAbbasi PhD MBChB MD

31

Common sites for CSF leak



- Cribriform plate, frontal sinus, Ant. Eth. roof.
- posterior ethmoid roof,
- sphenoid sinus.
- temporal bone (pseudorhinoliquorrhea).



www.indiandentalacademy.com
 Dr Maan AlAbbasi PhD MBChB MD

