JAUNDICE IN FAMILY MEDICINE

Assistant Prof.
Dr Alaa A.Salih –FICMS(FM) -2024

Jaundice, is a yellowish discoloration of tissue resulting from the deposition of bilirubin. Tissue deposition of Bilirubin occurs only in the presence of serum hyperbilirubinemia and is a sign of either liver disease or, less often, a hemolytic disorder.

- increases in serum Bilirubin level are best detected by examining the sclera, which have a particular affinity for bilirubin due to their high elastin content.
- The presence of scleral jaundice indicates a serum bilirubin level of at least 51 µmol/L (3 mg/dL).
- If the examiner suspects scleral jaundice, a second site to examine is underneath the tongue.

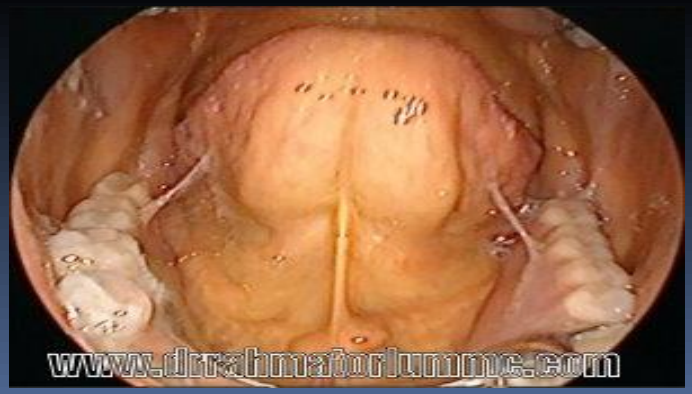

- As serum bilirubin levels rise, the skin will eventually become yellow in light-skinned patients and even green
- If the process is long-standing; the green color is produced by oxidation of bilirubin to biliverdin.

Critical Questions in the Evaluation of the Jaundiced Patient

- Is it jaundice?
- Acute vs. Chronic Liver Disease
- Prehepatic VS hepatic
- Hepatocellular vs. Cholestatic

Evaluation of the Jaundiced Patient

HISTORY

- Pain
- Fever
- Confusion
- Weight loss
- STI
- Alcohol
- Medications
- itching
- malaise, myalgias
- dark urine
- ↑ abdominal girth
- edema
- other autoimmune diseases
- HIV status
- family history liver dis

Evaluation of the Jaundiced Patient

PHYSICAL EXAM

- Vital signs
- Mental status
- Asterixis
- Abd tenderness
- hepatomegaly
- Splenomegaly
- Ascites
- Edema
- Spider angiomata
- Hyperpigmentation
- Kayser-Fleischer rings
- Xanthomas
- Gynecomastia
- Left supraclavicular adenopathy (Virchow's node)

Chronic Liver Disease

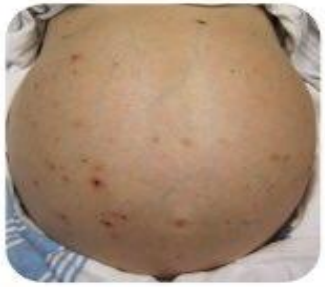

Hepatomegaly and **Ascites**

Cirrhosis

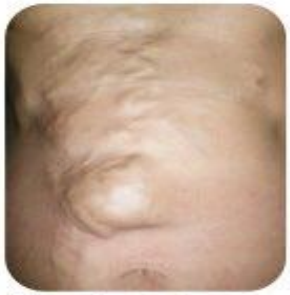

Caput medussae
(dilated veins around the umbilicus due to portal htn)

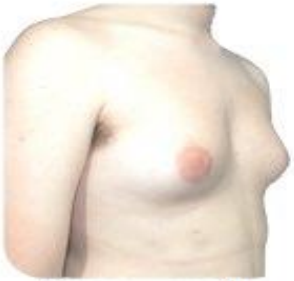

Gynecomastia
(impaired breakdown of estrogens)

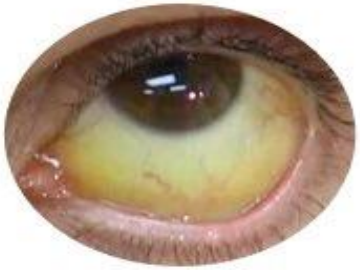

Icterus
(increased bilirubin due to dysfunction of bilirubin metabolism)

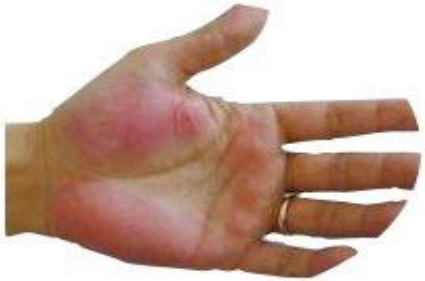

Palmar erythema
(impaired breakdown of sex hormones)

Spider nevi
(isolated telangiectasias)

Ecchymosis
(defective coagulation)

Leukonychia
(hypoalbuminemia)

Finger clubbing

Asterixis
(abnormal motor fct due to faculty metabolism)

FECTOR HEPATICUS

(characteristic odor due to volatile aromatic compounds)

Evaluation of the Jaundiced Patient

LAB EVALUATION

- AST(S.GOT)-ALT(S.GPT)-ALP
- Bilirubin –total/indirect
- Albumin=chronic
- INR&PT= acute
- B.Glucose
- Na-K-PO4, acid-base
- Acetaminophen level
- CBC/plt
- Viral serologies
- ANA-ASMA-AMA
- Ceruloplasmin
- Iron profile
- Blood cultures

Evaluation of the Jaundiced Patient

- Ultrasound:
  - More sensitive than CT for gallbladder stones
  - Equally sensitive for dilated ducts
  - Portable, cheap, no radiation, no IV contrast
- CT:
  - Better imaging of the pancreas and abdomen
- MRCP:
  - Imaging of biliary tree comparable to ERCP
- ERCP:
  - Therapeutic intervention for stones
  - Brushing and biopsy for malignancy

Case #1

- 59 year old male lawyer
  - Nausea, vomiting, lethargy, chronic back pain
  - Drinks alcohol
  - PMH: HTN, hypercholesterolemia
  - Meds: Lisino, atorvastatin, Vicodin
- SS afebrile, jaundice, no stigmata for cirrhosis
  - Ex no asterixis no edema, no ascites
  - RUQ tender, liver span 18 cm, no palp spleen
- AST 3246, ALT 4620, ALP 105, bili 5.2

Case #2

- 38 year old female manager
  - 3 days of episodic severe RUQ pain
  - 2 days of fever/chills/rigors
  - Daughter noticed yellow eyes today
  - PMH: DM, HTN
  - Meds: glipizide, HCTZ
- BP 110/64 HR 112, temp 39
  - Jaundice, no stigmata of cirrhosis
  - RUQ tender to palp, no spleen, no ascites
- AST 602, ALT 654, ALP 256, bili 5.2

Case #3

- 64 year old female
  - 1 month history of fatigue, anorexia, arthralgias
  - 1 week history of jaundice
  - No abdominal pain, no fever, 2.5 Kg wt. loss
  - Denies EtOH.
  - PMH: none PSH: none meds: rare
- AST 256, ALT 302, ALP 162, bili 8.6

  alb 3.2 INR 1.3 TP 8.4 plt 256

Clinical Aspects of Jaundice

- Clinically detectable if SB is >2.5 mg%
- With edema and dark skin – Jaundice is masked
- What is special about the sclera ? – Rich Elastin
- Darkening of the urine – Differential Diagnosis
- Skin discoloration – Yellowish, - Carotinemia – Eyes N
- Mucosa – hard palate (in dark skinned)
- Greenish of skin and sclera - due Biliverdin – indicates long standing jaundice
- Generalized Pruritus – Obstructive Jaundice – Why ?

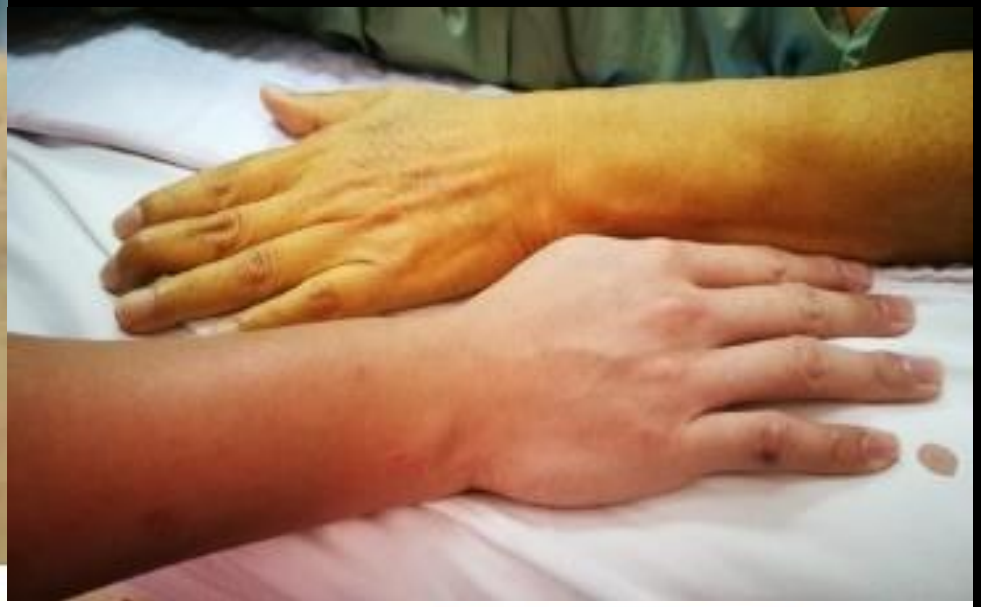

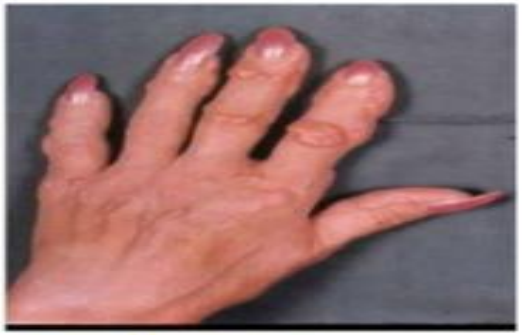

Xanthomas

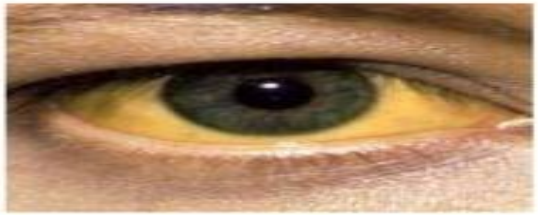

Sceral icterus

Scratch marks & pruritus

Cholestasis:
Retained bile pigments & bilirubin in hepatocytes

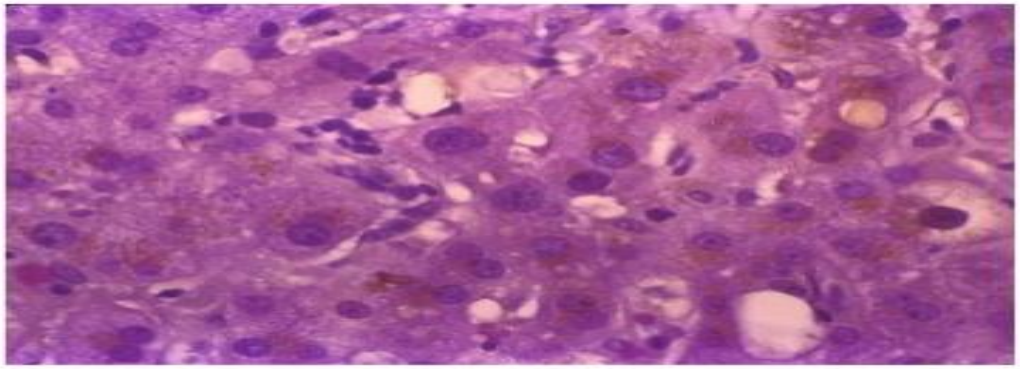

Clinical History – Imp. clues

- Duration of jaundice – Acute / Chronic
- Abdominal pain v/s painless jaundice
- Fever – Viral / bacteria /sepsis
- Arthralgia, rash, glands; Pruritus - obstructive
- Appetite – Hepatocellular / Malignancy
- Weight loss – Malignancy
- Colour of stools –chalky white –obstructive
- Family history – Hemolytic – Inherited dis.
- H/o transfusion, STI
- Alcohol abuse, Medications – INH, EM, Largactil=Chlorpromazine

SUUDEN DISTURBE CONSCIOUSNESS	BP=129/71		WBC=13.6	DIAMICRON 60MG ONCE
HICCOUGH-	HR=87		HB=12.8	BETALOC 100MG
ON LARGACTILE 50MG *2	CANNOT MOVE LT HAND		MCV=62	ASPIRIN 81MG
	NDR		RBS=146/ TSB=5.3	XIGDUO 5/1000*2
	CLEAR CHEST		AST=404/ALT=611	LEGALON
	NO LEG OEDEMA		U=72/HBA1C=6.3	LINCOCIN 600MG=5
	JAUNDICE		CRP=113	BELIRELAX/B12=5/
25/3/2023				
HICCOUGH	BP=129/71	U/S=IBS	HB=12.4/MCV=60	LYRICA 75MG
HYPOGLYCEMIA	HR=87		ALT=8.5/AST=9.4	BETALOC 100MG
TO RE-EVALUATE KIVER FUNCTION'	CANNOT MOVE LT HAND		U=50/C=0.5	ASPIRIN 81MG
	NDR		LDL=65	XIGDUO 5/1000*1
	CLEAR CHEST		CRP=17	DUPHALC SYP
	NO LEG OEDEMA		T4=100/TSH=1.65	MAXIM 400MG
	HICCUOGH			

Colored Urine – Differ. Diagnosis

- Concentrated urine in dehydration
- Fluid deprivation syndromes
- Sulfasalazine use – for Ulcerative colitis
- Rifampicin, Pyridium and Thiamine use
- Red urine – Porphyria,
- Hemoglobin & Myoglobinuria,Hematuria
- Melanin excretion from Melanoma
- Red sweat in Clofazamine, Rifampicin

An Approach to Jaundice

- Is it isolated elevation of serum bilirubin ?
- If so, is the↑unconjugated or conjugated fraction?
- Is it accompanied by other liver test abnormalities ?
- Is the disorder hepatocellular or cholestatic?
- If cholestatic, is it intra- or extrahepatic?
- These can be answered with a thoughtful History and physical examination
- Interpretation of laboratory tests and Radiological tests and procedures.

Normal values for LFT

Features	Healthy Normal
Total Bilirubin	**0.3-1.3 mg/dl**
Conjugated Bilirubin	**0.1-0.4 mg**
AST (S.GOT)	**12-38 U/L**
ALT (S.GPT)	**7-41 U/L**
Alkaline phosphatase	**13-100 U /L**
GGT and 5' Nucleosidase.	Significantly ↑ in ALD
Urine Bilirubin	Absent
Urine Urobilinogen	In trace quantity
Urine Bile Salts	Absent

Lab Diagnosis of Jaundice – D.D

Features	Prehepatic (Heamolytic)	Intrahepatic (Hepatocellular)	Posthepatic (Obstructive)
Unconjugated	↑	Normal	Normal
Conjugated	Normal	↑	↑
AST or ALT	Normal	↑ ↑	Normal
Alkaline phos. and GGT	Normal	Normal	↑ ↑
Urine bilirubin	Absent	Present	Increased
Urobilinogen	Increased	Present	Absent
Hb and Retic	Low+ increase	normal	normal

Utility of Liver Function Tests

LFT	Utility of the test
ALT/SGPT	ALT ↓than AST in alcoholism
Albumin	Assess severity / chronicity
Alk. phosphatase	Cholestasis, hepatic infiltrations
AST/SGOT	Early Dx. of Liver disease, Follow up
Bilirubin (Total) /Conjug.	Diagnose jaundice
Gamma-globulin	Dx. F/up Chronic hepatitis & cirrhosis
GGT	Dx alcohol abuse

Non Hepatic causes of abnormal LFT

ABNORMAL LFT	NON HEPATIC CAUSES
Albumin	Nephrotic syndrome Malnutrition, CHF
ALP	Bone disease, Pregnancy, Malignancy , Adv age
AST (S.GOT)	MI, Myositis, I.M.injections
Bilirubin	Hemolysis, Sepsis, Ineffective erythropoiesis
PTT	Antibiotics, Anticoagulant, Steatorrhea, Dietary

Algorithmic approach for Jaundice

How to clinically evaluate the patient ?

What tests will help us in D.D ?

What imaging modalities will be useful ?

How to monitor the progress ?

First Step

Estimate Serum Bilirubin

Is it less than 1 mg % - Normal

Is it more than 1 mg % - Elevated

Second Step : If SB > 1.0 mg

Is it unconjugated bilirubin ?

Haemolytic Jaundice

Is it Conjugated Bilirubin ? (> 20%)

Hepatocellular jaundice

Obstructive jaundice

↑ in Unconjugated Bilirubin

Hemolytic Jaundice - Uncommon

1. Hemolytic Disorders + Anemia

Inherited – Sphero, SS, G6PD, PK

Acquired – Paroxysmal nocturnal hemoglobinuria

2. Ineffective Erythropoesis –B_{12}, Fe, F

3. Drugs – Rifampicin, Probenecid

4. Inherited –Crigler Najjar, Gilberts

Third Step : If Conj SB increased

Do - AST and ALT (SGOT and SGPT)

Elevated AST and ALT

Hepatocellular jaundice

AKP, 5N, GGT will be normal

Do - Alkaline Phosphatase and GGT

AKP, GGT ↑↑ in Obstructive Jaundice

AST and ALT will be normal

Fourth Step : Hepatocellular

Hepatocellular – Features and D.D

Conjugated SB is increased

AST and ALT are increased

AKP, 5NS, GGT are normal

Hepititis – A,B,C,D,E, CMV,EBV

Toxic Hepatitis – Drugs, Alcohol

Malignancy – Primary Ca

Cirrhosis – ALD, NAFLD

What imaging we need

- Ultrasonography – 98% Sp, 90% Sen.
- For GB stones USG better than CT
- For duct stones –only 40% seen in USG
- PTC – Extrahepatic obstr. – drainage
- ERCP – Distal biliary obstruction Dx.Rx.
- MRCP – Most useful for duct stones

Chronic Liver Disease (CLD)

- Alcoholic Liver (ALD)
- Chronic viral hepatitis
  - Hepatitis B
  - Hepatitis C
- Autoimmune liver disease:
  - Autoimmune hepatitis
  - Primary Biliary Cirrhosis (PBC)
- Inherited conditions
  - Haemochromatosis
  - Wilson's Disease
  - Alpha1-Antitrypsin Deficiency (AATD)
- Non-alcoholic fatty liver disease (NAFLD)
- Budd-Chiari syndrome
- Cryptogenic

Hepatotoxic drugs

Conventional Drugs	Natural Substances
Acetaminophen, Alpha-methyldopa	Vitamins, Hypervitaminosis A
Amiodarone, Dantrolene, Diclofenac	Niacin, Cocaine, Mushrooms
Disulfiram, Fluconazole, Glipizide	Aflatoxins, Herbal remedies
Glyburide, Isoniazid, Ketaconazole	Senecio, crotaliaria,
Labetalol, Lovastatin, Nitrofurantoin	Pennyroyal oil, Chapparral,
Thiouracil, Troglitazone, Trazadone	Germander, Senna, Herbal mix.

Acute Cholecystitis

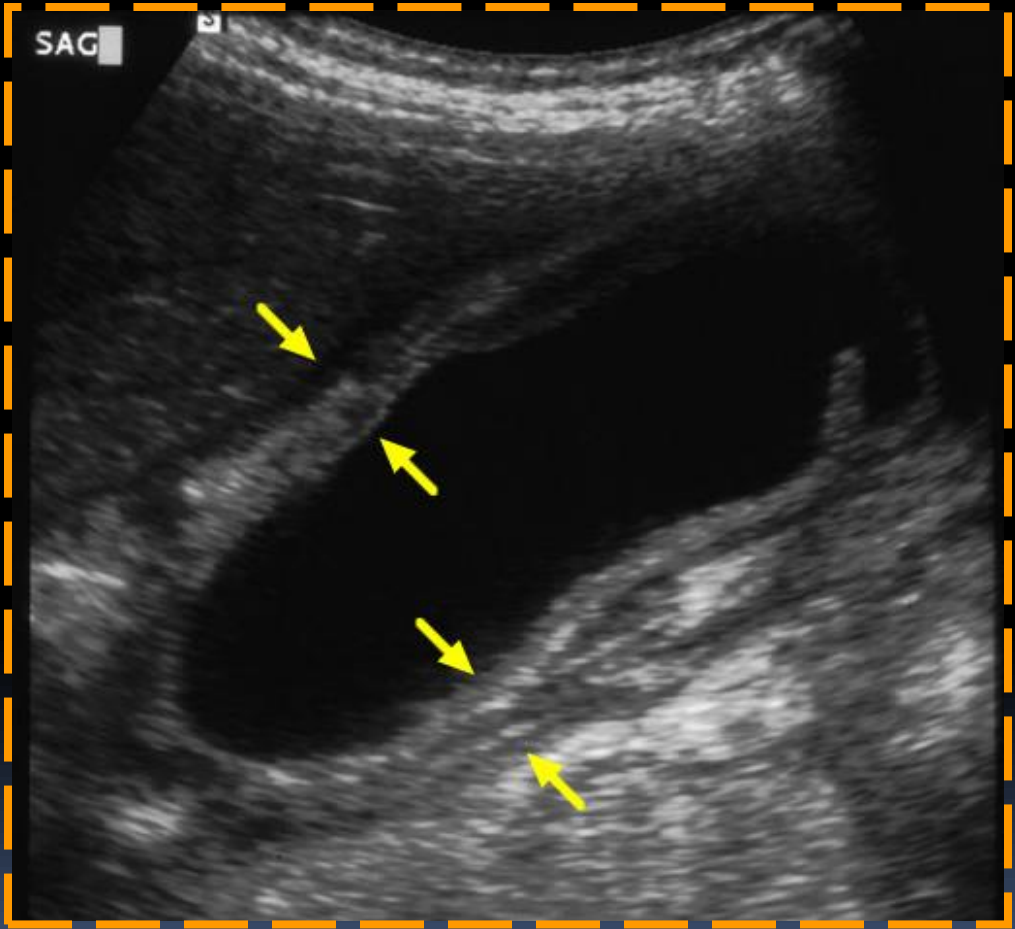

GB wall is thickened and striated.
Courtesy of Udo Schmiedl, M.D.

Causes of Cholestatic Jaundice

Intrahepatic	Extrahepatic
Acute liver injury, Viral hepatitis	Choledocholithiasis
Alcohol hepatitis, Drugs	Stone obstructing CBD, CD
Chronic liver injury, PBC, PSC	Biliary strictures
Autoimmune cholangiopathy	Cholangiocarcinoma
Drugs, Total parenteral nutrition	Pancreatic carcinoma
Systemic infection, Postoperative	Pancreatitis, Periampullary Ca
Benign causes, Amyloid, lymphoma	PSC, Biliary atresia, duct cysts

Drugs causing Cholestasis

- Anabolic steroids (testosterone)
- Antithyroid agents (methimazole)
- Azathioprine (Immunosuppressive drug)
- Chlorpromazine HCl (Largactil)
- Clofibrate, Erythromycin estolate
- Oral contraceptives (containing estrogens)
- Oral hypoglycemics (especially chlorpropamide)

Complications of CLD

- Portal hypertension
  - Varices
  - Ascites
  - Hypersplenism
- Synthetic dysfunction
  - Coagulopathy
  - Encephalopathy
- Immunodeficiency
- Malnutrition
- Hepato-cellular carcinoma

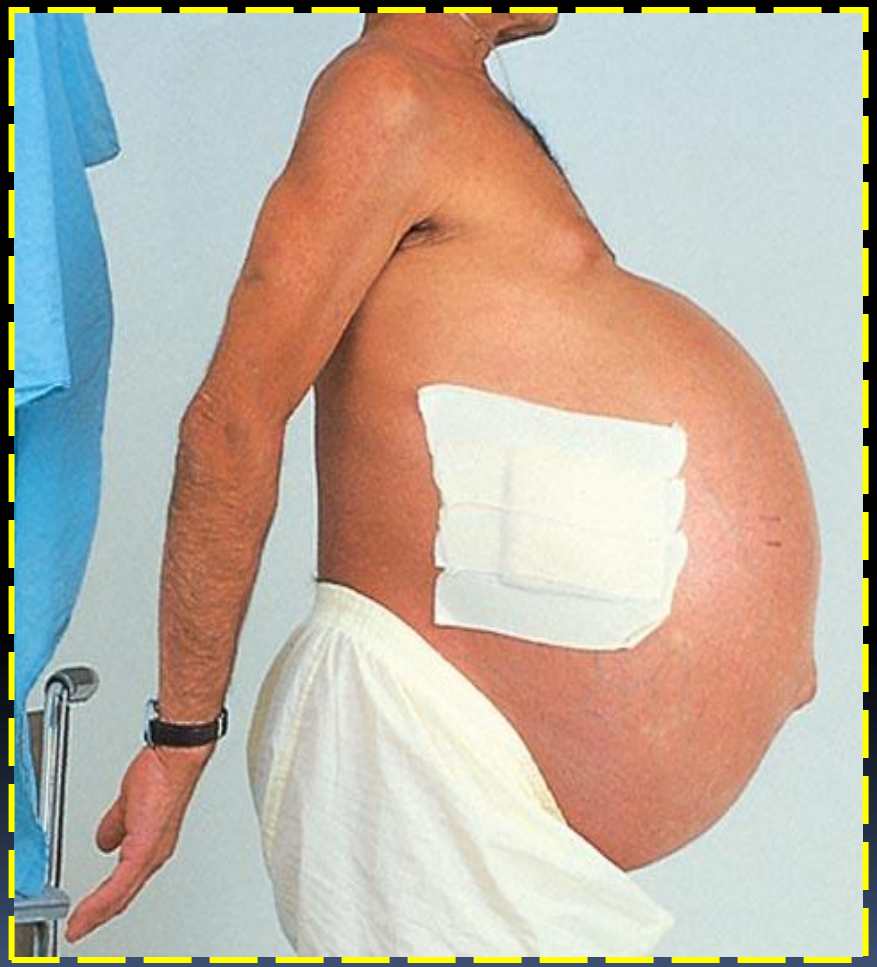

Manifestations of Wilson's Disease

Hepatic	Psychiatric
CAH, Cirrhosis, Fulminant hepatitis	Behavioral, organic dementia,
Early Neurological	Psychoneurosis, manic-depressive
Incoordination, dysarthria,	Schizophrenic psychosis
Resting and intention tremors	Ophthalmic
Excessive salivation, dysphagia	KF ring, sunflower cataract
Mask-like facies, ataxia	Hematologic and others
Late Neurological	IV hemolysis, Hypersplenism
Dystonia, spasticity, Rigidity, TCS	Distal RTA, Osteomalacia, OS

KF Ring of Periphery of Iris

Courtesy of Robert L. Carithers, Jr., M.D.

Magnetic Resonance Cholangio-Pancreatography (MRCP)

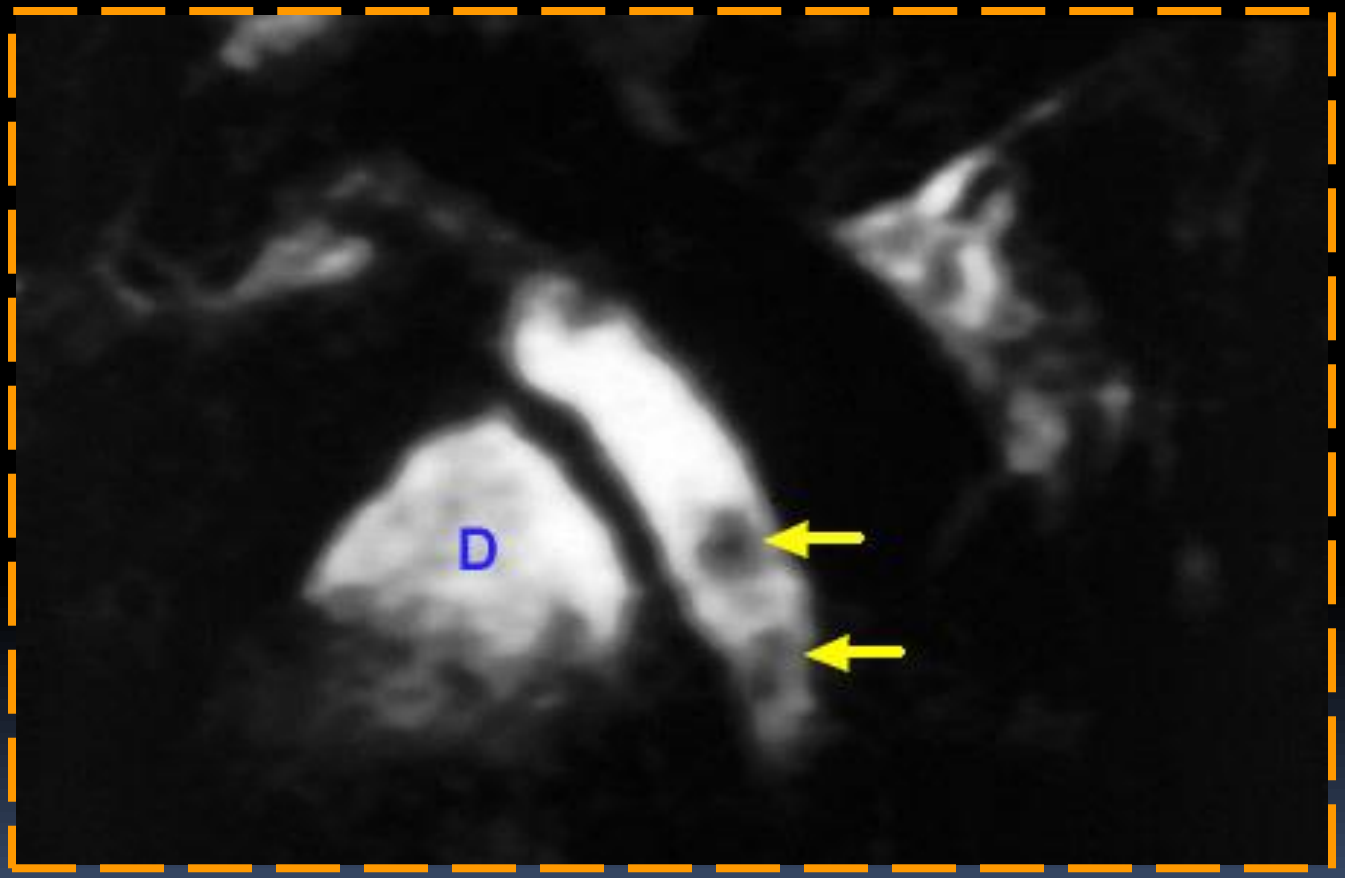

Two stones in the common bile duct

Courtesy of Udo Schmiedl, M.D.

Retrograde Cholangiogram - ERCP

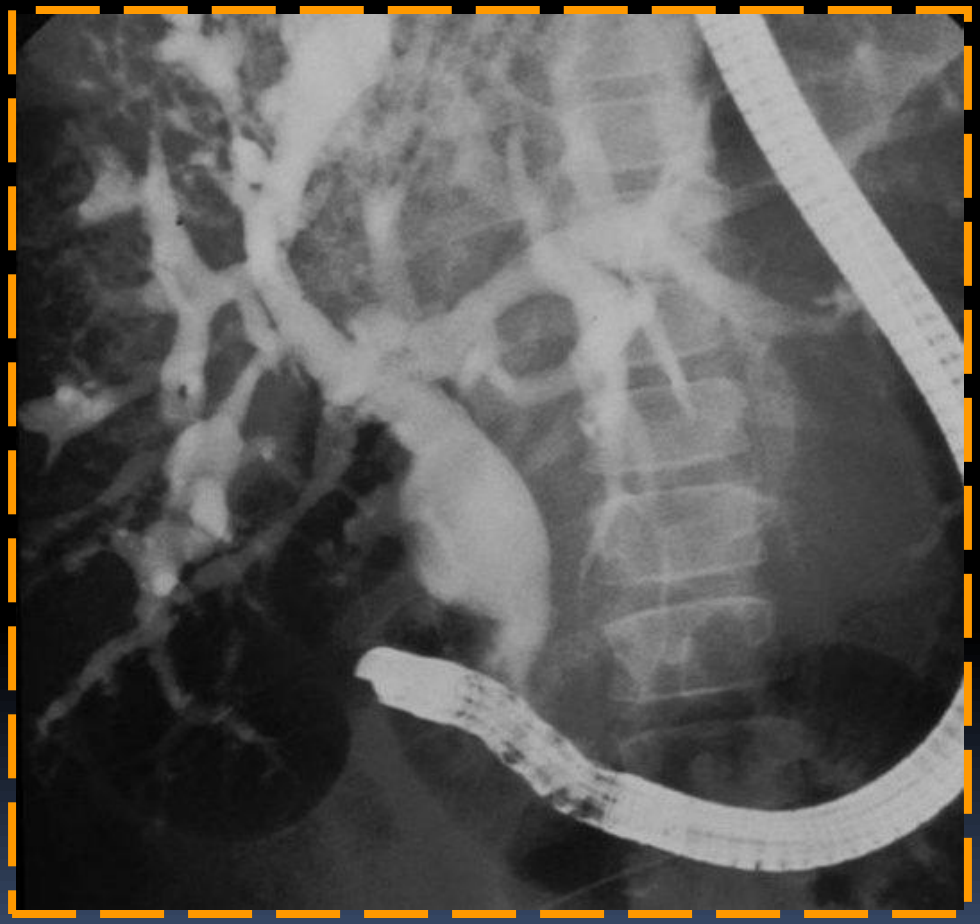

Irregular dilation of intrahepatic and extrahepatic ducts.
Courtesy of Charles Rohrmann, M.D.

CT Abdomen

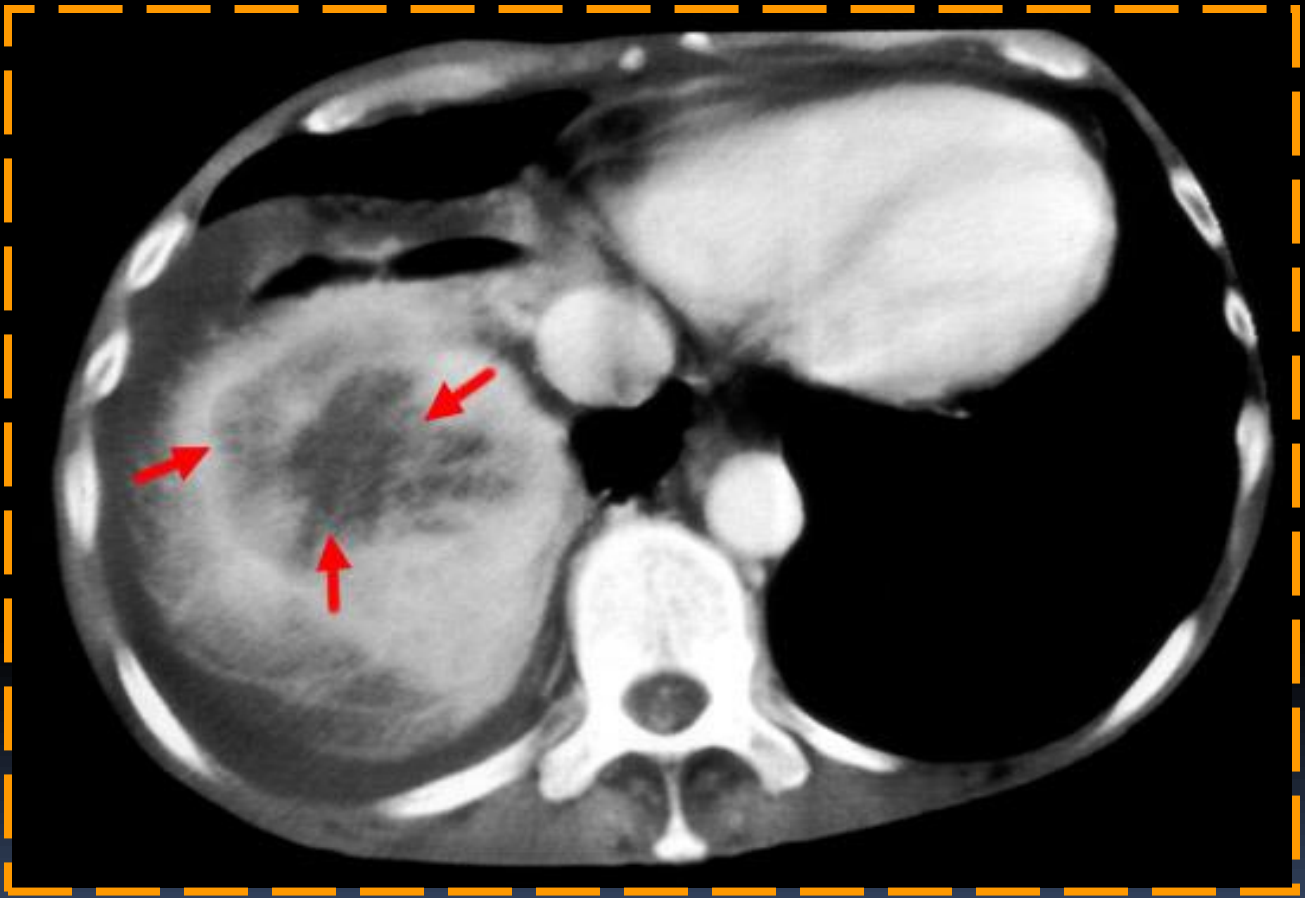

A large mass with a hepatoma.
Courtesy of Udo Schmiedl, M.D.

When to refer to GE Specialist

- Unexplained jaundice
- Suspected biliary obstruction
- Acute hepatitis - severe or fulminant
- Unexplained abnormal LFTs persisting (for 6 months or greater)
- Unexplained cholestatic liver disease
- Cirrhosis (in non-alcoholic) for consideration of liver transplant
- Suspected hereditary hemochromatosis
- Suspected Wilson's disease
- Suspected autoimmune hepatitis
- Chronic hepatitis C for consideration of antiviral therapy

THAN YOU