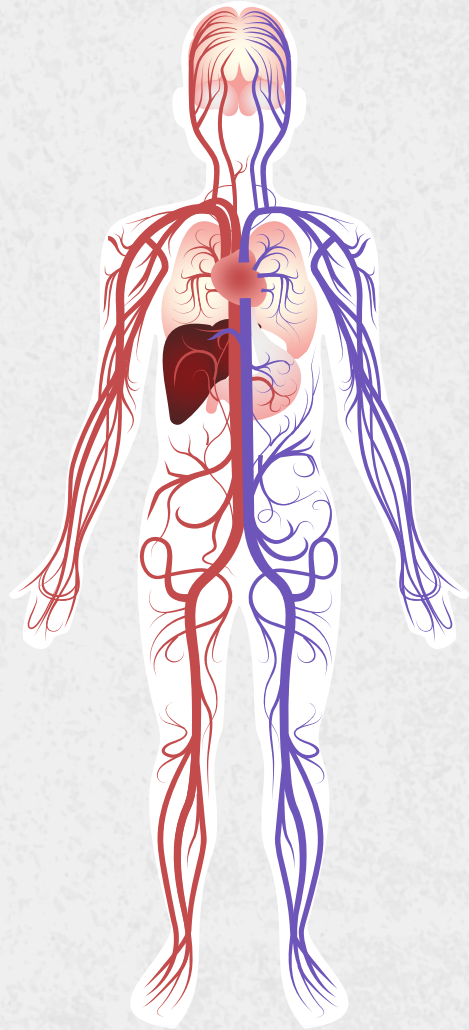


# Hemodynamic Disorders, Thromboembolism and Shock

**Dr. Raghad Hanoon**  
**LEC. 1**



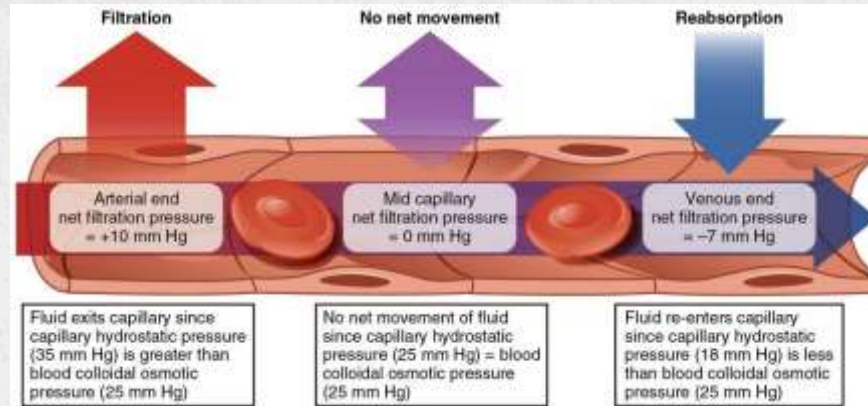
# Outlines

- **Edema**
- **Hyperemia and congestion**
- **Hemorrhage**
- **Hemostasis and thrombosis**
- **Embolism**
- **Infarction**
- **Shock**
- **References**




# Introduction

- The health of cells and tissues depends on the circulation of blood, which delivers oxygen and nutrients and removes wastes generated by cellular metabolism.
- The well-being tissues also requires normal fluid balance, which includes maintenance of vessel wall integrity as well as intravascular pressure and osmolarity within certain physiologic ranges.






# Edema

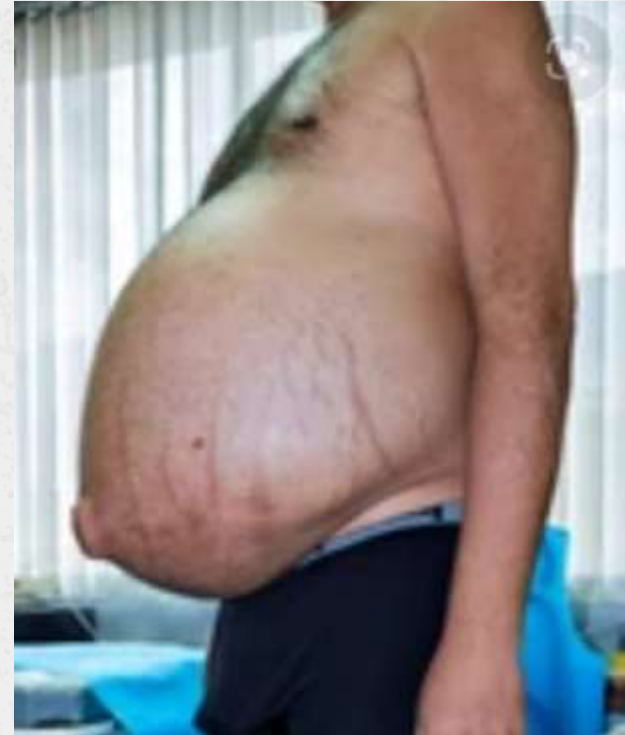
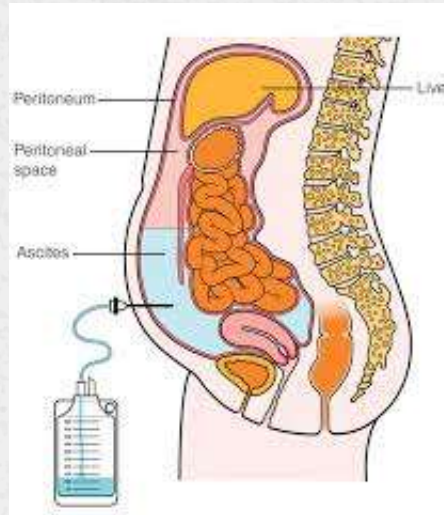


# Edema

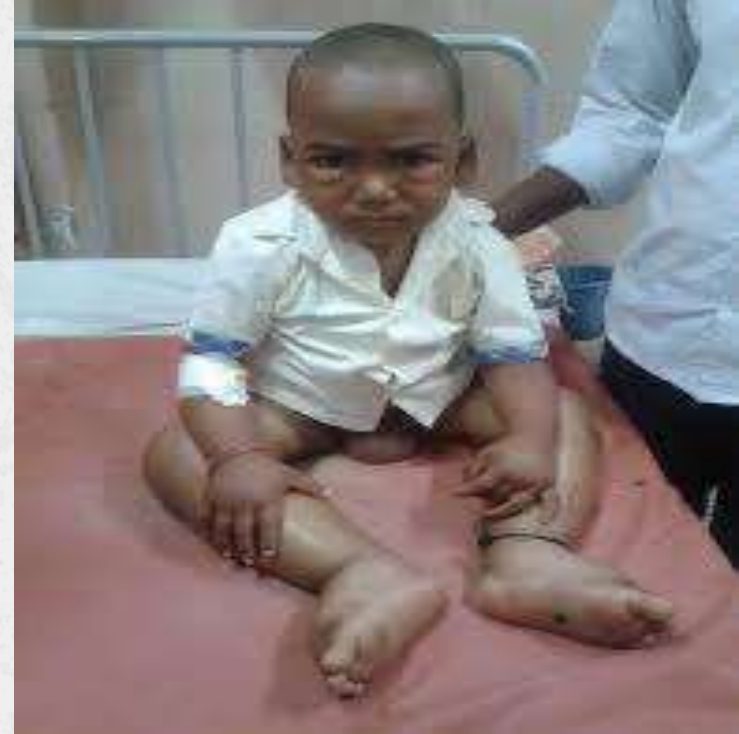- Approximately 60% of body weight is water. Two thirds of which is **intracellular**, and the remainder is **extracellular** in the form of interstitial fluid.
  - Only about 5% of total body water is **intra-vascular** (blood plasma).
  - **Edema:** is abnormal accumulation of interstitial fluid within tissues.
  - Collections of fluid in the different body cavities are referred to **effusions** . Examples include:  
**Hydrothorax** .....in pleura  
**Hydropericardium** .....in pericardium  
**Hydroperitoneum (ascites)** .. in peritoneum
- 

- **Ascites:** abnormal collection of fluids in the peritoneal cavity, complicating liver cirrhosis






- **Anasarca:** is a severe and generalized edema with widespread subcutaneous tissue swelling occur in liver cirrhosis ,heart and renal failure.

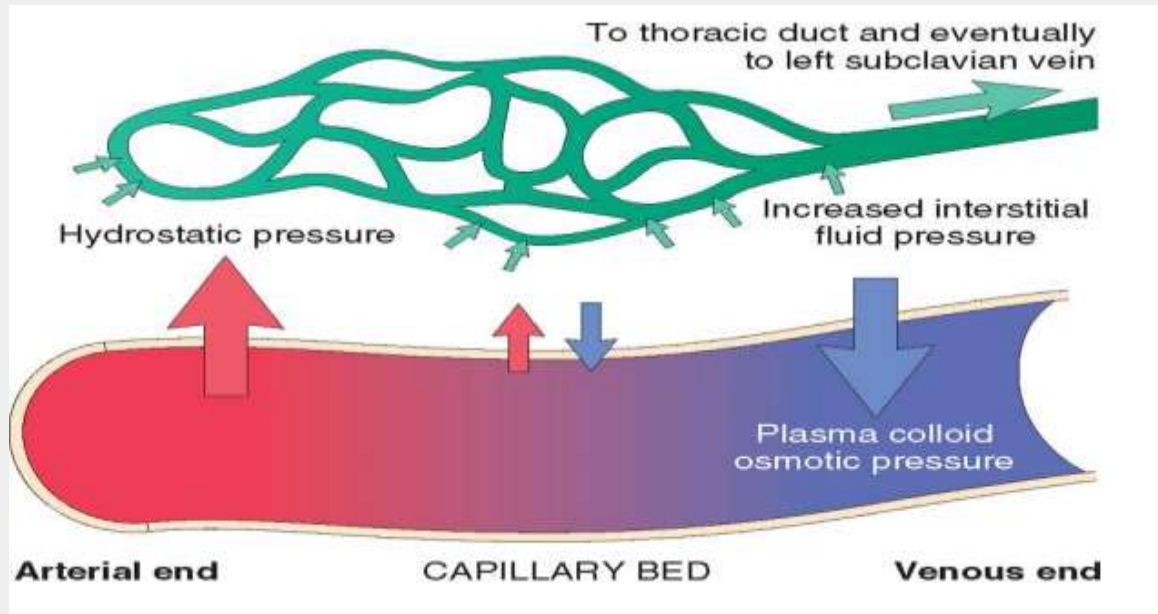




# Pathophysiology of edema:

- Fluid movement between the vascular and interstitial spaces is controlled mainly by two opposing forces;
    1. **Vascular hydrostatic pressure**
    2. **Plasma colloid osmotic pressure** (produced by plasma proteins).
  - Normally the outflow of fluid from the arteriolar end of the microcirculation into the interstitium is nearly balanced by inflow at the venular end; hence there is only a small residual amount of fluid may be left in the interstitium and is drained by the lymphatic vessels, which return to the bloodstream via the thoracic duct.
- 






Factors influencing fluid movement across capillary walls. Capillary hydrostatic and osmotic forces are normally balanced so there is little net movement of fluid into the interstitium. However, increased hydrostatic pressure or diminished plasma osmotic pressure leads to extravascular fluid accumulation (edema). Tissue lymphatics drain much of the excess fluid back to the circulation by way of the thoracic duct; however, if the capacity for lymphatic drainage is exceeded, tissue edema results.



# Types of edema fluid


1. **Transudates;** developed in the setting of **increased hydrostatic pressure or reduced intravascular colloid pressure**, it is a protein-poor fluid and specific gravity of **1.012** and less.
  2. **Exudate;** occurs with increased vascular permeability, due to inflammation (**inflammatory edema**); it is a protein-rich fluid with specific gravity of **1.020** and more.
- 



# **Causes of edema:**

**A- Inflammatory Edema**


**B- Non-Inflammatory Edema**

- 1. Increased Hydrostatic Pressure**
  - 2. Reduced Plasma Osmotic Pressure**
  - 3. Lymphatic Obstruction**
  - 4. Sodium and water Retention**
- 





## ❖ Inflammatory Edema:

- Occurs due to effects of **inflammatory mediators** that cause increase vascular permeability and accumulation of protein rich fluid (**exudates**) in the interstitial tissue.
- 



# ❖ Non-Inflammatory Edema


## 1. Increased hydrostatic pressure:

- Increases in hydrostatic pressure are mainly caused by disorders that impair venous return.

1- Localized increase in venous pressure e.g. (deep venous thrombosis **DVT**) with edema of the affected limb.

2- Generalized increase in venous pressure with systemic edema occur in **congestive heart failure** (in which **reduced cardiac output** leads to **systemic venous congestion and resultant increase in capillary hydrostatic pressure**, At the same time **reduced renal perfusion** & trigger of rennin angiotensin aldosterone axis (secondary hyperaldosteronism) causing sodium & water retention by kidney in order to increase intravascular volume & improve cardiac output & renal perfusion .This **extra fluid** load only increased venous pressure & edema.

Unless cardiac output restored or renal fluid retention reduced (e.g. salt restriction, diuretics &/or aldosterone antagonists), repeated cycles of renal fluid retention & worsening edema result).






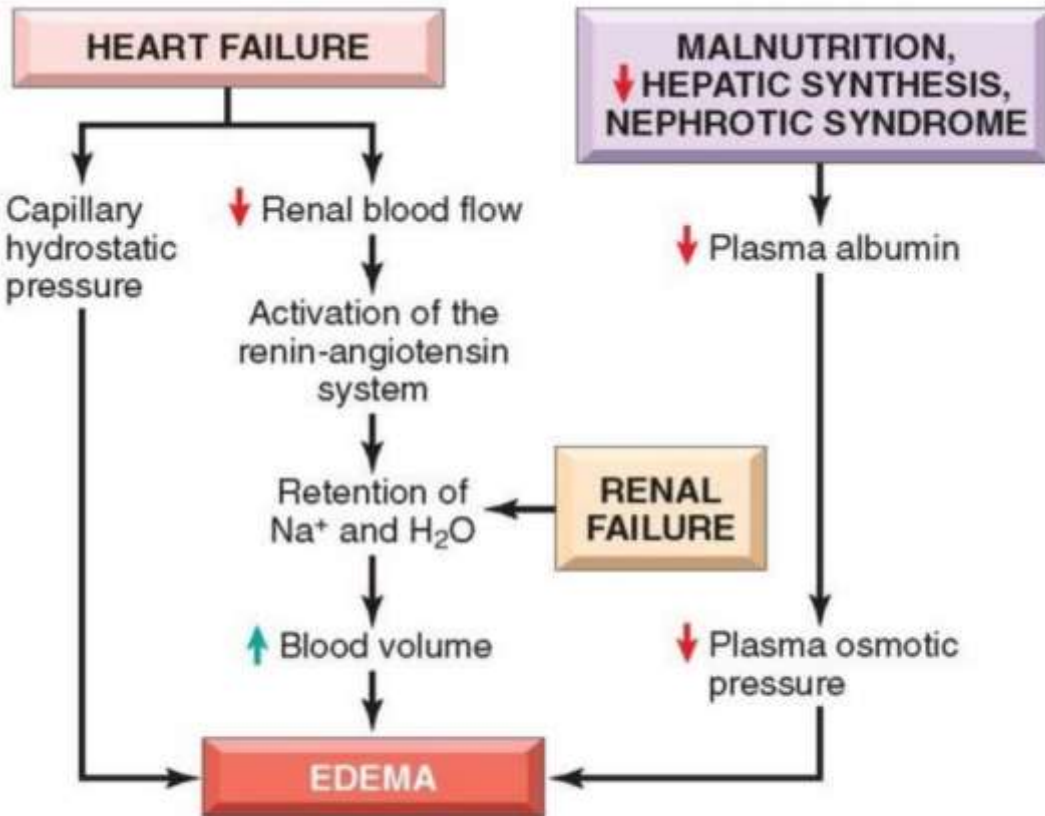
## 2. Reduced plasma osmotic pressure: (reduced plasma proteins)

- **Reduction of plasma albumin concentrations leads to decreased colloid osmotic pressure of the blood and loss of fluid from the circulation.**

Result from:

- **Increased loss of albumin** as in **nephrotic syndrome** (glomerular capillaries become leaky, leading to the loss of albumin (and other plasma proteins) in the urine and the development of generalized edema.
  - **Reduced protein synthesis** as in severe liver disease (**e.g. cirrhosis**) and **protein malnutrition**.
  - Regardless of cause, low albumin levels lead in a stepwise fashion to edema, **reduced intravascular volume, renal hypoperfusion**, and secondary hyperaldosteronism. Unfortunately, increased salt and water retention by the kidney not only fails to correct the plasma volume deficit but also exacerbates the edema, because the primary defect—low serum protein—persists.
- 





Mechanism of edema formation in heart failure , renal failure and hepatic failure




### 3. Lymphatic obstruction:

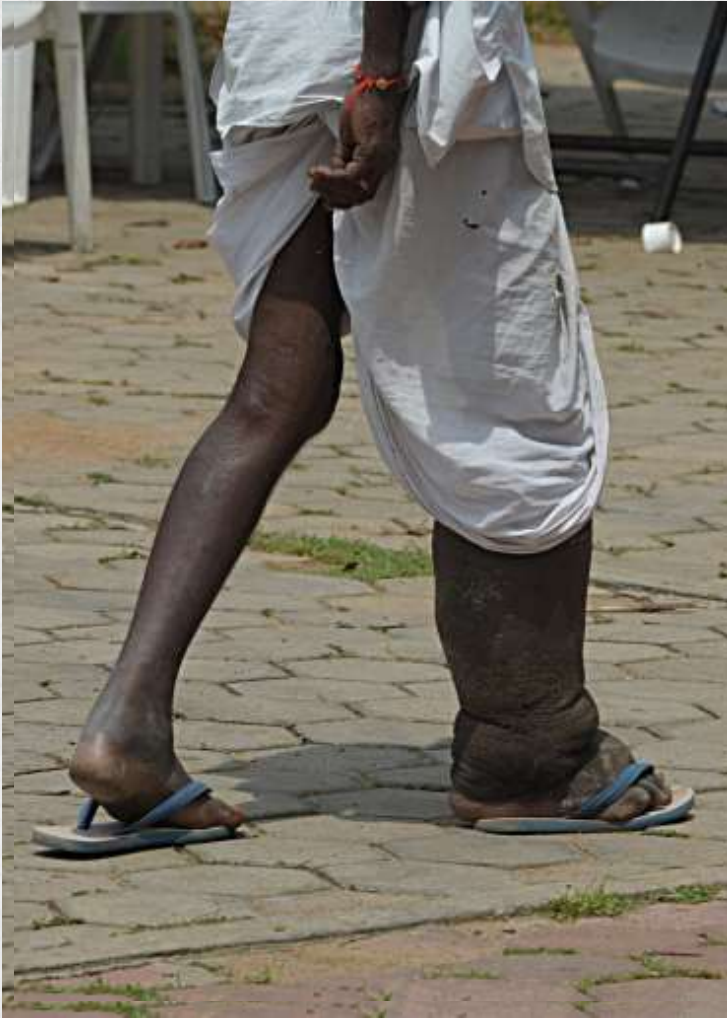- Edema may result from lymphatic obstruction that compromises resorption of fluid from interstitial spaces.
- **Usually localized.**
- **Causes:**

1- **Inflammatory obstruction** e.g. **filariasis**; which causes lymphatic obstruction & lymph node fibrosis in inguinal region leading to edema of genitalia & lower limb (elephantiasis).

2- **Breast cancer treated by surgery with axillary lymph node resection and/or irradiation**, both of which can disrupt and obstruct lymphatic drainage, resulting in severe **lymphedema of the arm**.

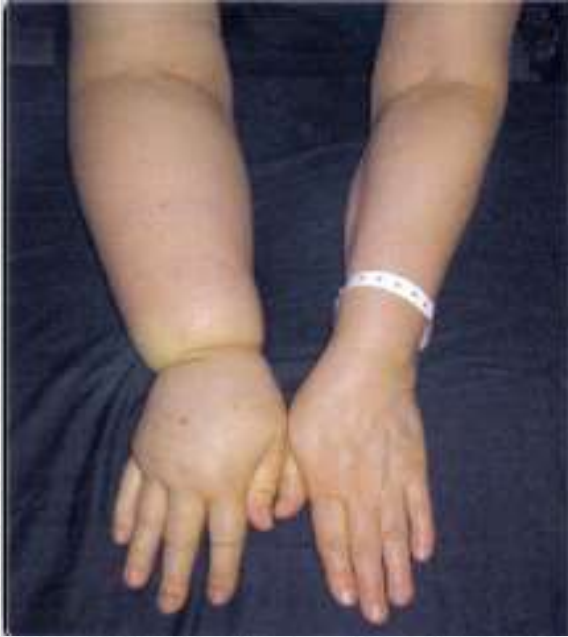3- **In breast cancer; infiltration & obstruction of superficial lymphatics by tumor cells** will cause edema of overlying breast skin (**peau-de-orange**) (orange peel) due to depression of the skin at site of hair follicles.





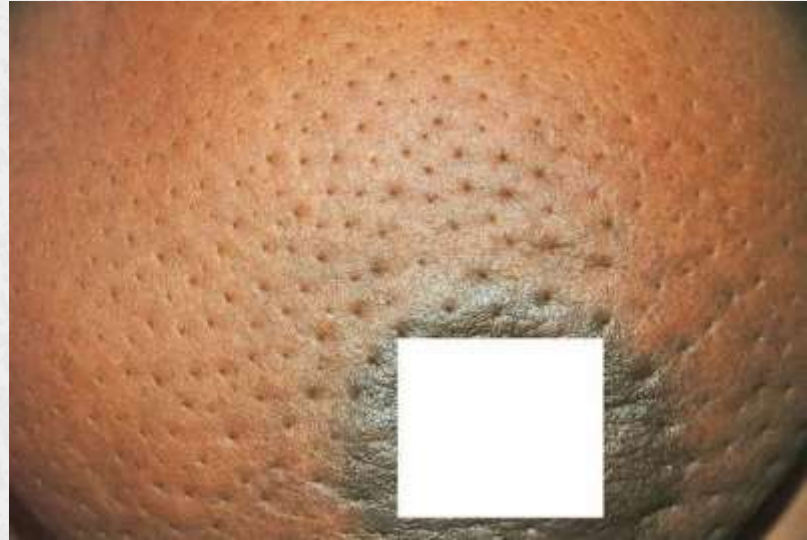
**1. Filariasis:** which causes lymphatic obstruction & lymph node fibrosis in inguinal region leading to edema of genitalia & lower limb (elephantiasis).





## 2. Lymphedema of arm;

Due to breast cancer treated by surgery or irradiation with resection of lymphatic drainage of upper limb & scarring




## 3. In CA breast;

Infiltration & obstruction of superficial lymphatics will cause edema of breast skin (**peau-de-orange**) due to depression of the skin at site of hair follicles.




## 4. Sodium and Water Retention

- Excessive retention of salt (and its obligate associated water) can lead to edema by increasing hydrostatic pressure (because of expansion of the intravascular volume) and reducing plasma osmotic pressure. Excessive salt and water retention are seen in a wide variety of diseases that compromise renal function, including poststreptococcal glomerulonephritis and acute renal failure.
- 

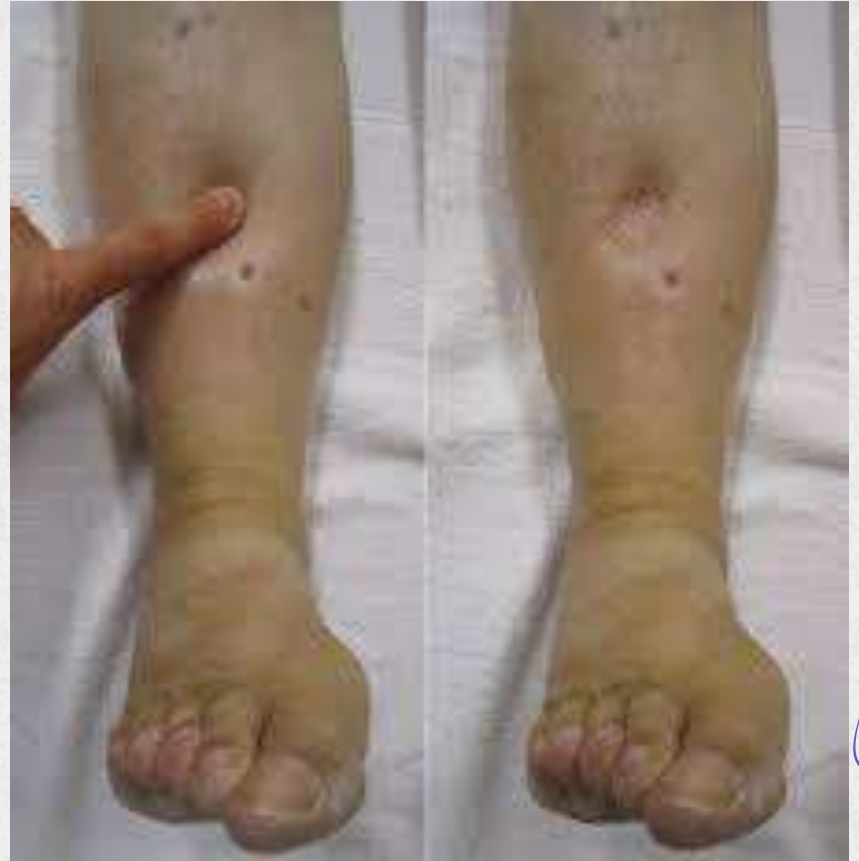

# Morphology of edema:

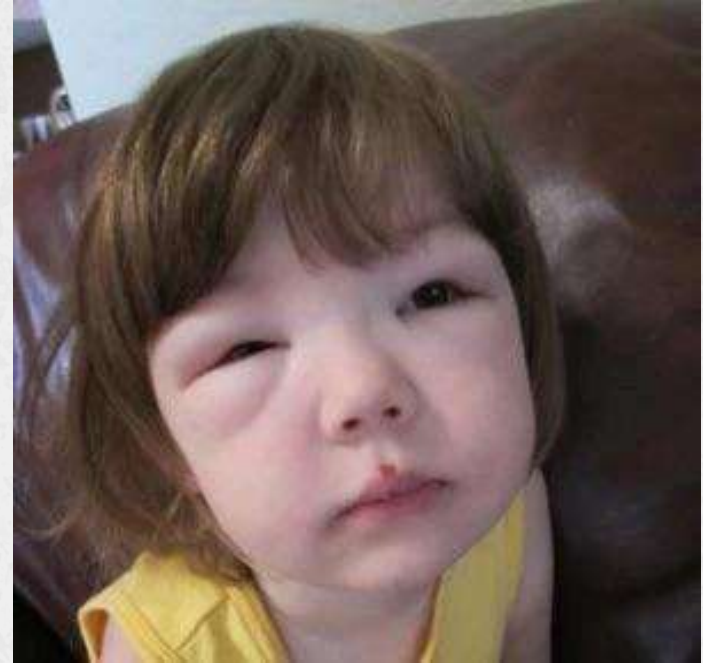- **Grossly:** Edema result in **increased in size** of affected organ.
  - **Microscopically:** it is appreciated as **clearing and separation of the extracellular matrix elements.**
  - Any organ or tissue can be involved, but edema is most commonly seen in **subcutaneous tissues, the lungs, and the brain.**
  - **Subcutaneous edema:**
    - Can be diffuse or more in regions with high hydrostatic pressures. In most cases the distribution is influenced by gravity and is termed **dependent edema** (e.g., the legs when standing, the sacrum when recumbent).
- 



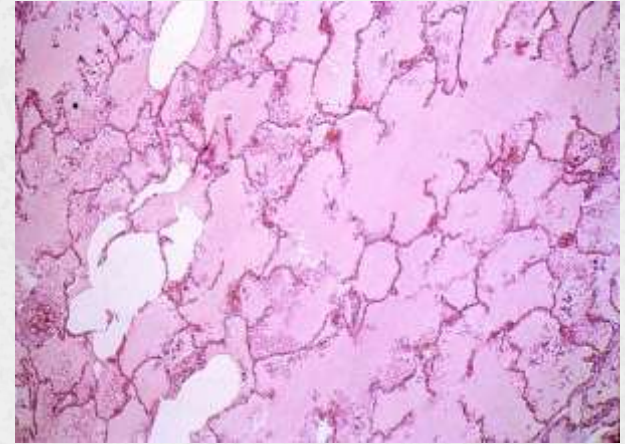
- Finger pressure over edematous subcutaneous tissue displaces the interstitial fluid and leaves a depression, a sign called **pitting edema**.



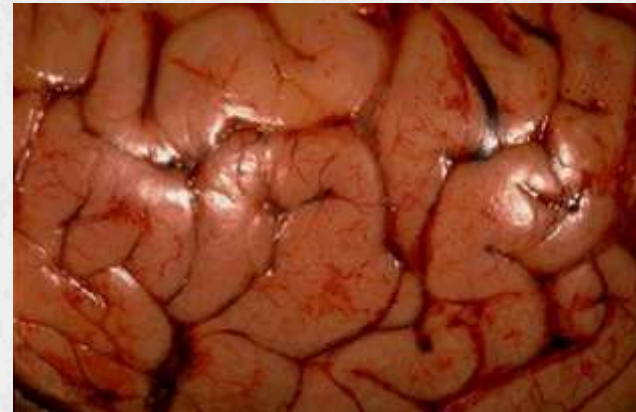
- Edema as a result of renal dysfunction can affect all parts of the body. It often initially manifests in tissues with loose connective tissue matrix, such as the eyelids; **periorbital edema** is thus a characteristic finding in severe renal disease.



- With **pulmonary edema**, the lung is 2-3 times their normal weight, cut section frothy, blood tinged fluid represent mixture of air, edematous fluid & extravasated RBCs.




- **Brain edema** can be; **localized**: due to abscess, neoplasm & trauma. Or **generalized**: due to encephalitis, hypertension crises & trauma
- **Grossly**: Swollen with narrowed sulci & distended gyri.








# Clinical correlation of edema:


- The effects of edema vary, ranging from only annoying to rapidly fatal.
  - 1. **Subcutaneous edema** in cardiac failure & renal failure can **impair wound healing or clearance of infection**.
  - 2. **Pulmonary edema** seen most frequently in the left ventricular failure, but also may occur in renal failure, acute respiratory distress syndrome and inflammatory and infectious disorders of the lung. It **can cause death** by interfering with normal ventilatory function by; **Fluid collects in alveolar space impair oxygen diffusion and represent a favorable environment for infection**.
  - 3. **Brain edema** if severe **may cause death** due to brain herniated through foramen magnum which causes compression of vital centers & also cause compression of vascular supply of brain.
- 

# Hyperemia & Congestion






# Hyperemia & Congestion

- **Both refer to an increase in blood volume within a tissue** but have different underlying mechanisms.
  - ❖ **Hyperemia**
  - It is an active process resulting from arteriolar dilation and increased blood inflow.
  - Affected tissues turn red (erythema) because of the engorgement of vessels with oxygenated blood.
  - As occurs at sites of inflammation or in exercising skeletal muscle.
- 






## Congestion

- It is a passive process resulting from impaired outflow of venous blood from a tissue.
  - It can be **systemic**, as in cardiac failure, or **local**, as in isolated venous obstruction.
  - Congested tissues have an **abnormal blue-red color (cyanosis)** resulting from the accumulation of deoxygenated hemoglobin in the affected area.
- 

# HYPERMIA AND CONGESTION

	<b>HYPEREMIA</b>	<b>CONGESTION</b>
<b>1</b>	<b>An active process</b>	<b>A passive process</b>
<b>2</b>	<b>Increased blood flow (vasodilatation)</b>	<b>Impaired venous blood outflow</b>
<b>3</b>	<b>During exercise &amp; in inflammation</b>	<b>Venous obstruction &amp; cardiac failure</b>
<b>4</b>	<b>Oxygenated blood (Affected tissues turn red)</b>	<b>Deoxygenated blood (Affected tissues turn blue- red "Cyanosed")</b>


## NORMAL



## HYPEREMIA erythema




## CONGESTION cyanosis/hypoxia





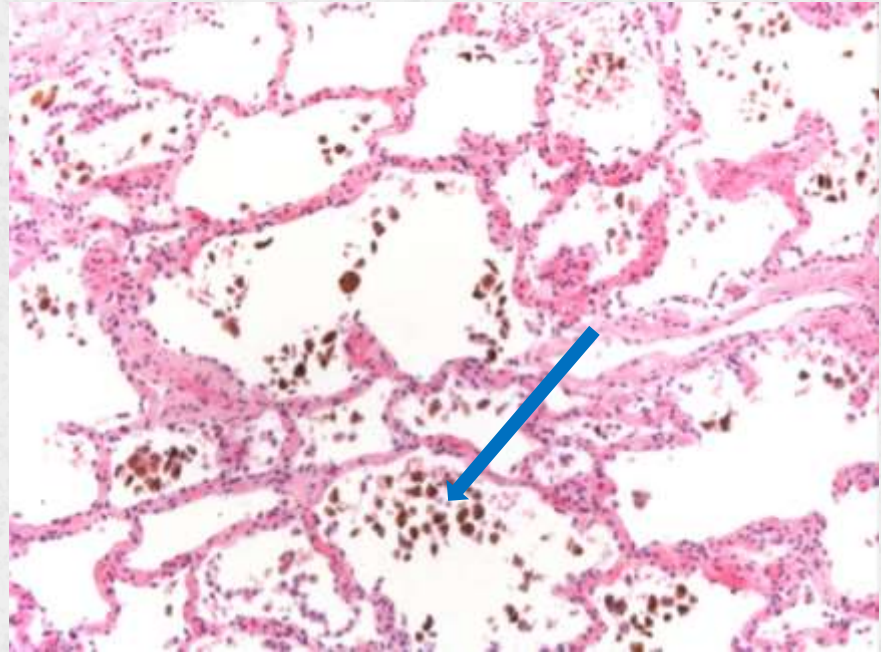




# Morphology

- **Gross;** Cut surfaces of hyperemic or congested tissues feel wet and typically ooze blood.
  - **Microscopic examination;**
    - **In acute pulmonary congestion** is marked by blood-engorged alveolar capillaries and variable degrees of alveolar septal edema and intraalveolar hemorrhage.
    - **In chronic pulmonary congestion**, (e.g. in **left ventricular failure**) the alveolar septa become thickened and fibrotic, and the alveolar spaces contain numerous macrophages laden with hemosiderin (“heart failure cells”) derived from phagocytosed red cells.
- 

# Chronic pulmonary congestion

- **Cause:** left sided heart failure
- **Mic.:** There is accumulation of blood in the surrounding **dilated capillaries** due to congestion capillaries, RBCs will escape to the alveolar space & engulfed by macrophages resulting in **hemosiderin laden macrophages** called (**heart failure cells**) which cause cough with blood stained sputum).



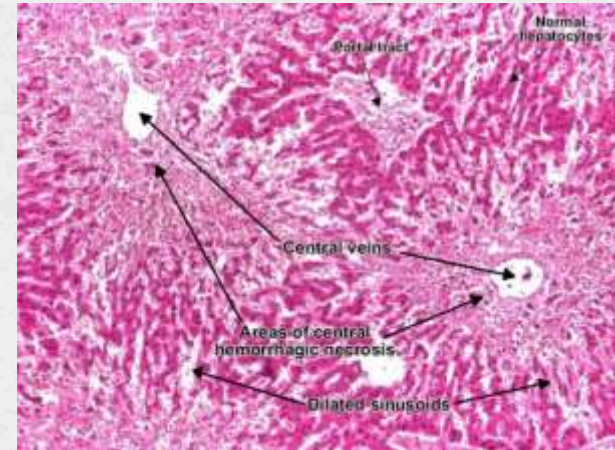
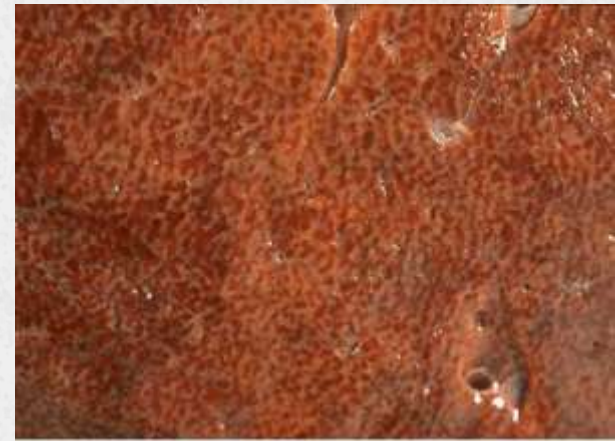
- 
- In **acute hepatic congestion**, the central vein and sinusoids are distended with blood, and there may even be necrosis of centrally located hepatocytes. The periportal hepatocytes, better oxygenated because of their proximity to hepatic arterioles, experience less severe hypoxia and may develop only reversible fatty change.
  - In **chronic passive congestion of the liver** (resulting from **right sided heart failure**).
  - **Grossly:** mottled appearance similar to the **nut meg** hence the name **Nut meg liver** (the central regions of the hepatic lobules are red-brown and slightly depressed (owing to cell loss) and are accentuated against the surrounding zones of uncongested tan, sometimes fatty liver.
  - **Microscopically:** Congestion of the central venule, necrosis of the surrounding hepatocytes because of pressure & hypoxia. The peripheral liver cells are normal or may show fatty change.
- 



# Chronic liver congestion



- Resulting from **right sided heart failure**
- **Gross**; Central areas are red and slightly depressed compared with the surrounding tan viable parenchyma, forming a “**nutmeg liver**” pattern (so-called because it resembles the cut surface of a nutmeg). **mottled appearance similar to the nutmeg (Nut meg liver)**
- **Microscopic** preparation shows centrilobular hepatic necrosis with **degenerating hepatocytes**, hemorrhage and scattered inflammatory cells.



The image features a light gray background with a fine, repeating pattern of small dots. In the top-left and bottom-right corners, there are abstract, tangled lines in red and blue, resembling stylized roots or branches. The word "Thanks" is centered in the middle of the image.

**Thanks**