

# Medical Biology

Dr. Khalida Ibrahim

## MUSCLE TISSUE

### General Characteristics:

1. Muscle tissue is characterized by its well-developed properties of contraction.
2. Muscle is responsible for the movements of the various parts of body.
3. Muscle develops from embryonic mesoderm (except for myoepithelium).

Muscle is classified into 3 categories according to morphology and physiological function:

- \* **Skeletal Muscle**
- \* **Cardiac Muscle**
- \* **Smooth Muscle**

**Specific nomenclature** associated with muscle commonly involves the prefix **sarco-** or **myo-**.

The cytoplasm of muscle fibers or cells is called **sarcoplasm**.

The endoplasmic reticulum of fibers or cells is called **sarcoplasmic reticulum**.

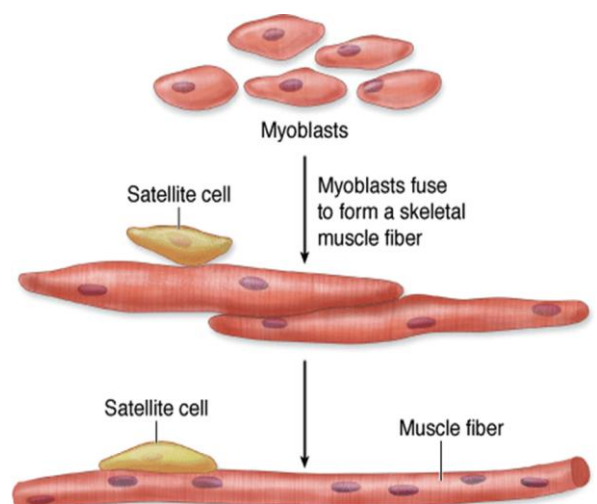
The plasmalemma of fibers or cells is called the **sarcolemma**.

Individual muscle cells are called **myocytes**.

## SKELETAL MUSCLE

**Skeletal muscle**, also known as **striated** or **voluntary muscle**, comprises 40-50% of the body mass in adults and constitutes part of the largest organ system of the body.

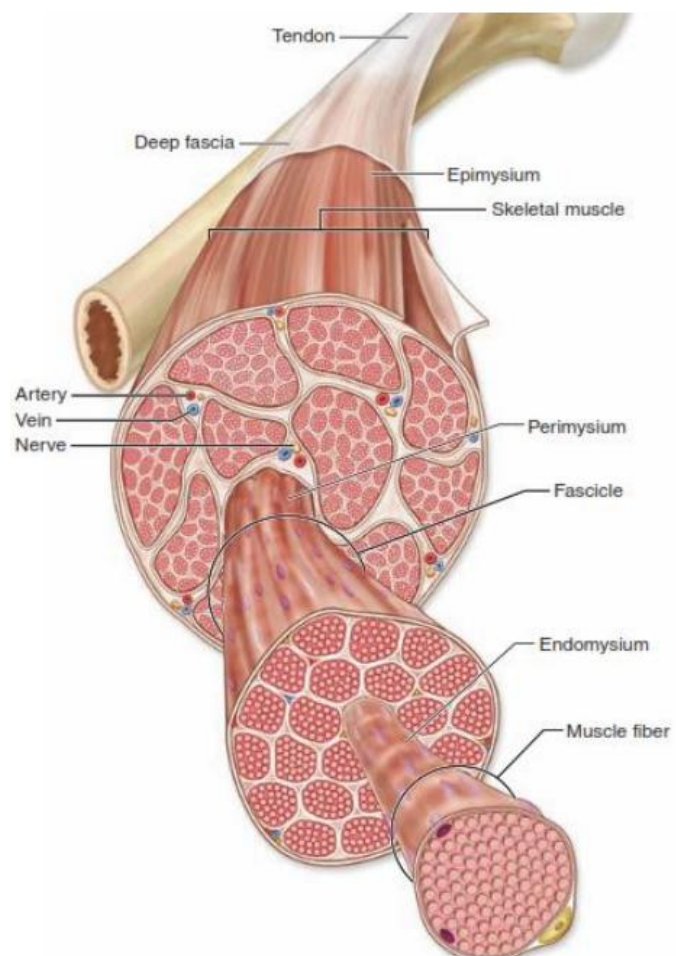
During embryonic development **mesodermal cells** differentiate into uninuclear **myoblasts**, which elongate and fuse together to form **myotubes**, which further develop into the mature muscle fibers or **myofibers**. These myofibers are the basic units of skeletal muscle and are up to 30 cm in length. Myofibers possess large numbers of elongated or oval nuclei at their periphery, close to the **sarcolemma**. These myofibers are **syncytia** (multinucleated post-mitotic structures in which the nuclei have lost the ability to synthesize DNA).



After regular staining myofibers are seen to have periodic cross striations (the source of the name "striated muscle"). A further cell-type, known as **satellite cells**, may be found adjacent to the sarcolemma, these cells developed from myoblasts that not fused and remain in endomysium. These are elongated, poorly differentiated cells that are very difficult to distinguish in typical preparations but become active during repair and regeneration processes after muscle injury.

### Connective tissue arrangements of skeletal muscles

The connective tissue in the muscle serves to bind and integrate the action of the various contractile units. A thin and delicate connective tissue layer, known as the **endomysium**, surrounds each individual myofiber. Myofibers are grouped together in bundles or **fascicles**, which are also surrounded by connective tissue, known as the **perimysium**. The fascicles are surrounded and bound together by a further connective tissue coating known as the **epimysium**. All these connective tissue coatings (endomysium, perimysium, and epimysium) contain collagen fibers, elastic fibers, fibroblasts and are richly



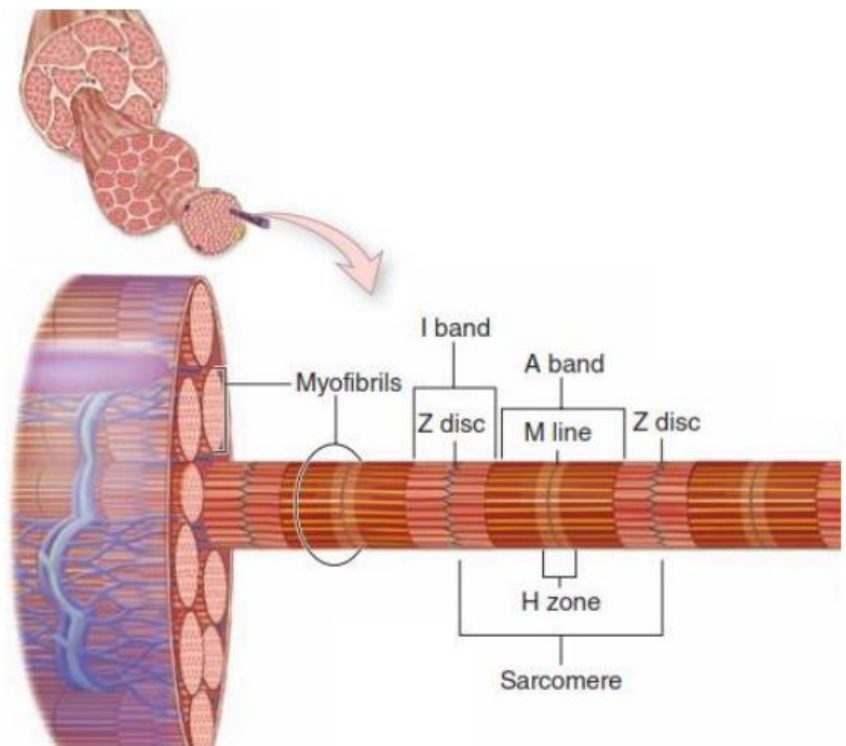
vascularized. The ends of skeletal muscles are attached to bones, cartilage, or ligaments by means of **tendons**. The attachment that moves the least is known as the tendon of origin, whereas the other tendon is known as the tendon of insertion. The flattened skeletal muscles have strong flattened sheets of tendon-like tissue at their ends known as aponeuroses.

## Light microscopy of myofibers

Longitudinal sections of skeletal muscle fibers show repeated cross-striations after regular staining (H&E). The stained bands are called **A-bands**, and in between these are non-stained **I-bands**. If the same myofiber is examined by polarizing microscopy the A-bands are seen to be **anisotropic** (bright against a dark background with crossed polars), whereas the I-bands are isotropic. (The origin of the nomenclature comes from these polarizing properties: **A** = Anisotropic, **I** = Isotropic).

At higher magnifications it is possible to see a line in the middle of the I band, known as the **Z line**.

Examination of a myofiber at high magnification shows that it is composed of many parallel **myofibrils**. The A and I bands, and Z lines are visible in the myofibrils. The unit between two Z lines is known as the **sarcomere**. The myofibrils consist of repeating strings of sarcomeres. The sarcomeres in adjacent myofibrils tend to be

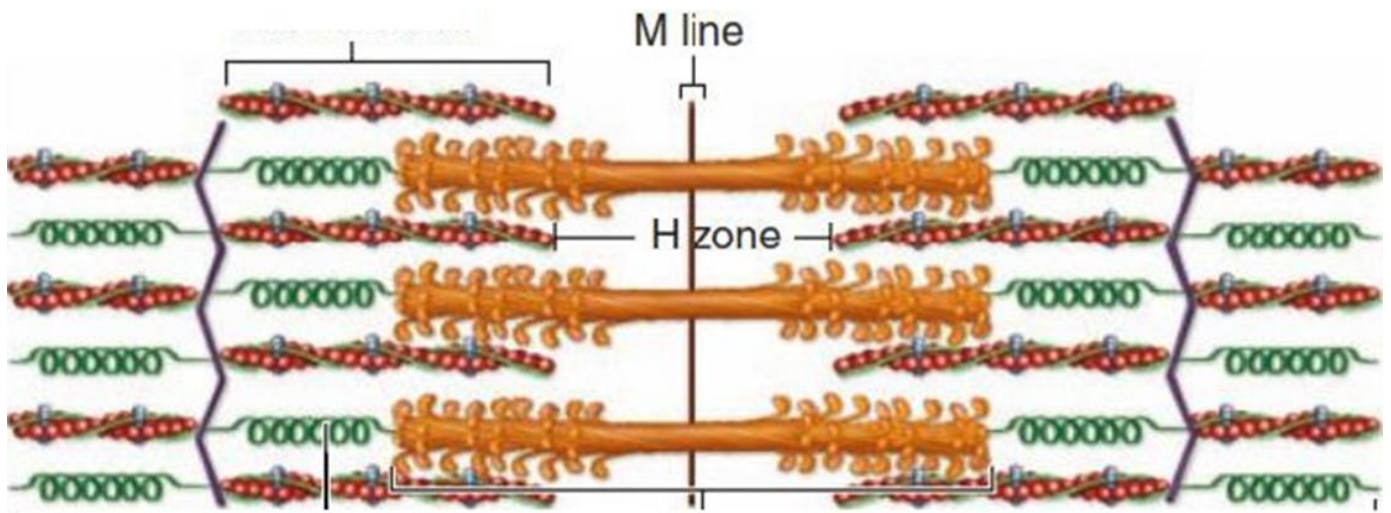


located in parallel, resulting in the overall cross-striations of the myofibers. It is also possible in some cases to distinguish a less-stained region in the middle of the A-bands, known as the **H-band** (Hensen's band).

*The sarcomeres form the basic contractile units of the fibers.*

## Ultrastructure of sarcomeres

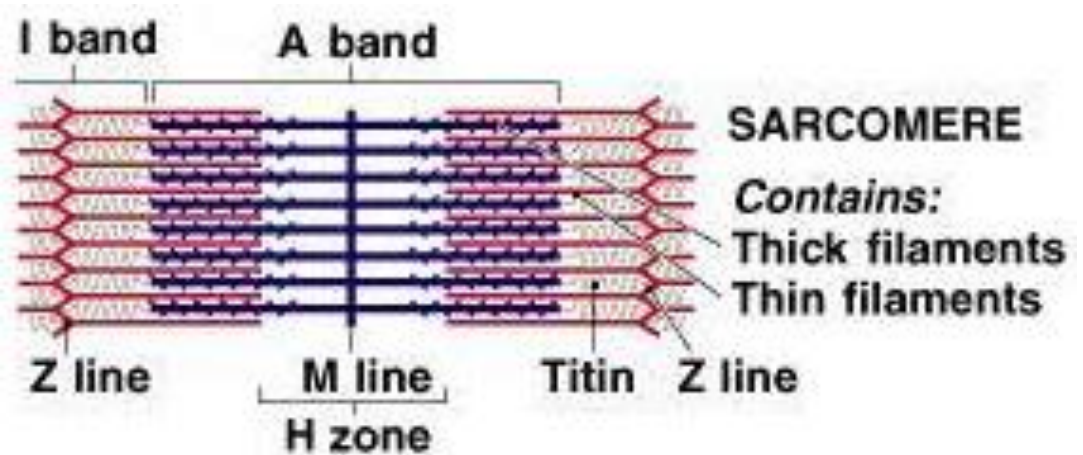
Examination of sarcomeres of myofibrils by transmission electron microscopy reveals two sorts of **myofilaments**. The thicker myofilaments belong to the A band and are composed mainly of **myosin**. The thinner myofilaments are mainly found in the I band and are composed mainly of **actin**. These thin myofilaments are connected to the Z-line and partially extend between the thicker myofilaments. This area of overlap is important in the contraction process.



## Molecular components of the myofilaments

**Thick myosin filaments** occupy the A band at the middle region of the sarcomere. Myosin is a large complex protein composing a twisted part called myosin tails & a globular projections called head of myosin. The myosin heads bind both actins, forming transient crossbridge between the thick and thin filaments, and ATP binding site. Myosin filaments are attached in the middle of the sarcomere into M line & connected to the Z disc via a large spring-like protein called **titin**.

**The thin actin filaments** run between the thick filaments; each actin monomer contains binding site for myosin. Actin filaments are anchored on the Z disc by an

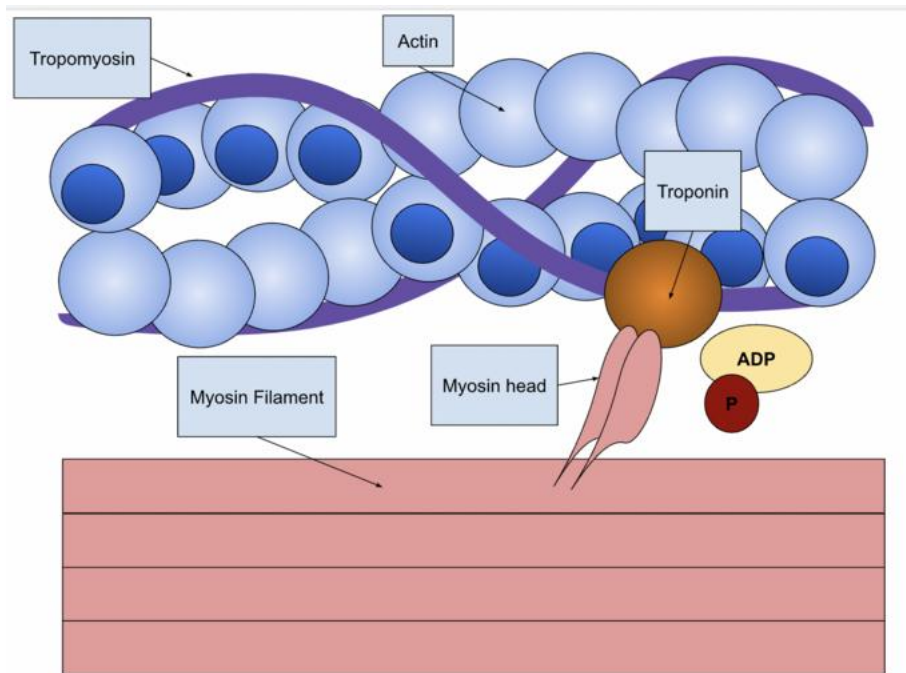


actin-binding protein called  $\alpha$ -actinin. Thin filaments (actin filaments) are associated with two regulatory proteins:

**Tropomyosin:** covers the myosin binding sites on actin.

**Troponin:** attaches to tropomyosin & has binding sites for calcium ions  $\text{Ca}^{2+}$ , through which it regulates actin-myosin interaction.



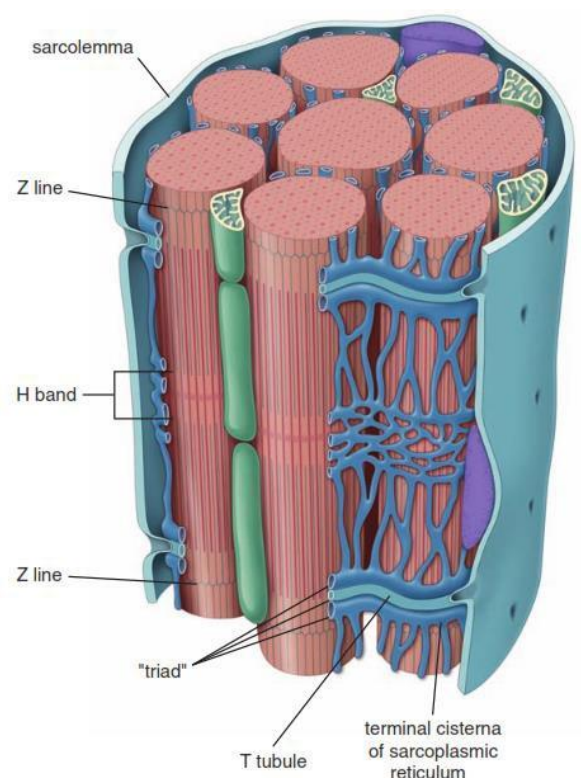


## Contraction mechanism

During muscle fiber contraction sarcomeres become shorter, the Z lines move closer to each other and the I band become less prominent. The A bands remain the same length in all phases of the contraction. The changes in the length of the sarcomere are the result of the thin myofilaments sliding or interdigitating between the thicker filaments resulting in a greater area of overlap.

## T-system of tubules

Tubular invaginations of the sarcolemma penetrate the myofibers in a transverse direction. These are known as **the T-tubules** (transverse tubules) and are found at the area of overlap between the A and I band of myofibrils. Each sarcomere has two of these tubules. The **sarcoplasmic reticulum** is a network of **sarcotubules** surrounding each myofibril. Swollen **terminal cisternae** or sacs of the sarcoplasmic reticulum are associated with the T-tubules. Two terminal cisternae are associated with each T-tubule to form structures (visible by



transmission electron microscopy) known as **triads**. The membranes of the terminal cisternae are separated from the T-tubules by gap junctions. These terminal cisternae are sites of accumulation of calcium ions during muscle relaxation and play an important role in the contraction process.

### **Other components of the sarcoplasm**

- ✱ **Glycogen** particles are found and serve as energy stores.
- ✱ Many elongated **mitochondria** are found located between the myofibrils or in accumulations just under the sarcolemma. The numbers and activities of the mitochondria are greater in muscle fibers with high metabolic activity.
- ✱ **Myoglobin** is an oxygen-binding protein that gives much of the red colour of muscle fibers.
- ✱ Relatively little rough endoplasmic reticulum or ribosomes are present in myofibers.
- ✱ In aged muscle fibers **lipofuscin** deposits (brown pigment) are common. These are now known to be large secondary lysosomes.

Prepared by Assist. Prof. Dr. Khalida I. Noel

Email: [dr.khalidanoel@uomustansiriyah.edu.iq](mailto:dr.khalidanoel@uomustansiriyah.edu.iq)