

**By the Name of ALLAH the Most Gracious the Most Merciful**



# The peritoneum, mesentery, greater omentum and retroperitoneal space Part II

د . أحمد اسامة حسن

**Specialist in General Surgery & Laparoscopic Surgery**

**8<sup>th</sup> ,October , 2025**

To be read in

**Bailey & Love's Short Practice of Surgery 28<sup>th</sup> Edition.**

**Ch 65.**

- **Abdominal Fluid Collections :**
  - Intraperitoneal collections ( Ascites ).
  - Retroperitoneal collections.
- **MESENTRY**
  - MESENTERIC TRAUMA.
  - MESENTERIC ADENITIS
  - IN CROHN'S DISEASE
  - TUBERCULOSIS OF THE MESENTERIC LYMPH NODES
  - Mesenteric panniculitis
  - Adhesions ( types , Mx, Cx ).
  - VASCULAR ABNORMALITIES OF THE MESENTERY
  - Tumours of the mesentery
    - Diffuse Fibromatosis
- **THE GREATER OMENTUM**

# Abdominal Fluid Collections

- Subdivided into:
- Intraperitoneal collections ( Ascites )
- Retroperitoneal collections. are further subdivided into :
  - Those limited to the retroperitoneal space (e.g. in pancreatitis)
  - Collections arising in relation to retroperitoneal organs such the kidney.

# Ascites

# Causes of Ascites

## Transudates (protein <25 g/L)

- Low plasma protein Concentrations
  - Malnutrition
  - Nephrotic syndrome
  - Protein-losing enteropathy
  - Cirrhosis
- High central venous pressure
  - Congestive cardiac failure
  - Constrictive pericarditis  
(Pick's disease)
  - Vena cava obstruction
- Portal hypertension
  - Portal vein thrombosis
  - Cirrhosis .
  - Budd–Chiari syndrome ( Chronic )  
(hepatic vein occlusion or thrombosis)

## Exudates (protein >25 g/L)

- Peritoneal malignancy
- Bacterial peritonitis.
- Tuberculous peritonitis
- Budd–Chiari syndrome ( Acute )  
(hepatic vein occlusion or thrombosis)
- Pancreatic ascites
- Chylous ascites
- Meigs' syndrome ( reversible )

## Ascites : Accumulation of peritoneal fluid, if there is excess production or reduced absorption.

- Peritoneal fluid is constantly secreted and absorbed.
- Production of large volumes of a protein-rich fluid occurs in peritonitis and carcinomatosis peritonei.
- Reduced absorption ( capillary pressure is increased as a result of generalised water retention, cardiac failure, constrictive pericarditis or vena cava obstruction. Capillary pressure is also raised selectively in the portal venous system in the Budd–Chiari syndrome, hepatic cirrhosis or extrahepatic portal venous obstruction.
- Plasma colloid osmotic pressure may be lowered in patients with malnutrition, diminished intestinal absorption, abnormal protein losses or defective protein synthesis ( cirrhosis)
- Peritoneal lymphatic drainage may be impaired, resulting in the accumulation of protein-rich fluid ( metastasis ).

# Examination :

- Underlying disease.
- Becomes clinically recognizable when greater than 1.5 liters of fluid is apparent (although greater volumes may be required in obese patients).
- The abdomen is distended evenly with fullness of the flanks, tense, which is dull on percussion.
- Usually, shifting dullness is present.
- But, when there is a very large accumulation of fluid, this sign is absent. In such cases, flicking the abdominal wall produces a characteristic transmitted fluid thrill on the other side of the abdomen. This is not a reliable clinical sign. In women, ascites must be differentiated from an enormous ovarian cyst.

# Investigations

- Investigation for the cause.
- Liver / Renal function tests ,cardiac function, ultrasonography and/or CT scanning .
- Ascetic aspiration or tap under imaging guidance ( Dx & Tx ) to be sent for microscopy/cytology, culture, including mycobacteria & and analysis of protein content and amylase.

# Management

- Therapeutic / Palliative.
- Portal hypertension : TIPSS.
- Dietary sodium restriction to 200 mg/day may be helpful, but diuretics are usually required (combination of spironolactone and furosemide).
- Paracentesis can be performed. Serial large volume paracentesis (4–6 L/day and up to 8 litres in one session) can be performed safely with albumin replacement and can be performed in patients with cirrhosis and deranged clotting.
- Indwelling external drain for smaller volume home paracentesis.

# Chylous ascites

- The ascitic fluid appears milky because of an excess of chylomicrons (triglycerides).
- Most of these cases are associated with malignancy (usually lymphoma).
- Other causes include cirrhosis, TB, filariasis, nephrotic syndrome, abdominal trauma (including surgery), constrictive pericarditis, sarcoidosis and congenital lymphatic abnormality.
- The prognosis is poor unless the underlying condition can be cured.
- In addition to other measures used to treat ascites, patients should be placed on a fat-free diet with medium-chain triglyceride supplements.
- Trauma to thoracic duct ( microsurgery ).

# The Mesentery

# GENERAL CONSIDERATIONS

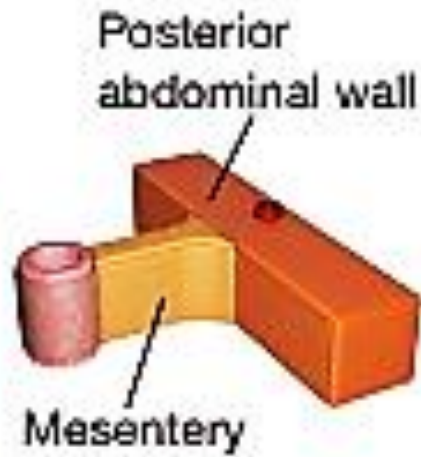
- The mesentery comprises adipose, connective tissue, neurological, lymphatic and vascular components. Abnormalities can arise in any of these and lead to either solid (tumour deposits, lymphatic metastases) or cystic lesions.
- The supportive capacity of the mesentery is reflected in the finding of splenunculi, heterotopic pancreas, calcifications, teratomas and even ectopic pregnancies in different regions of the mesentery.

# MESENTERY and PERITONEUM

(a)



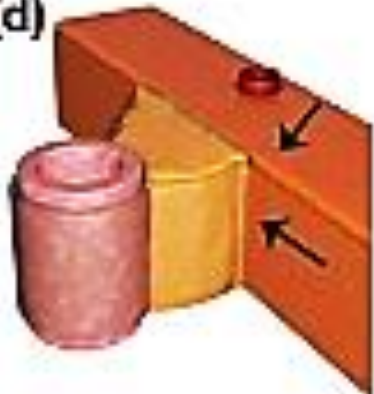
(b)



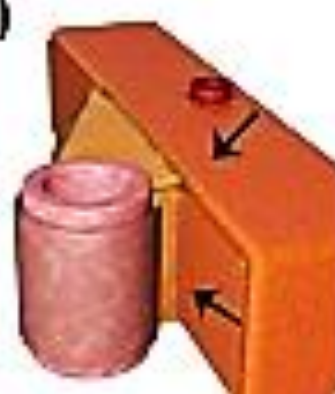(c)



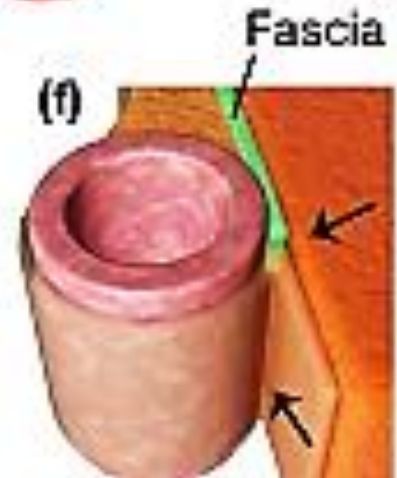
(d)



(e)



(f)



- Mesentery (lined on either side by a sheet of mesothelial cells, enclosing blood supply of the viscera ).
- Omentum ((lined on either side by a sheet of mesothelial cells, enclosing fat deposition ( Greater & Lesser )).
- Failure of **switch** formation occurs in malrotation (**Rotational disorders**) .
- Incomplete **adhesion** of the mid-region fold is associated with increased **mobility** of the ileocaecal region and volvulus (see **Volvulus of the intestine and adjoining mesentery**).

# Mobility

- The small intestinal region of mesentery, transverse mesocolon and lateral mesosigmoidal mesentery are **not adherent** and thus are mobile.
- The dorsal mesogastrium, mesoduodenum, right and left mesocolon and mesorectum are anchored (**adherent**) to the subjacent abdominal wall (or pelvic side wall).

# Vascular Supply

- The arterial inflow to the mesenteric domain is limited to the **coeliac trunk** and **superior** and **inferior mesenteric** arteries.
- The venous drainage of the mesenteric domain occurs via the hepatic veins at the junction of these and the inferior vena cava ( **portal vein** ).
- In between the arterial inflow and venous drainage, the vasculature of the abdominal digestive organs is entirely intramesenteric and aligned with the mesenteric regional anatomy.
- The limited routes of arterial inflow and venous drainage have significant implications when these are affected by pathology (discussed in Vascular abnormalities of the mesentery).

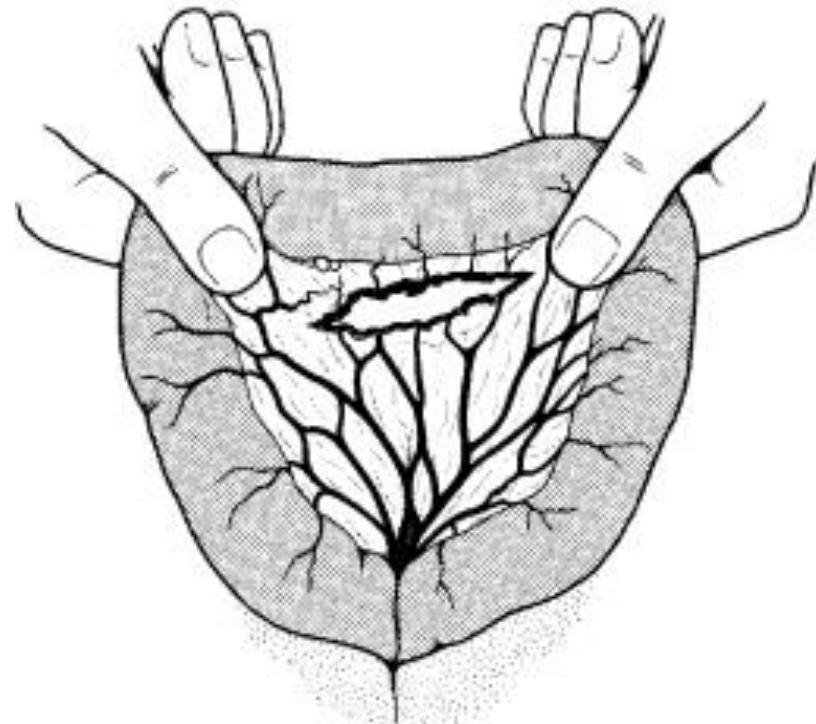
# Mesenteric Trauma :

- 1) Mesenteric tear
- 2) Mesenteric haematoma

## Mesenteric tear

Two patterns :

- 1) Longitudinal tear : Needs for suturing the edges for hemostasis and preventing internal hernia.
- 2) Horizontal tear : Assessment of bowel viability with excision of the ischemic part.



This mesenteric tear will result in an ischaemic segment of small bowel.

# MESENTERIC HAEMATOMA

can follow

- Abdominal compression in trauma (e.g. seat-belt syndrome)
- During abdominal surgery, when the mesentery must be manipulated.
- A haematoma may form and quickly enlarge to compress mesenteric veins.

# MESENTERIC ADENITIS

- It mostly occurs in the ileocaecal region because of the volume of lymphatic tissue.
- It is often the site of viral or infective lymphadenopathy (Yersinia spp., Campylobacter spp., Mycobacterium tuberculosis) and may follow an upper respiratory tract infection with either a viral or bacterial pathogen.
- Severe acute respiratory syndrome coronavirus 2 (SARS-CoV-2) is not uncommon.
- The patient is frequently pyretic (often the temperature is markedly elevated) and may have enlarged cervical lymph nodes.

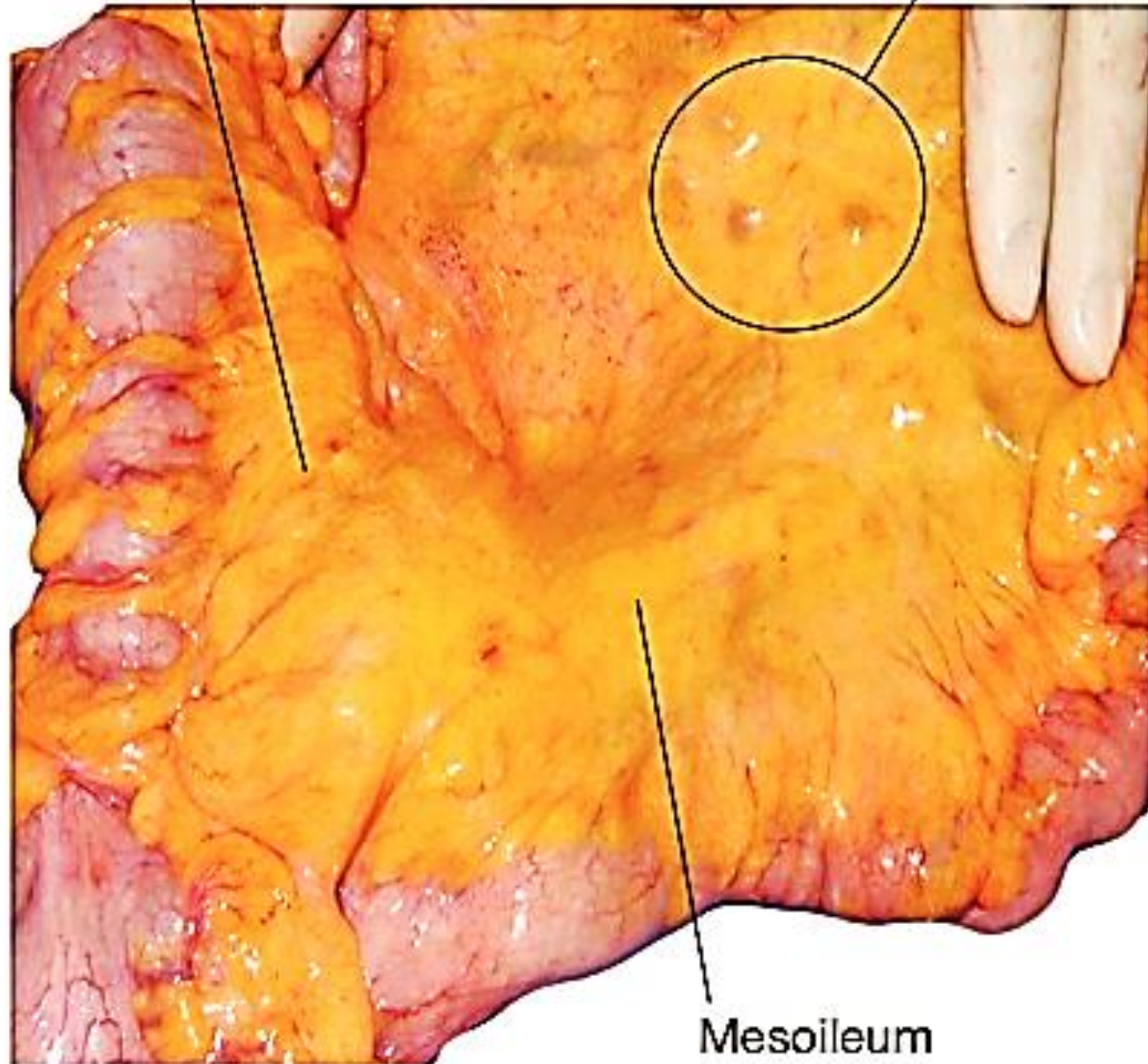
- During childhood, acute, non-specific mesenteric adenitis is a common condition. The typical history is one of short attacks of central abdominal pain lasting from 10 to 30 minutes, commonly associated with vomiting.
- The patient seldom looks ill. In more than half of the cases the temperature is elevated. Abdominal tenderness is poorly localised and, when present, shifting tenderness ( move to other side ) is a valuable sign for differentiating the condition from appendicitis. The neck, axillae and groins should be palpated for enlarged lymph nodes.

(Looking for tonsillitis ).

**DDx : acute appendicitis**

Right,  
mesocolon.

Mesenteric  
adenitis.



## Investigation

- There is often a leukocytosis of 10 000–12 000/ $\mu$ L or more on the first day of the attack, but this falls on the second day.
- Ultrasonography may be helpful in differentiating this from appendicitis.
- Sometimes a CT or exploratory laparoscopy is required.

## Treatment

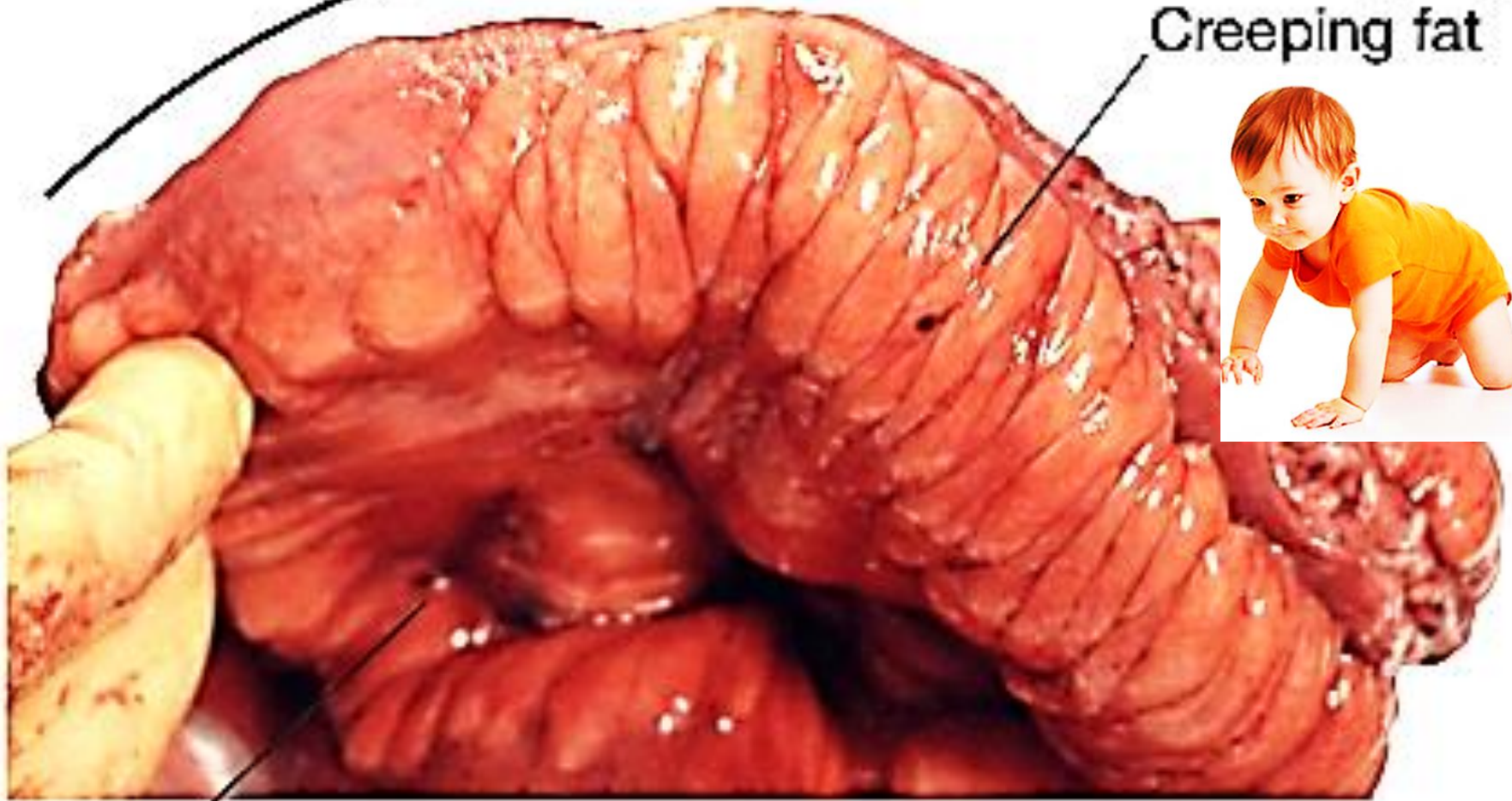
- This is normally supportive.
- Viral mesenteric adenitis normally resolves spontaneously but can recur.
- In bacterial mesenteric adenitis include cramping pain, vomiting and diarrhoea. They can be severe and require hospitalisation.

# MESENTERIC ADENITIS AND THE MESENTERY IN CROHN'S DISEASE

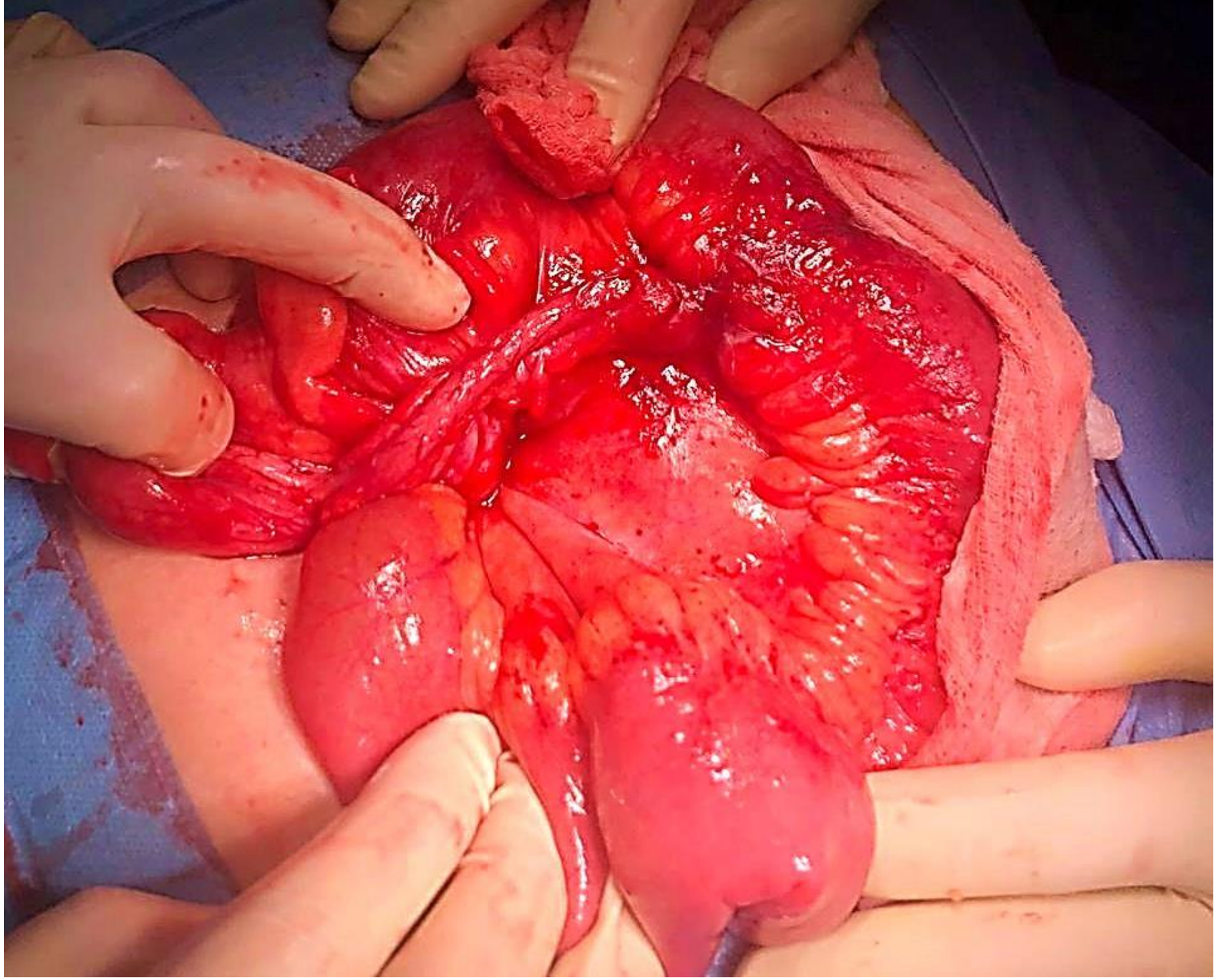
- Ileocaecal mesenteric adenitis occurs in ileocolic Crohn's disease and the mesentery is thickened, shortened and oedematous with a tendency to bleed if handled. The mesenteric vascular pedicles may not be apparent, thus great care is needed when dividing the mesentery as normal techniques may not be suitable.
- Specifically the mesentery can extend over adjoining intestine as 'fat wrapping' or 'creeping fat' .
- There is mesenteric transition zone. ( surgical excision would be at its intersection with adjoining mesentery ).

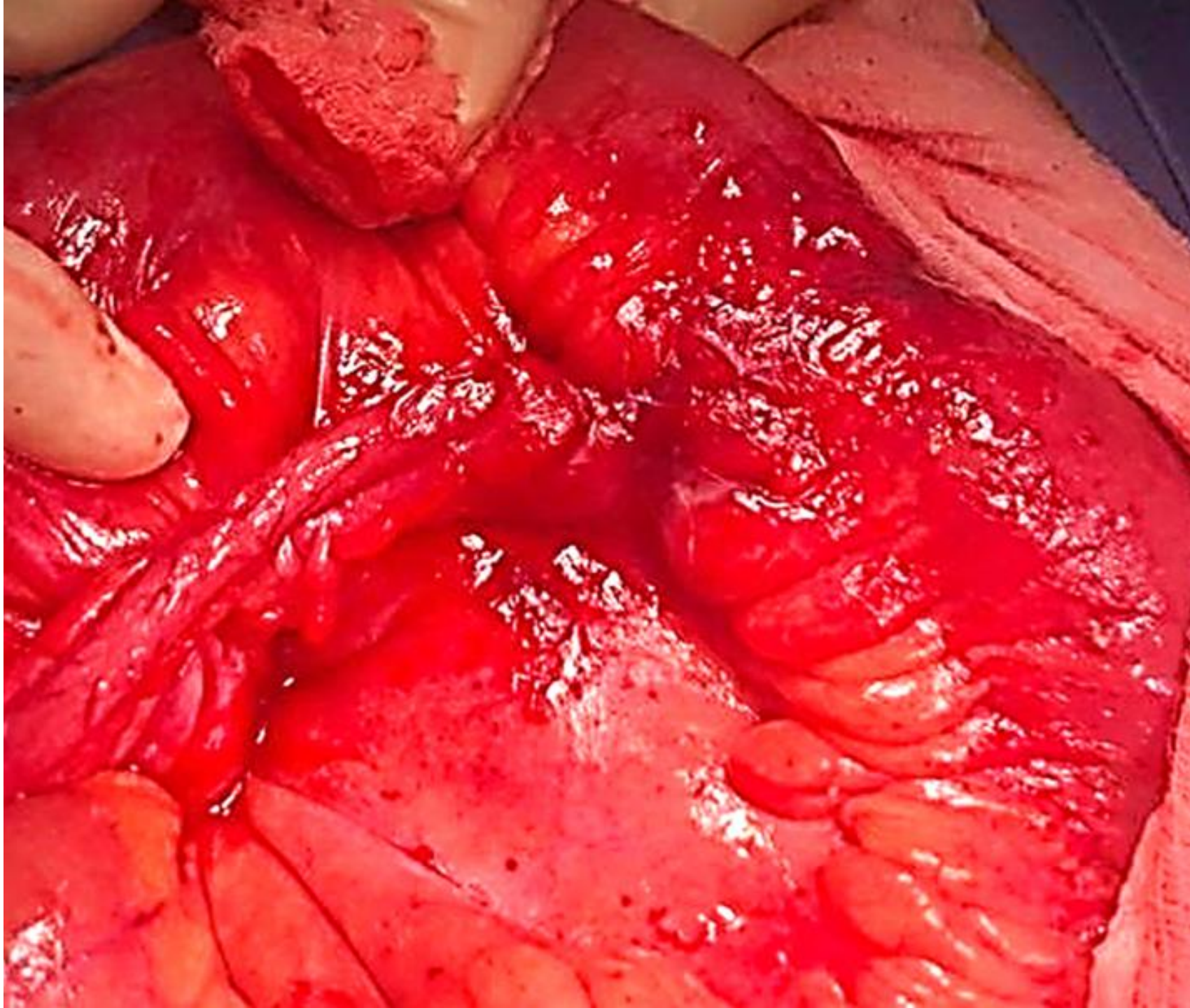
Mesenteric transition zone

Fat wrapping  
Creeping fat



Normal mesentery



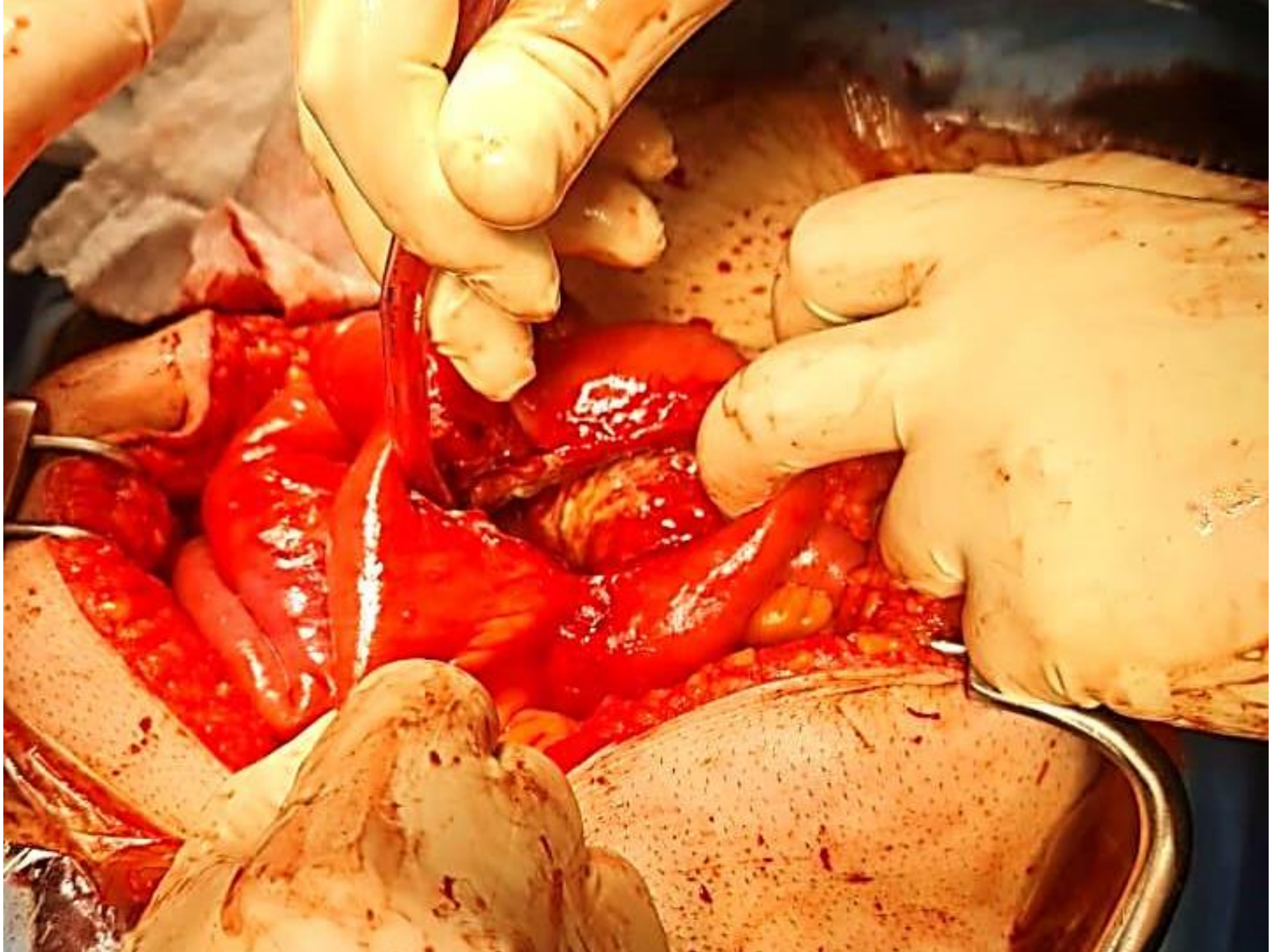


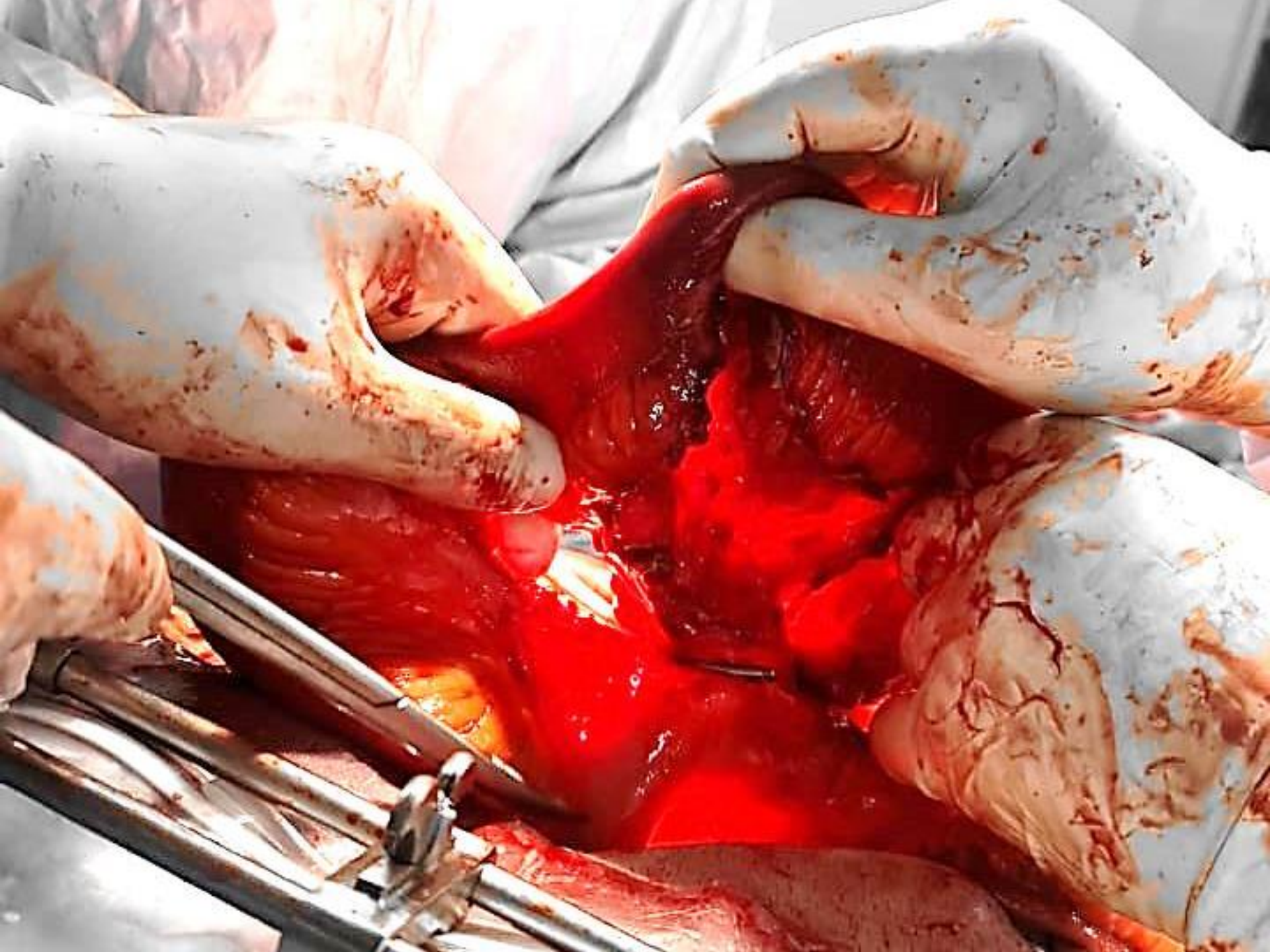
# TUBERCULOSIS OF THE MESENTERIC LYMPH NODES

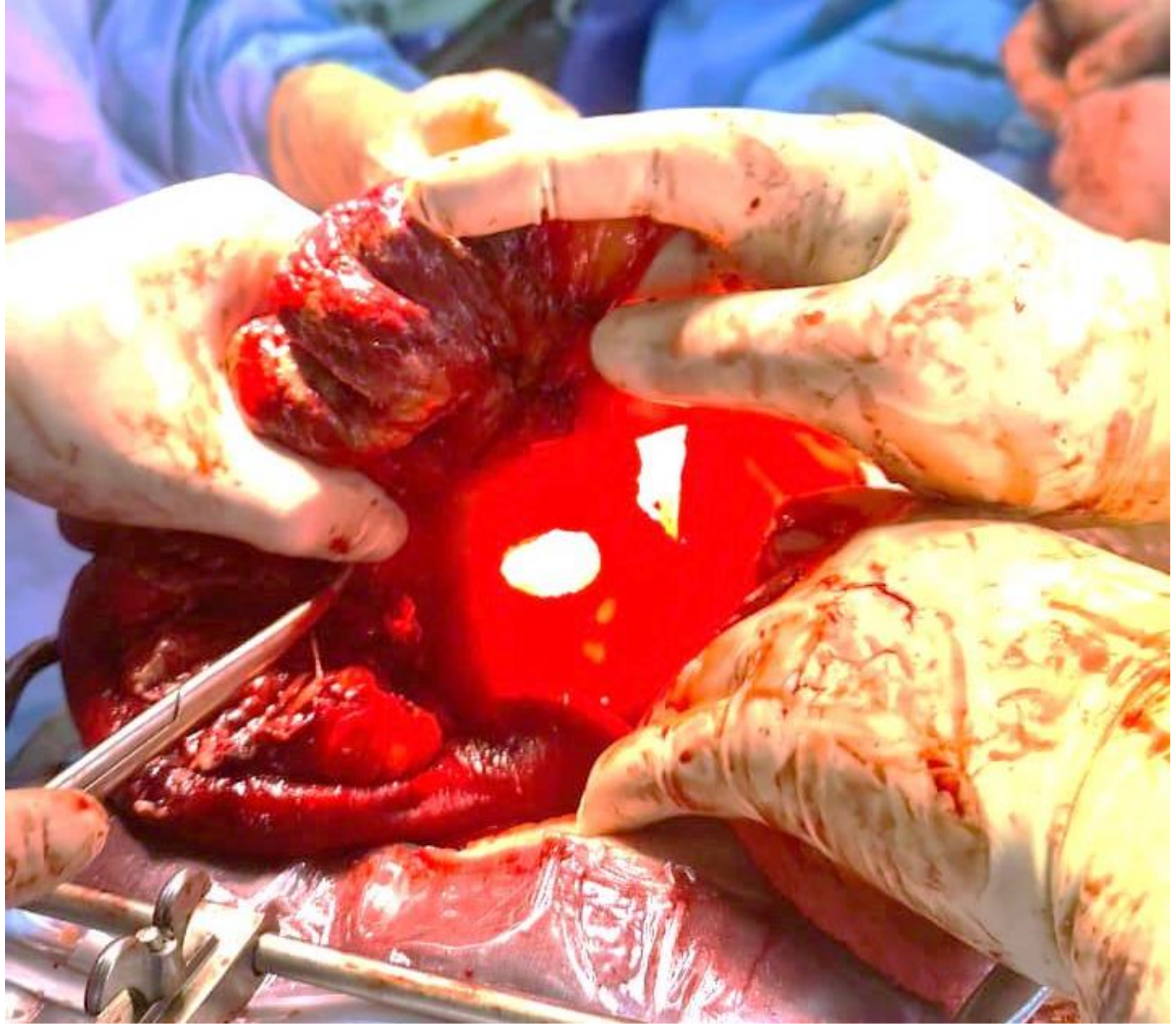
- Is considerably less common than acute non-specific lymphadenitis.
- Usually, but not necessarily, bovine in origin, are ingested and enter the mesenteric lymph nodes by way of Peyer's patches (rupture/ perforation ( H ) . .
- Usually there are several, and occasionally massive involvement occurs. May be Calcified that can be demonstrated on a plain radiograph of the abdomen, DDX ( renal or ureteric stones ) .
- The presentation may be with abdominal pain (a rare differential for appendicitis) or with general constitutional symptoms (pyrexia, weight loss, etc.).
- Ix : CBP, ESR,CRP, CXR, Sputum ( C+S ).
- Rx : Anti TB.

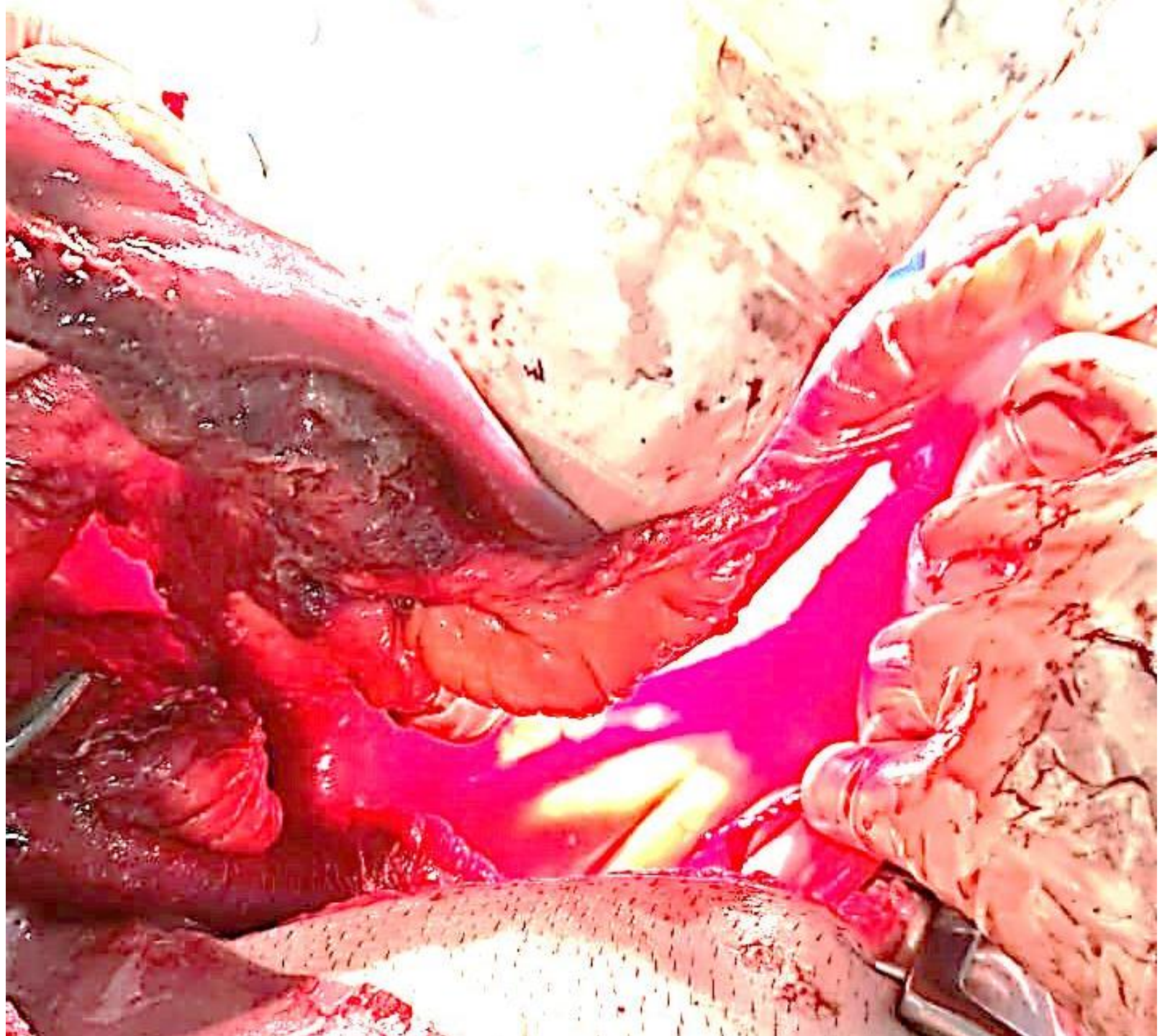
# Mesenteric panniculitis

- This is inflammation of the mesodermal mesentery (i.e. the mesenteric stroma).
- It is always present in Crohn's disease (**Mesenteric adenitis and the mesentery in Crohn's disease**).
- Often it is an incidental finding on cross-sectional imaging of the abdomen by CT ('misty mesentery' ( fat stranding ) ).
- It can arise secondary to inflammation in any digestive organ. It is associated with connective tissue disorders (including Weber– Christian disease).
- Treatment is normally medical and surgery is rarely required. Serial CT scanning is indicated to ensure resolution.







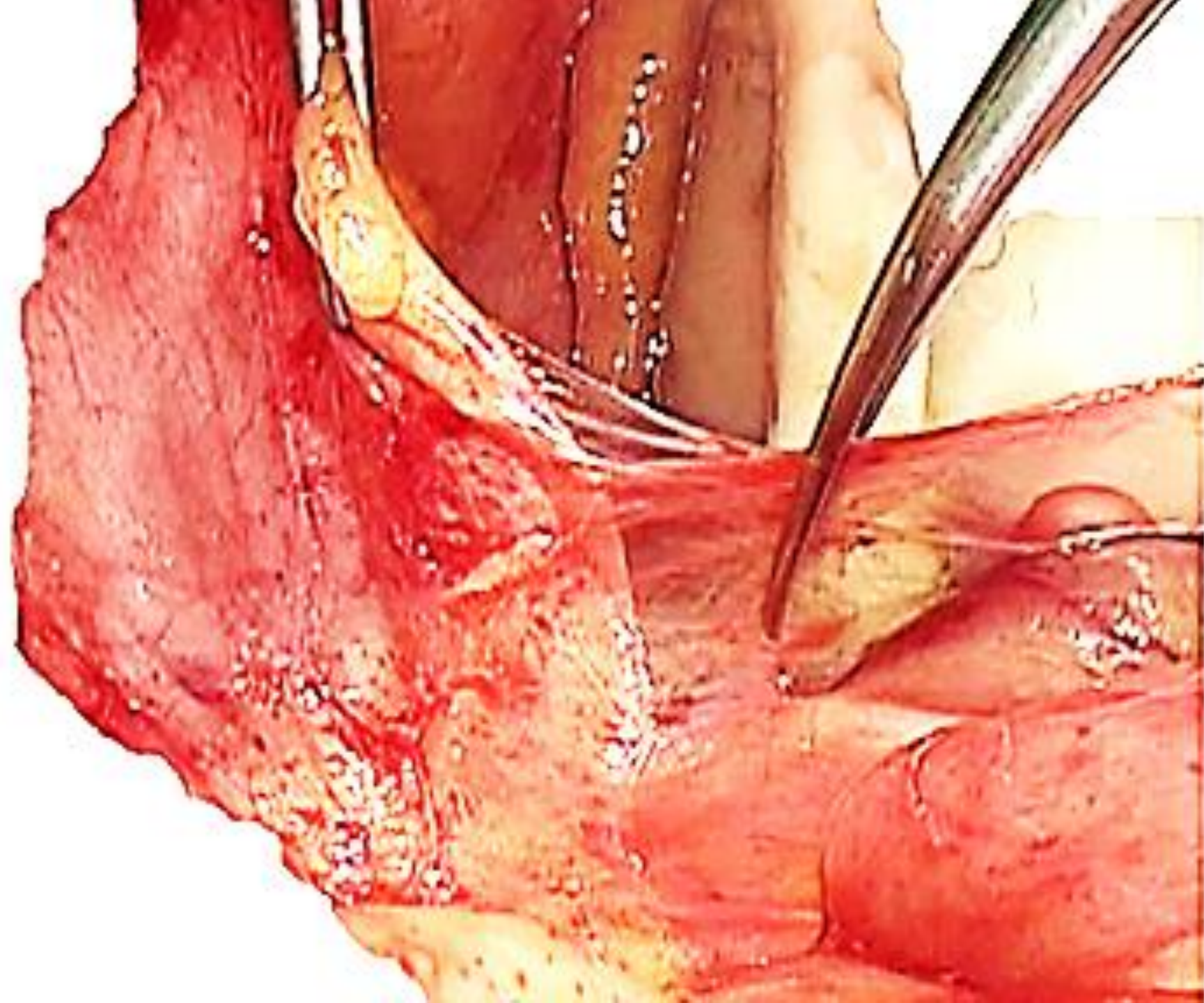


# Adhesions

- Peritoneal (sclerotic) adhesions
- Areolar adhesions.
- Dense adhesions.

# Peritoneal (sclerotic) adhesions

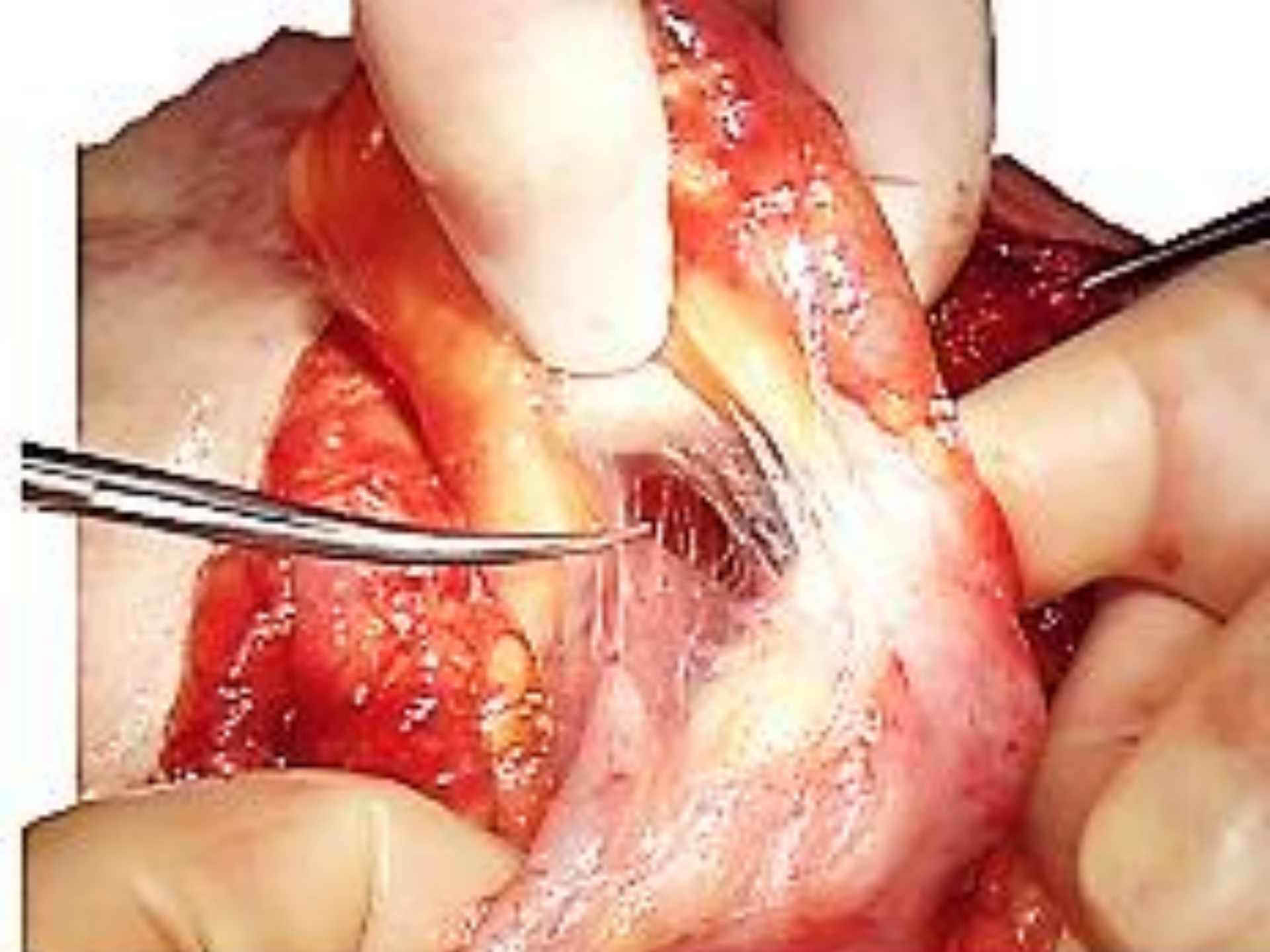- These are mesothelial adhesions between two mesothelial surfaces .They reflect mesothelial proliferation, resemble peritoneum and are generally soft and non-vascular.
- These can be band-like linking a viscus . They may occur following laparoscopic surgery, .
- Band adhesions can lead to focal abdominal pain, internal herniation (through the window created with surrounding related structures) or intestinal torsion around the band.



# Areolar adhesions

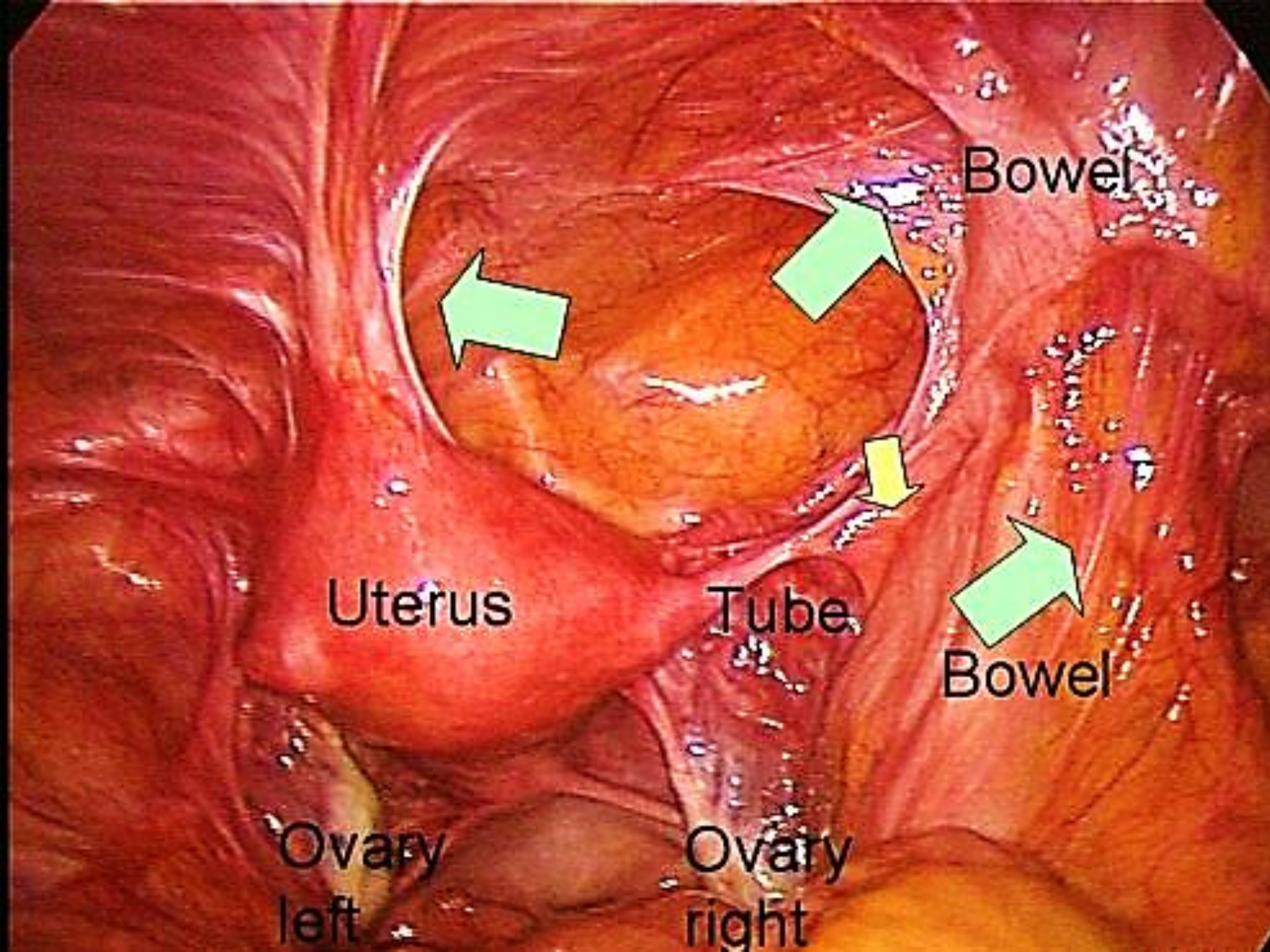


- These flimsy connective tissue adhesions are identical to the connective tissue that fills the retroperitoneal space between the mesentery and posterior abdominal wall .
- Given this appearance they have been called ‘angel hairs’.
- In the most extremes cases, the peritoneal cavity may be obliterated or limited to small pockets at the flanks. This generates considerable technical challenges during reoperative surgery.



## Dense adhesions

- Following severe intraperitoneal contamination (e.g. after perforation)
- They can bridge the abdominal wall and intestine, or intestine and mesentery, and lead to fusion of the bridged structures.
- Surgical division can be challenging. Sometimes it is not possible to separate conjoined organs without disrupting the integrity of one of them.



Bowel

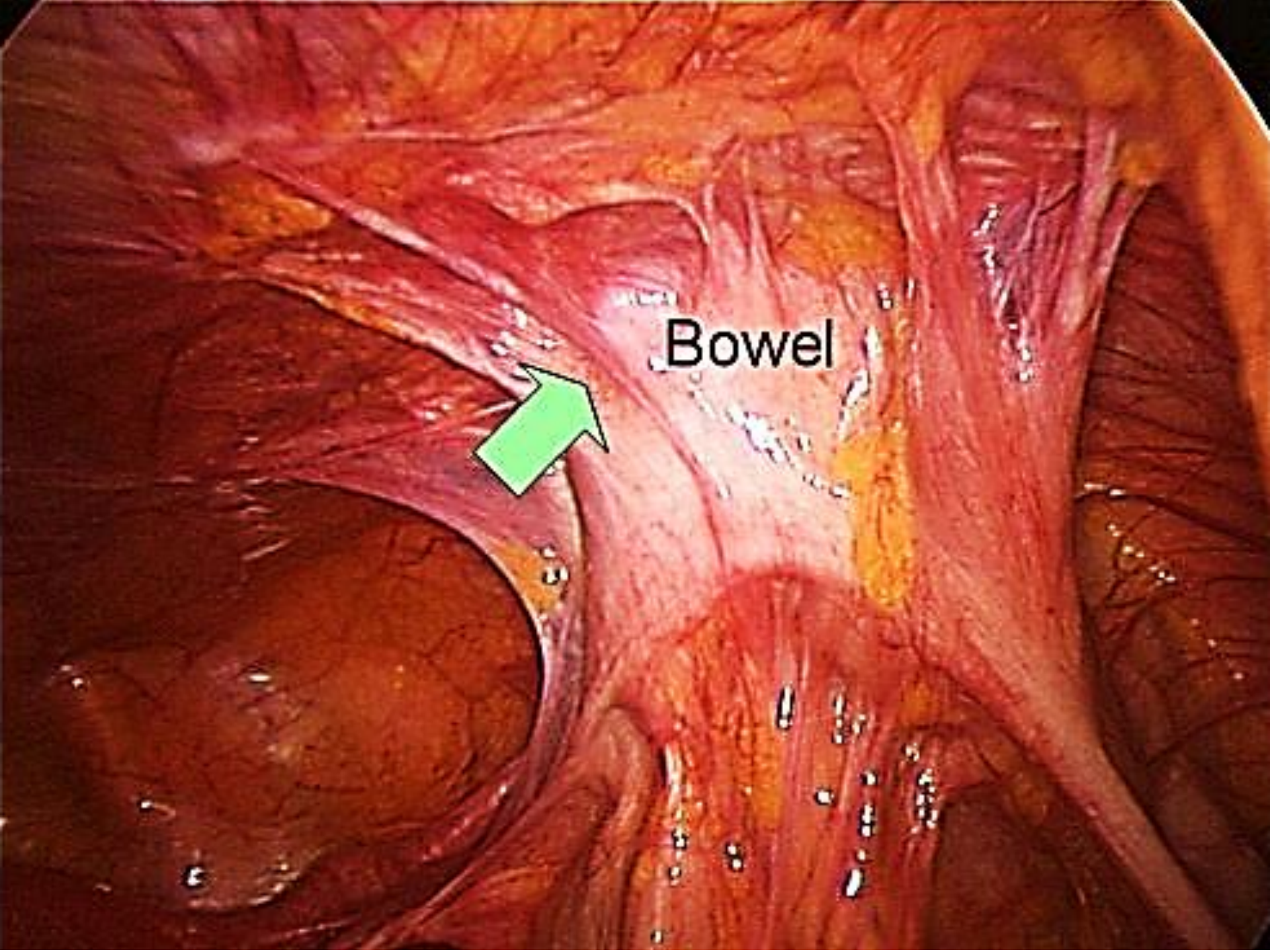
Uterus

Tube

Bowel

Ovary  
left

Ovary  
right



Bowel

# Complications of adhesions

- The most is small bowel obstruction (SBO). (Chapter 74). ( vomiting, abdominal pain, abdominal distension & constipation).
- As a major cause of secondary infertility (Chapter 87).
- Treatment : Guided division of adhesions ( adhesolysis )
- To date, no agent or mechanism has been identified that reliably reduces adhesion formation.

# Management in SBO

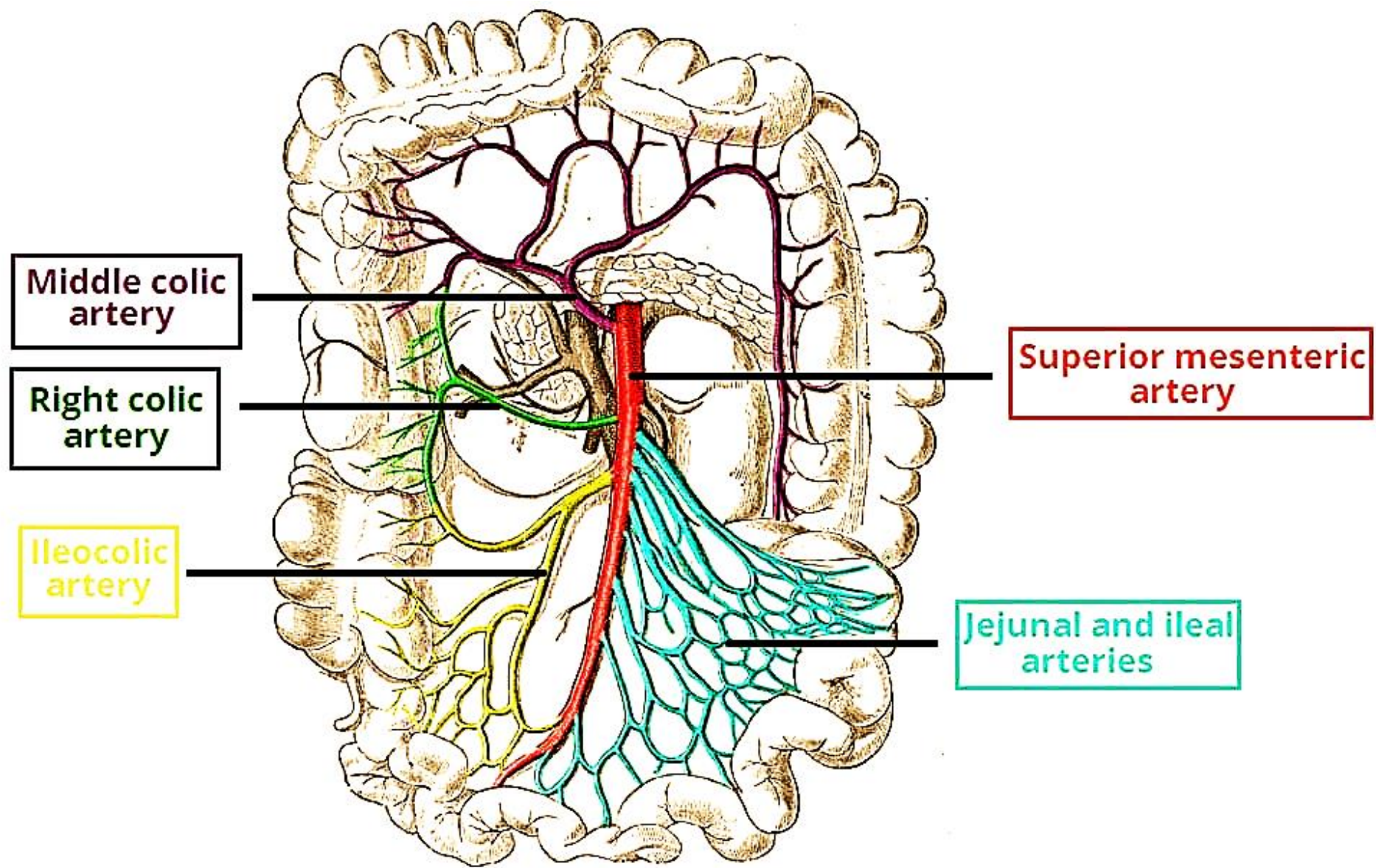
- Conservative.
  - Rehydration & electrolyte balance.
  - NG tube & Foley's catheter.
  - Antibiotics.
- Surgery ( > 72 hours ) :Adhesolysis.

# VASCULAR ABNORMALITIES OF THE MESENTERY

- Acute mesenteric ischaemia .
- Chronic mesenteric ischaemia
- Venous Thrombosis.

# Acute Mesenteric Ischaemia

- Three major vessels: the coeliac trunk and the superior and inferior mesenteric arteries.
- However, anastomoses between peripheral branches of the SMA and IMA, referred to as the marginal artery of Drummond, usually prevent critical ischaemia of the sigmoid and descending colon.
- Occlusive : Embolism (AF) : leads to ischaemia and necrosis of most of the intestine.
- Non occlusive ( spasmodic).



**Middle colic artery**

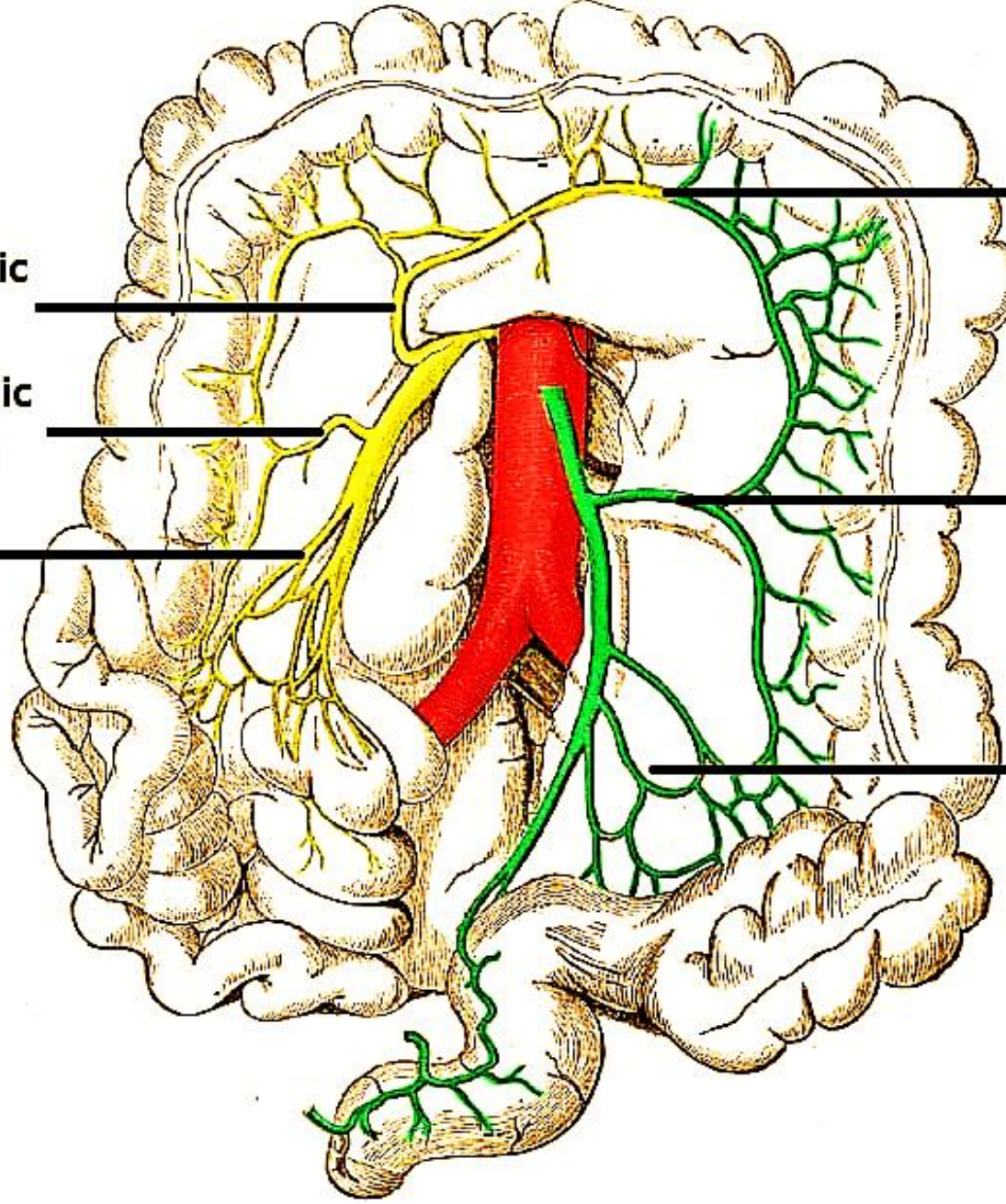
**Right colic artery**

**Ileocolic artery**

**Marginal artery**

**Left colic artery**

**Sigmoid arteries**



- At first, the severity of abdominal pain does not match clinical findings on examination. If ischaemia and necrosis occur, the patient develops peritonism as a result of irritation of the parietal peritoneum by the necrotic intestine.
- If ischaemia is limited to the mucosa, the patient may experience cramping suprapubic pain and diarrhoea that normally settles. If ischaemia is transmural the colon may become necrotic and require resection.
- Abdominal CT scan with angiography.
- Resuscitation .
- Surgical excision of the necrotized bowel.

# Chronic Mesenteric Ischaemia

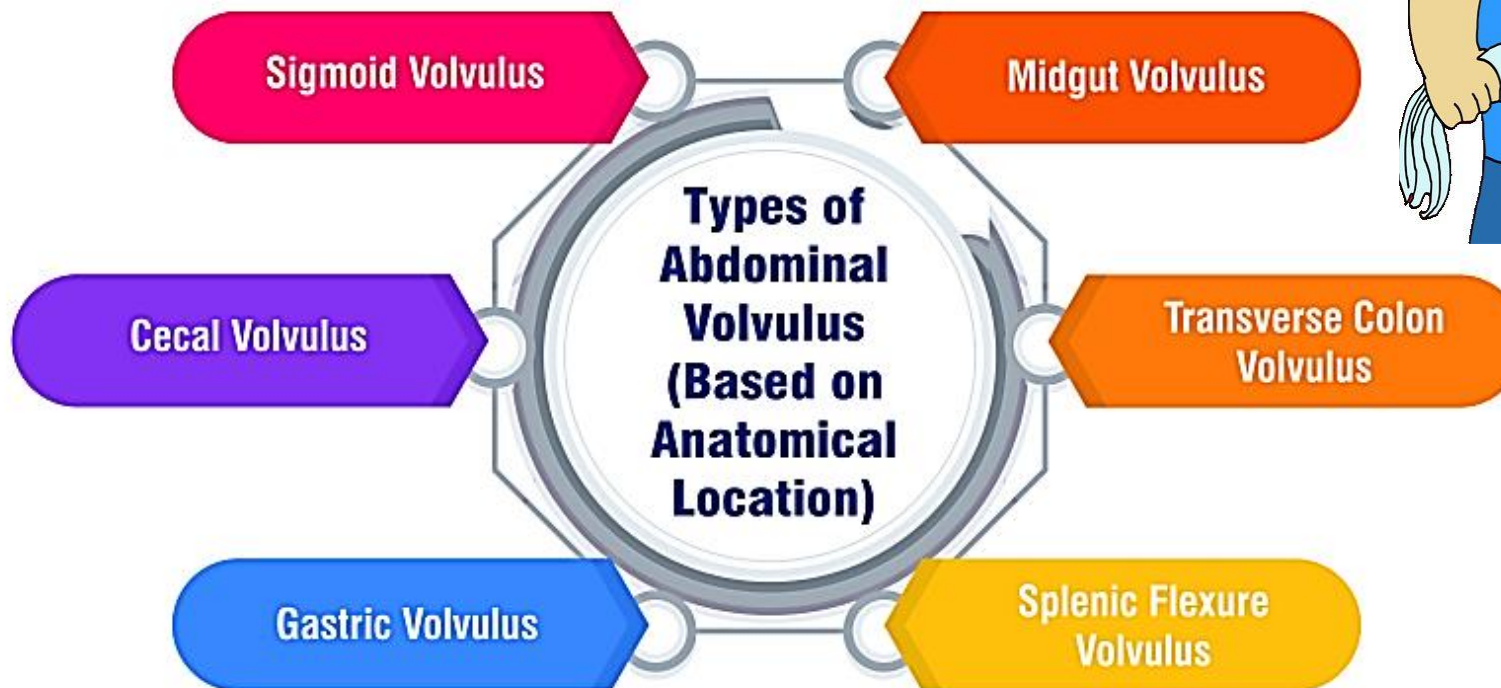
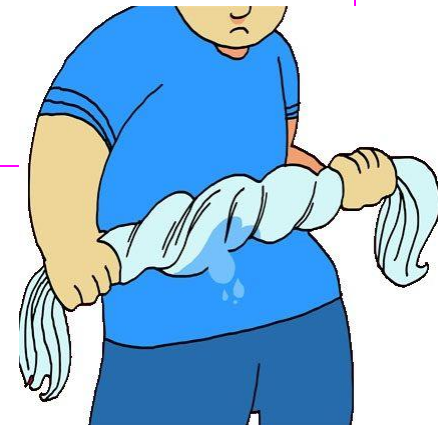- Is due to atherosclerotic narrowing at the origin of any of the three arterial trunks.
- Presentation : postprandial abdominal pain that can be severe, resulting in a fear of eating with progressive weight loss.
- The diagnosis requires CT angiography. Radiological stent placement may be successful, but surgical endarterectomy or bypass repair may be required.

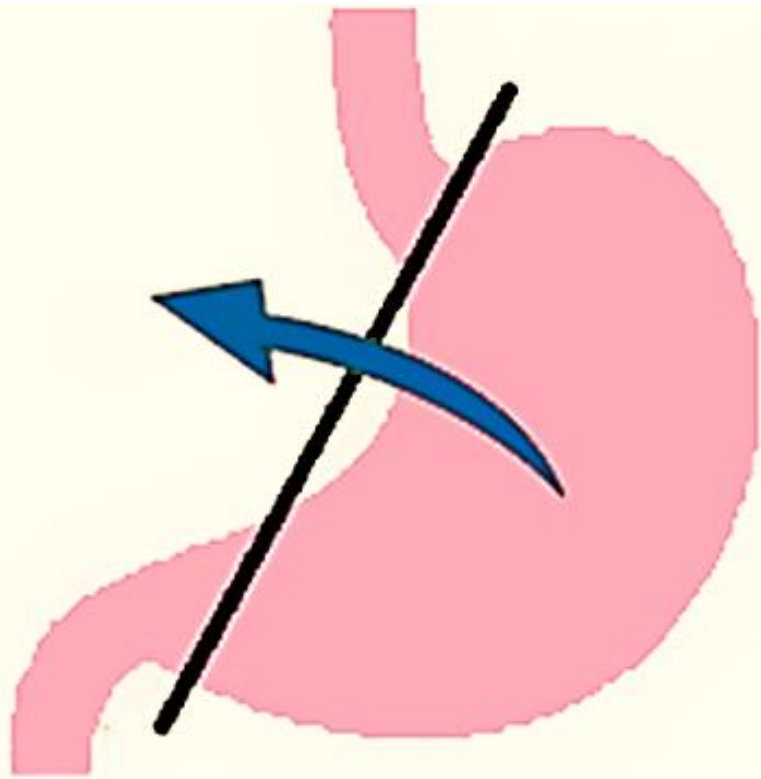
# Venous Thrombosis

- The venous drainage of the mesenteric domain is limited to the junction between the hepatic veins and the inferior vena cava (portal vein) organs , so an alternative drainage route opens (i.e. a portosystemic shunt) or is created .
- Narrowing or blockage of the lumen at this junction occurs in Budd–Chiari syndrome. It has major clinical implications.
- Portal venous thrombosis impedes venous drainage of all abdominal digestive organs unless an alternative drainage route opens (i.e. a portosystemic shunt) or is created by surgery.

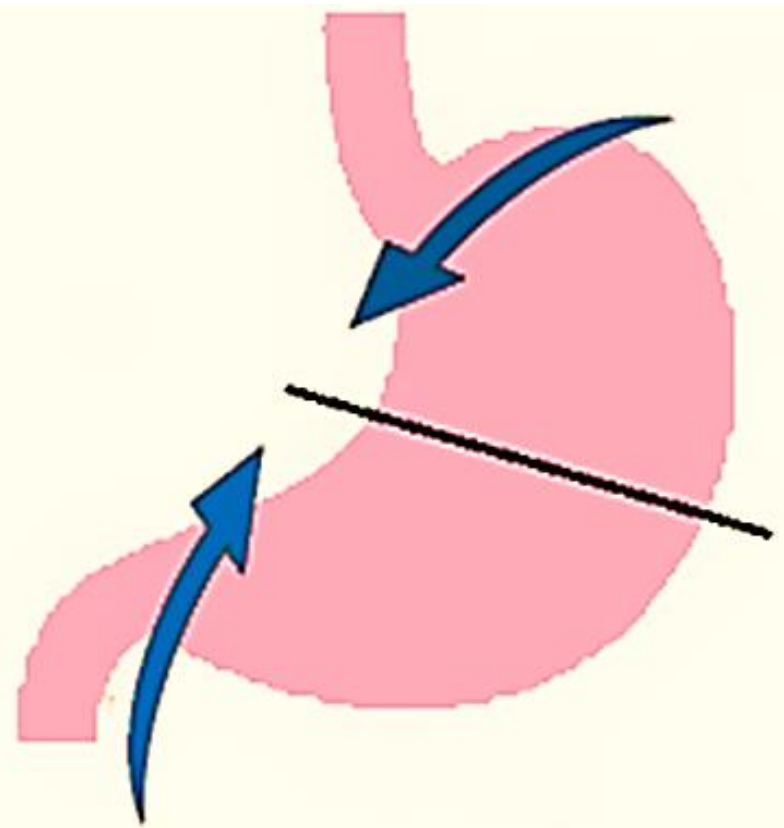
# ROTATIONAL DISORDERS

- Malrotation .( pediatric surgery )
- Volvulus of the intestine and adjoining mesentery .
  - Neonate .( pediatric surgery )
  - Adult ( aquired ): P/W GIT obstruction.

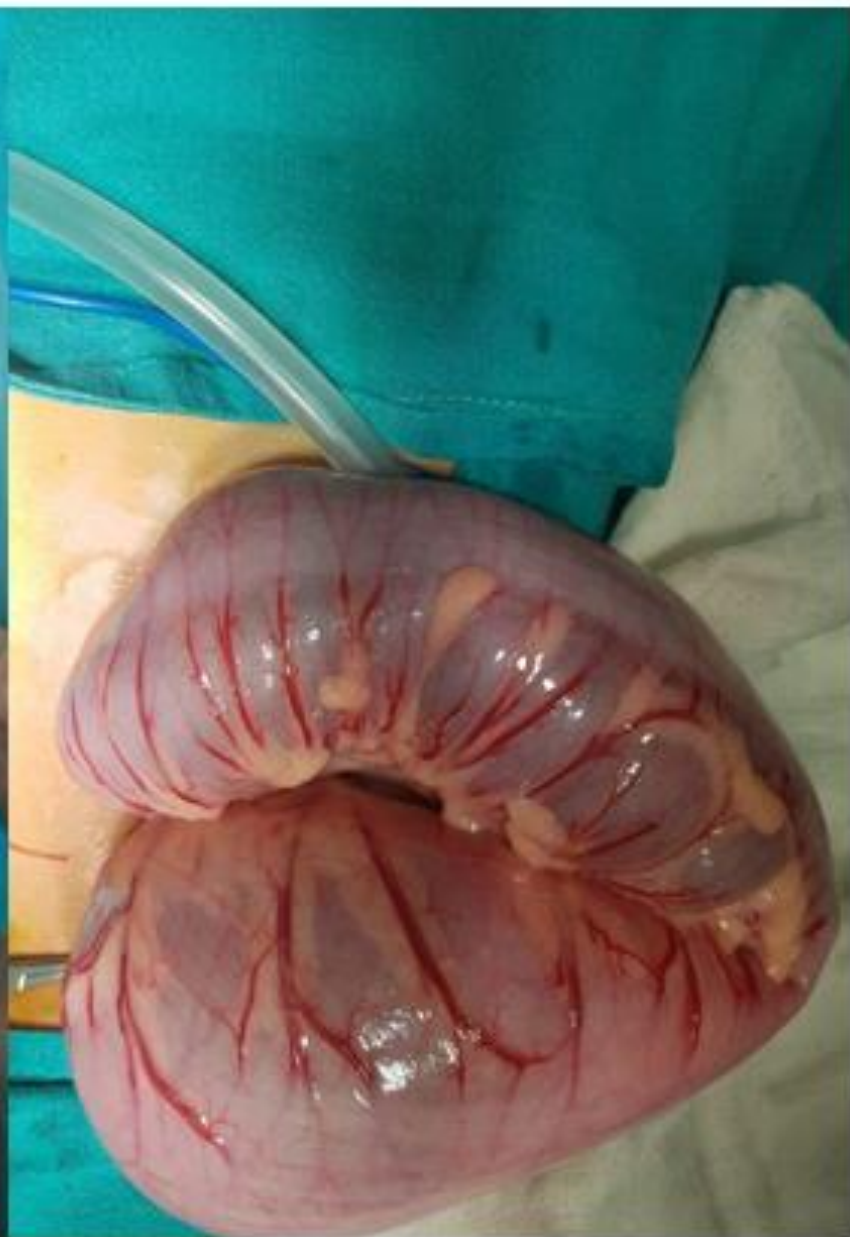
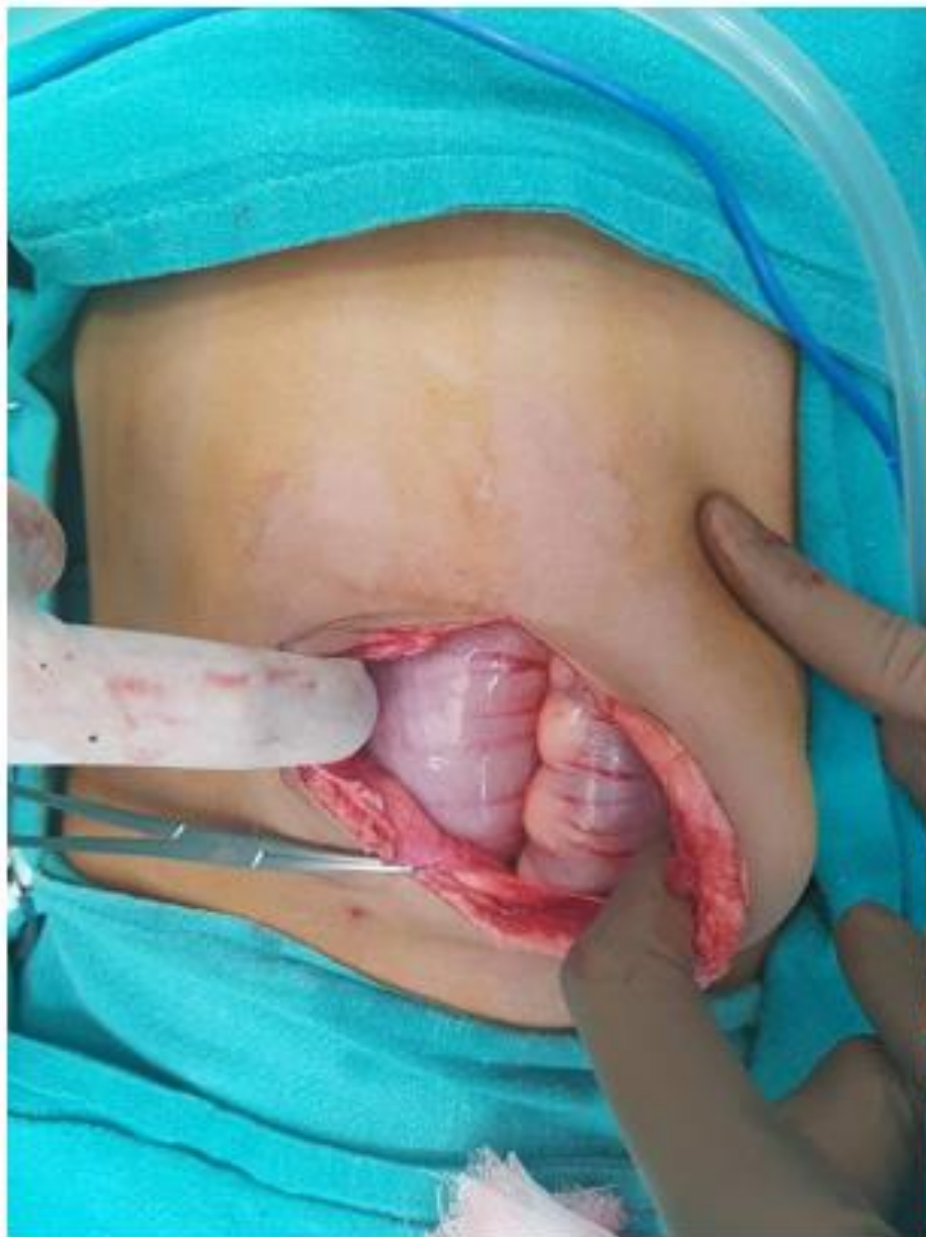
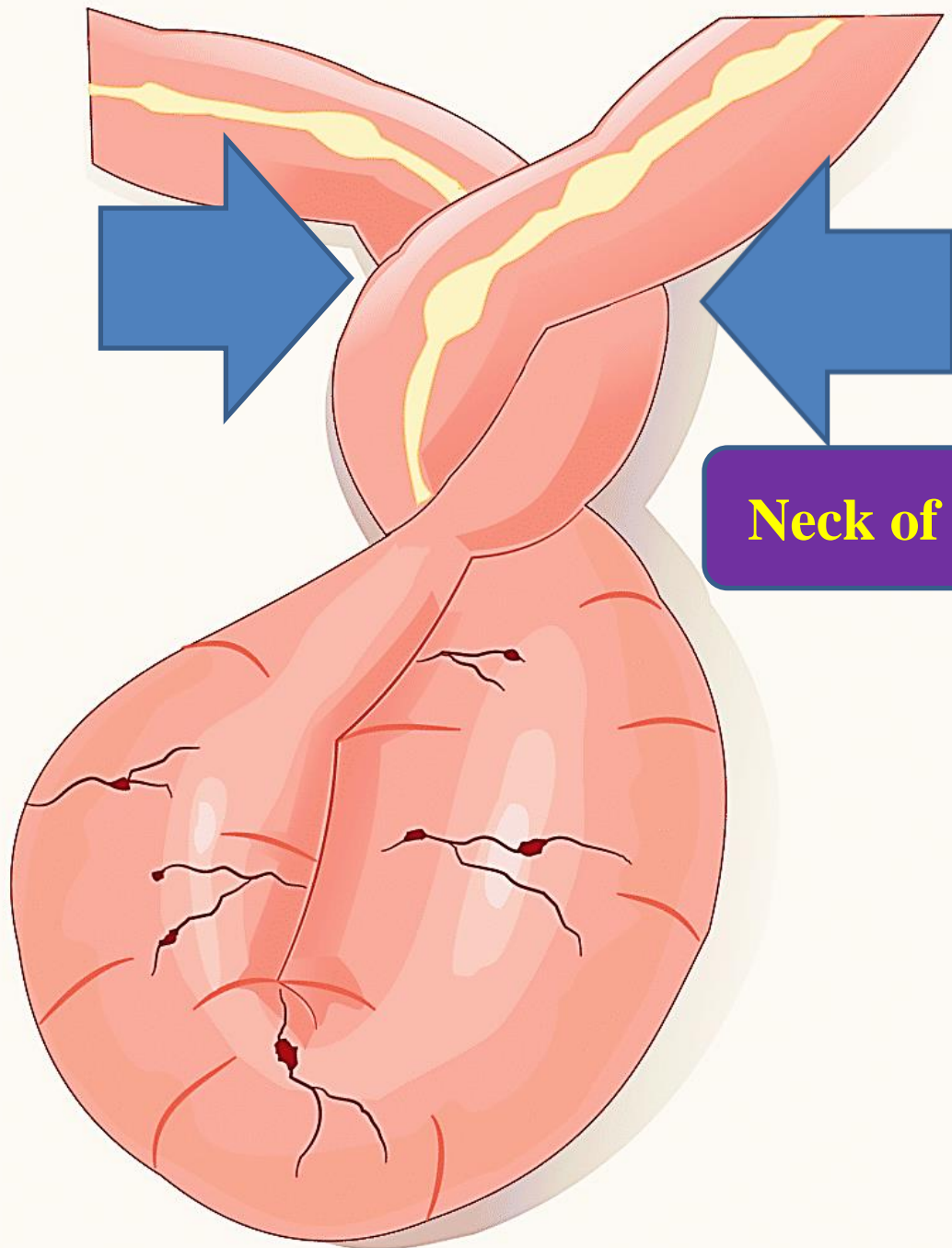


ORGANO-AXIAL  
GASTRIC VOLVULUS



MESENTERICO-AXIAL  
GASTRIC VOLVULUS





**Neck of inguinal hernia**

# Tumours of the mesentery

## Benign

- Lipoma
- Fibroma
- Fibromyxoma
- Desmoid.

## Malignant

- Lymphoma
- Secondary carcinoma.
- Neuroendocrine tumours.
- Lymphatic metastases.
- Tumour deposits (lymphovascular and perineural).
- Peritoneal carcinomatosis

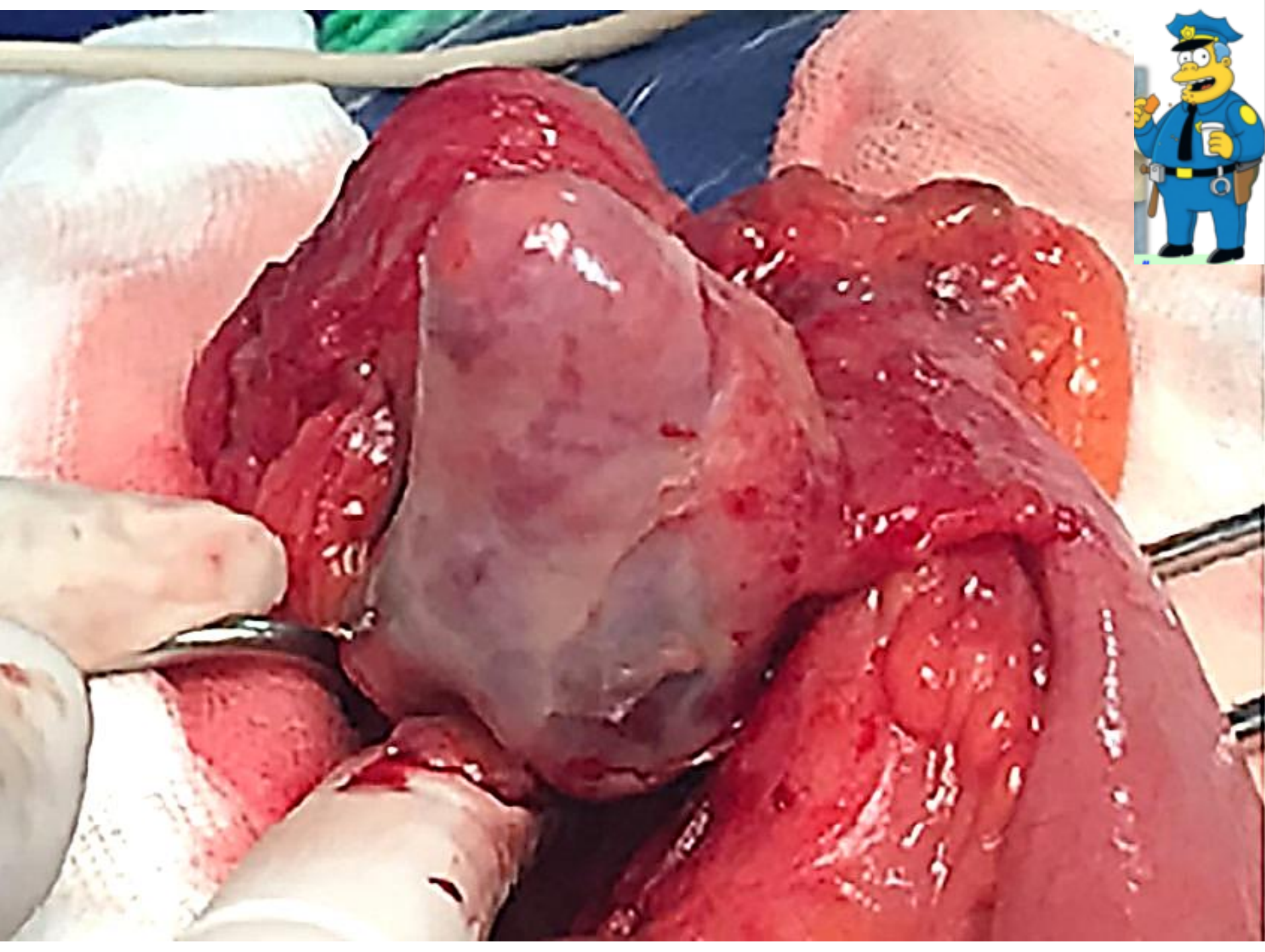
- Primary tumours of the mesentery include carcinoid, lymphoma, sarcoma and desmoid tumours. The mesentery is affected in local lymphatic spread of carcinoma arising from abdominal viscera .
- If indicated, a benign tumour of the mesentery may be excised with resection of the adjacent intestine.
- A malignant tumour of the mesentery requires biopsy confirmation and specific, usually non-surgical, treatment, e.g. chemotherapy for lymphoma.

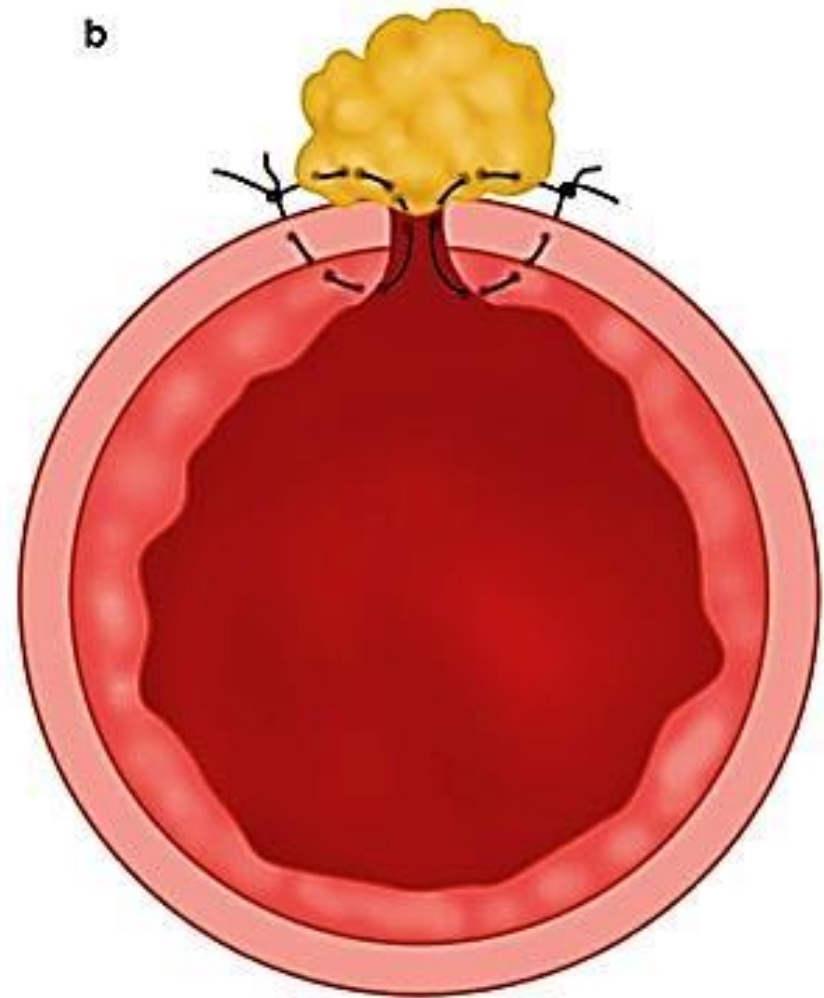
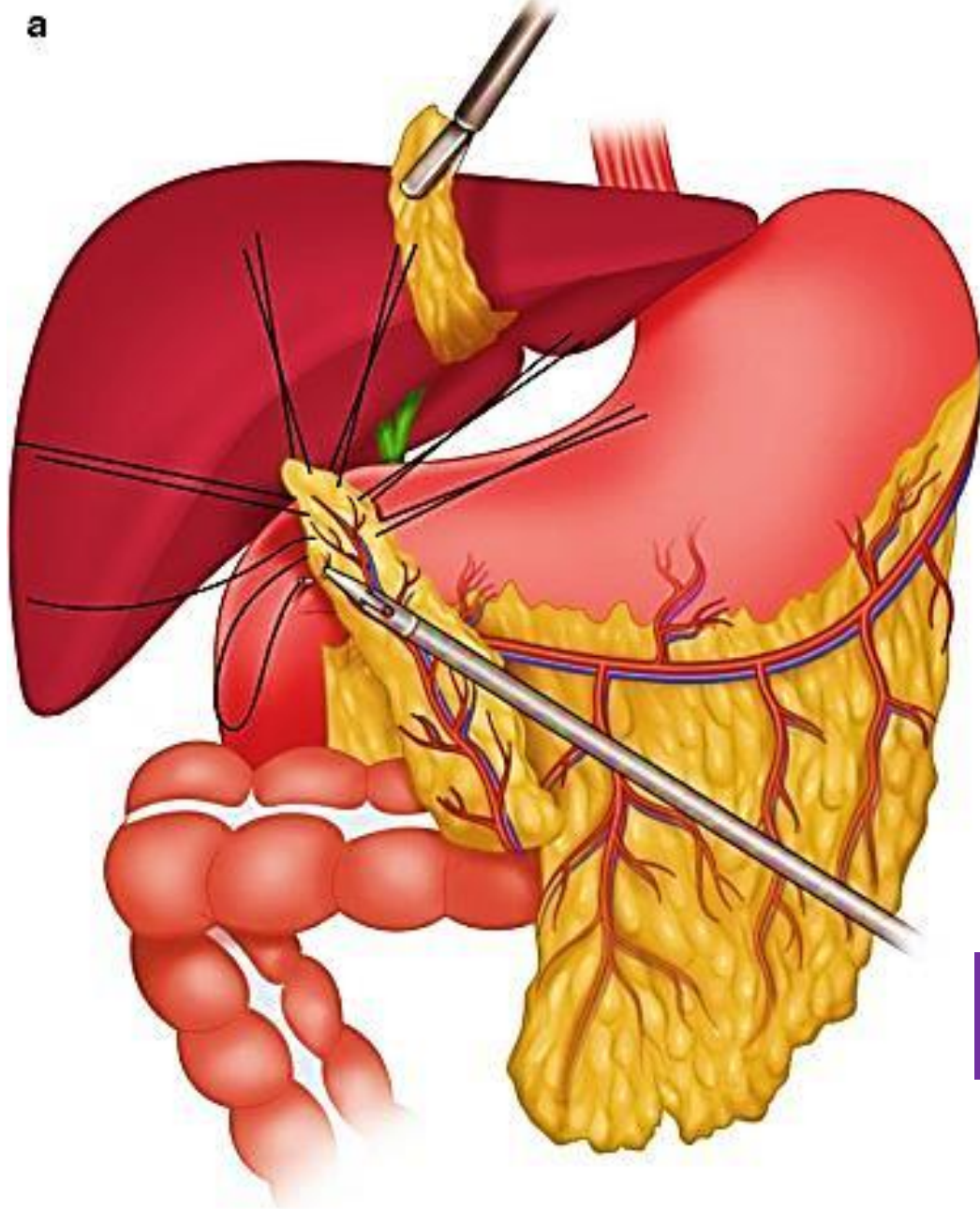
# Diffuse Fibromatosis

- It is rare, characterised by an abnormal proliferation of myofibroblasts.
- Although non-metastasising, and said to be benign, it can nevertheless prove widely invasive, compressing and infiltrating surrounding tissues such as the bowel and mesentery with complications.
- There is an association with familial adenomatous polyposis (FAP).

## THE GREATER OMENTUM ( gastrocolic ligament ).

- The greater omentum corresponds to the anterior wall of the upper region of the mesentery.
- **Storage** of fat.
- ‘The **abdominal policeman**’. It attempts to limit intraperitoneal infection ( an acutely inflamed appendix is often found wrapped in omentum) saving many patients developing diffuse peritonitis.
- *It often **plugs** the neck of a hernial sac and prevents a trapped intestine coils becoming strangulated.*
- It is used as a **plug** to control perforation as in modified Graham’ patch.
- It may be a cause of obstruction (acting as a large adhesion).
- It is usually involved in tuberculous peritonitis and carcinomatosis of the peritoneum.
- Spleniculi.
- Calcification (acute pancreatitis (saponification) ) ( T.B.)
- Mesh isolator.





**Laparoscopic Modified Graham patch operation of Perforated Duodenal**

**Stomach**

**Pancreas**

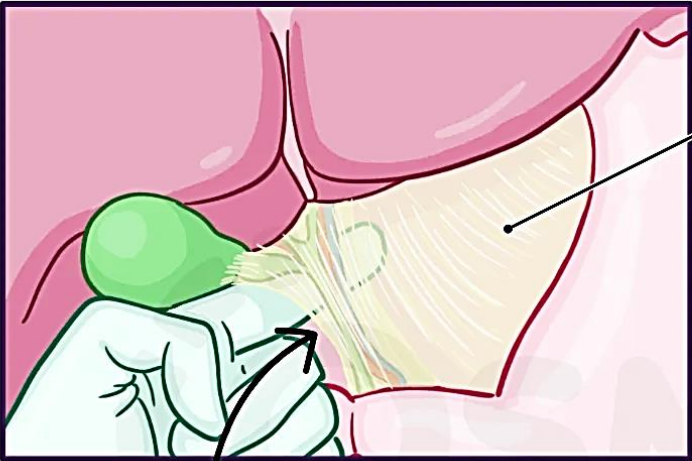
**Accessory Spleen**



## **THE LESSER OMENTUM**

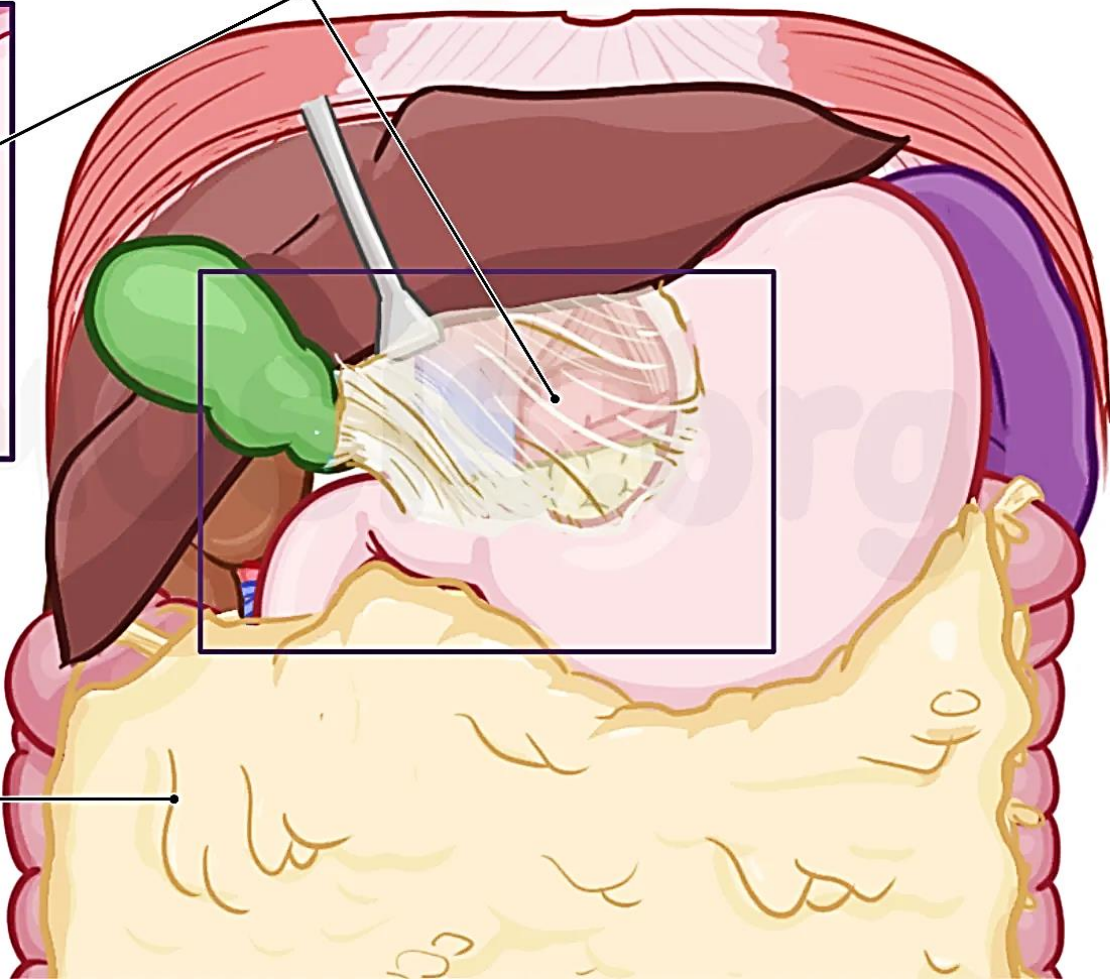
- Omental bursa( gastrohepatic ligament ). .
- Pringle maneuver

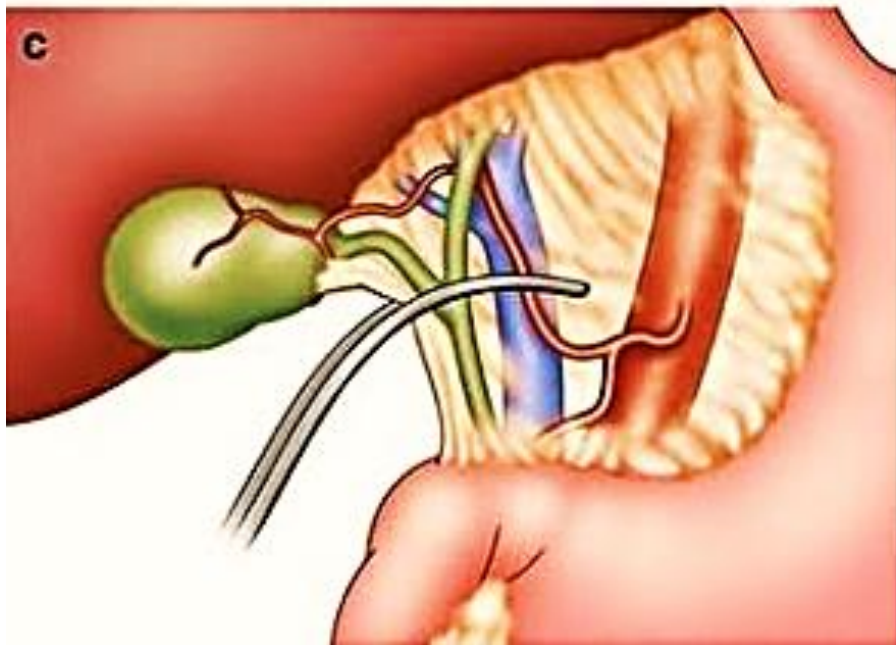
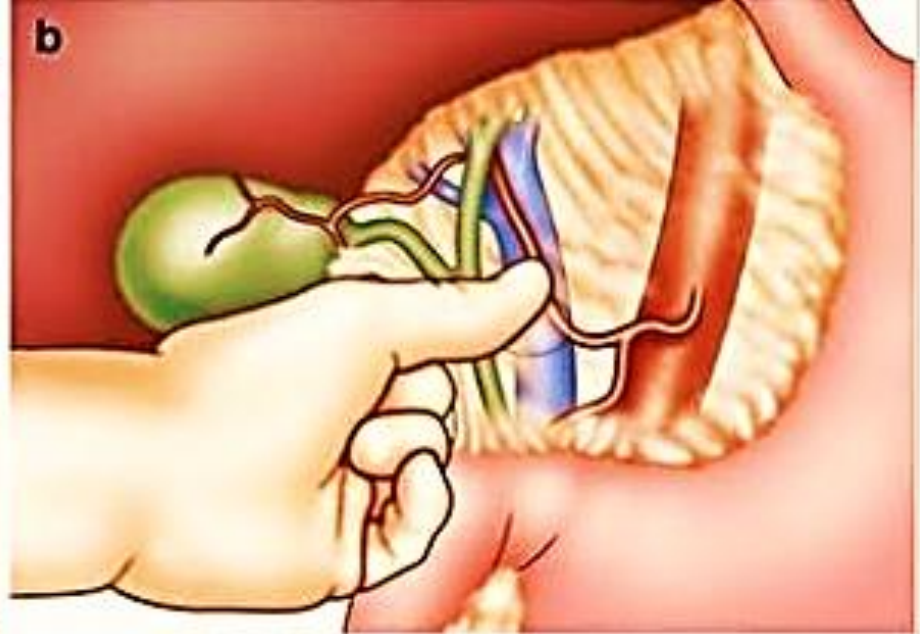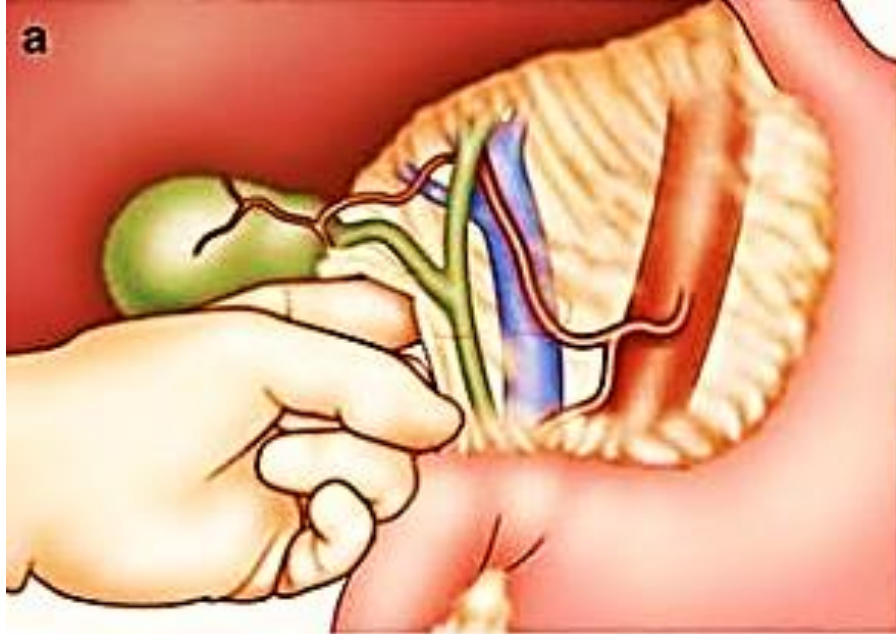Lesser omentum



Omental foramen  
(Epiploic foramen;  
Foramen of Winslow)

Greater omentum





- Pringle maneuver

**Clamping through foramen of Winslow and occlusion of the portal triad**

حَمْدُ اللَّهِ

**PRAISE BE TO ALLAH**