



---

# THE AXILLA

---

Pectoral Region



ASSISTANT PROFESSOR DR. AHMED ALMUSAWI

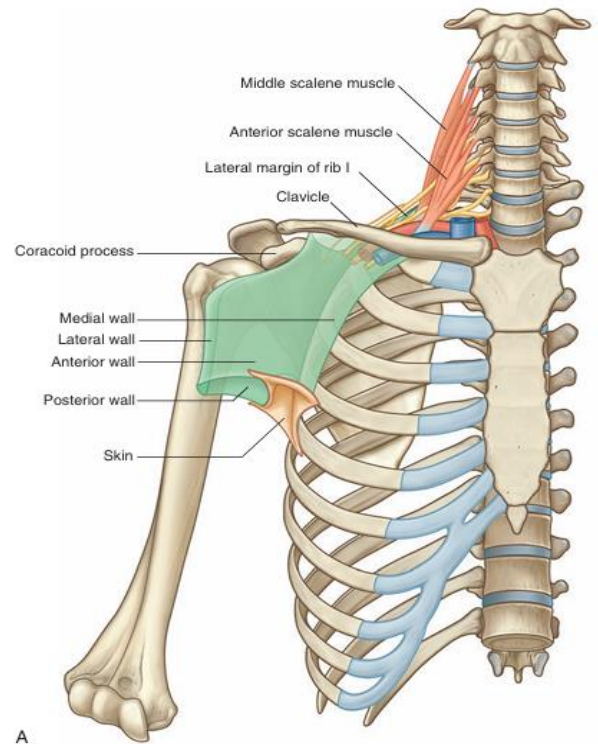
DEPARTMENT OF  
Human Anatomy

## AXILLA

The axilla is the gateway to the upper limb, providing an area of transition between the neck and the arm. (It acts as a funnel shaped tunnel for neurovascular structures to pass from the root of the neck to the upper limb and vice versa.) Formed by the clavicle, the scapula, the upper thoracic wall, the humerus, and related muscles, the axilla is an irregularly shaped pyramidal space with:

- four sides,
- an inlet, and
- a floor (base)

The axillary inlet is continuous superiorly with the neck, and the lateral part of the floor opens into the arm. All major structures passing into and out of the upper limb pass through the axilla. Apertures formed between muscles in the anterior and posterior walls enable structures to pass between the axilla and immediately adjacent regions (the posterior scapular, pectoral, and deltoid regions).



### Axillary inlet

The axillary inlet is oriented in the horizontal plane and is somewhat triangular in shape, with its apex directed laterally. The margins of the inlet are completely formed by bone:

- The medial margin is the lateral border of rib I.
- The anterior margin is the posterior surface of the clavicle.
- The posterior margin is the superior border of the scapula up to the coracoid process.

The apex of the triangularly shaped axillary inlet is lateral in position and is formed by the medial aspect of the coracoid process. Major vessels and nerves pass between the neck and the axilla by crossing over the lateral border of rib I and through the axillary inlet.

The subclavian artery, the major blood vessel supplying the upper limb, becomes the axillary artery as it crosses the lateral margin of rib I and enters the axilla. Similarly, the axillary vein becomes the subclavian vein as it passes over the lateral margin of rib I and leaves the axilla to enter the neck. At the axillary inlet, the axillary vein is anterior to the axillary artery, which, in turn, is anterior to the trunks of the brachial plexus. The inferior trunk (lower trunk) of the brachial plexus lies directly on rib I in the neck, as does the subclavian artery and vein. As they pass over rib I, the vein and artery are separated by the insertion of the anterior scalene muscle.

## Anterior wall

The anterior wall of the axilla is formed by the lateral part of the pectoralis major muscle, the underlying pectoralis minor and subclavius muscles, and the clavipectoral fascia.

## Pectoralis major

The pectoralis major muscle is the largest and most superficial muscle of the anterior wall. Its inferior margin underlies the anterior axillary fold, which marks the anteroinferior border of the axilla. The muscle has two heads:

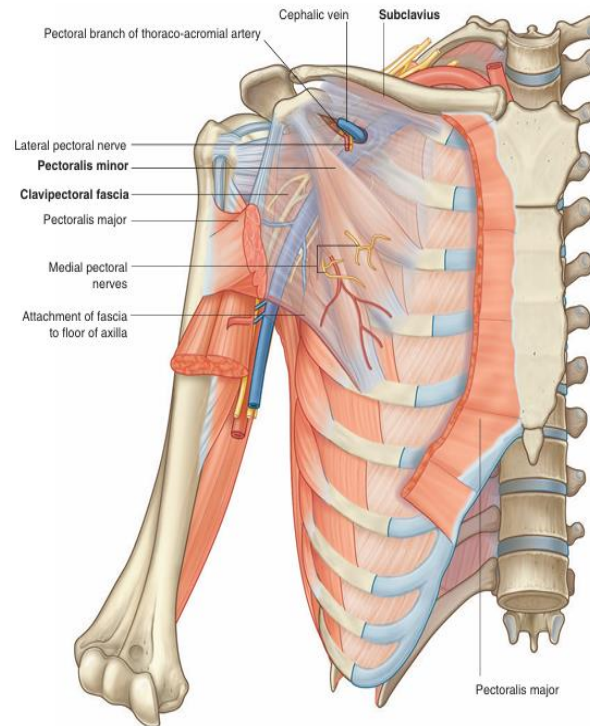
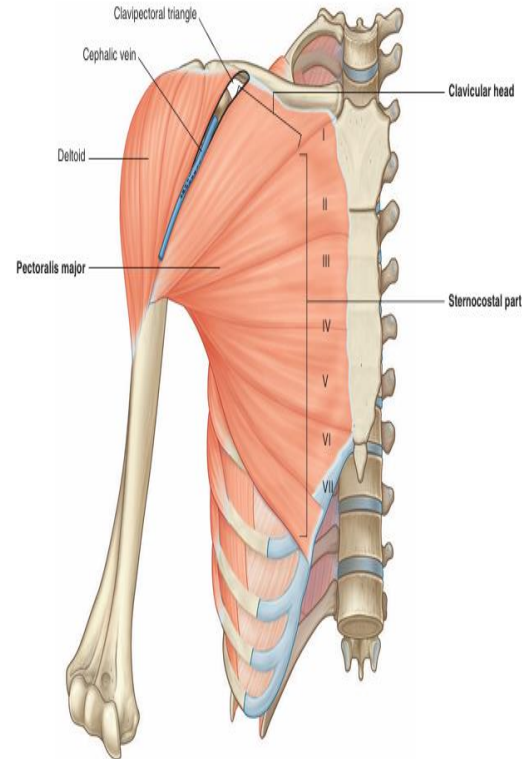
- The clavicular head originates from the medial half of the clavicle.
- The sternocostal head originates from the medial part of the anterior thoracic wall—often, fibers from this head continue inferiorly and medially to attach to the anterior abdominal wall, forming an additional abdominal part of the muscle.

The muscle inserts into the lateral lip of the intertubercular sulcus of the humerus. The parts of the muscle that have a superior origin on the trunk insert lower and more anteriorly on the lateral lip of the intertubercular sulcus than the parts of the muscle that originate inferiorly.

Acting together, the two heads of the pectoralis major flex, adduct, and medially rotate the arm at the glenohumeral joint. The clavicular head flexes the arm from an extended position, whereas the sternocostal head extends the arm from a flexed position, particularly against resistance. The pectoralis major is innervated by the lateral and medial pectoral nerves, which originate from the brachial plexus in the axilla.

## Subclavius

The subclavius muscle is a small muscle that lies deep to the pectoralis major muscle and passes between the clavicle and rib I. It originates medially, as a tendon, from rib I at the junction between the rib and its costal cartilage. It passes laterally and superiorly to insert via a muscular attachment into an elongate shallow groove on the inferior surface of the middle third of the clavicle. The function of the subclavius is not entirely clear, but it may act to pull the shoulder down by depressing the clavicle and may also stabilize the sternoclavicular joint by pulling the clavicle medially.

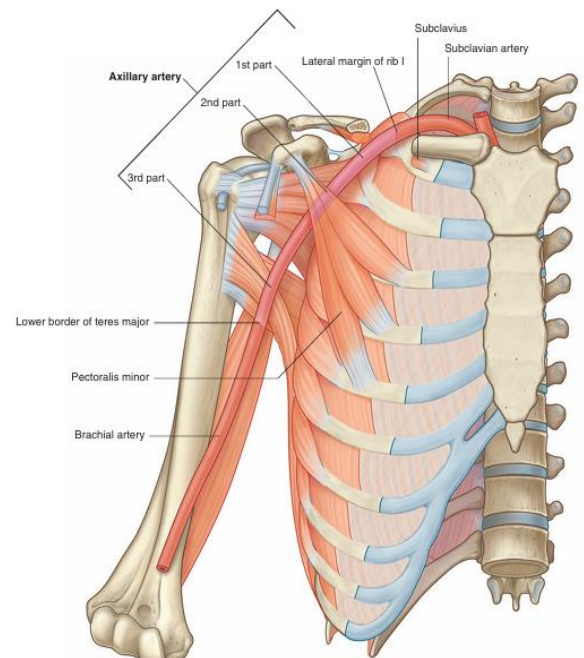


The subclavius muscle is innervated by a small branch from the superior trunk of the brachial plexus.

### **Pectoralis minor**

The pectoralis minor muscle is a small triangular-shaped muscle that lies deep to the pectoralis major muscle and passes from the thoracic wall to the coracoid process of the scapula. It originates as three muscular slips from the anterior surfaces and upper margins of ribs III to V and from the fascia overlying muscles of the related intercostal spaces. The muscle fibers pass superiorly and laterally to insert into the medial and upper aspects of the coracoid process.

The pectoralis minor muscle protracts the scapula (by pulling the scapula anteriorly on the thoracic wall) and depresses the lateral angle of the scapula. The pectoralis minor is innervated by the medial pectoral nerve, which originates from the brachial plexus in the axilla.



### **Clavipectoral fascia**

The clavipectoral fascia is a thick sheet of connective tissue that connects the clavicle to the floor of the axilla. It encloses the subclavius and pectoralis minor muscles and spans the gap between them. Structures travel between the axilla and the anterior wall of the axilla by passing through the clavipectoral fascia either between the pectoralis minor and subclavius muscles or inferior to the pectoralis minor muscle.

Important structures that pass between the subclavius and pectoralis minor muscles include the cephalic vein, the thoraco-acromial artery, and the lateral pectoral nerve.

The lateral thoracic artery leaves the axilla by passing through the fascia inferior to the pectoralis minor muscle. The medial pectoral nerve leaves the axilla by penetrating directly through the pectoralis minor muscle to supply this muscle and to reach the pectoralis major muscle. Occasionally, branches of the medial pectoral nerve pass around the lower margin of the pectoralis minor to reach and innervate the overlying pectoralis major muscle.

### **Medial wall**

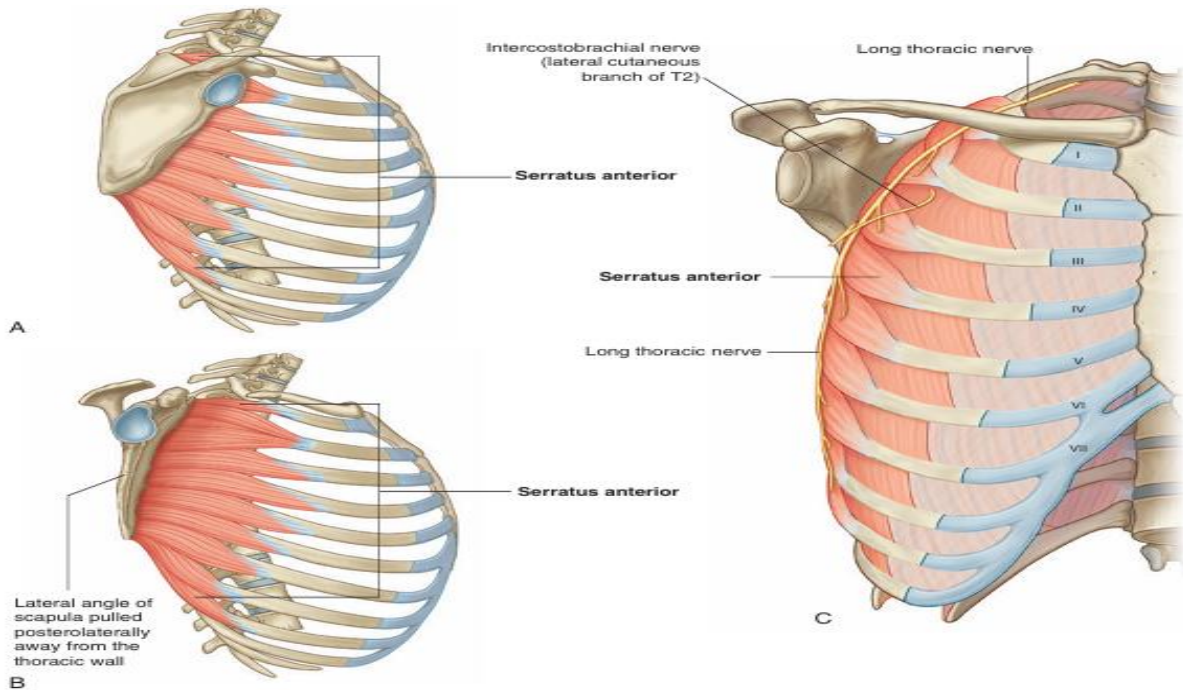
The medial wall of the axilla consists of the upper thoracic wall (the ribs and related intercostal tissues) and the serratus anterior muscle.

### **Serratus anterior**

The serratus anterior muscle originates as a number of muscular slips from the lateral surfaces of ribs I to IX and the intervening deep fascia overlying the related intercostal spaces. The muscle forms a flattened sheet, which passes posteriorly around the thoracic wall to insert primarily on the costal surface of the medial border of the scapula.

The serratus anterior pulls the scapula forward over the thoracic wall and facilitates scapular rotation. It also keeps the costal surface of the scapula closely opposed to the thoracic wall.

The serratus anterior is innervated by the long thoracic nerve, which is derived from the roots of the brachial plexus, passes through the axilla along the medial wall, and passes vertically down the serratus anterior muscle on its external surface, just deep to skin and superficial fascia.

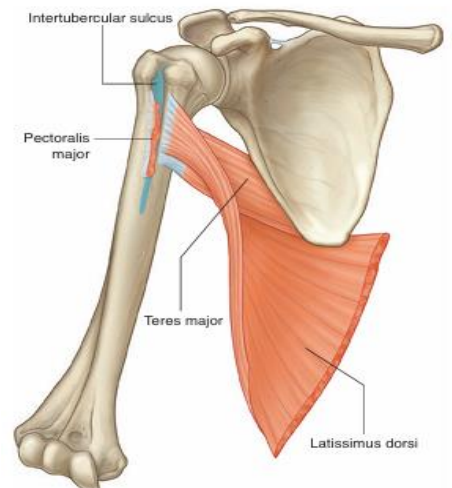


### Intercostobrachial nerve

The only major structure that passes directly through the medial wall and into the axilla is the intercostobrachial nerve. This nerve is the lateral cutaneous branch of the second intercostal nerve (anterior ramus of T2). It communicates with a branch of the brachial plexus (the medial cutaneous nerve of the arm) in the axilla and supplies skin on the upper posteromedial side of the arm, which is part of the T2 dermatome.

### Lateral wall

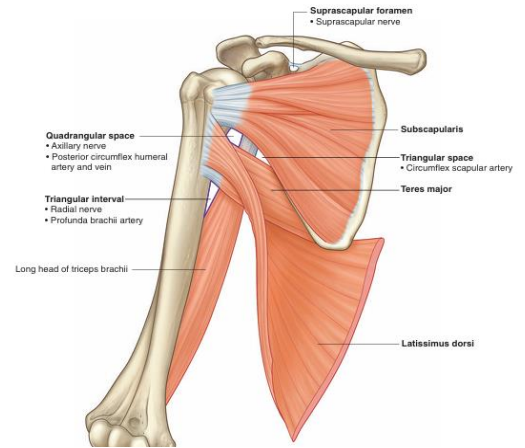
The lateral wall of the axilla is narrow and formed entirely by the intertubercular sulcus of the humerus. The pectoralis major muscle of the anterior wall attaches to the lateral lip of the intertubercular sulcus. The latissimus dorsi and teres major muscles of the posterior wall attach to the floor and medial lip of the intertubercular sulcus, respectively.



## Posterior wall

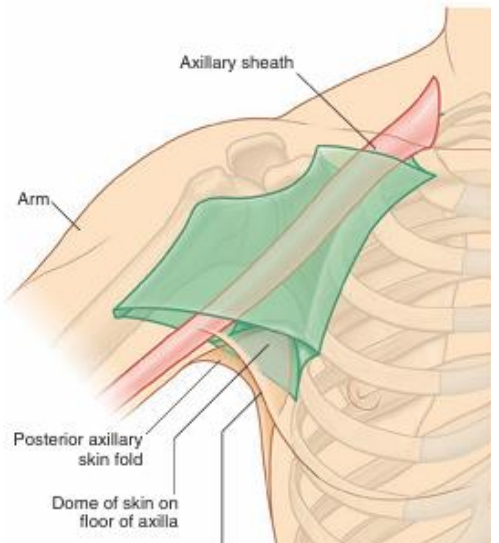
The posterior wall of the axilla is complex. Its bone framework is formed by the costal surface of the scapula. Muscles of the wall are:

- the subscapularis muscle (associated with the costal surface of the scapula),
- the distal parts of the latissimus dorsi and teres major muscles (which pass into the wall from the back and posterior scapular region), and
- the proximal part of the long head of the triceps brachii muscle (which passes vertically down the wall and into the arm).



## Floor

The floor of the axilla is formed by fascia and a dome of skin that spans the distance between the inferior margins of the walls. It is supported by the clavipectoral fascia. On a patient, the anterior axillary fold is superior in position than is the posterior axillary fold. Inferiorly, structures pass into and out of the axilla immediately lateral to the floor where the anterior and posterior walls of the axilla converge and where the axilla is continuous with the anterior compartment of the arm.



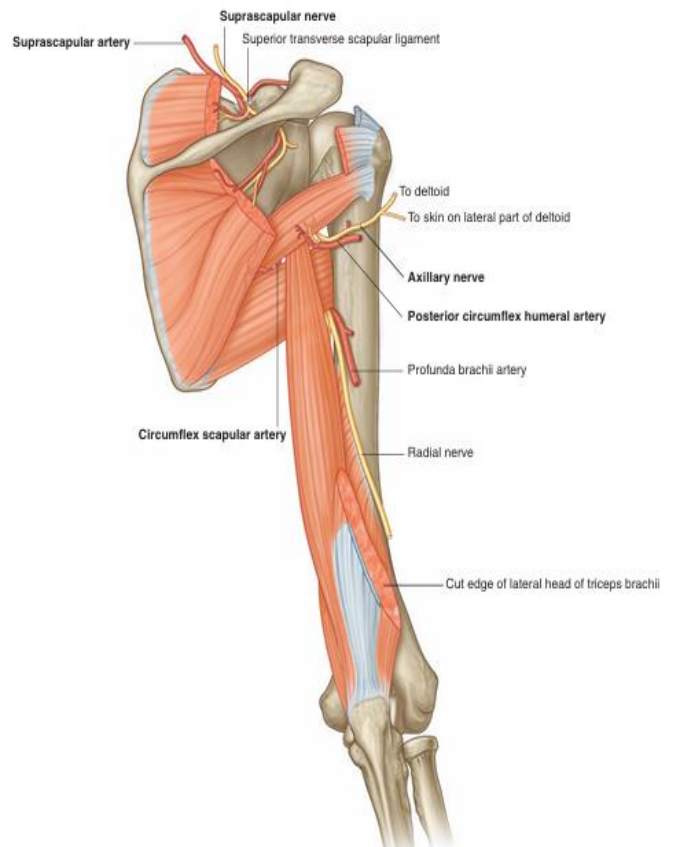
Gaps between the muscles of the posterior wall form apertures through which structures pass between the axilla, posterior scapular region, and posterior compartment of the arm.

## Gateways in the posterior wall

### Quadrangular space

The quadrangular space provides a passageway for nerves and vessels passing between the axilla and the more posterior scapular and deltoid regions. When viewed from anteriorly, its boundaries are formed by:

- the inferior margin of the subscapularis muscle,
- the surgical neck of the humerus,
- the superior margin of the teres major muscle, and
- the lateral margin of the long head of the triceps brachii muscle.



Passing through the quadrangular space are the axillary nerve and the posterior circumflex humeral artery and vein.

### **Triangular space**

The triangular space is an area of communication between the axilla and the posterior scapular region. When viewed from anteriorly, it is formed by:

- the medial margin of the long head of the triceps brachii muscle,
- the superior margin of the teres major muscle, and
- the inferior margin of the subscapularis muscle.

The circumflex scapular artery and vein pass into this space.

### **Triangular interval**

This triangular interval is formed by:

- the lateral margin of the long head of the triceps brachii muscle,
- the shaft of the humerus, and
- the inferior margin of the teres major muscle.

Because this space is below the inferior margin of the teres major, which defines the inferior boundary of the axilla, the triangular interval serves as a passageway between the anterior and posterior compartments of the arm and between the posterior compartment of the arm and the axilla. The radial nerve, the profunda brachii artery (deep artery of arm), and associated veins pass through it.