

# Medical Biology

**Dr. Khalida Ibrahim**

## **Epithelial Tissues**

### **Stratified epithelium:**

The stratified epithelial tissue is made of more than one layer of cells and classified according to the cell shape of its superficial layer to

**1. squamous 2. cuboidal 3. columnar 4. transitional.**

These typically are at sites needing a more defensive, rather than a metabolic function.

#### **1. stratified squamous epithelial tissue:**

Composed of many layers of cells, the basal layer composed of columnar or cuboidal cells, the middle cell layers composed of polygonal cells, and the superficial layer is squamous cells.

There are 2 types of stratified squamous epithelium:

❖ stratified squamous non- keratinized type:

It lines the moist cavities of the mouth, esophagus, vagina, and anal canal.

This exhibit live superficial cells containing nuclei.

❖ stratified squamous keratinized type:

It lines the dry areas like the skin and contains non- living cells rich with keratin intermediate filament and containing no nucleus.

#### **2. stratified cuboidal epithelium:**

Consist of 2 layers of cuboidal cells, the nuclei are large and central, is found in large excretory ducts of sweat and salivary glands.

#### **3. stratified columnar epithelium:**

It is present only in small areas in the human body such as the largest ducts of exocrine glands and male urethra and conjunctiva lining the eyelids. The

superficial cells are columnar and below there are polygonal cells and the basal cells either cuboidal or columnar.

**Note:** stratified cuboidal and columnar epithelium are both relatively rare in the body.

#### **4. transitional epithelium:**

Is found exclusively in the excretory passages of the urinary system. It lines the urinary bladder, the ureter, and the upper part of the urethra. The basal layer cells are small polygonal or short columnar. The middle layer cells are pyramidal, while the superficial layer cells are large, with umbrella shaped or domelike cells, and sometimes are binucleated.

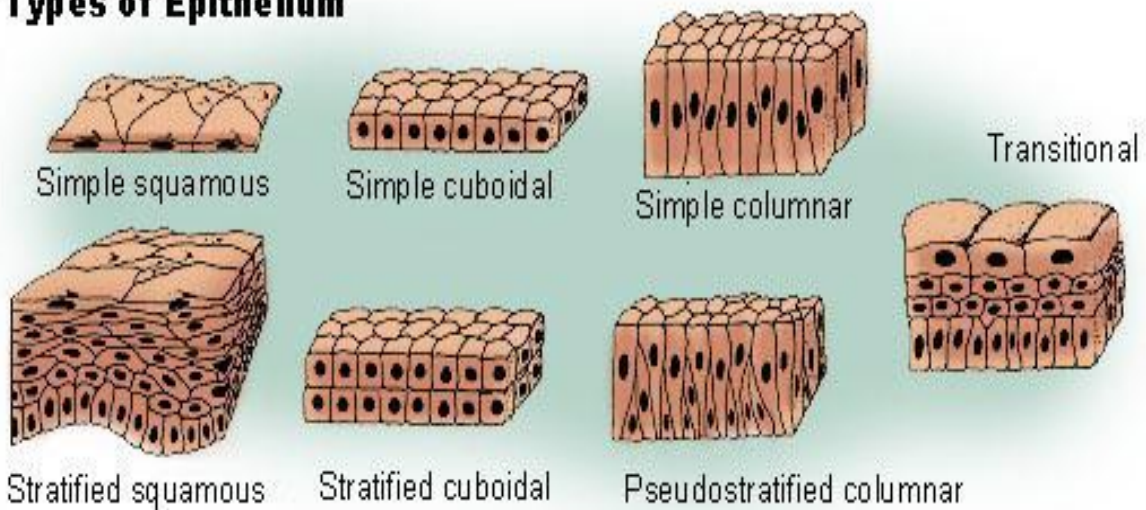
This type of tissue has the ability to rearrange the no. of the cell layers, depending on whether it is in a distended or contracted state.

e.g. in the contracted bladder, the epithelium consists of 5-6 layers and the cells are dome shaped while in distended bladder, the tissue is made up of 2-3 layers, the superficial layer is composed of large squamous cells, but only the basal one is composed of cuboidal cells.

#### **Medical notes:**

In cases of chronic vitamin A deficiency, epithelial tissues found in bronchi and urinary bladder may gradually be replaced by stratified squamous epithelium due to decrease in mucus-secreting elements, and keratinization.

## Types of Epithelium

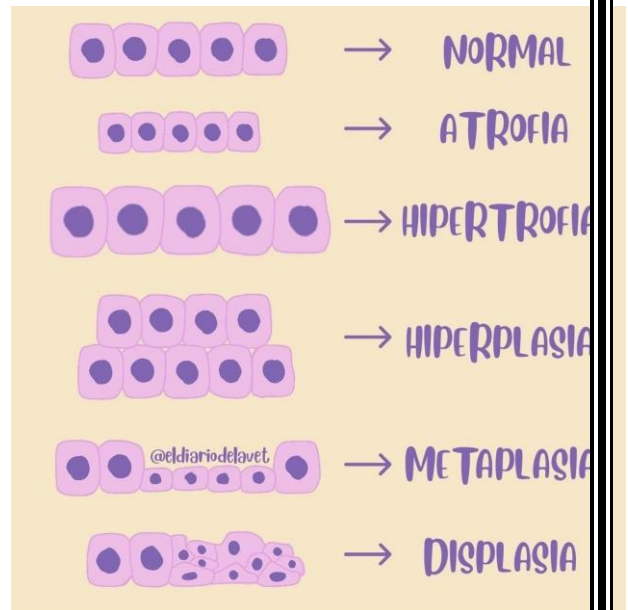


### Clinical Correlation:

#### Epithelial Metaplasia



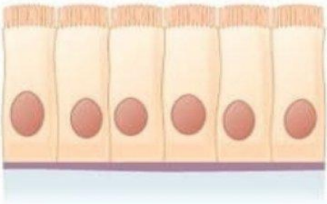
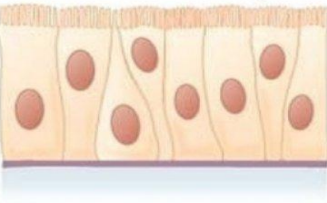
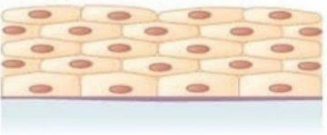

Epithelial metaplasia is a reversible conversion of one mature epithelial cell type to another mature epithelial cell type. Metaplasia is generally an adaptive response to stress, chronic inflammation, or other abnormal stimuli. The original cells are substituted by cells that are better suited to the new environment and more resistant to the effects of abnormal stimuli. The most common epithelial metaplasia is columnar-to-squamous and occurs in the glandular epithelium, where the columnar cells become replaced by the stratified squamous epithelium. For example, squamous metaplasia frequently occurs in the pseudostratified respiratory epithelium of the trachea and bronchi in response to prolonged exposure to cigarette smoke.

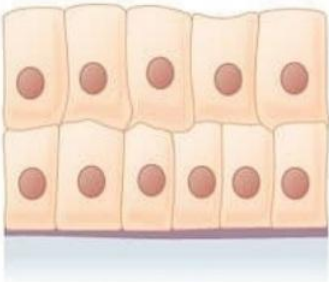
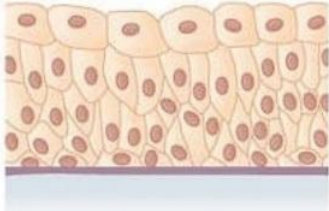
Metaplasia is usually a reversible phenomenon, and if the stimulus that caused metaplasia is removed, tissues return to their normal pattern of differentiation. If abnormal stimuli persist for a long time, squamous metaplastic cells may



transform into squamous cell carcinoma. Cancers of the lung often originate from squamous metaplastic epithelium. Pseudostratified columnar epithelium may give rise to glandular adenocarcinomas.

When metaplasia is diagnosed, all efforts should be directed toward removing the pathogenic stimulus i.e., cessation of smoking and monitoring the metaplastic site to ensure that cancerous changes do not begin to develop.

Cells	Location	Function
<b>Simple squamous epithelium</b> 	Air sacs of lungs and the lining of the heart, blood vessels, and lymphatic vessels	Allows materials to pass through by diffusion and filtration, and secretes lubricating substance
<b>Simple cuboidal epithelium</b> 	In ducts and secretory portions of small glands and in kidney tubules	Secretes and absorbs
<b>Simple columnar epithelium</b> 	Ciliated tissues are in bronchi, uterine tubes, and uterus; smooth (nonciliated tissues) are in the digestive tract, bladder	Absorbs; it also secretes mucous and enzymes
<b>Pseudostratified columnar epithelium</b> 	Ciliated tissue lines the trachea and much of the upper respiratory tract	Secretes mucus; ciliated tissue moves mucus
<b>Stratified squamous epithelium</b> 	Lines the esophagus, mouth, and vagina	Protects against abrasion
<b>Stratified cuboidal epithelium</b> 	Sweat glands, salivary glands, and the mammary glands	Protective tissue

<p><b>Stratified columnar epithelium</b></p> 	<p>The male urethra and the ducts of some glands</p>	<p>Secretes and protects</p>
<p><b>Transitional epithelium</b></p> 	<p>Lines the bladder, urethra, and the ureters</p>	<p>Allows the urinary organs to expand and stretch</p>

❖ **Glandular epithelium:**

One of the specialized functions of epithelia is secretion.

Glands consist of groups of epithelial cells modified to synthesize and secrete.

Glands are classified into three major groups based on the method of distribution of their secretory products:

- exocrine glands, which secrete their products to the external environment via ducts.
- endocrine glands, which secrete their products directly into the blood (ductless glands).
- mixed glands, which have both exocrine and endocrine secretion.

**Exocrine glands:**

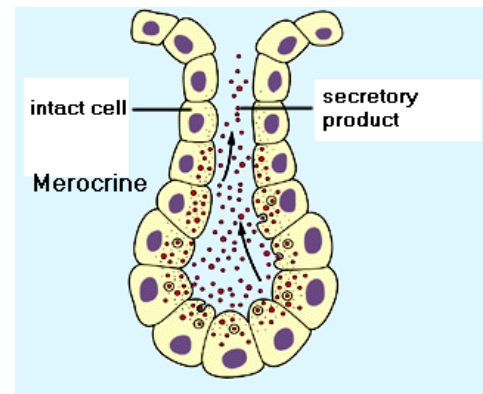
**Classification of exocrine glands:**

**1. Exocrine Glands Classified by Mechanisms of Secretion:**

Exocrine glands classified according to the mode or way in which the secretory products leave the cell into:

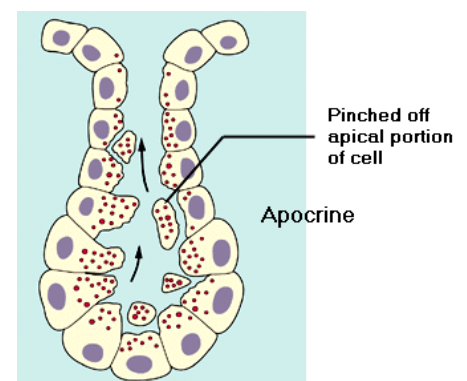
**(a) Merocrine (or eccrine) secretion:**

This is the most common type of exocrine secretion. Secretory granules (packaged in the Golgi bodies) migrate to the apical surface of the cell. The membranes of the secretory granules fuse with the apical membrane and the secretion are released to the external environment by exocytosis.



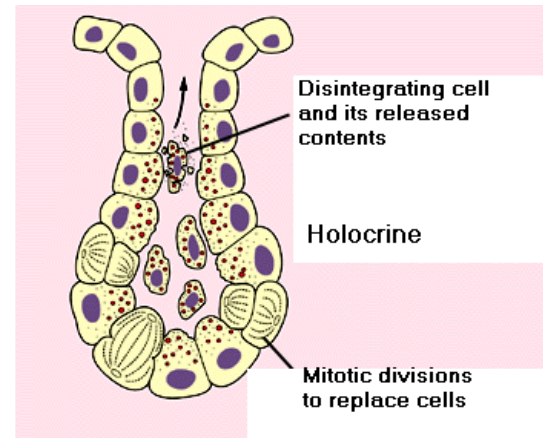
**(b) Apocrine secretion:**

With apocrine secretion the apical portion of the cells, together with the secretory contents, are budded off and released to the lumen or external environment. Examples of such apocrine secretion are found in the apocrine sweat glands of the armpits and mammary glands.



**(c) Holocrine secretion:**

Holocrine secretion involves the secretion of whole cells and their contents. This is best seen in the sebaceous glands associated with hairs of thin skin.



**Medical notes:**

The holocrine sebaceous glands are the primary structure involved in the common form of acne, acne vulgaris. Excessive holocrine secretion of sebum and keratin triggered by the surge of the steroid hormone testosterone that occurs in both genders at puberty frequently leads to blocked ducts within the gland and inflammation will be developed.