

# Medical Biology

Dr. Khalida Ibrahim

## Connective Tissue

### Connective Tissue Components:

1) Cells

2) Extracellular matrix:

#### I-Ground Substance:

Ground substance in connective tissue consists primarily of amorphous, transparent and colorless extracellular matrix, which has the properties of a semifluid gel and a high water content. It is binding cells to the fibers of connective tissue.

#### Ground substance composed of:

1. **Glycoaminoglycans.**
2. **Proteoglycans.**
3. **Adhesive Glycoproteins.**

The **glycosaminoglycan** are unbranched polysaccharide molecules of 5 types:

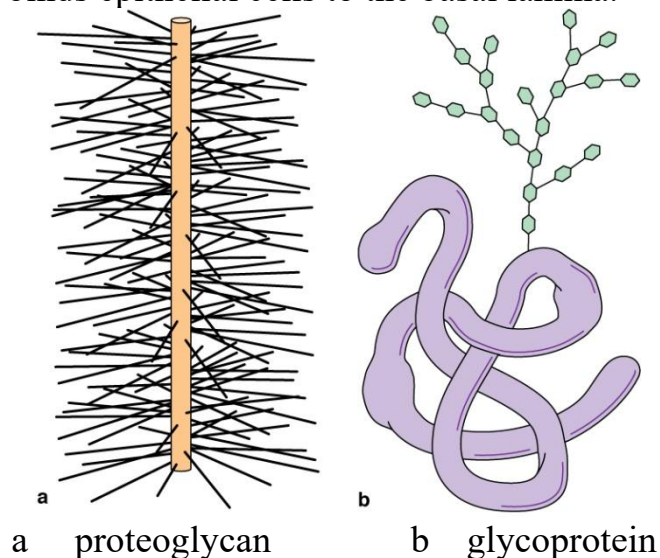
1. Hyaluronan (or hyaluronic acid) is the dominant glycosaminoglycan in connective tissues.
2. The remaining 4 major glycosaminoglycans are chondroitin sulfate, dermatan sulfate, keratan sulfate and heparan sulfate.

Except for hyaluronic acid, the other 4 glycosaminoglycans are bound to a core protein to form much larger molecules called **proteoglycan aggregates**. These proteoglycans attract large amounts of water, which forms the hydrated gel of the ground substance.

The third class of ground substance constituents is **adhesive glycoproteins** responsible for linking the components of the matrix both to one another and to the surfaces of cells. These include:

- Fibronectin
- Laminin

Such laminin glycoprotein are the major structural components of the cell basement membrane. This protein binds epithelial cells to the basal lamina.



In addition to the hydrated ground substance, there is a small quantity of free fluid called interstitial or tissue fluid that is similar to blood plasma in its content of ions and diffusible

substances, tissue fluid contains small percentage of plasma proteins that pass through the capillary walls as a result of the hydrostatic pressure of the blood. **Edema** results from accumulation of water in the extracellular space in many pathological conditions.

### Causes of Edema:

1. Edema may result from venous or lymphatic obstruction or from a decrease in venous blood flow (e.g, congestive heart failure).
2. It may also be caused by the obstruction of lymphatic vessels due to parasitic plugs or tumor cells and chronic starvation; protein deficiency results in a lack of plasma proteins and a decrease in colloid osmotic pressure. Water therefore accumulates in the connective tissue and is not drawn back into the capillaries.
3. Another possible cause of edema is the increased permeability of the blood capillary endothelium resulting from chemical or mechanical injury or the release of certain substances produced in the body (e.g, histamine). *Angioedema* is a condition where small blood vessels leak fluid into the tissues under the skin, causing swelling in different parts of the body. It can develop because of an allergic reaction

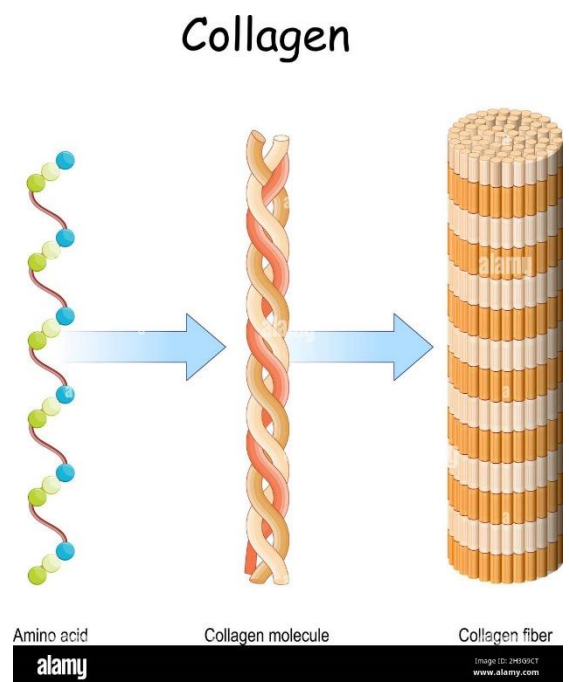
### Biomedical applications of hyaluronic acid

Hyaluronic acid (HA) is a large non-sulfated glycosaminoglycan that is the main component of the extracellular matrix (ECM). Because of its strong and diversified functions applied in broad fields. The molecular properties of HA and its derivatives, including a wide range of molecular weights but distinct effects on cells, moisture retention and anti-aging promised its role as a popular participant in tissue engineering, wound healing, cancer treatment, ophthalmology, and cosmetics.

### II-Fibers:

#### Collagen fibers (white fibers):

They are the most numerous and strongest fibers in the body derived from connective tissue cells called fibroblasts. Fresh collagenous fibers are colorless, and they give the tissue white color when grouped in great no. e.g. in tendon. These fibers are straight or wavy, unbranched consist of protein called collagen which is the major structural protein of the extracellular matrix and the single most abundant protein in human tissues. This protein is characterized by the formation of triple helices in which 3 polypeptide chains are wound tightly around one another in a ropelike structure. Collagen fibers always run parallel to each other forming bundles, which branched and anastomose. There are several types of collagen fibers.



### Types of collagen fibers:

About 20 different types of collagen fibers differ by their composition, morphology, distribution in tissues and functions. Examples:

- Type I: in connective tissue proper, fibrocartilage and bone.
- Type II: in cartilage (hyaline and elastic).
- Type III: reticular fibers.
- Type IV: in basement membrane.

## **Medical Application**

**Keloid** is a local swelling caused by abnormal amounts of collagen that form in scars of the skin. Keloids, which occur most often in individuals of black African descent, can be a troublesome clinical problem to manage; not only can be disfiguring, but excision is almost always followed by recurrence.

### **Elastic fibers (yellow fibers):**

Connective tissues also contain elastic fibers, which are particularly abundant in organs that regularly stretch and then return to their original shape.

Elastic fibers are composed principally of a protein called elastin.

They differ from collagen in that they are thinner than the white fibers, they branch and unite with one another forming irregular network, when they present in great quantity, they appear yellow, the fibers run individually and not in bundle.

They are not stained with hematoxylin-eosin, but stained with special stain **orcein**, they are generally formed by fibroblasts.

## **Medical Application**

**Marfan syndrome**, a disease characterized by a lack of resistance in tissues rich in elastic fibers. Because large arteries are rich in components of elastic fibers and because the blood pressure is high in the aorta, patients with this disease often experience aortic swellings called aneurysms, a life-threatening condition.

### **Reticular fibers:**

Reticular fibers are another form of collagen (Type III). They are arranged as a loose meshwork of thin fibers providing supportive scaffolding for the specialized cells of various organs as well as blood vessels.

They are formed from collagen, and they are not stained with hematoxylin-eosin, but stained with silver stains and appear black, they are associated with special cells called reticular cells.

## **Medical Application**

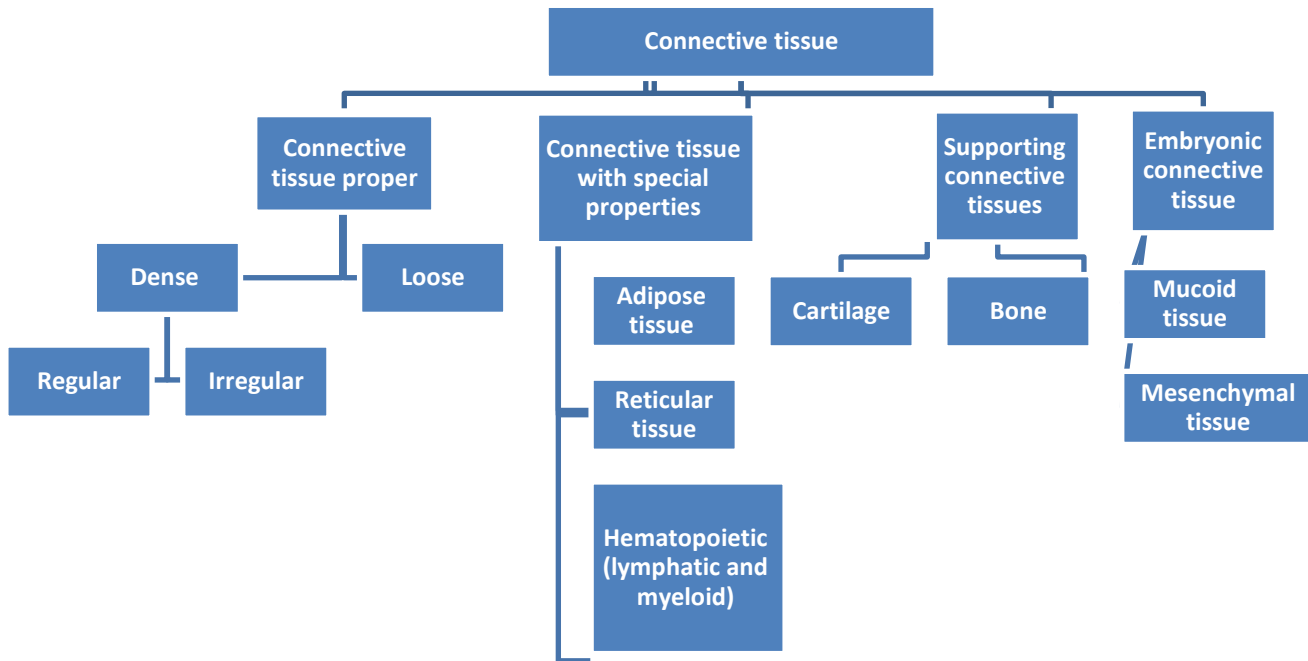
**Ehlers–Danlos type IV disease**, a deficiency of collagen type III, is characterized by ruptures in arteries and the intestine, both structures rich in reticular fibers.

## **Sun Exposure and Molecular Changes in Photoaged Skin**

**Chronological aging** of the skin is a complex process that is associated with functional and structural changes within the stratified squamous epithelium (epidermis) as well as the underlying connective tissue of the dermis. When these changes are intensified by prolonged exposure to solar or ultraviolet (UV) radiation, the process is referred to as **photoaging**. Chronic sun exposure ages the skin at an accelerated rate, especially in exposed areas of the body such as the face, neck, dorsal surface of the hands, and forearms. Clinical signs associated with photoaging include dyspigmentation, freckles, deep wrinkles, increased laxity, and increased risk for cutaneous cancers.

The best strategies to prevent photodamage caused by solar and UV radiation is the use of physical and chemical sunscreens to prevent UV penetration into skin. Other methods are also used in treating damaged skin. These include reducing skin inflammatory reactions with anti-inflammatory medications.

# Connective Tissue Classification



## Connective Tissue Proper:

### a-Loose Connective Tissue:

Loose connective tissue (areolar tissue) supports many structures that are normally under pressure and low friction. A very common type of connective tissue, Loose connective tissue comprises all the main components of connective tissue proper. There is no predominant element in this tissue. The most numerous cells are fibroblasts and macrophages, but all the other types of connective tissue cells are present. A moderate amount of collagen, elastic, and reticular fibers.

### b-Dense Connective Tissue:

Dense connective tissue is divided into two sub-categories:

- **Dense Irregular Connective Tissue**
- **Dense Regular Connective Tissue**

Dense connective tissue contains relatively few cells with much greater numbers of collagen fibers.

Dense irregular connective tissue has bundles of collagen fibers that appear to be randomly orientated (as in the dermis).

Dense regular connective tissue has closely packed densely arranged fiber bundles with clear orientation (cord like structure or bands) and relatively few cells (such as in tendons).

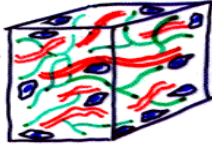
This type includes:

**1. White Regular Dense Connective Tissue e.g. tendons.**

**2. Yellow Elastic Dense Regular Connective Tissue e.g. ligaments:** They have a similar structural arrangement to tendons, but differ in their yellow color, which is due to the abundance of elastic fibers in the tissue.

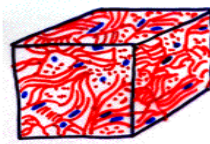
## TYPES OF CONNECTIVE TISSUE

**Loose Connective Tissue**



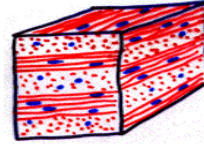
(e.i. mesentery, omentum)

**Dense Irregular Connective Tissue**

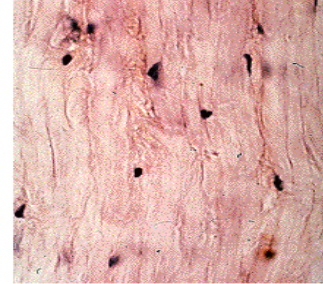
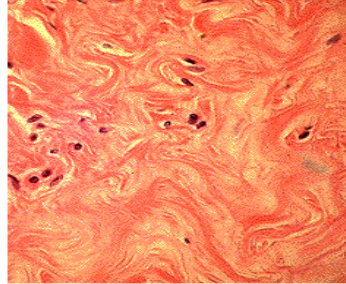
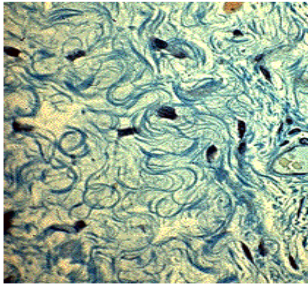


(e.i. dermis of skin)

**Dense Regular Connective Tissue**



(e.i. tendons, ligaments, cornea)



### Connective Tissue with Special Properties:

#### Reticular tissue:

Consists of delicate networks of type III collagen and is most abundant in certain lymphoid organs where the fibers form attachment sites for lymphocytes and other immune cells.

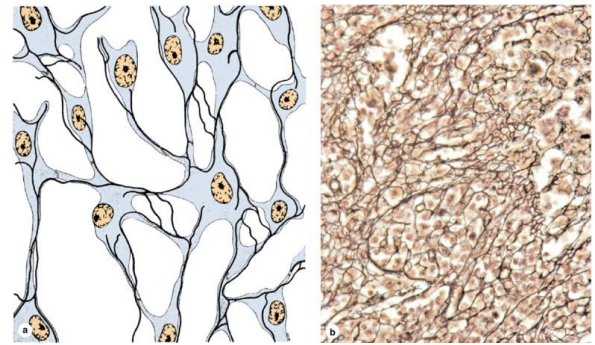
#### Embryonic Connective Tissue:

#### Muroid tissue:

It is referred to as (Wharton's jelly), it is a gel-like connective tissue with few cells found most abundantly around blood vessels in the umbilical cord.

#### Mesenchymal tissue:

Is the connective tissue of embryo consisting of mesenchymal cells in a gel like amorphous ground substance containing scattered reticular fibers.



	<b>Collage fibers</b>	<b>Reticular fibers</b>	<b>Elastic fibers</b>
<b>1. Fresh state</b>	White.	-----	Yellow.
<b>2. Stain</b>	H&E : pink.	Silver: brown.	H&E: faint.  Orcein: brick red.
<b>3. Types</b>	20 types, most common is type I.	Collagen type III.	-----
<b>4. Description</b>	<ul style="list-style-type: none"> <li>▪ Cylindrical.</li> <li>▪ Run in bundles.</li> <li>▪ Fibers are not branched but bundles do.</li> </ul>	Short branching fibers that form a network.	Either long & thin branching fibers or parallel sheets.
<b>5. Function</b>	Tensile strength.	Support.	Flexibility & elastic recoil (due to elastin protein).