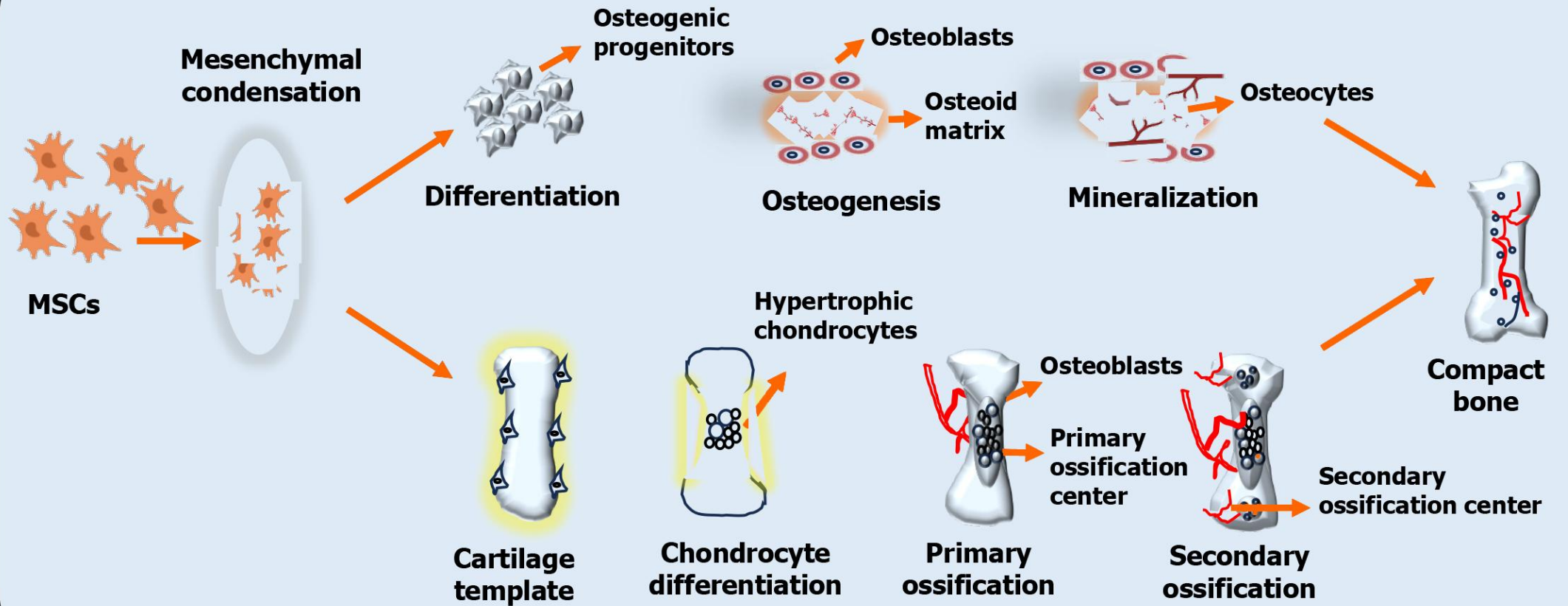




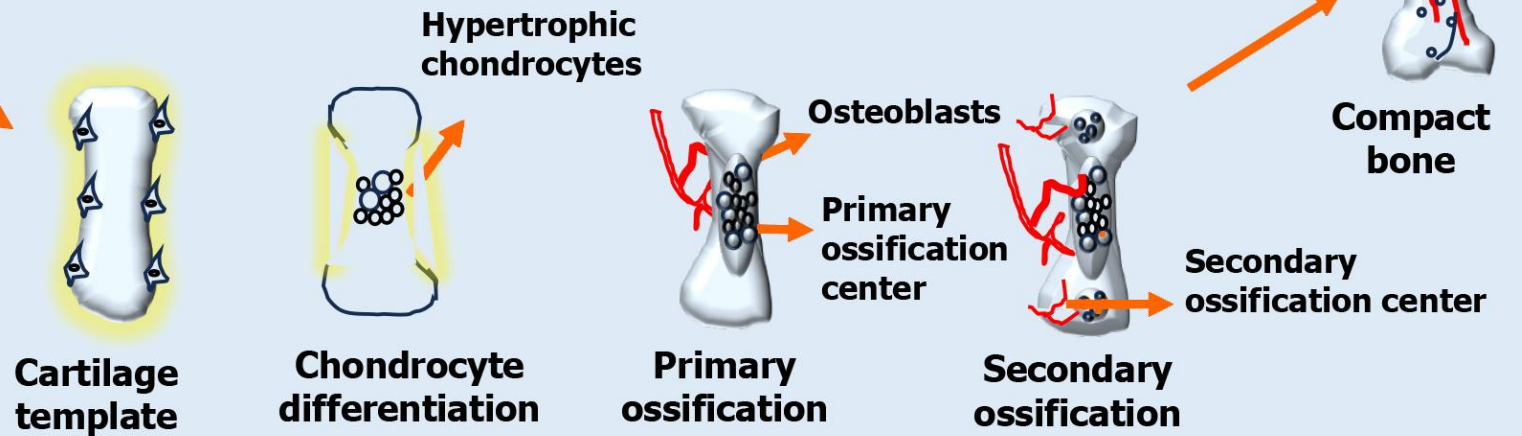
Medical Biology



Osteogenesis

A Intramembraneous ossification



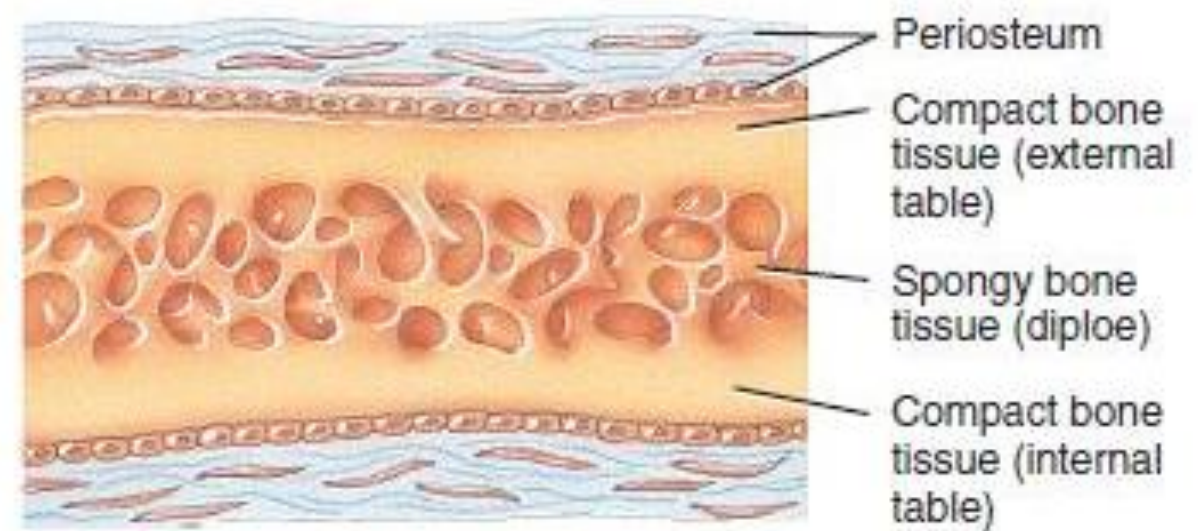
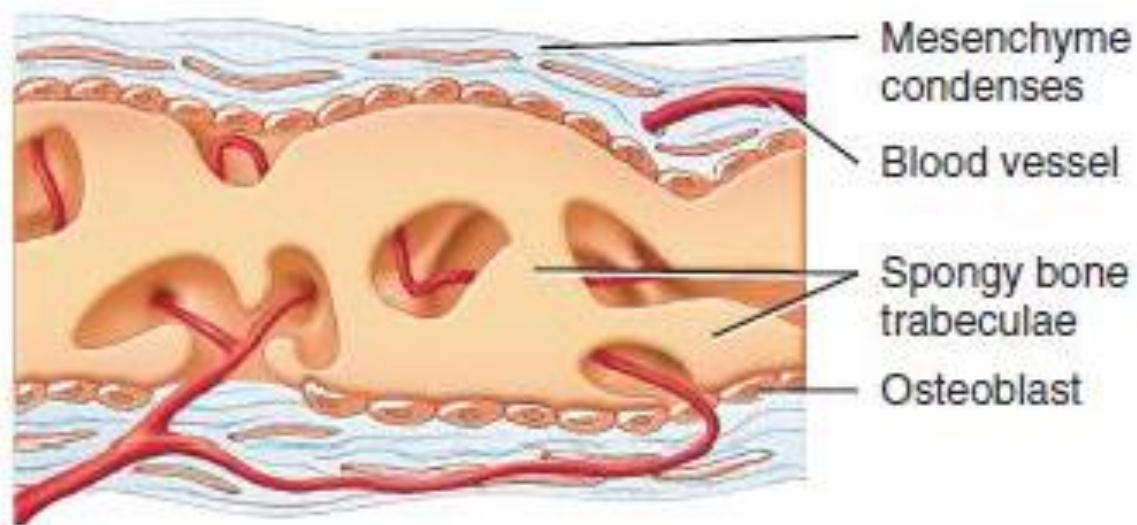
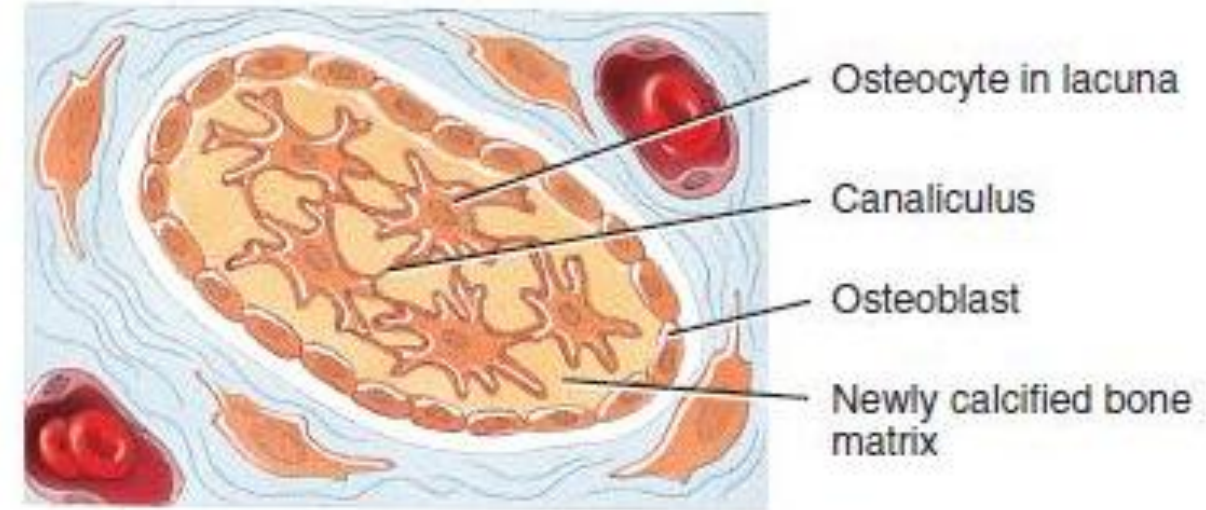
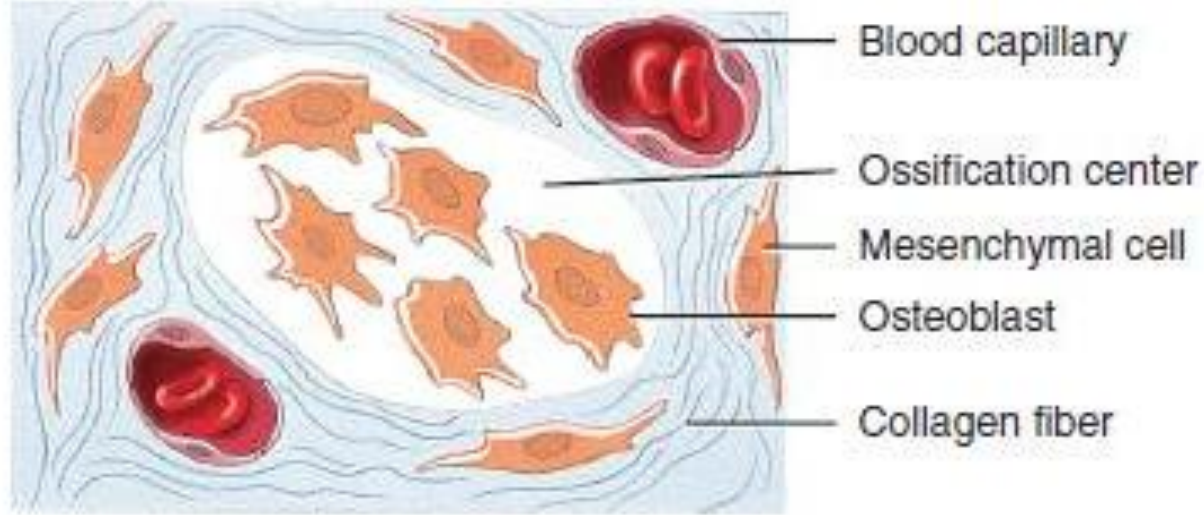
B Endochondral ossification



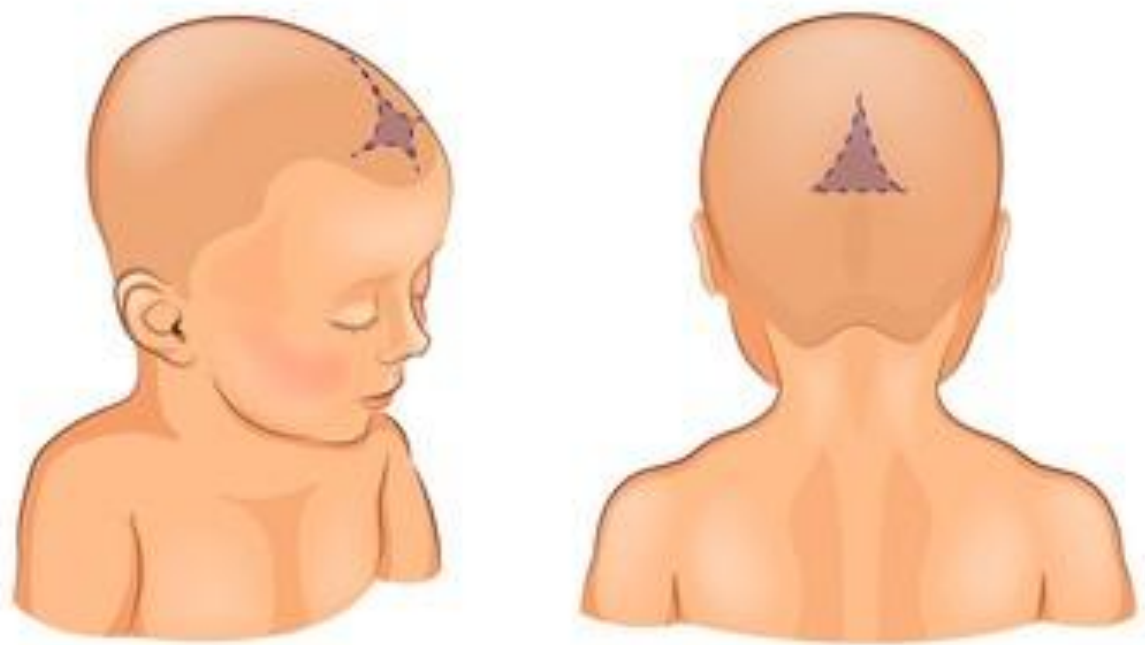


➔ Ossification begins around the 6th -7th week of embryonic life. At this time the embryonic skeleton is made of fibrous membranes and hyaline cartilage.

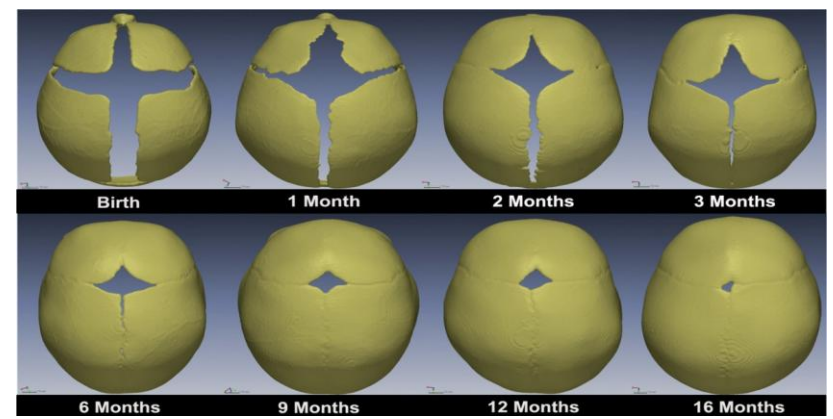
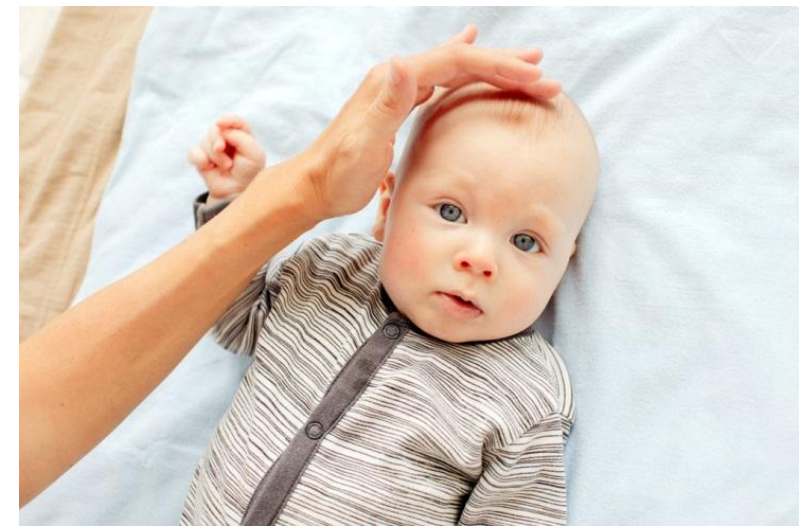Intramembranous Ossification



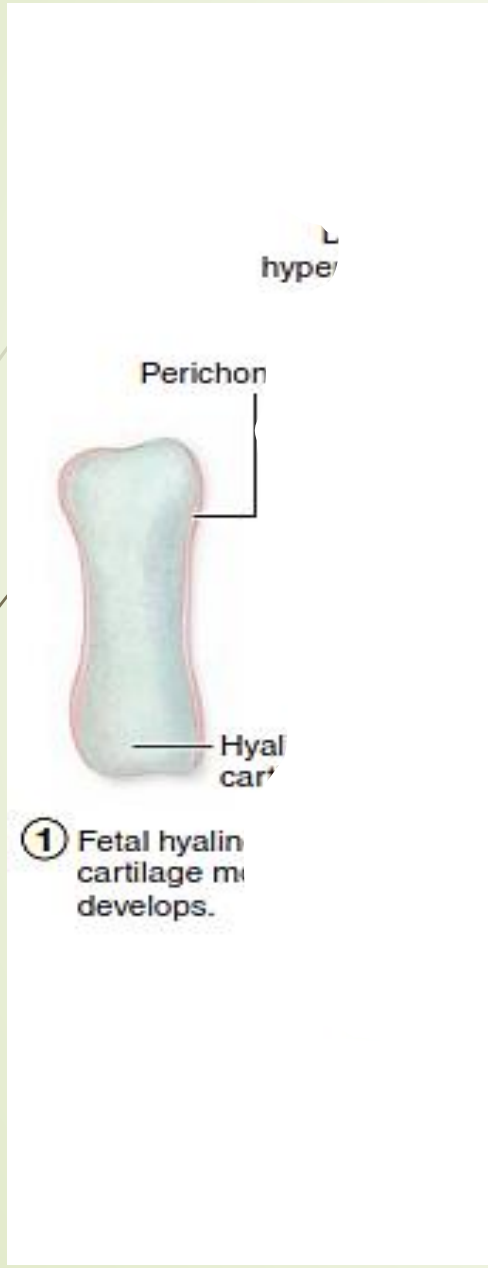FONTANELLE

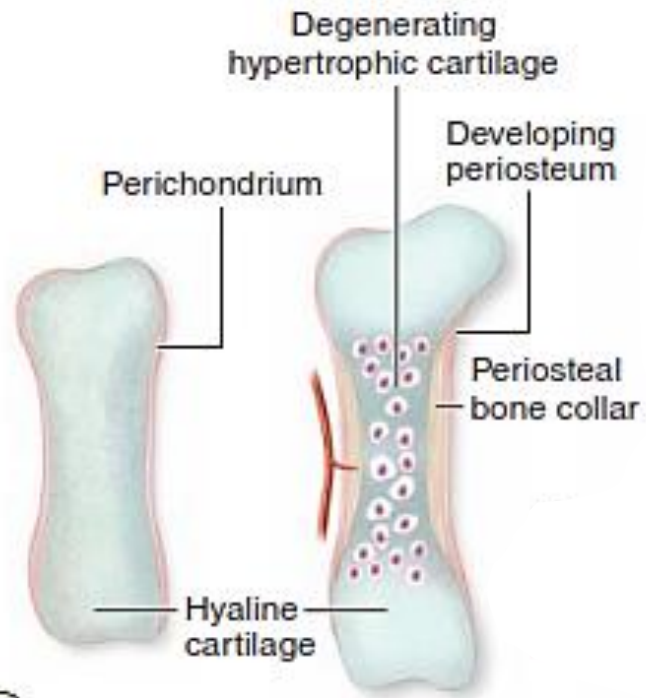


shutterstock.com • 769539667

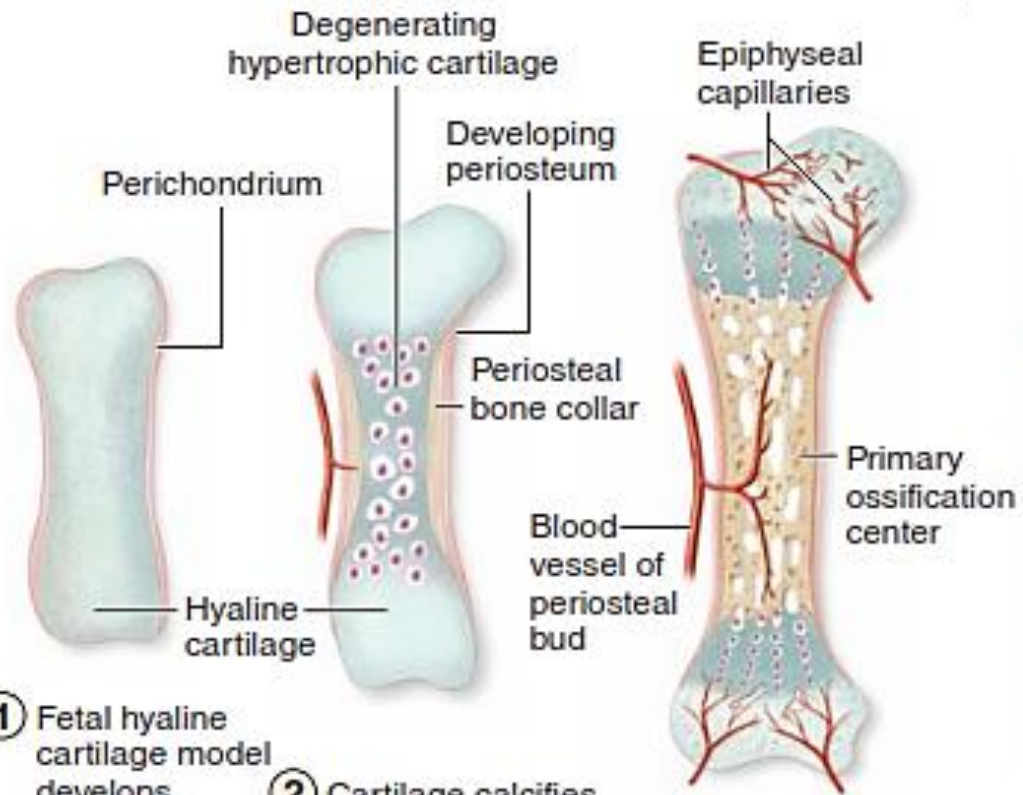


Endochondral ossification



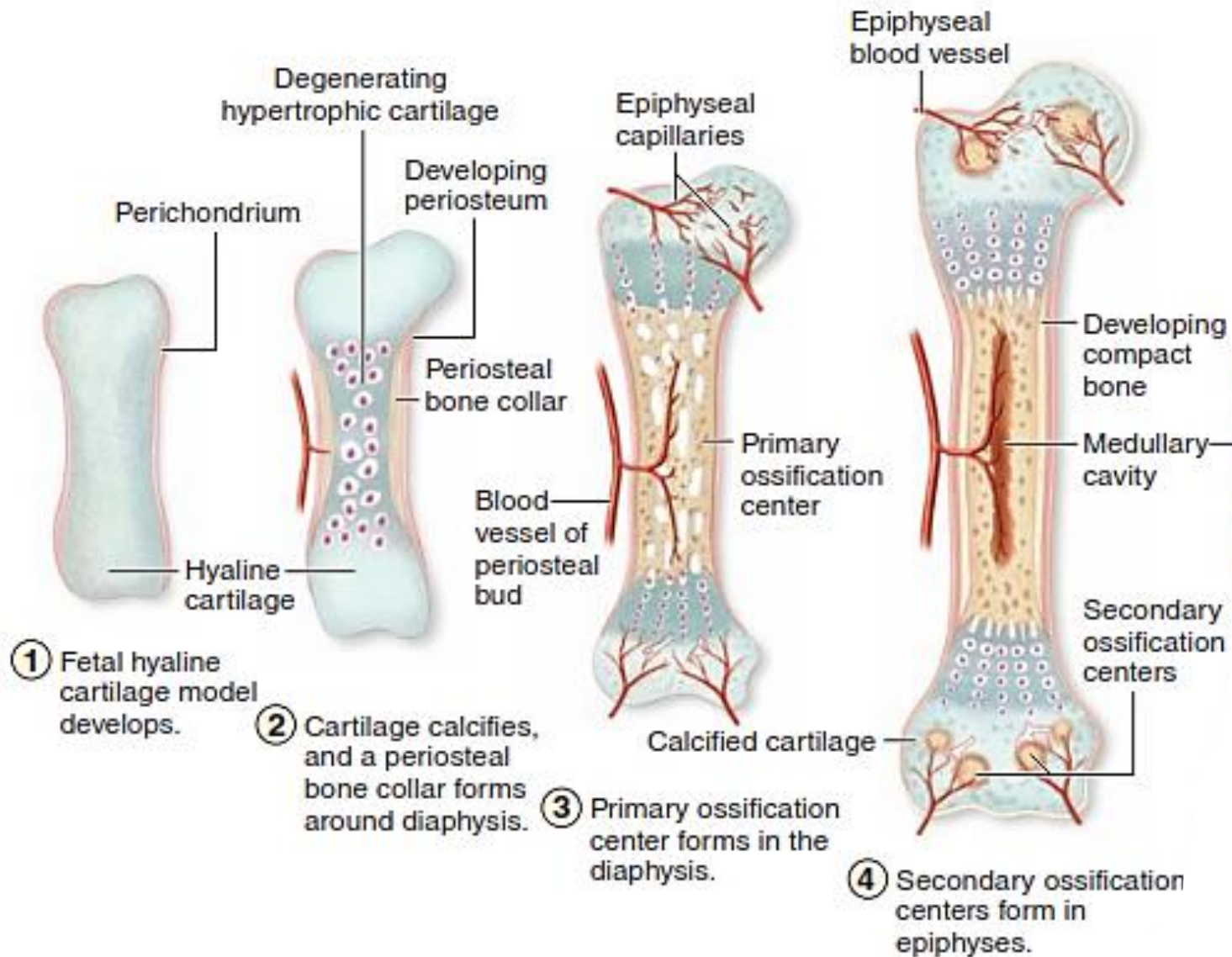


- ① Fetal hyaline cartilage model develops.
- ② Cartilage calcifies, and a periosteal bone collar forms around diaphysis.

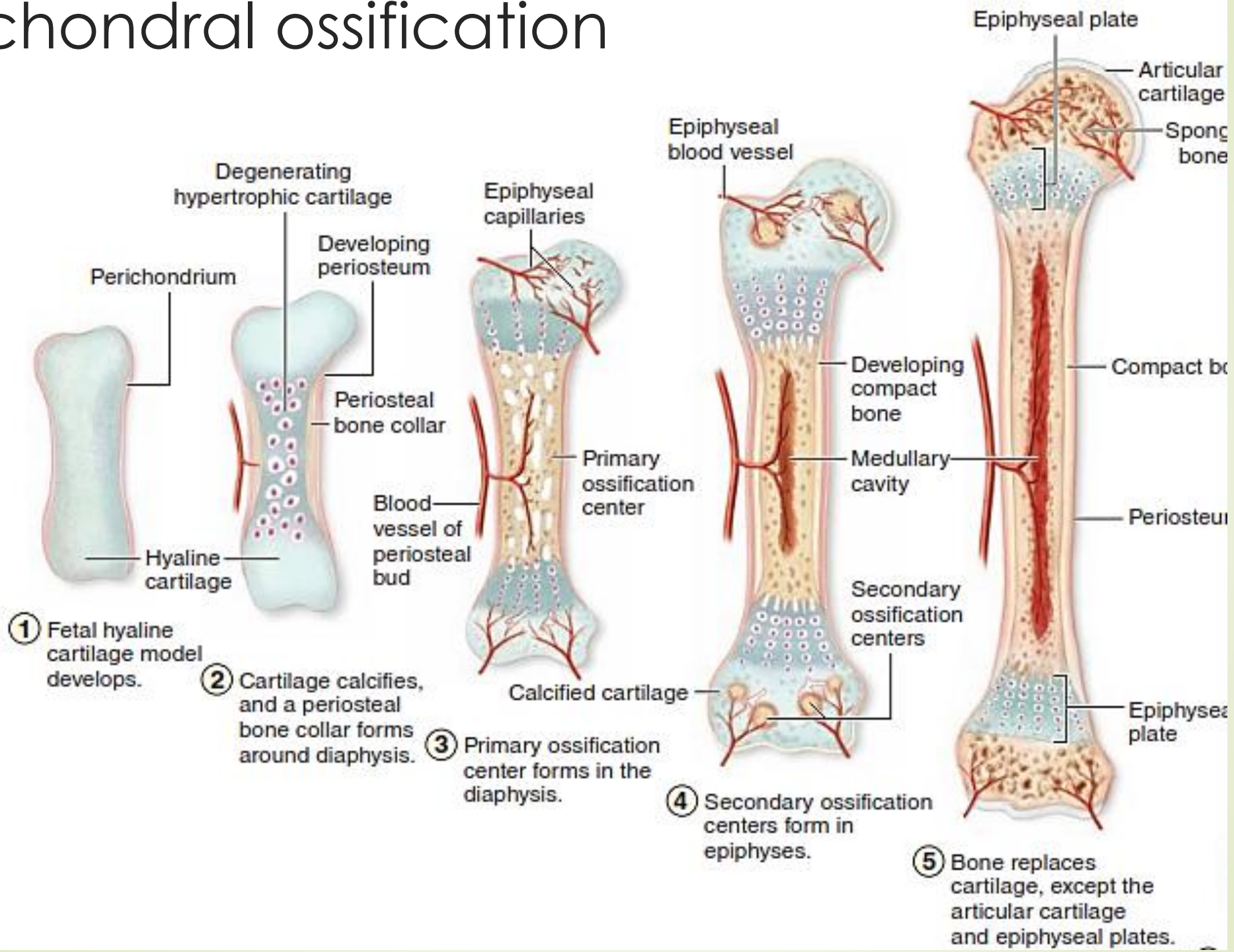


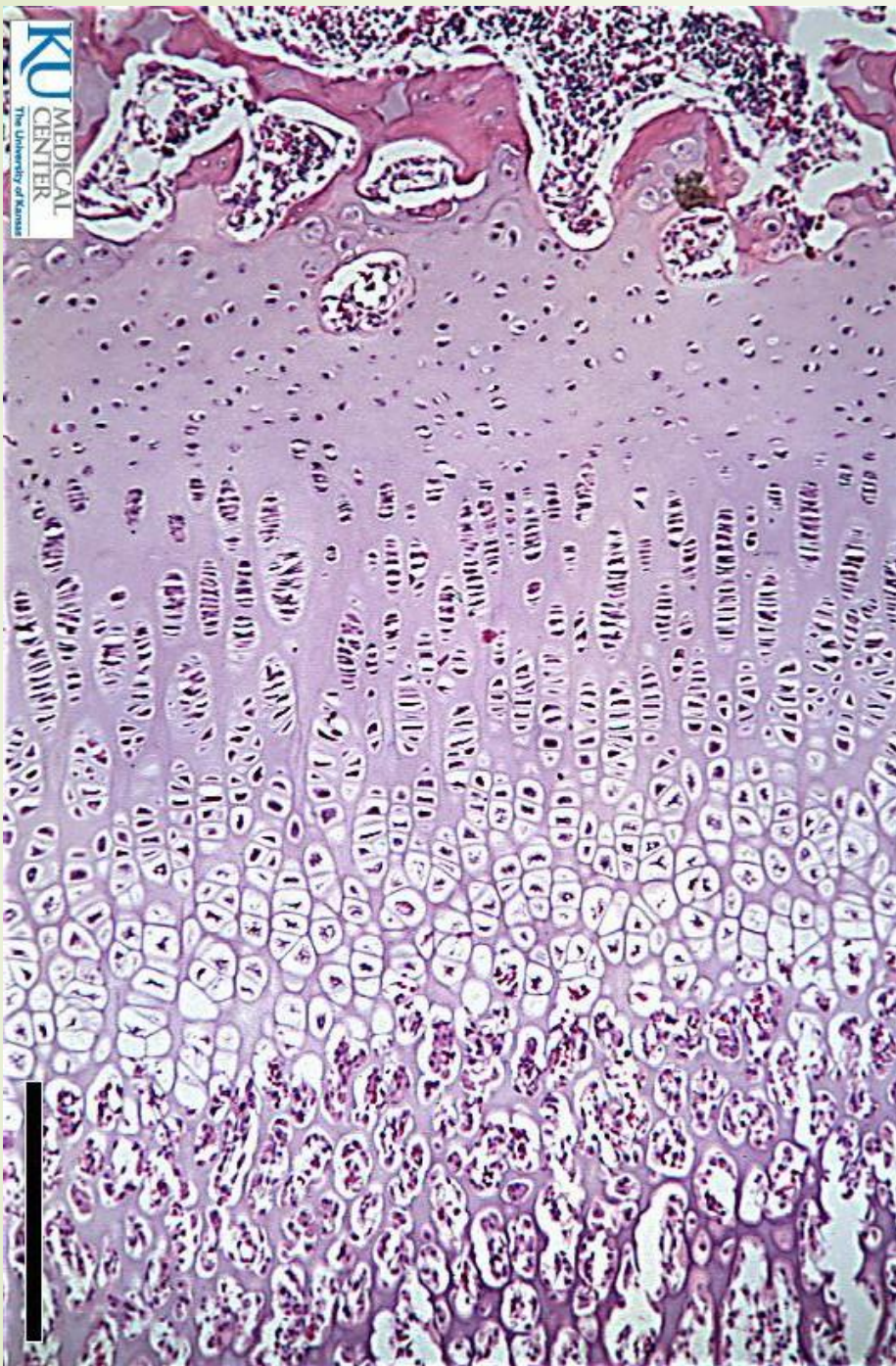
- ① Fetal hyaline cartilage model develops.
- ② Cartilage calcifies, and a periosteal bone collar forms around diaphysis.
- ③ Primary ossification center forms in the diaphysis.

Endochondral ossification



Endochondral ossification





Resting zone

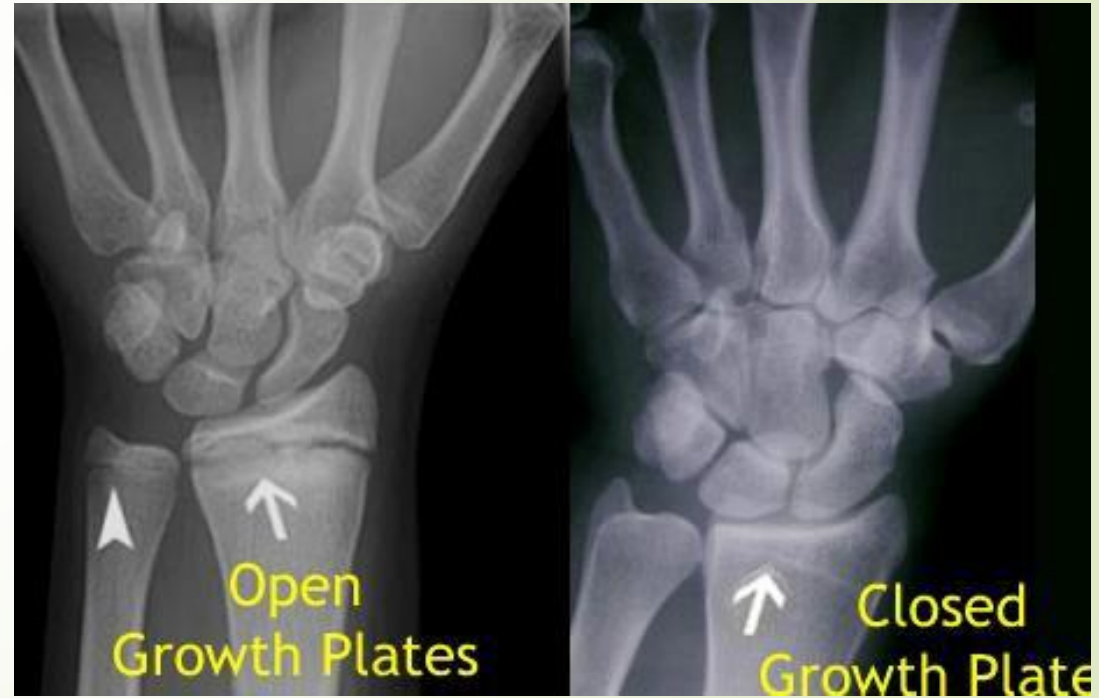Proliferative

Hypertrophic

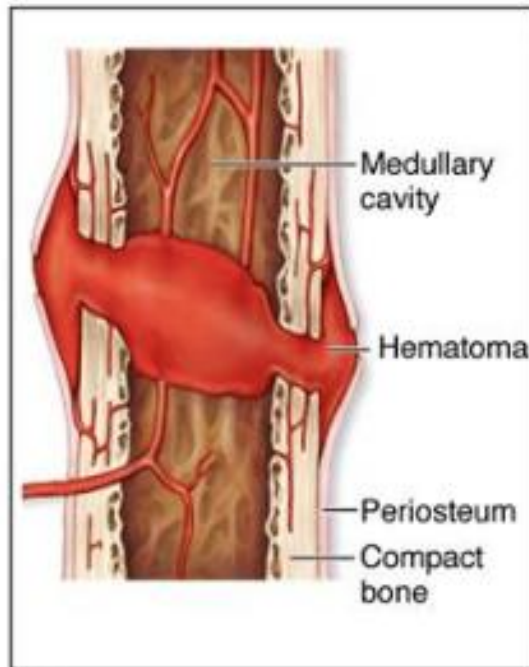
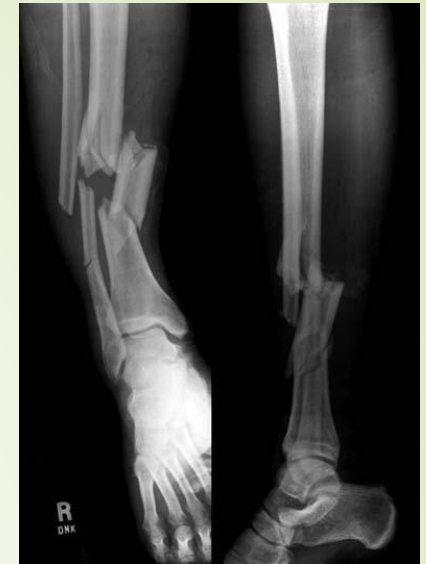Calcification

Ossification

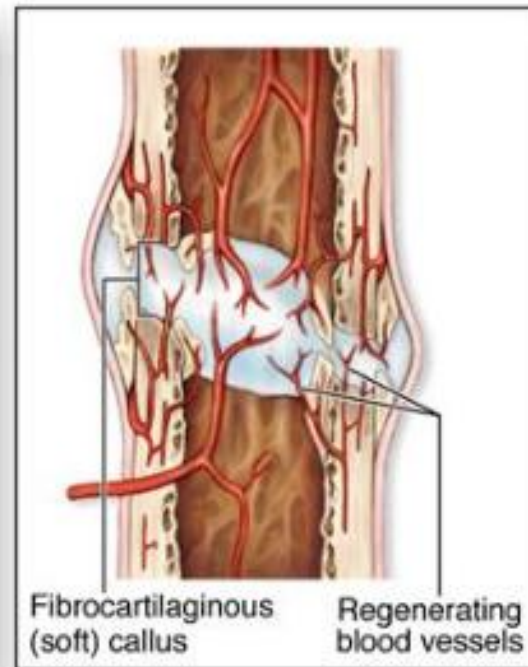
EPIPHYSEAL CARTILAGE (GROWTH PLATE)



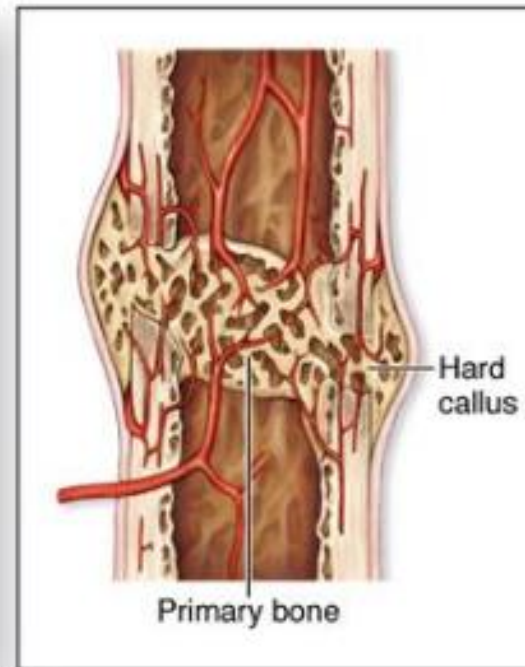
Fracture Repair



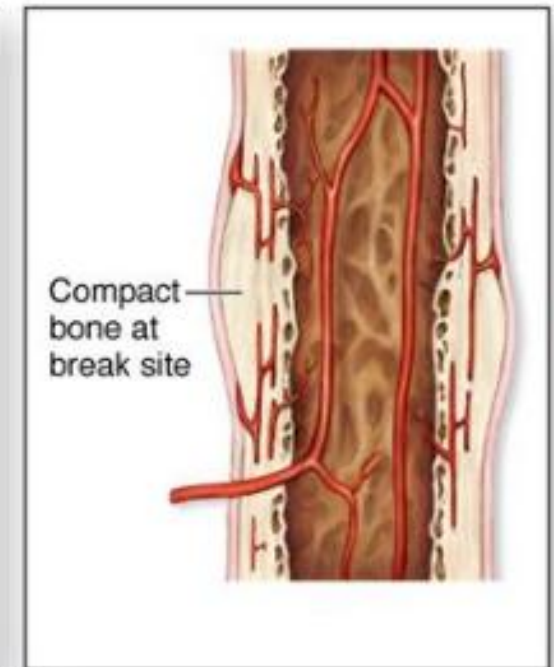
① A fracture hematoma forms.



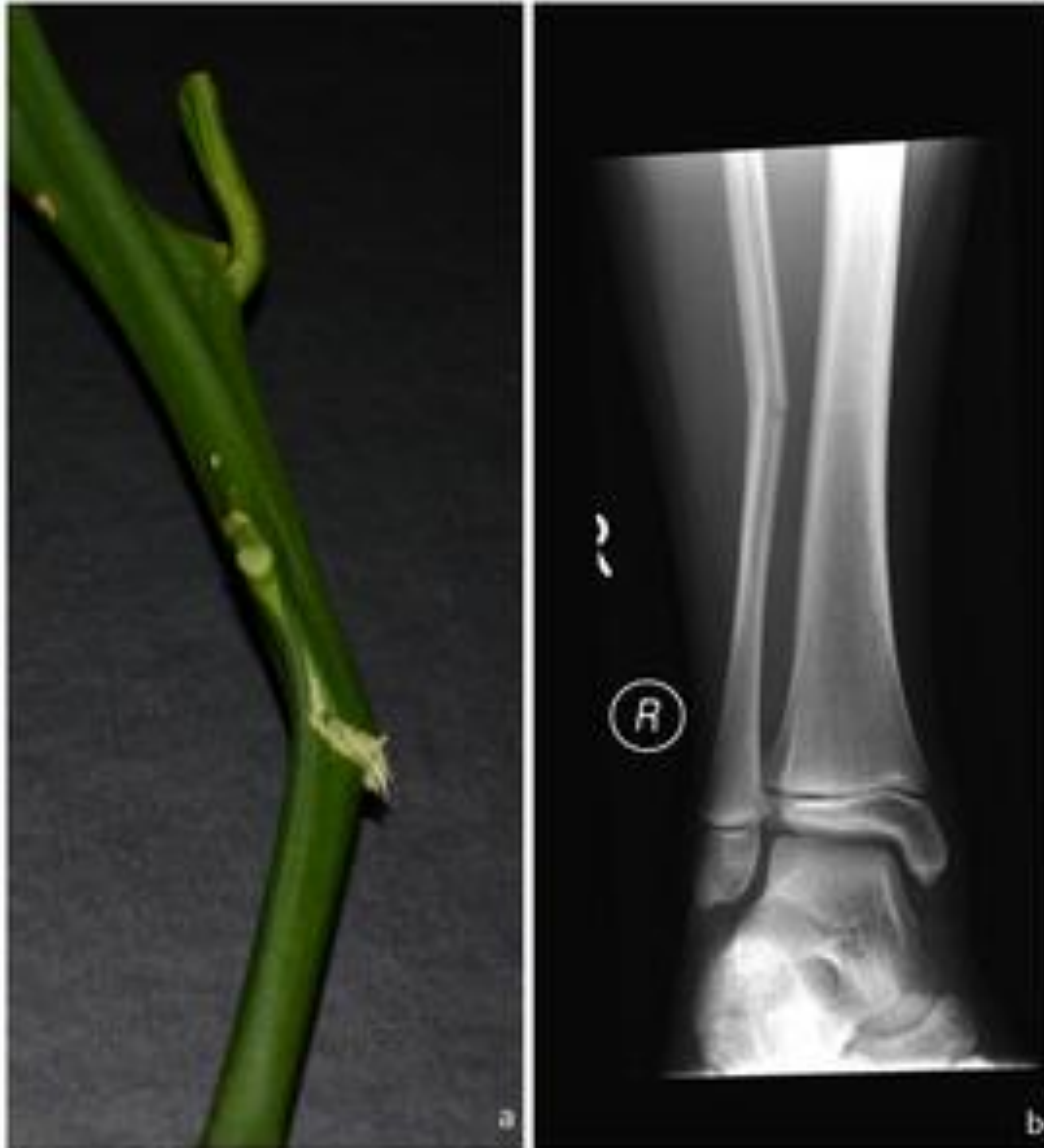② A fibrocartilaginous (soft) callus forms.



③ A hard (bony) callus forms.

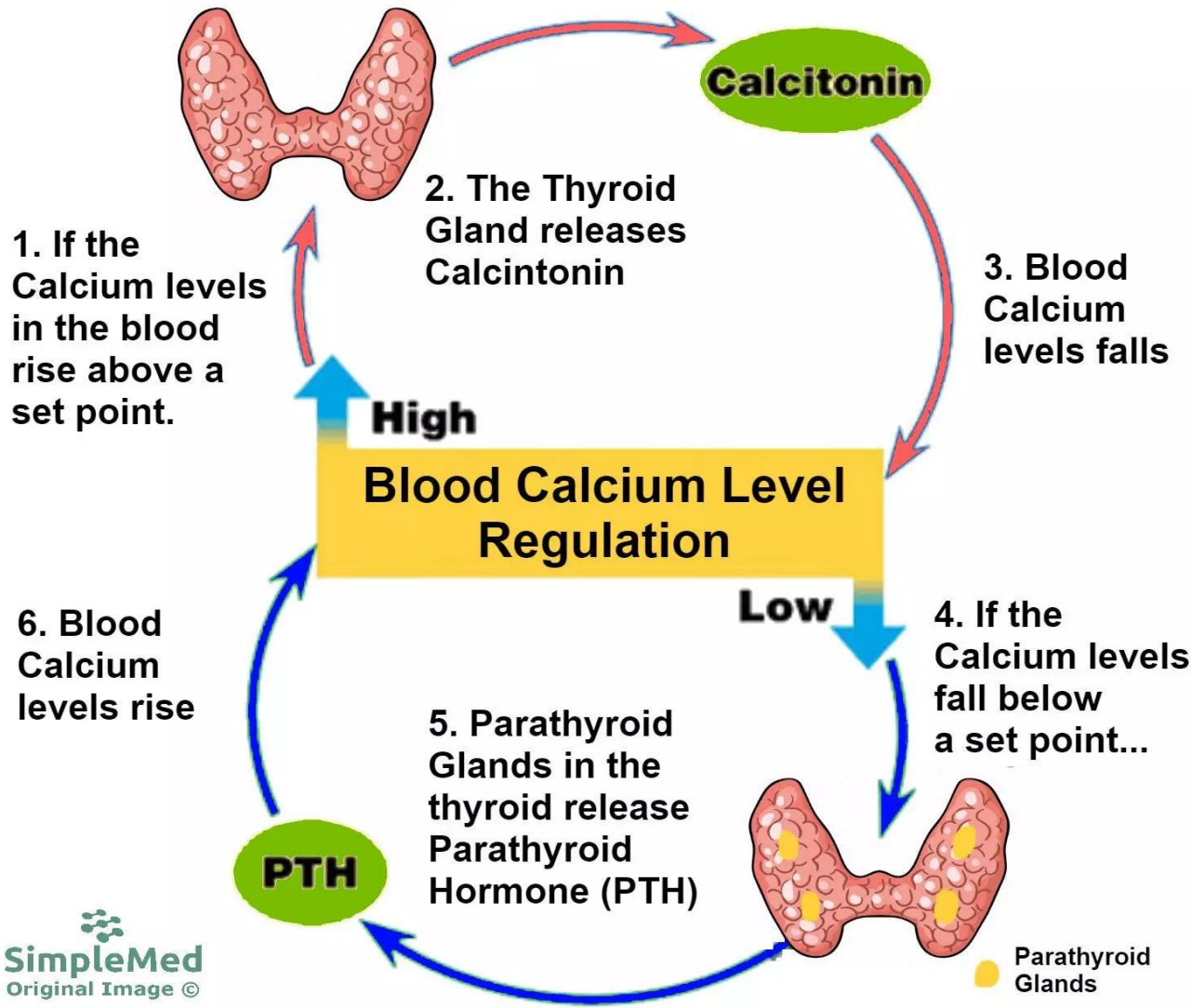


④ The bone is remodeled.

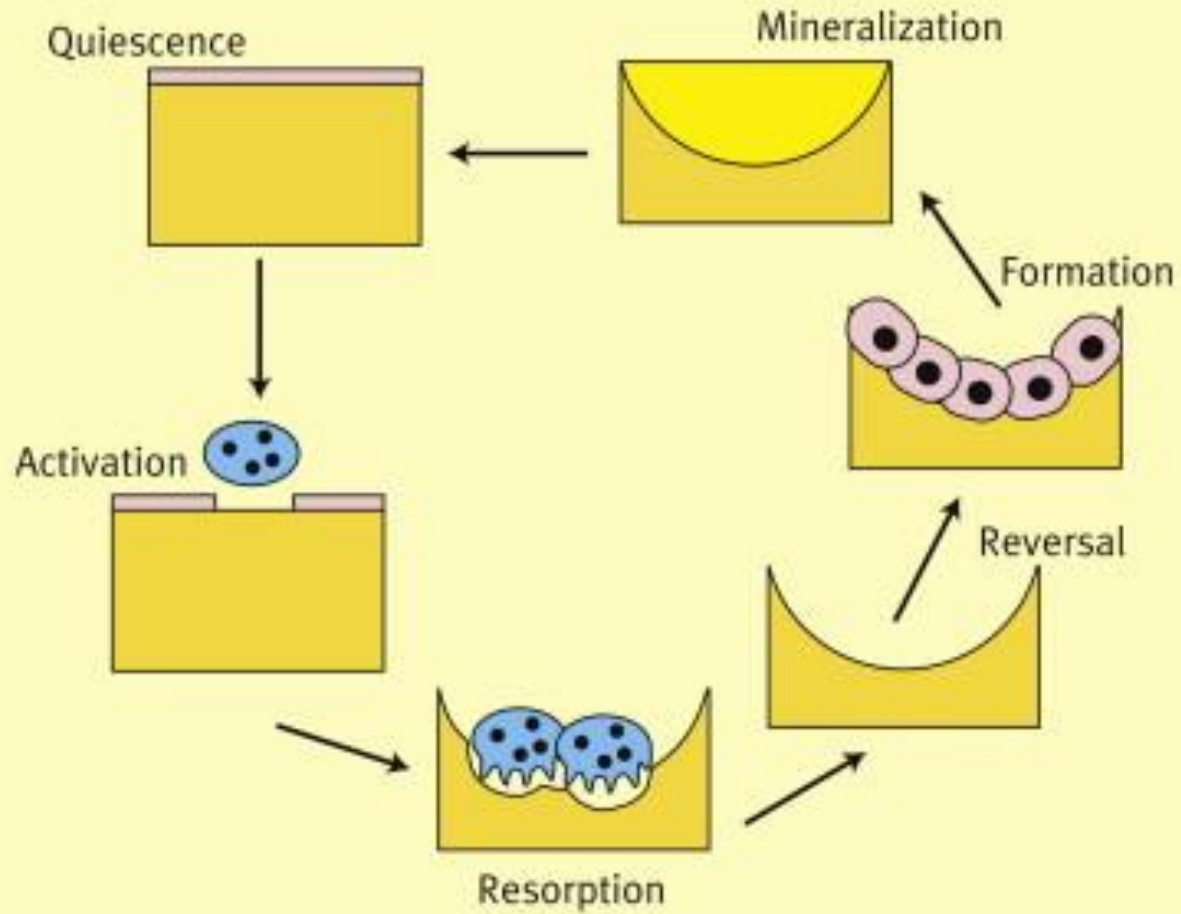


Green stick fracture

Metabolic Role of Bone



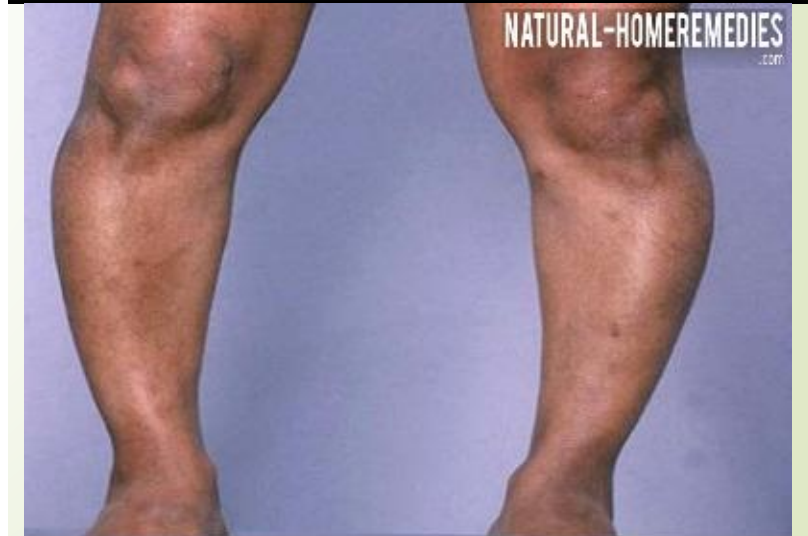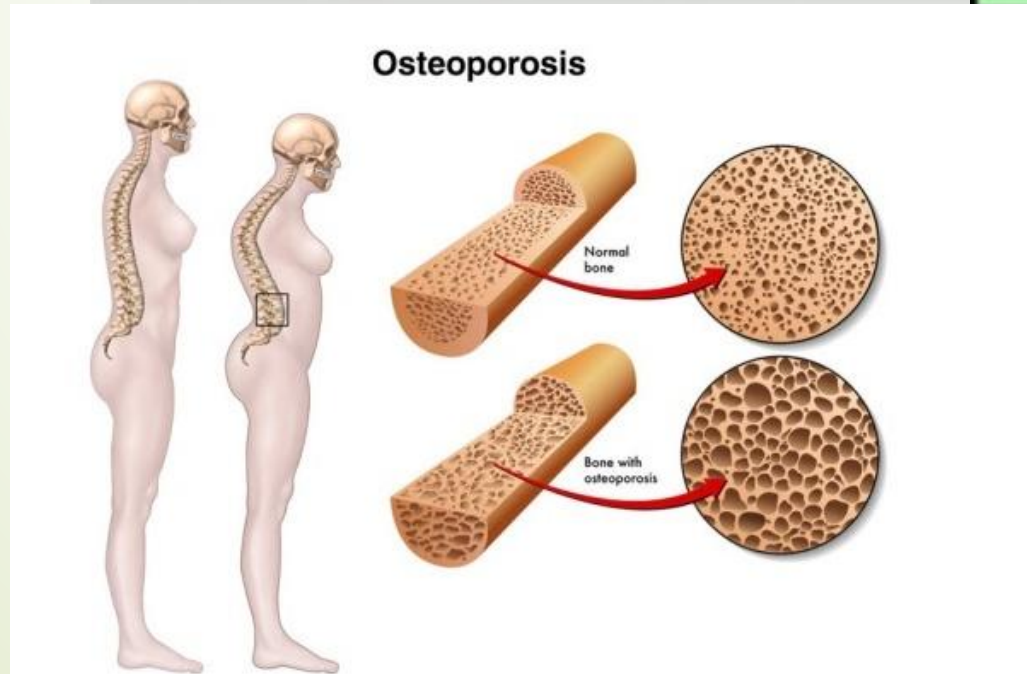
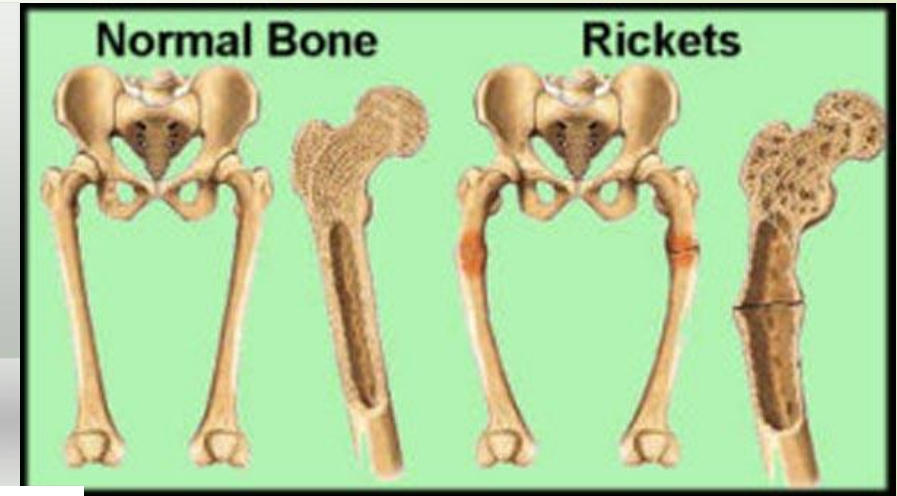
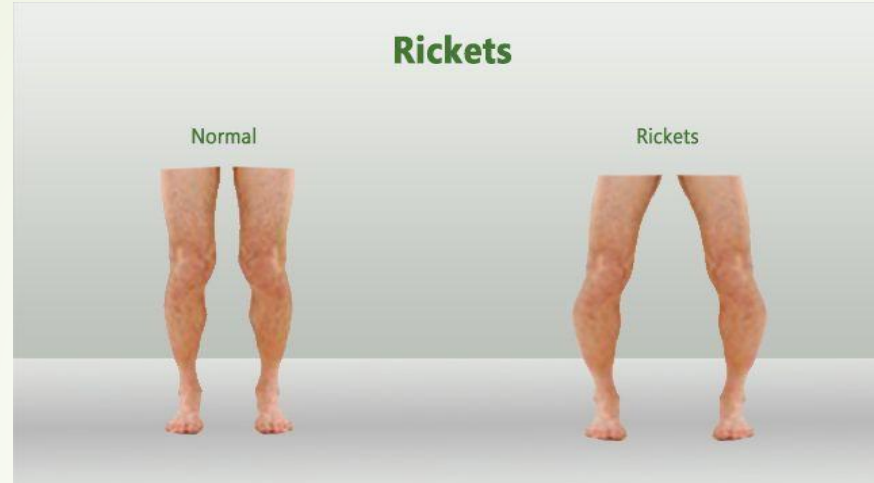Key stages of bone remodelling cycle



Bone Remodeling

Clinical notes:

- Rickets
- Osteomalacia
- osteoporosis



Osteomalacia is softening of bones caused due to the deficiency of vitamin D

THANK YOU