

# Parasitology

## Protozoa

Dr. Farah Tareq

### Lecture 4: Intestinal protozoa

#### Lumen – dwelling Flagellates

- ☒ Protozoa with one or more thread like extension of ectoplasm known as flagella.
- ☒ Flagellum, contains an axial structure (axoneme), arising from parabasal body, associated with kinetoplast.
- ☒ Flagellate of blood and tissues: (hemoflagellates) like *Trypanosoma* and *Leishmania*.
- ☒ Lumen – dwelling flagellates (intestinal & urogenital tracts flagellates):  
*Giardia lamblia*, *Dientamoeba fragilis*, *Chilomastix mesnili*, *Trichomonas hominis* (enteric), *Trichomonas tenax* (oral), *Trichomonas vaginalis* (urogenital)

#### *Chilomastix mesnili*

Is a non-pathogenic flagellate (commensal) with worldwide distribution? Its life cycle is similar to that of *Giardia lamblia*. Its trophozoites and cysts found commonly in colon.

#### Trophozoites:

- Rounded anteriorly, spirally twisted to a tapering end posteriorly.
- 20 µm long.
- One long, 2 short free flagella.
- One delicate flagellum within cytostome (mouth-like opening).
- Two fibrils at the margin of the cytostome.

#### Cyst:

- Lemon-shaped.
- 7-10 µm long X 4-6 µm wide.
- Cytostome with 2 curved fibrils.
- One nucleus.

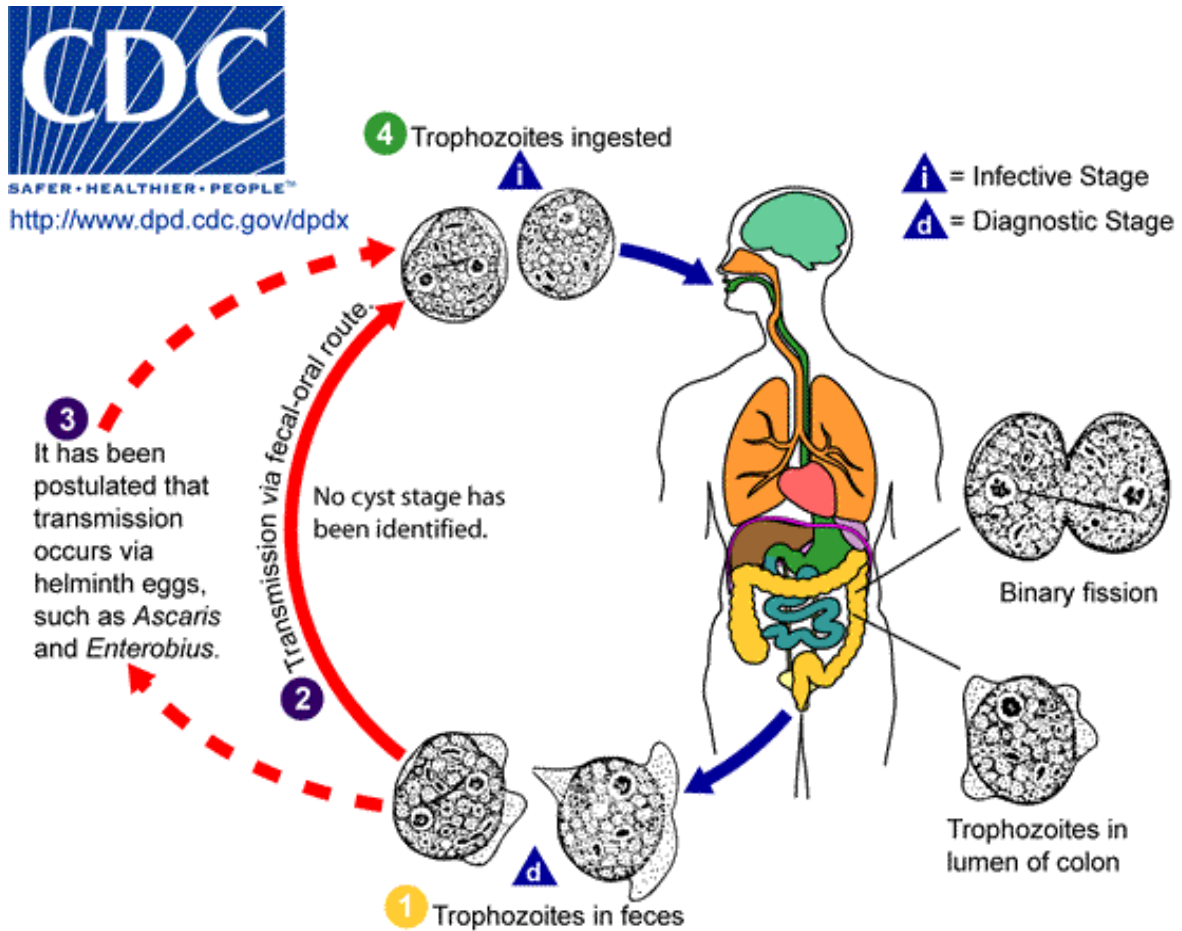
#### *Dientamoeba fragilis*

Despite its name, *Dientamoeba fragilis* is not an amoeba but a flagellate. This protozoan parasite produces **trophozoites only**; cysts have not been identified. This protozoan commensal in colon and may occasionally produce infection. Infection may be either symptomatic or asymptomatic.

#### Trophozoite:

- Actively motile by 2 flagella.
- 5-12 µm in diameter.
- Have hyaline pseudopodia.
- Ectoplasm & endoplasm distinct.
- 1-2 nuclei, with no chromatin at the nuclear membrane.
- Central karyosome as 4 distinct granules.

## Life Cycle:



To date, the cyst stage has not been identified in *D. fragilis* life cycle, and the trophozoite is the only stage found in stools of infected individuals (1). *D. fragilis* is probably transmitted by fecal-oral route (2) and transmission via helminthes eggs (e.g., *Ascaris*, *Enterobius* spp.) has been postulated (3). Trophozoites of *D. fragilis* have characteristically one or two nuclei (1, 4), and it is found in children complaining of intestinal (e.g., intermittent diarrhea, abdominal pain) and other symptoms (e.g., nausea, anorexia, fatigue, malaise, poor weight gain).

### Pathogenesis:

Symptoms that have been associated with infection include diarrhea, abdominal pain, anorexia, nausea, vomiting, fatigue, and weight loss.

**Diagnosis:** detection of trophozoites in permanently stained fecal smears (stool exam.)

**Treatment:** The drugs of choice are Paromomycin, tetracycline or metronidazole.

**Control:** personal hygiene.

### *Giardia lamblia* (*G. intestinalis*): (Disease: Giardiasis)

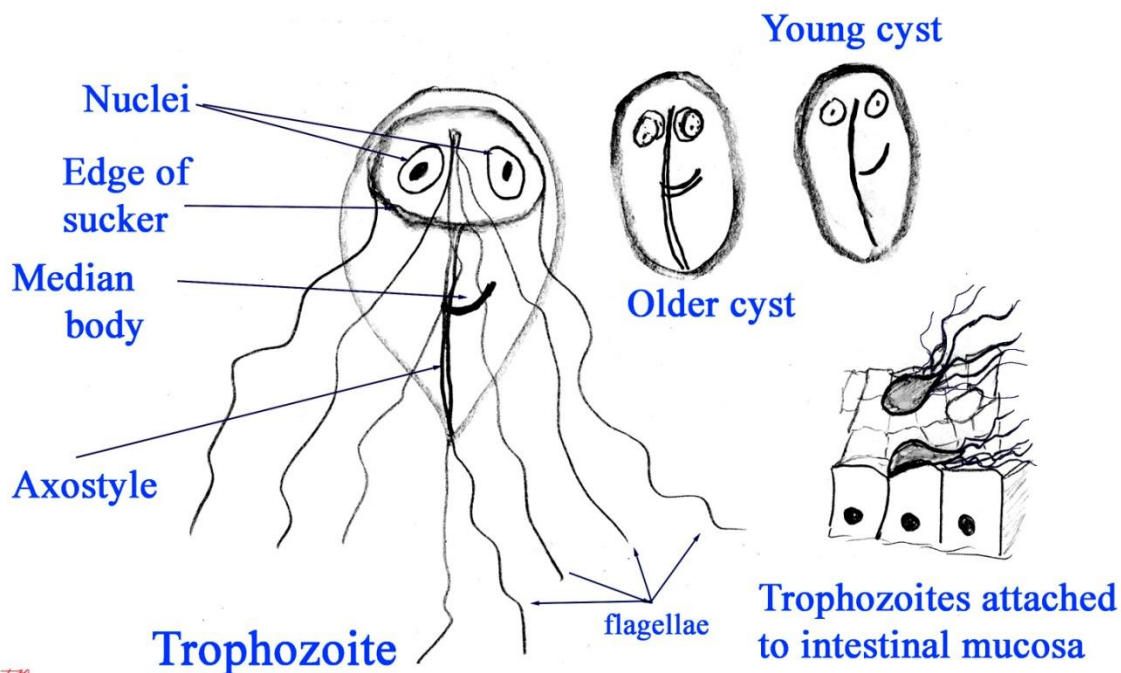
- ✓ *Giardia lamblia* is a protozoan flagellates belong to: **Phylum : Sarcomastigophora, Subphylum: Mastigophora , Family: Diplomonadida.**
- ✓ Exists in two morphological forms: a motile vegetative trophozoite, and a cyst stage.
- ✓ Both of which are seen in small intestine.
- ✓ This intestinal psrasite common in wild animals (beaver fever)

## Trophozoites:

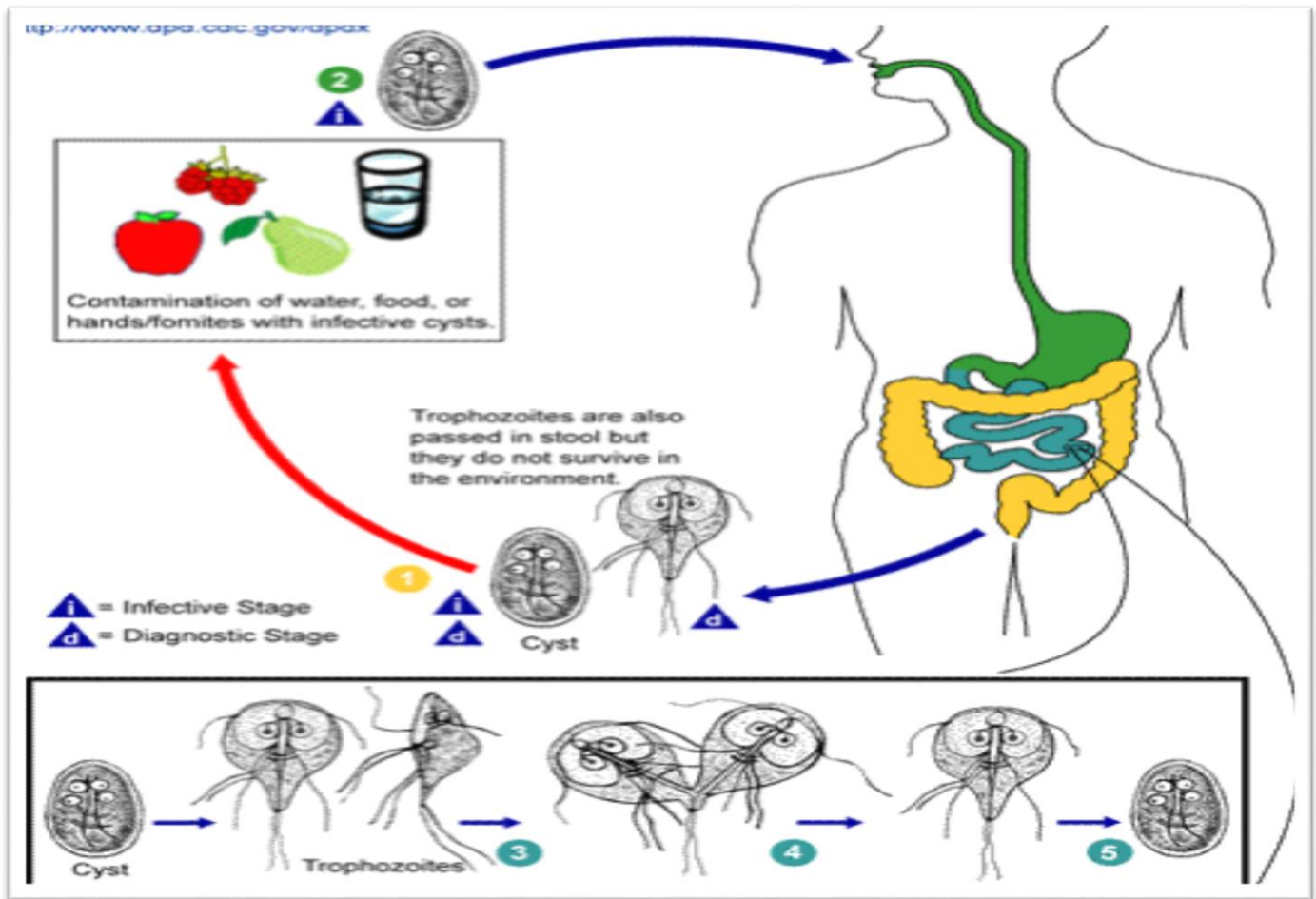
- Live on the small intestine mucosa (less frequently on the gallbladder mucosa).
- They are active, delicate, pyriform, 9–21  $\mu\text{m}$  long and 5–12  $\mu\text{m}$  wide X 2–4  $\mu\text{m}$  deep.
- Anterior end broad, posterior end narrow and tapering.
- Bilateral symmetry.
- Axoneme divided body longitudinally into 2 halves.
- Motility likened to falling leaf.
- Possess eight flagella (anterior, posterior, lateral and ventral).
- Two nuclei (large karyosome with no peripheral chromatin) – one at each side.
- Two claw-shaped median bodies.
- Their dorsal side is convex.
- The anterior part of the ventral side forms 2 hollow concave adhesive disks (sucking disk).
- Reproduction is by longitudinal binary fission of the trophozoites.

## Cyst:

- Oval (8–18  $\mu\text{m}$  X 7–10  $\mu\text{m}$ ).
- With four nuclei.
- Flagella retracted before encystations into stiff curved pairs of parallel fibrils.
- Claw-shaped median bodies.
- The cyst does not get destroyed by chlorination of water.
- Can survive several months in cold water.



## Life cycle:



- Cysts are resistant forms and are responsible for transmission of giardiasis. Both cysts and trophozoites can be found in the feces (diagnostic stages) ①.
- The cysts are hardy and can survive several months in cold water.
- Infection occurs by the ingestion of cysts in contaminated water, food, or by the fecal-oral route (hands or vomits) ②.
- In the small intestine, excystation releases trophozoites (each cyst produces two trophozoites) ③.
- Trophozoites multiply by longitudinal binary fission, remaining in the lumen of the proximal small bowel where they can be **free or attached** to the mucosa by a **ventral sucking disk = adhesive disk** ④.
- The trophozoites **do not invade tissues**, but form **pavement-like sheath (pavement membrane) covering mucosa** of small intestine. Encystation occurs as the parasites transit toward the colon. The cyst is the stage found most commonly in non-diarrheal feces ⑤.
- Because the **cysts are infectious** when passed in the stool or shortly afterward, person-to-person transmission is possible. The infection can also be transmitted during sexual intercourse.

## Pathogenesis:

- ☒ The spectrum varies from asymptomatic carriage to severe diarrhea and malabsorption.
- ☒ In humans, infection is symptomatic only about 50% of infected persons.
- ☒ The trophozoites do not invade tissues, but form pavement-like sheath covering mucosa.
- ☒ Therefore the colonization of the gut results in inflammation and villous atrophy, functional derangement of epithelium, reducing the gut's absorptive capability, reduced brush border enzymes and malabsorption.

## Acute giardiasis

- ❖ Develops after an incubation period of 1 to 14 days.
- ❖ Symptoms include:
  - Sudden **explosive watery**, foul-smelling diarrhea.
  - The stools are generally describes as loose, bulky, frothy, and/or **greasy** with no blood or mucous.
  - These symptoms accompanied by nausea, colicky epigastric pain, upper gastro-intestinal uneasiness, bloating, flatulence, vomiting, and/or prolonged belching, loss of appetite & weight.
  - The acute stage usually resolves spontaneously in 3-4 days
  - Occasionally an acute infection will persists leading to **malabsorption, steatorrhea** (excessive loss of fat in the feces), debility (loss of strength) and weight loss.
  - **steatorrhea** due mainly to uptake of bile salts by Giardia which inhibits the digestion of fats by pancreatic lipase .

## Chronic giardiasis

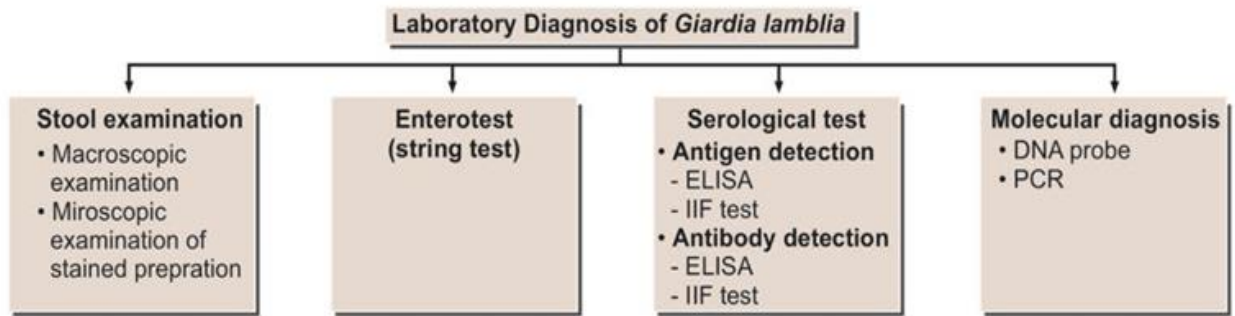
- Characterized by recurrent brief episodes of gastro-intestinal symptoms.
- Recurrent diarrhea and malabsorption (particularly of fat and carbohydrates) and debilitation.
- Anorexia accompanied by marked weight loss is sometimes associated with chronic infections.

## Post-*Giardia* Lactose Intolerance

- ❖ Some patients may present with a lactose intolerance during active *Giardia* infections which can persist after parasite clearance.
- ❖ This clinical manifestation is due to the parasite-induced lactase deficiency and is most common in ethnic groups with a predisposition for lactase deficiency.
- ❖ Lactase is an enzyme that breaks down lactose, a sugar found in milk, to monosaccharides which can be absorbed.
- ❖ This lactose intolerance syndrome should be considered in persons who still present mushy stools and excessive gas following treatment, but have no detectable parasites.

## Diagnosis:

---



Flowchart 4.1: Laboratory diagnosis of *Giardia lamblia*

**Treatment:** including metronidazole and tinidazole.

### Epidemiology:

- ❖ Cyst infective when passed with feces.
  
- ❖ The disease transmitted by: Fecal-oral route. Direct person to person contact. Ingestion of contaminated food or water. Waterborne outbreaks due to contamination of municipal water supplies.
  
- ❖ The infection occurs more frequent in children, in institutions and in large families.
- ❖ All ages are affected. Infants and young children have an increased susceptibility to giardiasis.
- ❖ The age-specific prevalence of giardiasis is highest in childhood and adolescence and begins to decline thereafter.

**Control:** 1. Improve personal hygiene 2. Public sanitation. 3. Adequate water purification methods.

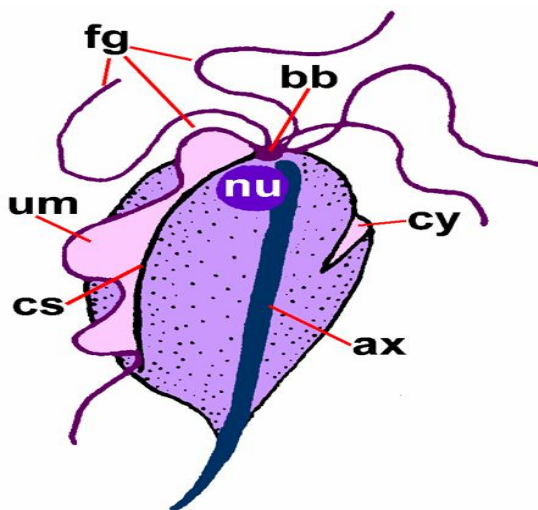
## Lec 5: *Trichomonas* spp.

- ☒ Flagellated protozoa of the intestinal and urogenital tract,
- ☒ Present in trophozoites stage only (no cyst stage).
- ☒ They are rounded anteriorly and pointed posteriorly.
- ☒ The axostyle arises near the median anterior pole and protrude from posterior end.
- ☒ Five flagella emerge from a basal body at the anterior pole, four freely extend forwards and one extends backwards, forming the outer edge of the undulating membrane.
- ☒ Small cytostome present in one side of the anterior end; spherical nucleus also present near the anterior pole.

### *Trichomonas vaginalis*

(trichomonads vaginitis or trichomoniasis vaginalis).

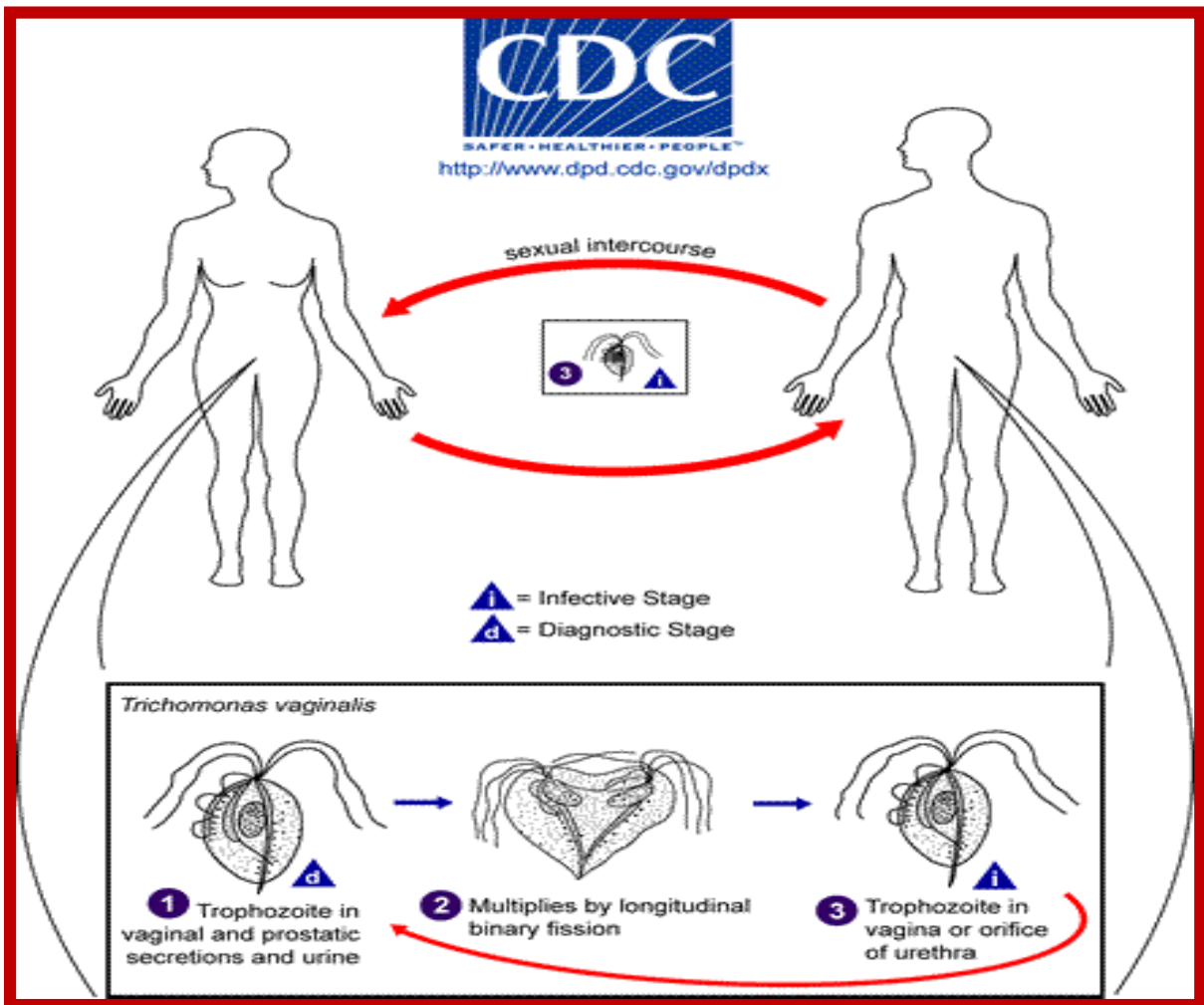
*Trichomonas vaginalis*, a flagellate, is the most important pathogenic protozoan of human's venereal disease.



#### Trophozoite:

- Pear shaped protozoon about 10–20  $\mu\text{m}$  long and 2–14  $\mu\text{m}$  wide.
- The undulating membrane, extending only about half the distance to the posterior end.
- Jerky non directional motility.
- Larger than *T. hominis*.
- Axostyle protrudes well beyond posterior end.
- Transmission is by sexual intercourse.

## Life Cycle:



The trophozoites of *Trichomonas vaginalis* resides in the female lower genital tract and the male urethra and prostate **1**, where it replicates by binary fission **2**. **The parasite does not appear to have a cyst form**, and does not survive well in the external environment. The infection is transmitted among humans, its only known host, primarily by sexual intercourse **3**. It also can be transmitted by sharing: contaminated bedding & sheets, toilet seats and damp towels. Babies may infect while passing through birth canal.

## Pathogenesis:

*Trichomonas vaginalis*, despite its name, infects both men and women. The incubation period is 5 to 28 days.

*Trichomonas vaginalis* infection **in women** is frequently symptomatic, which includes:

- ☒ Vaginitis with a purulent frothy discharge (yellowish or greenish) is the main symptom,
- ☒ Vulvar and cervical lesions due to petechial haemorrhage (**strawberry cervix**).
- ☒ **Frothy discharge and strawberry cervix are classic findings on exam.**

- ☒ Itching, burning or pain in the vagina and musty vaginal odor.
- ☒ Abdominal and groin pain.
- ☒ Dysuria (painful urination) followed by urinating more than usual
- ☒ Dyspareunia (pain or discomfort during sexual intercourse).
- ☒ Elevated vaginal pH, amines and secretion of lactic acid and acetic acid.

**In men**, the infection is frequently asymptomatic; occasionally, urethritis, epididymitis, and prostatitis can occur. Symptoms include thin whitish urethral discharge and dysuria.

### Diagnosis:

1. Microscopic examination of wet mounts of **URETHRAL** or **VAGINAL** discharges or **URINE** sample to detecting actively motile organisms.
2. **Pap Smears** are sometimes used to confirm diagnosis. The **Papanicolaou test** (also called **Pap smear, Pap test, cervical smear, or smear test**) is a screening test used to detect potentially pre-cancerous and cancerous processes in the endocervical canal of the female reproductive system. The test was invented by and named after the prominent **Greek** - American doctor Georgios Papanikolaou. The cells are collected from the outer opening of the cervix of the uterus and the endocervix examined under a microscope to look for abnormalities. The test aims to detect potentially pre-cancerous changes (called cervical intraepithelial neoplasia (CIN) or cervical dysplasia), which are usually caused by sexually transmitted human papillomaviruses. The test remains an effective, widely used method for early detection of pre-cancer and cervical cancer. The test may also detect infections (such as **trichomoniasis**) and abnormalities in the endocervix and **endometrium**.

**Treatment:** The drugs of choice for treatment are metronidazole and tinidazole.

### Control:

1. Personal hygiene.
2. Treating of infected persons.
3. Avoiding of coitus with infected partner.

### ***Trichomonas tenax***

- Present in **trophozoite** stage only. Commensal in mouth
- Smaller than *T. hominis*.
- Undulating membrane short.
- Axostyle protrudes well beyond posterior end.

### ***Trichomonas hominis***

- Trophozoite stage only (no cyst stage). Commensal in colon.
- Marginal flagellum extends beyond posterior end.

- Axostyle protrudes short distance beyond posterior end.

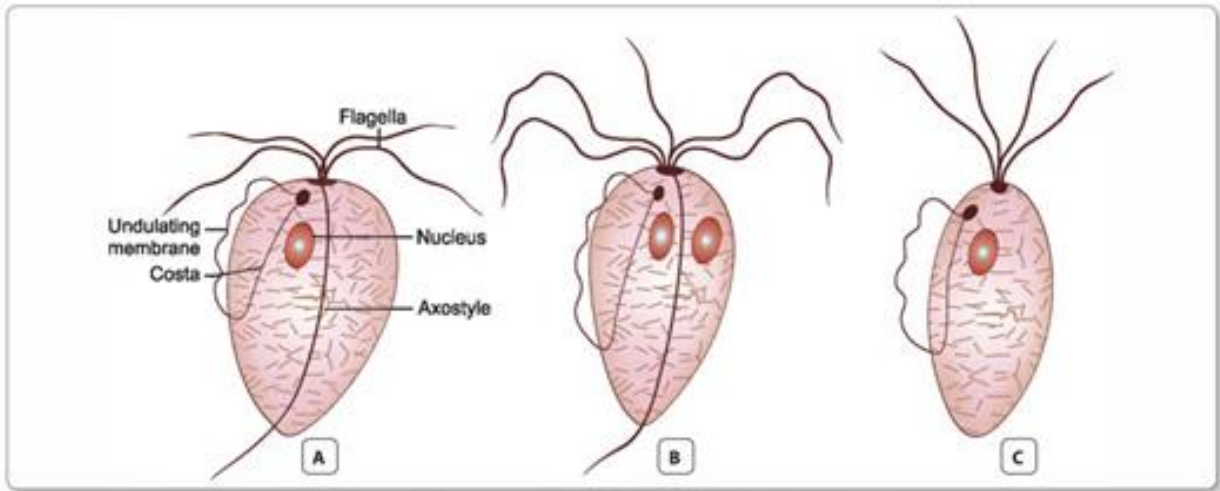


Fig. 4.4: Trichomonas species. A. *T. vaginalis*; B. *T. hominis*; C. *T. tenax*