Dr. Ali Mohsin

Anatomy of the Breast

The breasts, consisting of mammary glands, superficial fascia, and overlying skin, are in the pectoral region on each side of the anterior thoracic wall. The breast exists in both males and females. It is rudimentary in all children and adult males, so, here we study the breast of the adult female.

Breast components

The breasts consist of 3 elements: skin, mammary glands, and connective tissue.

The ***skin*** over the breast is part of the skin on the thoracic wall. It shows a central circular pigmented elevation called the **nipple**, surrounded by a circular pigmented area called the **areola**.

The ***mammary glands*** are modified apocrine sweat glands in the superficial fascia anterior to the pectoral muscles. The mammary glands consist of a series of ducts and associated secretory lobules (compound tubuloalveolar glands). These converge to form 15 to 20 **lactiferous ducts**, which open independently onto the nipple. Just before opening on the nipple, each lactiferous duct has a dilation called the “lactiferous sinus”.

A well-developed, ***connective tissue*** stroma surrounds the ducts and lobules of the mammary gland. In certain regions, this condenses to form well-defined ligaments, the **suspensory ligaments (Cooper’s ligaments)** of breast, which extend from the pectoral deep fascia to the dermis of the skin, and act to support the breast. The suspensory ligaments divide the breast into many compartments, called breast lobules. Each lobule contains fat and a mammary gland, except for the lobules in the peripheral regions which contain only fatty tissue.

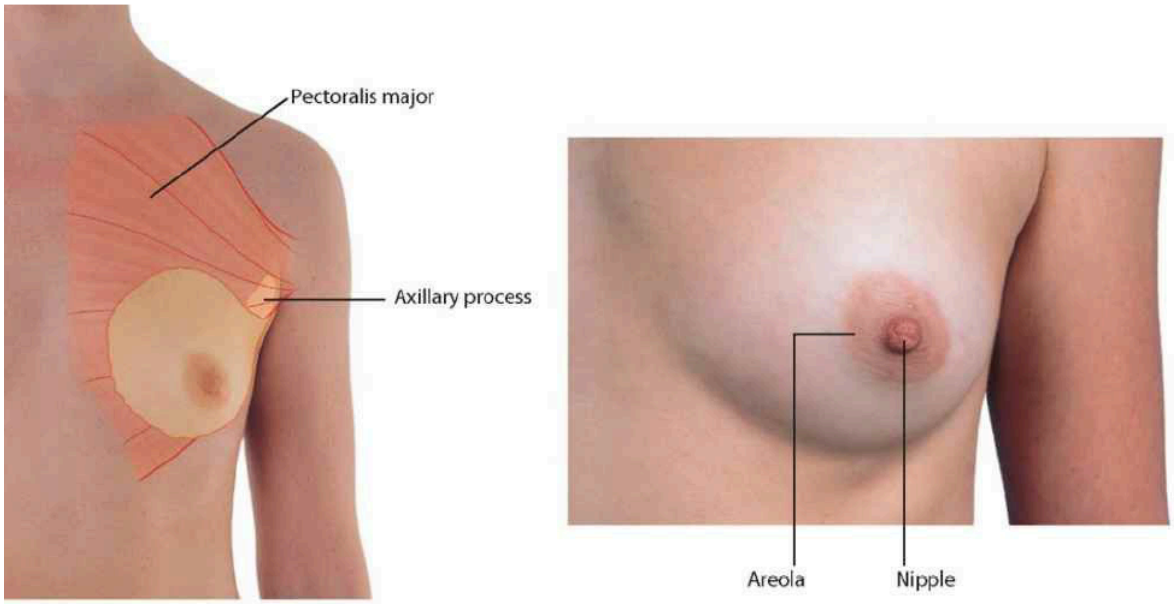

Anterior view

In nonlactating women, the predominant component of the breasts is fat, while glandular tissue is more abundant in lactating women. Adipose tissue within the breast contributes largely to the contour and size of the breast.

Location and position

The breast lies on the deep fascia covering the pectoralis major muscle and other surrounding muscles (serratus anterior and external oblique muscles). A layer of loose connective tissue (the retromammary space) separates the breast from the deep fascia and provides some degree of movement over underlying structures.

The base, or attached surface, of each breast extends vertically from ribs II to VI, and transversely from the sternum to as far laterally as the midaxillary line.

The upper lateral region of the breast can project around the inferolateral margin of the pectoralis major muscle and into the axilla. This axillary process (axillary tail) of the breast may perforate deep fascia and extend as far superiorly as the apex of the axilla.

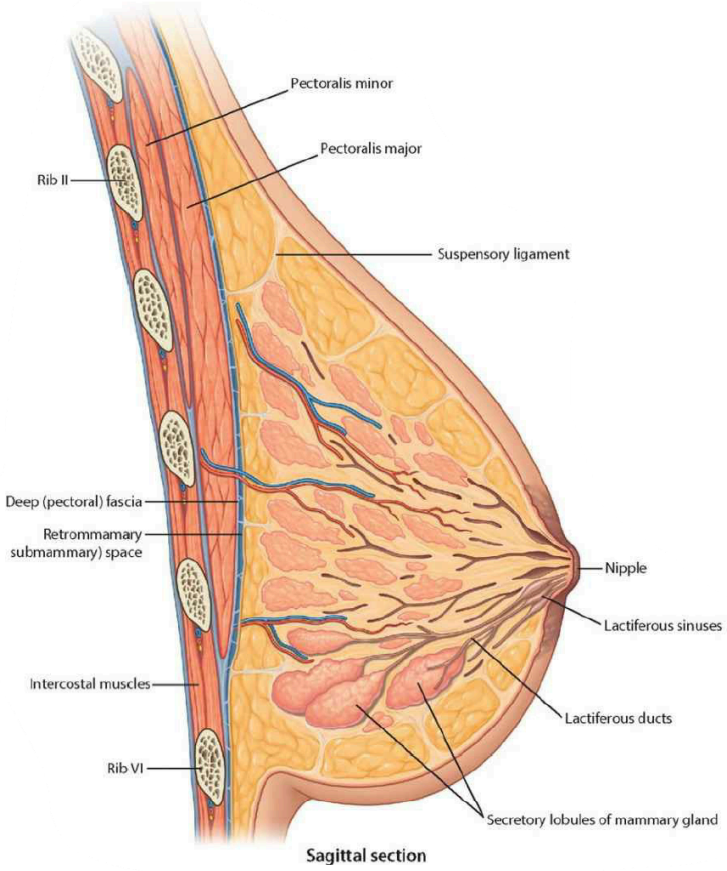

Arterial supply

The breast is related to the thoracic wall and to structures associated with the upper limb; therefore, its vascular supply and drainage are derived from multiple routes:

- Laterally, the breast is supplied by the lateral mammary branches of vessels from the axillary artery—superior thoracic, thoraco-acromial, lateral thoracic, and subscapular arteries;
- Medially, by medial mammary branches of the internal thoracic artery;
- In between the above 2 regions, the breast is supplied by the second to fourth intercostal arteries (anterior and posterior) via perforating branches that perforate the thoracic wall and overlying muscle.

Venous drainage
Veins draining the breast parallel the arteries and have the same names, and ultimately drain into the axillary, internal thoracic, and intercostal veins.

Innervation
Innervation of the breast is via anterior and lateral cutaneous branches of the second to sixth intercostal nerves. The anterior branches supply the medial part while the lateral collateral branches supply the lateral part of the breast. The nipple is innervated by the fourth intercostal nerve.

Lymphatic drainage
Within the breast, lymph vessels form extensive plexuses that ultimately aggregate in the subareolar region. From there, lymphatic vessels drain the breast tissues to the following lymph nodes and according to the region:

1. Lymph Drainage From the Lateral Quadrants
    - A majority of the lymph (>75%) from the lateral quadrant of the breast drains as follows: Axillary nodes (humeral, subscapular, pectoral, central, and apical) → infraclavicular and supraclavicular nodes → right subclavian lymph trunk (for the right breast) or left subclavian lymph trunk (for the left breast).
    - The remaining ~25% of lymph drainage occurs via the interpectoral, deltopectoral, supraclavicular, and inferior deep cervical nodes.
2. Lymph Drainage From the Medial Quadrants
    - The lymph from the medial quadrant of the right and left breast drains as follows: Parasternal nodes → right bronchomediastinal lymph trunk (for the right breast) or left bronchomediastinal lymph trunk (for the left breast).
    - Lymph from the medial quadrant may also drain into the opposite breast.
3. Lymph Drainage From the Inferior Quadrants
    - The lymph from the inferior quadrant of the right and left breast drains into the nodes of the upper abdomen (e.g., inferior phrenic lymph nodes).

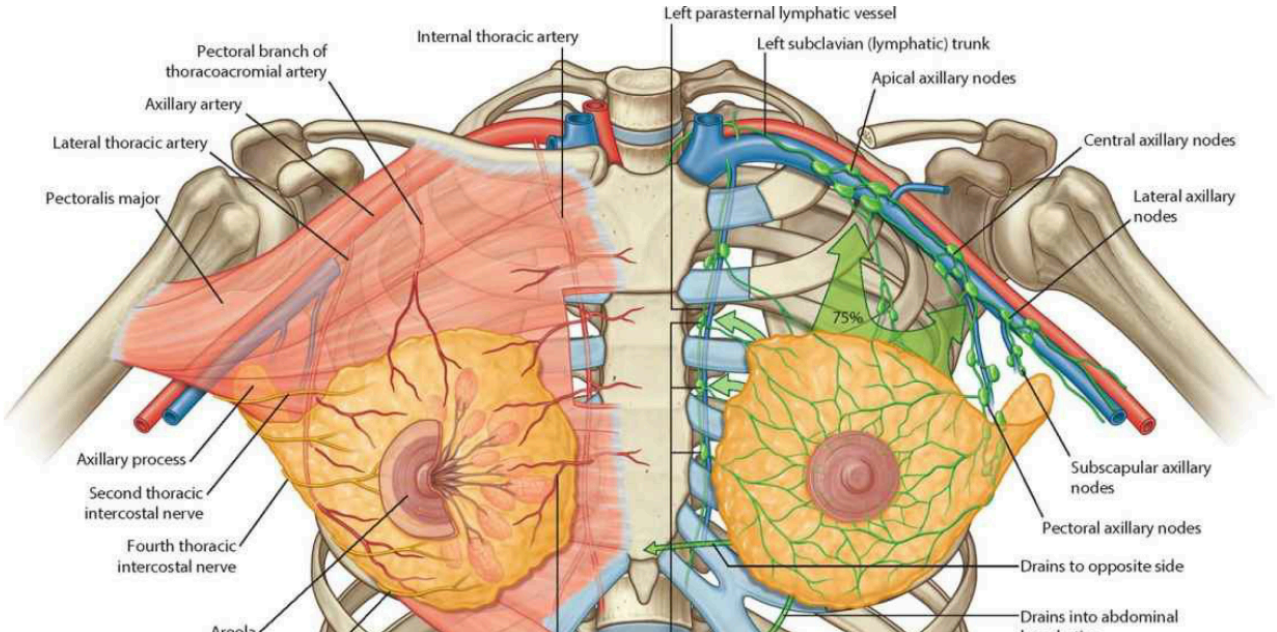

Some drainage may occur via lymphatic vessels that follow the posterior intercostal arteries and connect with intercostal nodes situated near the heads of ribs, which ultimately drain into the thoracic duct.

Breast in men

The breast in men is rudimentary and consists only of small ducts, often composed of cords of cells, that normally do not extend beyond the areola. Breast cancer can occur in men. Male breasts may increase in size secondary to specific hormonal abnormalities or specific diseases, a condition called “gynecomastia”.

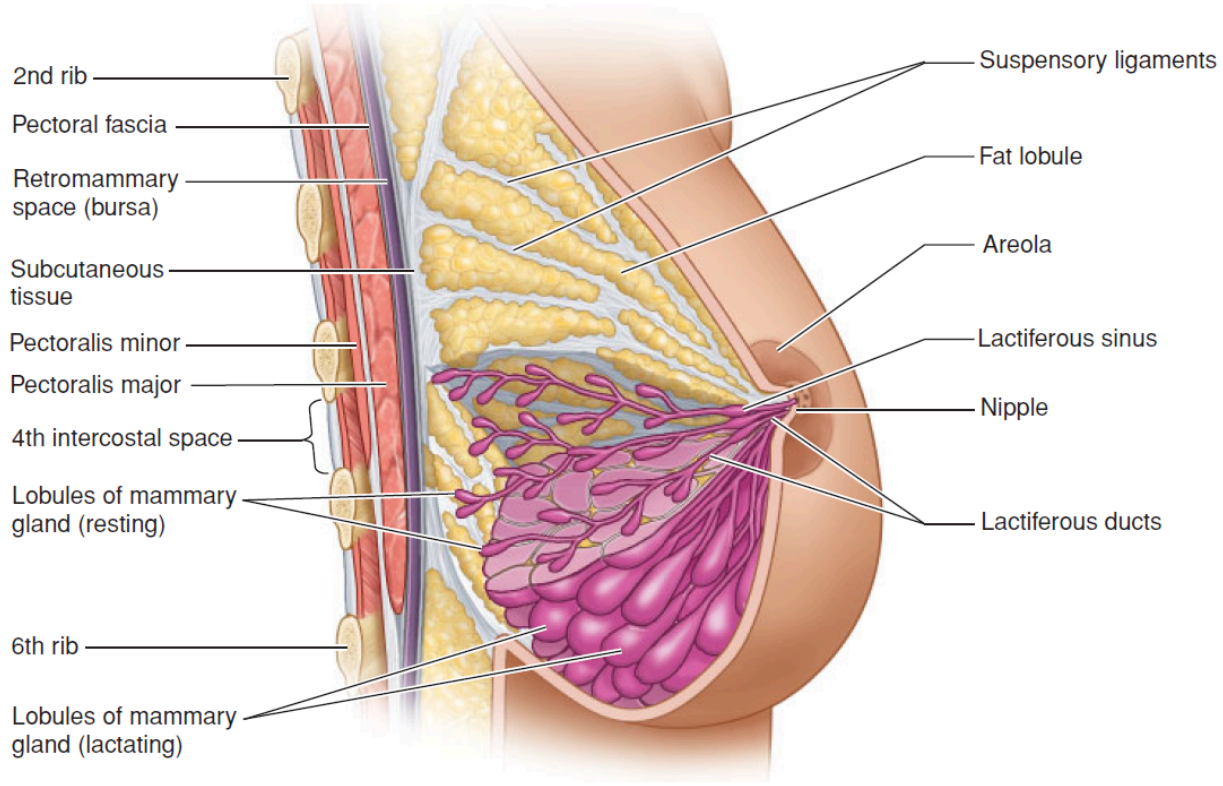

Breast inflammation (mastitis)

Mastitis is swelling and redness of breast tissue that may involve an infection by bacteria. Besides causing swelling and redness, mastitis causes breast pain and warmth. Mastitis most often affects women who are breastfeeding. This is called lactation mastitis. But mastitis can happen to people who aren't breastfeeding. Causes include: (1) ***A blocked milk duct.*** *If a breast doesn't empty all the way during feedings, one of the milk ducts can get clogged. Then milk backs up, leading to breast infection. (2)* ***Bacteria going into the breast.*** *Germs from the skin's surface and baby's mouth can enter the milk ducts. This can happen through a crack in the skin of the*

nipple or through a milk duct opening. Germs can grow in milk that stays in a breast that isn't emptied.

Breast cancer

Breast cancer is one of the most common malignancies in women. It develops in the cells of the acini, lactiferous ducts, and lobules of the breast. Tumor growth and spread depends on the exact cellular site of origin of the cancer.

Breast tumors spread via the lymphatics and veins, or by direct invasion.

When a patient has a lump in the breast, a diagnosis of breast cancer is confirmed by a biopsy and histological evaluation.

Computed tomography (CT) scanning of the body may be carried out to look for any spread to the lungs (pulmonary metastases), liver (hepatic metastases), or bone (bony metastases).

Lymph drainage of the breast is complex. Lymph vessels pass to axillary, supraclavicular, and parasternal nodes and may even pass to abdominal lymph nodes, as well as to the opposite breast. Containment of nodal metastatic breast cancer is therefore potentially difficult because it can spread through many lymph node groups.

Subcutaneous lymphatic obstruction and tumor growth pull on connective tissue ligaments in the breast, resulting in the appearance of an orange peel texture (peau d'orange) on the surface of the breast, and can also cause nipple inversion.

A mastectomy (surgical removal of the breast) involves excision of breast tissue. Within the axilla the breast tissue must be removed from the medial axillary wall. Closely applied to the medial axillary wall is the long thoracic nerve. Damage to this nerve during breast surgery can result in paralysis of the serratus anterior muscle, producing a characteristic "winged" scapula.