Dr. Ali Mohsin

Bone Histology -2

Osteogenesis

Bone can be formed in two ways: by direct mineralization of matrix secreted by osteoblasts (intramembranous ossification) or by deposition of bone matrix on a preexisting cartilage matrix (endochondral ossification). In both processes, the bone tissue that appears first is primary, which is soon replaced by the secondary bone.

Intramembranous Ossification:

Intramembranous ossification, the source of most of the flat bones, is so called because it takes place within condensations of mesenchymal tissue (membranes) as follows:

Within the condensed mesenchyme bone formation begins in ***ossification centers***, areas in which osteoprogenitor cells arise, proliferate, and form incomplete layers of osteoblasts around a network of developing capillaries.

Osteoid is secreted by the osteoblasts, then it calcifies forming small irregular areas of woven bone with osteocytes in lacunae.

These areas enlarge & fuse to each other, then the woven bone matrix is replaced by compact bone on the outer & inner sides of the membrane, that encloses a region of cancellous bone (**diploë**) in between.

Mesenchymal regions that do not undergo ossification give rise to the endosteum and the periosteum.

The **fontanelles** of newborn infants are areas of the skull in which the membranous tissue is not yet ossified.

Endochondral Ossification:

Endochondral ossification takes place within a piece of hyaline cartilage whose shape resembles a small model of the bone to be formed. This type of ossification is principally responsible for the formation of short and long bones.

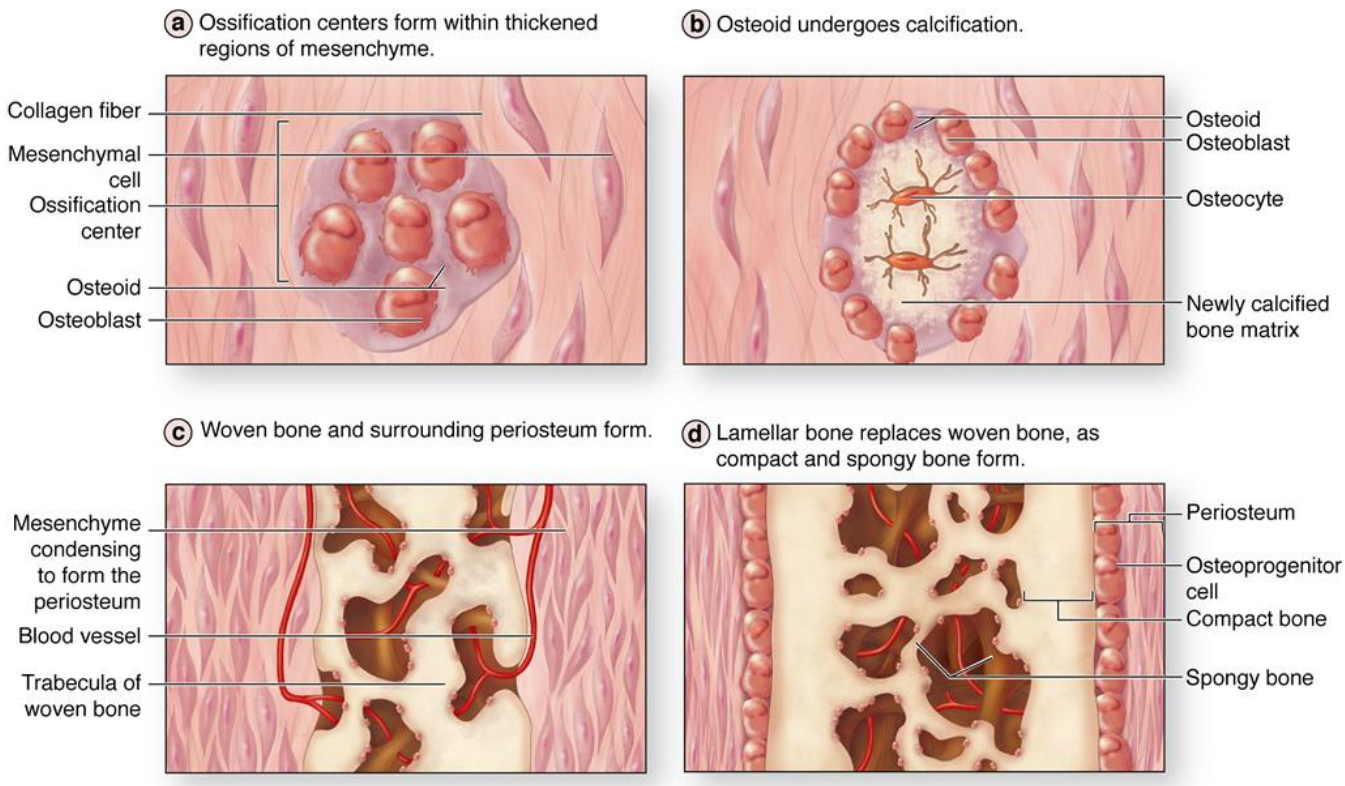

Endochondral ossification of a long bone consists of the following sequence of events:
Initially, the first bone tissue appears as a cylindrical bony layer (the bone collar) surrounding the mid portion of the cartilage model. This bone collar is produced by intramembranous ossification within the local perichondrium.
Then, the local cartilage inside the bone collar degenerates with chondrocytes apoptosis (death & enlargement) and matrix calcification, resulting in a three-dimensional structure formed by the remnants of the calcified cartilage matrix.
Blood vessels penetrate through the bone collar bringing osteoprogenitor cells to this region.
Next, osteoblasts adhere to the calcified cartilage matrix and produce continuous layers of primary bone that surround the cartilaginous matrix remnants. In this way the primary ossification center is produced.
Then, secondary ossification centers appear at the epiphyses.
By expansion and remodeling, the primary and secondary ossification centers produce cavities that are gradually filled with bone marrow.
In the secondary ossification centers, cartilage remains in two regions: the articular cartilage, which persists throughout adult life, and the epiphyseal cartilage (plate) which connects the two epiphyses to the diaphysis. The epiphyseal plate is responsible for the growth in length of the bone, and it disappears (ossifies) in adults, when bone growth ceases in adulthood.

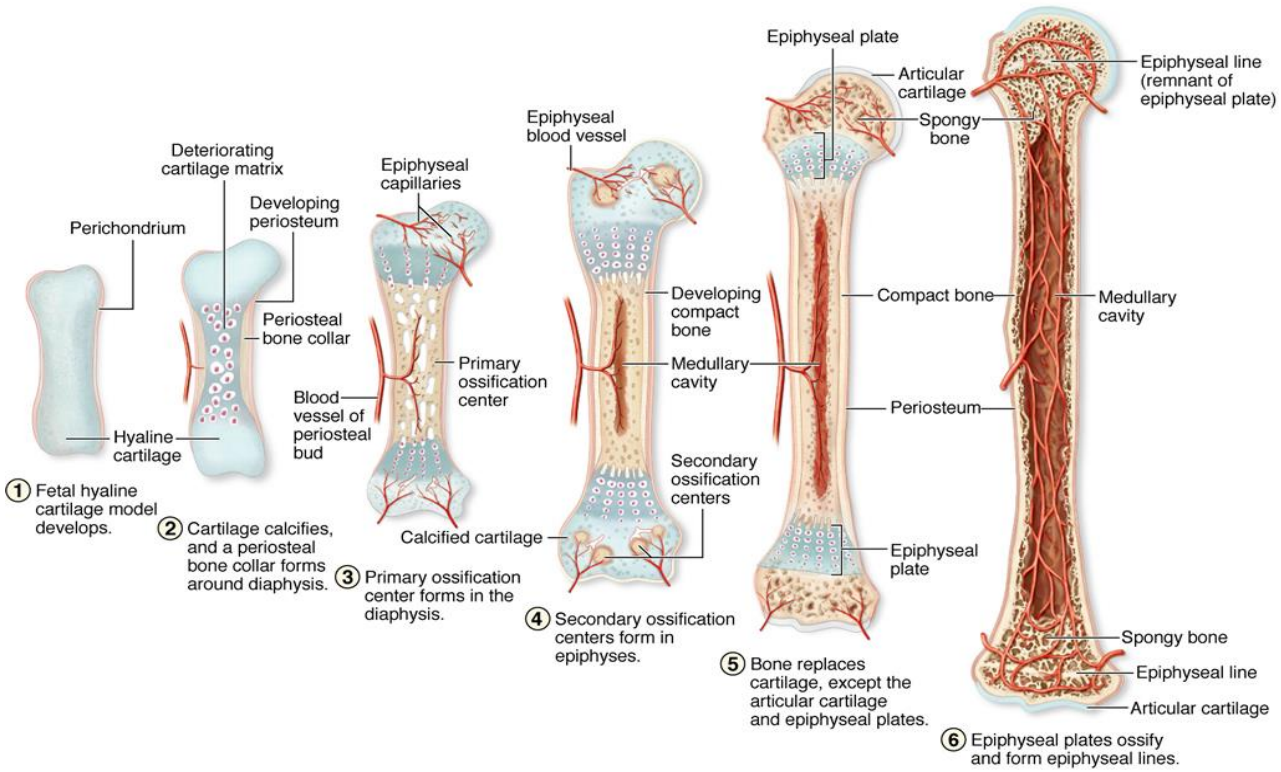

By close examination of the epiphyseal plate, it appears to be divided into 5 zones (starting from the epiphysis side):
(1) The **zone of reserve (resting) cartilage** consists of hyaline cartilage without morphological changes in the cells.
(2) The **proliferative zone:** chondrocytes divide rapidly and form columns of stacked cells parallel to the long axis of the bone.
(3) The **hypertrophic cartilage zone** contains large chondrocytes whose cytoplasm has accumulated glycogen. The resorbed matrix is reduced to thin septa between the chondrocytes.
(4) The **calcified cartilage zone:** chondrocytes die, & the thin septa of cartilage matrix become calcified

(5) The **ossification zone:** endochondral bone tissue appears. Blood capillaries and osteoprogenitor cells (from the periosteum) invade the cavities left by the chondrocytes. The osteoprogenitor cells form osteoblasts, which deposit bone matrix over the three-dimensional calcified cartilage matrix.

In summary, growth in length of a long bone occurs by proliferation of chondrocytes in the epiphyseal plate adjacent to the epiphysis, & simultaneous ossification of the plate from the diaphysis side. The rates of these two events (proliferation and destruction) are equal, so the epiphyseal plate does not change thickness. Instead, it is displaced away from the diaphysis, resulting in growth in length of the bone.

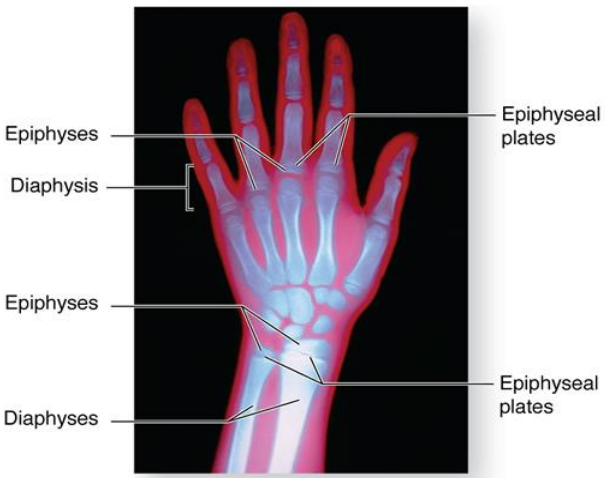

a X-ray of a hand

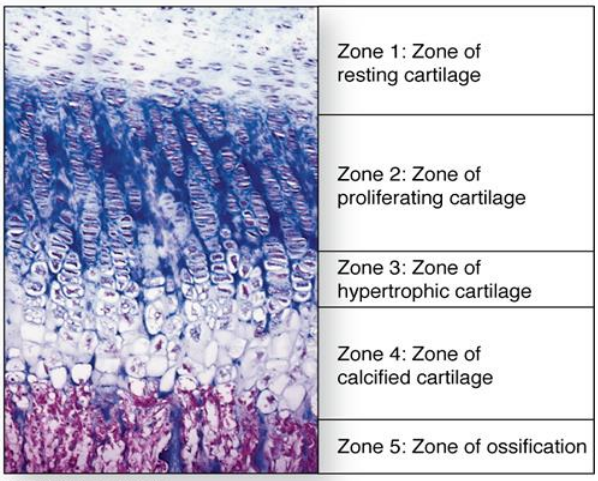

b Epiphyseal plate

Fracture Repair

When a bone is fractured, bone matrix is destroyed and bone cells near the fracture die. The damaged blood vessels produce a localized hemorrhage and form a blood clot.

During repair, the blood clot, cells, and damaged bone matrix are removed by macrophages. The periosteum and the endosteum around the fracture show intense proliferation producing a tissue that surrounds the fracture and fills the gap between the two bone pieces.

Primary (woven) bone is then formed by endochondral and intramembranous ossification. The irregularly formed trabeculae of primary bone temporarily unite the extremities of the fractured bone, forming a bone callus.

The primary bone tissue of the callus is gradually resorbed and replaced by secondary tissue, remodeling the bone and restoring its original structure. Unlike other connective tissues, bone tissue heals without forming a scar.

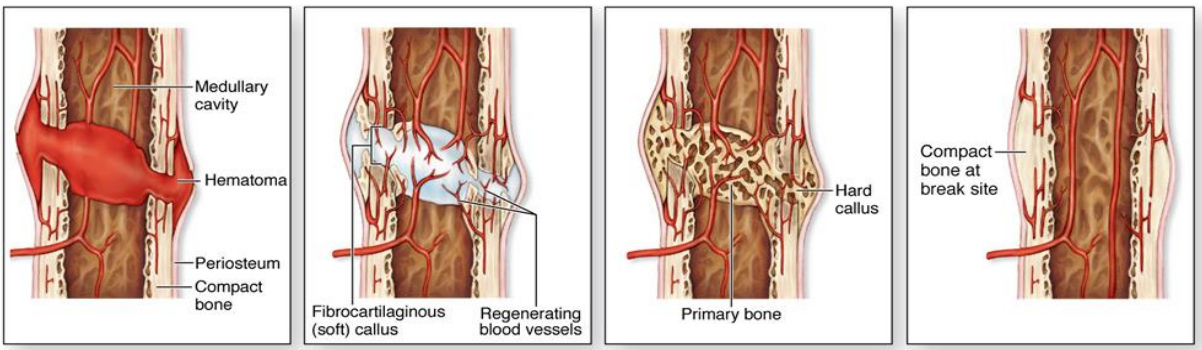

① A fracture hematoma forms. ② A fibrocartilaginous (soft) callus forms. ③ A hard (bony) callus forms. ④ The bone is remodeled.

Metabolic Role of Bone Tissue

The skeleton contains 99% of the total calcium of the body and acts as a reservoir of calcium and phosphate ions. Blood calcium level is quite stable because of a continuous interchange between blood calcium and bone calcium. Bone calcium is mobilized by two mechanisms: The first is the simple transfer of ions from bone crystals to interstitial fluid, from which calcium passes into the blood. The second mechanism depends on hormones. Parathyroid hormone promotes osteoclastic resorption of the bone matrix with the consequent liberation of calcium. Calcitonin, from the thyroid gland, inhibits osteoclast matrix resorption, reducing calcium liberation from the bone.

Joints

Joints are regions where two (or more) bones meet. Joints may be classified as diarthroses (synovial joints), in which there is free bone movement, or synarthroses (solid joints), in which very limited or no movement occurs. There are 2 categories of solid joints: those where the bones are connected by a connective tissue (fibrous joints), & those where the bones are connected by a cartilage (cartilaginous joints). **Synarthroses** include:

- **Fibrous joints:** these include (1) ***synostosis*** *(sutures)*, bones are united by dense connective tissue with osteogenic cells. No movement occurs in this type, eg: skull sutures in older adults. (2) ***Gomphoses*** that occur between the teeth and jaw bone, where collagen fibers in the periodontal ligament connect the root of the tooth to the bony socket. (3) ***Syndesmoses*** in which two adjacent bones are linked by a ligament. Examples: distal tibiofibular joint, interosseous membrane which links the radius and ulna in the forearm.
- **Cartilagenous joints*:*** these include (1) ***Synchondroses*** where two ossification centers in a developing bone are separated by hyaline cartilage, eg: the growth plate between the head and shaft of developing long bones. These joints allow bone growth and eventually become ossified. (2) ***Symphyses*** where two bones are interconnected by a fibrocartilage. These joints occur in the midline, eg: the pubic symphysis between the two pelvic bones, and intervertebral discs between adjacent vertebrae.

In **diarthroses** (synovial joints), ligaments and a capsule of dense connective tissue hold the articulating bones. The capsule is lined with the synovial membrane that encloses the articular cavity filled with synovial fluid. The resilient **articular cartilage** is an efficient absorber of the intermittent mechanical pressures applied to the joint. A similar mechanism is seen in intervertebral disks.

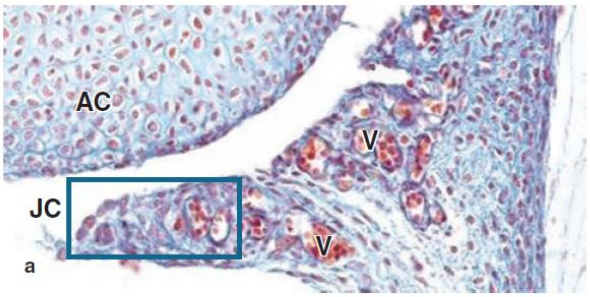

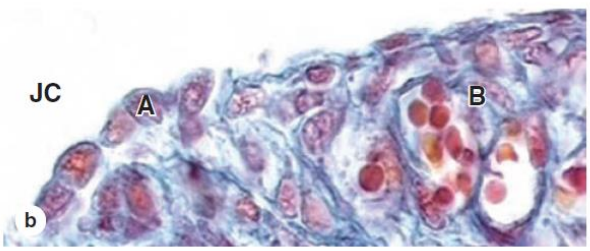

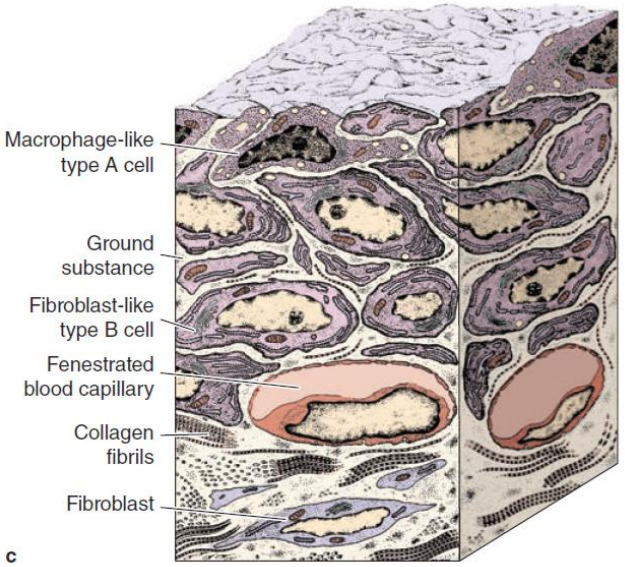

The **synovial membrane** lines the inner surface of the capsule. It is a special connective tissue with minimal fibers & ground substance, & two types of cells: (1) **macrophage-like synovial cells** (type A), derived from the blood monocytes, they remove wear-and-tear debris from the synovial fluid & regulate inflammatory events in the joint. (2) **fibroblasts-like synovial cells** (type B), that produce hyaluronan and proteoglycans, which are transported (with water from the rich blood capillaries) into the joint cavity to form the synovial fluid. **Synovial fluid** is a blood plasma filtrate with a high concentration of hyaluronic acid (produced by type B cells). It is a colorless, transparent, & viscous fluid that facilitates the sliding of the avascular articular cartilage and supplies it with nutrients and oxygen.

The resilient **articular cartilage** is an efficient absorber of the intermittent mechanical pressures applied to the joint. The collagen fibers of the hyaline articular cartilage are disposed as arches with their tops near the exposed surface which is not covered by perichondrium. This arrangement of collagen helps distribute more evenly the forces generated by pressure on joints.

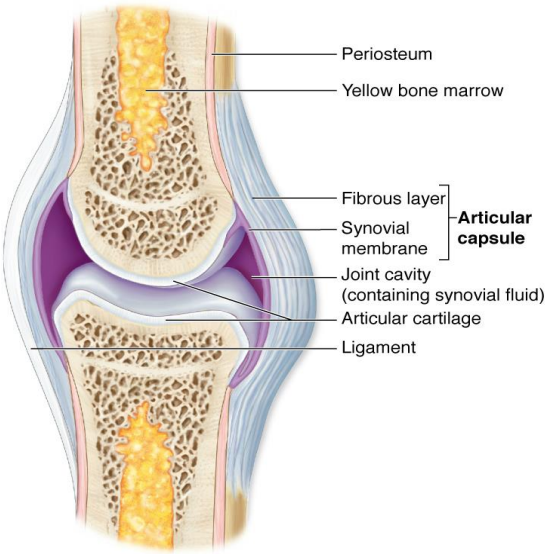

a Typical synovial joint

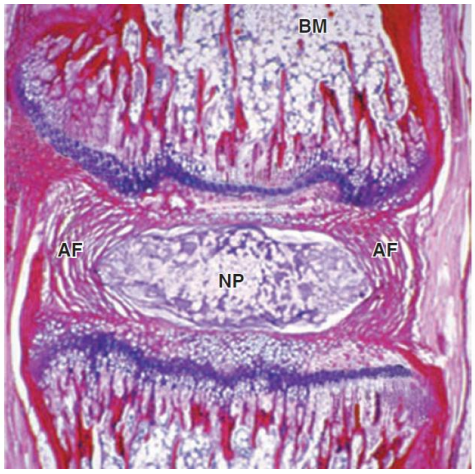

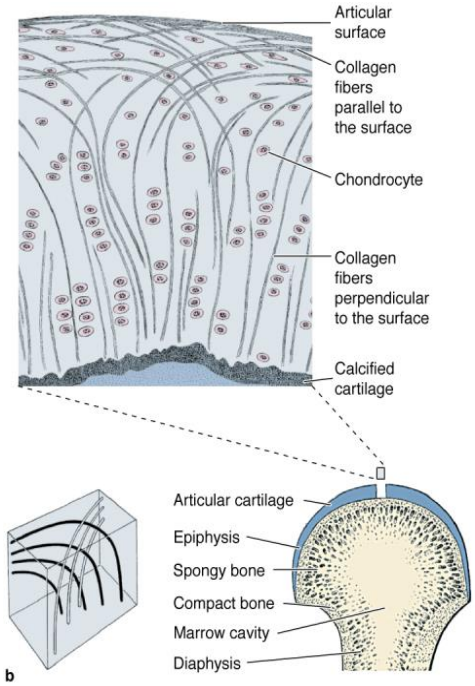

b

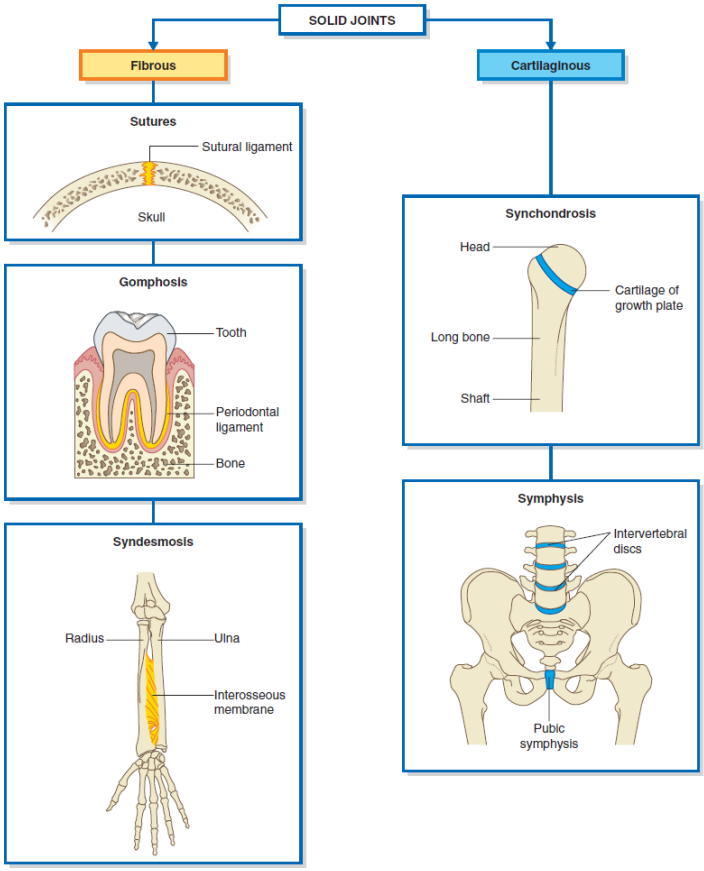

Medical Applications:

- *Resistance exercise can produce **increased bone density** and thickness in affected regions, while lack of exercise (or the weightlessness experienced by astronauts) leads to decreased bone density, due in part to the lack of mechanical stimulation of the bone cells.*

- ***Osteoporosis**, frequently found in immobilized patients and in postmenopausal women, is an imbalance in skeletal turnover so that bone resorption exceeds bone formation. This leads to calcium loss from bones and reduced bone mineral density (BMD). Individuals at risk for osteoporosis are routinely tested for BMD by dual-energy x-ray absorptiometry (DEXA scans).*

- ***Osteogenesis imperfecta**, or "brittle bone disease," refers to a group of related congenital disorders in which the osteoblasts produce deficient amounts of type-I collagen or defective type-I collagen due to genetic mutations. Such defects lead to a group of disorders characterized by significant fragility & low resiliency of the bones. This leads to frequent bone fractures during childhood & other disorders related to type-I collagen.*

- *Calcium deficiency in children can lead to **rickets**, a disease in which the bone matrix does not calcify normally and the bones (of the legs) can become distorted by the body weight and muscular activity. Ossification processes are consequently impeded, which causes bones to grow more slowly and often become deformed (bent). The deficiency can be due either to insufficient calcium in the diet or a failure to produce vitamin D, which is important for the absorption of Ca^{2+} by cells of the small intestine. That's why children are usually given supplemental vitamin D to prevent this disorder.*
- *In adults calcium deficiency can give rise to **osteomalacia** (osteon + Gr. malakia, softness), characterized by deficient calcification of recently formed bone and partial decalcification of already calcified matrix.*



Legs of a child with rickets

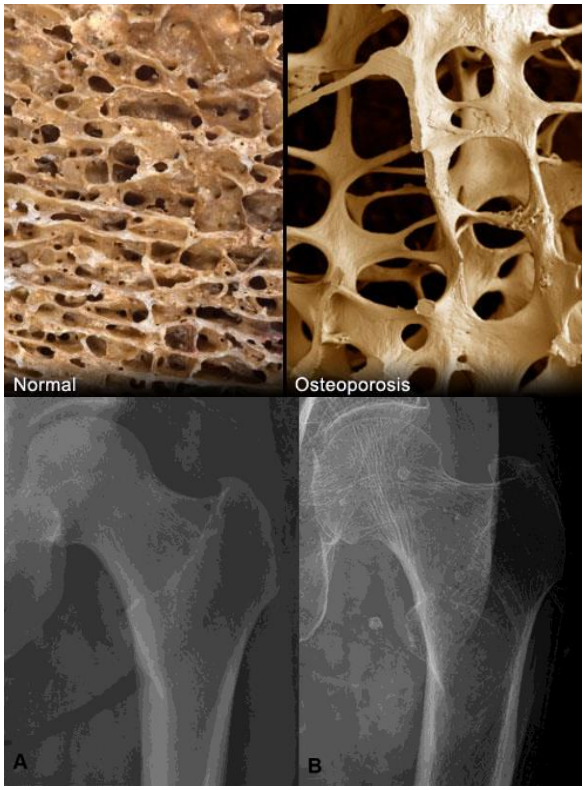

END