Dr. Ali Mohsin

Cartilage Histology

Cartilage is a specialized form of connective tissue (supportive connective tissue) that has a firm & resilience consistency which enables it to perform its functions:

(1) bearing mechanical stresses without permanent distortion, (2) supporting & protecting soft tissues, (3) providing the sliding surfaces of joints that facilitate bone movements, & (4) providing a scaffold for the development and growth of long bones both before and after birth.

Cartilage has an extracellular matrix enriched with glycosaminoglycans and proteoglycans, which are macromolecules that interact with collagen and elastic fibers. Variations in the composition of these matrix components produce the three types of cartilage: hyaline, elastic, & fibro- cartilage.

Unlike other types of connective tissues, cartilage contains one type of cells: chondrocytes, that produce the extracellular components (fibers & ground substance) & then decrease in activity to become chondrocytes. Fibroblasts are present in the dense connective tissue surrounding most cartilages, the perichondrium, but do not belong to the cartilage itself.

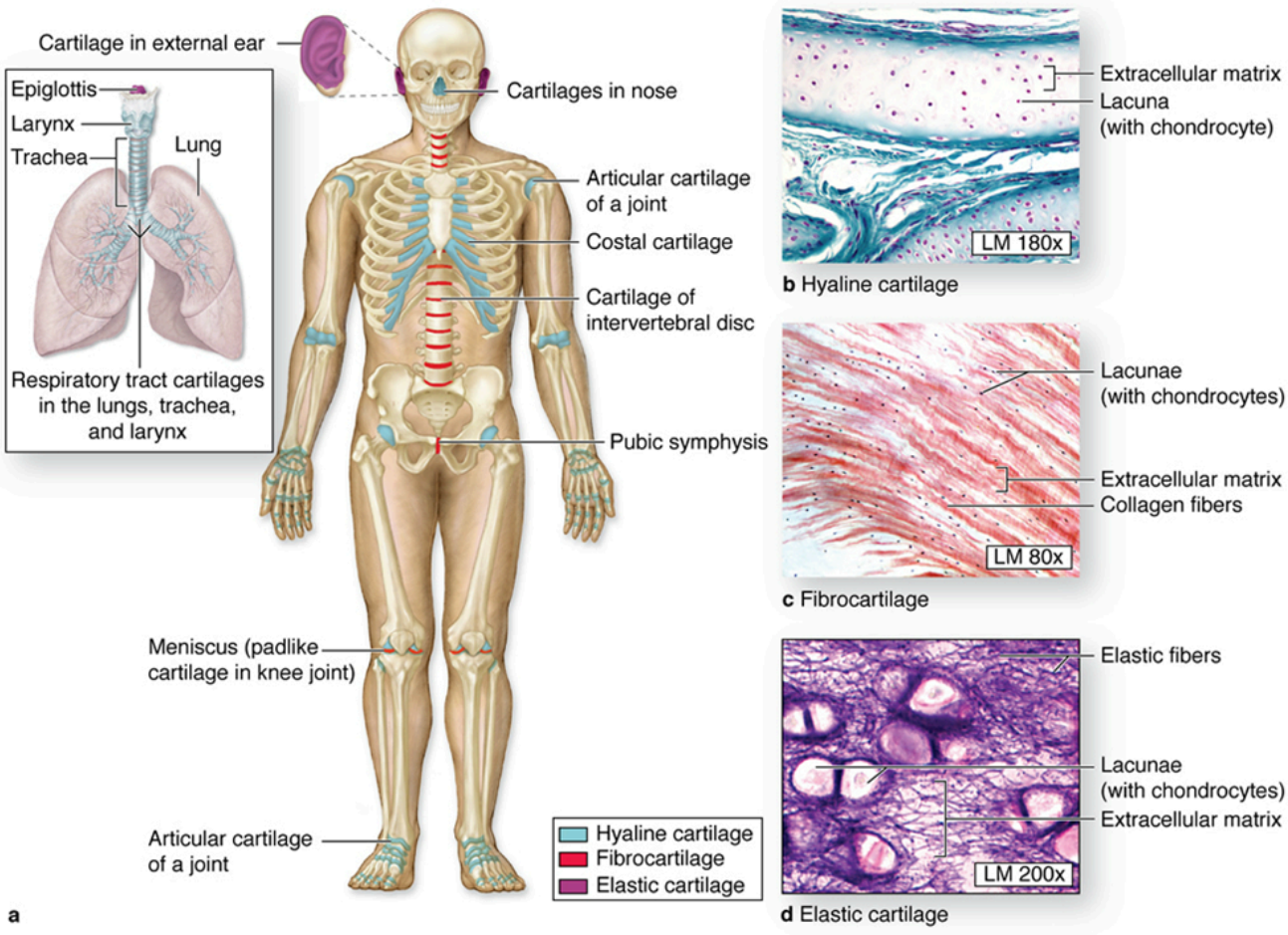

Cartilage is avascular and is nourished by the diffusion of nutrients from capillaries in adjacent connective tissue (perichondrium) or by synovial fluid from joint cavities. So, chondrocytes exhibit low metabolic activity. Because of this, the maximum width of the cartilage is limited. Cartilage has no lymphatic vessels or nerves.

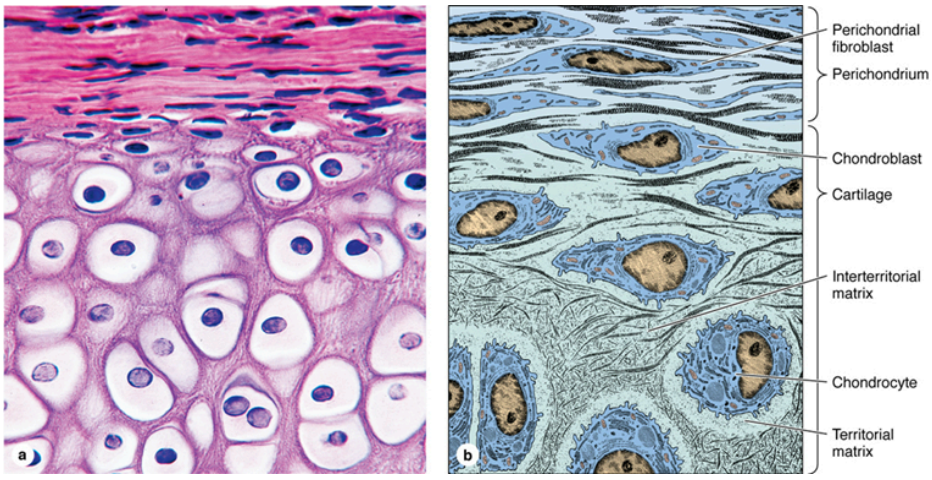

The **perichondrium** is a sheath of dense connective tissue that surrounds cartilage in most places, which is essential for the growth and maintenance of cartilage. The outer region of the perichondrium consists largely of collagen type-I fibers and fibroblasts, but the inner layer near the cartilage matrix also contains mesenchymal stem cells which provide a source for new chondroblasts that divide and differentiate into chondrocytes. The perichondrium has the vascular supply for the cartilage and also contains nerves and lymphatic vessels. Perichondrium surrounds all cartilages except (1) fibrocartilage, (2) hyaline cartilage of synovial joints.

Matrix

The matrix of hyaline cartilage is made of collagen embedded in a firm, hydrated gel of proteoglycans and structural glycoproteins. In histological sections, the proteoglycans make the matrix generally basophilic and the thin collagen fibrils are barely visible. Most of the collagen in hyaline cartilage is type II, although small amounts of minor collagens are also present.

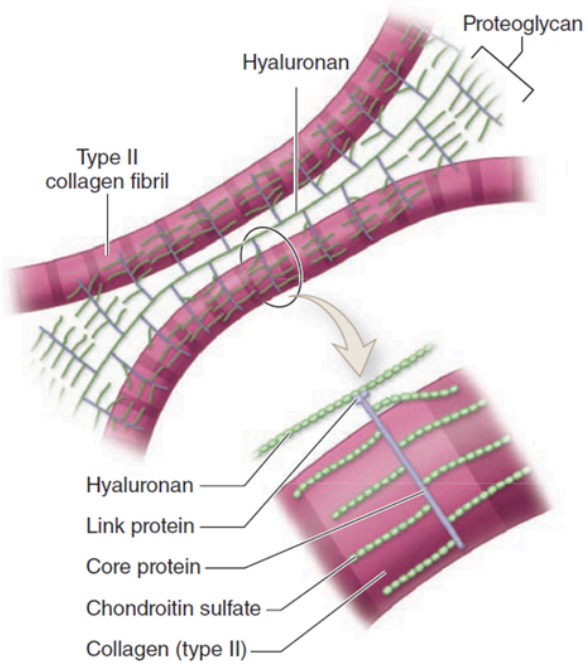

Aggrecan is the most abundant proteoglycan of hyaline cartilage, with approximately 150 GAG side chains (of chondroitin sulfate and keratan sulfate) attached to it. Hundreds of these proteoglycans are bound noncovalently by link proteins to long polymers of hyaluronan (hyaluronic acid). These proteoglycan complexes bind further to the surface of type II collagen fibrils. Water bound to GAGs in the proteoglycans constitutes up to 60%-80% of the weight of fresh hyaline cartilage.

Another important component of cartilage matrix is the glycoprotein *chondronectin*. Like fibronectin in other connective tissues, chondronectin binds GAGs & collagen (in the ECM) to integrins on the

chondrocytes. The cartilage matrix surrounding each chondrocyte (called the **territorial** or **capsular** matrix) is rich in glycosaminoglycan and poor in collagen, therefore it stains lighter than the rest of the matrix.

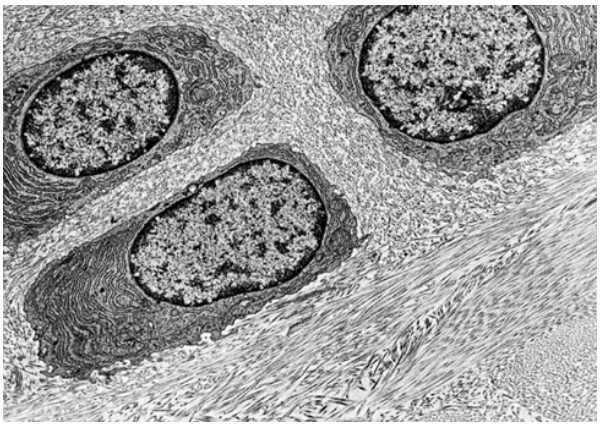

Chondroblasts and Chondrocytes

At the periphery of hyaline cartilage, chondroblasts originate from the mesenchymal stem cells in the inner zone of the perichondrium. They have an elliptic shape, with the long axis parallel to the surface. Deeper in the cartilage, they are called *chondrocytes*, which are round and may appear in groups of up to eight cells originating from mitotic divisions of a single chondrocyte (isogenous aggregates). In living tissue, and in properly prepared histological sections, the chondrocytes fill the lacunae completely. As the chondrocytes become more active in secreting ECM components, the aggregated cells are pushed apart and occupy separate lacunae. Chondrocyte function is accelerated by growth hormone and some growth factors.



Cartilage formation:

Cartilage derives from the mesenchyme (a). The first event is the rounding up of the mesenchymal cells, which retract their extensions, multiply rapidly, and form mesenchymal condensations of chondroblasts (b). Chondroblasts have a ribosome-rich basophilic cytoplasm. Synthesis and deposition of the matrix then begin to separate the chondroblasts from one another (c). Then, those separated chondroblasts start to divide mitotically, producing several chondrocytes in each lacuna (d). The differentiation of cartilage takes place from the center outward; therefore, the more central cells have the characteristics of chondrocytes (older), whereas the peripheral cells are typical chondroblasts (younger). The superficial mesenchyme develops into the perichondrium.

Cartilage Growth:

The growth of cartilage occurs by two processes: interstitial growth (resulting from the mitotic division of preexisting chondrocytes), and appositional growth (resulting from the differentiation of perichondrial cells). In both cases, cartilage grows by the synthesis of new matrix. Interstitial growth occurs (1) during the early phases of cartilage formation (mainly prenatally), when it increases tissue mass by expanding the cartilage matrix from within, (2) in the epiphyseal plates of long bones (where it mediates increasing the length of long bones) and (3) within articular cartilage where there is no perichondrium to replace superficial chondrocytes worn away. In cartilage found elsewhere in the body, interstitial growth stops & cartilage then grows only by apposition. Chondroblasts of the

perichondrium proliferate and become chondrocytes once they have surrounded themselves with cartilaginous matrix and are incorporated into the existing cartilage.

Poor Regeneration of Cartilage Tissue:

Except in young children, damaged cartilage regenerates with difficulty and often incompletely, by activity of the perichondrium, which invades the injured area and generates new cartilage. In extensively damaged cartilage, the perichondrium produces a scar of dense connective tissue instead of forming new cartilage.

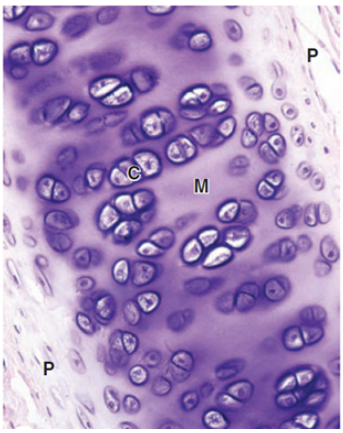

Hyaline Cartilage

Hyaline cartilage is the most common type. Fresh hyaline cartilage is bluish-white and semitransparent. In the embryo, it serves as a temporary skeleton until it is gradually replaced by bone. In adults, hyaline cartilage is located in the articular surfaces of the synovial joints, in the walls of respiratory passages (nose, larynx, trachea, bronchi), in the ventral ends of ribs, and in the epiphyseal plate, where it is responsible for the longitudinal growth of bone.

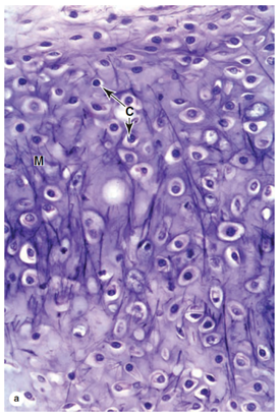

Elastic Cartilage

Elastic cartilage is found in the auricle of the ear, the walls of the external auditory canals, the auditory (eustachian) tubes, the epiglottis, and the cuneiform cartilage in the larynx.

Elastic cartilage is essentially identical to hyaline cartilage except that it contains an abundant network of fine elastic fibers in addition to collagen type-II fibrils. Fresh elastic cartilage has a yellowish color owing to the presence of elastin in the elastic fibers.

Fibrocartilage

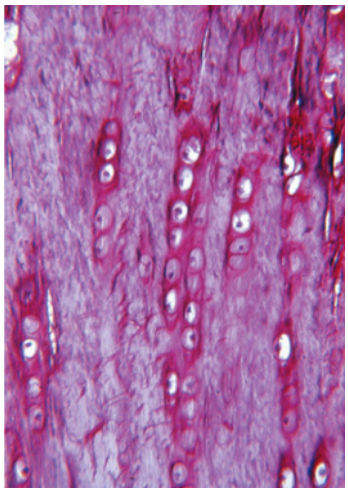

Fibrocartilage is actually a mixture of dense connective tissue and hyaline cartilage. It is found in intervertebral disks, menisci of the knee joint, in attachments of certain ligaments to the bones, and in the symphysis pubis. The border areas between fibrocartilage & dense connective tissue are not clear-cut, showing a gradual transition, so this type has no perichondrium.

Fibrocartilage contains chondrocytes, either singly or in isogenous groups, usually arranged in long rows separated by coarse collagen type-I fibers. Because it is rich in collagen type-I, the fibrocartilage matrix is acidophilic.

In fibrocartilage, the numerous collagen fibers either form irregular bundles between the groups of chondrocytes or are aligned in a parallel arrangement along the columns of chondrocytes. This orientation depends on the stresses acting on fibrocartilage. **Intervertebral Disks**

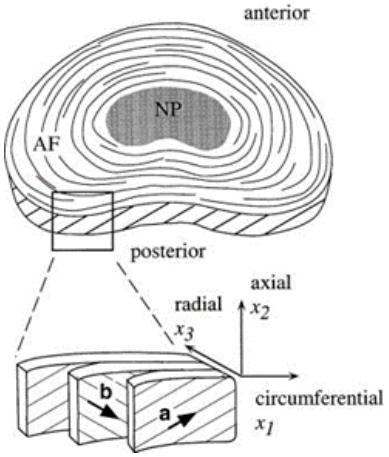

Each intervertebral disk is situated between two vertebrae and is held to them by means of ligaments. The disks have two components: the fibrous "**annulus fibrosus**" and the gelatinous "**nucleus pulposus**". The intervertebral disk acts as a lubricated cushion that prevents adjacent vertebrae from eroding each other during movement of the spinal column.

The annulus fibrosus has an external layer of dense connective tissue, & the rest is composed of overlapping laminae of fibrocartilage in which collagen bundles are parallel. Collagen fibers of each lamina make 90°angle with collagen fibers of the next lamina, providing the disk with unusual resilience to withstand the pressures generated by vertebrae.

The nucleus pulposus is situated in the center of the annulus fibrosus. It consists of a few rounded cells embedded in a viscous matrix rich in hyaluronic acid and type-II collagen fibrils. In children, the nucleus pulposus is large, but it gradually becomes smaller with age and is partially replaced by fibrocartilage.

Clinical Correlations

***Osteoarthritis (OA)**, a chronic condition that commonly occurs during aging, involves the gradual degenerative loss of the hyaline cartilage that covers the articular ends of bones in synovial joints, especially weight-bearing joints (knees, hips) or heavily used joints (wrist, fingers). This causes pain and inflammation within the joint. In the advanced severe cases of OA, the cartilage may be totally eroded exposing the underlying bone.*

*Hyaline cartilage is susceptible to partial or isolated regions of **calcification** during aging, especially in the costal cartilage adjacent to the ribs. Calcification of the hyaline matrix, accompanied by degenerative changes in the chondrocytes, is a common part of the aging process.*

***Intervertebral disc prolapse**: a condition that occurs when the annulus fibrosus (fibrocartilage) of the intervertebral disc ruptures due to trauma or degenerative changes, resulting in the herniation of the nucleus pulposus of the disc into the spinal canal. Disc herniation occurs commonly in the lumbar vertebrae, and –to a lesser extent- in the cervical vertebrae. This may cause pressure of the herniated material on the spinal nerve roots causing pain in the lower (or upper) limb.*

END