By the Name of ALLAH the Most Gracious the Most Merciful

The peritoneum, mesentery, greater omentum and retroperitoneal space Part I

د . أحمد اسامة حسن

Specialist in General Surgery & Laparoscopic Surgery

7th ,October , 2026

To be read in

Bailey & Love's Short Practice of Surgery 28th Edition.

Ch 65.

Objectives

To understand:

- The development and anatomy of the mesentery and peritoneum.
- Surgical conditions of the peritoneum, mesentery, greater omentum and retroperitoneal space

The Peritoneum

- Definition
- Peritonism
- Peritonitis : (Localized , Generalized).
- Intraperitoneal abscess (Subphrenic , Pelvic).
- Pneumoperitoneum
- Primary peritoneal malignancy
- Secondary peritoneal malignancy
- Peritoneal carcinomatosis

MESENTERY and PERITONEUM

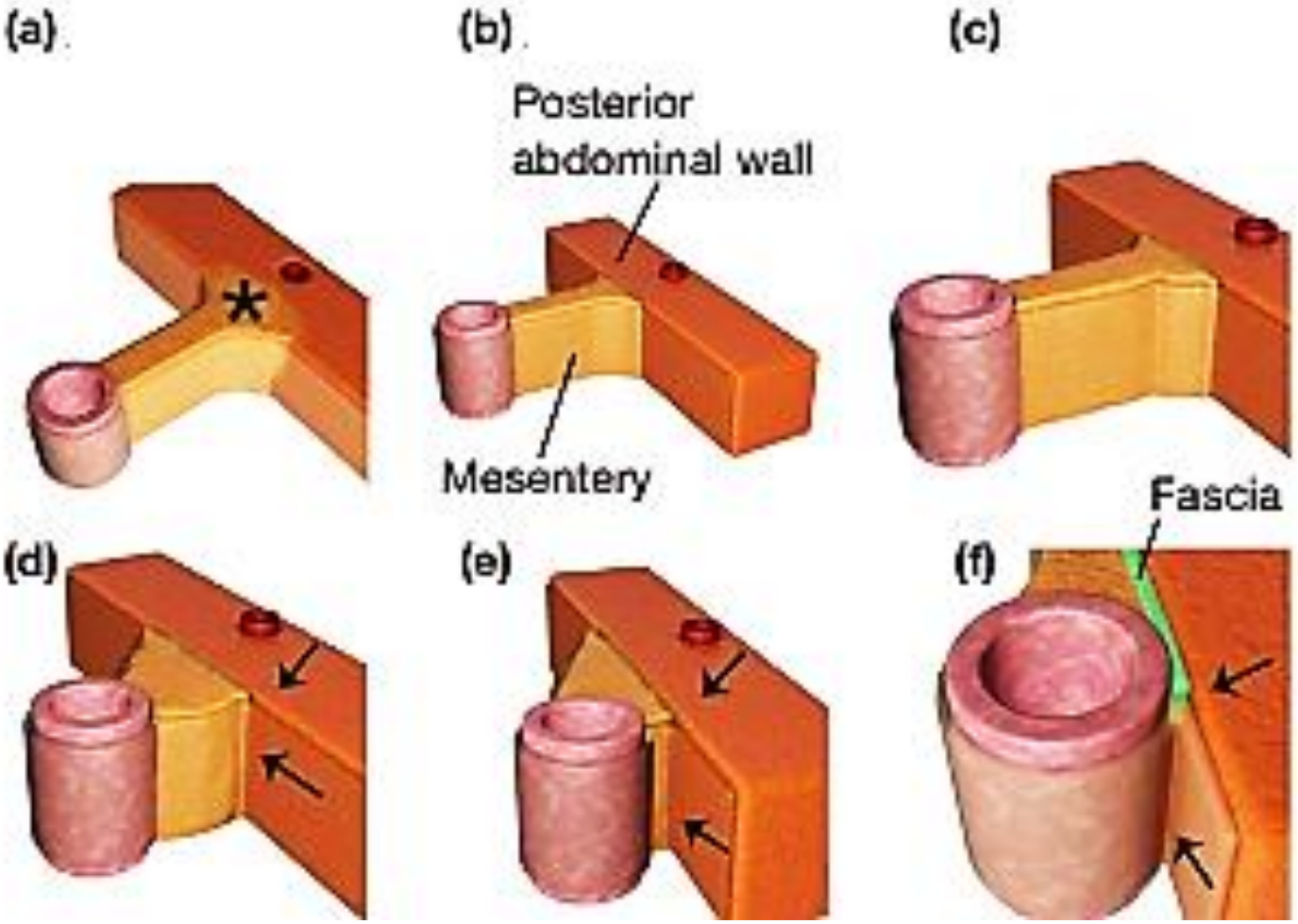

THE PERITONEUM

- The peritoneal membrane is composed of mesothelium , one layer thick, resting on a thin layer of fibroelastic tissue.
- Beneath the peritoneum, supported by a small amount of areolar tissue, lies a network of lymphatic vessels and a rich plexus of capillary blood vessels from which all absorption and exudation must occur.
- In health, only a few millilitres of peritoneal fluid are found in the peritoneal cavity. The fluid is pale yellow, somewhat viscid and contains lymphocytes and other leukocytes; it lubricates the viscera, allowing easy movement and peristalsis.

- The parietal portion (non-mesenteric domain) is richly innervated and, when irritated, causes severe pain that is accurately localised to the affected area (somatic).
- The visceral peritoneum (mesenteric domain), in contrast, is poorly innervated and irritation causes pain that is usually poorly localised to the midline.
- Mesentery (lined on either side by a sheet of mesothelial cells, enclosing blood supply of the viscera).
- Omentum ((lined on either side by a sheet of mesothelial cells, enclosing fat deposition (Greater & Lesser sac)).

- In the **male**, the peritoneal cavity is normally **closed**. In the **female**, the peritoneal cavity is open to the environment at the fimbrial entrance to the fallopian tubes.
- **In both sexes** (but more frequently in the male) a peritoneal tube (processus vaginalis) can persist at the deep inguinal ring and predispose to inguinal hernia formation.
- The peritoneum has the capacity to **absorb** large volumes of fluid; however, the peritoneum can also **produce** large volumes of fluid (ascites) and an inflammatory **exudate / exudate** when injured (seen in peritonitis).

- The surface contours generated by the organisation of the domains and the peritoneum explains the sacs, recesses, fossae and pouches in which abnormal fluid collections arise in the abdomen.

Functions of the peritoneum

In health

- Visceral lubrication.
- Fluid and particulate absorption. (P.Dialysis & V.P. shunt)

In disease

- Pain perception (mainly parietal).
- Inflammatory and immune responses.
- Fibrinolytic activity.
- Sac of the hernia.

PERITONITIS

Peritonitis is an inflammation / infection of the peritoneum and is diagnosed clinically).

It can be categorized as :

- Localized or Diffuse.
- Acute or chronic .
- According to the primary underlying pathology: (Primary (, secondary or tertiary) .

Tertiary peritonitis (TP) is an intraperitoneal infection that persists or recurs ≥ 48 hours following successful and adequate surgical source control (Secondary Peritonitis.)

- There is a reactionary, serous exudate (rich in leukocytes and plasma proteins) that gradually becomes turbid in appearance. The fluid may transform to frank pus if not evacuated.
- Plaques of yellow/white fibrin may be apparent, causing loops of intestine (and mesentery) to adhere to themselves and to the parietes.

Causes of Peritoneal Inflammation

- **Bacterial**: gastrointestinal and non-gastrointestinal
- **Chemical** :Bile, barium
- **Allergic** : starch peritonitis
- **Traumatic** : Operative handling
- **Ischaemia** : Strangulated bowel, vascular occlusion
- **Miscellaneous** : Familial Mediterranean fever

Paths to peritoneal infection

- **Gastrointestinal perforation**, e.g. perforated ulcer, appendix, diverticulum (2nd B.P.).
- **Exogenous** contamination, e.g. drains, open surgery, trauma, peritoneal dialysis
- **Female genital** tract infection, e.g. pelvic inflammatory disease
- **Transmural translocation** (no perforation), e.g. pancreatitis, ischaemic bowel, (primary bacterial peritonitis).
- **Haematogenous** spread (rare), e.g. septicaemia

Clinical features of peritonitis

- Constitutional upset: anorexia, malaise, lassitude , nausea +/– vomiting. Signs may be limited in obese patients or in patients on immunosuppressive medications.

Localised Peritonitis

- Pyrexia (may be absent ?) & raised pulse rate.
- Abdominal pain, worse on movement, coughing and deep respiration.
- Peritonism and the patient is described as peritonitic. ➡
- Rebound tenderness, tenderness +/– guarding/rigidity.

Special Localised Peritonitis

- Subdiaphramatic : shoulder tip pain.
- Pelvic peritonitis, e.g. from an inflamed appendix or salpingitis, abdominal signs may be limited; deep seated tenderness may be detected by digital rectal or vaginal examination.
- Lesser sac : - peforated posterior wall of the stomach
  - following acute pancreatitis.

Diffuse (generalised) peritonitis

- A life-threatening condition.
- Perforated viscus i.e duodenal ulcer or anastomotic leak).
- The pain may be localised at first and then become diffuse.
- The patient is gravely ill looking (Hippocratic facies) and usually lies as still as possible .
- Absent or reduced bowel sounds (paralytic ileus) abdominal distension.
- The abdomen does not move with respiration.
- (‘Board-like’ rigidity) scaphoid abdomen in thin patient .
- Vitally unstable with change level of consciousness.
- ‘Septic shock’ (systemic inflammatory response syndrome[SIRS] and multiorgan dysfunction syndrome [MODS]) in later stages

- Investigations for peritonitis:
- CBP, ESR,CRP.
- Erect chest radiograph / lateral decubitus radiograph to identify subcostal gas .
- Peritoneal aspirate.
- Abdominal U/S & CT scan.

Chest x-ray PA view (erect) shows (Pneumoperitoneum)

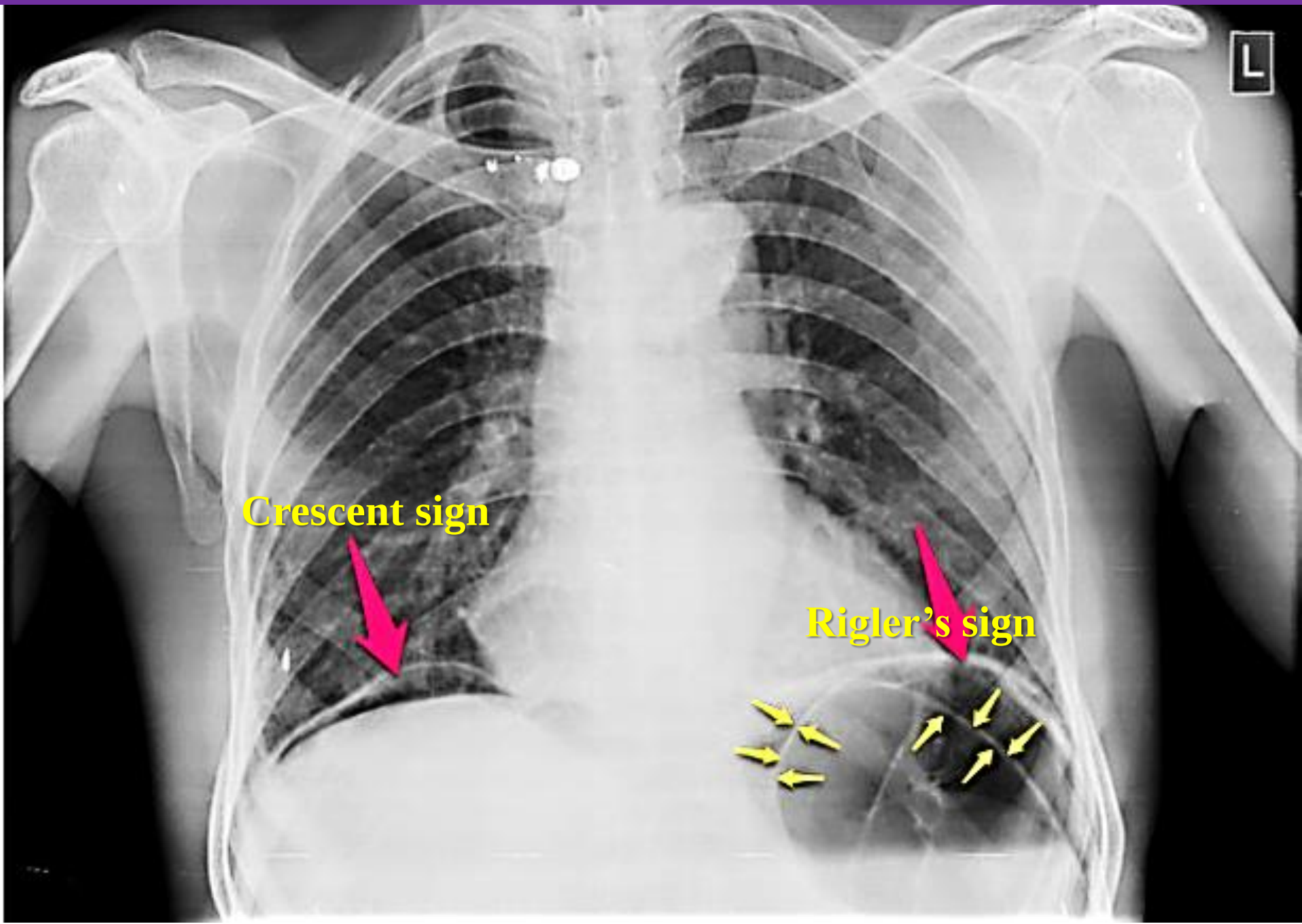

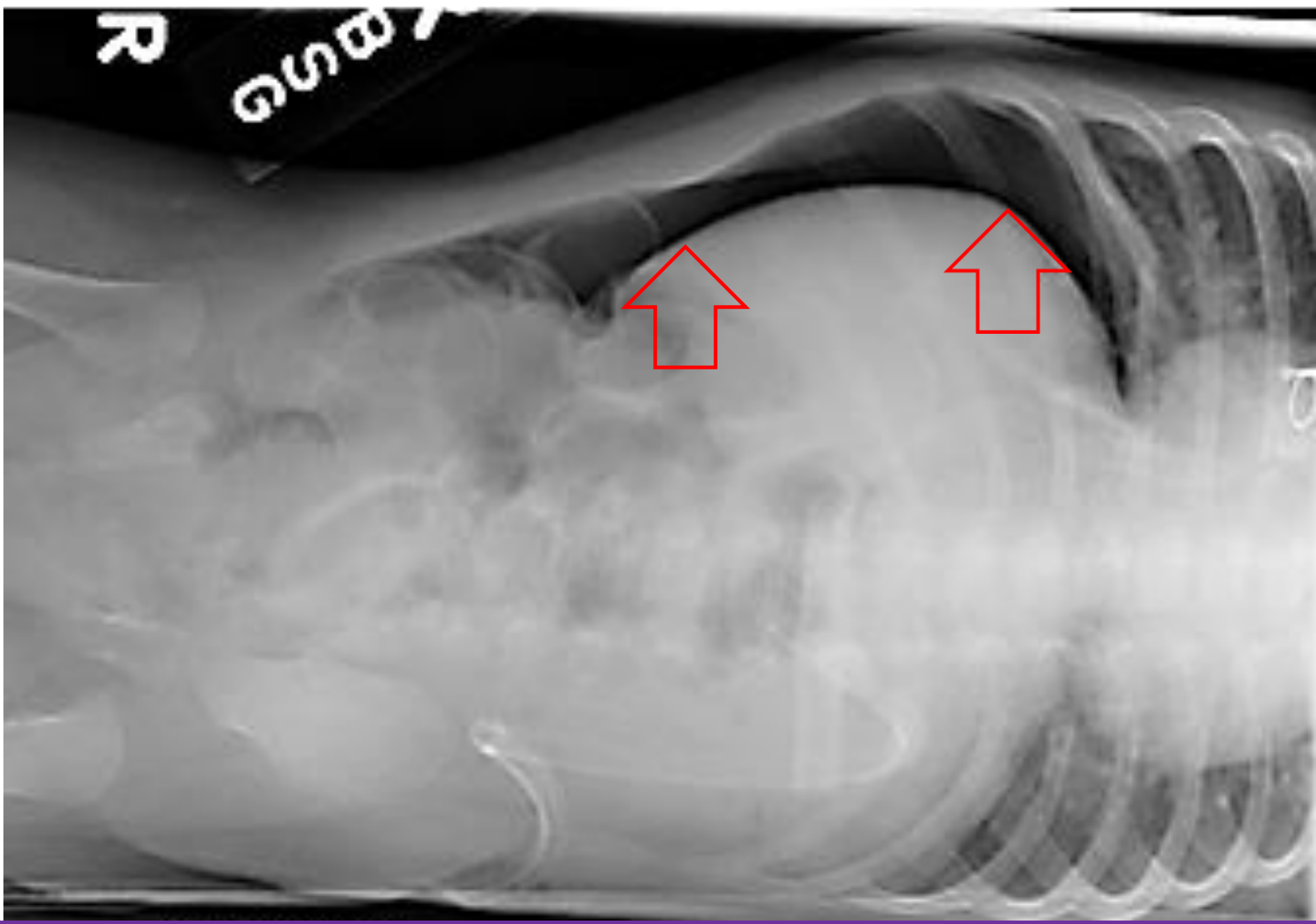

Plain X ray film (left lateral decubitus view) Pneumoperitoneum

Management of peritonitis

- General care of patient.
- Correction of fluid and electrolyte imbalance
- Insertion of nasogastric drainage tube and urinary catheter
- Broad-spectrum antibiotic therapy
- Analgesia
- Vital system support

Surgical treatment of cause when appropriate

- ‘Source control’ by removal or exclusion of the cause
- Peritoneal lavage +/– drainage

Acute bacterial peritonitis

- Perforation of a viscus (commonly).
- Female genital tract (Chlamydia spp. and gonococci
- Exogenous contamination.
- Less commonly is a primary ‘spontaneous’ peritonitis due to streptococcal, pneumococcal or Haemophilus infection.
- A variant of transperitoneal spread of such organisms is perihepatitis, which can cause scar tissue to form on Glisson’s capsule.
- Fungal peritonitis is rare but may complicate severely ill patients.

Primary Bacterial Peritonitis
Spontaneous bacterial peritonitis

- Is an acute bacterial infection of ascitic fluid. There is often a history of cirrhosis and ascites. The clinical picture is highly variable as the patient may be asymptomatic. The course can be prolonged.
- Diagnosis is made by paracentesis (increased neutrophil count of 250/mm^3)
- Culture of ascites is negative in 60%.
- Gram-negative bacteria, usually Escherichia coli, and Gram-positive cocci (mainly streptococci and enterococci).
- Third-generation cephalosporin, e.g. cefotaxime, is a reasonable first-line treatment that avoids the renal toxicity of aminoglycosides. Alternatives are amoxicillin/clavulanic acid and quinolones such as ciprofloxacin.

Primary pneumococcal peritonitis

- It may complicate nephrotic syndrome or cirrhosis in children; however, otherwise healthy children may also be affected.
- In girls, the route of infection may be via the vagina and Fallopian tubes.
- Blood-borne route secondary to respiratory tract or middle-ear disease is also possible.

- Sudden, localised pain to the lower half of the abdomen. Fever is up to 39°C or more and frequent vomiting.
- After 24–48 hours, profuse diarrhoea is characteristic. There is usually increased frequency of micturition.
- The last two symptoms are caused by severe pelvic peritonitis.

- On examination, peritonism is usually diffuse but less prominent than in cases of a perforated viscus, leading to peritonitis.
- An underlying pathology must always be excluded before primary peritonitis can be diagnosed with certainty. Causative organisms include Haemophilus spp., group A streptococci and a few Gram-negative bacteria. Idiopathic streptococcal and staphylococcal peritonitis can also occur in adults.

Treatment

- Rehydration and electrolyte correction.
- Antibiotic therapy.
- Early surgery is required unless spontaneous infection of pre-existing ascites is strongly suspected, in which case a diagnostic peritoneal tap is useful and sent to the laboratory for microscopy, culture and sensitivity tests.
- Laparotomy or laparoscopy may be used (exudate is aspirated (microscopy, culture and sensitivity) , thorough peritoneal lavage is carried out and the incision closed).
- Antibiotics and fluid replacement therapy are continued and recovery is usual.

Tuberculous peritonitis

- Includes intraperitoneal, gastrointestinal tract and solid organ disease forms. it is often diagnosed late.
- Source : GIT : (typically the ileocaecal region) via mesenteric lymph nodes or directly from the blood, usually from the ‘miliary’ but occasionally from the ‘cavitating’ form of pulmonary TB, lymph and the Fallopian tubes.
- Types : 90 % wet, ascitic type disease (generalised or loculated).
- Less common form fibrotic fixed loops of bowel and omentum are matted together and may present with subacute intestinal obstruction.
- Dry, plastic type (ascitis is not present).
- Presentation is often insidious with abdominal pain, weight loss and abdominal distension. Distinction from diffuse peritoneal metastases is difficult and may require biopsy.

Diagnosis

- Mantoux test (tuberculin skin test).
- abdominal plain X ray (nodule calcifications) ultrasonography or CT to detect ascites and lymphadenopathy with/without diffuse thickening of the peritoneum, mesentery and/or omentum.

- Ascitic fluid is typically a straw-coloured exudate (protein >25–30 g/L) with white cells >500/mL and lymphocytes >40%.
- Unfortunately, diagnostic smears for acid-fast bacilli are often not diagnostic and culture may take up to 4–8 weeks, so laparoscopy and peritoneal biopsy may thus be helpful to couple typical appearances with histology.
- Interferon-gamma (IFN-γ) release assays.
- PCR (polymerase chain reductase).
- Measurement of adenosine deaminase activity in ascitic fluid has a high sensitivity and specificity .

Management

- Management is supportive (nutrition and hydration) and medical (systemic anti-TB therapy, noting that multidrug resistance may be higher for abdominal than for pulmonary TB).
- Surgery is required for specific complications such as intestinal obstruction.

Biliary Peritonitis

- Post-cholecystectomy (slippage of a clip o the cystic duct, leakageage of bile from an accessory cystic duct or perforation of the common bile or hepatic duct , post- hepatectomy &Duodenal surgery, although this is unusual if a drain has been placed at the time of surgery.
- **Investigation** follows the principles and steps described in Peritonitis. The natural course varies depending on the volume of contamination. In severe contamination the patient will be extremely unwell and urgent intervention is required.
- Localised collections can be treated by percutaneous insertion of a drain followed by endoscopic retrograde pancreatography (ERCP) to identify the source of bile leak. ERCP enables placement of a stent across the source of the leak.
- Diffuse or high-volume contamination, or the presence of multiple separate locules, normally mandates surgical exploration with the aim being lavage and drainage.

Familial Mediterranean Fever

- An autosomal recessive inherited autoinflammatory syndrome .
- Episodic diffuse abdominal pain and tenderness, mild pyrexia and joint pain.
- DDX of acute appendicitis in childhood .
- Usually mild and resolve within 24–72 hours.
- Rarely pericardial or meningeal inflammation may occur.
- Amyloidosis is a long-term complication.
- Colchicine can be used to reduce the frequency and severity of the attacks and to prevent development of amyloidosis.

INTRAPERITONEAL ABSCESS

- It is a collection of pus in the peritoneal cavity. It normally arises secondary to another pathology. Inflammation of any viscus, if unresolved, will lead to hypersecretion of peritoneal fluid (exudate) or unresolved perforated viscus.
- Atypical Inratperitoneal abscess (Subphrinic, lesser sac and pelvis).

- The circulation of peritoneal fluids may be responsible for the occurrence of abscesses anatomically remote from primary disease. The two sites most prone to collection are the pelvis and subdiaphragmatic areas, reflecting the effects of gravity while standing and lying, respectively .
- During expiration, intra-abdominal pressure is reduced and peritoneal fluid, aided by capillary attraction, travels in an upward direction towards the diaphragm. Particulate matter and bacteria are absorbed within a few minutes into the lymphatic network through a number of ‘pores’ in the diaphragmatic peritoneum (**pleural effusion**).

Clinical features of an intra-abdominal abscess

- **Symptoms**
- Malaise, lethargy – failure to recover from surgery as expected

•A swinging pyrexia is strongly suggestive of intraperitoneal abscess formation.

- Anorexia and weight loss. Sweats +/– rigors
- Abdominal/pelvic pain
- Local irritation, e.g. shoulder tip pain/hiccoughs (subphrenic), diarrhoea and mucus (pelvic), nausea and vomiting (any upper abdominal)
- **Signs**
- Increased temperature and pulse +/– swinging pyrexia
- Localised abdominal tenderness +/– mass (including on pelvic examination) . Digital R Exam tenderness.

Investigation

- CBP, ESR, CRP.
- S.glucose level.
- Abdominal ultrasound & abdominal CT scan for diagnosis and for drain placement or aspiration.
- Radiolabelled white cell scanning (if an abscess is suspected but has not been identified by the above means).

Treatment

- Abscesses less than 5 cm in diameter normally resolve with intravenous antibiotic treatment.
- Abscesses greater than 5 cm require either percutaneous aspiration/drainage or surgical intervention (laparoscopically = laparoscopic lavage) or laparotomy approach. The bowel may be matted together, drainage any residual collections, ensure that there are no residual interloop abscesses.

Prevention of abscess formation after appendicitis

- Following appendectomy for a perforated appendix , it is important to aspirate the pelvic, paracolic and subhepatic spaces prior to closure of the abdominal wall.

Abscess formation following intestinal surgery and anastomosis

- Locules of gas or free contrast (Gastrografin) on CT support anastomotic leak.
- Pelvic abscess formation is not uncommon following excision of the rectum and formation of a pelvic anastomosis.

Subphrenic abscess

- Patients may complain of shoulder tip pain. The diaphragm also develops at the same level as the C5 dermatome. If the parietal peritoneum under the diaphragm is irritated, pain is referred to the shoulder tip.
- Shoulder tip pain following laparoscopic or robotic surgery).
- In the era preceding that of cross-sectional imaging via CT, the adage ‘pus somewhere, pus nowhere, pus under the diaphragm’ was useful.
- Tx:

Ressuscitation, ABCs, Drainage under imaging / laparotomy / laparoscopy with tube drain and irrigation.

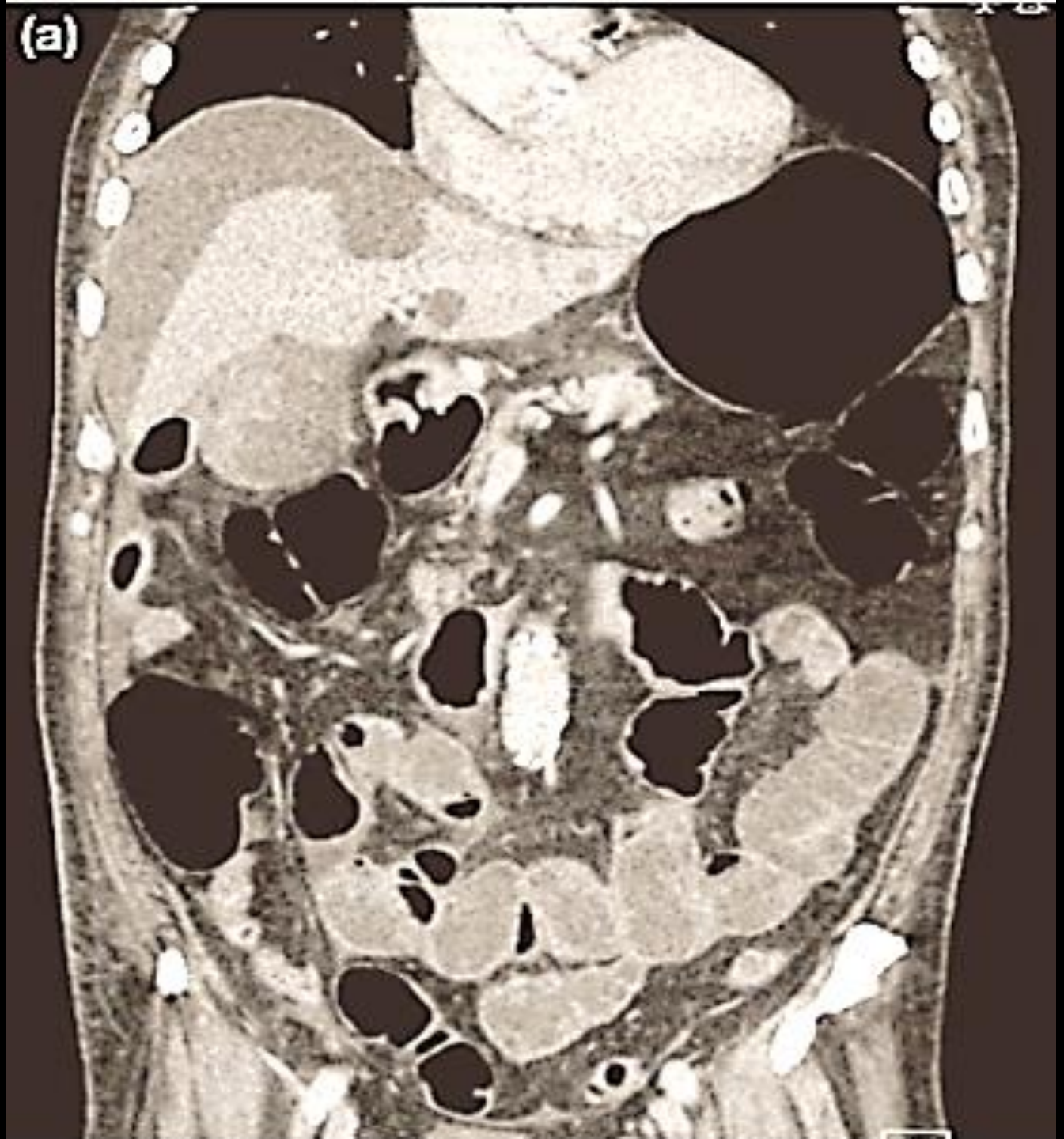
(a)


(b)

Pelvic abscess

- Gravity.
- Is the most common site of abscess formation because :
- The vermiform appendix is often pelvic in position .

  The Fallopian tubes are also frequent sites of infection.
- As a sequel to diffuse peritonitis .
- After anastomotic leakage following colorectal surgery.

Clinical features

- Pelvic pain, diarrhoea and passage of mucus in the stools.
- Lower back pain or a pressure sensation in the pelvis. This symptom can be quite severe in intensity.
- The abscess may discharge into the anal canal as the pelvic collection points through an anastomotic leak (the point of least resistance).
- Rectal or vaginal examination can be extremely uncomfortable for the patient .
- It should be confirmed by ultrasonography or CT scanning.

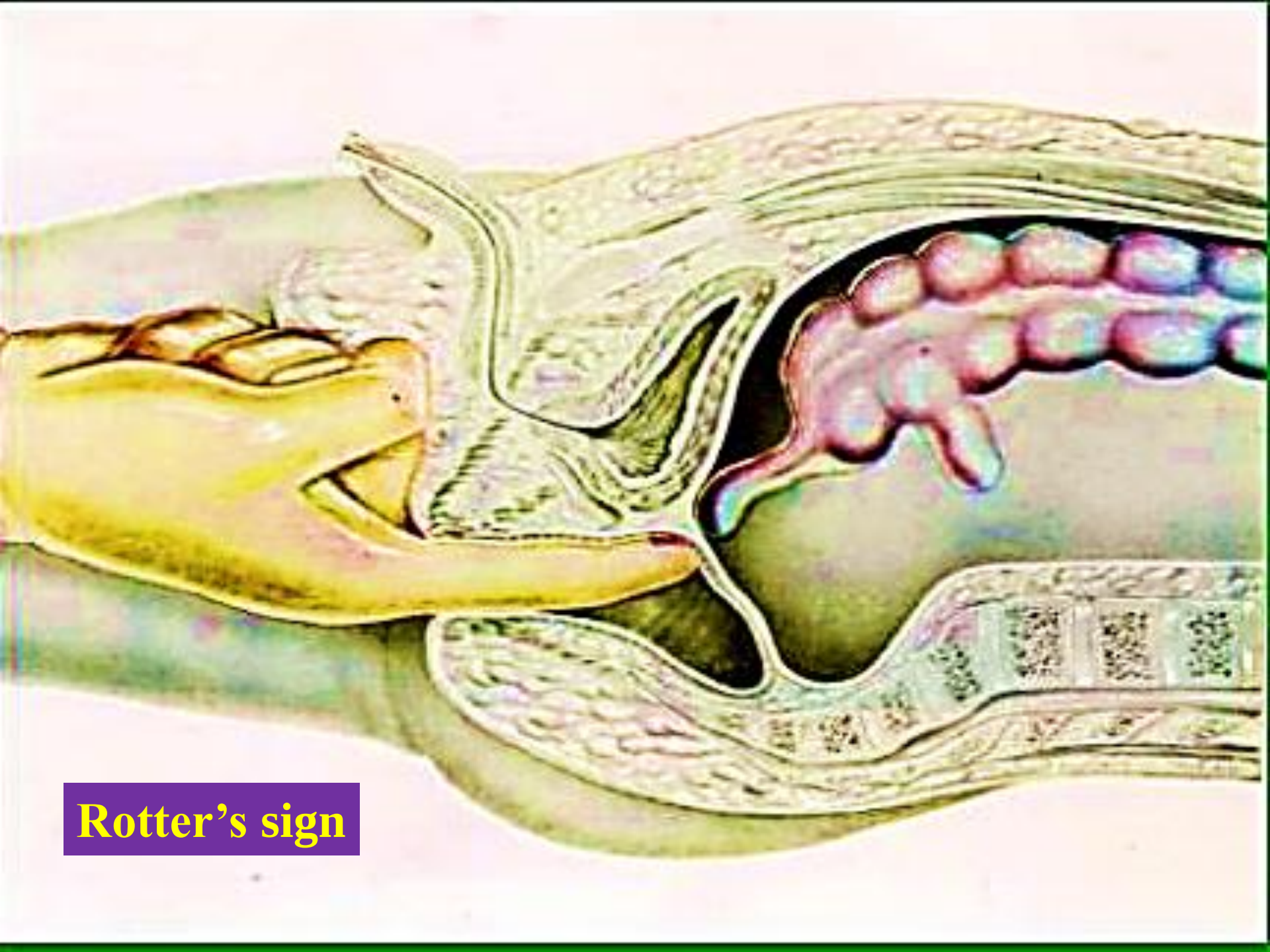
Rotter’s sign


(c)

Management

- Antibiotics.
- Pelvic abscesses can be drained transanally or transgluteally.
- *The past vogue for transintestinal drainage is no longer practised because of the high incidence of complications such as fistulae.*
- Laparotomy may sometimes be indicated.

Hemoperitoneum

- Anterior ruptured of aortic aneurysm.
- Ruptured ectopic pregnancy.
- Blunt trauma to the intraabdominal organ (liver , spleen).
- Penetrated intra-abdominal trauma.

- Dyspnea & Paler.
- Hemodynamically unstable.
- Distended abdomen
- Peritonism.
- Dull abdominal percussion.

Ix:

- Abdominal ultrasonography (FAST).
- Peritoneal aspiration.

- Resuscitation.
- Control the cause.

Pneumoperitoneum

Collection of air in the peritoneal cavity :

- *Perforated hollow viscus.*
- *Subdiaphramatic abscess with gas forming bacteria.*
- *Penetrated abdominal wall injury.*
- Post-laparoyomy.
- Post laparoscopic insufflation.
- Peritoneal dialysis.

conservative

- O/E : The abdomen id distended, and hyperresonant on percussion.
- DDX : Ascites. Chilaiditi's syndrome.

- Plain X Ray signs (Gas under the diaphragm (Crescent sign) and Rigler's sign (double wall appearance). DDX : Chilaiditi's sign (colon interposition below Rt diaphragm).

Chest x-ray PA view (erect) shows (Pneumoperitoneum)

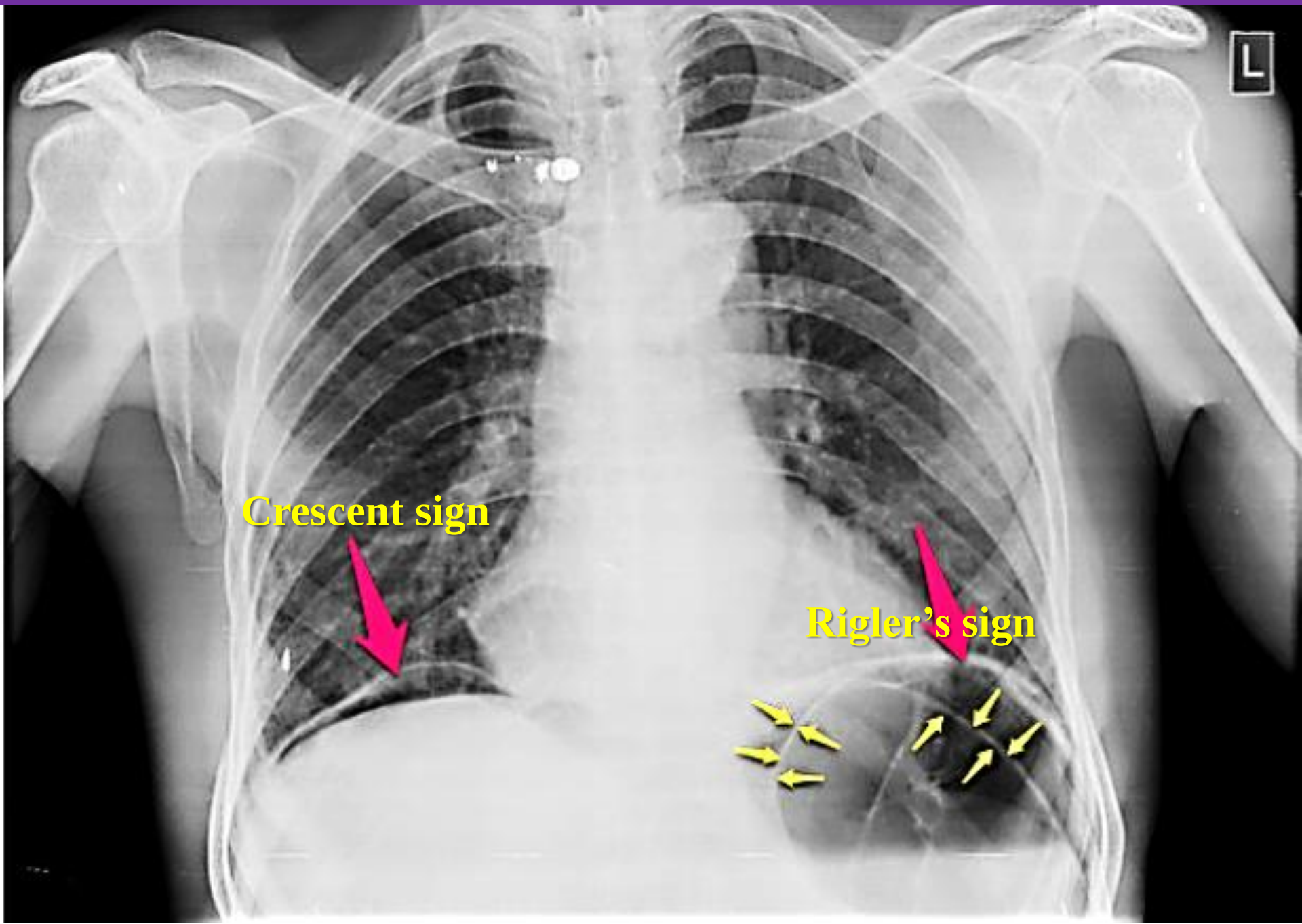

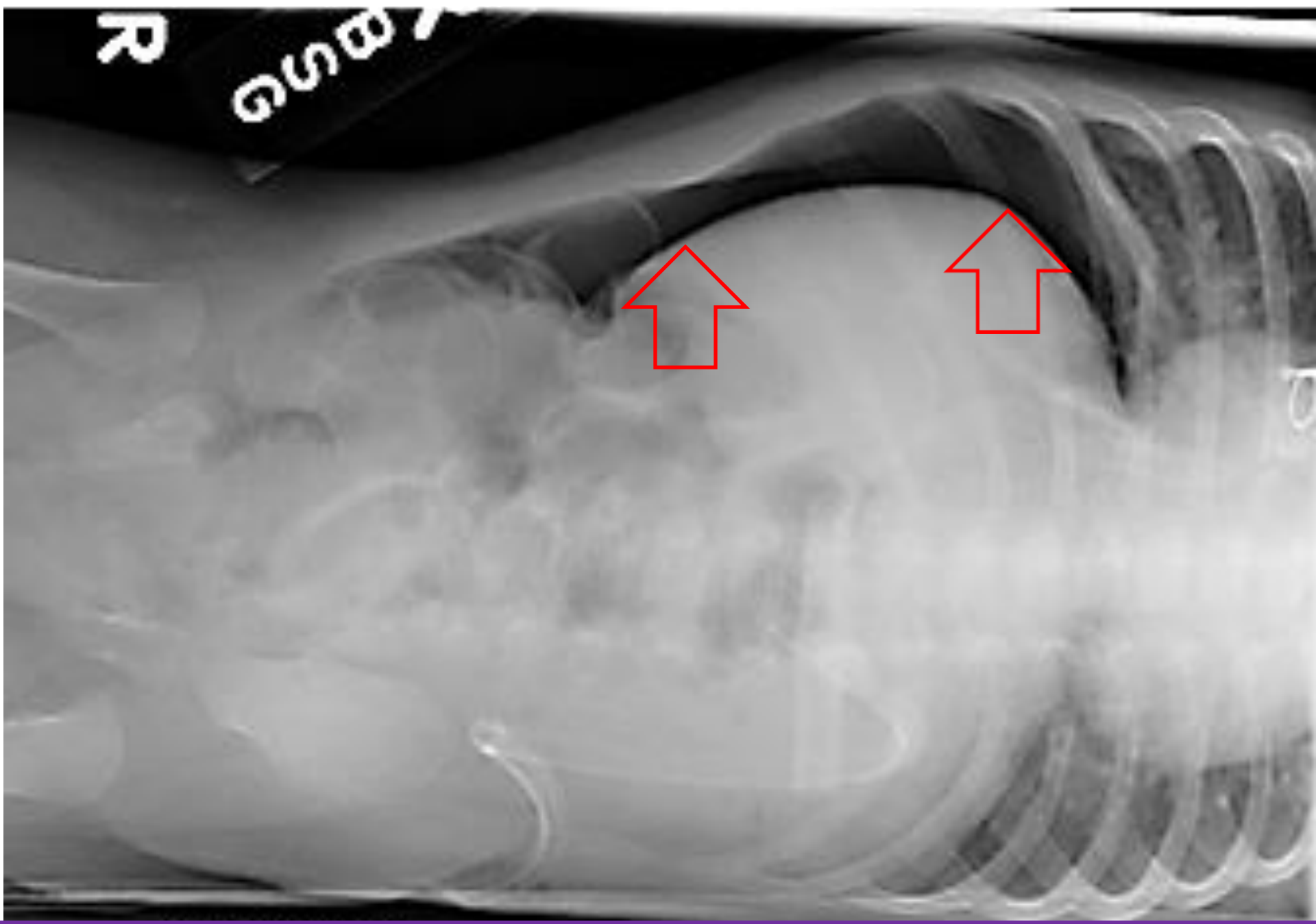

Plain X ray film (left lateral decubitus view) Pneumoperitoneum

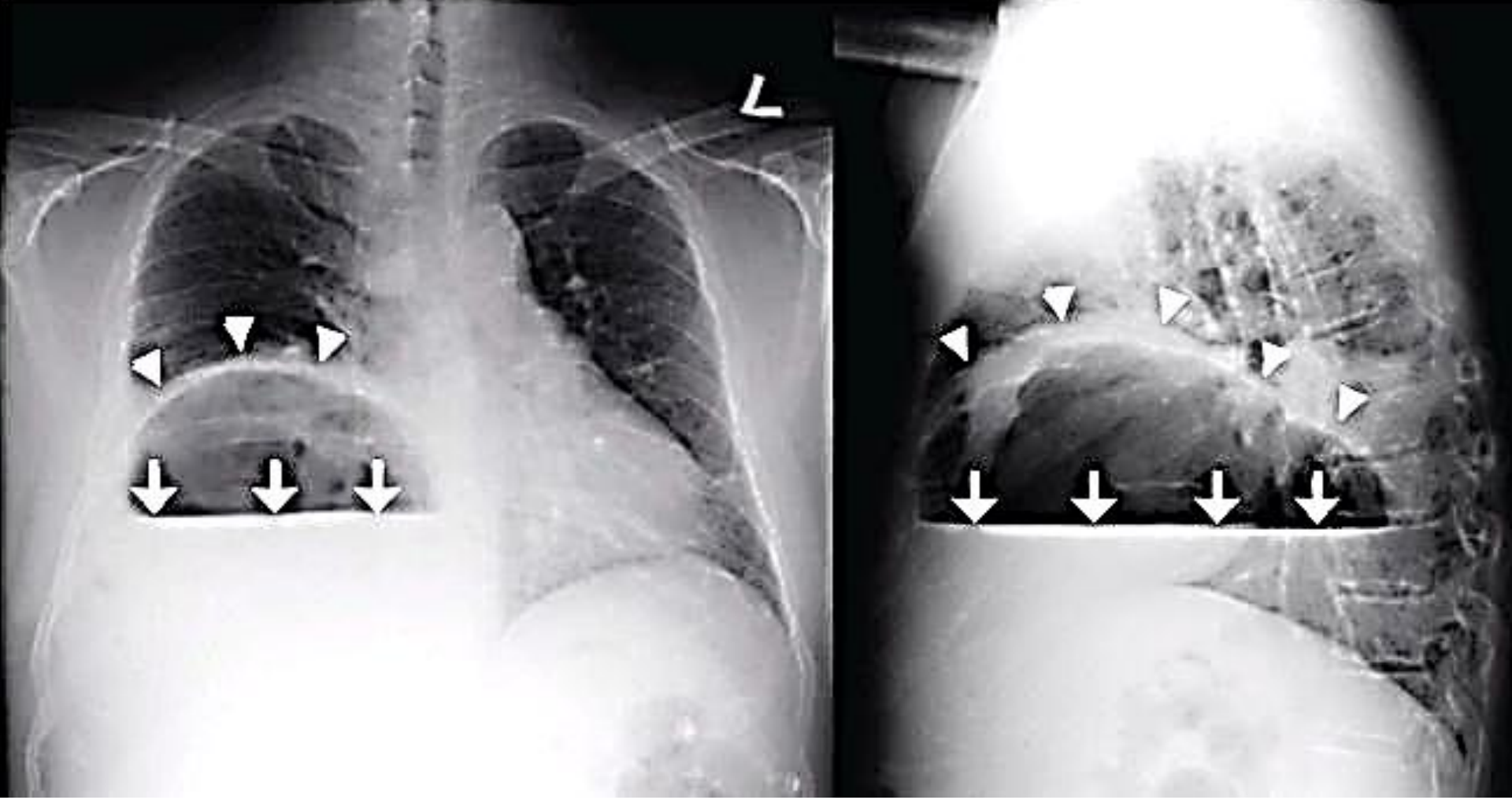

Plain chest radiography showed dramatic elevation of the right hemidiaphragm with a large subphrenic air-fluid level with Rt pleural effusion.

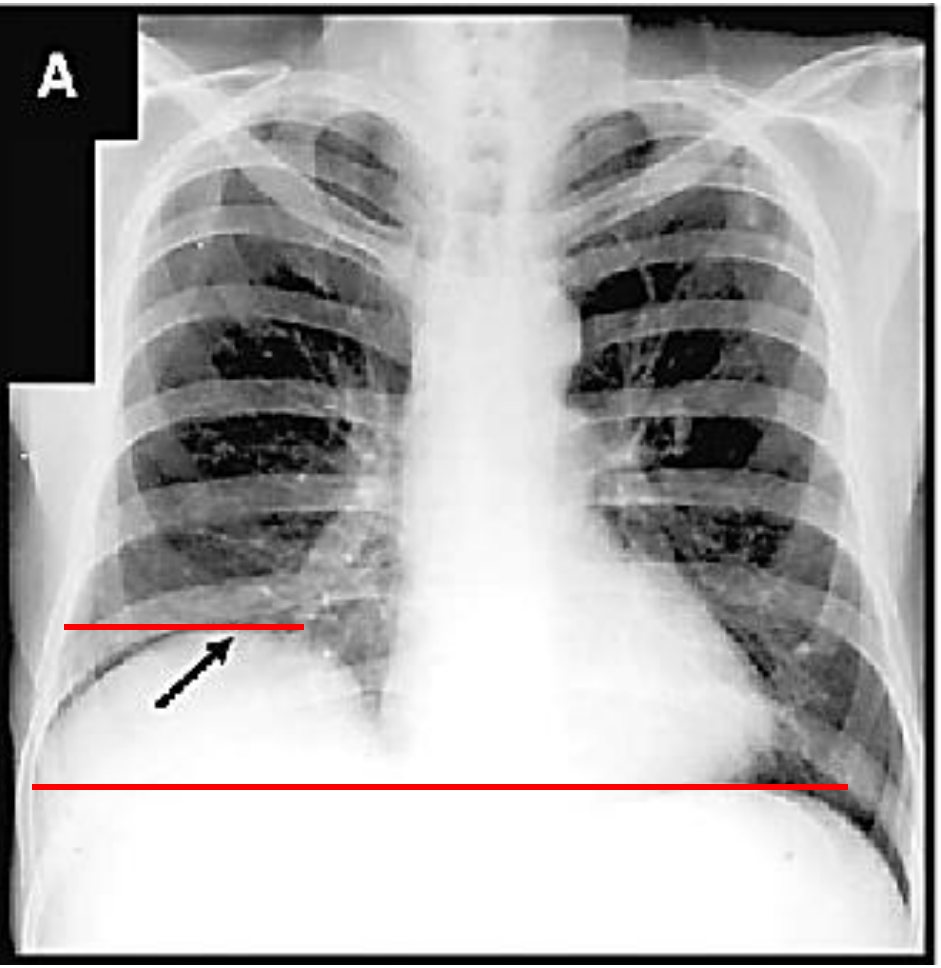

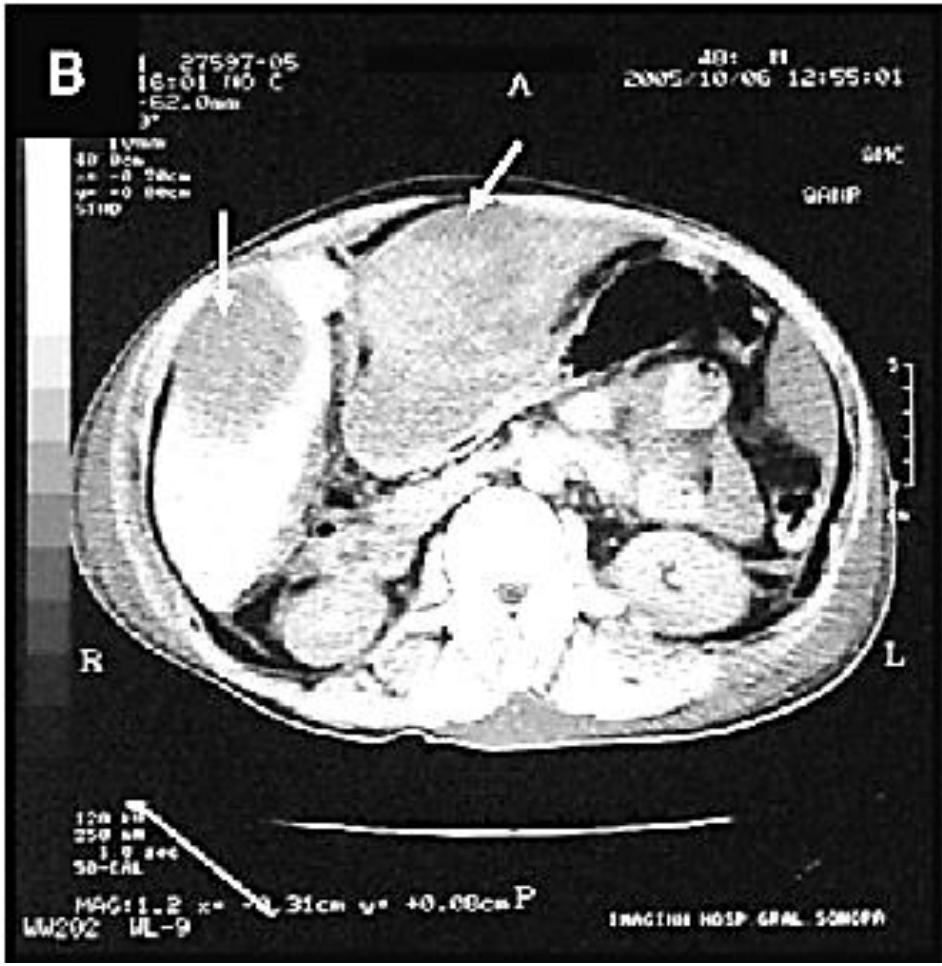

Liver span to assess the upper border of the liver

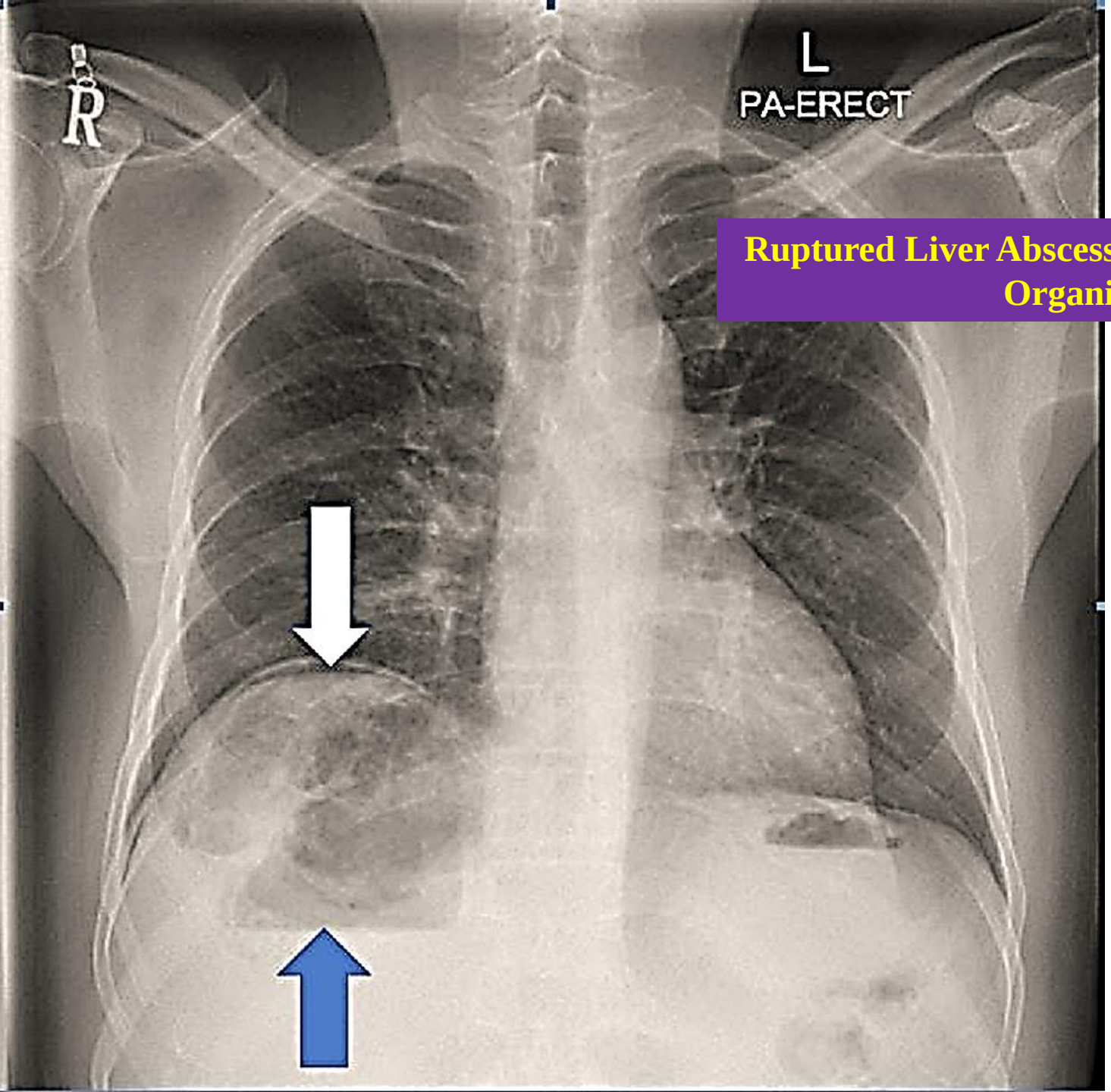

Ruptured Liver Abscess With Gas Forming Organism

Chest X-ray revealed right subdiaphragmatic free air suggesting pneumoperitoneum, with heterogeneous liver shadow and air-fluid level

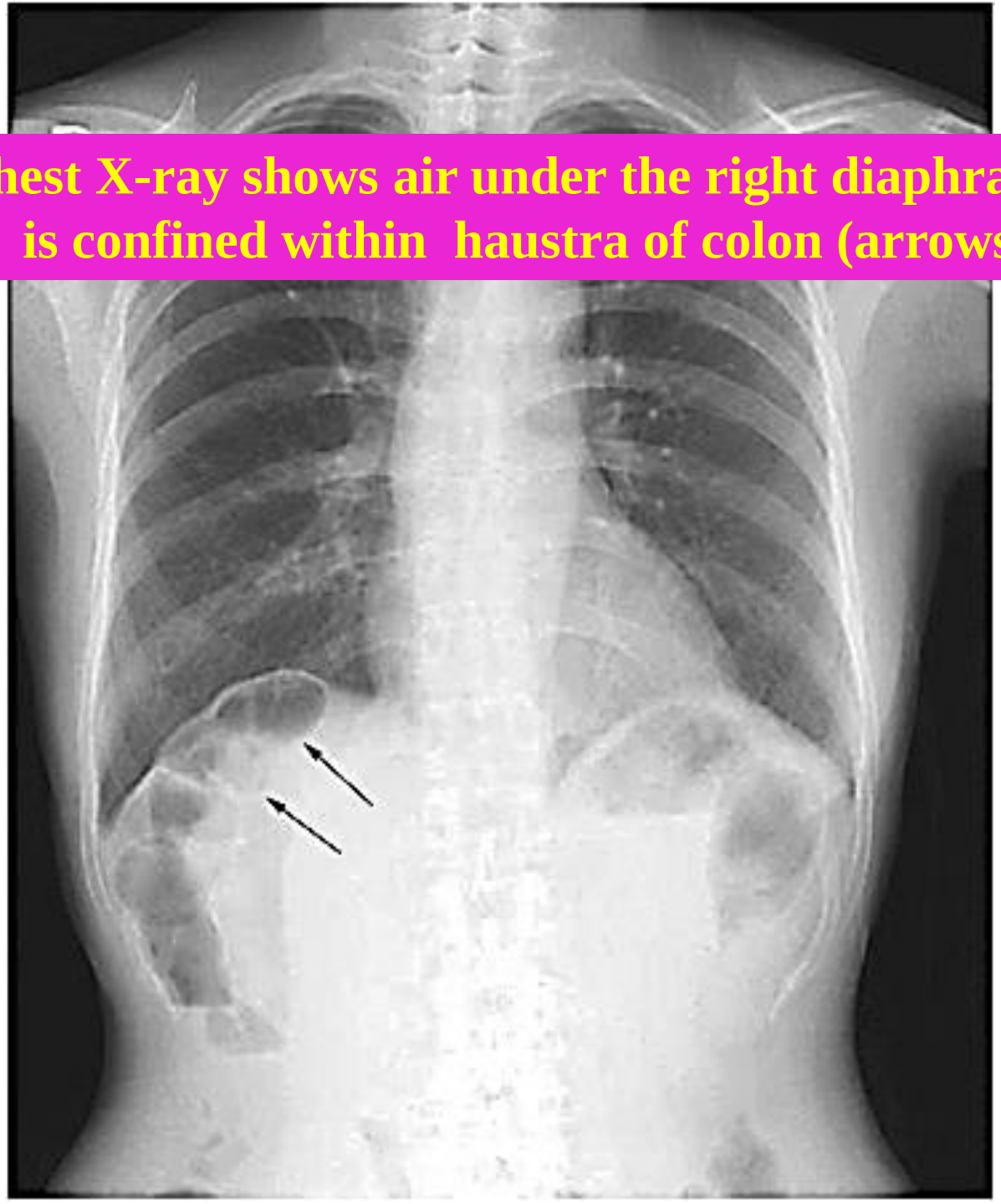

Plain chest X-ray shows air under the right diaphragm which is confined within haustra of colon (arrows).

Chilaiditi's sign

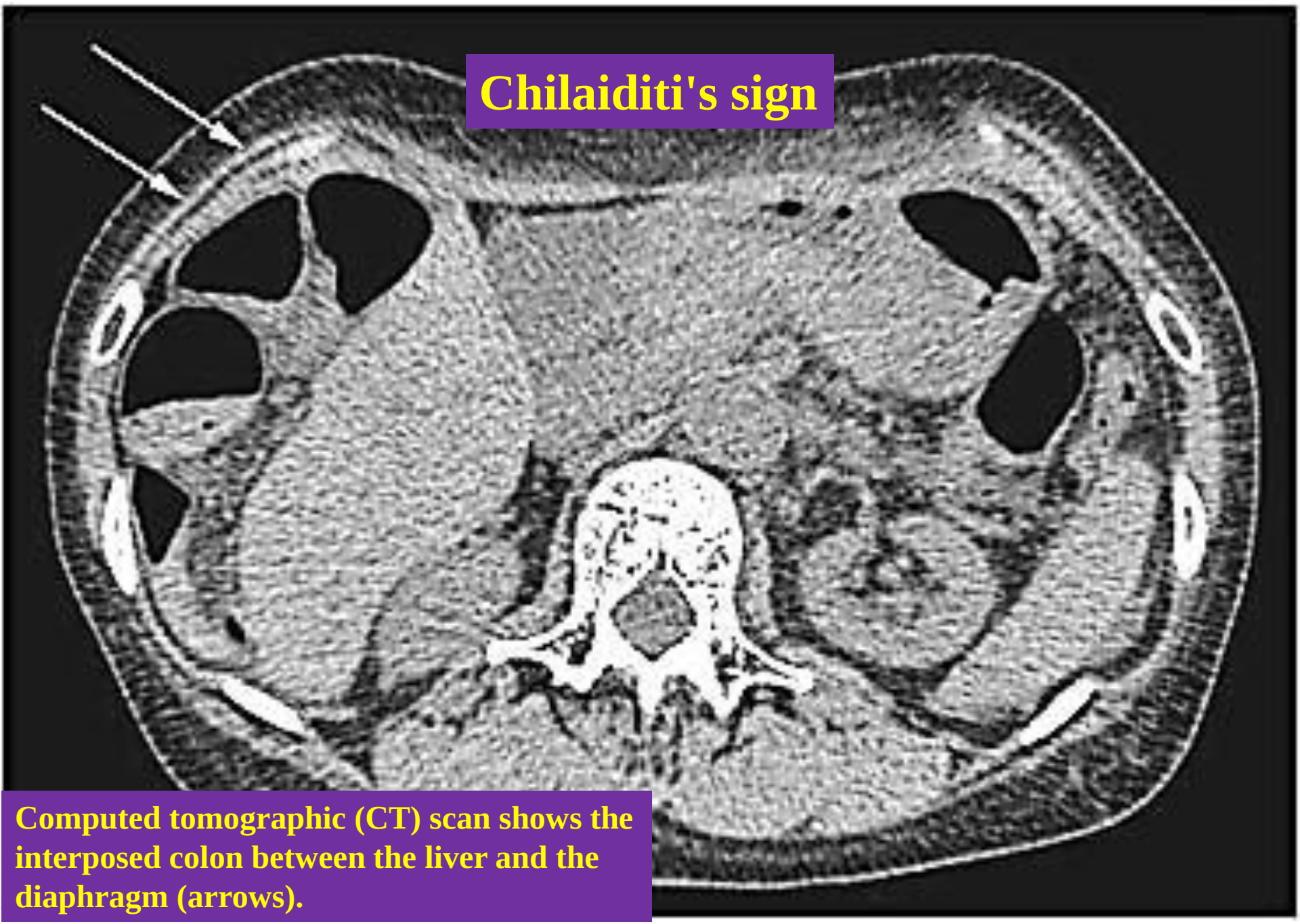

Computed tomographic (CT) scan shows the interposed colon between the liver and the diaphragm (arrows).

TUMOURS OF THE PERITONEUM

- Primary peritoneal malignancy
- Secondary peritoneal malignancy

Primary peritoneal malignancy

- Rare.
- They arise in the mesothelium of the peritoneum.
- Mesothelioma of the peritoneum is less frequent than in the pleural cavity but is equally lethal. Asbestos is a recognised cause. It has a predilection for the pelvic peritoneum.
- Presentation : abdominal distension (mass & ascites).
- Cytoreductive surgery with heated intraperitoneal chemotherapy (HIPEC) or systemic cisplatin-based chemotherapy are the mainstays of treatment.

- **Cytoreductive surgery** (CRS) is a surgical procedure that aims to reduce the amount of cancer cells in the abdominal cavity for patients with tumors that have spread intraabdominally (peritoneal carcinomatosis). It is often used to treat ovarian cancer but can also be used for other abdominal malignancies. It is often used in combination with Hyperthermic Intraperitoneal chemotherapy (HIPEC).

- HIPEC is a highly concentrated, heated (41–42°C) chemotherapy delivered directly into the abdomen for 90 minutes after cytoreductive surgery. HIPEC is particularly valuable in treatment of pseudomyxoma peritonei and has become the standard of care in carefully selected patients assessed in specialist centres .



HIPEC Machine

HIPEC at time of interval debulking surgery

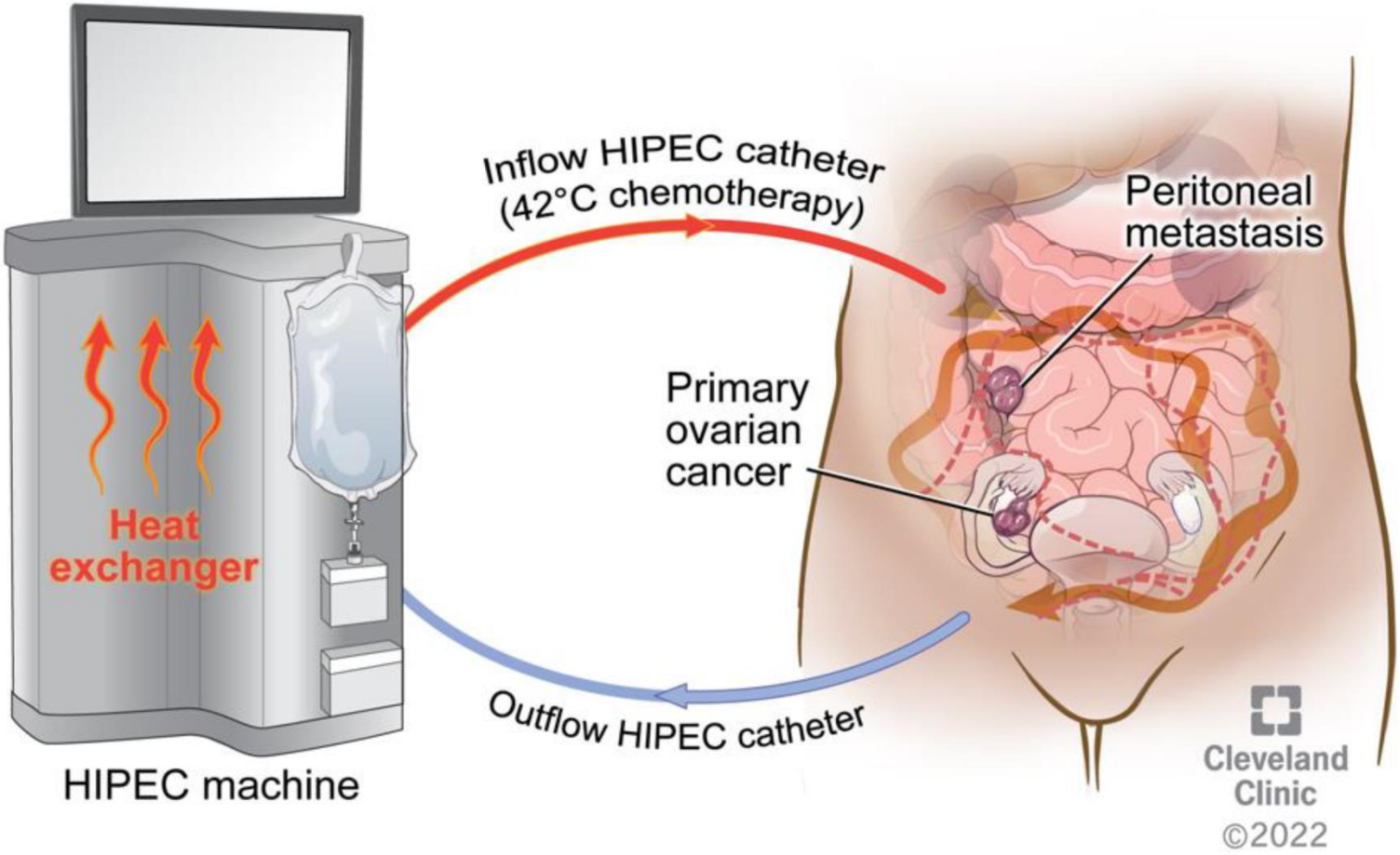

	IDS (months)	IDS + HIPEC (months)	HIPEC Benefit (months)
RFS	10.7	14.2	+3.5
OS	33.9	45.7	+11.8

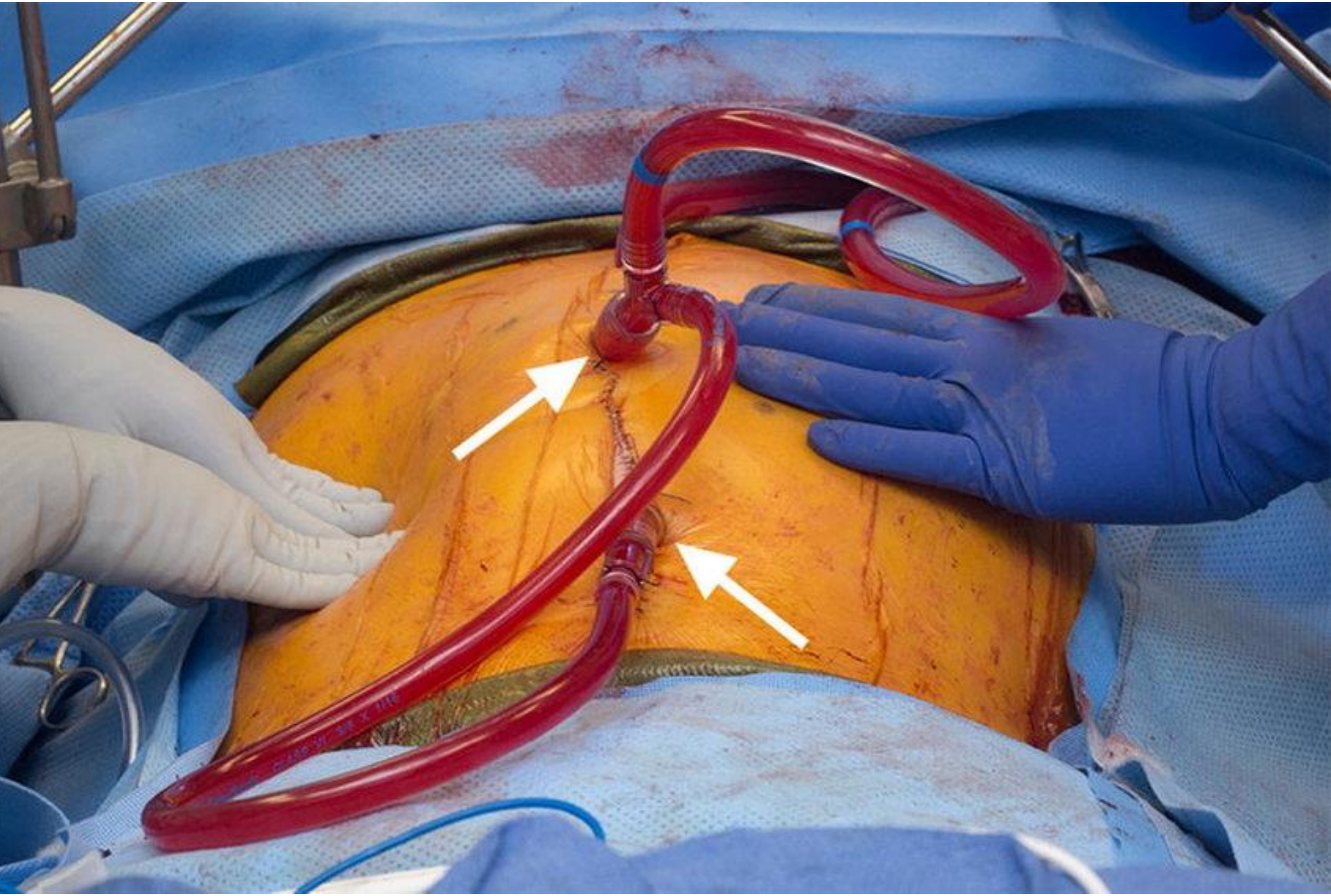

Secondary peritoneal malignancy

- Peritoneal carcinomatosis
- It is common and refers to malignant nodules on the surface of the peritoneum.
- It arises in conjunction with ovarian malignancy or malignancy in an organ of the mesenteric domain.
- It can be localised or diffuse.
- Any peritoneal surface can be involved. Sometimes the omentum is diffusely involved, forming a mass termed an omental cake.
- The symptoms and signs are mainly related to the primary pathology (cachexia (3 As), abdominal distension (mass & ascites or SBO), under lying malignancy & metastatic signs (4 Ls).

- Adominal CT scan or (MRI) is usually diagnostic. But, histological or cytological confirmation is essential to distinguish it from peritoneal TB. The visceral origin of peritoneal carcinomatosis is important as this can guide chemotherapy and cytoreductive or extirpative surgery.
- The visceral origin of peritoneal carcinomatosis is important because if curative resection of the primary tumour is deemed feasible and the peritoneal disease considered resectable, resection with peritonectomy and HIPEC should be considered.
- In the majority of patients with peritoneal carcinomatosis treatment is palliative. Subacute intestinal obstruction may require intestinal bypass or a defunctioning stoma.
- Malignant ascites may be drained externally or via a peritoneovenous shunt (LeVeen).

Pseudomyxoma peritonei

- Is caused by cancerous cells (mucinous adenocarcinoma) that produce abundant mucinor gelatinous ascites.The tumors cause fibrosis of tissues and impede digestion or organ function, and if left untreated, the tumors and mucin they produce will fill the abdominal cavity.
- This disease is most commonly caused by an appendiceal primary cancer (cancer of the appendix); mucinous tumors of the ovary .
- Ps: cachexia, abdominal distension (jelly belly),
- Abdominal CT scan , laparoscopic biopsy & tumor marker.
- Treatment ranges from watchful waiting to debulking and hyperthermic intraperitoneal chemotherapy (HIPEC)with cytoreductive surgery.

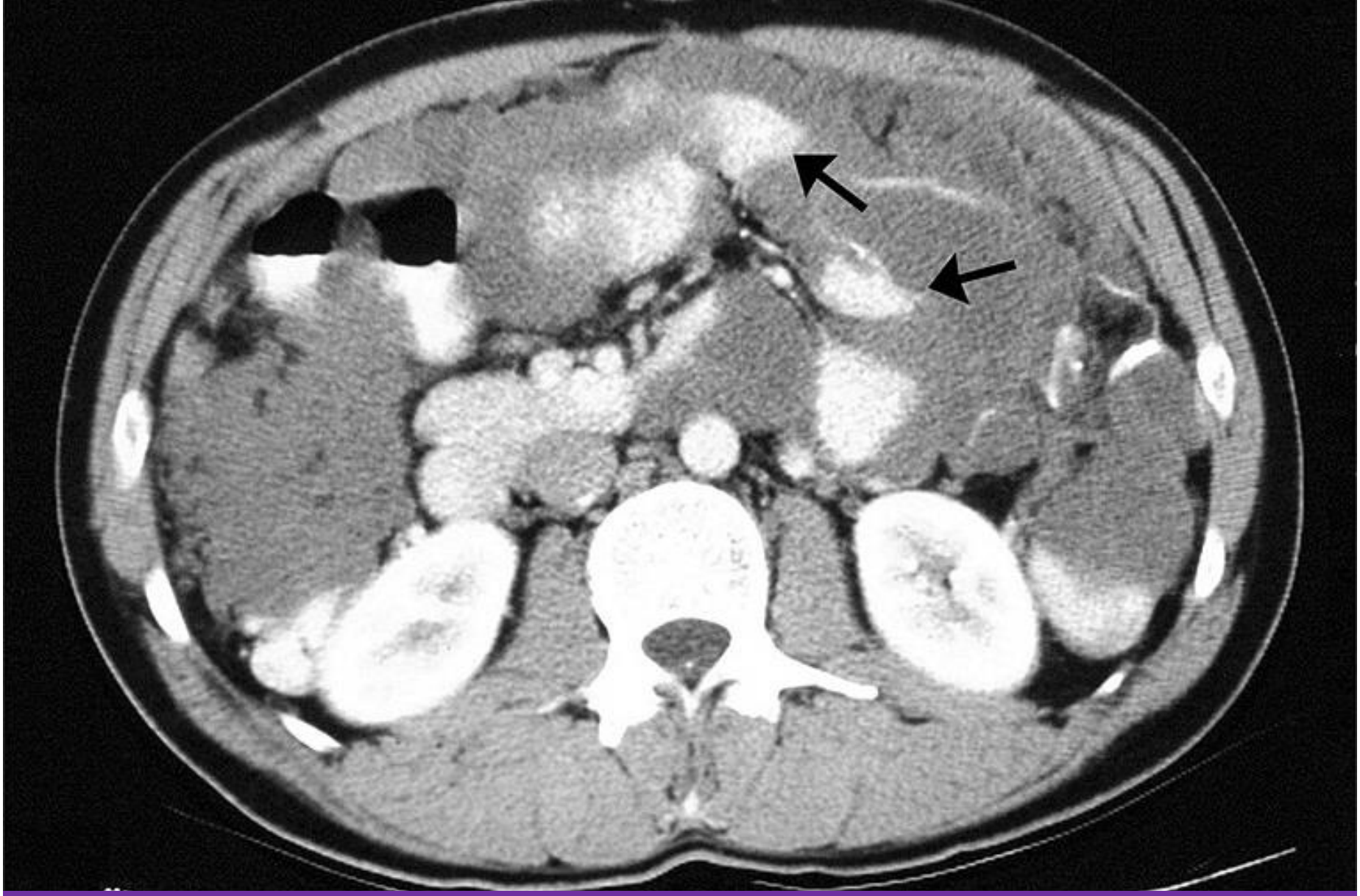

Computed tomographic scan of an abdomen showing pseudomyxoma peritonei with multiple peritoneal masses (arrow) with "scalloping effect" seen.



Appendicular pseudomyxoma with enlarged base (female)

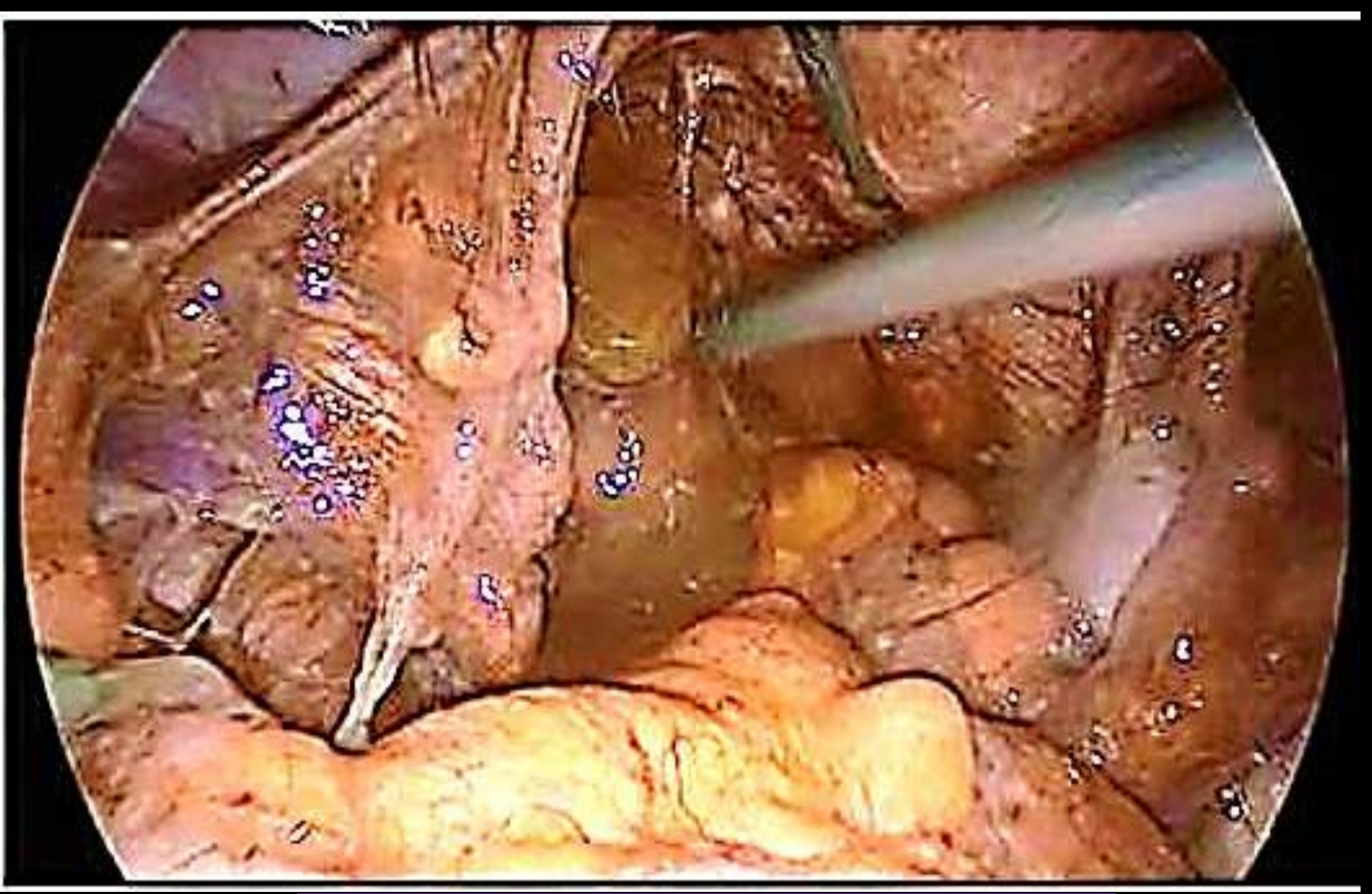

Gelatinous material in the Douglas' pouch (female)



PRAISE BE TO ALLAH