Lymphoreticular system pathology

LEC.1

Dr. Raghad Hanoon

- **The Lymphoreticular system** consists of **the tissues of the lymphoid system and the mononuclear phagocyte system.**
- **The mononuclear phagocyte system** includes monocytes, tissue macrophages, the endothelium lining the sinusoids of the spleen, lymph nodes, and bone marrow, and the fibroblastic reticular cells of hematopoietic tissues.
- **Lymphocytes** are the immunologically competent cells that assist the phagocytes in defense of the body against infection and other foreign invasion.

Lymphoid Organs:

➢ ***The primary lymphoid organs*:**

- Include the bone marrow and thymus, where lymphocytes develop in the postnatal life.

➢ ***The secondary lymphoid organs:***

- In which specific immune responses are generated, include the lymph nodes, spleen and **Mucosa-associated lymphoid tissue (MALT): includes** discrete lymphoid structures such as in the appendix, Peyer's patches in the submucosa of the intestine and the tonsils and adenoids (the latter collectively referred to as Waldeyer's ring) in the pharynx.

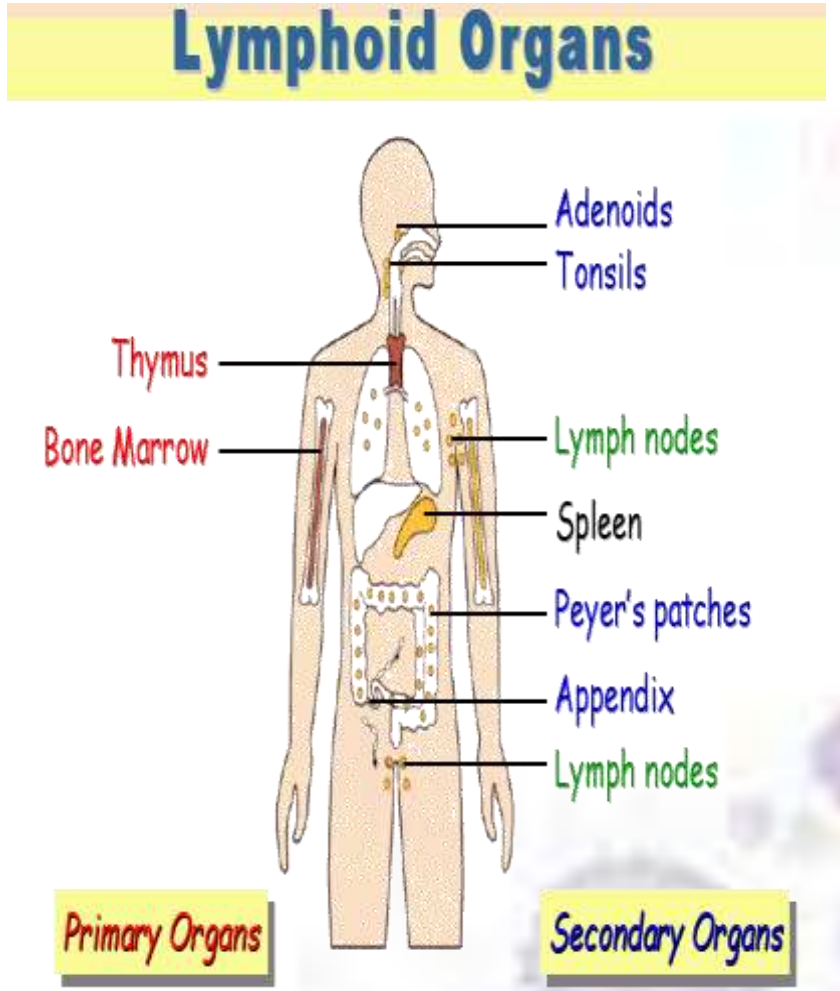

The structure of lymph node:

- **Lymph node is divided into:**

1. Cortex: within the cortex are **primary follicles**, which are composed of B-lymphocytes and follicular dendritic cells.

- **On antigen exposure,** proliferation and maturation of B cells cause the primary follicle to develop into **a secondary follicle.**
- Secondary follicle has **a germinal center surrounded by a mantle zone** of small B-lymphocytes.
- Outside the mantle zone, some lymph node germinal center have a **marginal zone,** also composed of B-lymphocytes.

2. Paracortex: T cells occupy the paracortex, which surrounds and underlies the primary and secondary follicles. The paracortex also has abundant dendritic cells.

3. Medulla: In the center of the lymph node, it composed of medullary cords and sinuses. B and T lymphocytes, plasma cells and macrophages occupy the medullary cords.

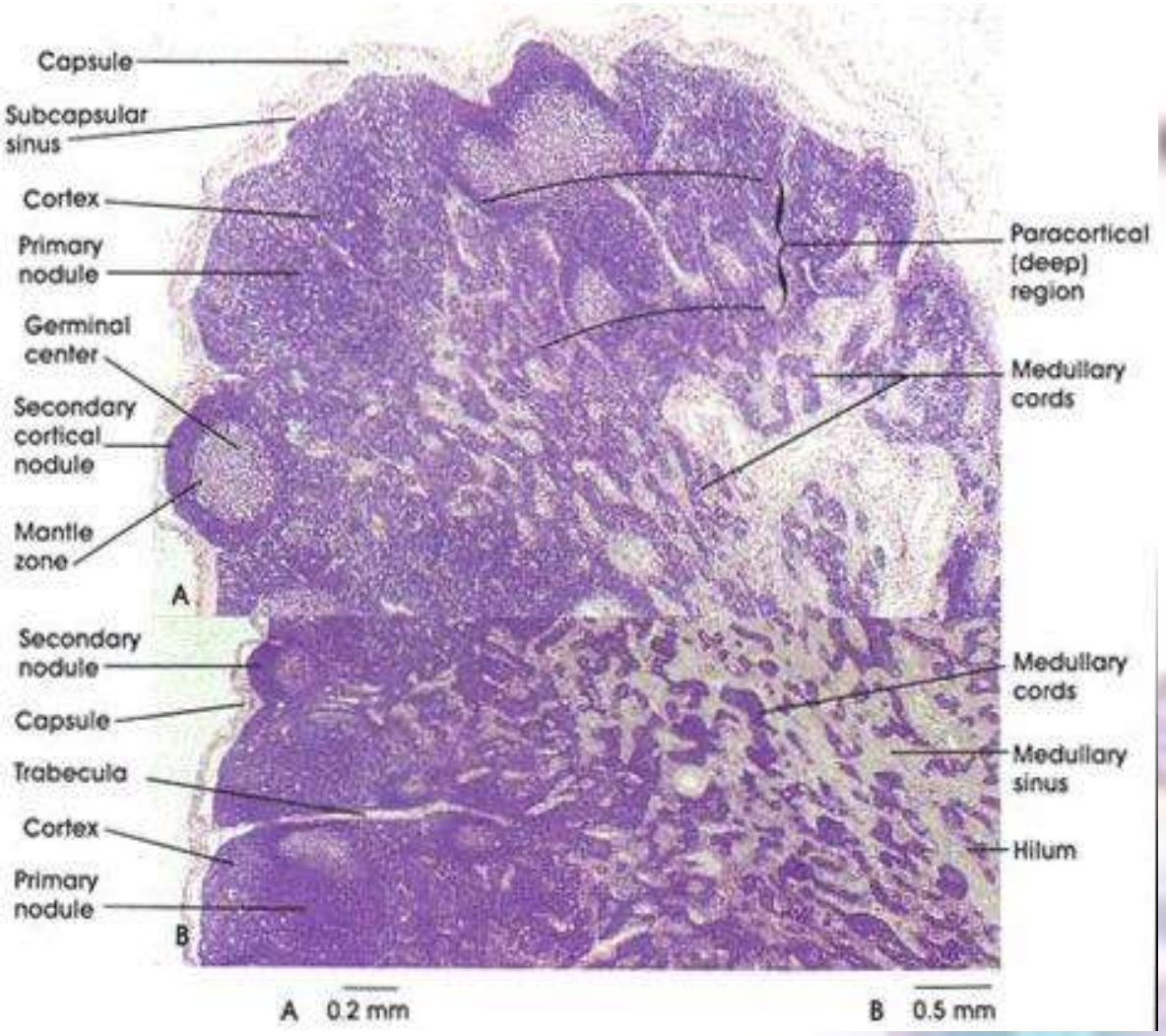

❖ Lymphocytosis:

- **It is an increased lymphocyte count**
- ***Causes:***

1. **Infections;**

- *Acute: infectious mononucleosis, rubella, pertussis,* mumps, infectious hepatitis, cytomegalovirus, herpes simplex or zoster
- *Chronic: tuberculosis, toxoplasmosis, brucellosis,* syphilis

2. **Chronic lymphoid leukemia .**
3. **Acute lymphoblastic leukemia**
4. **Non-Hodgkin's lymphoma (some)**

❖ lymphopenia:

- **It is a reduced lymphocyte count**
- **Causes:**

1. Severe bone marrow failure.
2. Corticosteroid and other immunosuppressive therapy.
3. Malnutrition
4. Certain acute viral infections..
5. Widespread irradiation.
6. Immunodeficiency syndromes, the most important of which is HIV infection.

Infectious Mononucleosis (glandular fever)

- An acute, self-limited disease of adolescents and young adults that is caused by Epstein-Barr virus (EBV), a member of the herpes virus family.

- Characterized by;

(1) Fever, sore throat and generalized lymphadenitis

(2) A lymphocytosis of activated **CD8+ T cells.**

➢ Pathogenesis:

- EBV is ubiquitous in all human populations. **In developing** countries infection occur early in life and usually asymptomatic, **In developed** countries occur at adolescence and usually symptomatic.
- Transmission to a seronegative **"kissing cousin"** usually involves direct oral contact.
- The virus initially infects oropharyngeal epithelial cells and then spreads to underlying lymphoid tissue (tonsils and adenoids), **mature B cells are infected and proliferate.**
- Early in the course of the infection, IgM antibodies are formed against viral capsid antigens; Later the serologic response shifts to IgG antibodies, which persist for life.
- More important in the control of the EBV-positive B cell proliferation are cytotoxic CD8+ T cells.
- Virus-specific CD8+ T cells appear in the circulation as **atypical lymphocytes**, a finding that is characteristic of mononucleosis.

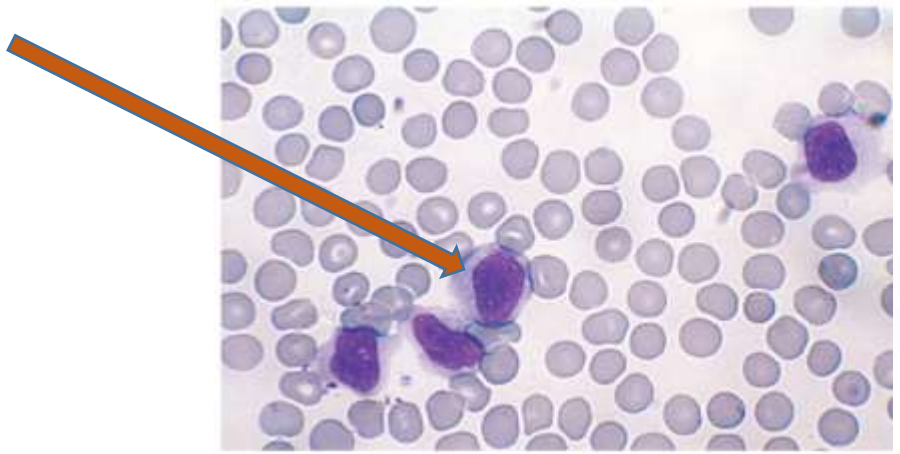

➢ Diagnosis:

The diagnosis depends on the following findings:

1. Lymphocytosis with the characteristic atypical lymphocytes in the peripheral blood.

2. A positive heterophil reaction (monospot test).

3. A rising titer of antibodies specific for EBV antigens**.**

4. In atypical cases (only fever or only lymphadenopathy…etc) biopsy of lymph node is indicated to differentiate from lymphoma.

➢ Clinical course and complications:

- In most patients, mononucleosis resolve within 4 to 6 weeks.
- Occasionally, one or more complications develop:-

*Perhaps the most common of these is hepatic dysfunction (the virus produce viral hepatitis which might progress into hepatic failure).

*Other complications involve the nervous system, kidneys, bone marrow, lungs, eyes, heart, and spleen (splenic rupture can occur due to extensive infiltration of the spleen by the atypical lymphocytes producing enlargement and weakening of the capsule).

*EBV is a potent transforming virus that plays a role in the pathogenesis of a number of human malignancies, including **several types of B cell lymphoma** (if there is impairment of T-cell immunity).

Non-Neoplastic Conditions

Reactive Lymphadenitis:

- Any immune response against foreign antigens is often associated with lymph node enlargement **(lymphadenopathy)**.
- The infections that cause lymphadenitis are numerous and varied and may be acute or chronic.
- In most instances, the **histologic appearance** of the nodes is entirely **nonspecific.**
- A somewhat distinctive form of lymphadenitis that occurs with cat-scratch disease is described separately later.

Causes of Lymphadenopathy

Localized	Generalized
local infection • pyogenic infection, e.g. pharyngitis, dental abscess, otitis media, • viral infection • cat scratch • lymphogranuloma venereum • tuberculosis ***lymphoma*** • Hodgkin's lymphoma • non-Hodgkin's lymphoma ***Carcinoma (secondary)***	***Infection*** • **viral**, e.g. infectious mononucleosis, measles, rubella, viral hepatitis, HIV • **bacterial**, e.g. syphilis, brucellosis,tuberculosis, *Salmonella,* • **fungal,** e.g. histoplasmosis • **protozoal**, e.g. toxoplasmosis ***Non-infectious inflammatory diseases***, e.g. sarcoidosis, rheumatoid arthritis, SLE, other connective tissue diseases, ***Malignant*** • leukaemias, especially CLL, All • lymphoma: non-Hodgkin's lymphoma, Hodgkin's lymphoma ***Miscellaneous*** • reaction to drugs and chemicals • hyperthyroidism

Acute Nonspecific Lymphadenitis

- It may be **Focal** confined to local group of L.N draining focal infection, Or it may be **Generalized** as in systemic infectious and inflammatory conditions.

- **Macroscopically**: inflamed nodes are swollen gray-red.
- **Microscopically**: there are **large germinal centers** containing numerous mitotic figures.
- When the cause is a pyogenic organism, a neutrophilic infiltrate is seen.
- With severe infections, there is necrosis and abscess formation**.**
- The overlying skin is frequently red, and sometimes penetration of the skin can produce draining sinuses.
- With control of the infection, the lymph nodes can revert to their **normal appearance** or, if damaged by the immune response, undergo **scarring.**

Acute Nonspecific Lymphadenitis

Gross : L.N swollen tender the overlying skin is red with **fluctuation** if there is abscess.

Microscopic : large germinal centers, neutrophils, the center of the follicles undergo necrosis result in the formation of an **abscess.**



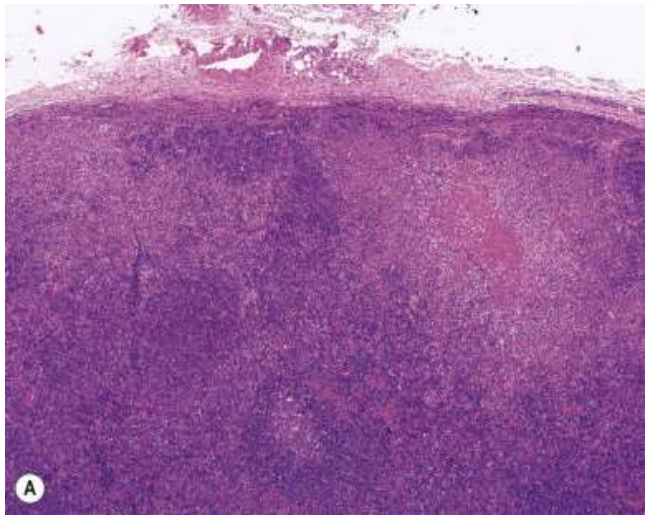

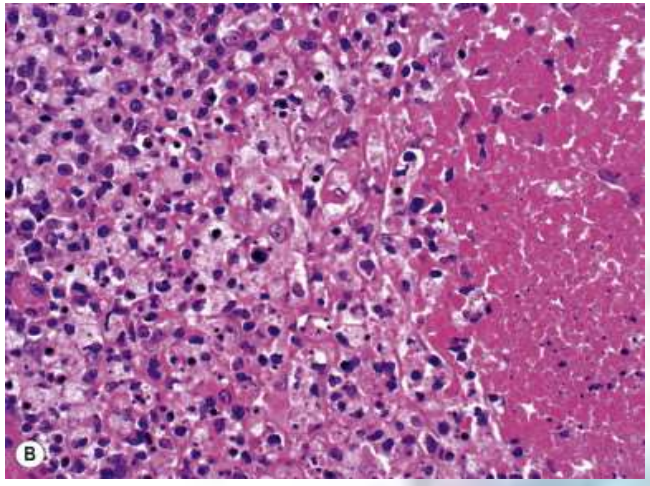

Chronic Nonspecific Lymphadenitis

- This condition can assume one of three patterns, **depending on the causative agent:**

1- Follicular hyperplasia:

- Associated with infections or inflammatory processes that **activate B cells** which migrate into B cell follicles and create the follicular (or germinal center) reaction.
- The cells in the reactive follicles include: the activated B cells (called follicular center cells), phagocytic macrophages containing nuclear debris (tangible body macrophages) and meshwork of antigen-presenting follicular dendritic cells.
- **Causes** include Rheumatoid arthritis, Toxoplasmosis, and the early stages of HIV infection.

Note: This form of lymphadenitis must be distinguished from follicular lymphoma (discussed later). **Findings that favor follicular hyperplasia are:**

(1) the preservation of the lymph node architecture;

(2) variation in the shape and size of the germinal centers;

(3) prominent phagocytic and mitotic activity in germinal centers.

(A)

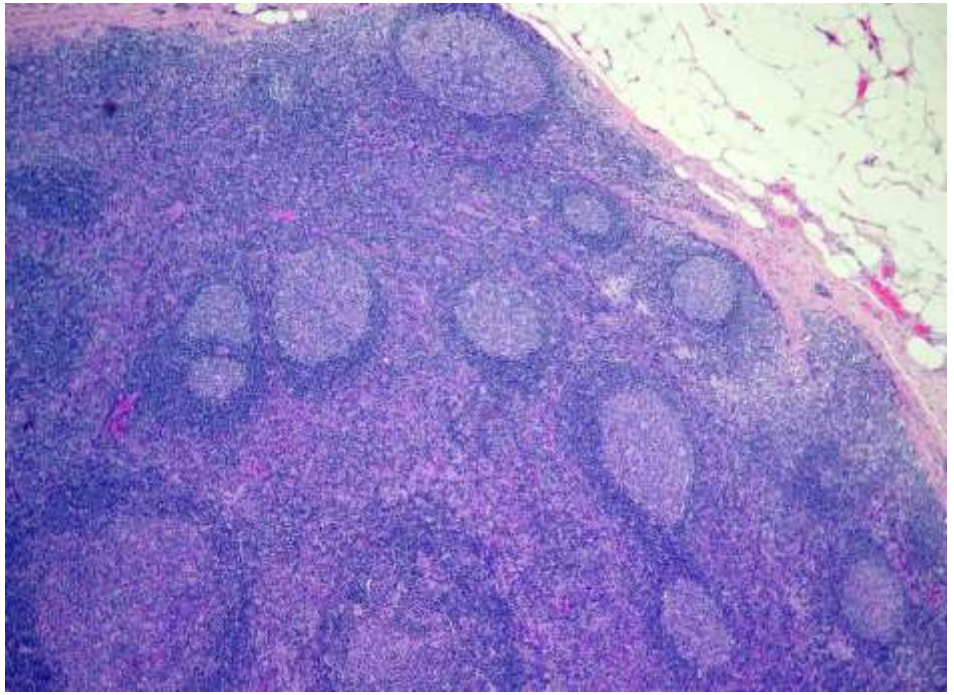

(B)

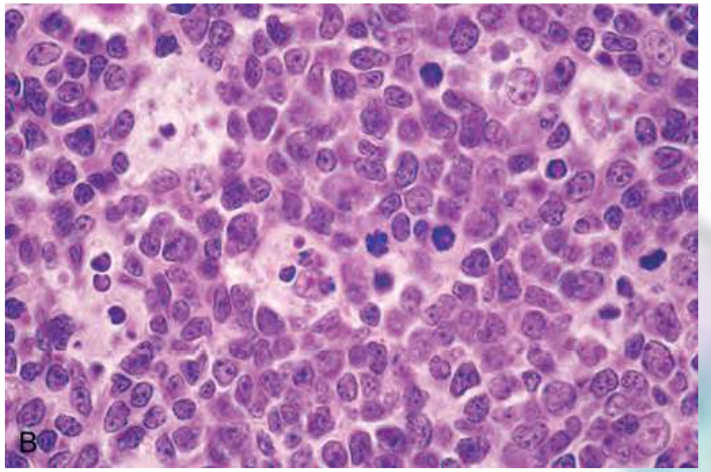

Follicular hyperplasia. (A) Low-power view showing a reactive follicles and surrounding mantle zone. **(B)** High-power view of the dark zone shows several mitotic figures and numerous macrophages containing phagocytosed apoptotic cells (tangible bodies).

2-Paracortical hyperplasia:

- Caused by immune reactions involving **the T cell regions of the lymph node,** which is reflected microscopically as expanded zones between the cortical follicles.
- Paracortical hyperplasia is encountered in:

Viral infections (such as EBV), Following certain vaccinations (e.g., smallpox), and in immune reactions induced by certain drugs (especially phenytoin).

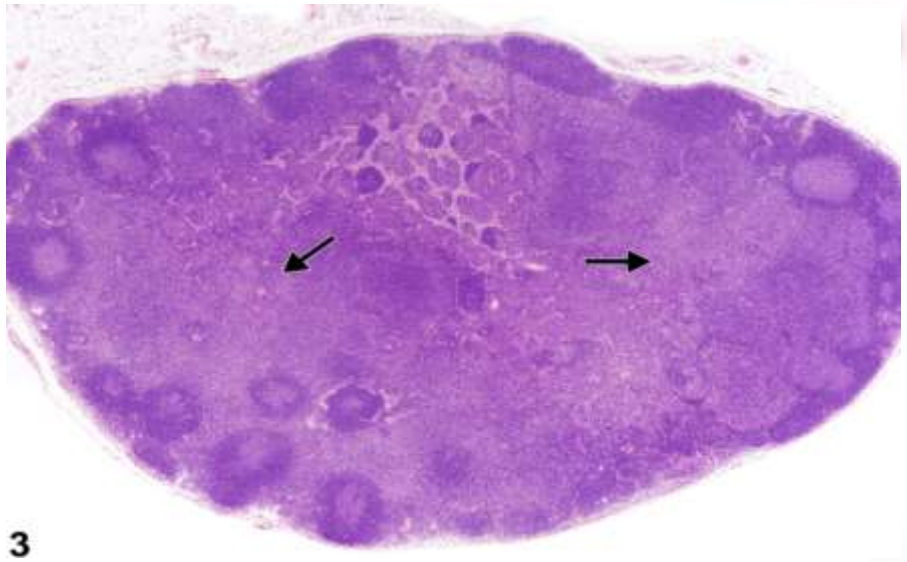

3

3-Sinus Histiocytosis:

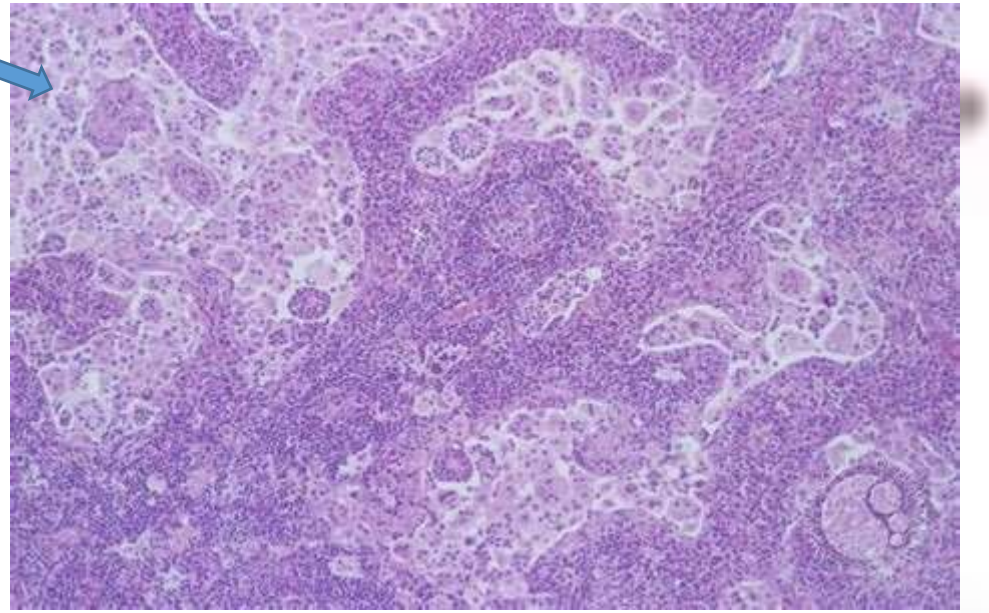

- Characterized by distention and prominence of the lymphatic sinusoids, owing to a marked hypertrophy of lining endothelial cells and an infiltrate of macrophages (histiocytes).
- Sinus histiocytosis is often encountered in: Lymph nodes draining cancers (may represent an immune response to the tumor or its products).

Granulomatous Inflammation

- Large number of diseases that can result in granulomatous formations in lymph nodes. They include;

A. Various types of infections: **Tuberculosis and atypical mycobacteria, Sarcoidosis, Fungal infections and Cat-scratch disease**

B. Foreign body reactions

C. Immunological conditions.

D. Chemical causes; beryllium, zirconium, silica, talc,. Etc.

E. Reaction to malignancy (Lymphoma or metastasis), whether the LN is involved or not by the tumor).

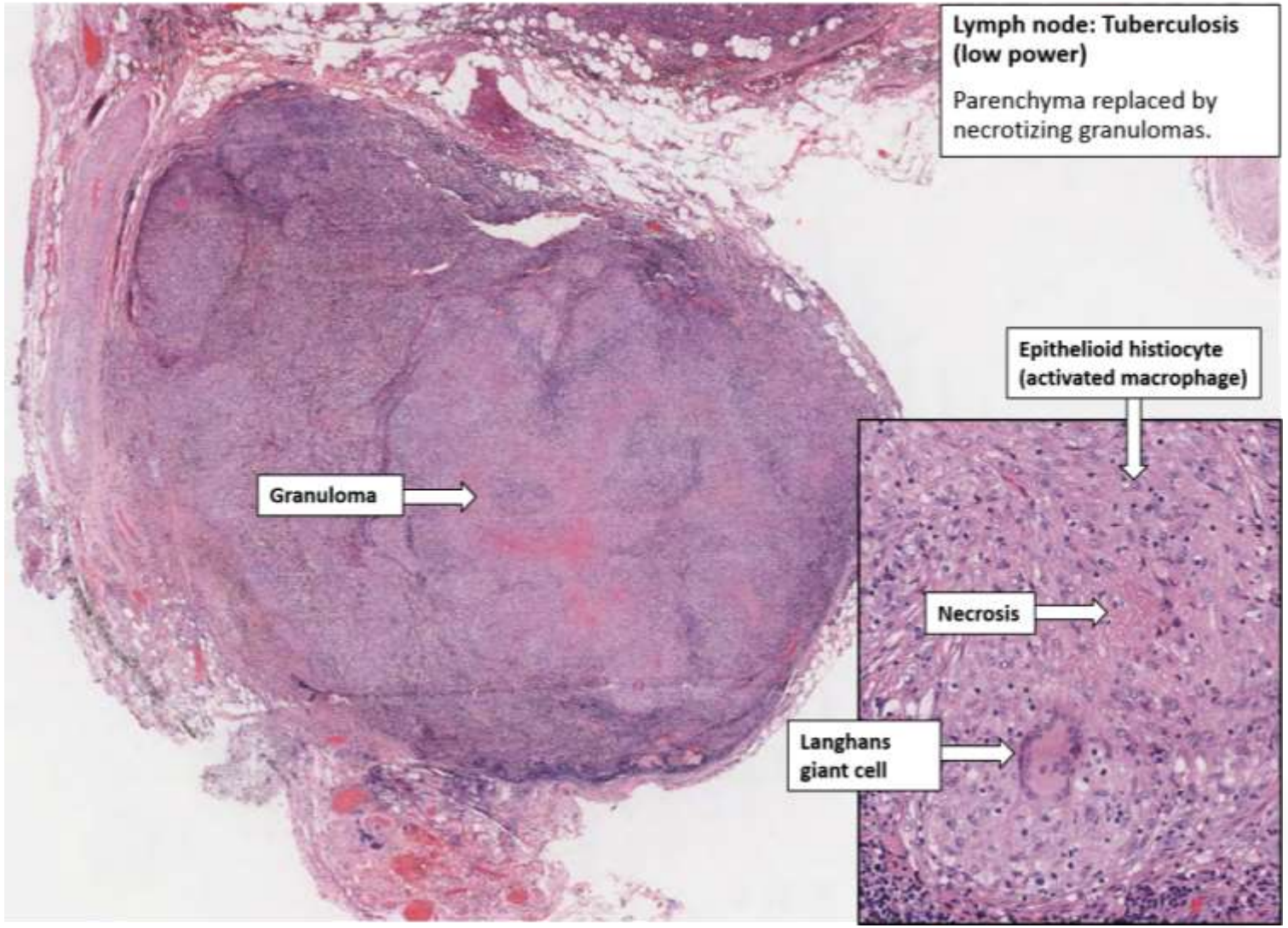
Lymph node: Tuberculosis (low power)
Parenchyma replaced by necrotizing granulomas.
Epithelioid histiocyte (activated macrophage)
Granuloma
Necrosis
Langhans giant cell

❖ Cat scratch disease

- A **self-limited lymphadenitis** caused by the bacterium ***Bartonella henselae*.**
- It is primarily a disease of childhood; 90% of the patients are younger than 18 years of age.
- It presents as **regional lymphadenopathy**, appears approximately 2 weeks after a feline scratch or a splinter or thorn injury, most frequently in the **axilla and neck.**
- A raised, inflammatory nodule or vesicle, is sometimes visible at the site of skin injury
- In most patients, the lymph node enlargement regresses over the next 2 to 4 months. Rarely, patients develop encephalitis, thrombocytopenia or osteomyelitis.

➢ Morphology of Cat scratch disease:

Sarcoid-like granulomas, these then undergo central necrosis associated with the accumulation of neutrophils forming **irregular stellate necrotizing granulomas**.

➢ **The diagnosis** is based on **a history** of exposure to cats, the characteristic **clinical findings**, a positive result on **serologic** testing for antibodies to *Bartonella,* and the distinctive **morphologic** changes in the lymph nodes.

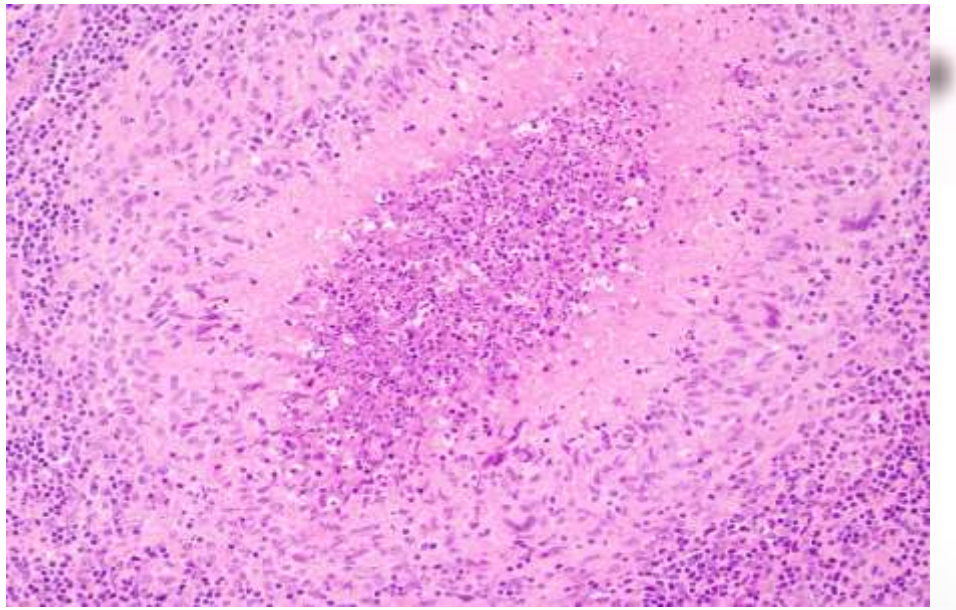

- Stellate –like central abscess surrounded by palisaded histiocytes

THANK YOU