Lymphoreticular system pathology

LEC.2

Dr. Raghad Hanoon

Lymphoid Neoplasms

- The numerous lymphoid neoplasms vary widely in their clinical presentation and behavior.
- These include: ***leukemias, lymphomas, and*** **Plasma cell tumors.**
- All lymphoid neoplasms have the potential to spread to lymph nodes and various tissues throughout the body, especially the liver, spleen, bone marrow and peripheral blood.
- In some cases, lymphomas spill over into the peripheral blood, creating a leukemia-like picture; Conversely, leukemias of lymphoid cells, originating in the bone marrow, can infiltrate lymph nodes and other tissues, creating the histologic picture of lymphoma
- Because of the overlap in clinical course so that the **diagnosis and prognosis depends on tumor cell type** rather than on where the tumor reside within the patient.

Lymphomas

- Lymphoma is the **malignant tumors of the lymphoid system** and specifically of lymphocytes and their precursor cells, whether of T, B, or NK phenotypes that accumulate in lymph nodes and other tissues.
- Like all neoplasms, they are monoclonal in origin (Lymphomas arise because of a series of mutations in a single lymphoid cell).
- The major subdivision of lymphomas is into **Hodgkin's lymphoma and non-Hodgkin's lymphoma** and this is based on the histological **presence of Reed-Sternberg (RS) cells in Hodgkin's lymphoma** which is the neoplastic cell surrounded by plenty of non-tumor cells.
- The biologic behavior and treatment of Hodgkin lymphoma differ from those of most NHLs, thus making the distinction between the two is of practical importance.

Hodgkin's lymphoma

- Type of malignant lymphoma characterized by the presence of a tumor giant cell, the **Reed-Sternberg (RS)cells**.
- Molecular studies have shown that it is a tumor **of B-cell origin** (The neoplastic RS-cells are derived from germinal center or post-germinal center B cells in the vast majority of cases).
- The neoplastic Reed-Sternberg cells typically make up **a minor fraction** (1- 5%) of the total tumor cell mass, making HL more difficult to study than typical NHLs.
- The **EBV genome** is present in the RS cells in up to 70% of cases of the mixed-cellularity type and a smaller fraction of other “classical” forms of Hodgkin lymphoma. Thus, EBV infection is likely to be a contributing step to the development of Hodgkin lymphoma, particularly the mixed-cellularity type.
- **The characteristic nonneoplastic, inflammatory cell infiltrate** is generated by a number of cytokines; Some of these are secreted by RS cells.

➢ Pathogenesis:

Mutation either by EBV or other causes transform the cells to RS that will secret cytokines to attract other inflammatory cells which in turn will produce factors that support the growth and survival of the tumor cells and further modify the reactive cell response.

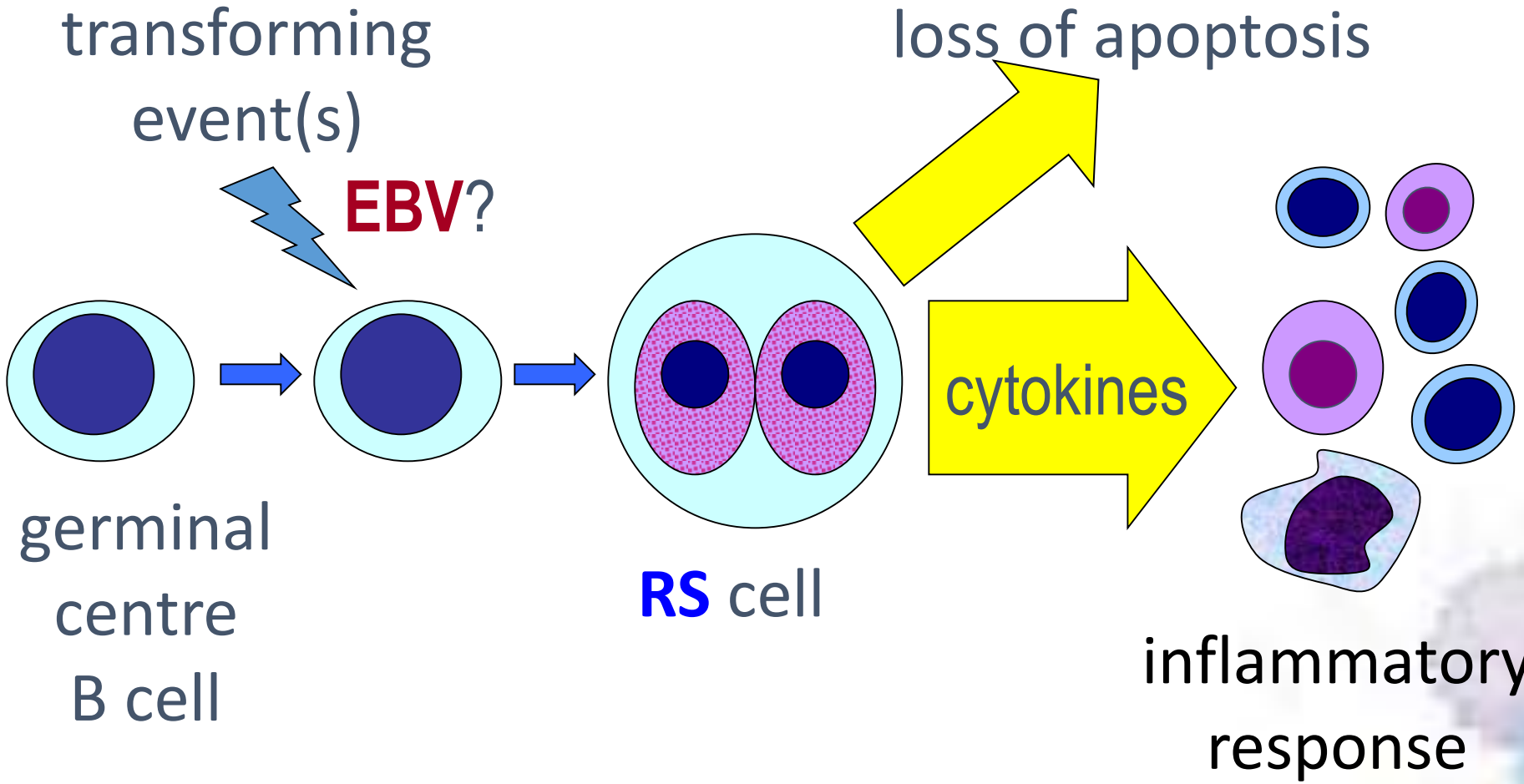

➢ Clinical Features:

- Can present at any age but is rare in children and has a peak incidence in young adults.
- There is an almost 2 : 1 male predominance.
- The usual clinical presentation is with painless asymmetrical lymphadenopathy–most commonly in the neck (Cervical 80%, mediastinal, axillary, para-aortic).
- Typically the disease is localized initially to **a single** peripheral lymph node region and its subsequent **progression is by contiguity** within the lymphatic system.
- Constitutional symptoms of fever (May first present as fever of unknown origin; Fever persists for days to weeks followed by afebrile intervals and then recurrence), weight loss & sweating are prominent in patients with widespread disease.



➢**The diagnosis** is made by histological examination of an excised lymph node.

- The histologic diagnosis of Hodgkin lymphoma rests on the definitive identification of Reed-Sternberg cells or their variants in the appropriate background of reactive cells.
- **Immunophenotyping** plays an important role in distinguishing Hodgkin lymphoma from reactive conditions and other forms of lymphoma.
- In all subtypes, **involvement of the spleen, liver, bone marrow, and other organs may appear** in the course and takes the form of irregular nodules composed of a mixture of RS cells and reactive cells, similar to what is observed in lymph nodes.

Morphology of Reed –Sternberg cells

- A very large cell (15 to 45 µm in diameter) with an enormous multilobate nucleus, prominent nucleoli, and abundant slightly eosinophilic cytoplasm.
- Particularly characteristic are **“classic” RS** cells with **two mirror image nuclei or nuclear lobes, each containing a large (inclusion-like) acidophilic nucleolus surrounded by a clear zone**, features that impart an owl-eye appearance.
- Typical RS cells and variants (EXCEPT Lymphohistiocytic variant) have a characteristic immunophenotype, they are **positive for CD15 and CD30** and negative for other B-cell markers (CD20), T-cell markers, and CD45.
- **Variants**: mononuclear (Hodgkin’s cell), mummified cell, lacunar cell, L/H cell (popcorn).

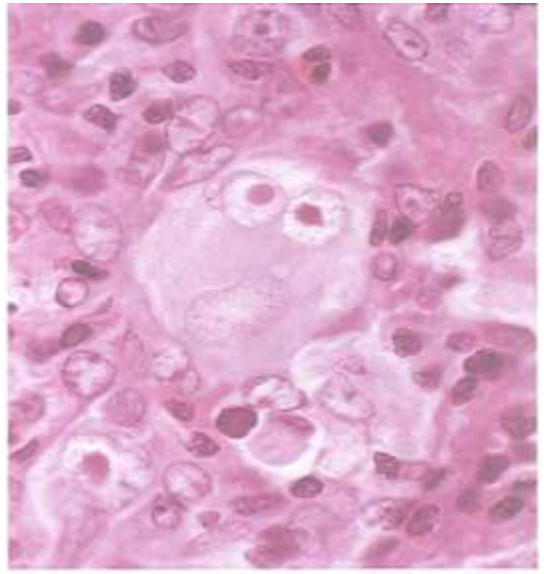



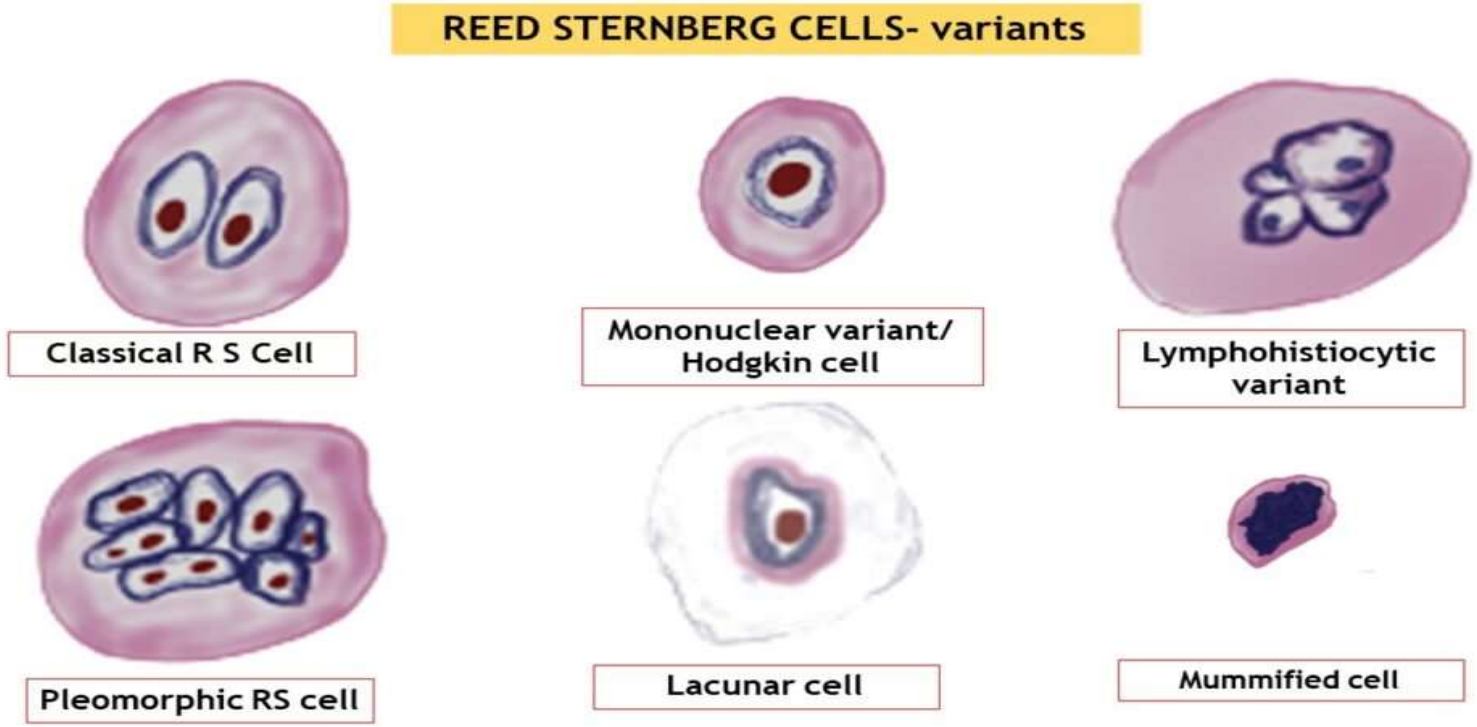

- **Mononuclear variants** contain a single nucleus with a large inclusion-like nucleolus.
- **Polypoid Lacunar cells (in the nodular sclerosis subtype)** have more delicate, folded, or multilobate nuclei and abundant pale cytoplasm that is often disrupted during the cutting of sections, leaving the nucleus sitting in an empty space (a lacuna).
- In classic forms of Hodgkin lymphoma, RS cells undergo a peculiar form of cell death in which the cells shrink and become pyknotic, a process described as **"mummification."**
- **Lymphohistiocytic variants (L&H cells) or popcorn cell:** with nuclei, inconspicuous nucleoli, and moderately abundant cytoplasm are characteristic of the **nodular lymphocyte predominant subtype.**

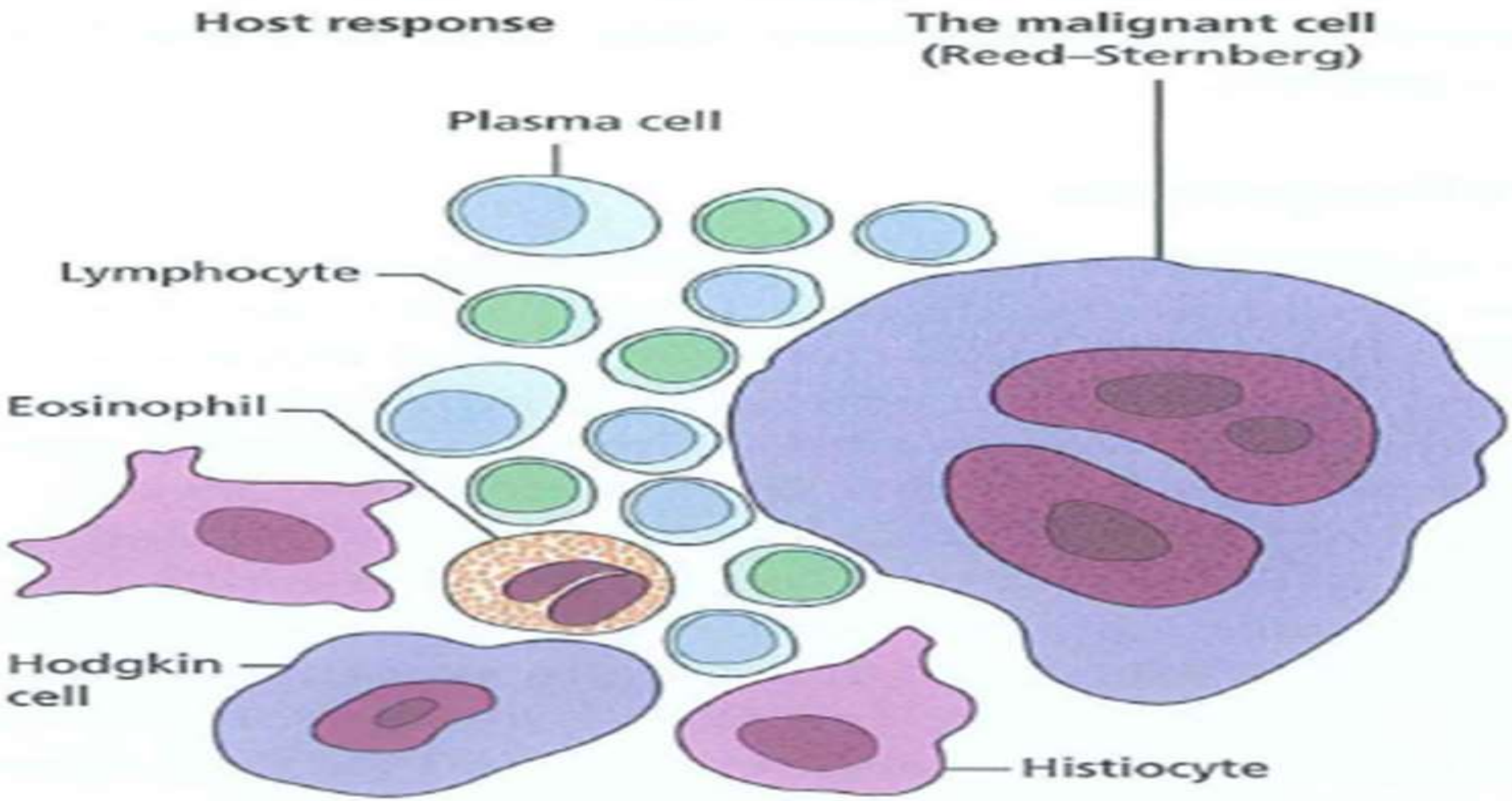

Diagrammatic representation of the different cells seen histologically in Hodgkin's lymphoma.

Classification of Hodgkin lymphoma

A. Classical Hodgkin lymphoma; which are subclassified to:

(1) Nodular sclerosis.

(2) Mixed cellularity.

(3) Lymphocyte rich.

(4) Lymphocyte depletion.

B. Nodular lymphocyte - predominant Hodgkin lymphoma.

- In the first four subtypes the RS cells share certain morphologic and immunophenotypic features (**positive for CD15 and CD30** and negative for other B-cell markers, T-cell markers, and CD45), so lumped together as **classical Hodgkin lymphoma**; While **Nodular lymphocyte- predominant type** is set apart because the RS cells **positive for B cell markers (CD20)** and negative for CD15 and CD30.

Nodular sclerosis classical Hodgkin lymphoma

- The **most common** form (65% to 70% of cases)**.**
- It is equally frequent in **men** and women**.**
- Involve the lower cervical, supraclavicular, and mediastinal lymph nodes.
- Most of the patients are **adolescents or young adults.**
- This subtype is **uncommonly** associated with **EBV.**
- The overall prognosis is **excellent.**

➢**Morphology:** characterized by the following:

1. A variant of the RS cell, the **lacunar cell**; This cell is large and has a single multilobated nucleus with multiple small nucleoli and an abundant, pale-staining cytoplasm. In formalin-fixed tissue, the cytoplasm often retracts, giving rise to the appearance of cells lying in empty spaces or **lacunae**.

2. There are varying proportions of lymphocytes, eosinophils, histiocytes.

3. There are fibrous bands **(Collagen bands)** that divide the lymphoid tissue into circumscribed nodules hence the name as nodular sclerosis.

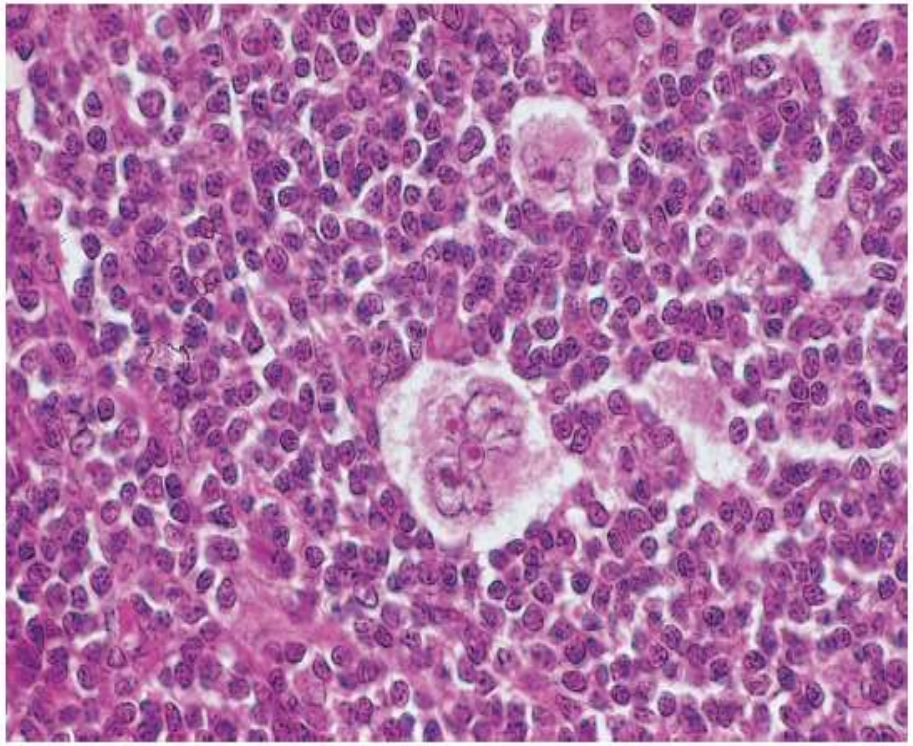

Fig. 12.21 Hodgkin lymphoma, nodular sclerosis type—lymph node. A distinctive "lacunar cell" with a multilobed nucleus containing many small nucleoli is seen lying within a clear space created by retraction of its cytoplasm. It is surrounded by lymphocytes. *(Courtesy of Dr. Robert W. McKenna, Department of Pathology, University of Texas Southwestern Medical School, Dallas, Texas.)*

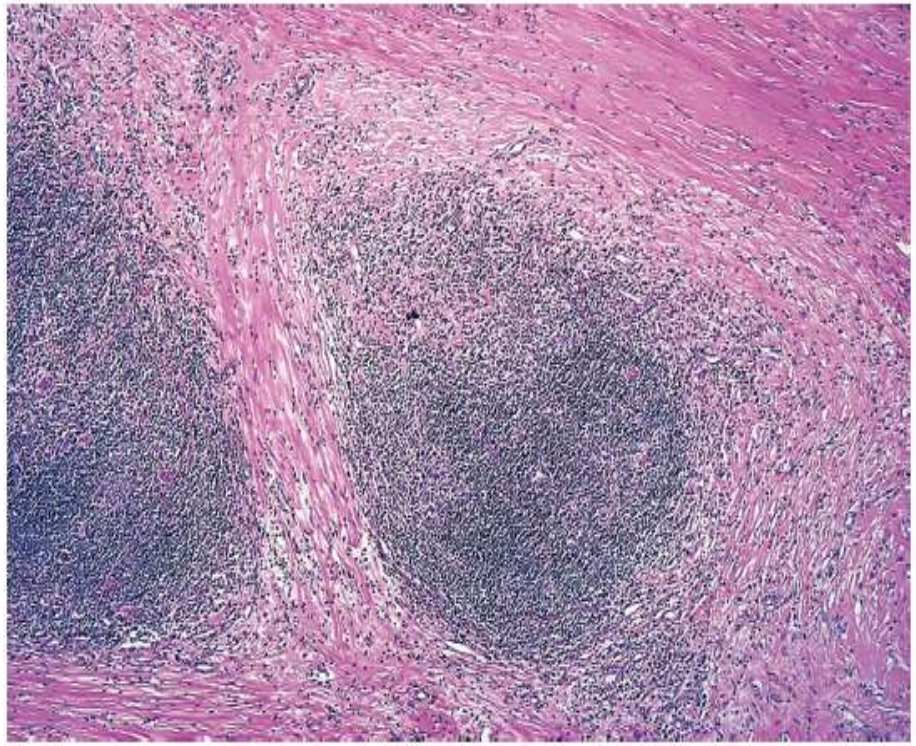

Fig. 12.22 Hodgkin lymphoma, nodular sclerosis type—lymph node. A low-power view shows well-defined bands of pink, acellular collagen that have subdivided the tumor cells into nodules. *(Courtesy of Dr. Robert W. McKenna, Department of Pathology, University of Texas Southwestern Medical School, Dallas, Texas.)*

Mixed- cellularity classical Hodgkin lymphoma

- Is the most common form of Hodgkin lymphoma **in patients older than 50** years of age .
- Constitutes about 20% to 25% of cases.
- **Male** predominance.
- The Reed-Sternberg cells are infected with **EBV in about 70% of cases.**
- **Classic RS cells are plentiful** within cellular infiltrate of small lymphocytes, eosinophils, plasma cells, and macrophages.
- More patients with mixed cellularity have **disseminated disease and systemic manifestations.**
- Overall prognosis is **very good.**

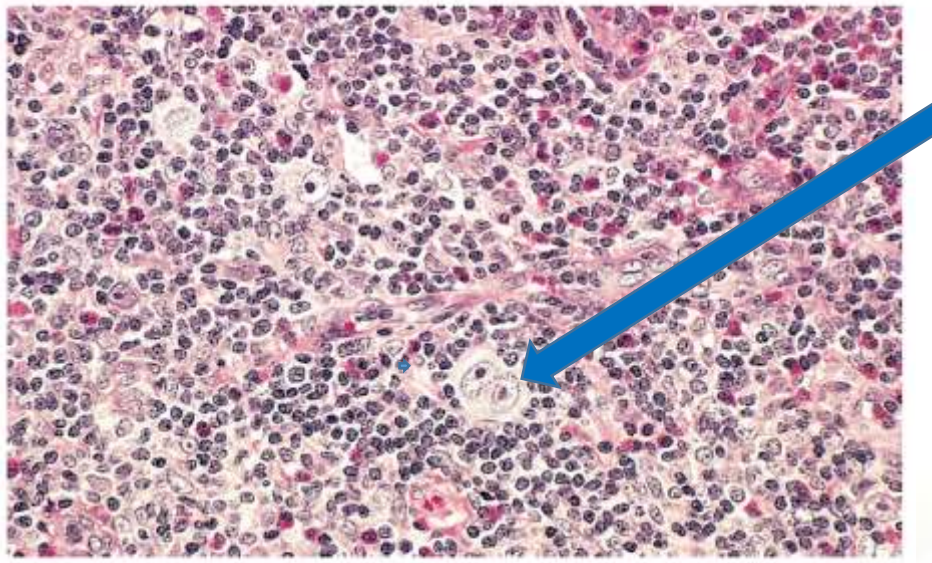

Fig. 12.23 Hodgkin lymphoma, mixed-cellularity type—lymph node. A diagnostic, binucleate Reed-Sternberg cell is surrounded by eosinophils, lymphocytes, and histiocytes. *(Courtesy of Dr. Robert W. McKenna, Department of Pathology, University of Texas Southwestern Medical School, Dallas, Texas.)*

Lymphocyte-Rich classical Hodgkin lymphoma

- This is an **uncommon** form of classic Hodgkin lymphoma
- In which reactive lymphocytes make up the vast majority of the cellular infiltrate.
- This entity is distinguished from the lymphocyte predominance type by the presence of frequent mononuclear variants and diagnostic Reed-Sternberg cells.
- It is associated with **EBV in about 40%** of cases
- Has a **very good to excellent** prognosis.

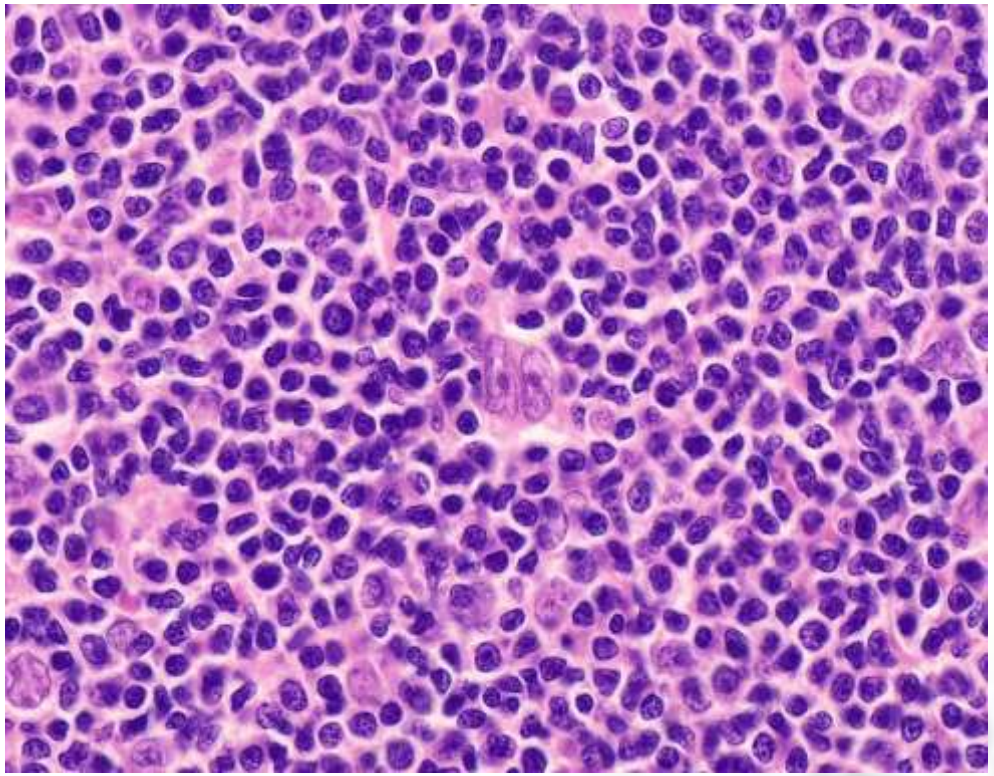

➢ The histologic hallmark of this subtype is small number of **Hodgkin and Reed-Sternberg cells** scattered in a sea of small lymphocytes. A binucleated Reed-Sternberg cell is seen in the center of this image.

Lymphocyte Depleted classical Hodgkin lymphoma

- This is the **least common** form of Hodgkin lymphoma, amounting to less than 5% of cases.
- Characterized by a paucity of lymphocytes and a relative abundance of Reed-Sternberg cells or their pleomorphic variants.
- The Reed-Sternberg cells are infected with **EBV in over 90% of cases.**
- Lymphocyte depletion Hodgkin lymphoma occurs predominantly in **older adults, in HIV-positive individuals of any age,** and in individuals living in lower-income countries.
- Advanced stage and systemic symptoms are frequent, and the overall **outcome is less favorable** than in the other subtypes.

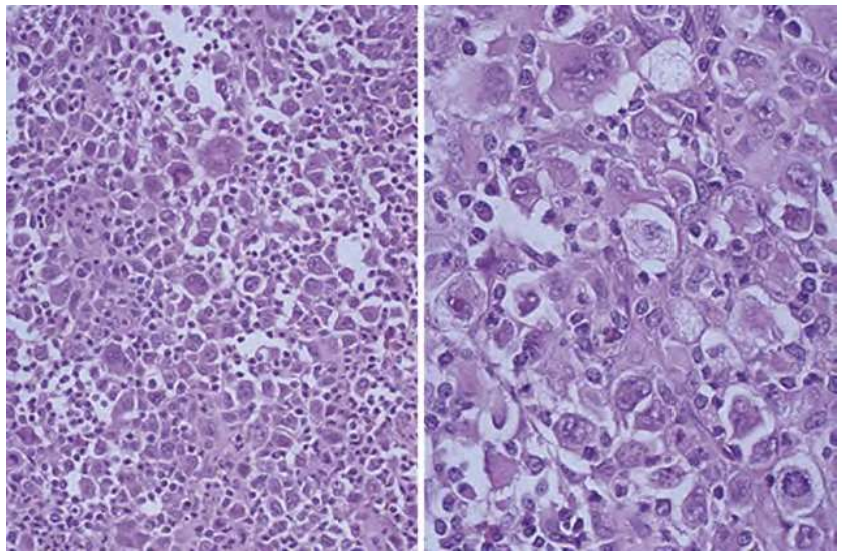

➢ Many Reed-Sternberg variants are present here. Few lymphocytes or other reactive cells are found.

Nodular Lymphocyte-Predominant Hodgkin Lymphoma

- This subgroup, comprising about **5%** of Hodgkin lymphoma.
- It is characterized by the presence **of lymphohistiocytic (L&H) variant RS cells** that have a delicate multilobed, puffy nucleus resembling popped corn (popcorn cell). L&H variants usually are found within large nodules containing mainly small B cells admixed with variable numbers of macrophages. Other reactive cells, such as eosinophils, are scanty or absent.
- Unlike the RS variants in "classical" Hodgkin lymphoma, **L&H variants positive for B cell markers (CD20) and negative for CD15 and CD30.**
- **EBV is rarely** associated with this subtype**.**
- Most patients present with isolated cervical or axillary lymphadenopathy.
- Is more likely to recur than the classic subtypes, but the prognosis is excellent.

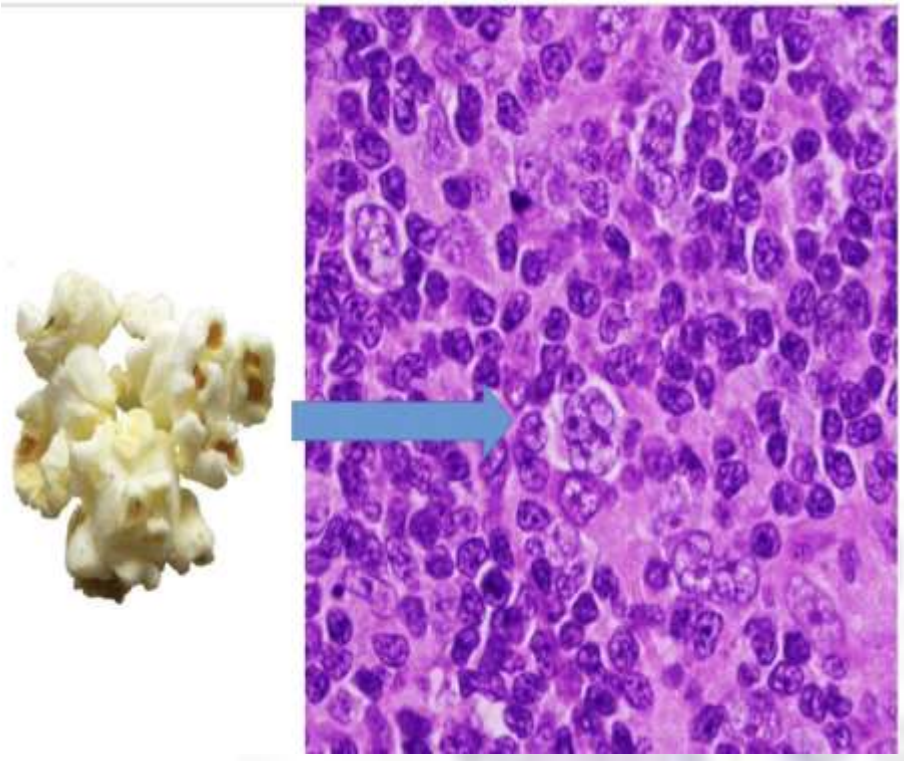

Non-Hodgkin's lymphomas

- These are a large group of clonal lymphoid tumors, about **85 % are of B cell origin and 15% of T or NK** (natural killer) cell origin.
- They are characterized by an irregular pattern of spread and a significant proportion of patients develop extra nodal disease.
- The Non-Hodgkin's lymphomas are a diverse group of diseases and vary from highly proliferative and rapidly fatal diseases to some of the most indolent and well-tolerated malignancies.

➢ **Cell of origin for NHLs:**

- B-cell lymphomas tend to mimic normal B cells at different stages of development.
- T-cell lymphomas resemble precursor T cells or peripheral mature T cells.

➢Clinical features of Non-Hodgkin's lymphoma

1- Superficial lymphadenopathy: asymmetric painless enlargement of lymph nodes in one or more peripheral lymph node regions

2-Constitutional symptoms: Fever, night sweats and weight loss occur less frequently than in Hodgkin’s disease.

3- Oropharyngeal involvement

4-Organs involvement: the liver and spleen are often enlarged. The GIT is the most commonly involved extranodal site after the bone marrow. Also Skin, brain, testis or thyroid can be involved.

5- Other features: due to anemia, neutropenia or thrombocytopenia.

Clinical Differences Between Hodgkin and Non-Hodgkin Lymphomas

Hodgkin Lymphoma Presence of RS cells	Non-Hodgkin Lymphoma Absence of RS cells
1. More often localized to a single axial group of nodes (cervical, mediastinal, para-aortic	1. More frequent involvement of multiple peripheral nodes
2. Orderly spread by contiguity (spreads in an orderly stepwise fashion)	2. Noncontiguous spread (NHL disseminate widely and somewhat unpredictably early in their course)
3. Mesenteric nodes and Waldeyer ring rarely involved	3. Mesenteric nodes and Waldeyer ring commonly involved
4. Extranodal involvement uncommon	4. Extranodal involvement common

➢ Risk factors and etiology in the development of NHLs

- The etiology of the majority of cases of non-Hodgkin lymphomas (NHL) is unknown.

1. Infectious agents are an important cause in particular subtypes, see next table.
2. Immunodeficiency (primary or secondary).
3. Autoimmune disorders (Sjogren, rheumatoid arthritis, Hashimoto thyroiditis).
4. Radiation.
5. Chemotherapy.

❖ Association of some infectious agent with certain types of lymphoma

Infection	Organism	Tumour
Virus	HTLV–1	Adult T-cell leukaemia/lymphoma
	Epstein–Barr virus	Burkitt and Hodgkin lymphomas; post-transplant lymphoproliferative disease (PTLD)
	HHV–8	Primary effusion lymphoma
	HIV–1	High-grade B-cell lymphoma, primary CNS lymphoma, Hodgkin lymphoma
	Hepatitis C	Marginal zone lymphoma
Bacteria	Helicobacter pylori	Gastric lymphoma (mucosa-associated lymphoid tissue MALT)
Protozoa	Malaria	Burkitt lymphoma

Investigations:

1. **Histology**

- **Lymph node biopsy** or other involved tissue is the definitive investigation.

Morphological examination is assisted by Immunophenotypic and genetic analysis.

- **A fine needle aspiration**

(aspirating cells from enlarged lymph node using syringe) may be performed to exclude another cause of lymphadenopathy (e.g. Tuberculosis, carcinoma) but less useful in establishing a diagnosis of lymphoma.

2. **Hematological investigations:** -

- In advanced disease with marrow involvement, there may be anemia, neutropenia or thrombocytopenia.
- Blood film: of paramount importance in the leukemias and if lymphoma cells spill out to the circulation.
- Trephine biopsy of marrow to see if there is bone marrow involvement.

3. **Biochemical tests:** Increase LDH and uric acid.
4. **Immunological tests:** immunoglobulin electrophoresis may reveal a paraprotein (immunoglobin secreted by neoplastic plasma cells).

➢ Classification of Non Hodgkin lymphoma:

- The lymphomas are classified within a group of mature or immature B- cell and T-cell neoplasm.
- For many years, clinicians have subdivided lymphomas into **low and high-grade disease.**
- In general terms, the **low-grade disorders** are relatively indolent, respond well to chemotherapy but are very difficult to cure whereas **high-grade lymphomas** are aggressive and need urgent treatment but are often curable.
- Low grade lymphoma: e. g. Follicular lymphoma, Mantle cell lymphoma.
- High grade Lymphoma: e. g. Diffuse Large B-Cell Lymphoma, Burkitt's lymphoma.

THANK YOU