Lymphoreticular system pathology

LEC.3

Dr. Raghad Hanoon

Specific subtypes of Non-Hodgkin's lymphoma

❖Follicular lymphoma

- It is the **most common** form of indolent NHL (40%).
- **Pathogenesis;** it is associated with the t(14,18) translocation in 90% of cases that results in overexpression of BCL2 (antiapoptotic and promotes the survival of follicular lymphoma cells).
- Occurs mainly in adults **older than 50** years of age.
- Affects males and females equally.
- It usually manifests as painless, generalized lymphadenopathy.
- The bone marrow is involved at diagnosis in approximately 80% of cases.
- Although the natural history is prolonged (overall median survival, approximately 10 years), follicular lymphoma is **not curable**, an unfortunate feature shared with most other relatively indolent lymphoid malignancies.
- In about 30% to 40% of patients, follicular lymphoma **progresses to diffuse large B- cell lymphoma.**

➢ MORPHOLOGY:

- Lymph nodes **effaced by nodular proliferation** (follicular growth pattern).
- Two types of cell are present in varying proportions:

(1) Centrocytes: small cells with irregular or cleaved nuclear contours and scant cytoplasm, and

(2) Centroblasts: larger cells > 3 times the size of lymphocytes with open nuclear chromatin, several nucleoli, and modest amounts of cytoplasm; In most follicular lymphomas, **centrocytes are in the majority.**

- **NOTE:** mitoses are infrequent, and single necrotic cells (cells undergoing apoptosis) are not seen. These features help to distinguish follicular lymphoma from follicular hyperplasia, in which mitoses and apoptosis are prominent



(A)

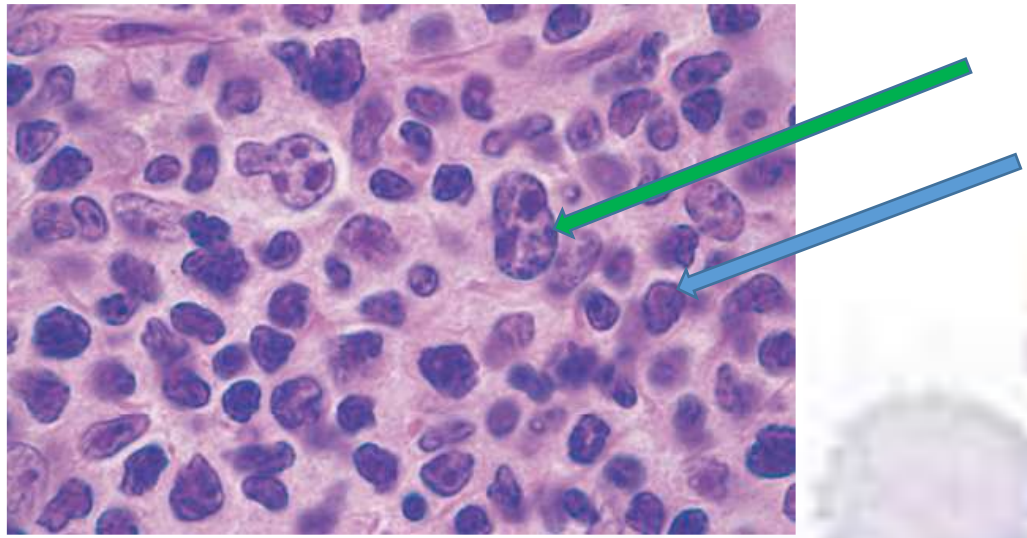

(B)

Follicular lymphoma (lymph node). (A) Nodular aggregates of lymphoma cells are present throughout lymph node. **(B)** At high magnification shows centrocytes and centroblasts.

❖ Mantle cell lymphoma

- It constitutes 6% of all NHLs.
- Occurs mainly in **men older than 50 years** of age and shows a male predominance.
- As the name implies, the **tumor cells closely resemble the normal mantle zone B cells** that surround germinal centers.
- **Pathogenesis:** Almost all tumors have an (11;14) translocation that results in over-expression of cyclin $D_{1.}$
- Most patients have generalized lymphadenopathy, and 20% to 40% have peripheral blood involvement.
- Frequent sites of extranodal involvement include the bone marrow, spleen, liver, and gut. Occasionally, mucosal involvement of the small bowel or colon produces polyp-like lesions (lymphomatoid polyposis).
- These tumors are **moderately aggressive and incurable.**

➢ MORPHOLOGY:

- Nodal tumor cells may surround reactive germinal centers to produce a **nodular appearance** at low power or diffusely efface the node.
- Typically, the proliferation consists of a homogeneous population of small lymphocytes with irregular nuclear outlines , condensed chromatin, and scant cytoplasm.

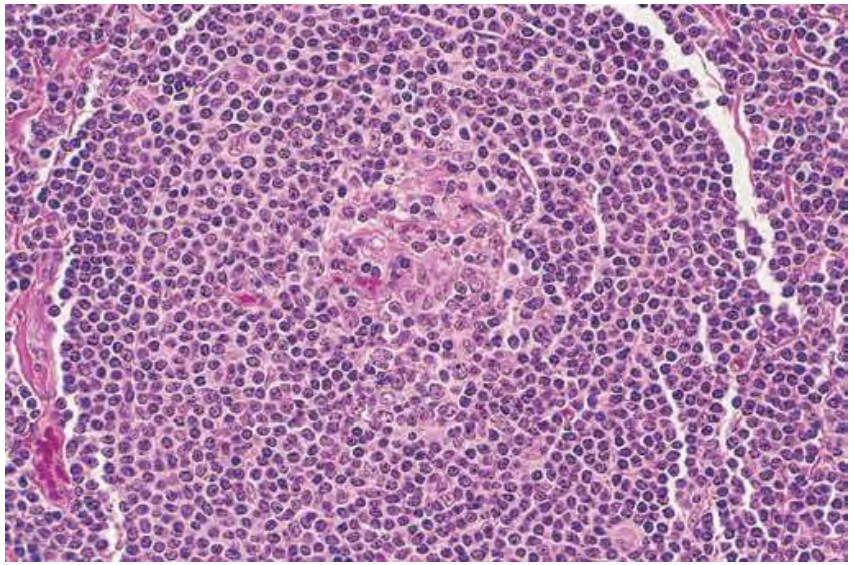

(A)

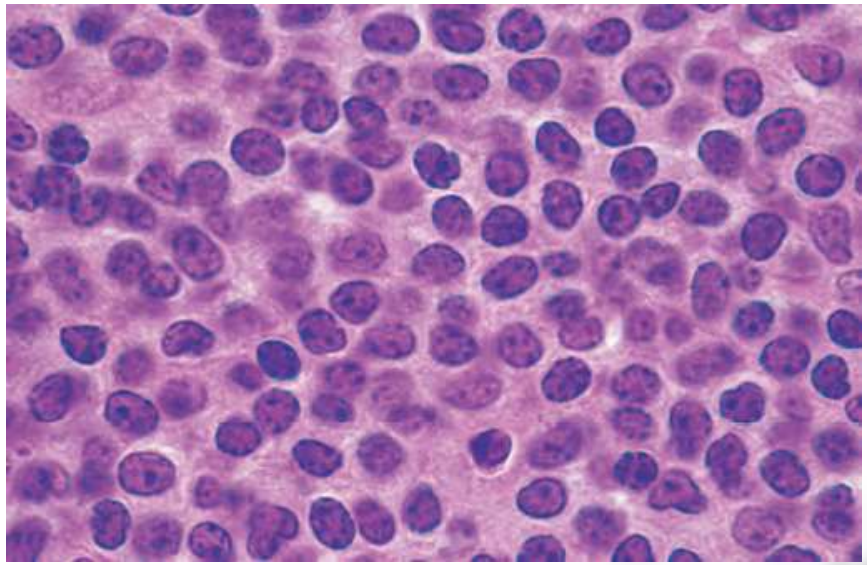

(B)

Mantle cell lymphoma. (A) At low power, neoplastic lymphoid cells surround a small, atrophic germinal center, producing a mantle zone pattern of growth. **(B)** High-power view shows a homogeneous population of small lymphoid cells with irregular nuclear outlines, condensed chromatin, and scant cytoplasm

❖ Marginal zone lymphomas

- It is a heterogeneous group of B-cell tumors that arise within **lymph nodes, spleen, or extranodal tissues.**
- The extranodal tumors were initially recognized at mucosal sites and are often referred to as mucosa-associated lymphoid tumors (or MALTomas).
- **Extrannodal MZL share characteristics features:**

1- Arise within tissues involved by **chronic inflammatory disorders of autoimmune or infectious etiology;** examples include the salivary gland in Sjögren disease, the thyroid gland in Hashimoto thyroiditis, and the stomach in Helicobacter gastritis.

2- They **remain localized for prolonged periods,** spreading systemically only late in their course.

3- They **may regress** if the inciting agent (e.g., H. pylori) is eradicated.

- These characteristics suggest that extranodal MZL arising in chronically inflamed tissues **begin as polyclonal reactive lymphoid hyperplasia and then transform into monoclonal lymphoma.**
- At this stage, **withdrawal of the responsible antigen causes tumor involution;** Like in gastric MALToma, in which antibiotic therapy directed against H. pylori often leads to tumor regression.

- **With time** tumors may acquire additional mutations that render their growth and survival antigen-independent, **such as (11;18), (14;18), or (1;14) chromosomal translocations**, which are relatively specific for extranodal marginal zone lymphomas.
- With further clonal evolution, spread to distant sites and transformation to DLBCL may occur.

➢ **MORPHOLOGY:**

- The clonal B cells infiltrate the epithelium of involved tissues, often collecting in small aggregates that are called **lymphoepithelial lesions.**

- The extranodal lymphoma seen here involving gastric mucosa (MALT) lesion and is composed of small round to irregular lymphocytes *(right panel)* resembling those seen in the marginal zone of lymphoid follicles. The cells tend to invade epithelium as small nests *(left panel).*

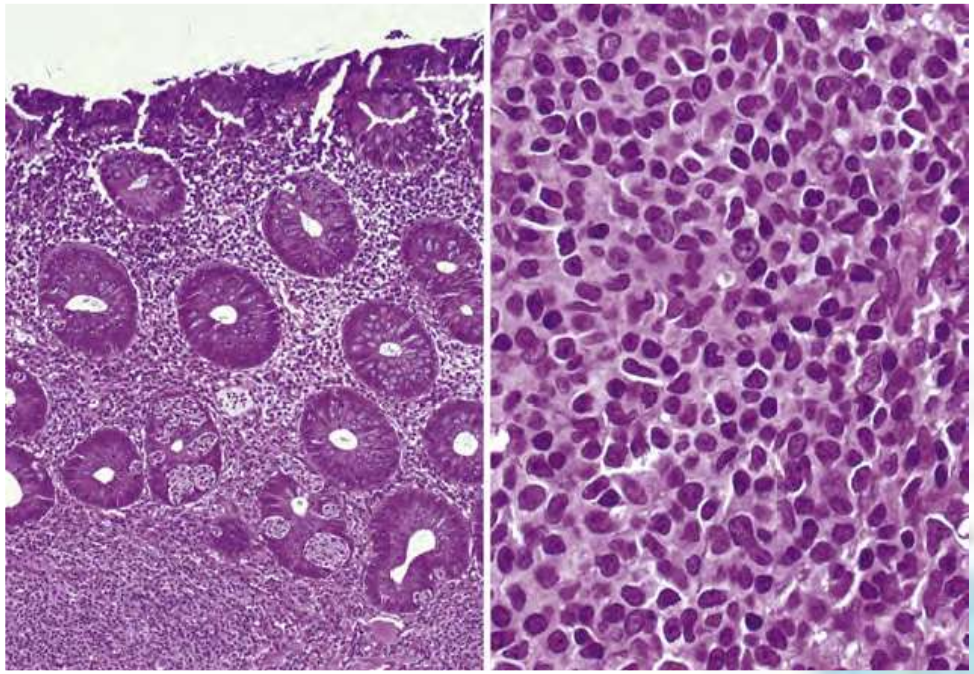

❖ Diffuse Large B-Cell Lymphoma

- It is the **most common type** of NHL lymphoma.
- **Heterogeneous group of mature B cell tumors** that share a similar large-cell morphology and aggressive clinical behavior.
- **Pathogenesis;** Highly associated with rearrangements or mutations of BCL6 gene or BCL2.
- Patients present with a rapidly enlarging mass at a nodal or extranodal site.
- It can arise virtually anywhere in the body; Waldeyer ring, the oropharyngeal lymphoid tissue that includes the tonsils and adenoids, is involved commonly.
- Primary or secondary involvement of the liver and spleen may take the form of large destructive masses.
- Without treatment, diffuse large cell B cell lymphomas are **aggressive and rapidly fatal.**

➢ MORPHOLOGY:

- Diffuse pattern of growth of large neoplastic B cells (at least three to four times the size of resting lymphocytes).
- **Tumor cells** have a round or oval nucleus that appears vesicular due to margination of chromatin to the nuclear membrane, but large multilobated or irregular nuclei are prominent in some cases. Nucleoli may be two to three in number and located adjacent to the nuclear membrane or single and centrally placed. The cytoplasm is usually moderately abundant and may be pale or basophilic.

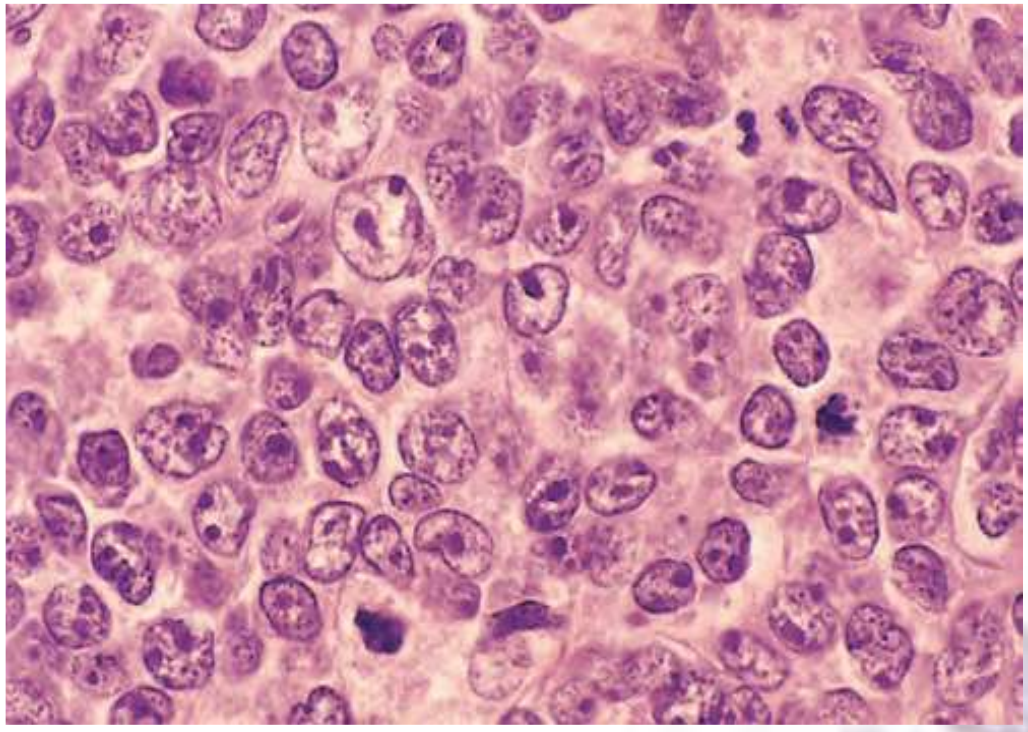

Diffuse large B-cell lymphoma. Tumor cells have large nuclei, open chromatin and prominent nucleoli.

❖ Burkitt lymphoma

➢ Burkitt lymphoma occurs in **three different settings;**

1. African (endemic).
2. Sporadic (nonendemic).
3. A subset of aggressive lymphomas occurring in patients infected with HIV.

- Although they are histologically identical, but they have distinct clinical, genotypic, and virologic features.

➢ **Pathogenesis;** It is associated with translocations of the MYC gene on chromosome 8, as result of translocation t (8;14) that result in overexpression of the MYC transcription factor.

- All endemic Burkitt lymphomas are latently infected with EBV, which also is present in about 25% of HIV-associated tumors and 15% to 20% of sporadic cases. Molecular analysis shows that the viral DNA configuration is identical in all tumor cells, indicating that infection precedes cellular transformation.
- Burkitt lymphoma is among the fastest-growing human tumors.

➢Clinical Features:

- Both the endemic and sporadic forms affect mainly **children and young adults.**
- Burkitt lymphoma accounts for approximately 30% of childhood NHLs in the United States.
- The disease **usually arises at extranodal sites.**
- **Endemic Burkitt lymphoma** often manifest as **maxillary or mandibular masses,** and shows an unusual predilection for involvement of abdominal viscera, in contrast **sporadic Burkitt lymphoma** often appears as **a mass involving the bowel (ileocecum), retroperitoneum, and ovaries.**
- Involvement of the bone marrow and peripheral blood is uncommon, especially in endemic cases.
- Leukemic presentations sometimes occur and must be distinguished from ALL, which is treated with different drug regimens.
- Burkitt lymphoma is highly aggressive; however, with very intensive chemotherapy regimens, a majority of patients can be cured.

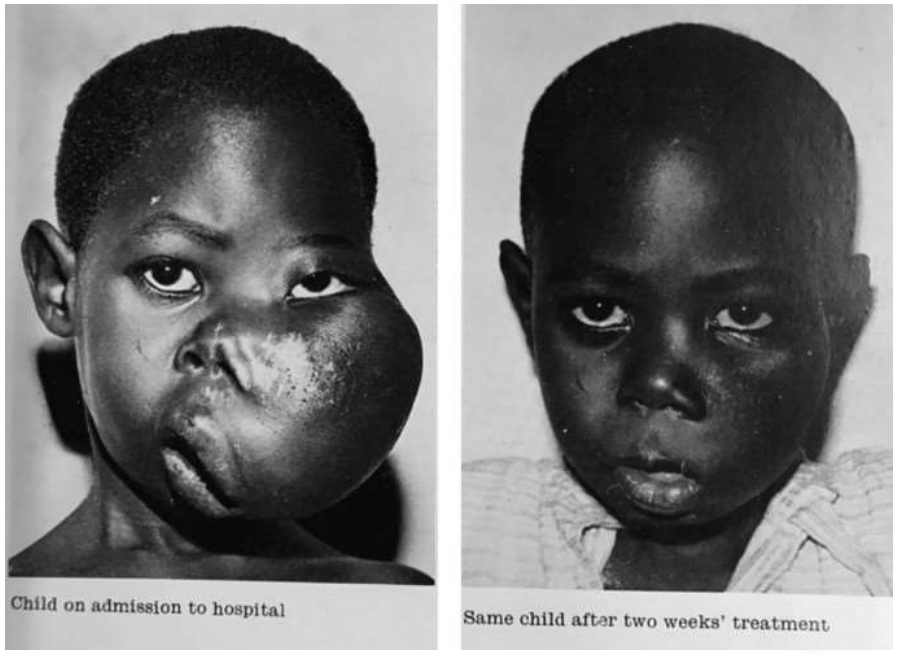

Child on admission to hospital

Same child after two weeks' treatment

➢MORPHOLOGY:

- The tumor cells are intermediate in size and typically have round or oval nuclei and two to five distinct nucleoli.
- There is a moderate amount of basophilic or amphophilic cytoplasm that often contains small, lipid-filled vacuoles (a feature appreciated on smears).
- Very high rates of proliferation and apoptosis are characteristic, the latter accounting for the presence of numerous tissue macrophages containing ingested nuclear debris.
- These benign macrophages often are surrounded by a clear space, creating a **“starry sky” pattern.**

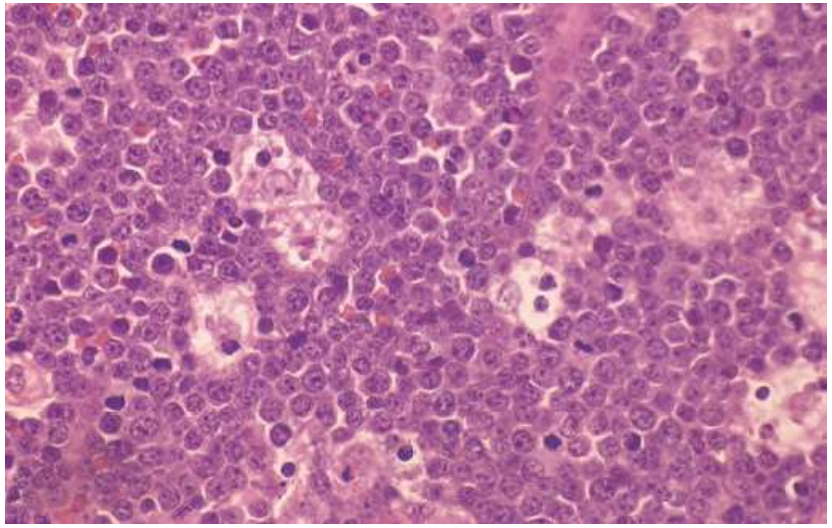

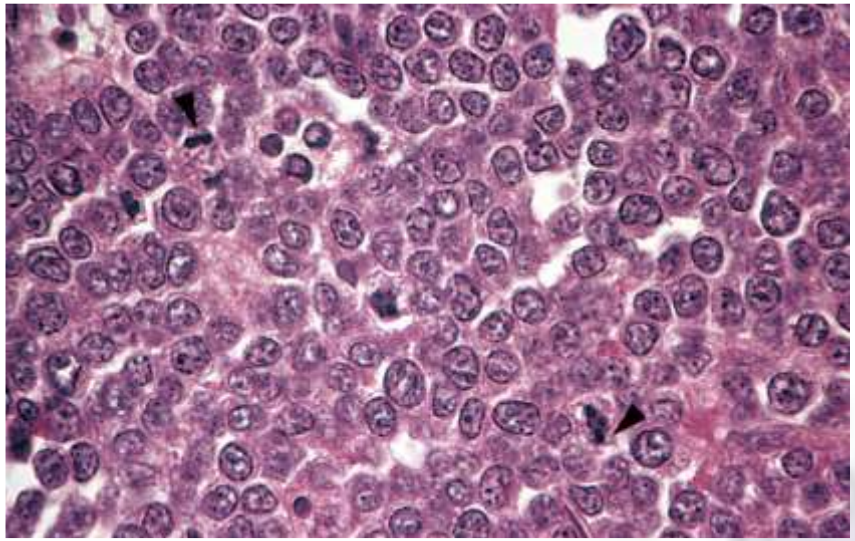

Burkitt lymphoma; The tumor cells and their nuclei are fairly uniform, giving a monotonous appearance. Note the high level of mitotic activity *(arrowheads)* and prominent nucleoli. The “starry sky” pattern produced by interspersed, lightly staining, normal macrophages is better appreciated at a lower magnification.

Clinical Staging of Hodgkin and Non-Hodgkin Lymphomas (Ann Arbor staging)

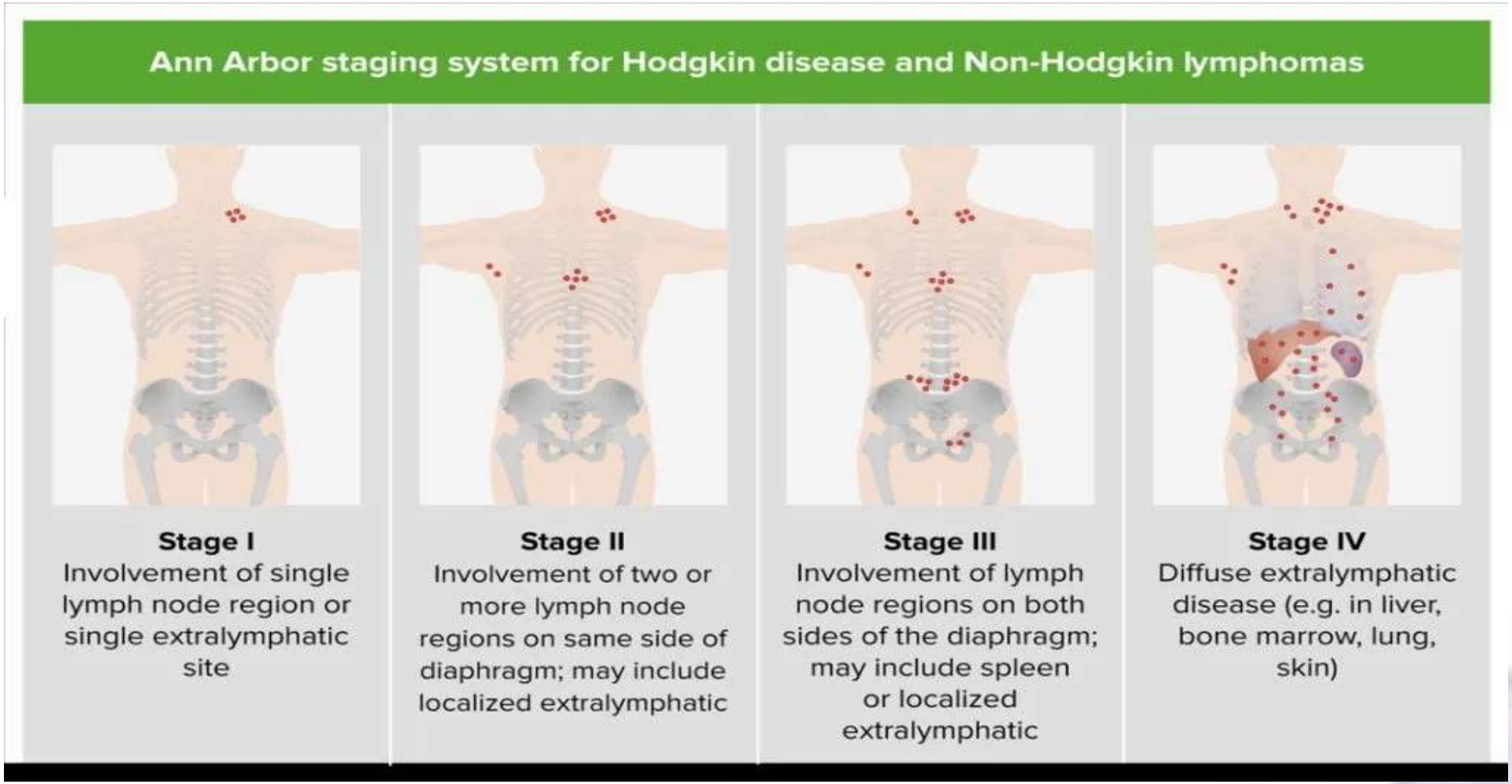

- *All stages are further categorized in to A and B. (A); absence of B symptoms . (B) presence of B symptoms.
- NOTE: B symptoms are the same constitutional symptoms (fever, night sweats and weight loss).

Peripheral T-Cell and Natural Killer Cell Neoplasms

- Are a heterogeneous group united by phenotypes that resemble normal mature T or NK cells.
- Peripheral T-cell tumors account for 5% to 10% of NHL in the United States and Europe, while NK cell tumors are rare. Both types are more common in Asia.
- In general, these are aggressive tumors that respond poorly to therapy and have a poorer prognosis than B-cell lymphomas.
- **Most common subtypes;**

- Mycosis fungoides/Sézary syndrome
- Peripheral T cell lymphoma, unspecified
- Anaplastic large cell lymphoma.
- Enteropathy-type T cell lymphoma
- Extranodal NK/T cell lymphoma; Nasal type: strongly associated with EBV.

lymph nodes metastatic tumors

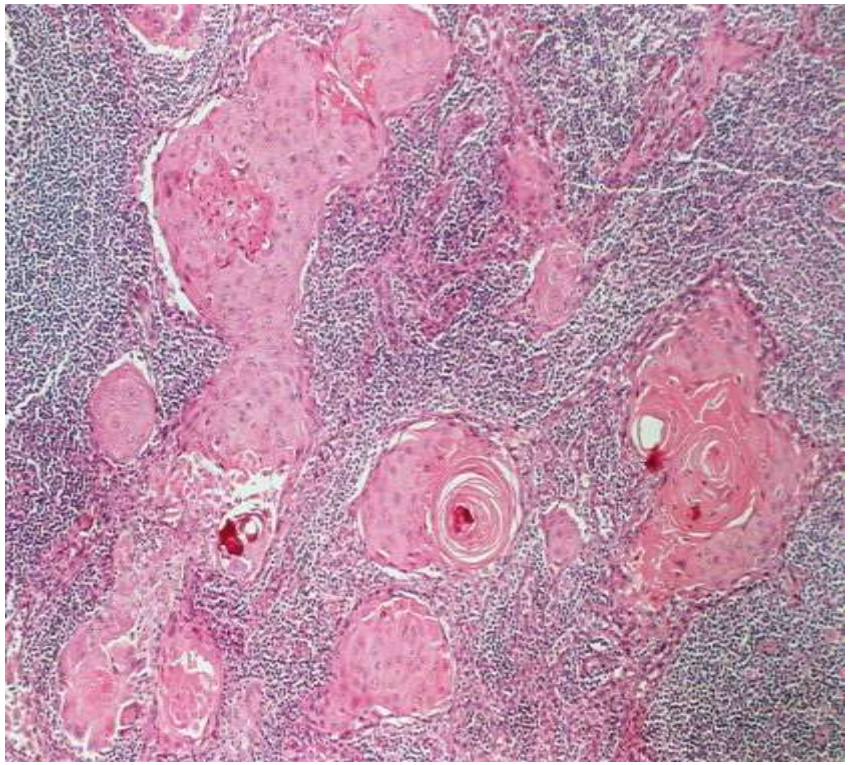

Metastatic squamous cell carcinoma

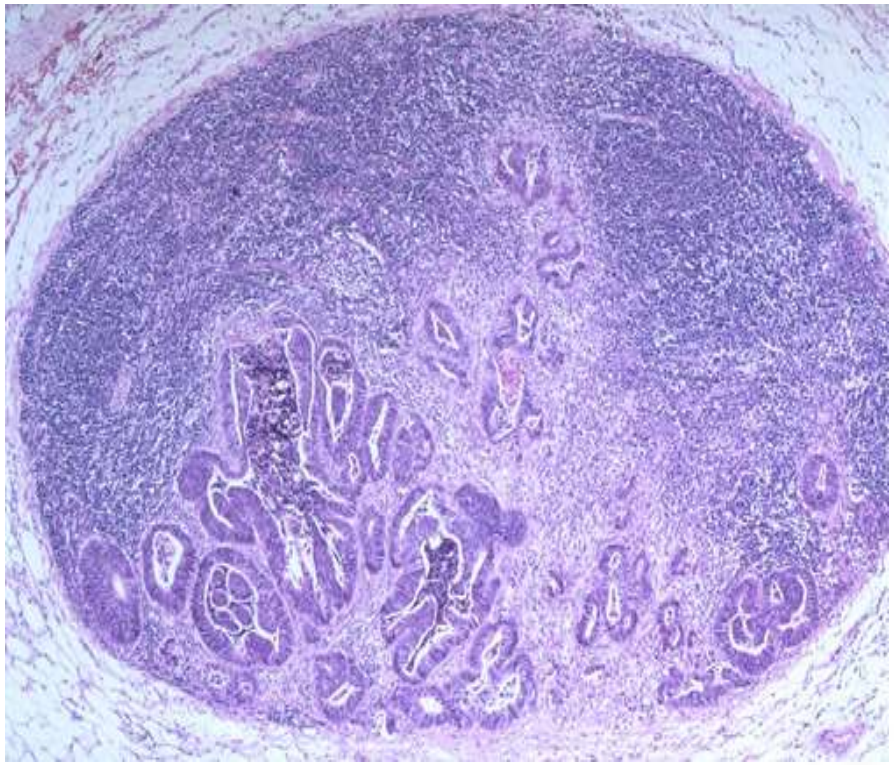

Metastatic adenocarcinoma

Disorders of the Spleen

- The spleen is frequently involved in a wide variety of systemic diseases. In all instances the spleen responds by enlarging (splenomegaly).
- **Causes of splenomegaly:**

- **Infections:**

Parasite: Malaria, hydatid cyst, bilharziasis, kalazar
Viral: Infectious mononucleosis
Bacterial: typhoid, TB, abscess
Septic spleen (feels soft, unlike most of the other big spleens).

- **Congestion related to Portal hypertension:**

Cirrhosis
Right-sided heart failure
Splenic vein thrombosis

- **Neoplastic:**

Lymphoma, Hemangioma, Secondary neoplasm.

- **Blood diseases:**

Anemia, polycythemia, Chronic myeloid leukemia(CML)
Hairy cell leukemia, Splenic over-destruction of blood cells, Hereditary spherocytosis, Hemoglobinopathies
Thalassemia, Immune hemolytic anemia
Immune thrombocytopenic purpura

- **Immunologic-Inflammatory Conditions:**

SLE , Rheumatoid arthritis

- **metabolic**

Storage diseases (huge spleen); Gaucher's , Hunter's diseases
Amyloidosis

- **Idiopathic:** Sarcoidosis.

➢Clinical presentation of splenomegaly:

- Pressure on stomach, Dragging sensation and hypersplenism

➢**Hypersplenism:** is a clinical syndrome that can be seen in any form of splenomegaly characterized by the **triad of:**

1. Splenomegaly
2. Anemia, leukopenia, thrombocytopenia, or any combination of these, leading to compensatory hyperplasia of the marrow precursors of the deficient cell type.
3. Correction of the blood cytopenia (s) by splenectomy.

- The likely cause of the cytopenias in this syndrome is increased sequestration of formed elements and the consequent enhanced phagocytosis by the splenic macrophages.

Disorders of the thymus

- As is well known, the thymus has a crucial role in T cell differentiation.
- Therefore, the thymus can be involved by lymphomas, particularly those of **T cell** lineage.
- The focus here is on the two most frequent disorders of the thymus: thymic hyperplasia and thymoma.

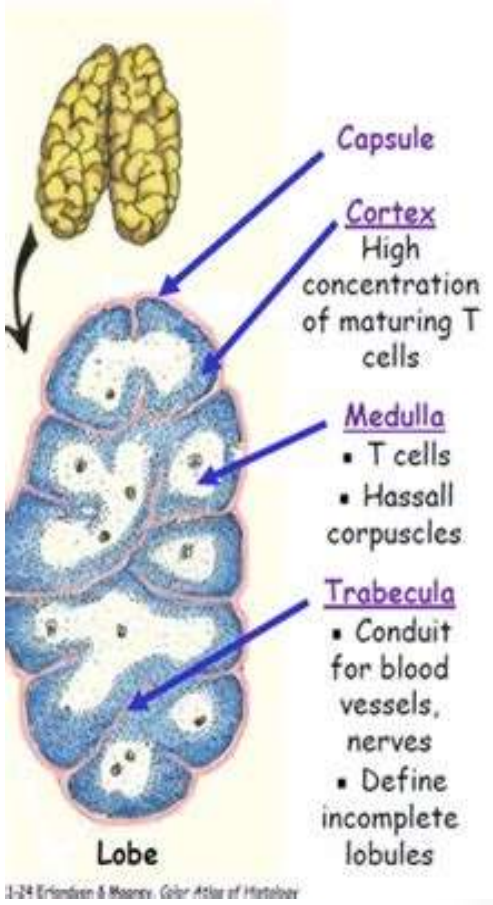

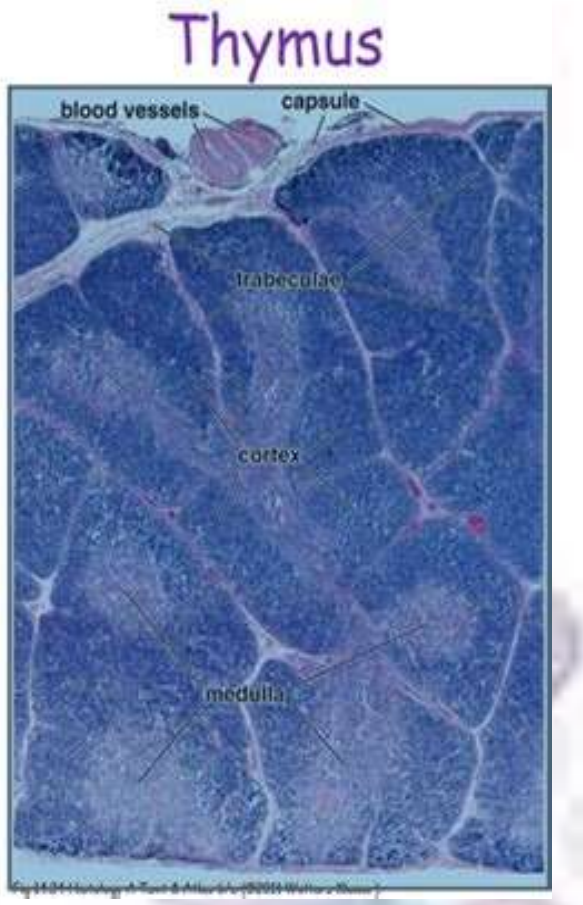

Thymic Hyperplasia

- Thymic enlargement often is associated with the presence of lymphoid follicles or germinal centers within the medulla.
- These germinal centers contain reactive B cells, which are only present in small numbers in normal thymuses.
- Thymic follicular hyperplasia is found in most patients with myasthenia gravis and sometimes also occurs in other autoimmune diseases, such as systemic lupus erythematosus and rheumatoid arthritis.

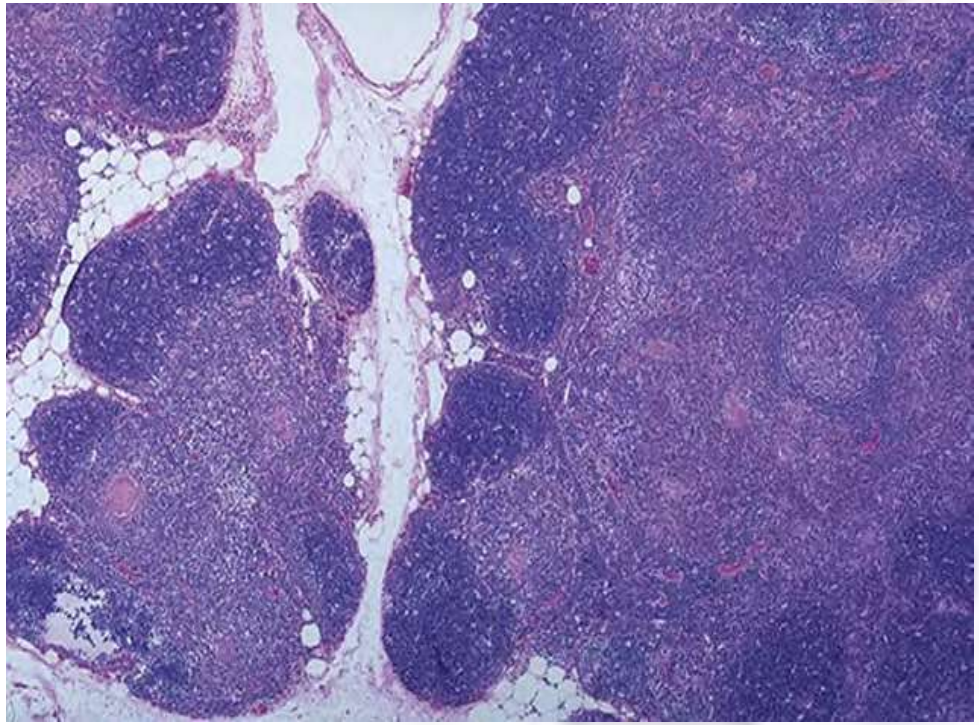

Thymoma

- Thymomas are **tumors of thymic epithelial cells** accompanied by varying numbers of benign immature T cells (thymocytes).
- Thymomas are **classified** as follows:

- **Benign or encapsulated thymoma:** cytologically and biologically benign
- **Malignant thymoma:**

--Type I: cytologically benign but infiltrative and locally aggressive
--Type II (thymic carcinoma): cytologically and biologically malignant

- **Clinical features:**

- Occur in middle-aged adults.
- In a large series about **30% were asymptomatic**; 30% to 40% produced local manifestations such as cough, dyspnea, and superior vena cava syndrome; and the remainder were associated with a systemic disease, most commonly myasthenia gravis, in which a concomitant thymoma is discovered in 15% to 20% of patients.

- In addition to myasthenia gravis, other associated autoimmune disorders include hypogammaglobulinemia, pure red cell aplasia, Graves disease, pernicious anemia, dermatomyositis, polymyositis, and Cushing syndrome.

➢ MORPHOLOGY:

(A) **(B)** **(C)**

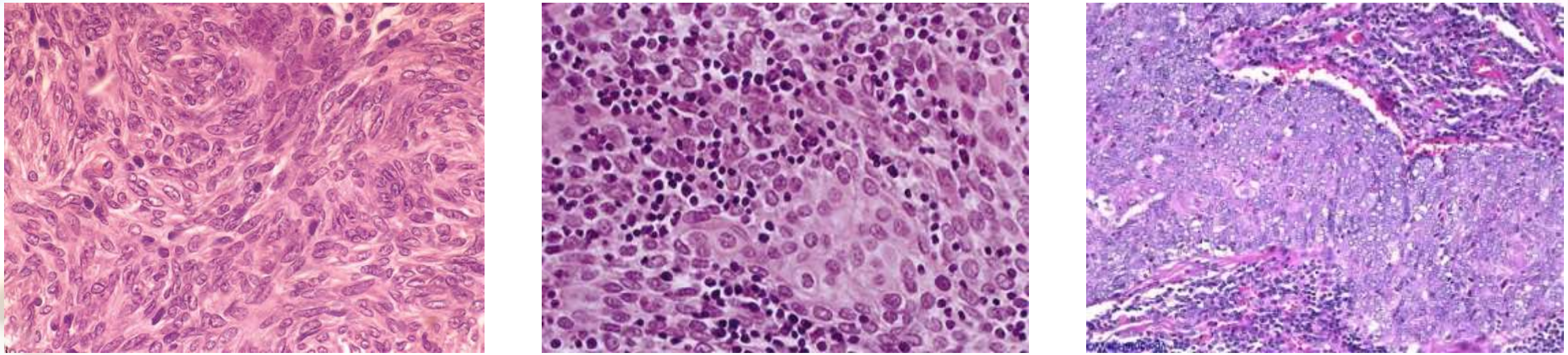

- **(A) Benign thymoma** (medullary type). The neoplastic epithelial cells are **elongated or spindle-shaped with a few small, reactive lymphoid cells**. **(B) Malignant thymoma, type I.** The neoplastic epithelial cells usually have **abundant cytoplasm and rounded vesicular nuclei** with **numerous small, reactive lymphoid cells. (C) Malignant thymoma type II (thymic carcinoma):** Microscopically, most **resemble squamous cell carcinoma.**

THANK YOU