

## *Mandibular first premolar*

Is the fourth tooth from the median line & the first posterior tooth in the mandible. It is developed from four lobes. Although this tooth has two cusps & corresponds to the second premolar more closely in size, it has many of the characteristics of a small canine, since its long, sharp & well-developed buccal cusp is the only functioning part of it. It functions along with the mandibular canine, also it supplements second premolar in function.

The first premolar is always the smaller of the two mandibular premolars, where as the opposite is true in many cases of the maxillary premolars.

The mandibular first premolar has some characteristics common to each of canine & second premolar.

**The characteristics that resemble those of the mandibular canine are as follows: -**

1. The buccal cusp is long & sharp & is the only occluding cusp.
2. The buccolingual measurement is similar to that of the canine.
3. The occlusal surface slopes sharply lingually in a cervical direction.
4. The mesial cusp ridge of the buccal cusp is shorter than the distal cusp ridge.
5. The outline form of the occlusal aspect resembles the outline form of the incisal aspect of the canine.

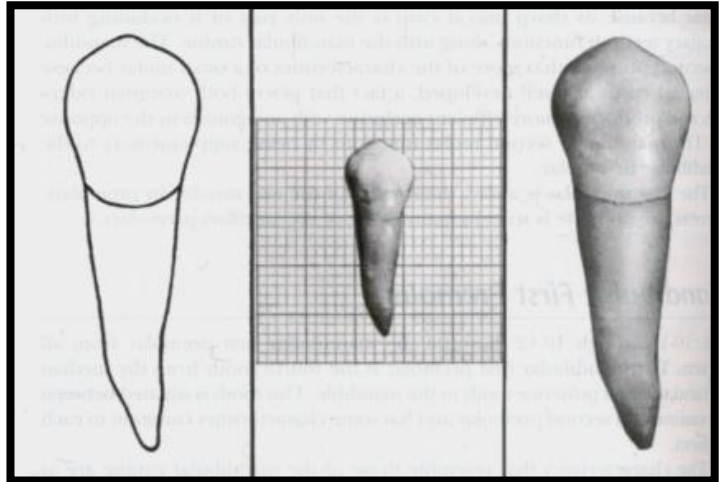
**The characteristics that resemble those of the second mandibular premolar are as follows: -**

1. The outline of crown & root from the buccal aspect resembles that of second premolar, except for the longer cusp.
2. The contact areas mesially & distally are near the same level.
3. The curvatures of the cervical line mesially & distally are similar.
4. The tooth has more than one cusp.
5. The root length is closer to that of the second premolar.

TABLE 10-2 Mandibular Second Premolar									
								First evidence of calcification	2¼-2½ yr
								Enamel completed	6-7 yr
								Eruption	11-12 yr
								Root completed	13-14 yr
MEASUREMENT TABLE									
	CERVICO- OCCLUSAL LENGTH OF CROWN	LENGTH OF ROOT	MESIODISTAL DIAMETER OF CROWN	MESIODISTAL DIAMETER OF CROWN AT CERVIX	LABIO- OR BUCCOLINGUAL DIAMETER OF CROWN	LABIO- OR BUCCOLINGUAL DIAMETER OF CROWN AT CERVIX	CURVATURE OF CERVICAL LINE—MESIAL	CURVATURE OF CERVICAL LINE—DISTAL	
Dimensions* suggested for carving technique	8.0	14.5	7.0	5.0	8.0	7.0	1.0	0.0	
*In millimeters.									

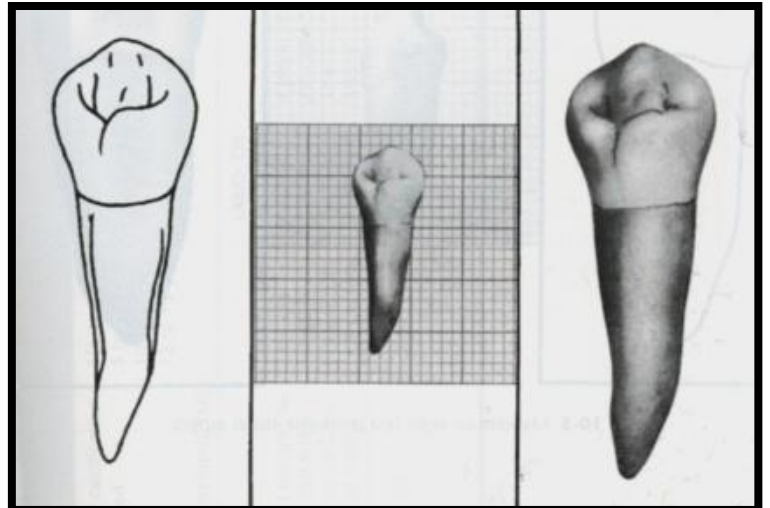
## ***Buccal aspect***

- The crown is roughly trapezoidal with the longest uneven side toward occlusal surface.
- The crown is nearly symmetrical bilaterally.
- The middle buccal lobe is well developed resulting in a large pointed buccal cusp.
- The mesial cusp ridge is shorter than the distal cusp ridge.
- The mesial & distal outlines from the cervix to the crests of curvatures are slightly concave.
- The contact areas are broad, with the crests of curvatures almost at the same level mesially & distally, this level being a little more than half the distance from the cervical line to the cusp tip.
- The mesial slope outline of the buccal cusp usually shows some concavity, as well as, the distal slope outline.
- The tip of the buccal cusp is pointed & is, in most cases, located a little mesial to the center of the crown buccally.
- The measurement mesiodistally at the cervical line is small when it is compared with the measurement at the contact areas.
- The continuous ridge from the cervical margin to the cusp tip is called the **buccal ridge**.
- Developmental depressions are often seen between the three lobes.
- The outline of the buccal portion of the root resembles that of the canine, has tendency toward mesial inclination, although most of these roots curve distally.



## ***Lingual aspect***

- The crown & root tapers markedly toward the lingual, so that most of the mesial & distal surfaces of both may be seen from the lingual aspect.
- The occlusal surface slopes greatly toward the lingual in a cervical direction down to the short lingual cusp. Therefore, most of the occlusal surface of this tooth can be seen from this aspect.
- Although the lingual cusp is short & poorly developed (resembling a strongly developed cingulum at times), it usually shows a pointed tip, which is in alignment with the buccal triangular ridge of the occlusal surface. The mesial and distal occlusal fossae are on each side of the triangular ridge.
- A **characteristic** of the lingual surface of this tooth is the ***mesiolingual developmental groove***. This groove acts as a line of demarcation between the mesiobuccal lobe & the lingual lobe, & extends into the mesial fossa of the occlusal surface.



## ***mesial aspect***

From this aspect, the mandibular first premolar shows an outline that is fundamental & characteristic of all mandibular posterior teeth when viewed from the mesial or distal aspect.

**(This is a variation in the functional design from that of maxillary posterior teeth): -**

1. The crown outline is roughly rhomboidal.
2. The tip of the buccal cusp is nearly centered over the root.
3. The convexity of the lingual outline of the lingual cusp is lingual to the lingual outline of the root.
4. The surface of the crown presents an overhang above the root trunk in a lingual direction.
5. The tip of the lingual cusp will be on a line approximately with the lingual border of the root.
6. The buccal outline of the crown is prominently curved from the cervical line to the tip of the buccal cusp. The crest of curvature is near the middle third of the crown.
7. The lingual outline is a curved outline of less convexity than that of the buccal surface, the crest of curvature lingually approaches the middle third of the crown.

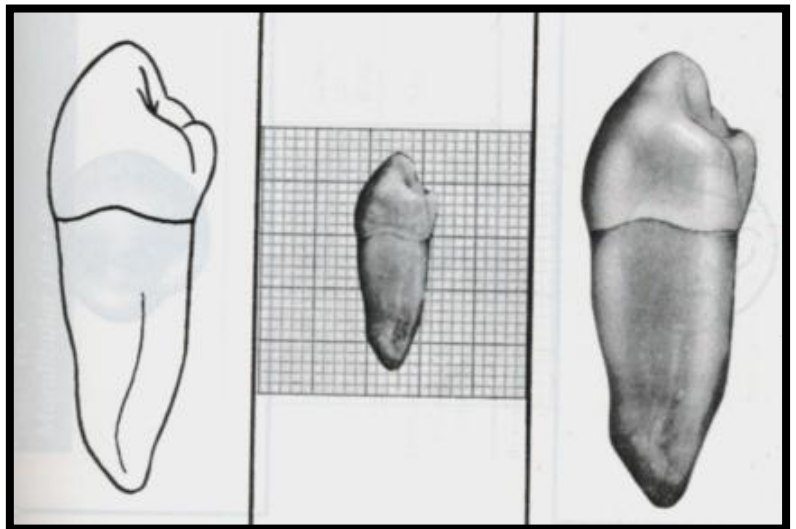
■ The distance from the cervical line lingually to the tip of the lingual cusp is about two thirds of that from the cervical line buccally to the tip of the buccal cusp.

■ The mesiobuccal lobe development is prominent from this aspect, it creates by its form the mesial contact area & the mesial marginal ridge.

■ Some of the occlusal surface of the crown mesially may be seen with the mesial portion of the buccal triangular ridge.

■ The surface of the crown mesially, is smooth except for the mesiolingual groove.

■ The surface is convex at the mesial contact area, & it is sharply concave between that area & the cervical line.

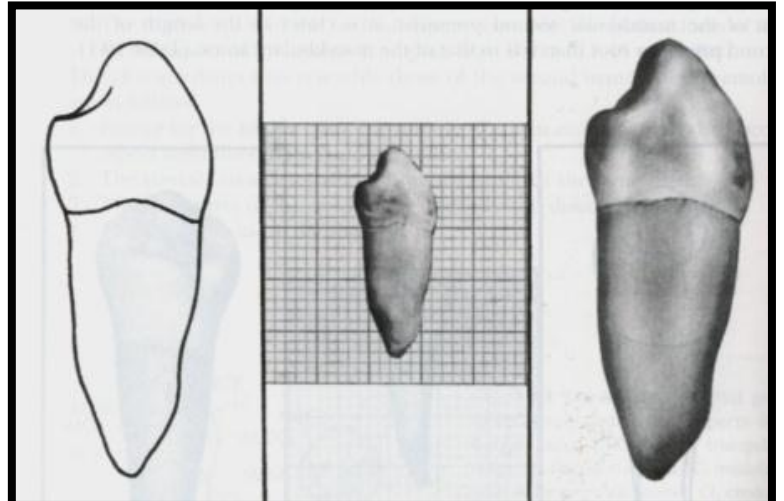


- The root surface often displaying a developmental groove that is occasionally a deep one will end in a bifurcation in the apical third.

## ***Distal aspect***

The distal aspect of mandibular first premolar differs from the mesial aspect in some respects:-

- The distal marginal ridge is higher & has less inclination of the lingual slope cervically, being more nearly at right angles to the axis of crown & root.
- There is no developmental groove on the distal marginal ridge.
- The distal contact area is broader than the mesial although it is centered in the same relation to the crown outlines.
- The cervical curvature is practically nil.
- The surface of the root distally exhibits more convexity than was found mesially.
- Shallow developmental depression centered on the root, but rarely does it contain a deep developmental groove.
- The slope of the distal surface of the root from the buccal margin toward the center of the root lingually is more gradual than found mesially.

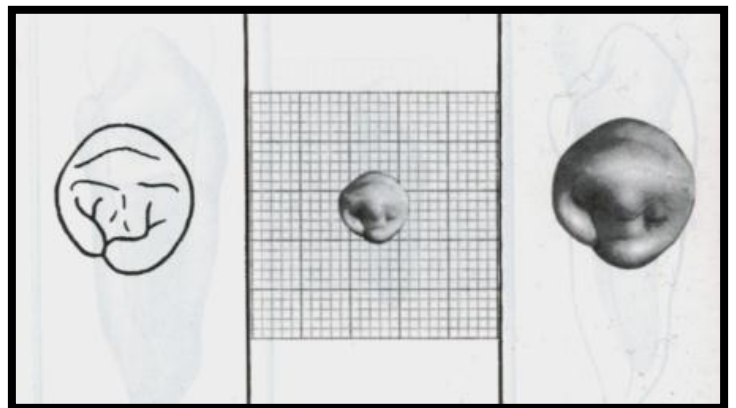


## ***Occlusal aspect***

Both mandibular premolars exhibit more variations in form occlusally than maxillary premolars.

The characteristics common to all mandibular first premolars when viewed from the occlusal aspect are these: -

- The middle buccal lobe makes up the major bulk of the tooth crown.
- The buccal ridge is prominent.
- The mesiobuccal & distobuccal line angles are prominent even though rounded.
- The curvatures representing the contact areas are relatively broad, the distal area being the broader.
- The marginal ridges are well developed.
- The lingual cusp is small.
- Heavy buccal triangular ridge & small lingual one.
- There are two depressions, which are called **mesial & distal fossae** because of their irregularity of form.
- Mesiolingual developmental groove.
- Mesial & distal developmental grooves in the mesial & distal fossae.
- Because of the position of the crown over the root, most of the buccal surface may be seen from the occlusal aspect, whereas very little of the lingual surface is seen.



# END