

The permanent Canines *Maxillary & Mandibular*

The maxillary and mandibular canines bear a close resemblance to each other, and their functions are closely related. The four canines are placed at the “corners” of the mouth; each one is the third tooth from the median line, right and left, in the maxilla and mandible. They are commonly referred to as the *cornerstone* of the dental arches.

In function, the canines support the incisors & premolars, since they are located between these groups. The canine crowns have some characteristics of functional form which resemble the incisor form, & some which resemble the premolar form.

They are the longest teeth in the mouth, & their roots are longer & larger than those of any of other teeth.

The middle labial lobe in each canine has been developed incisally into strong well-formed cusp. The canine sometimes called *cuspid*.

The shape of the crowns, with their pointed cusps, their locations in the mouth & the extra anchorage provided by the long and strong roots, make these canines resemble the prehensile teeth of carnivores. This resemblance gives rise to the term canine. (Latin canis-dog).

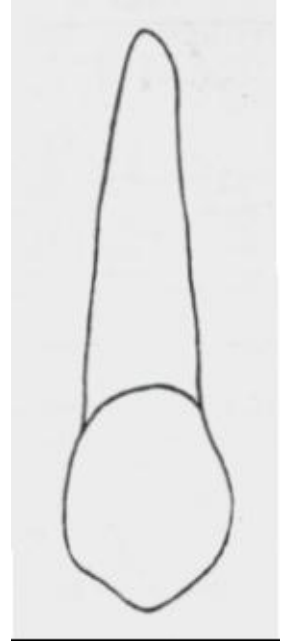
Because of the labiolingual thickness of crown & root & the anchorage in the alveolar process of the jaws, these teeth are the most stable in the mouth. Furthermore the crowns of the canines are shaped in a manner that promotes cleanliness. This self-cleansing quality, along with efficient anchorage in the jaws, tends to preserve these teeth throughout life. When teeth are lost, the canines usually the last teeth to be lost. Therefore, the canines are valuable & important teeth when considered as units of the natural dentition or as abutments in prosthetic restorations.

The positions & forms of these teeth & their anchorage in the bone, along with the bone ridge over the labial portions of the roots which is called *canine eminence*, also have a cosmetic value. They help to ensure normal facial expression at the corners of the mouth.

Maxillary Canine

Labial Aspect

- The crown & root are narrower mesiodistally than those of maxillary central incisor.
- Mesially, the outline may be convex from the cervix to the contact area. The crest of curvature is approximately at the junction of middle & incisal thirds of the crown.
- Distally, the outline of the crown usually concave between the cervical line & distal contact area. The distal contact area is usually at the center of the middle third of the crown.
- The cusp has a mesial slope & a distal slope, the mesial slope being the shorter of the two. Both slopes show a tendency toward concavity before wear has taken place. The cusp tip is on a line with the center of the root.
- The cervical line is convex, toward the root.
- The labial surface of the crown is smooth except for shallow depressions mesially & distally, dividing the three labial lobes. The middle labial lobe show greater development producing the labial ridge.
- The root appears slender from the labial aspect, it is conical in form with a bluntly pointed apex that may curve distally in most instances.



Lingual Aspect

- The crown & root are narrower lingually than labially.
- The cingulum is larger than that found in maxillary central & lateral incisors, & in some cases is pointed like a small cusp.
- Occasionally, a well-developed lingual ridge is seen which is confluent with the cusp tip, this extends to a point near the cingulum. There may be shallow concavities between this ridge & the marginal ridges, these concavities are called *mesial & distal lingual fossae*.
- Developmental depressions mesially & distally may be seen on most of roots, extending most of the root length.
- The lingual ridge of the root is rather narrow, but it is smooth & convex at all points from the cervical line to the apical end.

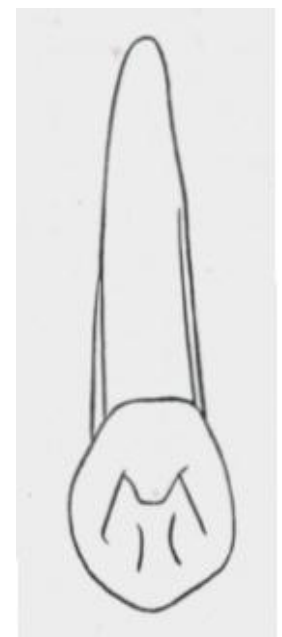


TABLE 8-1 Maxillary Canine

First evidence of calcification	4-5 mo
Enamel completed	6-7 yr
Eruption	11-12 yr
Root completed	13-15 yr

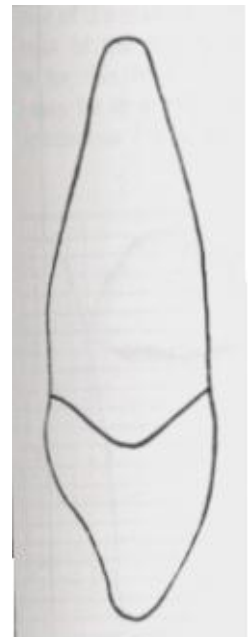
MEASUREMENT TABLE

	CERVICOINCISAL LENGTH OF CROWN	LENGTH OF ROOT	MESIODISTAL DIAMETER OF CROWN	MESIODISTAL DIAMETER OF CROWN AT CERVIX	LABIO- OR BUCCOLINGUAL DIAMETER OF CROWN	LABIO- OR BUCCOLINGUAL DIAMETER OF CROWN AT CERVIX	CURVATURE OF CERVICAL LINE—MESIAL	CURVATURE OF CERVICAL LINE—DISTAL
Dimensions* suggested for carving technique	10.0	17.0	7.5	5.5	8.0	7.0	2.5	1.5

*In millimeters.

Mesial Aspect

- The labiolingual measurement is greater than any of the other anterior teeth.
- The outline of the crown is wedge-shaped and the greatest measurement being at the cervical third, & the wedge point being represented by tip of the cusp.
- The outlines of the crown below the cervical line labially & lingually correspond to that of incisors. However, the crest of curvature is found at a level more incisal. Many canines show a flattened area labially at the cervical third.
- Below the cervical third, the labial face is slightly convex from the crest of curvature to the tip of the cusp. [The entire labial outline of the crown from this aspect exhibits more convexity than that of maxillary central incisor].
- The lingual outline may be represented by a convex line describing the cingulum which straightens as it reaches the middle third, then becoming convex again in the incisal third.
- The outline of the root from this aspect is conical with a tapered or bluntly pointed apex.
- A line bisecting the cusp is labial to a line bisecting the root.
- The mesial surface of the canine crown presents convexities at all points except for a small area above the contact area, where it is concave & flat.
- The mesial surface of the root appears broad, with a shallow developmental depression for part of the root length. Developmental depressions on the heavy roots help to anchor the teeth in the alveoli & help to prevent rotation & displacement.



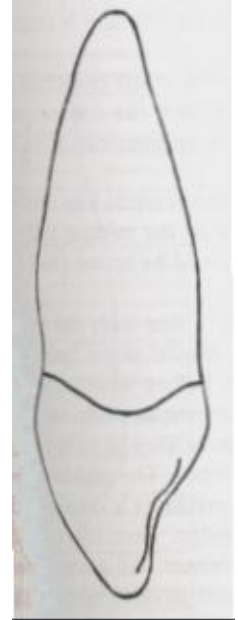
Note:

The greater labiolingual measurement gives the crown greater bulk & more reinforcement to compensate directional lines of the force brought against it when in use.

Distal Aspect

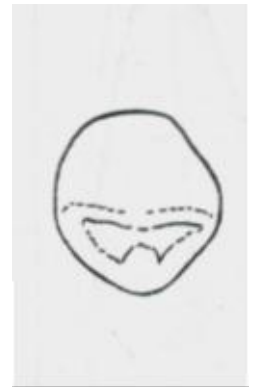The distal aspect of the maxillary canine shows somewhat the same form as the mesial aspect, with the following variations: -

- The cervical line exhibits less curvature toward the cusp ridge.
- The distal marginal ridge is heavier & more irregular in outline.
- The surface displays more concavity usually above the contact area.
- The developmental depression on the distal side of the root is more pronounced.



Incisal Aspect

- In general, the labiolingual dimension is greater than the mesiodistal. Occasionally, the two measurements are about equal.
- The tip of the cusp is labial to the center of the crown labiolingually & mesial to the center mesiodistally.
- The ridge of the middle labial lobe is very noticeable labially from this aspect, with its greatest convexity at the cervical third of the crown, becoming broader & flatter at the middle & incisal thirds.
- The cingulum development makes up the cervical third of the crown lingually. The outline of the cingulum may be described by a shorter arc than the one labially from this aspect.



END