

*Lec. 7***Dental Anatomy**

د. حكمت الغراوي

Mandibular Central Incisor

*Normally, the mandibular central incisor is the smallest tooth in the dental arches.

*The crown & root are narrow mesiodistally, although they are wide labiolingually. The crown has little more than half the mesiodistal diameter of the maxillary central incisor. The length of the root is as great, if not longer than that of the maxillary central incisor.

Labial Aspect

*The labial aspect of the mandibular central incisor is regular, tapering evenly from the mesio- & distoincisoral angles to the apex of the root.

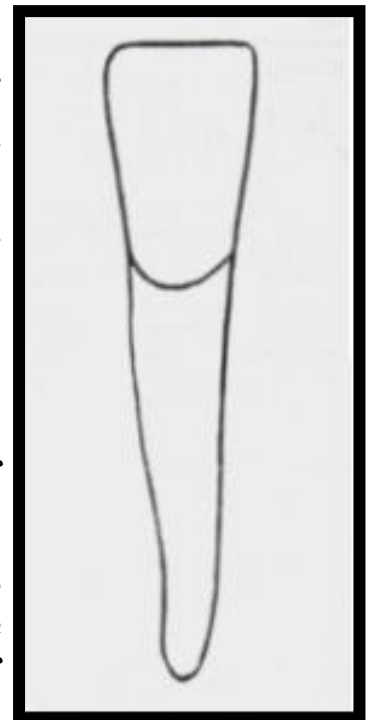
*The incisal ridge or edge is straight & is at approximately a right angle to the long axis of the tooth.

*The mesioincisal angle is sharp & the distoincisoral angle is very slightly rounded.

*The contact areas are near the incisal ridge mesially & distally, they are incisal to the junction of incisal & middle thirds of the crown.

*The labial face of the crown is ordinarily smooth, with a flattened surface at the incisal third, the middle third is more convex, narrowing down to the convexity of the root.

*The mesial & distal outlines of the root are straight. The apical third of the root terminates in a small pointed taper, in most cases curving distally; the labial surface of the root is regular & convex.

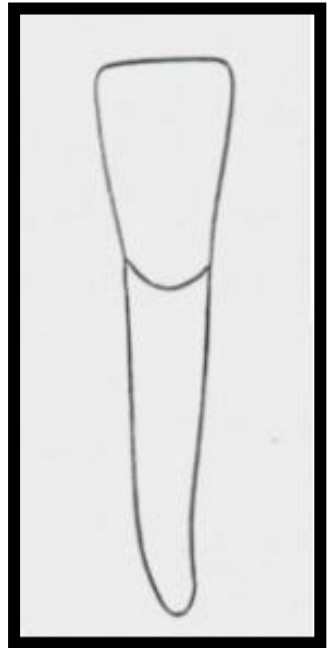


Lingual Aspect

*The lingual surface of the crown is smooth, with very slight concavity at the incisal third between the indistinct marginal ridges.

*The lingual surface becomes flat & then convex as progression is made from the incisal third to the cervical third.

*No developmental lines mark the cingulum development on this tooth. No other tooth in the mouth, except the mandibular lateral incisor, shows so few developmental lines & grooves.



Mesial Aspect

*The curvature labially & lingually of the cervical third of the crown above the cervical line is less than that found on the maxillary incisors.

*The labial outline is straight above the cervical curvature.

*The lingual outline of the crown is straight line inclined labially for a short distance above the smooth convexity of the cingulum. The straight outline joins a concave line at the middle third, which extend upward to join the rounded outline of a narrow incisal ridge.

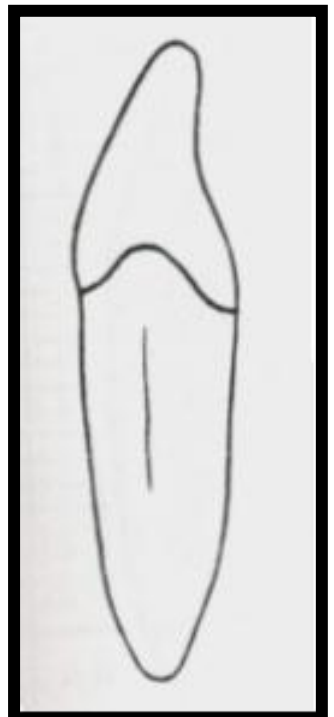
*The incisal ridge is rounded or worn flat & it is lingual to a line bisecting the root.

*The curvature of the cervical line is marked, curving incisally about one-third the length of the crown.

*The mesial surface of the crown is convex & smooth at the incisal third & becomes broader & flatter at the middle & cervical thirds.

*The root outlines are straight with uniform root diameter through the cervical third & part of the middle third, then begins to taper & end in a bluntly round or pointed root end.

*The mesial surface of the root is flat just below the cervical line. Most of these roots have a broad developmental depression for most of the root length. The depression usually deeper at the junction of the middle & apical thirds.



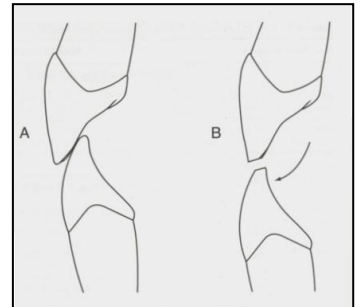
Distal Aspect

*The cervical line curves incisally about 1mm less than that on the mesial.

*The distal surface is similar to that of the mesial surface. The developmental depression on the distal surface of the root may be more marked, with a deeper & more well defined developmental groove at its center.

Note:

The incisal surface shows a labial inclination, that is different from that in maxillary incisors when the incisal edge has a lingual inclination.



Incisal Aspect

*This aspect illustrates the bilateral symmetry. The mesial half of the crown is almost identical with the distal half.

*The incisal edge is almost at right angle to the line bisecting the crown labiolingually. This is a characteristic feature serves as a mark of identification in differentiation between mandibular central & lateral incisors.

*The labial surface of the crown at the incisal third is broad & flat, but it has a tendency toward convexity at the cervical third. Whereas the lingual surface of the crown at the incisal third has an inclination toward concavity.

*The labiolingual diameter is greater than mesiodistal diameter of the crown.

*The labial surface of the crown is wider mesiodistally than the lingual surface.

*More of the labial surface may be seen than of the lingual surface.

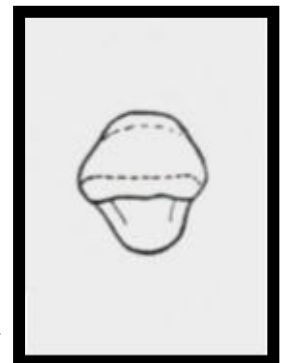


TABLE 7-1 Mandibular Central Incisor

First evidence of calcification	3-4 mo
Enamel completed	4-5 yr
Eruption	6-7 yr
Root completed	9 yr

MEASUREMENT TABLE

	CERVICOINCISAL LENGTH OF CROWN	LENGTH OF ROOT	MESIODISTAL DIAMETER OF CROWN	MESIODISTAL DIAMETER OF CROWN AT CERVIX	LABIO- OR BUCCOLINGUAL DIAMETER OF CROWN	LABIO- OR BUCCOLINGUAL DIAMETER OF CROWN AT CERVIX	CURVATURE OF CERVICAL LINE—MESIAL	CURVATURE OF CERVICAL LINE—DISTAL
Dimensions* suggested for carving technique	9.5	12.5	5.0	3.5	6.0	5.3	3.0	2.0

*In millimeters.

TABLE 7-2 Mandibular Lateral Incisor

First evidence of calcification	3-4 mo
Enamel completed	4-5 yr
Eruption	7-8 yr
Root completed	10 yr

MEASUREMENT TABLE

	CERVICOINCISAL LENGTH OF CROWN	LENGTH OF ROOT	MESIODISTAL DIAMETER OF CROWN	MESIODISTAL DIAMETER OF CROWN AT CERVIX	LABIO- OR BUCCOLINGUAL DIAMETER OF CROWN	LABIO- OR BUCCOLINGUAL DIAMETER OF CROWN AT CERVIX	CURVATURE OF CERVICAL LINE—MESIAL	CURVATURE OF CERVICAL LINE—DISTAL
Dimensions* suggested for carving technique	9.5	14.0	5.5	4.0	6.5	5.8	3.0	2.0

*In millimeters.

Mandibular lateral incisor

This tooth is closely resembles the mandibular central incisor but it is somewhat larger.

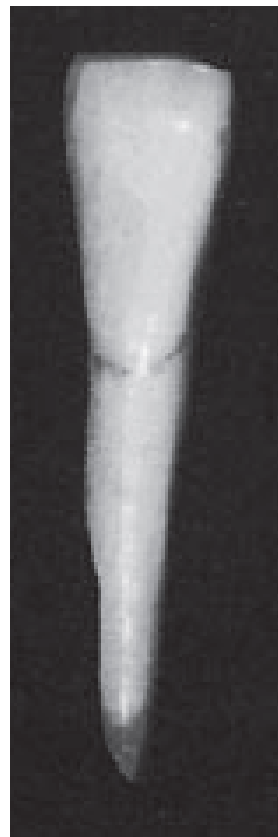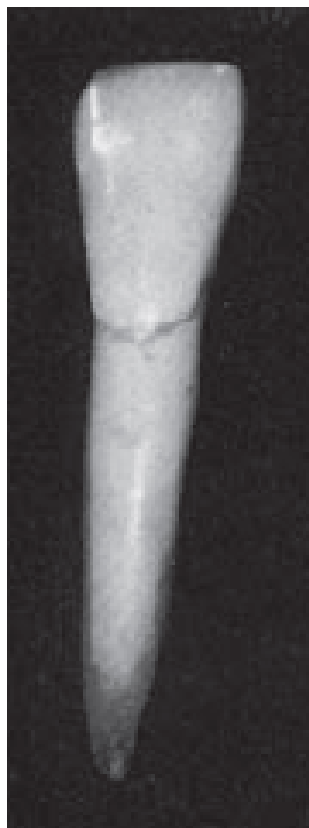Compare the graphs of the lateral incisor with those of the central incisor, observing the following variations:-

***The labial & lingual aspects show the added 0.5 mm of the crown width mesiodistally added to the distal half.**

***The distal contact area is more cervical in location than the mesial contact area.**

***The mesial side of the crown is often longer than the distal side, causing the incisal ridge to slop downward in a distal direction.**

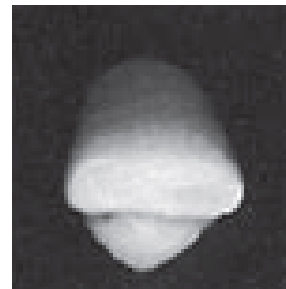
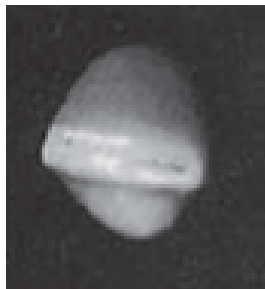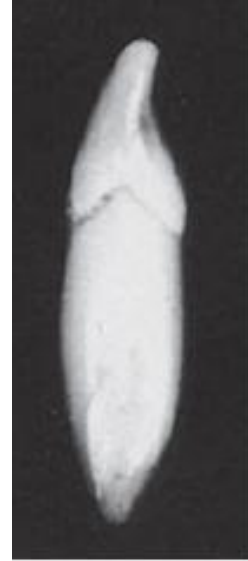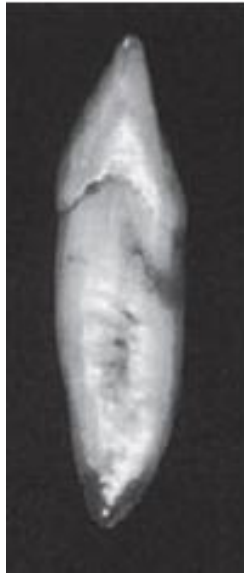***The crown is slightly longer than that of central incisor, but the root may be considerably longer.**



***There is no marked difference between the mesial & distal surfaces of central & lateral incisors except for size & the tendency toward deeper concavity immediately above the cervical line on the distal surface.**

***The incisal edge is not at approximately right angle to a line bisecting the crown & root labiolingually.**

***The edge follows the curvature of the mandibular dental arch, giving the crown of the mandibular lateral incisor the appearance of being twisted slightly on its root base.**



End