

CROWN AND BRIDGE

Lect.18

RESIN-BONDED FIXED PARTIAL DENTURES

د. حيدر حسن

INTRUDUCTION

One of the disadvantages of a conventional fixed partial denture is the destruction of tooth structure required for the abutment preparations upon which the retainers will be placed.

The patient usually asks "it is really necessary to cut away that entire good tooth?" This question troubled dentists in prescribing the replacement of a missing tooth.

Some dentists have tried to minimize the problem by eliminating one of the abutment teeth and fabricating a cantilever fixed partial dentures. While this type of restoration does have its place in carefully selected situations, it is discriminate use can result in failures that are costly both in money spent for subsequent replacement and in loss of periodontal support around previously sound teeth.

Others have tried to use unilateral removable partial denture to avoid undesirable destruction of tooth structure, but these are usually wanting in both retention and stability and may present the risk of aspiration if they become dislodged.

The development of acid etching of enamel to improve the retention of resin has proven to be a means of attaching fixed partial dentures to teeth by less destructive means.

First trial was consisting of attaching acrylic resin pontic to an unprepared tooth using a composite bonding resin, as intermediate replacement of a missing tooth.

METAL FRAMEWORK

The addition of a metal substructure and "wings" or retainers, extending onto the abutment teeth was a logical progression in the development of the restoration.

The Classification of Resin-Bonded Fixed Partial Dentures: -

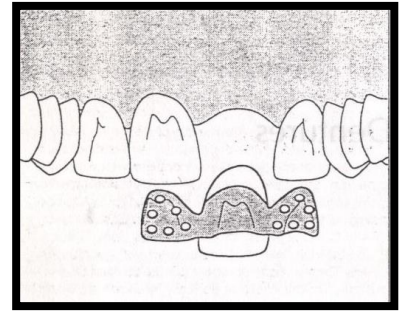
- 1. ROCHETTE BRIDGE**
- 2. MARYLAND BRIDGE**
- 3. CAST MESH FPD.**
- 4. VIRGINIA BRIDGE**
- 5. ADHESION BRIDGE**

✚ These classifications are reflection of the metal surface finishing technique employed.

ROCHETTE BRIDGE

First used by Rochette in 1973. It consists of a wing like retainer attached to the pontic, with funnel-shaped perforations through the wing (retainer) to enhance resin retention (mechanical retention in addition to application of a silane coupling agent to produce adhesion to the metal).

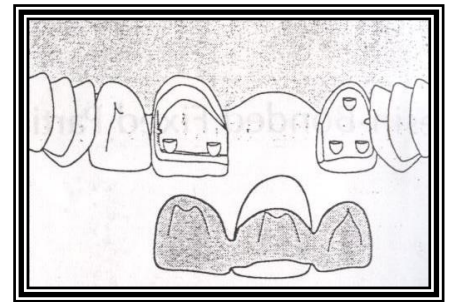
Used for both anterior and posterior fixed partial dentures.



MARYLAND BRIDGE

The searchers postulated that the retentive resin extruding through the perforated framework in rochette design were exposed to increased stresses as well as abrasion and leakage that diminished their longevity.

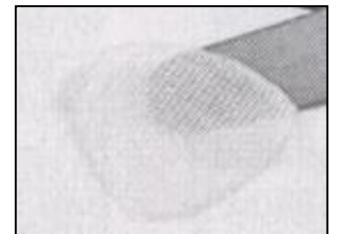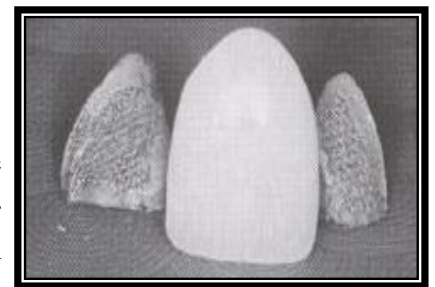
The new design of the wing is perforation free, and the retention to the resin could be obtained by producing micro-spaces in the wing (retainer) internal surface through various ways such as electrochemical pit corroding technique (metal etching)



CAST MESH FPD

In this design, they used a non-etching method to produce metal surface roughness before the alloy is cast. A ready-made net-like nylon mesh can be placed over the lingual

surfaces of the abutment teeth on the working cast. It is then covered by and incorporated into the retainer wax pattern, with the undersurface of the wing (retainer) becoming a mesh-like surface when the retainer is cast.



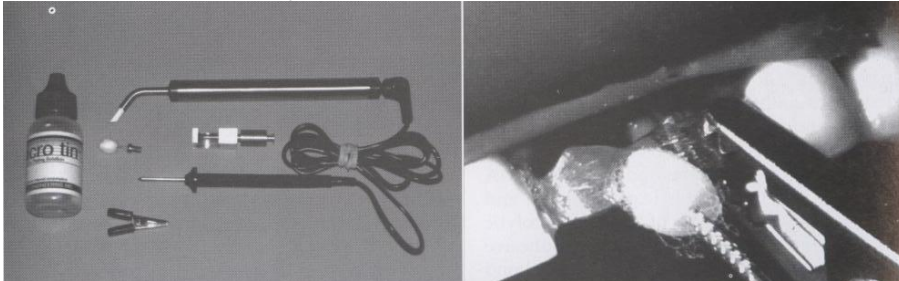
VIRGINIA BRIDGE

This design produced particle-roughened retainers by incorporating salt crystals into the retainer patterns to produce roughness on the inner surfaces; this method is known as the lost salt technique for producing Virginia bridges.

The framework is outlined on the die with a pencil, and the area to be bonded is coated first with model spray and then with lubricant, then salt crystals (NACL) ranging in size from 149-250Mm are sprinkled over the outlined area. The retainer pattern is fabricated from resin, leaving a 0.5 to 1.0mm wide, crystal free margin around the outlined area. When the resin has polymerized, the patterns are removed from the cast, cleaned with a solvent, and then placed in water in an ultrasonic cleaner to dissolve the salt crystals. This leaves cubic voids in the surface that are reproduced in the cast retainers, producing retention for the fixed partial denture.

Adhesion Bridge

In this design there is no need to make any surface modification before casting, after casting, we clean the surfaces with air abrasion, then prepare the retainer inner surface for adhesion by various methods such as tin plating which carried intraorally. The bond in this design depends on the inherent bond ability of the newer resin cement to the alloy.



Advantages of Resin-Bonded Fixed Partial Dentures

- 1- Reduced cost and chair time by as much as 50 percent.
- 2- Conservative, minimum tooth structure needs to be removed; the preparation is confined to enamel only.
- 3- Anaesthesia is not used during tooth preparation (aid to monitor the proximity of the preparation to the DEJ by the patient comfort's level).
- 4- Supragingival margin is mandatory in resin-bonded fixed partial dentures.
- 5- The restoration can be rebounded.

Disadvantages

- 1- Uncertain longevity, the longevity of the prostheses is less than that for conventional prostheses.
- 2- Irreversible.
- 3- No space correction, if the edentulous space is wider than the mesiodistal width of the tooth that would normally occupy the space.
- 4- No alignment correction, good alignment of the abutment teeth is required because the prosthesis's path of insertion is limited by enamel thickness.
- 5- Difficult temporization.

Indication

➤ Mandibular incisor replacements

It is the treatment of choice for replacing one or two missing mandibular incisors when the abutment teeth are undamaged.

➤ Maxillary incisor replacements

+end-to-end, or moderate overbite situation.

➔ **Periodontal splint**

The splinting of periodontally involved teeth was the first use of a resin-bonded fixed partial denture.

➔ **Single posterior tooth replacements.**

Contraindications

- ✓ **Extensive caries:** Because it covers relatively little surface area and relies on bonding to enamel for its retention.
- ✓ **Deep vertical overbite** So much enamel must be removed from the lingual surface of a maxillary incisor in this occlusal relationship, the retention would be drastically reduced because of the poor bonding strength afforded by the exposed dentin.

Tooth Preparation

The tooth preparation includes axial reduction and guide planes on the proximal surfaces with a slight extension onto the facial surface to achieve faciolingual lock. The preparation should encompass at least 180 degrees of the tooth to enhance the resistance of the retainer.

The preparation must be extended as far as possible to provide maximum bonding area, there should be a finish line which is a very light chamfer and should be placed about 1.0 mm supragingivally.

Occlusal clearance which is about 0.5mm is needed on maxillary incisors, the thickness of enamel on the lingual surfaces of maxillary anterior teeth are shown in the table.

Tooth	Millimeters from cemento-enamel junction					
	1	2	3	4	5	6
Central incisor	0.3	0.5	0.6	0.7	0.7	0.7
Lateral incisor	0.4	0.5	0.5	0.6	0.7	0.7
Canine	0.2	0.4	0.6	0.7	0.9	0.9

Vertical stops are placed on all the preparations.

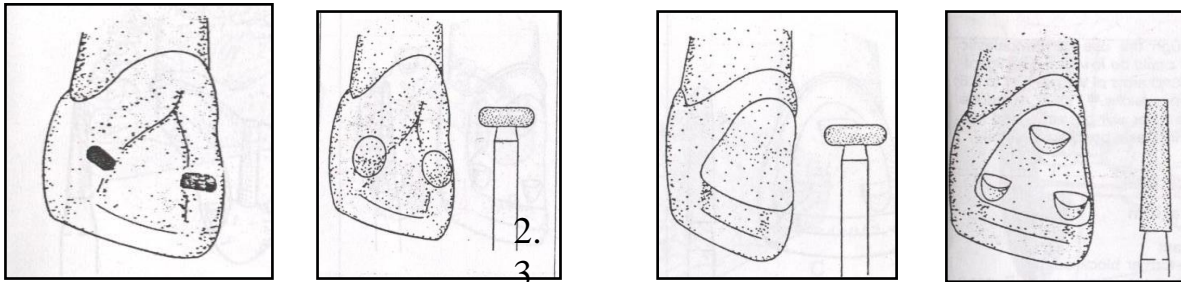
On the maxillary incisor consist of two or three flat countersinks on the lingual surface.

A cingulum rest on a canine, or an occlusal rest seat on a premolar or molar, contributing to both resistance and rigidity.

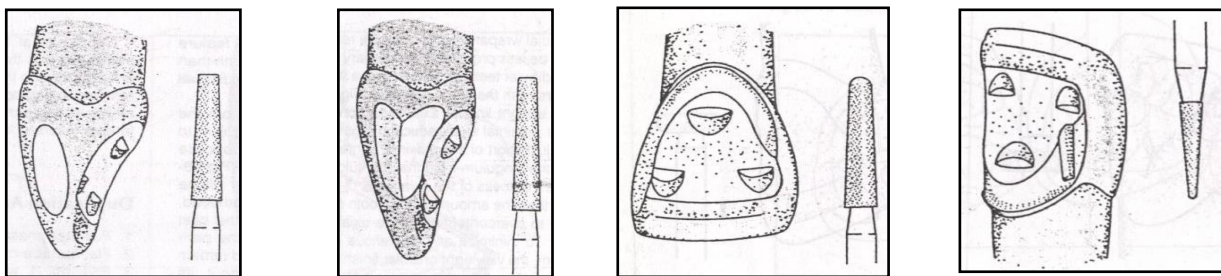
The resistance features normally are grooves.

Preparation Sequence for maxillary incisor.

1. The centric occlusal contacts are marked with articulating paper. To ensure adequate occlusal clearance in this area, use a small wheel diamond to remove 0.5mm of tooth structure, this step is necessary only on maxillary anterior teeth.



- 2- Wheel diamond bur is also used to create a concave reduction on the entire cingulum surface, producing 0.5mm of lingual clearance. End this reduction 1.5 to 2.0mm from the incisal edge.
- 3- Use a flat-end tapered diamond to prepare flat notches or countersinks on the lingual surface of the tooth to provide resistance to gingival displacement.



- 4- Proximal reduction on the surface adjacent to the edentulous space is done with a tapered diamond, as follows: -
 - A- Producing a small plane that extends slightly facial to the facio-proximal line angle. This helps produce facial wraparound to enhance resistance.
 - B- A second plane is produced lingual to the first with the same diamond.
- 5- Light upright lingual axial reduction is done from biplanes proximal axial reduction around the cingulum to appoint just short of the proximal contact on the opposite side of the cingulum from the edentulous space.
- 6-A short groove is placed at the facial most extension of the reduction on the opposite side of the cingulum with a short needle diamond. The same diamond used to place a groove in the vicinity of the wraparound or break between the facial and lingual planes of proximal axial reduction adjacent to the edentulous space.

