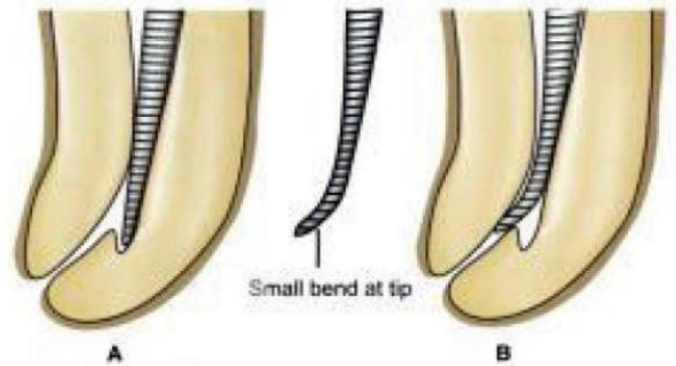


Endodontic mishaps I



Endodontic mishaps or procedural accidents are those unfortunate occurrences that happen during treatment, some owing to inattention to detail, others totally unpredictable. The mishaps listed in Table will be described in detail, including how to recognize them, how to correct them, how they affect prognosis, and how to prevent them.

Recognition of a mishap is the first step in its management; it may be by radiographic or clinical observation or as a result of a patient complaint; for example, during treatment, the patient tastes sodium hypochlorite owing to a perforation of the tooth crown allowing the solution to leak into the mouth.

Correction of a mishap may be accomplished in one of several ways depending on the type and extent of procedural accident. Unfortunately, in some instances, the mishap causes such extensive damage to the tooth that it may have to be extracted.

Re-evaluation of the prognosis of a tooth involved in an endodontic mishap is necessary and important. The re-evaluation may affect the entire treatment plan and may involve dentolegal consequences. Dental standard of care requires that **patients be informed about any procedural accident.**

Table Endodontic Mishaps

Access related

Treating the wrong tooth

Missed canals

Damage to existing restoration

Access cavity perforations

Crown fractures

Instrumentation related

Ledge formation

Cervical canal perforations

Mid root perforations

Apical perforations

Separated instruments and foreign objects

Canal blockage

Obturation related

Over- or under extended root canal fillings

Nerve paresthesia

Vertical root fractures

Miscellaneous

Post space perforation

Irrigant related

Tissue emphysema

Instrument aspiration and ingestion

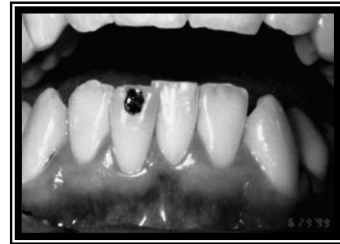Endodontic mishaps sometimes have dentolegal consequences. These can be minimized or avoided by providing patients with adequate information prior to the endodontic procedure. The following suggestions can help in establishing good patient communication:

1. Inform the patient before treatment about the possible risks involved. If the patient has been told that a porcelain crown may chip during treatment, when this occurs it will not be unexpected.
2. When a procedural accident occurs, explain to the patient the nature of the mishap, what can be done to correct it, and what effect the mishap may have on the tooth's prognosis and on the entire treatment plan.
3. If a procedural accident leads to a situation that is beyond the treating dentist's training and ability to handle, he or she should recognize the need to refer the patient to a specialist. It is important to note here that the standard of care in endodontics has only one level; both general dentists and specialists are held to the same standard.

ACCESS-RELATED MISHAPS

Treating the Wrong Tooth

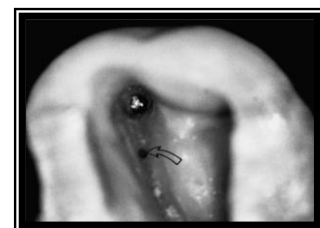
If there is no question about diagnosis, treating the wrong tooth falls within the category of inattention on the part of the dentist. Obviously, misdiagnosis may happen and should not be automatically considered an endodontic mishap. But if tooth #23 has been diagnosed with a necrotic pulp and the rubber dam is placed on tooth #24 and that tooth opened, that is a mishap.



Once a correct diagnosis has been made, the embarrassing situation of opening the wrong tooth can be prevented by marking the tooth to be treated with a pen before isolating it with a rubber dam.

Missed Canals

Some root canals are not easily accessible or readily apparent from the chamber; additional canals in the mesial roots of maxillary molars and distal roots of mandibular molars are good examples of canals often left untreated. Other canals are also missed because of a



lack of knowledge about root canal anatomy or failure to adequately search for these additional canals.

Recognition of a missed canal can occur during or after treatment. During treatment, an instrument or filling material may be noticed to be other than exactly centered in the root, indicating that another canal is present.

Correction. Re-treatment is appropriate and should be attempted before recommending surgical correction.

Prognosis. A missed canal decreases the prognosis and will most likely result in treatment failure. In some teeth with multicanal roots, two canals may have a common apical exit. As long as the apical seal adequately seals both canals, it is possible that the bacterial content in a missed canal may not affect the outcome for some time.

Prevention. Locating all of the canals in a multicanal tooth is the best prevention of treatment failure. **Adequate coronal access** allows the opportunity to find all canal orifices. Additionally, radiographs taken from mesial and/or distal angles will help to determine if the one canal that has been located is centered in the root, recalling that an eccentrically located canal is highly suggestive of the presence of another canal yet to be found. Knowledge of root canal morphology and knowing which teeth have multiple canals is a good foundation.

Damage to Existing Restoration

An existing porcelain crown presents the dentist with its own unique challenges. In preparing an access cavity through a porcelain or porcelain-bonded crown, the porcelain will sometimes chip, even when the most careful approach using water-cooled diamond stones is followed. There is usually no way to predict such an occurrence. Knowing when to exercise caution can, however, reduce unwanted results.

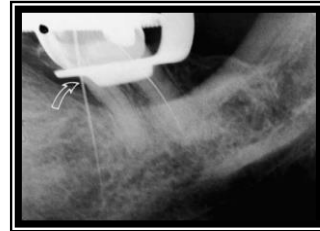
Correction. Minor porcelain chips can at times be repaired by bonding composite resin to the crown. However, the longevity of such repairs is unpredictable.

Prevention. Placing a rubber dam clamp directly on the margin of a porcelain crown is asking for trouble. This may result in damage to the crown margin and/or fracture of the porcelain. Even removal of a **provisionally** cemented new crown prior to endodontic therapy may also pose a problem. These crowns can be difficult to remove, and often a margin will be damaged, or the porcelain may chip.

Access Cavity Perforations

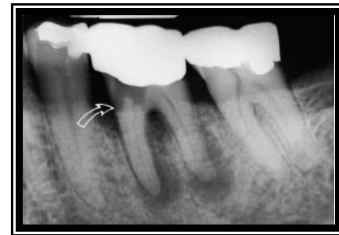Undesirable communications between the pulp space and the external tooth surface may occur at any level: in the chamber or along the length of the root canal. They may occur during preparation of the access cavity, root canal space, or post space. In this section, the problem of access cavity perforations will be addressed.

Access preparations are made to allow the locating, cleaning, and shaping of all root canals. In the process of searching for canal orifices, perforations of the crown can occur, either peripherally through the sides of the crown or through the floor of the chamber into the furcation.



Recognition. If the access cavity perforation is **above the periodontal attachment**, the first sign of the presence of an accidental perforation will often be the presence of leakage: either saliva **into** the cavity or sodium hypochlorite **out** into the mouth, at which time the patient will notice the unpleasant taste.

When the crown is perforated **into the periodontal ligament**, bleeding into the access cavity is often the first indication of an accidental perforation. To confirm the suspicion of such an unwanted opening, place a **small** file through the opening and take a radiograph; the film should



clearly demonstrate that the file is not in a canal. In some instances, a perforation may initially be thought to be a canal orifice; placing a file into this opening will provide the necessary information to identify this mishap.

Correction. Perforations of the coronal walls **above the alveolar crest** can generally be repaired intracoronally without need for surgical intervention.

Perforations into the periodontal ligament, whether laterally or into the furcation, should be done as soon as possible to minimize the injury to the tooth's supporting tissues. It is also important that the material used for the repair provides a good seal and does not cause further tissue damage.

A material recently approved by the US Food and Drug Administration, mineral trioxide aggregate (MTA), has shown **convincing** results and several new studies have supported its use for perforation repairs.

Prognosis for a perforated tooth must generally be downgraded. How much it is downgraded is a clinical decision based on the circumstances such

as the perforation size and the existing periodontal condition. The prognosis for a tooth with a perforation depends on the location of the perforation; the length of time the perforation is open to contamination, the ability to seal the perforation, and accessibility to the main canal.

Prevention. Thorough examination of diagnostic preoperative radiographs is the paramount step to avoid this mishap. Checking the long axis of the tooth and **aligning the long axis of the access bur with the long axis of the tooth** can prevent unfortunate perforations of a tipped tooth. The presence, location, and degree of calcification of the pulp chamber noted on the preoperative radiograph are also important information to use in planning the access preparation.

Crown Fractures

Crown fractures of teeth undergoing root canal therapy are a complication that can be avoided in many instances.

The tooth may have a preexistent infraction that becomes a true fracture when the patient chews on the tooth weakened additionally by an access preparation.

Recognition of such fractures is usually by direct observation. It should be noted that infractions are often recognized first after removal of existing restoration in preparation of the access. When infractions become true fractures, parts of the crown may be mobile.

Treatment. Crown fractures usually have to be treated by extraction unless the fracture is of a “chisel type” in which only the cusp or part of the crown is involved; in such cases, the loose segment can be removed and treatment completed. If the fracture is more extensive, the tooth may not be restorable and needs to be extracted. Crowns with infractions should be supported with circumferential bands or temporary crowns during endodontic treatment.

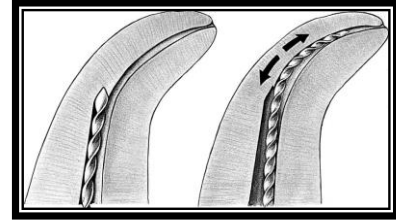
Prognosis for a tooth with a crown fracture, if it can be treated at all, is likely to be less favorable than for an intact tooth, and the outcome is unpredictable. Crown infractions may spread to the roots, leading to vertical root fractures.

Prevention is simple: reduce the occlusion before working length is established. In addition to preventing this mishap, it also will aid in reducing discomfort following endodontic therapy. As described above, bands and temporary crowns are also valuable.

Instrumentation related

Ledge Formation

Ledges in canals can result from a failure to make access cavities that allow direct access to the apical part of the canals or from using straight or too-large instruments in curved canals. The newer instruments with non cutting tips have reduced this problem by allowing the instruments to track the lumen of the canal, as have nickel-titanium files. Occasionally, even skilled and careful clinicians develop canal ledges when treating teeth with unsuspected aberrations in canal anatomy.



Recognition. Ledge formation should be suspected when the root canal instrument can no longer be inserted into the canal to full working length. There may be a loss of normal tactile sensation of the tip of the instrument binding in the lumen. This feeling is supplanted by that of the instrument point hitting against a solid wall: a loose feeling with no tactile sensation of tensional binding.

Correction. The use of a small file, No. 10 or 15, with a distinct curve at the tip can be used to explore the canal to the apex. The curved tip should be pointed toward the wall opposite the ledge.

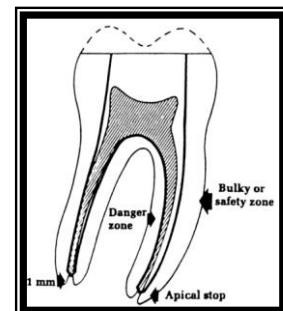
Completion of canal preparation can best be accomplished by following these recommendations: Use a lubricant, irrigate frequently to remove dentin chips, maintain a curve on the file tip, and, using short file strokes, press the instrument against the canal wall where the ledge is located.

Prevention. The best solution for ledge formation is prevention. Accurate interpretation of diagnostic radiographs should be completed before the first instrument is placed in the canal. Awareness of canal morphology is imperative throughout the instrumentation procedure. Finally, precurving instruments and not “forcing” them is a sure preventive measure.

Perforations

Accidental canal perforations may be categorized by location. Radicular perforations can be identified as either cervical, mid root, or apical root perforations.

Perforations in all of these locations may be caused by two errors of commission: **(1)** creating a ledge in the canal wall during initial instrumentation

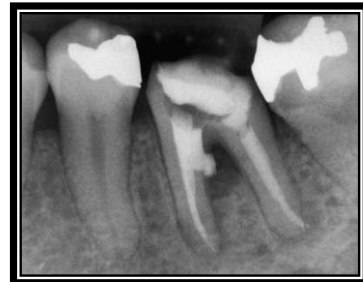

and perforating through the side of the root at the point of canal obstruction or root curvature and (2) using too large or too long an instrument and either perforating directly through the apical foramen or “wearing” a hole in the lateral surface of the root by over instrumentation (canal “stripping”).

Cervical Canal Perforations

The **cervical portion** of the canal is most often perforated during the process of locating and widening the canal orifice or inappropriate use of Gates-Glidden burs.

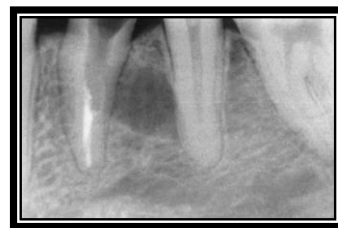
Recognition often begins with the sudden appearance of blood, which comes from the periodontal ligament space. Rinsing and blotting (with a cotton pellet) may allow direct visualization of the perforation; magnification with either loupes, an endoscope, or a microscope is very useful in these situations. If direct visualization is not adequate to make a definitive identification of a perforation, it may be necessary to place a small file into the area that has been exposed and take a radiograph of the tooth; the film should clear up any uncertainty.



Correction of the perforation may include both internal and external repair. A small area of perforation may be sealed from inside the tooth. If the perforation is large, it may be necessary to seal first from the inside and then surgically expose the external aspect of the tooth and repair the damaged tooth structure; a material that has been recommended for this is MTA. **Prevention** may be achieved by reviewing each tooth’s morphology prior to entering its pulp space.

Mid root Perforations

Lateral perforations at mid root level tend to occur mostly in curved canals, either as a result of perforating when a ledge has formed during initial instrumentation or along the inside curvature of the root as the canal is straightened out. The latter is often referred to as canal “stripping” and results in a fairly long perforation that seriously compromises the outcome of treatment.



Recognition. “Stripping” is a lateral perforation caused by over instrumentation through a thin wall in the root and is most likely to happen on the inside, or concave, wall of a curved canal, such as the **distal wall of the mesial roots** in mandibular first molars.

Correction. Successful repair of a lateral perforation is contingent on the adequacy of the seal established by the repair material. Since the primary concern is to prevent overextension, unless a resorbable material is first introduced against which to condense, the material is often forced out into the ligament space despite gentle placement, and a likely poor seal will result.

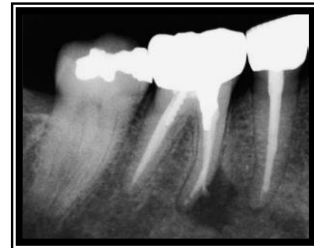Access to mid root perforation is most often difficult, and repair is not predictable. Calcium hydroxide has been used in the hope of stimulating a biologic barrier against which to pack filling material, but usually filling material ends up into the perforation area.

Prognosis. Both “stripping” perforation and direct lateral perforation of the root result in a reduction of the prognosis.

Apical Perforations

Perforations in the **apical segment** of the root canal may be the result of the file not negotiating a curved canal or not establishing accurate working length and instrumenting beyond the apical confines.

Recognition. An apical perforation should be suspected if the patient suddenly complains of pain during treatment, if the canal becomes flooded with hemorrhage, or if the tactile resistance of the confines of the canal space is lost.



Correction. Efforts to repair may be to attempt to renegotiate the apical canal segment or to consider the perforation site as the new apical opening and then decide what treatment the untreated apical root segment will require. One is now dealing with two foramina: one natural, the other iatral. Obturation of both of these foramina and of the main body of the canal requires the vertical compacting techniques with heat-softened gutta-percha. Often surgery is necessary, particularly if a lesion is present apically.

Creating an **apical barrier** is another technique that can be used to prevent overextensions during root canal filling. Materials used for developing such barriers include dentin chips, calcium hydroxide powder, Proplast, hydroxyapatite and, more recently, MTA.

Prognosis. There are probably more apical perforations than perforations in other areas of the pulp space. Fortunately, with successful

repair, apical perforations have less adverse effect on prognosis than more coronal perforations.

Canal Blockage

When a canal suddenly does not permit a working file to be advanced to the apical stop, a situation sometimes referred to as a “block out” has occurred. “...blockage occurs when files compact apical debris into a hardened mass.”

Recognition occurs when the confirmed working length is no longer attained. Evaluation radiographically will demonstrate that the file is not near the apical terminus.

Correction is accomplished by means of recapitulation. Starting with the smallest file used, the quarter-turn technique using a chelating agent can be helpful. If the block out occurs at a curve or bend of the root, gently precurving the instruments to redirect it is also effective.

Prognosis depends on the stage of instrumentation completed when the block out occurs. If the canal has been adequately cleaned, it should have little or no effect. If, however, the block out occurs before the canal is clean, prognosis will be reduced. Teeth with vital pulps have a better prognosis than those with necrotic pulps.

Prevention consists of frequent irrigation during canal preparation to remove dentin debris.

