

# The Human Bones

---

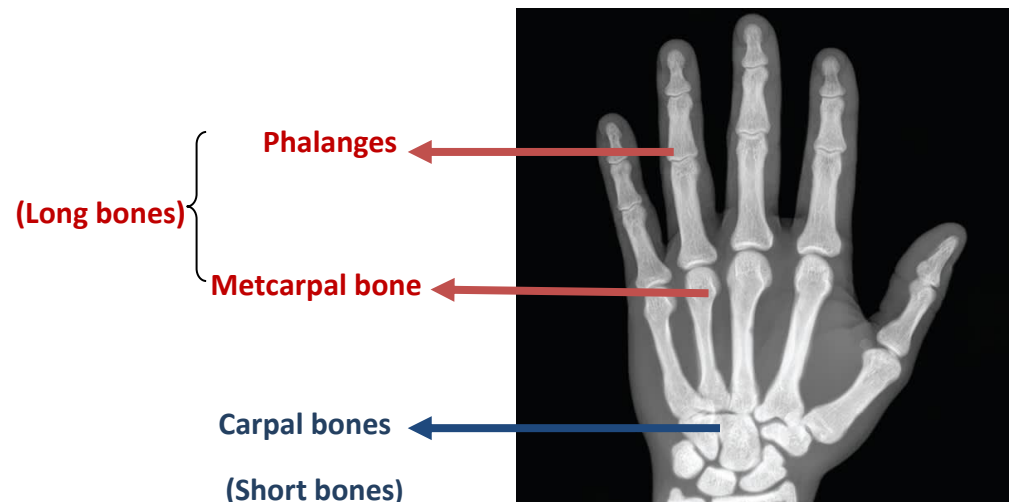
## The Bones

- Bones are type of connective tissue that is covered by a thick layer of fibrous tissue, known as **Periosteum**.
  
- **Major Functions:**
  - a) Protection for example, the skull and vertebral column protect the brain and spinal cord from injury, and the sternum and ribs protect the thoracic and upper abdominal viscera.
  - b) Support of the body organs and soft tissues.
  - c) Facilitates the movement of the body and locomotion.
  
- **Classification**
  - According to density: **compact** (dense, solid) and  **cancellous** (spongy).
  - According to the site (region): the bones are organized into two main groups: the *axial* and *appendicular* skeletons.

The **axial skeleton** consists of the elements forming the central axis of the body (skull, vertebral column, and thoracic cage).

The **appendicular skeleton** consists of the bones forming the shoulder, pelvis, upper limb, and lower limb.
  - According to the shape; bones are organized into five categories: **Long, Short, Flat, Irregular, and Sesamoid**.

- **Long Bones:** Long bones are found in the limbs (e.g., the humerus, femur, metacarpals, metatarsals, and phalanges). Their length is greater than their width.
- **Short Bones:** Short bones are found in the hand (carpal bones) and foot (tarsal bones). They are roughly cuboidal in shape.



- **Flat Bones:** Flat bones are found in the vault of the skull (frontal, parietal and occipital bones). They are composed of thin inner and outer layers of compact bone, the **tables**, separated by a layer of cancellous bone, the **diploë**. The scapulae, although irregular in shape, are included in this group.
- **Irregular Bones:** Irregular bones include those not assigned to the previous groups (e.g., the bones of the skull, the vertebrae, and the pelvic bones).
- **Sesamoid Bones:** A sesamoid bone is one formed within a tendon where the tendon passes over a joint. The greater part of a sesamoid bone is buried in the tendon. The largest sesamoid bone is the patella (“kneecap”), which is located in the tendon of the quadriceps femoris.  
The function of a sesamoid bone is to reduce friction on the tendon.

## The Skeleton

- The adult human skeleton composed of 206 bones.
- These bones vary in size from the small ossicles of the inner ear to the femur bone which may exceed 45 cm in length.

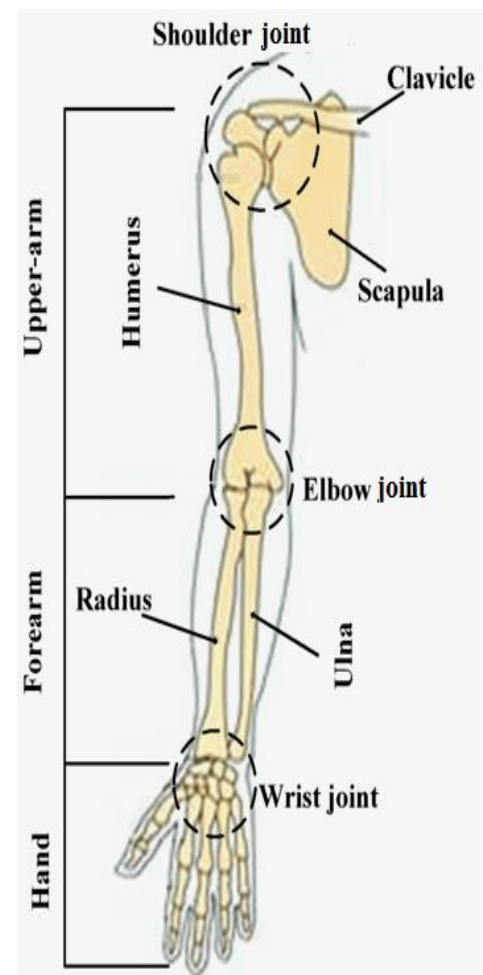
## Upper Limb

The upper limb is organized into the shoulder joint, the arm, the cubital fossa, the forearm, the wrist, and the hand.

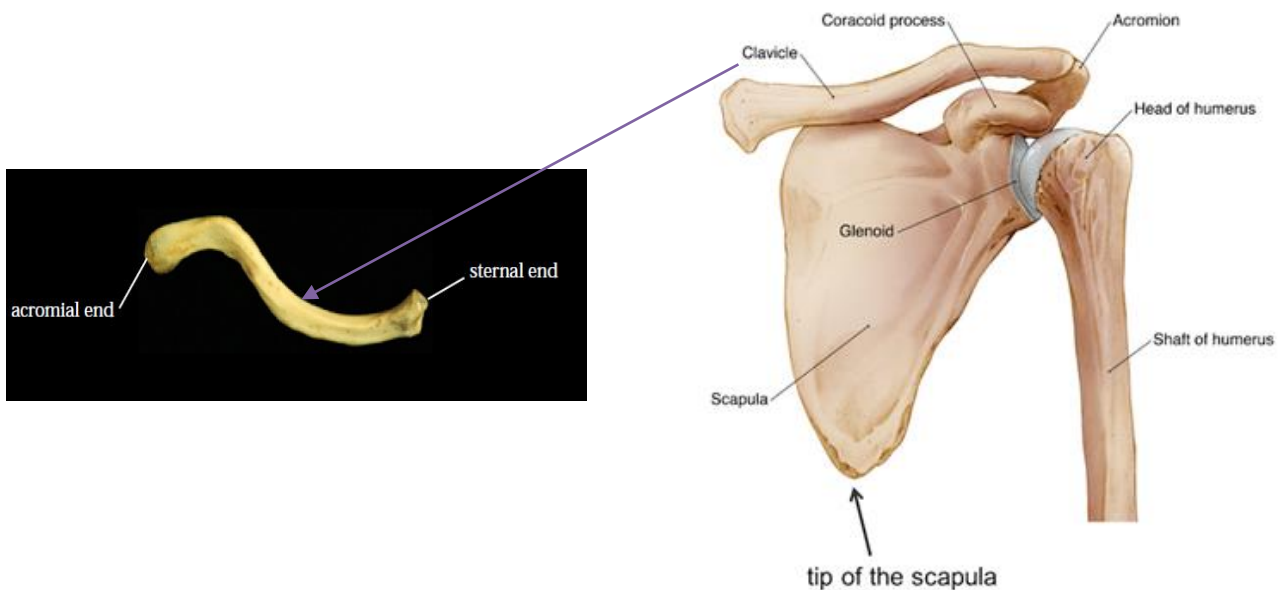
The upper limb is freely movable at the shoulder joint. Its primary function is to maneuver the hand.

The hand has with the unique ability to grasp items in both coarse and fine ways. The opposable action of the thumb (which enables the tip of the thumb to contact the tips of the other digits) plays a major role in hand grasping.

The bones of upper limb are the clavicle, scapula, humerus, ulna, radius, carpal bones, metacarpal bones, and phalanges. The humerus defines the arm, whereas the radius and ulna delineate the forearm. The carpal bones form the wrist, and the metacarpals and phalanges constitute the hand

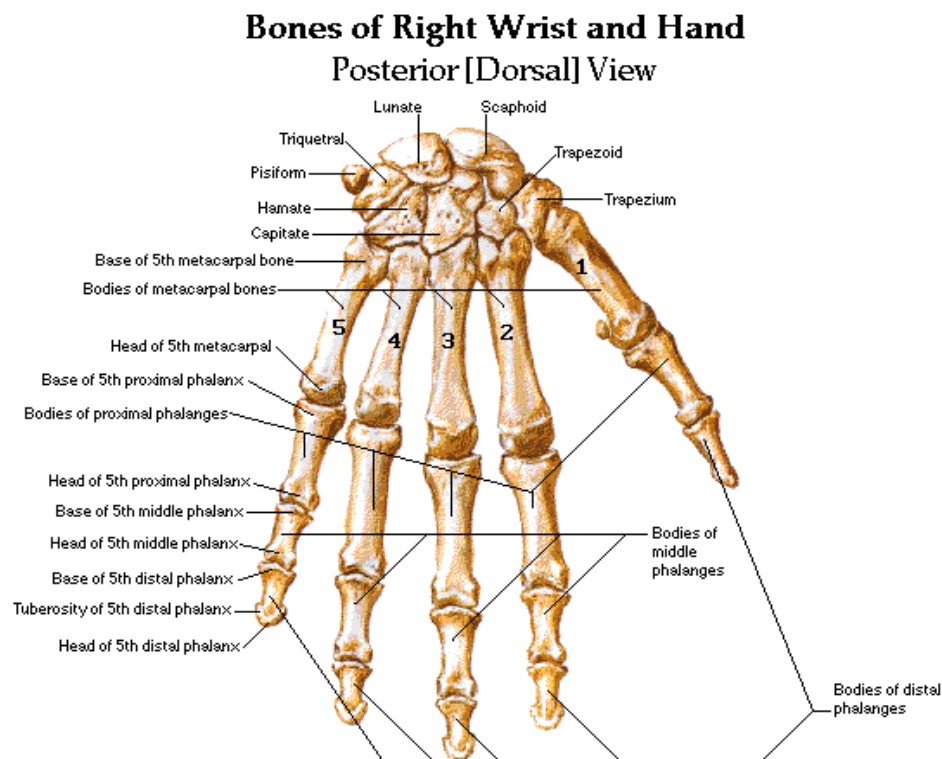


- **Clavicle:** Also known as the “collar bone,” the clavicle is located between the sternum and the scapula and lies horizontally across the root of the neck. It is roughly S-shaped. The clavicle is subcutaneous and easily palpable along its entire length. It articulates with the acromion process of the scapula
- **Scapula:** Also known as the “shoulder bone,” is a large, flat, triangular bone. It articulates with the clavicle and the head of the humerus.



- **Humerus:** Humerus is the longest bone of the upper limb. Proximally, the humerus articulates with the scapula, at the shoulder joint. Distally, it articulates with the head of the radius and the ulna at the elbow joint.
- **Radius** The radius is the bone on the lateral side of the forearm.
- **Ulna:** It is the bone that lies on the medial side of the forearm.
- **Carpal Bones:** The carpal (*carp-* is Greek for wrist) bones are the eight small bones comprising the wrist.

- **Metacarpal Bones:** The metacarpal bones are the five bones located between the carpal bones and the phalanges of the hand. These comprise the body of the hand, whereas the phalanges make up the fingers. The bones are identified by number (1–5), starting with the most lateral unit (i.e., metacarpal 1 aligns with the thumb)



- **Phalanges:** are the bones that comprise the digits of the hand. As with the metacarpals, each has a base, body (shaft), and head. The thumb has 2 phalanges (proximal and distal), whereas each other digit has 3 phalanges (proximal, middle, distal). Thus, each hand has 14 phalanges in total.

## The Lower limb

The primary functions of the lower limbs are to support the weight of the body and produce locomotion.

The lower limbs are very stable and can bear the weight of the body. This stability also provides the foundation for standing in the upright posture, walking, and running.

Each lower limb is organized into the **gluteal region**, the **thigh**, the **popliteal fossa**, the **leg**, the **ankle**, and the **foot**.

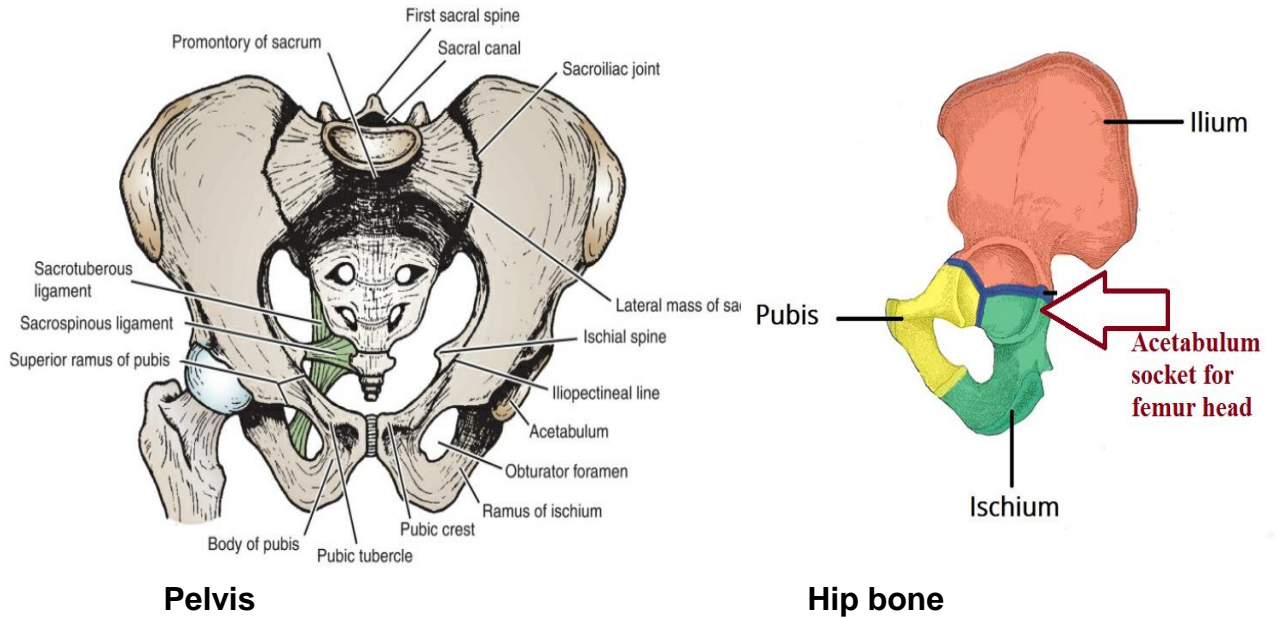
The bones of the lower limb are the hip bone (pelvis bone), femur, patella, tibia, fibula, metatarsal bones, tarsal bones, and phalanges. The general arrangement of the bones is very similar to that in the upper limb.

- **Pelvis:** The bony pelvis is a bowl-shaped bony structure. The main function of the bony pelvis is to transmit the weight of the body from the vertebral column to the femurs. In addition, it contains, supports, and protects the lower parts of the gastrointestinal and urinary tracts and the internal organs of reproduction.

Hip bone is functionally the equivalent of the upper limb clavicle and scapula. Three skeletal elements that form the hip bone are: the ilium, ischium, and pubis.

The **ilium**, is the largest, which is the upper flattened part of the bone, possesses the **iliac crest**. This can be felt through the skin along its entire length.

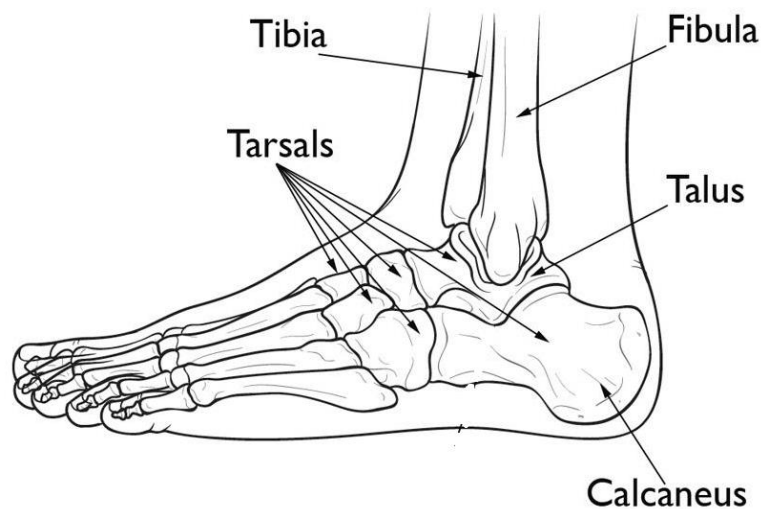
The bodies of the two pubic bones articulate with each other in the midline anteriorly at the **symphysis pubis**.



- **Femur:** The femur articulates above with the acetabulum to form the hip joint and below with the tibia and the patella to form the knee joint. It is the longest and strongest bone in the body.
- **Patella (kneecap):** is the largest **sesamoid bone** (it develops within the tendon of the quadriceps femoris muscle in front of the knee joint). It is triangular, and its apex lies inferiorly.
- **Tibia:** The tibia is the large medial bone of the leg. It articulates with the femur, and fibula above and with the talus, and fibula below. The lower end is prolonged downward medially to form the large **medial malleolus**.
- **Fibula:** The fibula is the slender lateral bone of the leg. It takes no part in the articulation at the knee joint, but it participates in the ankle joint below. It takes no part in the transmission of body weight.

The **lower end** of the fibula forms the triangular **lateral malleolus**, which is subcutaneous

- **Foot Bones:** The bones of the foot are the **tarsal bones**, the **metatarsals**, and the **phalanges**. The general groupings are similar to that of the carpals, metacarpals, and phalanges in the wrist and hand.
  - **Calcaneum:** is the largest bone of the foot and forms the prominence of the heel.



**This is the End of the Lecture - Good Luck**