

# Failure of restorative materials

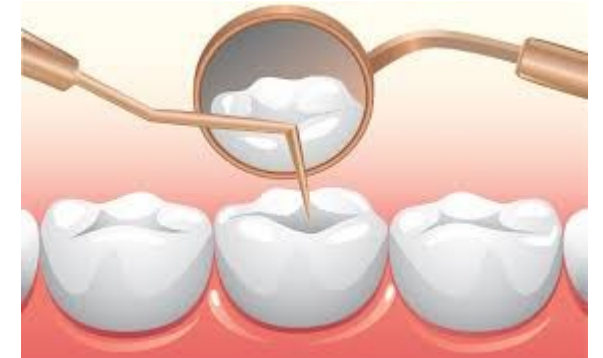

## Failure of a restoration could be caused by

- **Patient related factors (short-term and long-term failures).**
- **Material related factors (res and long-term failures).**
- **Operator related factors (mostly short-term failures).**

## II – clinical examination of amalgam restoration.

Evaluation of all restoration must be done systemically in a clean, dry, well lighted field. Clinical evaluation of amalgam restoration requires **visual observation**, application of tactile sense with the **explorer**, use of **dental floss**, and **radiographs**.



## Failure of amalgam restoration

Several conditions may be encountered when amalgam restorations are evaluated

- Amalgam “blues”
- Proximal overhangs
- Marginal ditching
- Voids
- Fracture lines
- Improper anatomic contours
- Marginal ridge incompatibility
- Improper proximal contacts
- Recurrent caries
- Improper occlusal contacts

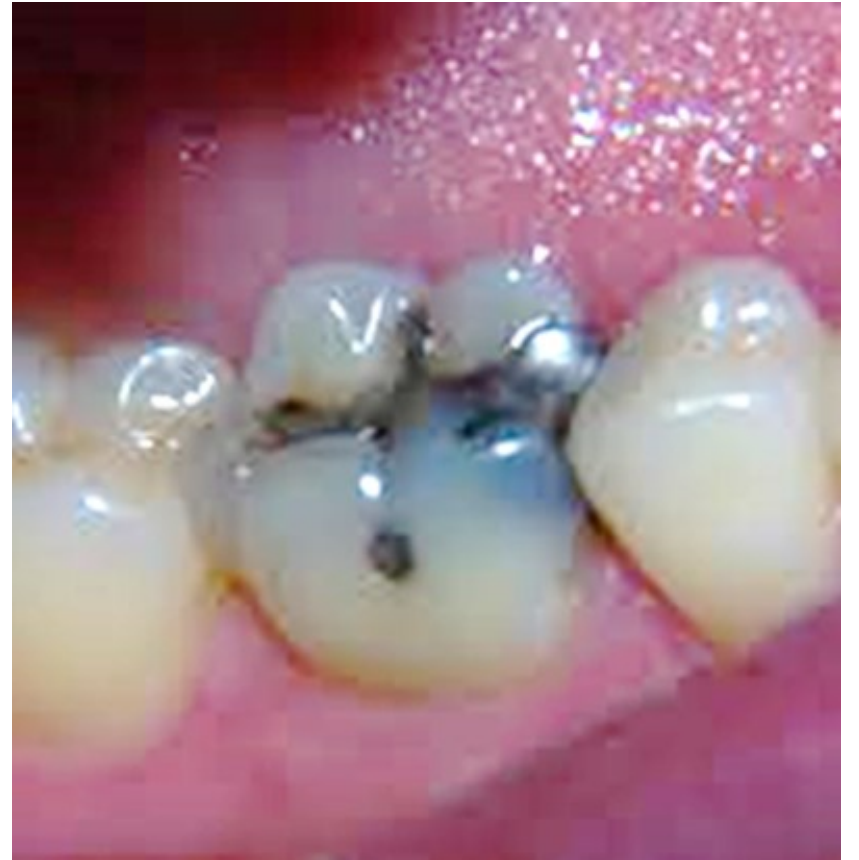# Amalgam blues

---

**Description:** Amalgam blues is a discolored area are often seen through the enamel in the teeth that have amalgam restorations

**Causes:** This bluish hue results either from leaching of corrosion products of amalgam into the dentinal tubules or from the color of underlying amalgam as seen through translucent enamel. The latter occurs when the enamel has no dentin support, such as undermined cusps, marginal ridges and regions adjacent to proximal margins.

**Treatment:** When other aspects of the restoration are sound no further treatment required.



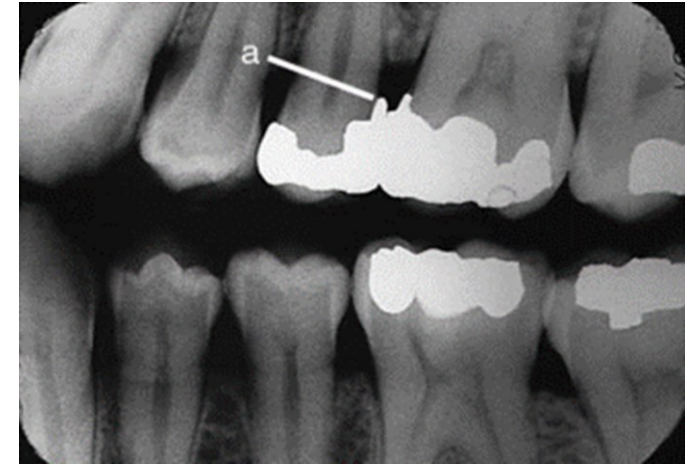
## Proximal overhangs

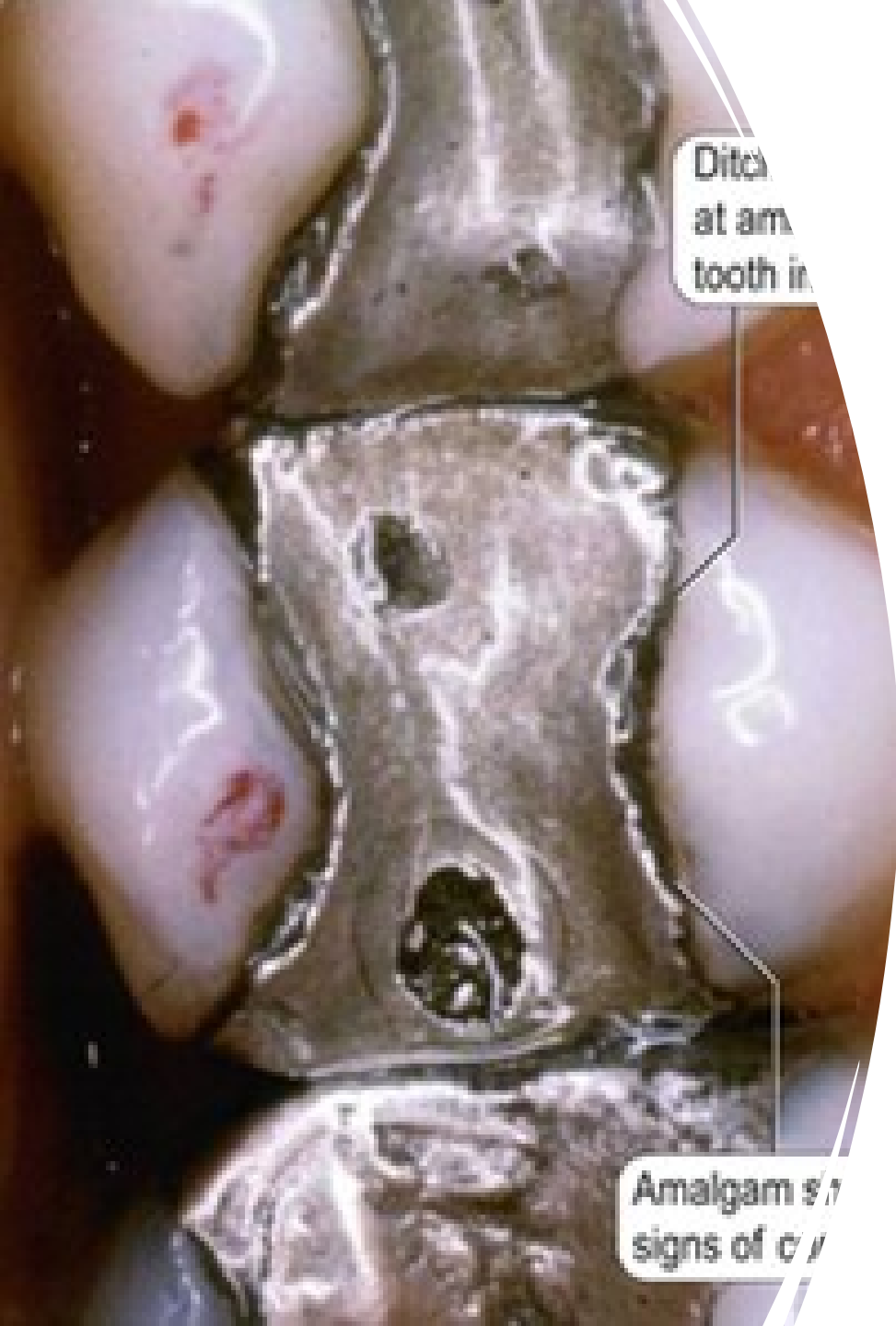
**Description:** An extension of amalgam restorative material beyond the cavity preparation lines

**Diagnosis:** diagnosed visually, tactilely, and radiographically.

1. The amalgam-tooth junction is evaluated by moving the explorer back and forth across it. If the explorer stops at the junction and then moves outwardly onto the amalgam, an overhang is present.
2. Overhangs can be confirmed by the catching or tearing of dental floss. Such an overhang can be a plaque trap and result in inflammation of the adjacent soft tissue.

**Treatment:** If causing problems, an overhang should be corrected, and this often indicates replacement of the defective restoration.





# Marginal gap or ditching

---

**Description:** is the deterioration of the amalgam-tooth interface as a result of wear, fracture, or improper tooth preparation.

**Diagnosis:** It can be diagnosed visually or by the explorer dropping into an opening as it crosses the margin. Shallow ditching less than 0.5 mm deep usually is not a reason for restoration placement.

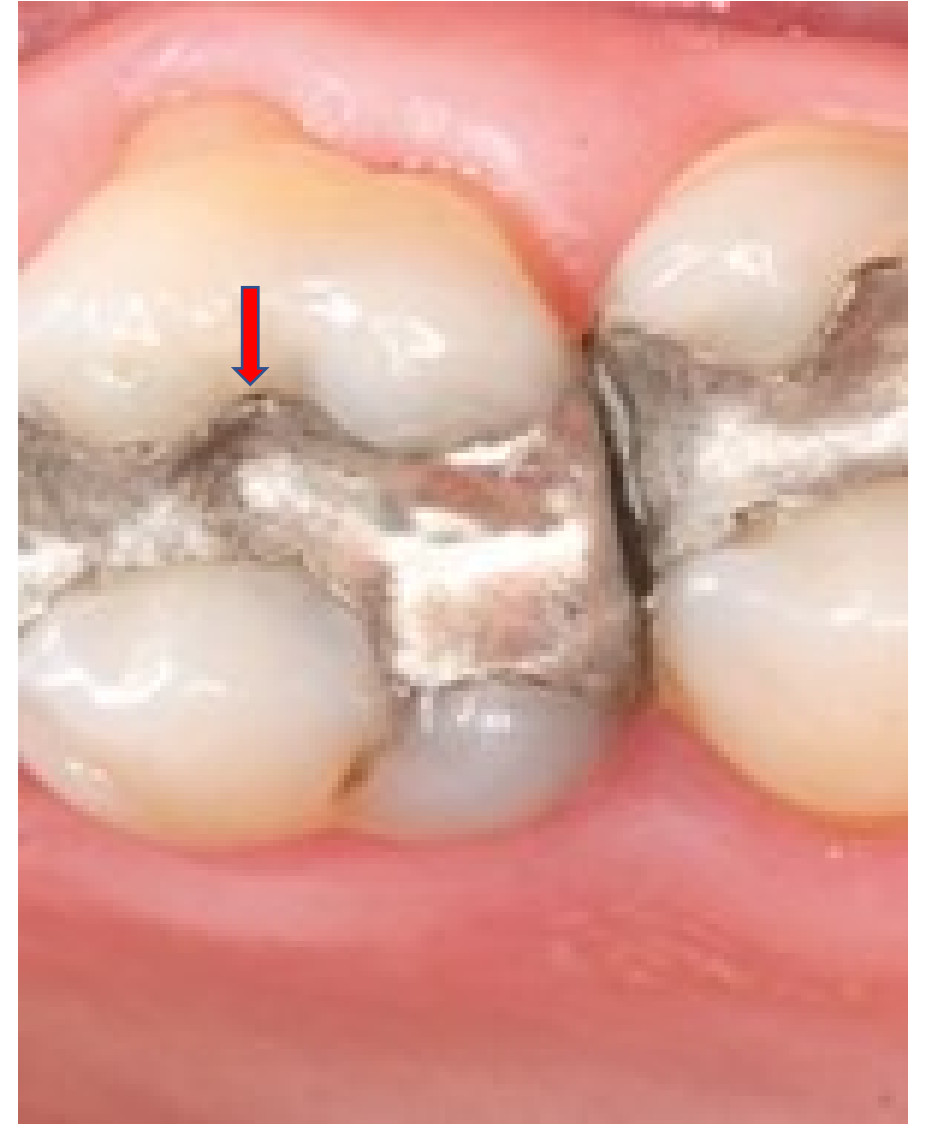**Treatment:** If the ditch is too deep to be cleaned or jeopardizes the integrity of the remaining restoration or tooth structure, the restoration should be replaced. In addition, secondary caries is frequently found around marginal gaps near the gingival wall.

# Voids

**Description:** Voids other than ditching also occurs at the margins of amalgam restoration.

**Diagnosis and treatment:**

1. If the void is at least 0.3 mm deep and located in the gingival third of the tooth crown, then the restoration is judged as defective and should be repaired or replaced.
2. Accessible small voids in other marginal areas where the enamel is thicker may be corrected by re-contouring or repairing with a small restoration.

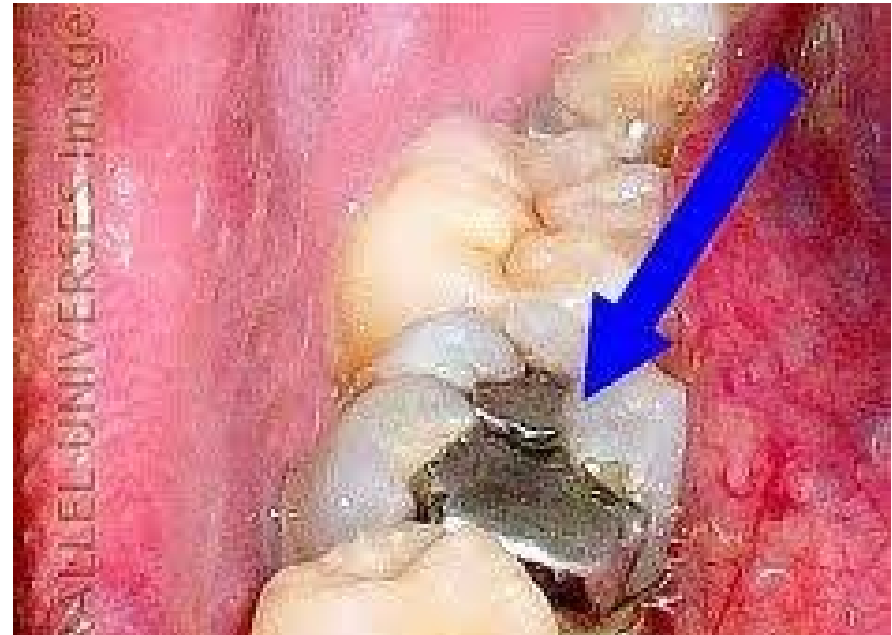

# Fracture lines

**Description:** separation of an amalgam restoration into two or more fragments manifested as crack lines on the amalgam surface

**Diagnosis:** A careful clinical examination will detect any fracture line across the occlusal portion of an amalgam restoration or in the isthmus region.

**Treatment:** Generally, a fractured amalgam is a defective restoration that needs replacing.



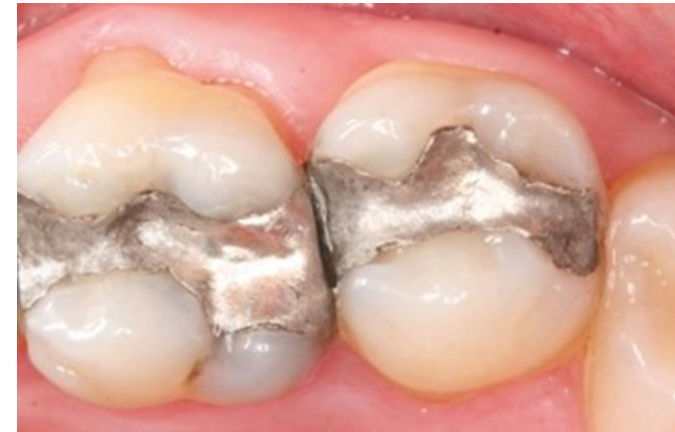
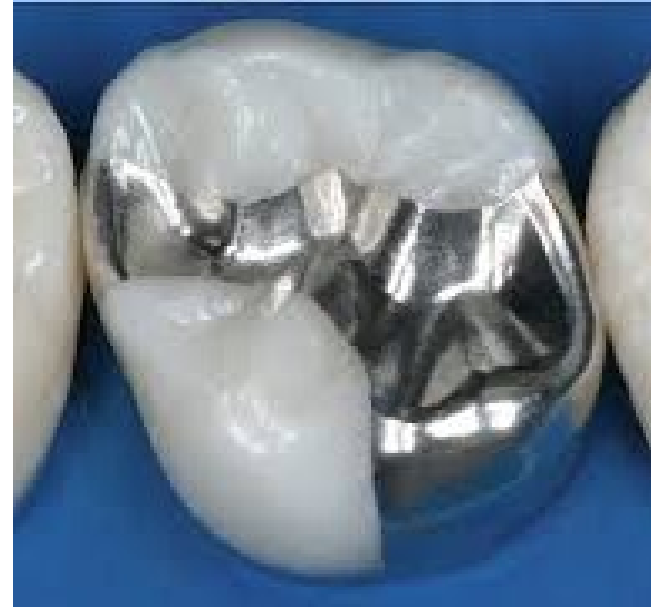
# Improper anatomic contours

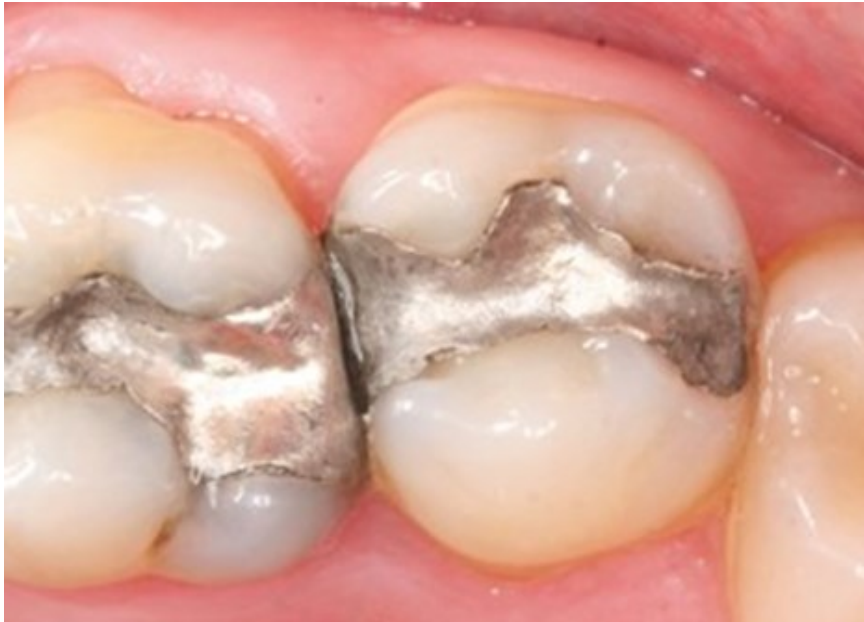---

Amalgam restoration should duplicate the normal anatomic contours of the teeth.

**Treatment:** Restorations that have inadequate embrasure form or proximal contact, should be classified as defective, indicating re-contouring or replacement.



# Marginal ridge incompatibility

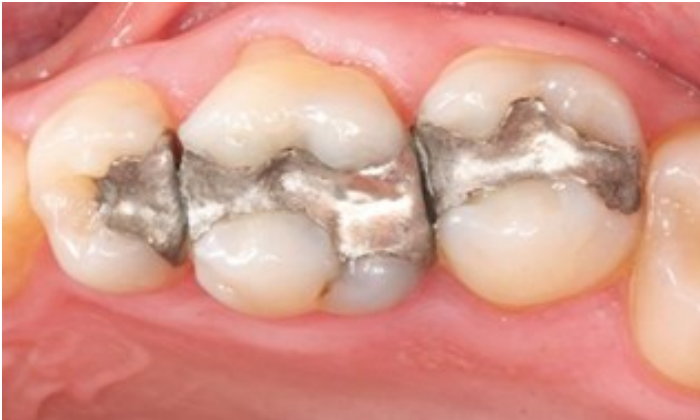

**Description:** The marginal ridge portion of the amalgam restoration should be compatible with adjacent marginal ridge.

**Diagnosis:** Both marginal ridge should be approximately the same level and display correct occlusal embrasure form for passage of food to the facial and lingual surfaces and for proper proximal contact area.

**Treatment:** If marginal ridge is not compatible, the restoration is defective and should be re-contoured and replaced.

## Improper proximal contact



**Description:** The proximal contact area of an amalgam restoration should touch the adjacent tooth at the proper contact level and with correct embrasure form.

**Diagnosis:** If the proximal contact of any restoration is suspected to be inadequate, it should be evaluated with dental floss and/or visually by trial angulation of mouth mirror) held lingually when viewing the facial aspect) to reflect light and actually see if there is a space at the contact (“open” contact).

**Treatment:** If the contact is “open” and is associated with poor interproximal tissue health and/or food impaction, the restoration should be replaced.

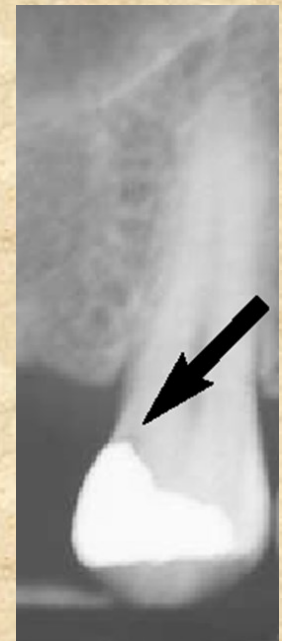
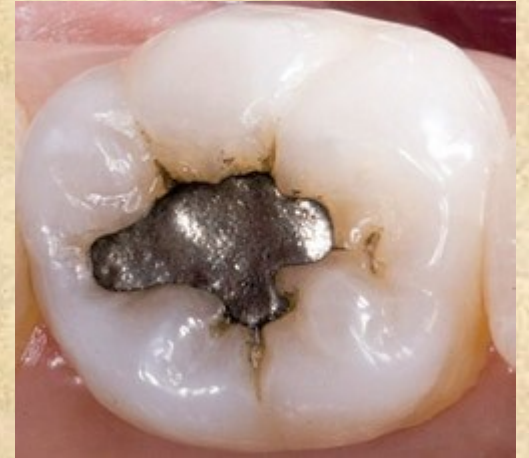**Inadequate occlusal contacts on an amalgam restoration may cause improper occlusal functioning and/or undesirable tooth movement. Such condition warrants correction or replacement**

## Recurrent caries

**Description:** one of the most causes of amalgam failure and replacement

**Diagnosis:** Recurrent caries at the marginal area of the restoration is detected visually, tactilely, or radiographically.

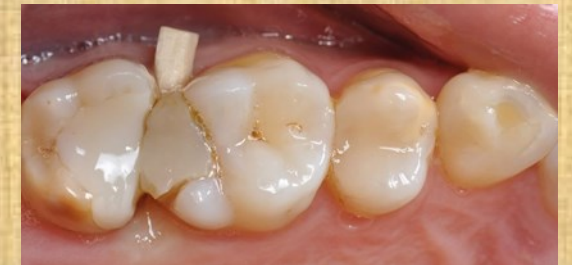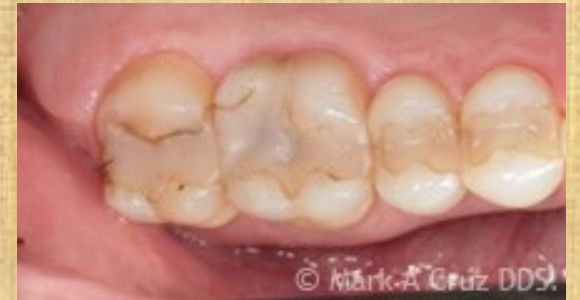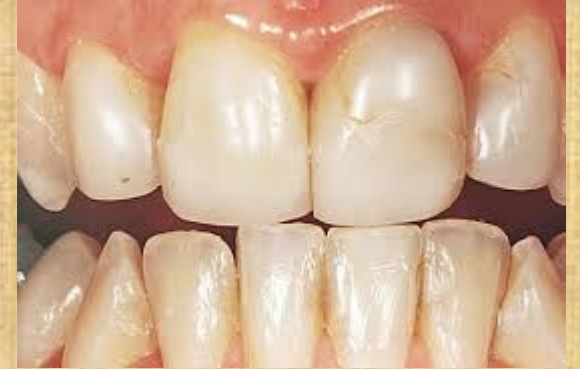**Treatment:** Is indication for repair or replacement.



## Failure in composite restoration

Tooth colored restorations should be evaluated clinically in the same manner as amalgam and cast restorations. If there is an improper contour or proximal contact, overhanging, recurrent caries or other condition that impairs cleaning, the restoration is considered defective. Corrective procedures include re-contouring, polishing, repairing, or replacing.

**One of the main concerns with anterior teeth is aesthetics.**



## Failure of composite restoration

### Factors to be considered

- Composite restorations are more susceptible to secondary caries than amalgam restorations, therefore special care should be taken for patient with high risk of dental caries
- Large restorations have less survival rate than small restorations
- The anterior restorations have lower survival rate than posterior restorations

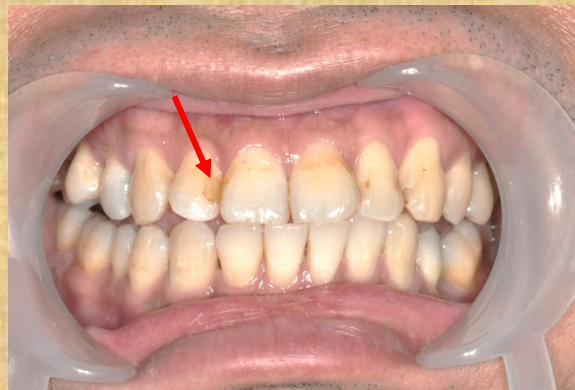
## Causes of failure of composite restoration

1. Surface staining
2. Marginal staining
3. Translucency and color stability
4. Fracture
5. Adhesive failure: Retention, marginal adaptation
6. post-operative sensitivity: pain after placement of composite restoration
7. Tooth vitality

## Surface staining (brown discoloration):

### Causes and treatment:

1. Operator related: the dentist did not perform proper finishing and polishing to the composite restoration. Such a case is treated with re-polishing of the composite using proper procedures and instruments.
2. Material related: the composite restoration has large size filler particles which are difficult to be finished to a smooth surface. Replacement of the filling with a microfine type composite is the treatment of choice.
3. Patient related: patients who smoke and drink coffee very frequently without maintaining good oral hygiene. The treatment of choice is polishing of the restoration surface and reassurance of the patient to maintain good oral hygiene.



Surface staining

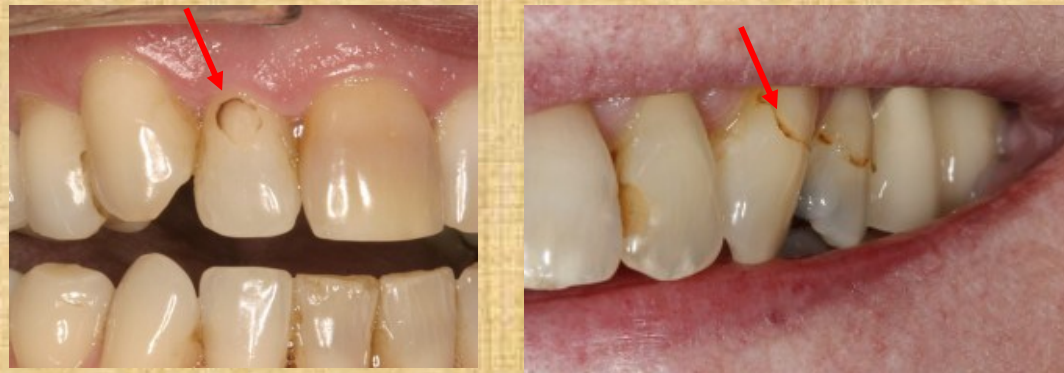

## Marginal staining:

It is a brown discoloration at the tooth/filling margin. It could be partial staining or complete including the whole margin. It can be diagnosed visually and differentiated from secondary caries using a sharp dental explorer. Secondary caries always reveals cavitation at the margin that catches the tip of the explorer.

**Causes:** Adhesive failure at the margin or overhanging filling.

**Treatment:** Partial staining can be corrected locally, however, complete marginal staining requires the complete replacement of the composite restoration.

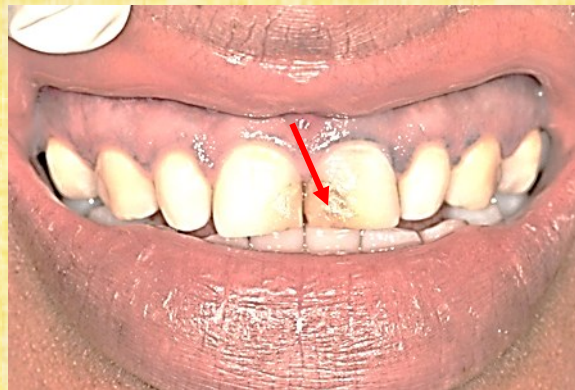


Marginal staining

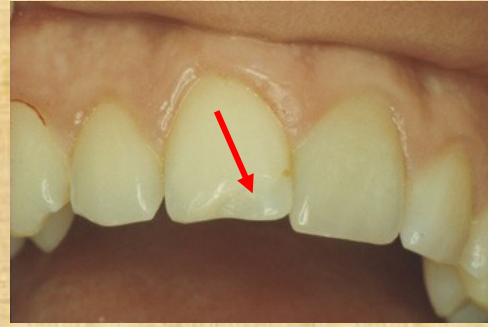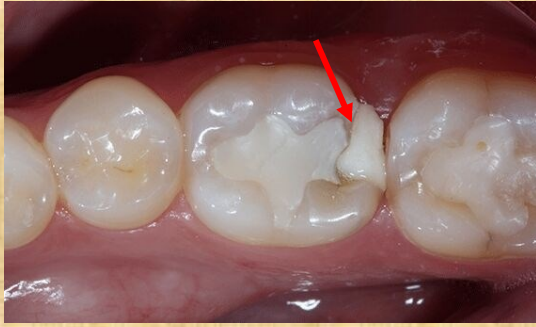## Changing in translucency and color stability of a composite restoration

It is a reddish-brown discoloration including the whole bulk of a composite restoration.

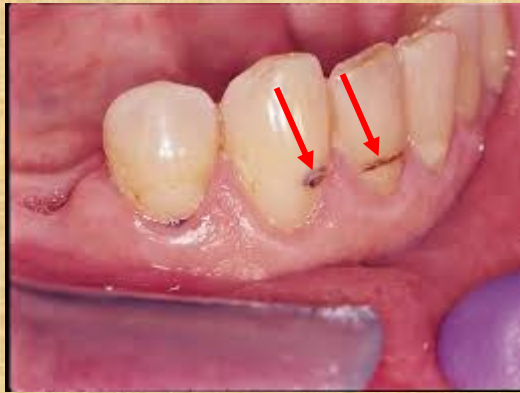**Causes:** Accumulative exposure to ultraviolet light especially in the aged composite restoration.



Translucency and color stability

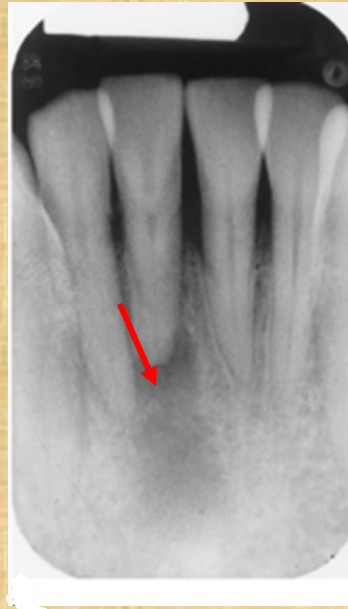

Fracture or chipping of composite restoration



Secondary caries

Tooth vitality



**Thank you**