

CROWN AND BRIDGE

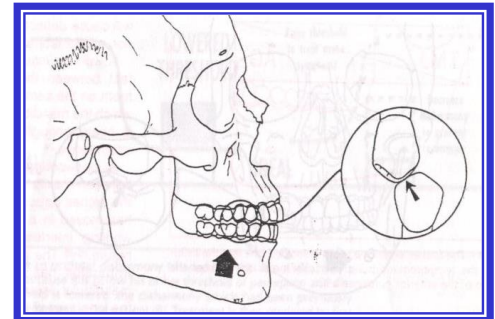
OCCLUSAL INTERFERENCES

Interferences are undesirable occlusal contacts that may produce mandibular deviation during closure to maximum intercuspation or may hinder smooth passage to and from the intercuspal position.

TYPES OF OCCLUSAL INTERFERENCES

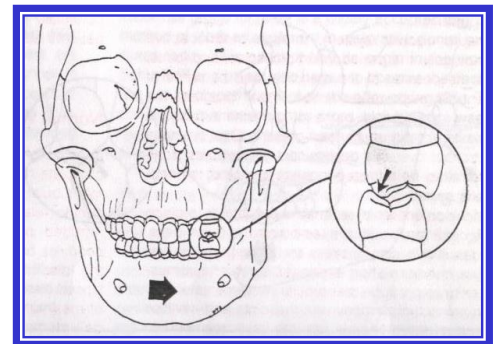
1- CENTRIC INTERFERENCE

It's a premature contact that occurs when the mandible closes with the condyles in their optimum position in the glenoid fossae. It will cause deflection of the mandible in a posterior, anterior, and/or lateral direction.



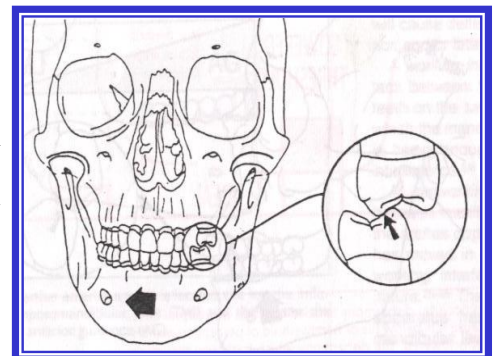
2- WORKING INTERFERENCE

Occur when there is contact between the maxillary and mandibular posterior teeth on the same side of the arches as the direction in which the mandible has moved. If that contact is heavy enough to disocclude anterior teeth, it is interference.



3- NONWORKING INTERFERENCE

Occlusal contact between maxillary and mandibular teeth on the side of the arches opposite the direction in which the



mandible has moved in a lateral excursion. The nonworking interference is of destructive nature because: -

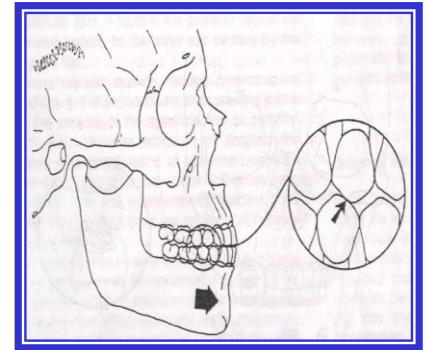
- Placement of forces outside the long axes of the teeth.
- Disruption of normal muscle function.

4- PROTRUSIVE INTERFERENCE

Premature contact occurring between the mesial aspects of mandibular posterior teeth and the distal aspects of maxillary posterior teeth, it is destructive because: -

- The proximity of the teeth to the muscles.
- The oblique vector of the forces.

Usually interfere with the patient's ability to incise properly.



OPTIMUM OCCLUSION

In the placement of restorations, the dentist must strive to produce for the patient an occlusion that is as nearly optimum as his or her skills and the patient's oral condition will permit. The optimum occlusion is one that requires a minimum of adaptation by the patient.

Criteria of optimum occlusion: -

- ◆ In closure, the condyles are in the most superoanterior position against the discs on the posterior slopes of the eminences of the glenoid fossae. The posterior teeth are in solid and even contact, and the anterior teeth are in slightly lighter contact.
- ◆ Occlusal forces are in the long axes of the teeth (Tips of the centric cusps are located centrally over the roots and when loading of the teeth occurs in the fossae of the occlusal surfaces rather than on the marginal ridges).

- ◆ In lateral excursions of the mandible, working-side contacts (preferably on the canines) disocclude or separate the nonworking teeth instantly (Horizontal forces are minimized if posterior tooth contact during excursive movements is avoided).
- ◆ In protrusive excursions, anterior tooth contacts will disocclude the posterior teeth.
- ◆ In an upright posture, posterior teeth contact more heavily than do anterior teeth.

Static Occlusion: Classified into four types:

1- Surface -to-Surface contact. It is also referring to as “mashed potato occlusion”.

It is stressful, Produces lateral interferences in any function. Never used.

2- Tripod contact. In tripod contact the tip of the cusp never touches the opposing tooth. no advantages over proper cusp tip-to-fossa contact.

- ✓ difficult to achieve.
- ✓ hard to adjust. limited in its use.

3- Cusp-Ridge contact. It’s also called a “tooth-to-two-teeth” occlusion.
“cusp-embrasure” occlusal pattern

4- Cusp tip-to-fossa contact. Also called “tooth-to-one-tooth”

Cusp tip-to-fossa contact offers:

- ✓ excellent function.
- ✓ stability with flexibility.
- ✓ resistance to wear.

Advantages of Cusp-Fossa over Cusp-Marginal Ridge Pattern of occlusion:

- 1-Produces an interlocking of the upper and lower teeth, thus giving maximum support in centric occlusion.
- 2-The forces are closer to the long axis of each tooth, giving a more efficient chewing apparatus and less tipping.
- 3- There is elimination of food impaction between marginal ridges.
- 4- The teeth are more stable, with more stable occlusion, and lesser wear of the cusp tips.

ORGANIZATION OF THE OCCLUSION

☉ There are three recognized concepts that describe the manner in which teeth should and should not contact in the various functional and excursive positions of the mandible they are: -

- ▣ **Bilateral Balanced Occlusion.**
- ▣ **Unilateral Balanced Occlusion.**
- ▣ **Mutually Protected Occlusion.**

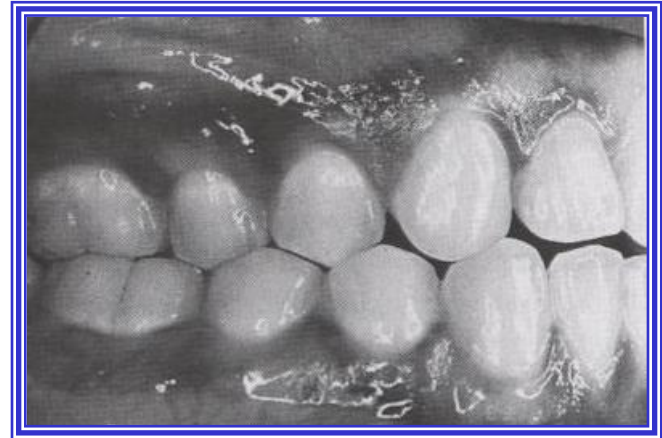Bilateral Balanced Occlusion

- It dictates that a maximum number of teeth should contact in maximum intercuspation and all excursive positions.
- Old concept.

■ Usefull in complete denture construction, in which contact on the nonworking side is important to prevent tipping of the denture.

■ If applied to natural dentition and in fixed prosthodontics, it will result in high rates of failure due to: -

- ✗ An increased rate of occlusal wear.
- ✗ Accelerated periodontal breakdown.
- ✗ Neuromuscular disturbances.



Unilateral Balanced Occlusion (GROUP FUNCTION)

✚ Teeth are contoured so that excursive contact occurs between all opposing posterior teeth on the working side only. On the nonworking side, no contact occurs until the mandible has reached centric relation.

✚ The absence of contact on the nonworking side prevents those teeth from being subjected to the destructive, obliquely directed force found in nonworking interference.

✚ It saves the centric cusps from excessive wear.

✚ The obvious advantage is the maintenance of the occlusion.

This concept is characterized by:

- 1- Applying the theory of Long Centric.
- 2-All working side teeth share lateral forces during lateral movements.
- 3-Nonworking side teeth are free from contacts during lateral movements.

Long Centric:

Long centric or “Freedom in Centric” is an occlusal concept, in which a flat region is built between the retruded position (CR) and the maximum intercuspation (MIC), without a change in the vertical dimension.

This flat region, having a length of 0.5-1mm, gives the mandible freedom to close in Centric or slightly anterior to it without any interference.

Cases that need Freedom in Centric:

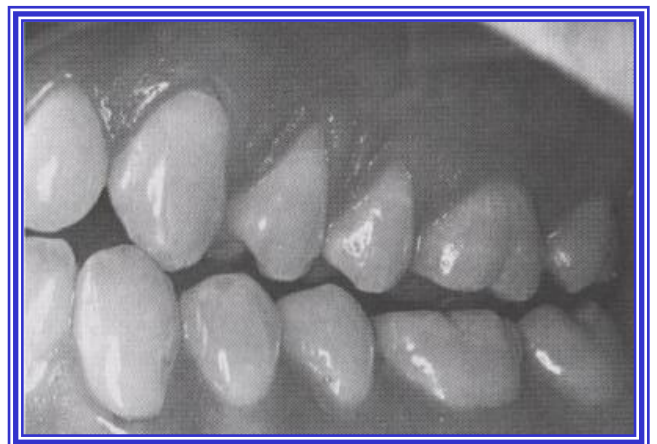When teeth are in the way if the patients close normally, but are fine when the mandible is pushed to the back.

When teeth are fine when lying down, but are in the way while sitting upright.

If a patient needs long centric and does not get it, bruxism and clenching could happen.

Mutually Protected Occlusion CANINE PROTECTED OCCLUSION (ORGANIC OCCLUSION)

They observed that in many mouths with a healthy periodontium and minimum wear, the teeth were arranged so that the overlap of the anterior teeth prevented the posterior teeth from making any contact on either the working or the nonworking sides during mandibular excursions. This separation from occlusion was termed disocclusion.



This arrangement is the most widely accepted because of its ease of fabrication and greater tolerance by patients.

✘ The anterior teeth bear an entire load and the posterior teeth are disocclude in any excursive position of the mandible. The desired result is an absence of frictional wear.

✘ **In Maximum Intercuspation: -**

✘ All posterior teeth are in contact with the forces being directed along their long axes.
✘ The anterior teeth either contact lightly or are very slightly out of contact (25 microns), relieving them of the obliquely directed forces that would be the result of anterior teeth contact.

✘ As a result of the anterior teeth protecting the posterior teeth in all mandibular excursions and the posterior teeth protecting the anterior teeth at the intercuspal position.

✘ To reconstruct a mouth with a mutually protected occlusion, the anterior teeth should be periodontally healthy. In the presence of anterior bone loss or missing canines, the mouth should probably be restored to group function (unilateral balance).

✘ Contraindicated in either a class II or a class III malocclusion (angle classification), because the mandible can not be guided by the anterior teeth.

✘ Contraindicated in reverse occlusion, or cross bite, in which the maxillary and mandibular buccal cusps interfere with each other in a working-side excursion.

THE END