

Orthodontics

Lecture One

Orthodontic

Ortho = correct

Dontic = tooth

Orthodontics

Orthodontics is that branch of dentistry concerned with facial growth, with development of the dentition and occlusion, and with the diagnosis, interception, and treatment of occlusal anomalies.

Orthodontics

According to British society of orthodontics (1922)

“Orthodontics: includes the study of growth & development of the jaws & face particularly, & the body generally as influencing the position of the teeth; the study of action & reaction of internal & external influences on the development & the prevention & correction of arrested & perverted development.

According to American Board of orthodontics “Orthodontics is that specific area of dental practice that has as its responsibility the study and supervision of the growth and the development of the dentition and its related anatomical structures from birth to dental maturity, including all preventive and corrective procedures of dental irregularities requiring the repositioning of teeth by functional or mechanical means to establish normal occlusion and pleasing facial contours”.

Orthodontics

In 1911 Noyes defined orthodontics as “The study of the relation of the teeth to the development of the face and correction of arrested and perverted development”.

In 1907 Angle stated that the objective of the science of orthodontics is “The correction of malocclusion of the teeth”.

Definitions of certain orthodontic terms

Occlusion and malocclusion

Normal Occlusion

of



**Permanent
Dentition**

Normal Occlusion

Types of dentition



```
graph TD; A[Types of dentition] --> B[Primary dentition]; A --> C[Mixed dentition]; A --> D[Permanent Dentition];
```

**Primary
dentition**

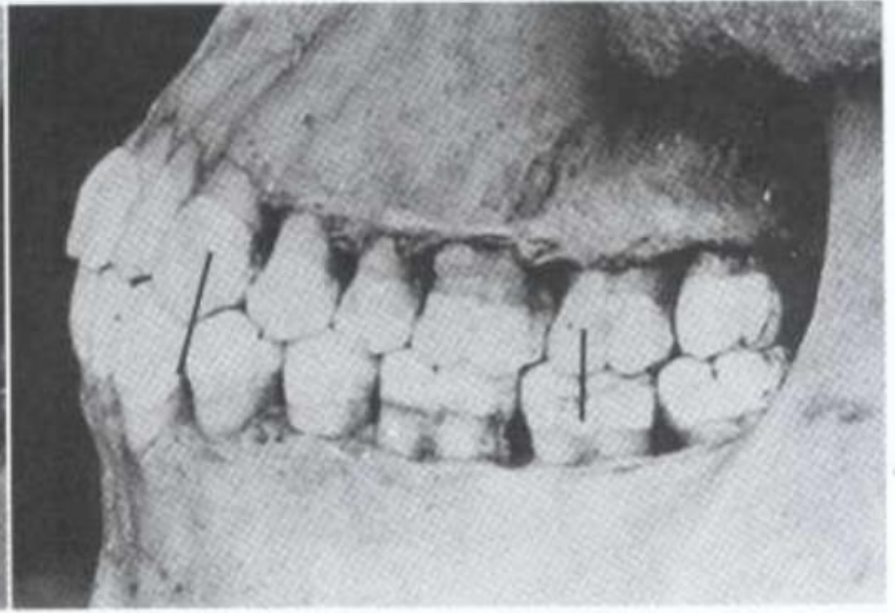
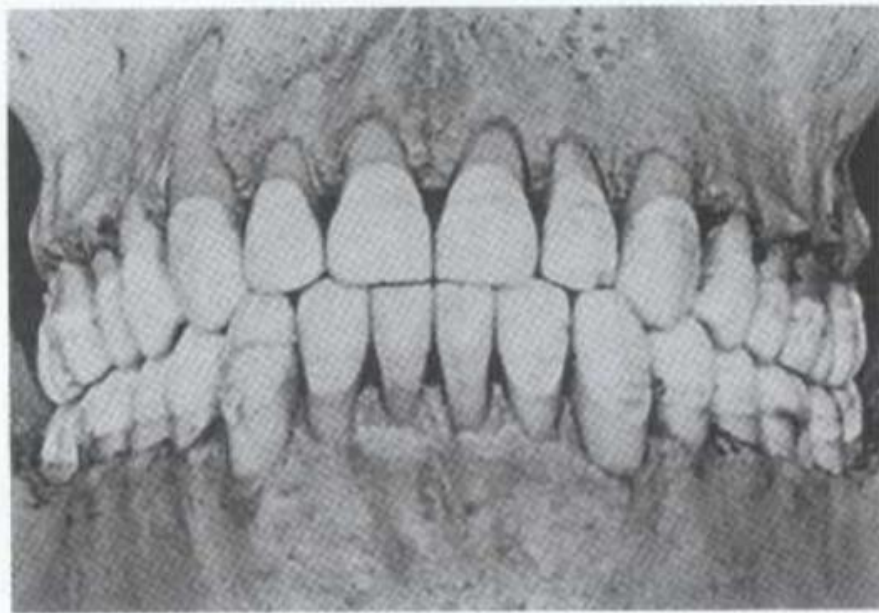**Mixed
dentition**

**Permanent
Dentition**

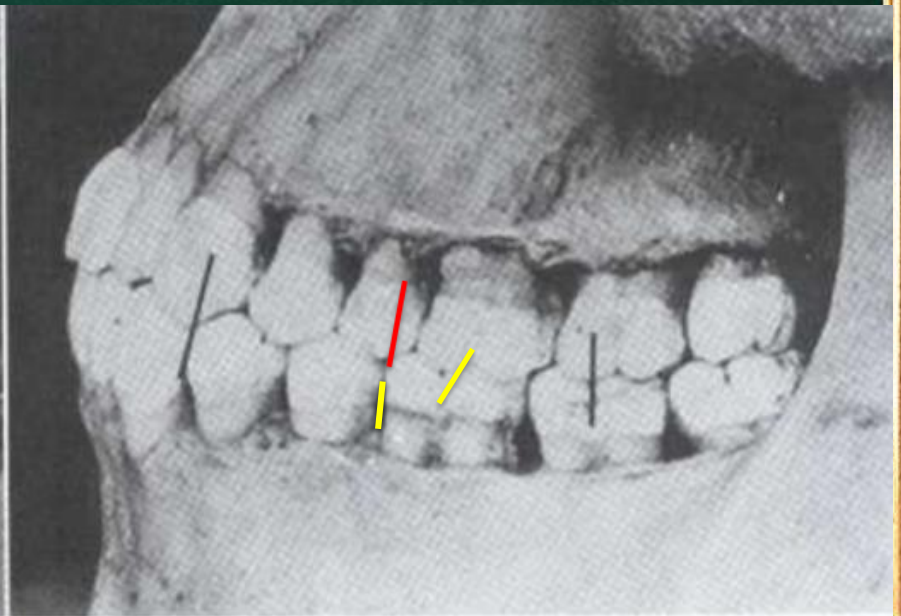
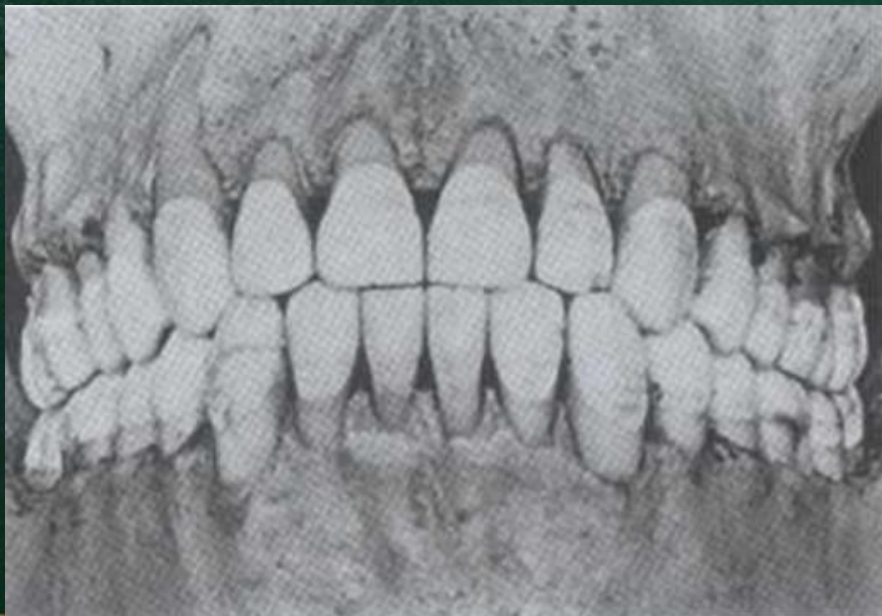Normal Occlusion

Andrews' six keys to normal occlusion

I. Molar interarch relationship



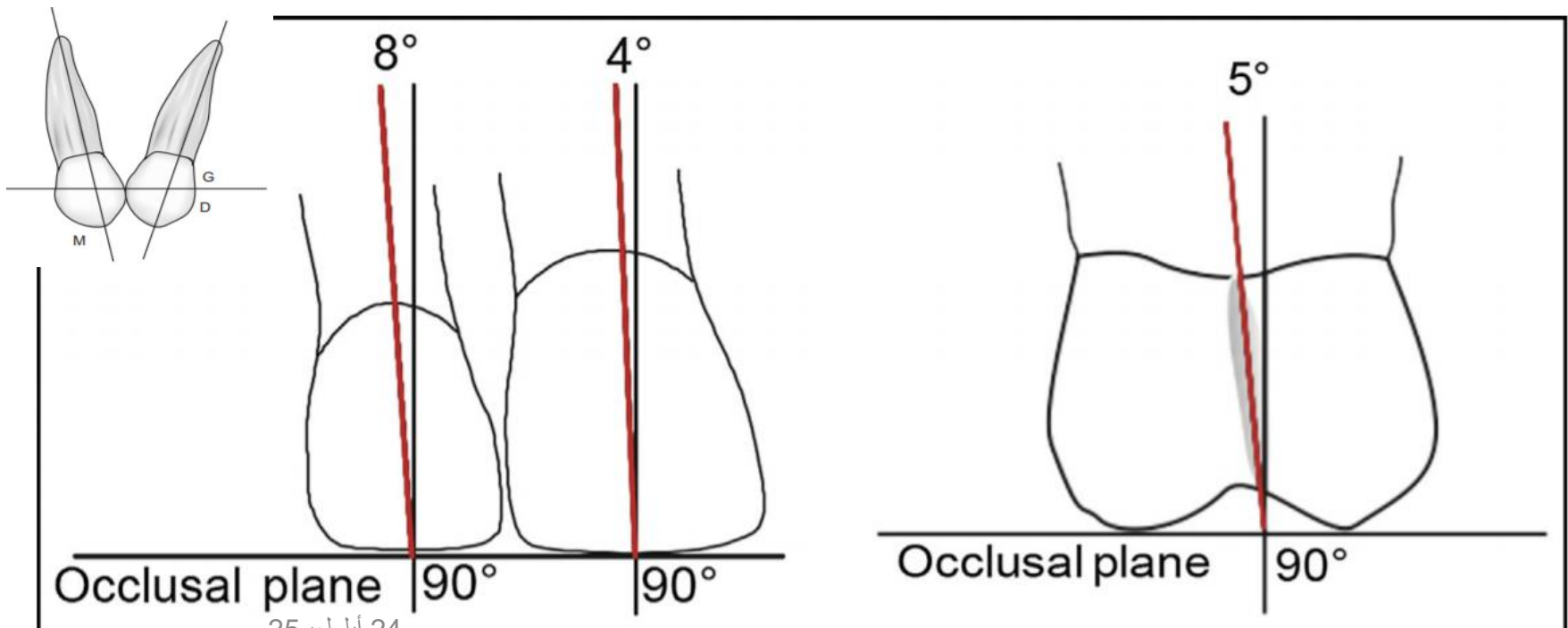
1. Mesio Buccal cusp of maxillary first molar rests in the mesio Buccal groove of mandibular first molar.
2. Distal surface of the disto Buccal cusp of maxillary first molar should occlude with mesial surface of the mesio Buccal cusp of mandibular second molar.
3. Mesio lingual cusp of the maxillary first molar should occlude in the central fossa of mandibular first molar.



Andrews' six keys

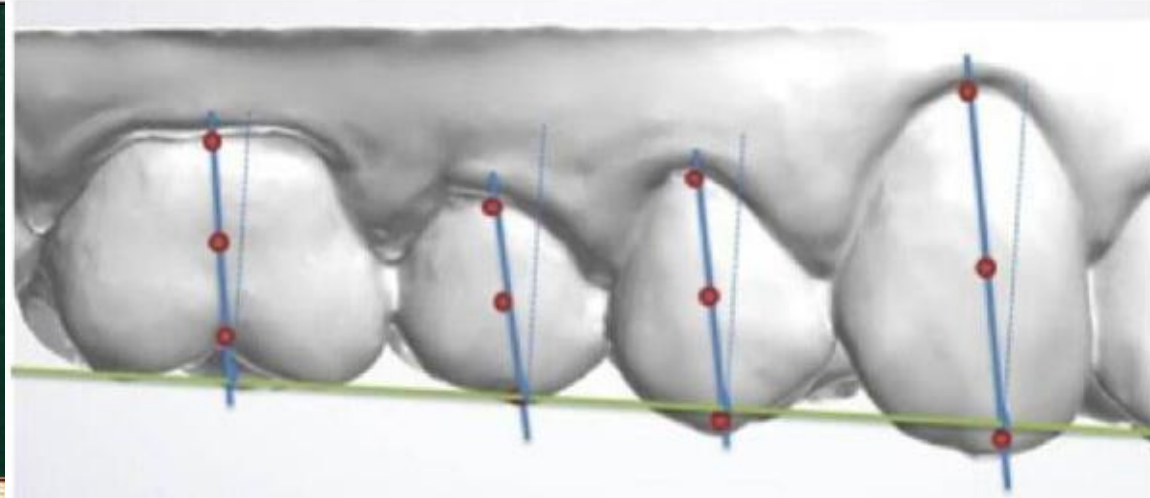
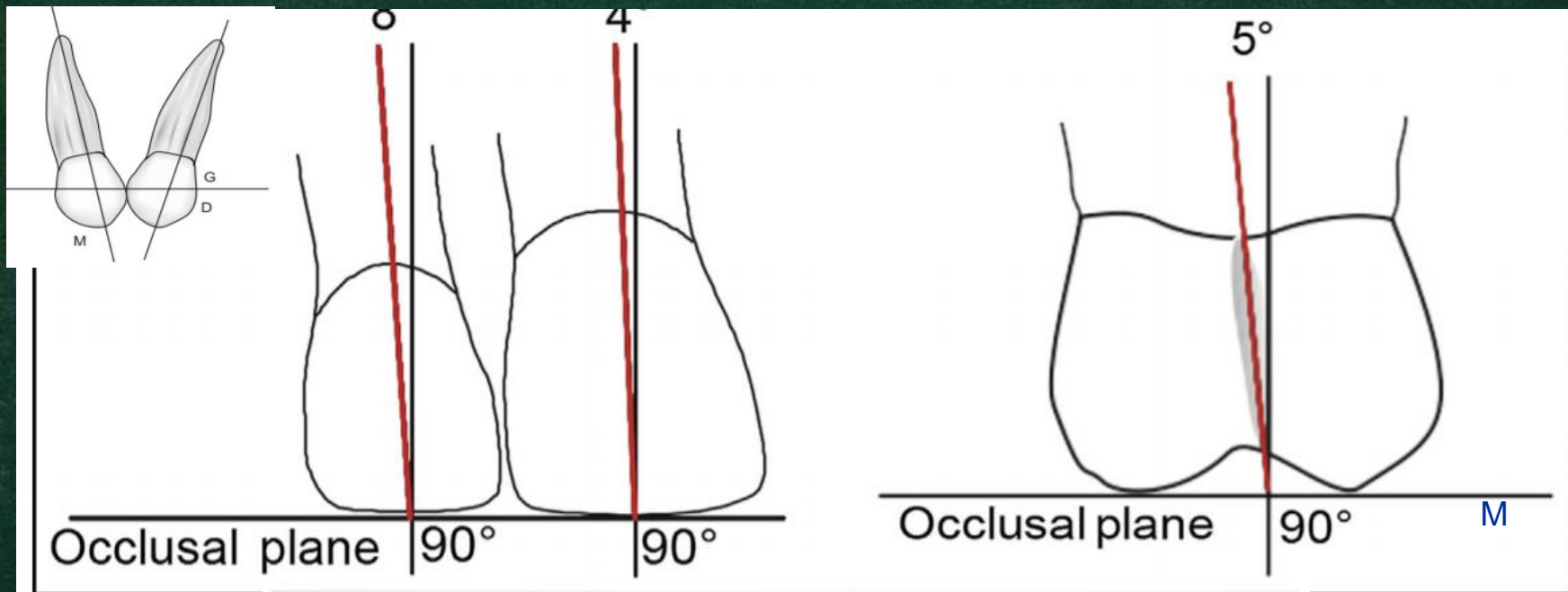
II. Mesiodistal crown angulation (tip)

Crown angulations (tip) The gingival portion of the long axis of each crown should be distal to the incisal portion, this is known as crown angulation.




Andrews' six keys

II. Mesiodistal crown angulation (tip)



Andrews' six keys

II. Mesiodistal crown angulation (tip)

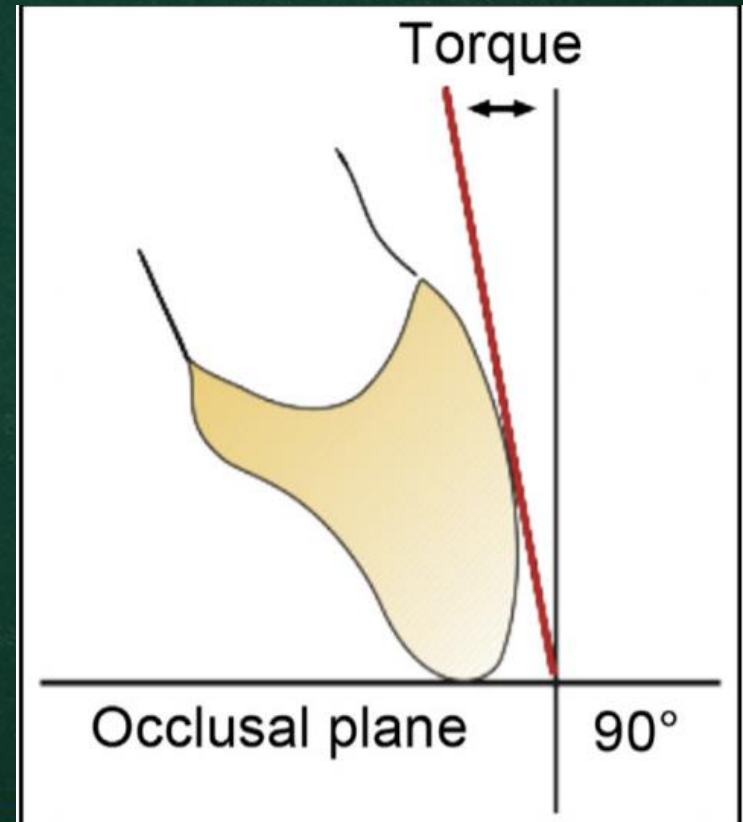


Andrews' six keys

III. Labiolingual crown inclination

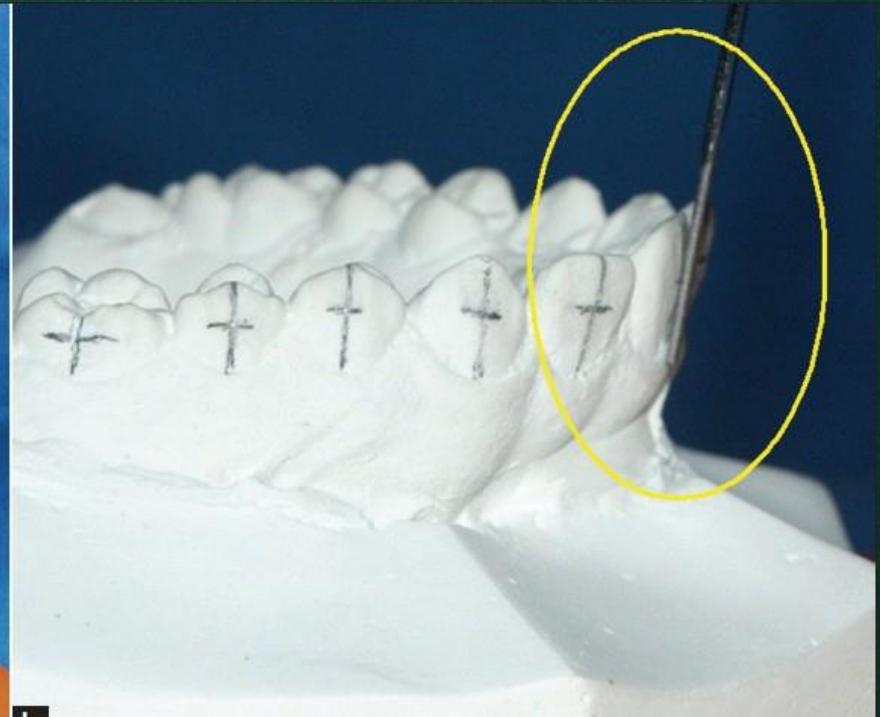

Crown inclination (torque): The buccolingual inclination of the long axis of the crown and not the long axis of the entire tooth is known as crown inclination.

Negative crown inclination or lingual crown inclination occurs in the maxillary and mandibular posteriors, whereas positive or labial inclination is seen in maxillary incisors.



Andrews' six keys

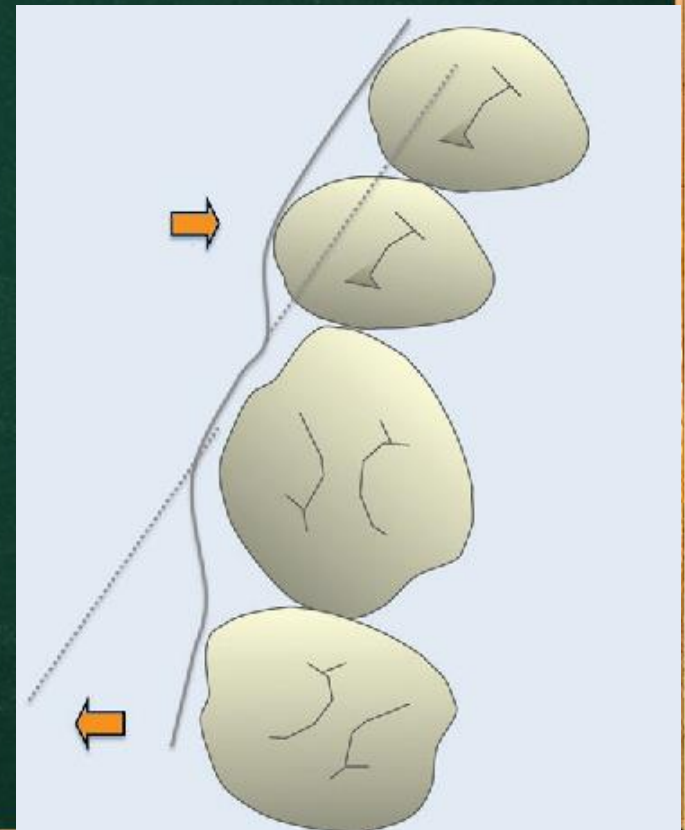
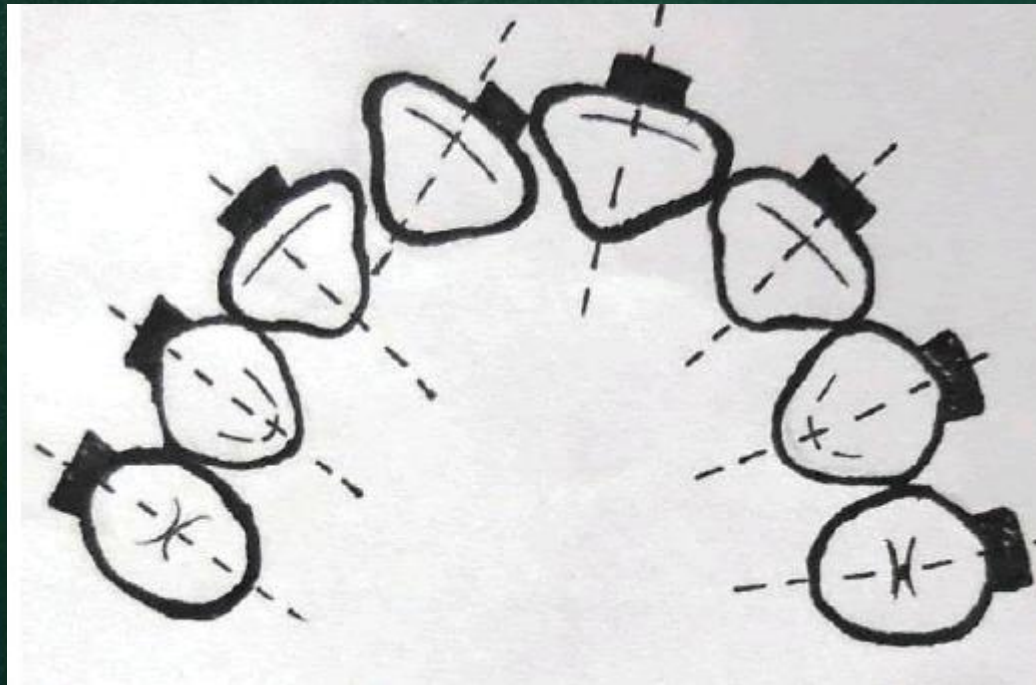
III. Labiolingual crown inclination



Andrews' six keys

IV. Absence of rotation

- Arch should be devoid of any rotated tooth.

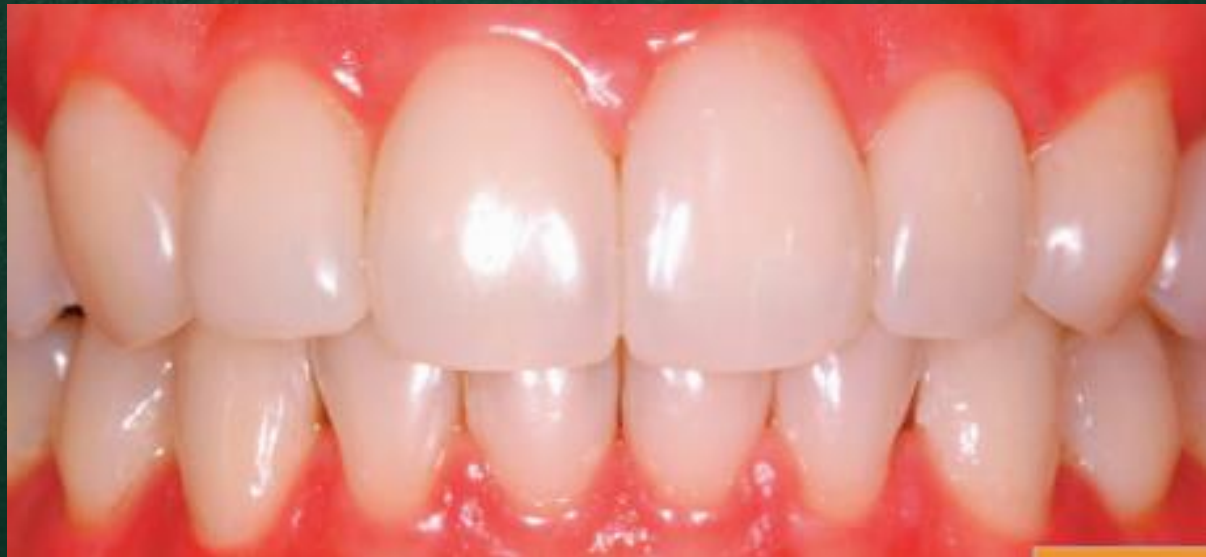

Andrews' six keys

V. Tight contacts

Interproximal contact:

Proximal contacts should be **tight and no spacing** should be present.

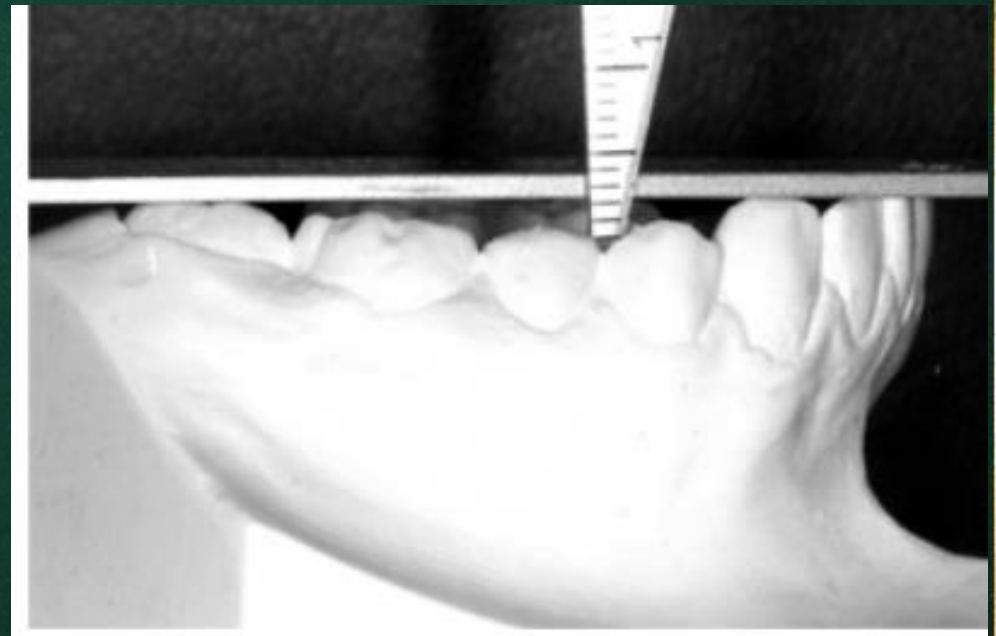


Andrews' six keys

VI. Curve of Spee (occlusal plane): imaginary plane on which the teeth meet in occlusion

The anteroposterior curvature in the mandibular arch is called the **curve of Spee**.

According to Andrews a normal occlusion plane should be **flat**, with the **curve of Spee not exceeding 1.5 mm**.

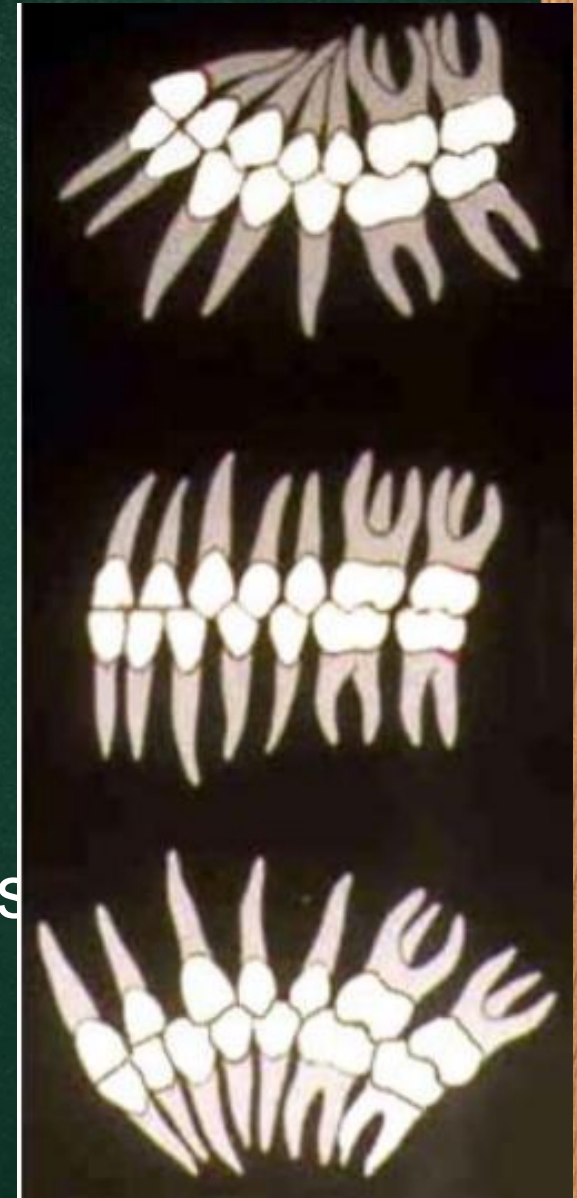


Curve of spee depth figure Morales, F. J. U. (2007)

Deep curve of Spee results in confined room for maxillary teeth **crowding**.

Flat curve of Spee is most receptive for **normal occlusion**.

Reverse curve of Spee results excessive space for maxillary teeth **spacing**.



Normal occlusion

Angle's concept

Angle's concept of normal occlusion is based on:

- I. key of occlusion and
- II. line of occlusion.

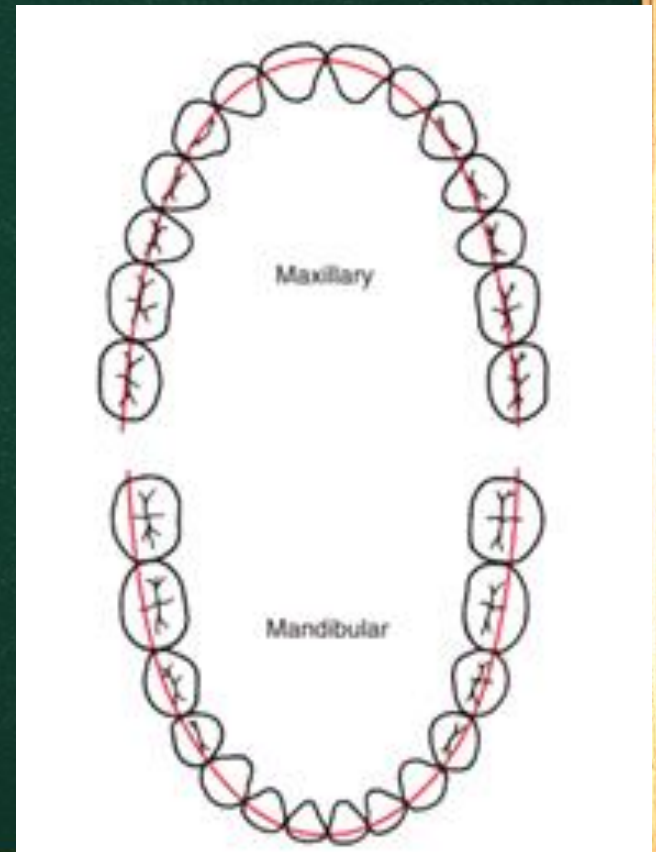


Edward H. Angle in his 50s,
as the proprietor of the
Angle School of Orthodontia

line of occlusion.

The line of occlusion is a smooth curve passing through the central fossa of each upper molar and across the cingulum of the upper canine and incisor teeth. The same line runs along the buccal cusps and incisal edges of the lower teeth, thus specifying the occlusal as well as interarch relationships once the molar position is established.

According to Angle, in normal occlusion **full complement of teeth** should be present. **Lines of occlusion are intact** in both maxillary and mandibular arches, and **molars in class I relation**.



malocclusion

Occlusion: Any position or relationship in which the upper and the lower teeth come together.

Ideal Occlusion: A theoretical concept of an ideal arrangement of the teeth within the dental arches, combined with an ideal inter-arch relationship, which concentrates optimal esthetic, function, and stability of the dentition and supporting structures. But it is almost never found in nature.

Normal occlusion: That occlusion which satisfies the requirements of function and esthetic but in which there are minor irregularities of individual teeth.

malocclusion

Any deviation from normal occlusion

in which

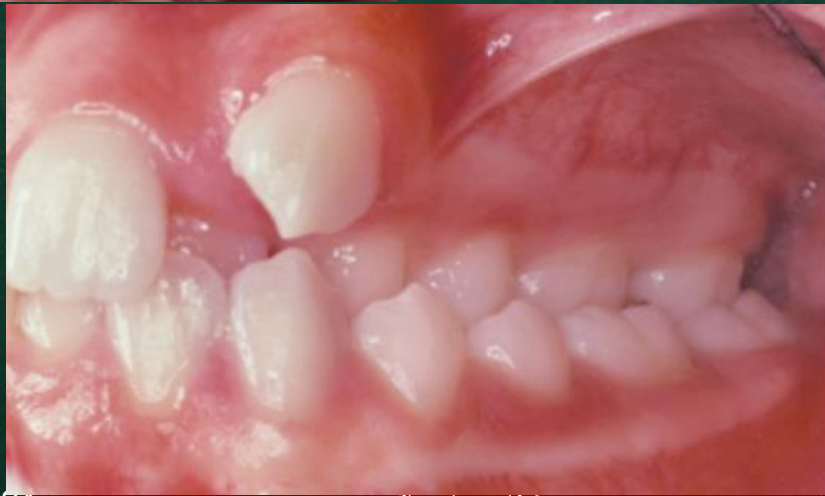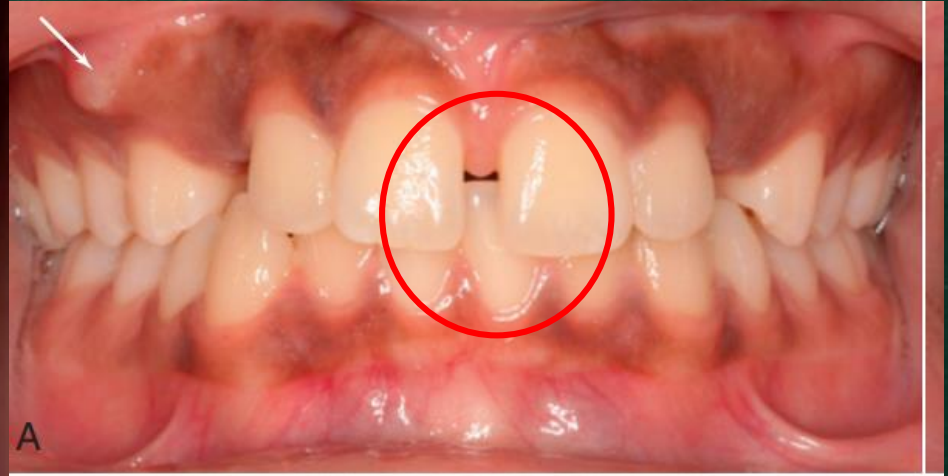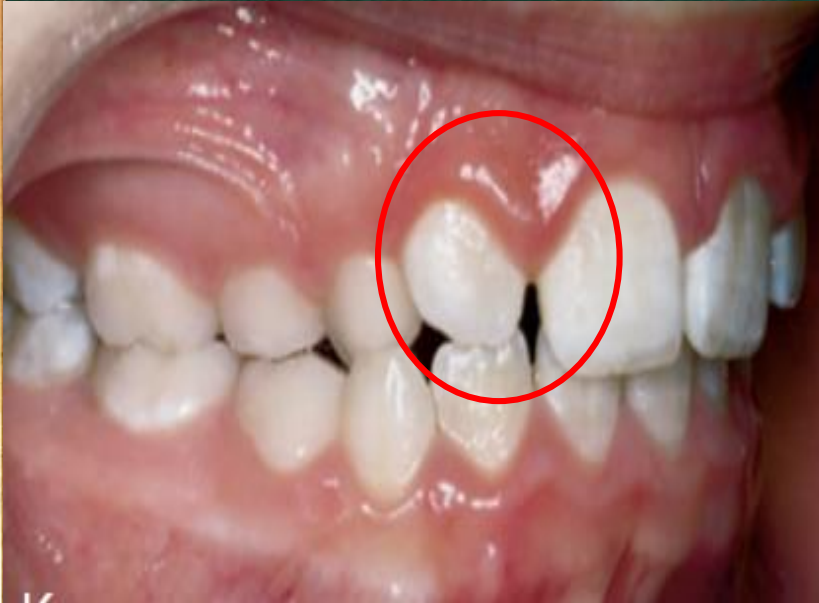1. Teeth are not in a normal position in relation to adjacent teeth in the same jaw and/or the opposing teeth when the jaws are closed'.
2. Abnormal relations between dental arch.
3. Abnormal skeletal morphology and/or relations which result in abnormal occlusion.

Davies, 2007

Ass. prof. Munad Jihad AL Duliamy

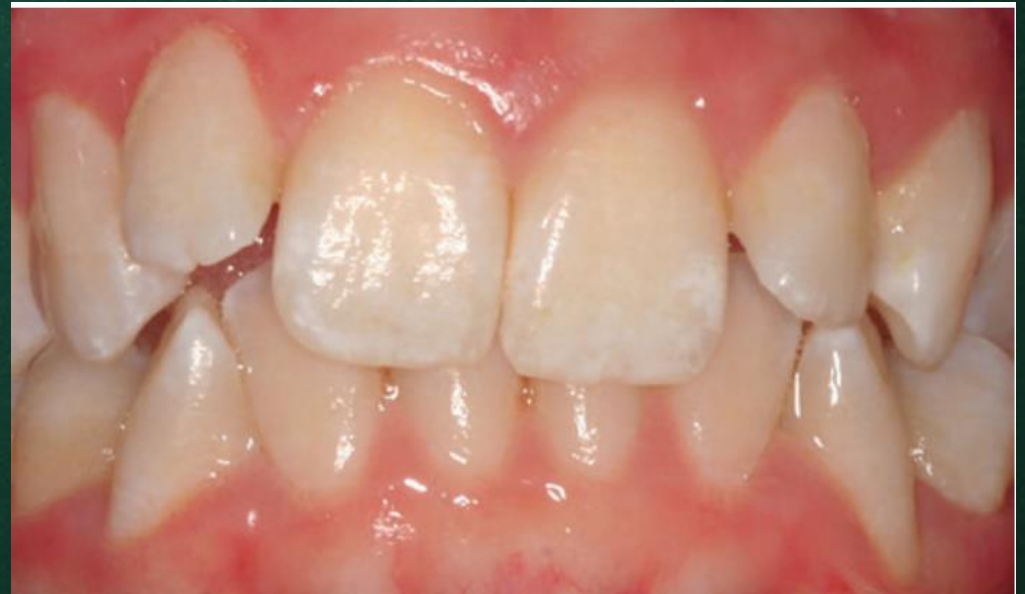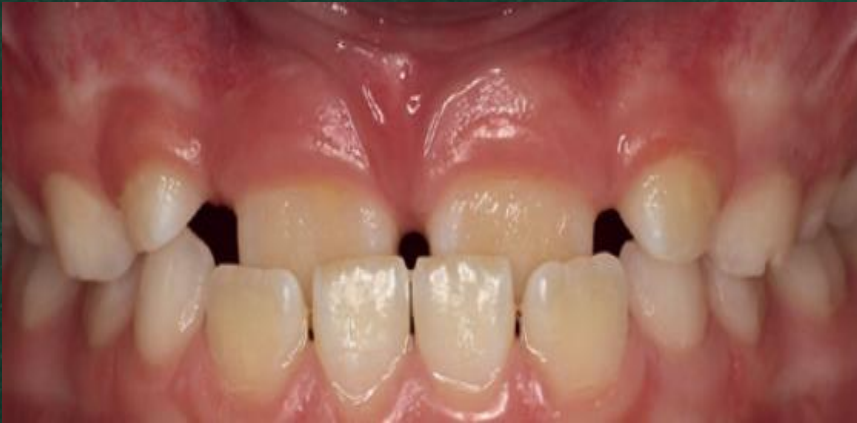malocclusion

Teeth with neighboring



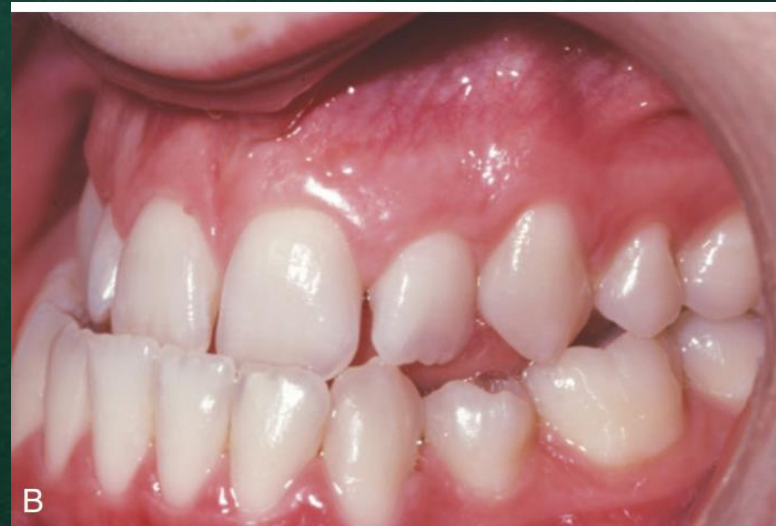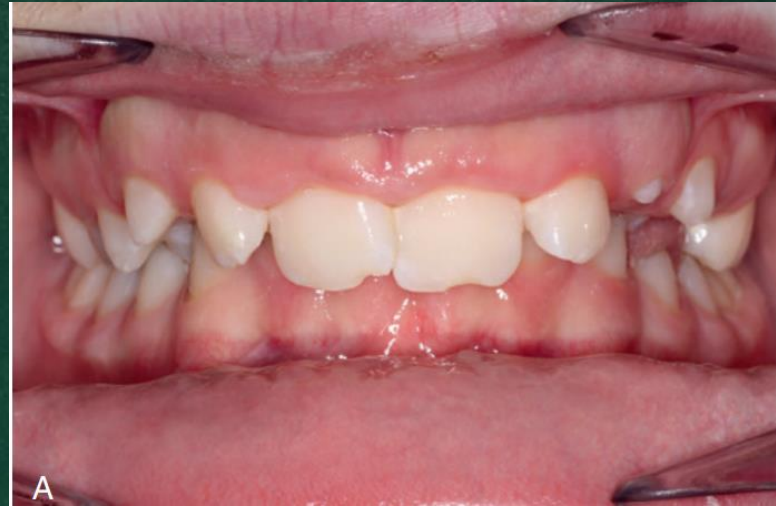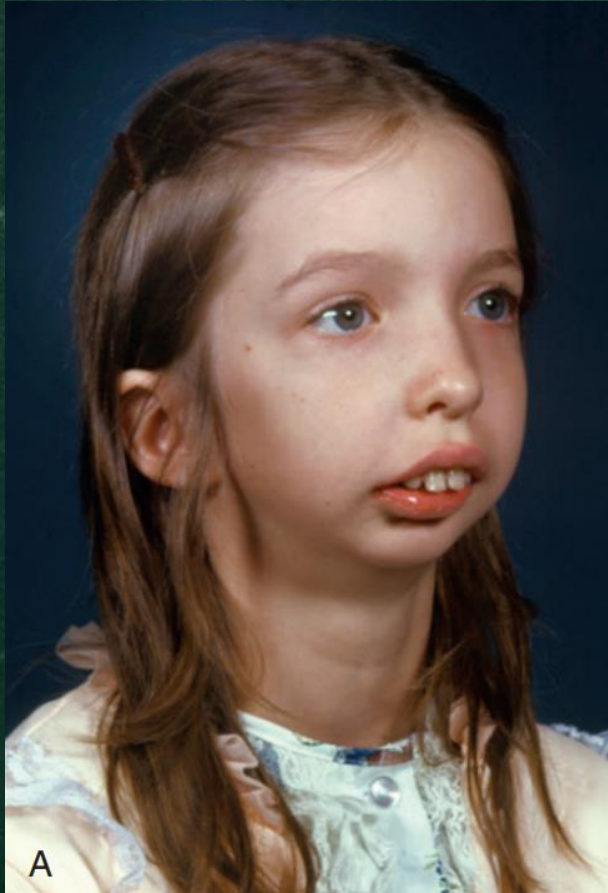malocclusion

Abnormal relations between dental arch.

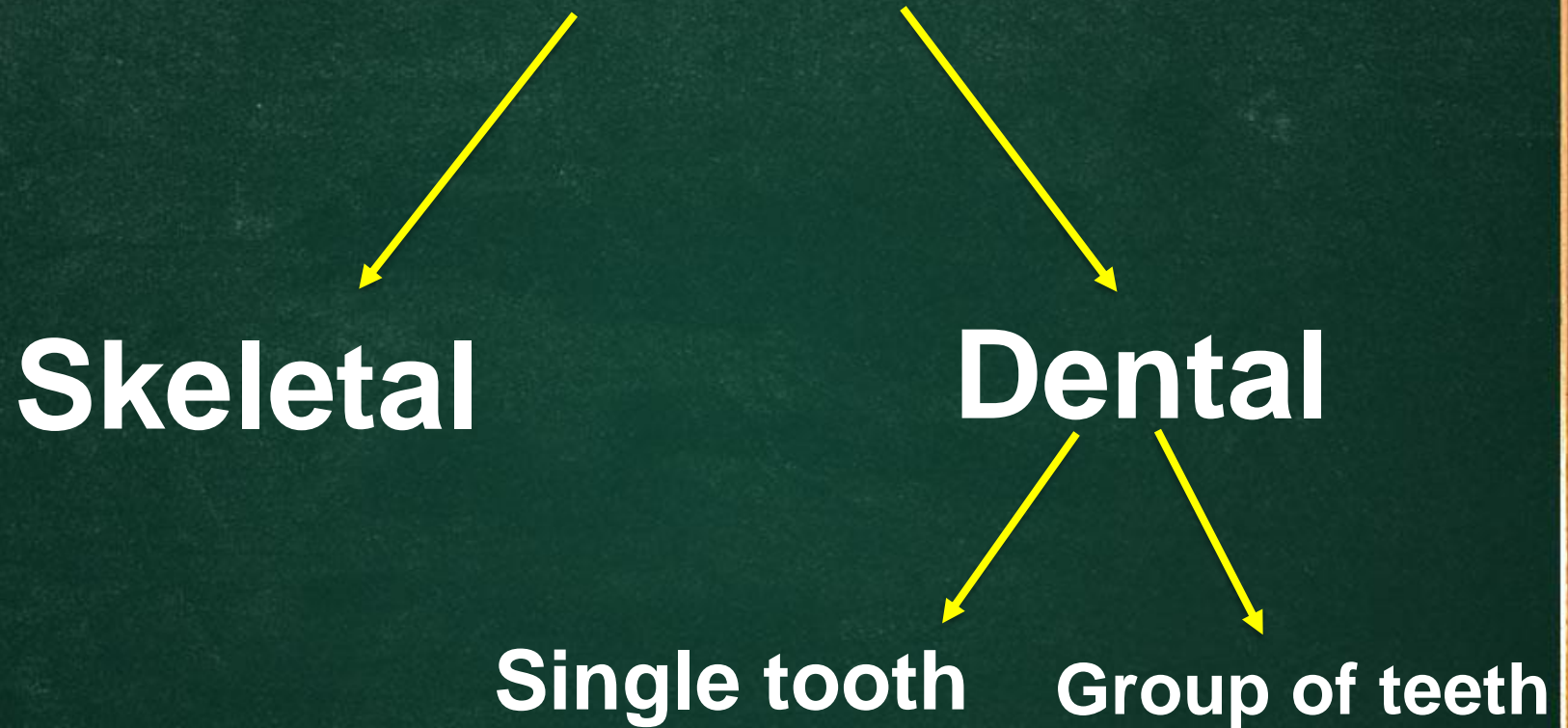


malocclusion

Abnormal skeletal morphology and/or relations



malocclusion



Classification of malocclusion

Classification has traditionally been an important tool for:

- diagnosis and treatment planning
- Estimating the severity of the problem
- communication tool between dental school professor and student, between practitioners
- Case presentation and discussion to the patient

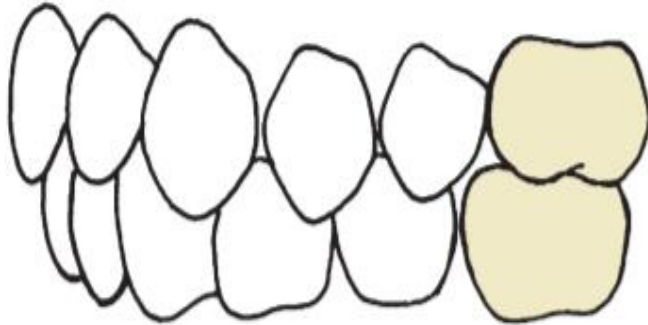
Angle's classification

Divisions and subdivisions

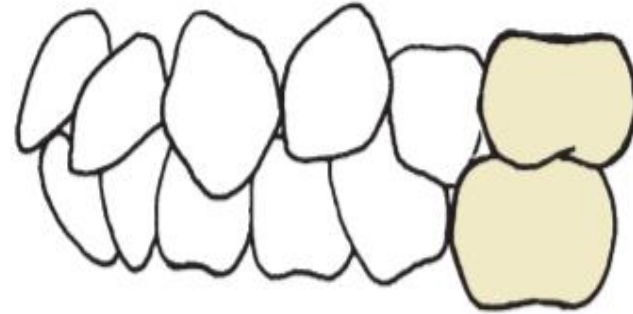
Antero-posterior relation

There are many classifications Angle's classification is the most widely used and accepted occlusal classification system.

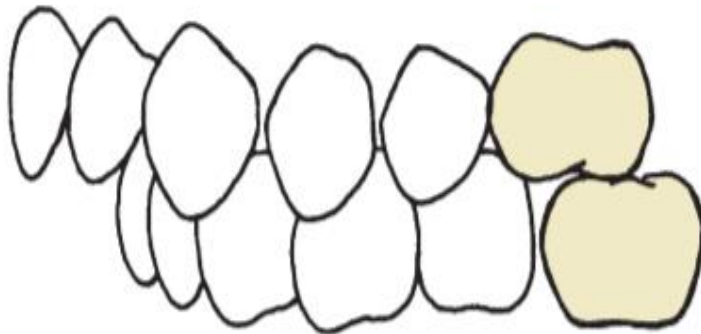
Angle's classification



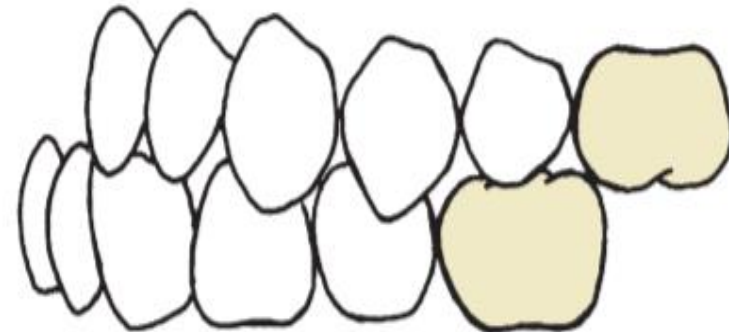
Normal occlusion



Class I malocclusion



Class II malocclusion



Class III malocclusion

Normal occlusion and malocclusion classes as specified by Angle

Classification of malocclusion

The Angle classification system for malocclusions proposed by Angle is widely used and serves as an excellent means of general description that has facilitated the communication about different malocclusions within the profession.

The system basically describes anteroposterior relationships of the permanent **first molars and canines**.

Angle's classification Divisions and subdivisions

Angle's classification

Angle's Class I Malocclusion (Neutroocclusion)

Molar relation: The mesiobuccal cusp of the upper first molar occludes with the mesiobuccal groove of the lower first molar.

Line of occlusion: will be altered in maxillary and mandibular arches:

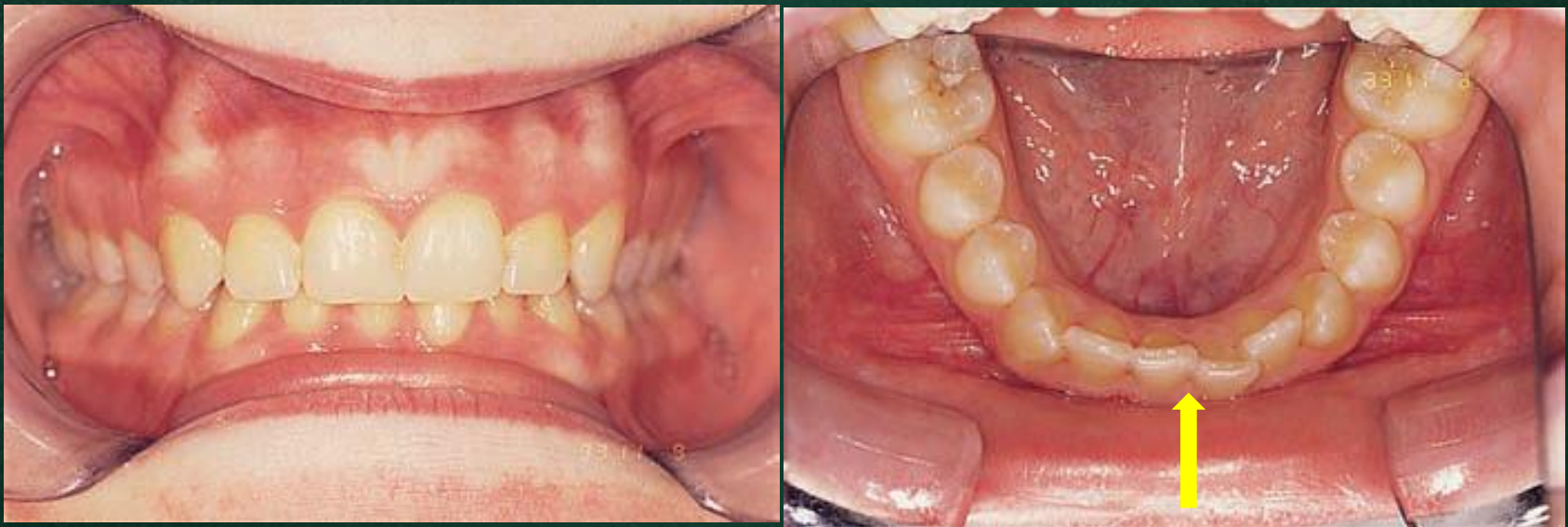Individual tooth irregularities like crowding, spacing, rotations, absence of tooth will be seen.

Interarch problems like deep bite, open bite, proclination or increased overjet, crossbite will be present.

Angle's classification

Angle's Class I Malocclusion (Neutroocclusion)

Molar relation: The mesiobuccal cusp of the upper the mesiobuccal groove first molar occludes with of the lower first molar.



Class I occlusion with acceptable mild lower labial segment crowding.

Angle's classification

Angle's Class II Malocclusion (Distocclusion)

Class II malocclusion has divisions:

- a. division **i** and
- b. division **ii**.

Angle's classification

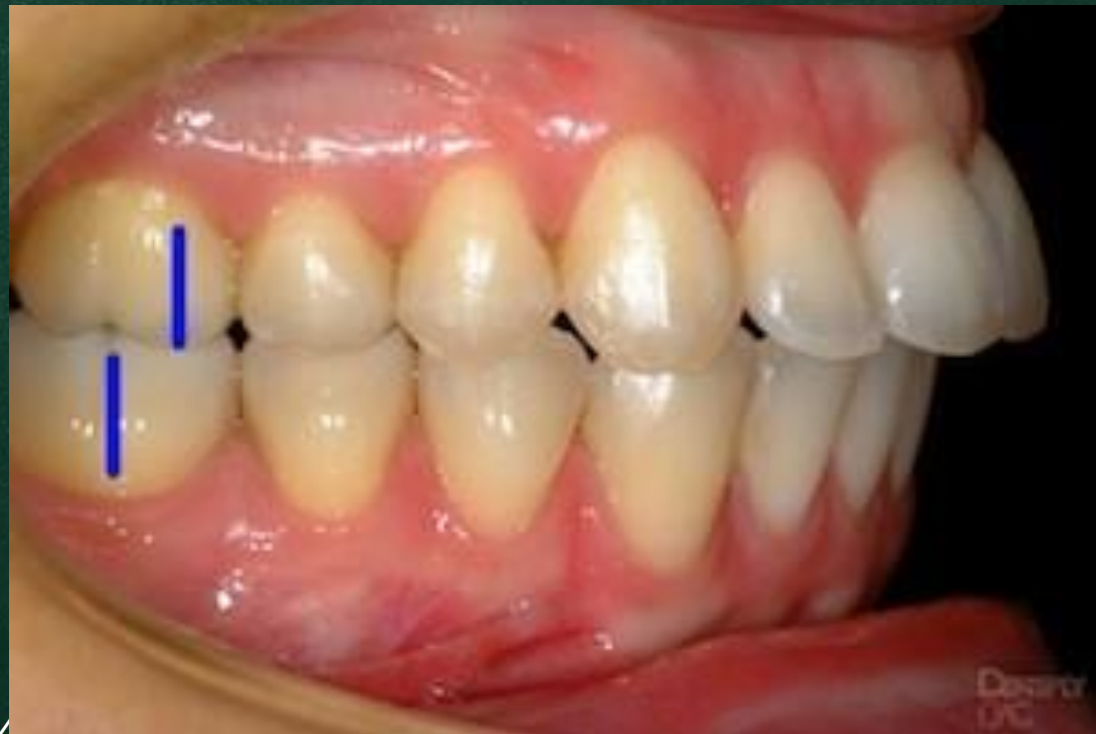Class II malocclusion



Angle's classification

Class II malocclusion
Division I

Angle's Class II With proclination of all the upper incisors

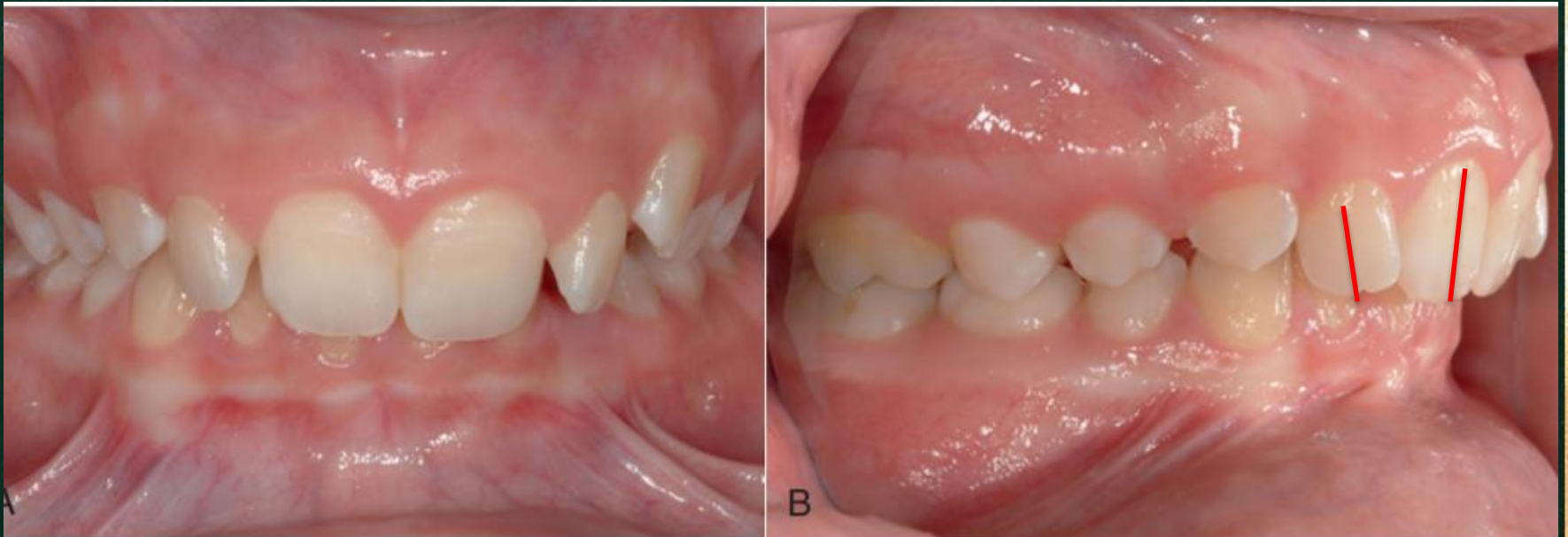

Angle's classification

Class II malocclusion

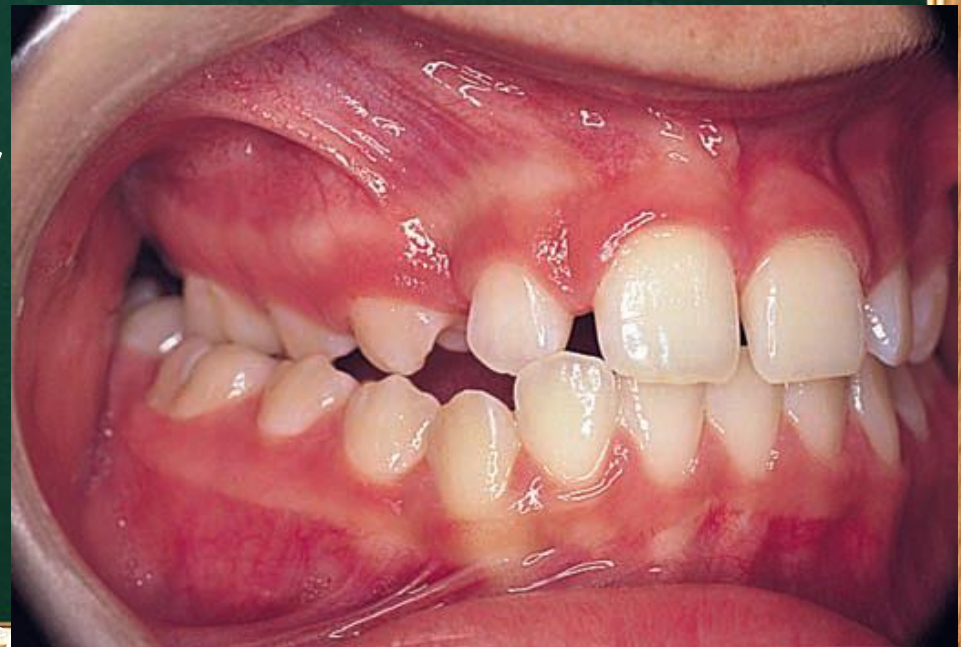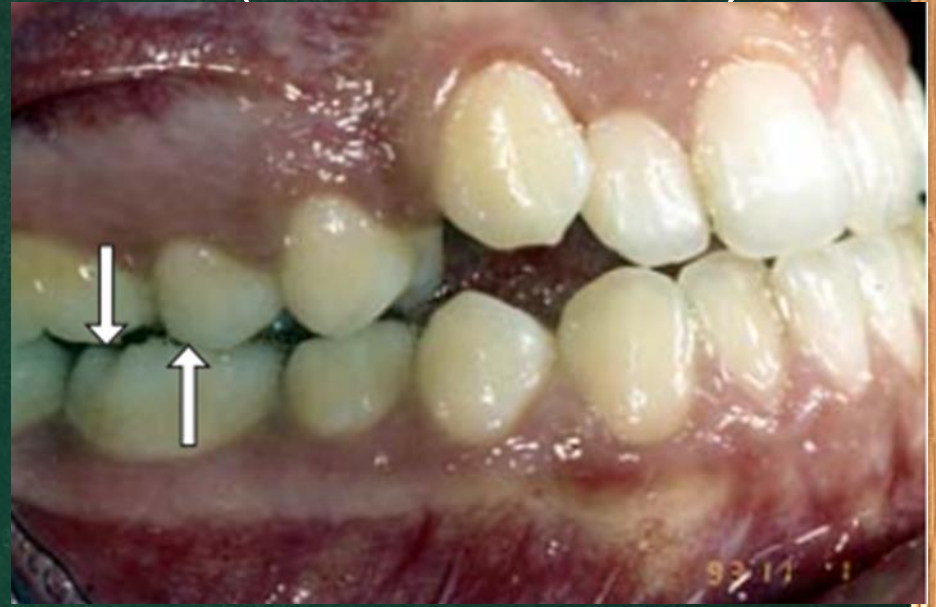Division ii

Angle's Class II With retroclination of the upper central incisors



Angle's Class III Malocclusion (Mesiocclusion)

is a condition in which the lower molar is positioned mesial to the upper molar.



Class III malocclusion

Pseudo class III/ habitual class III.

This is not a true class III malocclusion.

When the mandible moves from rest position to occlusion due to occlusal prematurities, it slides forward into a pseudo class III position.

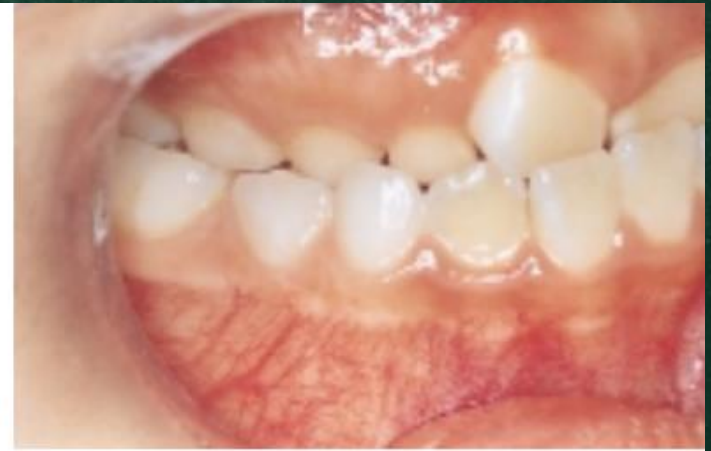True class III and pseudo class III malocclusions can be differentiated by taking a cephalogram in both at rest position and occlusion.

pseudo—Class III [i.e., shifting into anterior crossbite because of incisor interferences]).

Pseudo class III/habitual class III

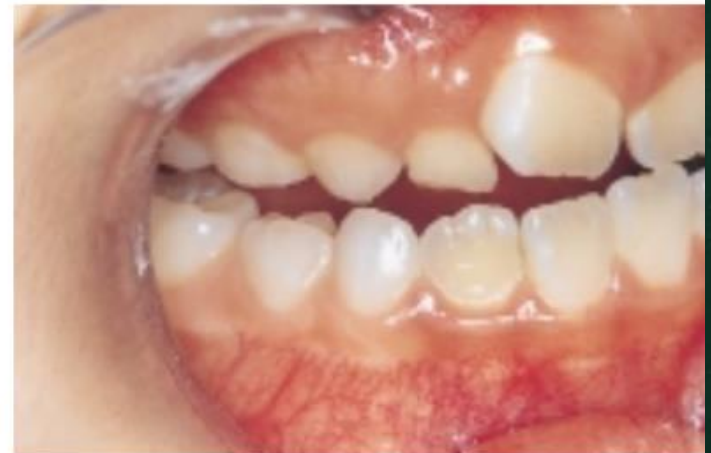A) intraoral photo at centric occlusion,

A



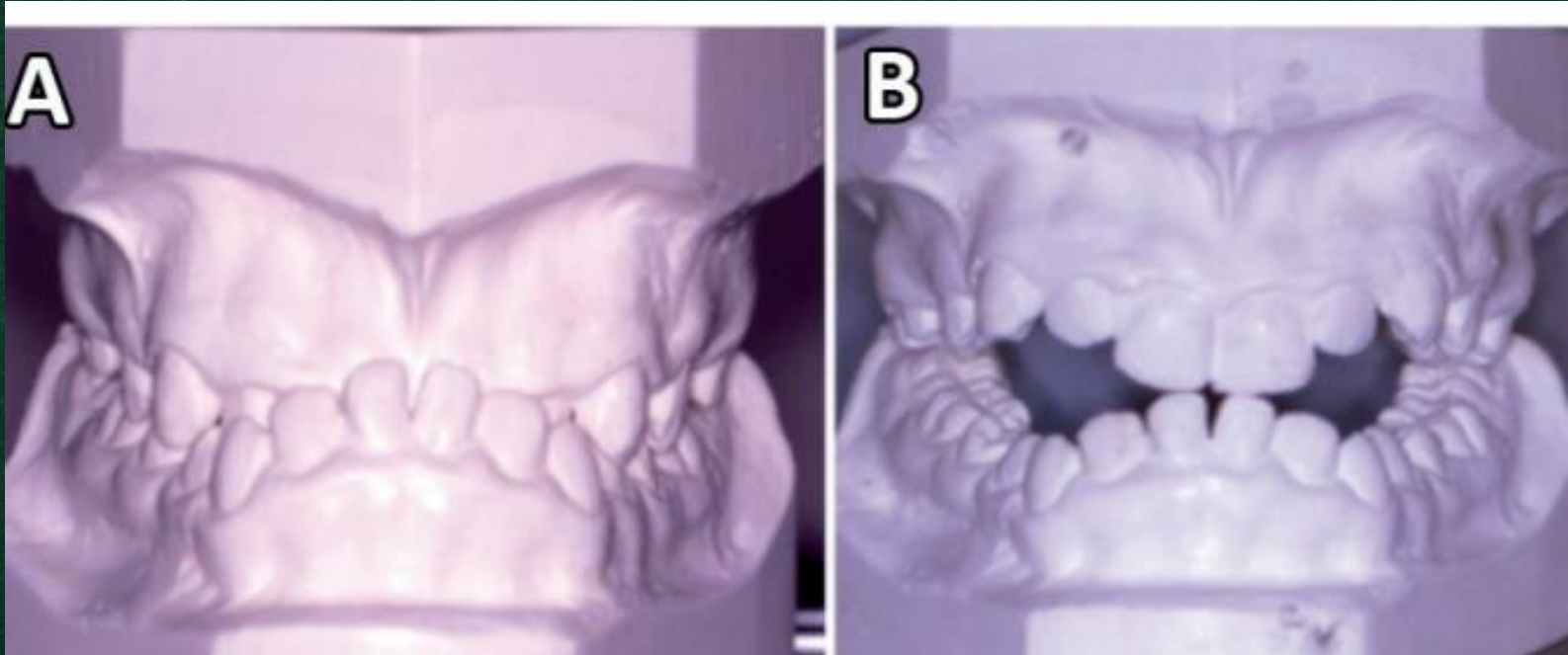
B) centric relation

B



These patients show normal molar relationship in rest position while class III relation in centric occlusion.

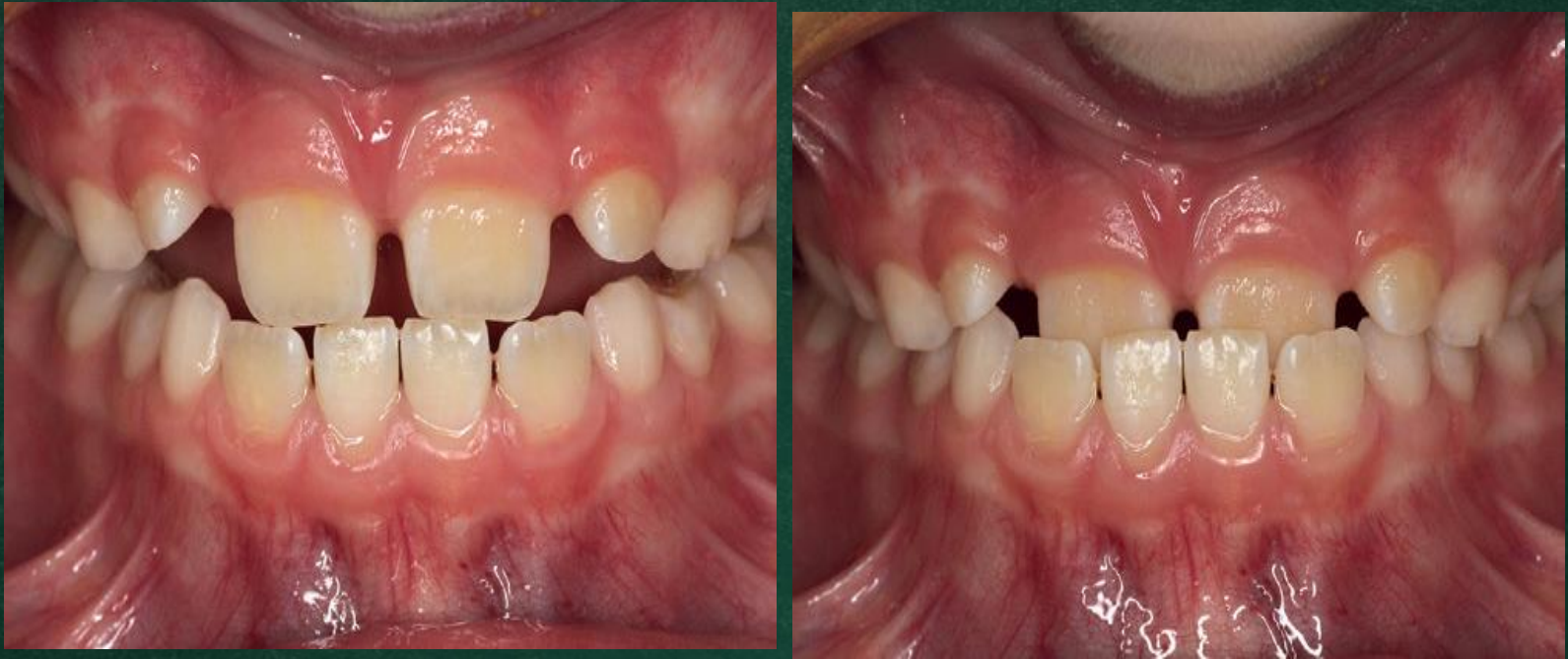Pseudo class III/habitual class III



A) centric occlusion

B) centric relation

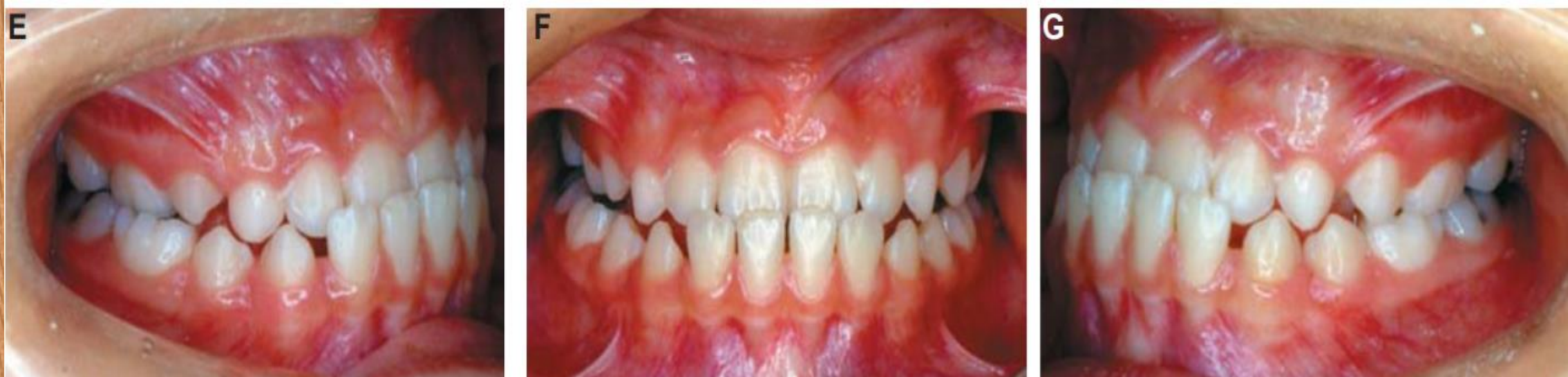Pseudo class III/habitual class III



Anterior crossbite with a forward mandibular shift.
(A) When the anterior teeth contact in centric relation and cause an interference so that a natural continuation to centric occlusion is not possible,
(B) the mandible shifts forward so maximum intercuspation (centric occlusion) of the posterior teeth can be achieved.

Class III malocclusion

True class III In this class III, molar relation exists both in centric occlusion and at rest position



Angle's classification

The term half & full cusp unit

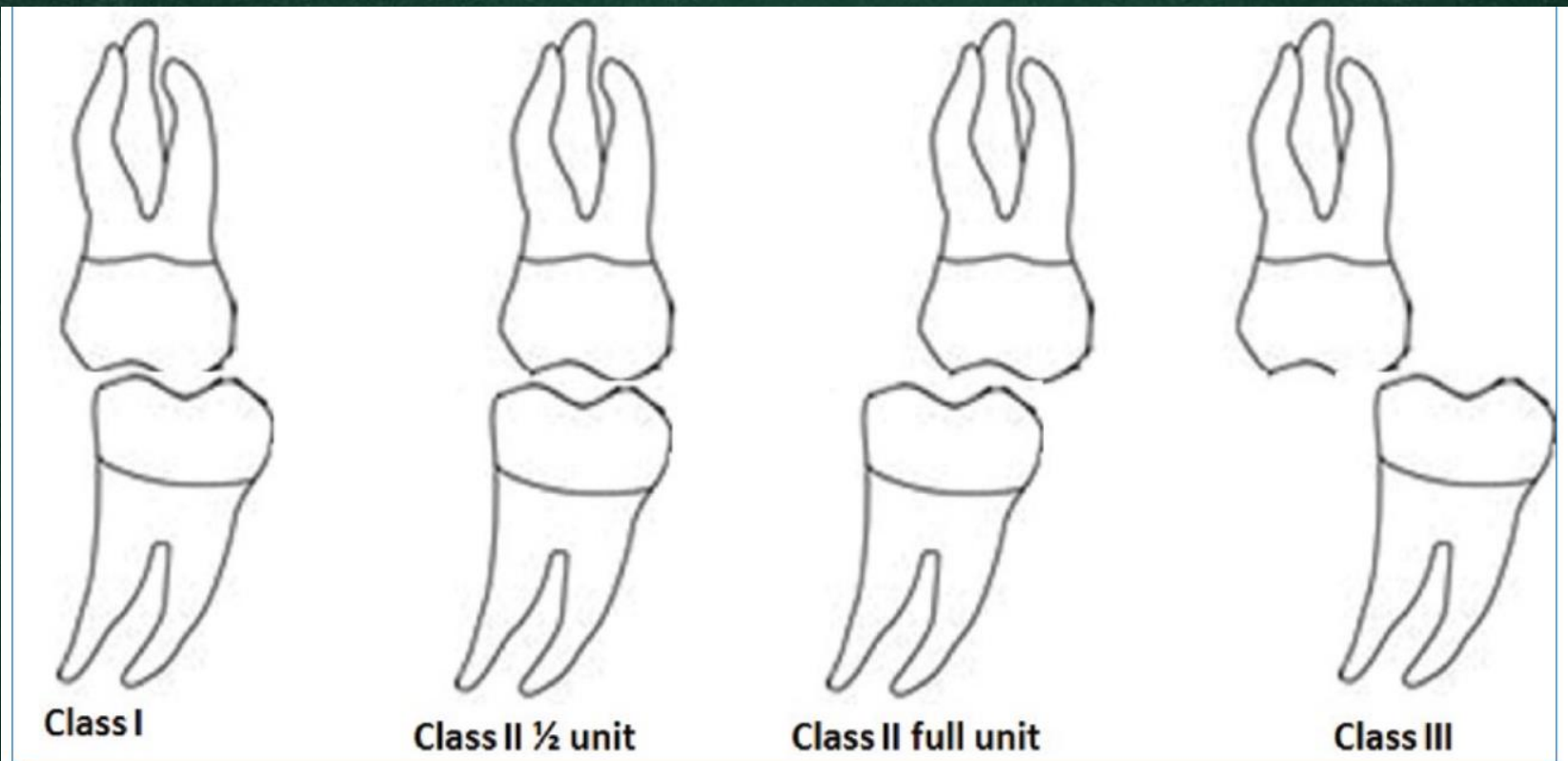
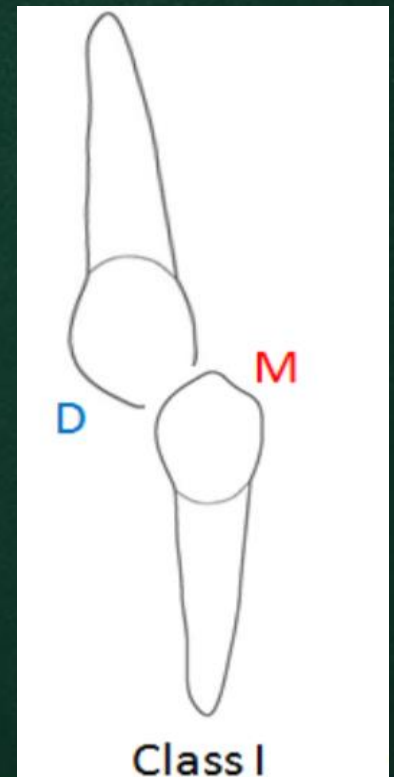
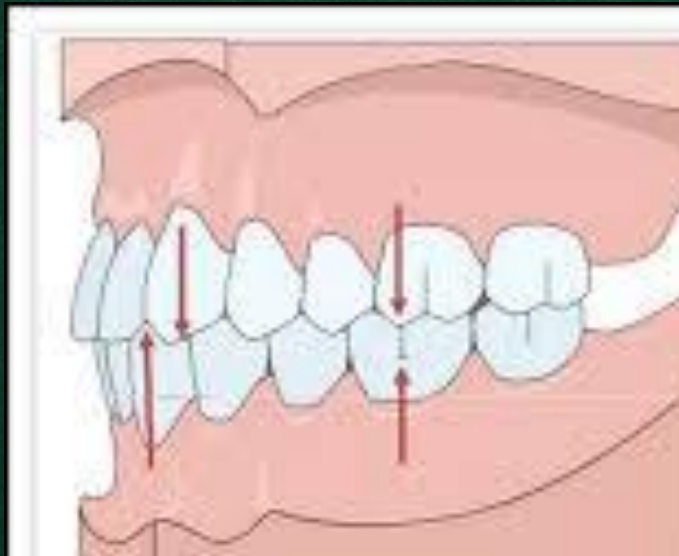


Figure 4. Molar's Classification

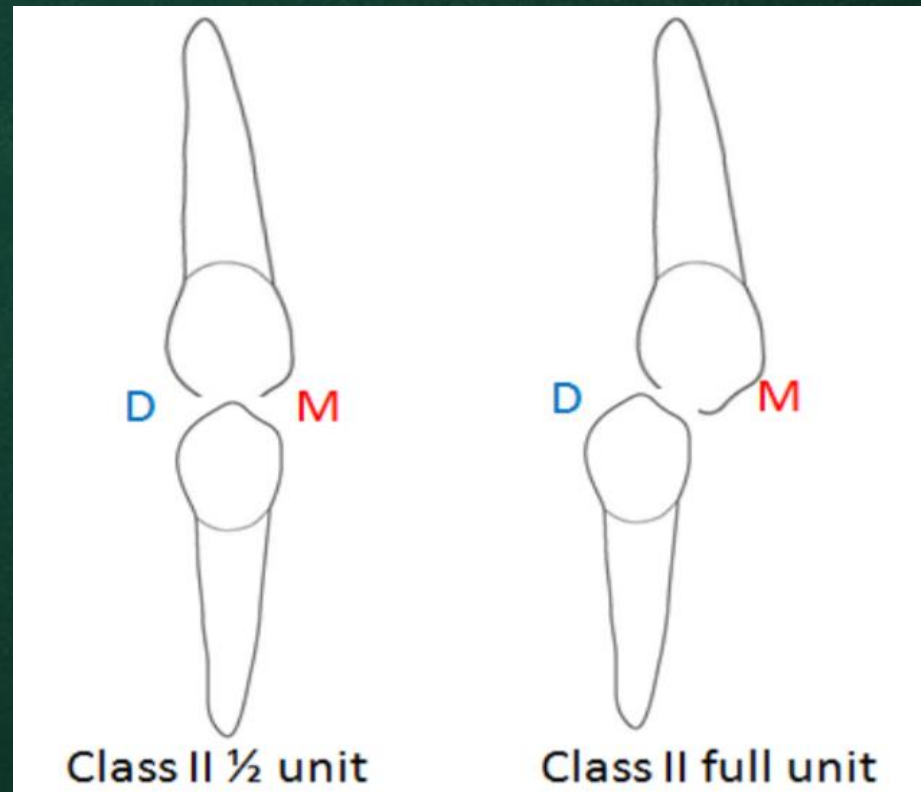
Canine's classification

Class I: mesial incline of the upper canine overlaps the distal slope of the lower canine (The maxillary canine occludes between the mandibular canine and 1st premolar).



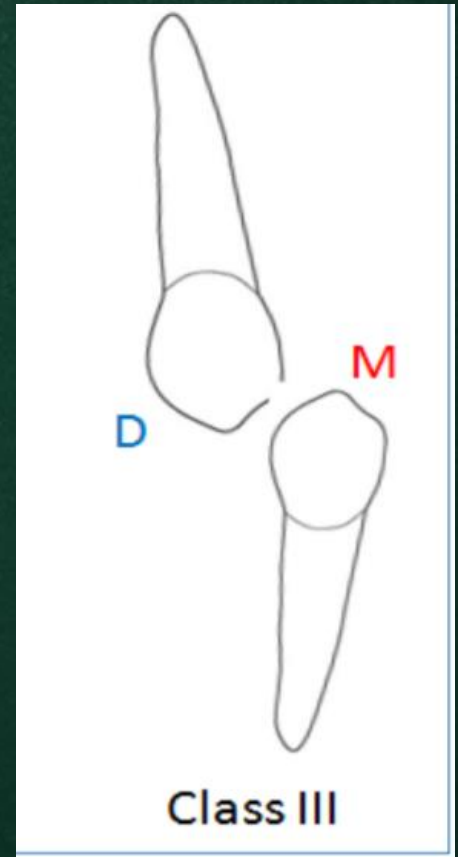
Canine's classification

Class II: Distal slope of the maxillary canine occludes or contacts the mesial slope of the lower canine.

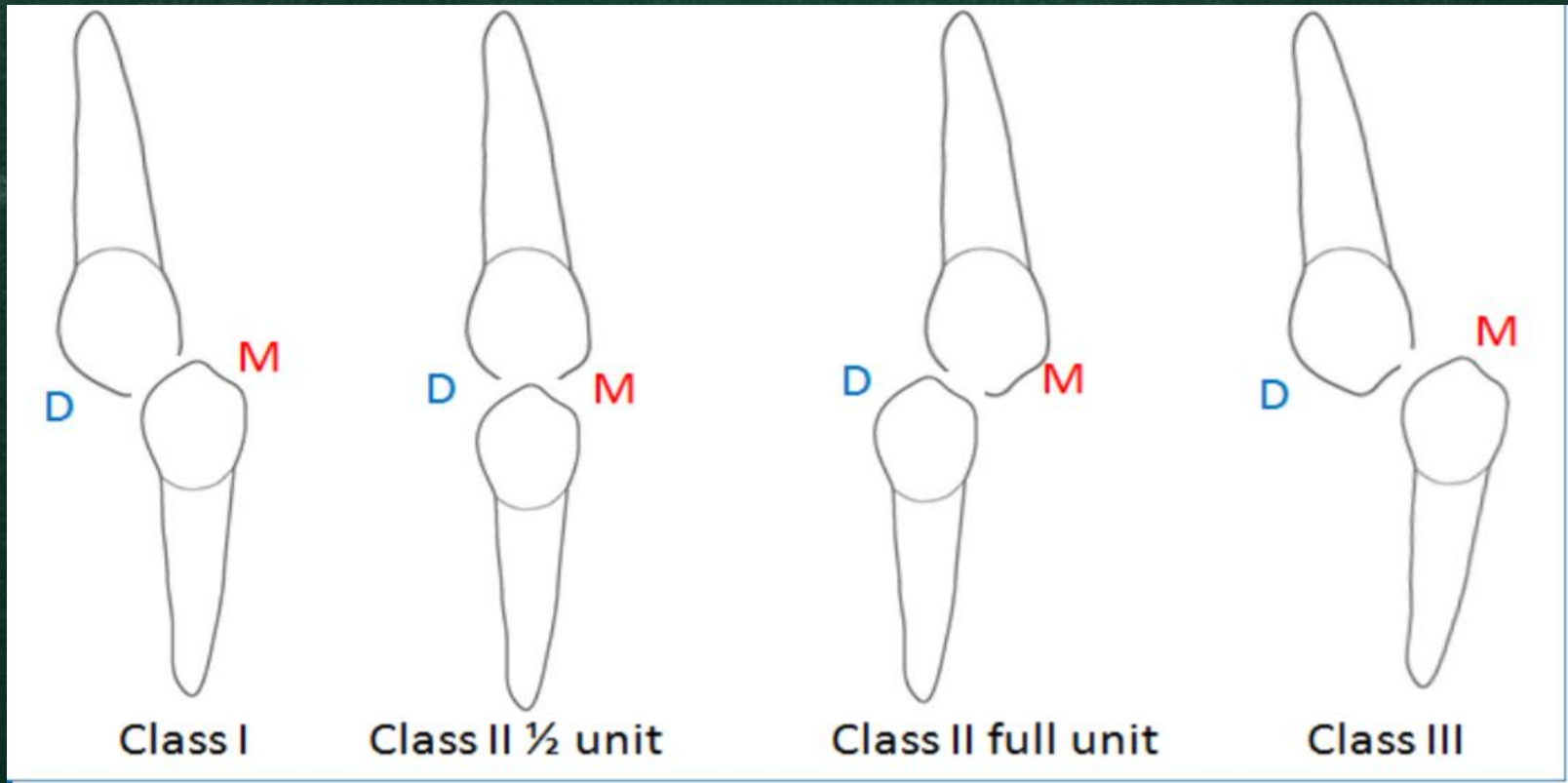


Canine's classification

Class III: The mandibular canine is displaced anterior to the maxillary canine with no overlapping

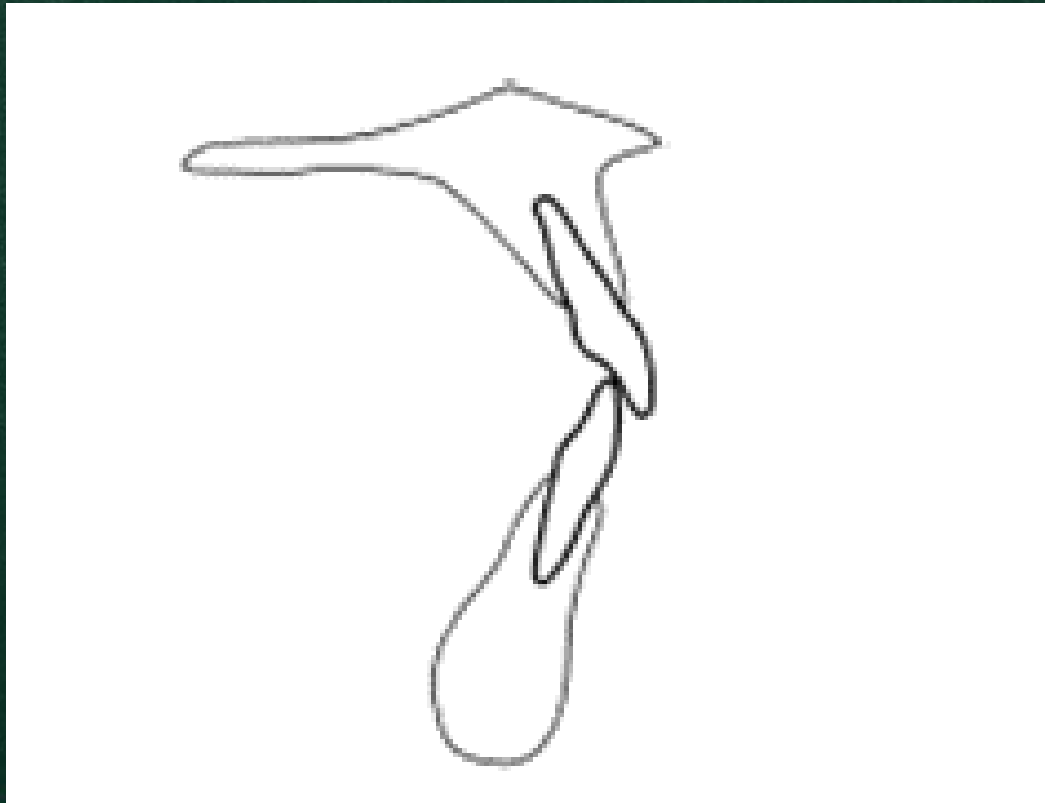


Canine's classification



incisor's classification

- British Standards incisor classification
- Class I — the lower incisor edges occlude with or lie immediately below the cingulum plateau of the upper central, the overjet is 2-4 mm.



incisor's classification

- Class II — the lower incisor edges lie posterior to the cingulum plateau of the upper incisors. There are two subdivisions of this category:
 - Division 1 — the upper central incisors are proclined or of average inclination and there is an increase in overjet.



Fig. 2.3 Incisor classification — Class II division 1.

incisor's classification

- Class II — the lower incisor edges lie posterior to the cingulum plateau of the upper incisors. There are two subdivisions of this category:
- Division 2 — The upper central incisors are retroclined. The overjet is usually minimal or may be increased.



Fig. 2.4 Incisor classification — Class II division 2.

incisor's classification

- Class III — The lower incisor edges lie anterior to the cingulum plateau of the upper incisors. The overjet is reduced or reversed



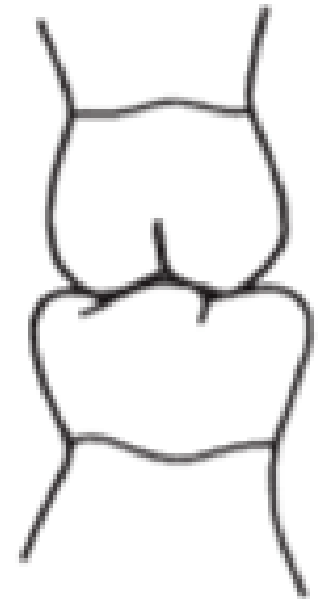Fig. 2.5 Incisor classification — Class III.

Occlusion

PRIMARY DENTITION

Flush terminal (FT): Present when the distal surfaces of the upper and lower second primary molars were in the same vertical plane when the jaws were in centric occlusion.

Flush
terminal
plane

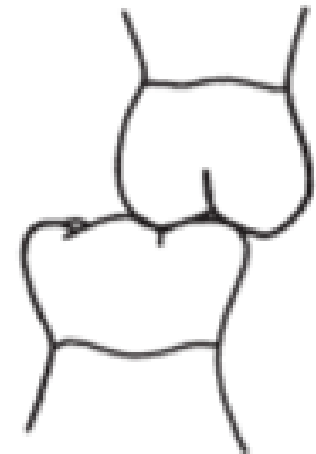


Occlusion

PRIMARY DENTITION

Distal step (DS): Recorded when the distal surfaces of the lower primary second molar present in posterior relationship to the distal surface of the upper second molars when the jaws were in centric occlusion.

Distal
step

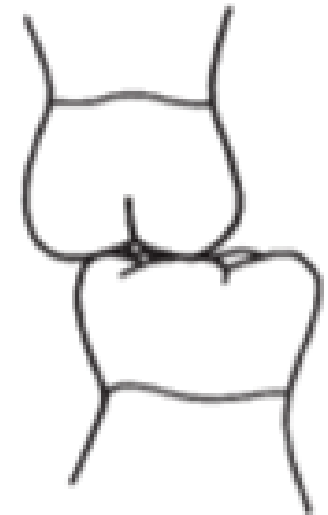


Occlusion

PRIMARY DENTITION

Mesial step (MS): It was listed as present when the jaws were in centric occlusion and if the distal surfaces of the lower primary second molar occurred in anterior relationship to the distal surface of the upper second molars

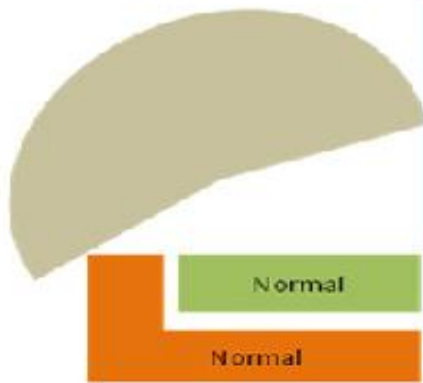
Mesial
step



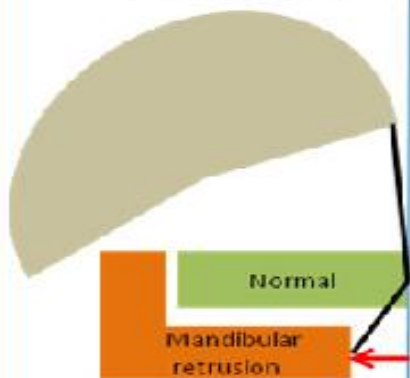
Classification of malocclusion

SKELTAL

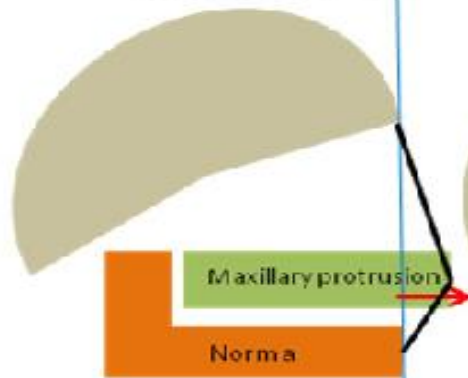
1. Sagittal jaw relationships (anteroposterior).
2. Vertical relationships.
3. Horizontal relation.



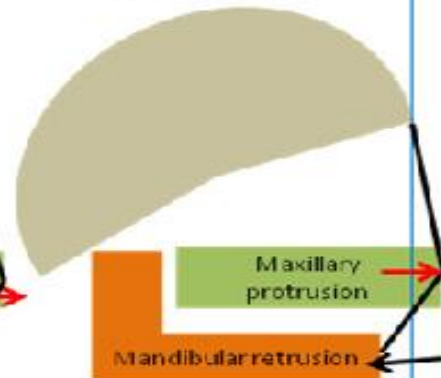
Skeletal II type 1



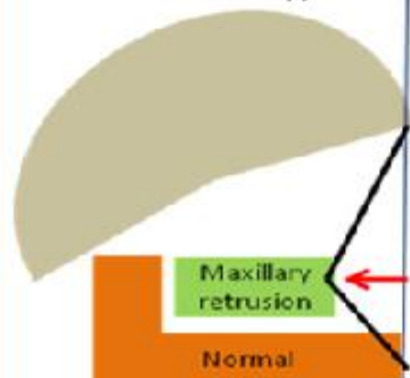
Skeletal II type 2



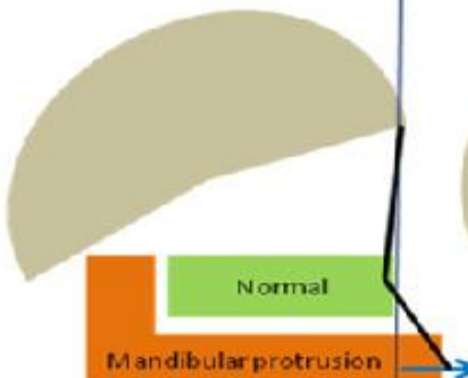
Skeletal II type 3



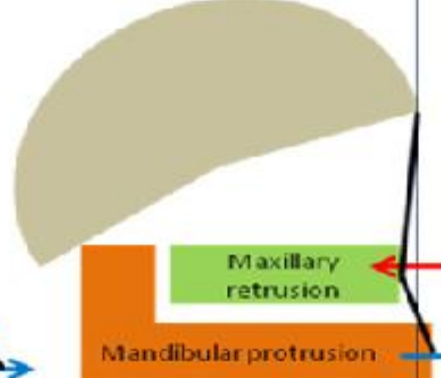
Skeletal III type 1



Skeletal III type 2



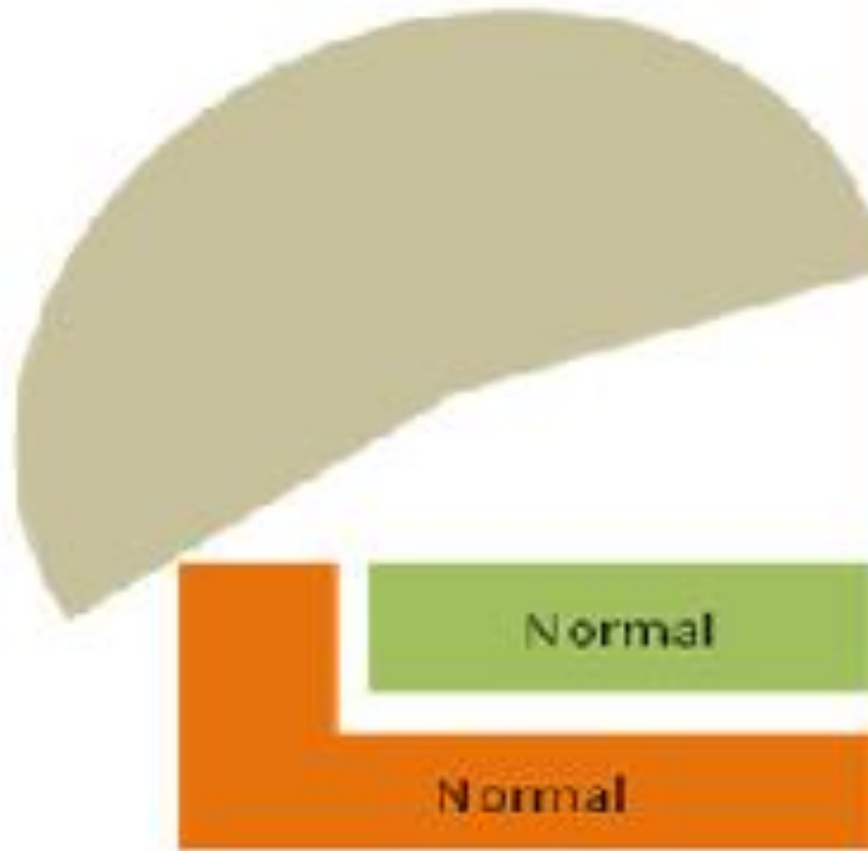
Skeletal III type 3



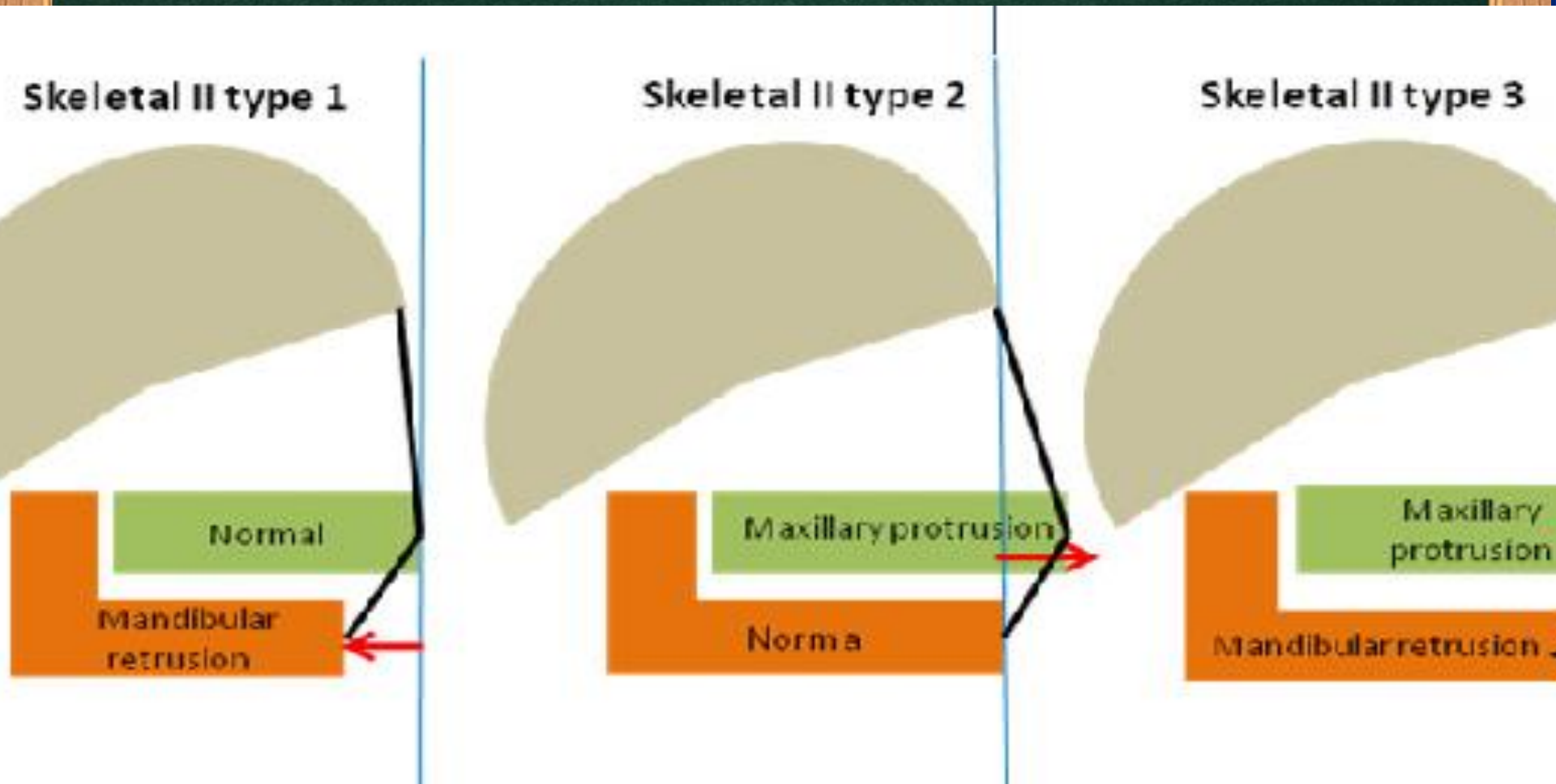
Classification of malocclusion

SKELTAL

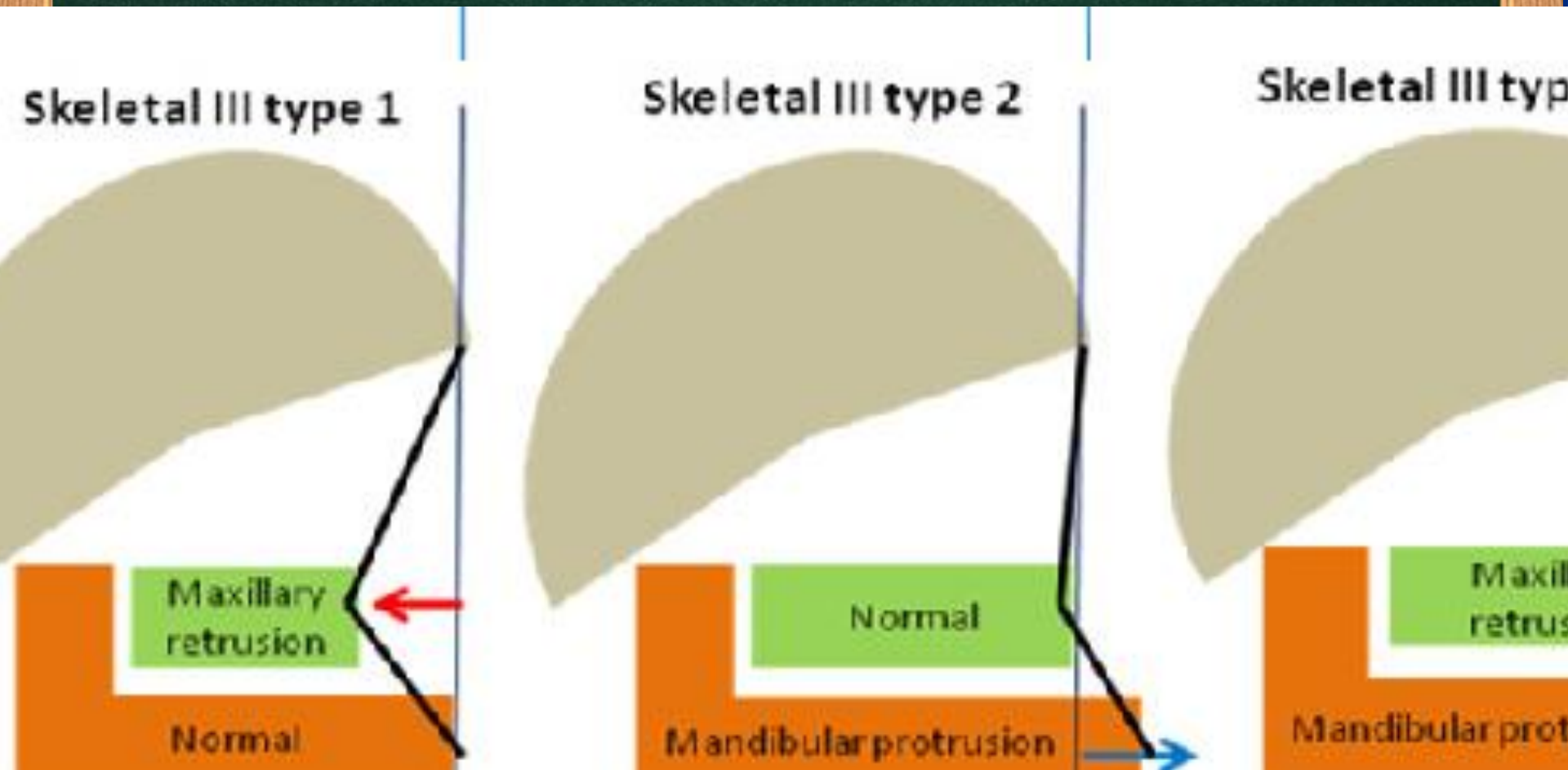
Class I skeletal

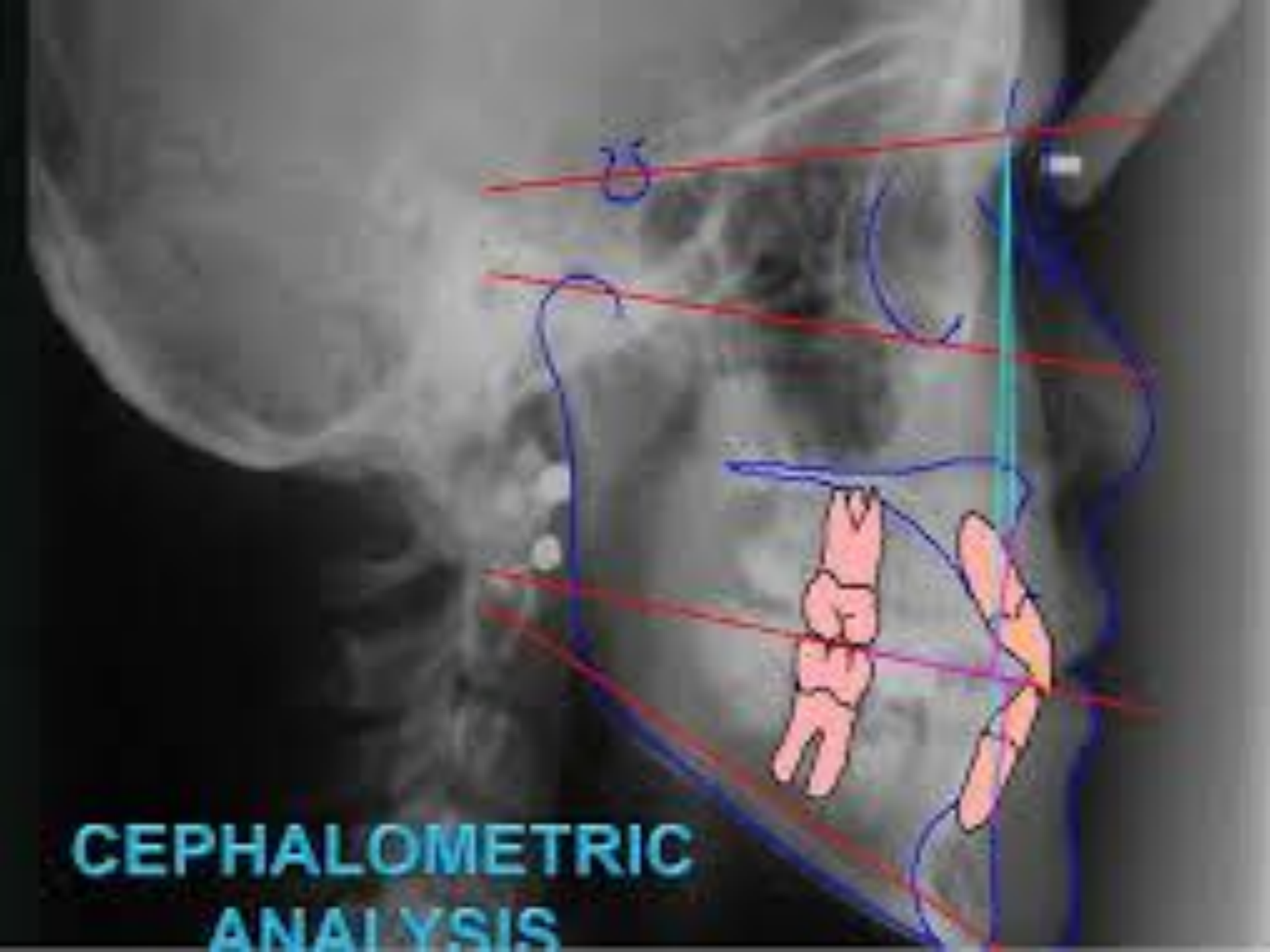


Classification of malocclusion SKELTAL



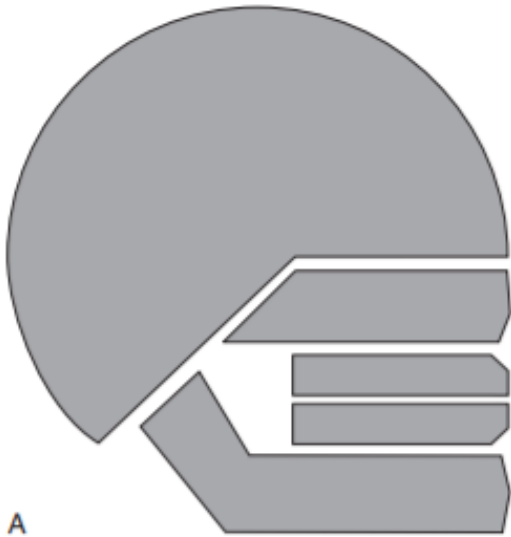Classification of malocclusion SKELTAL



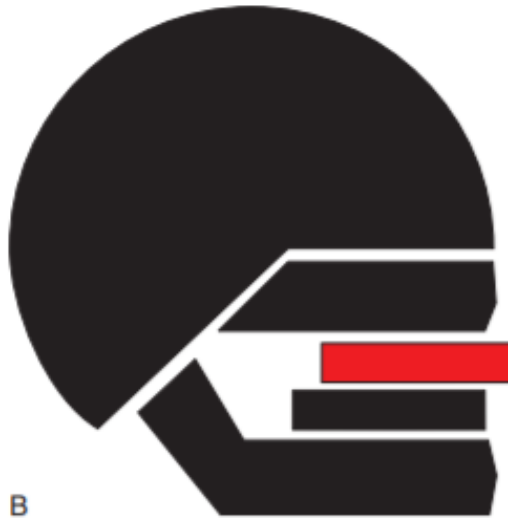

**CEPHALOMETRIC
ANALYSIS**

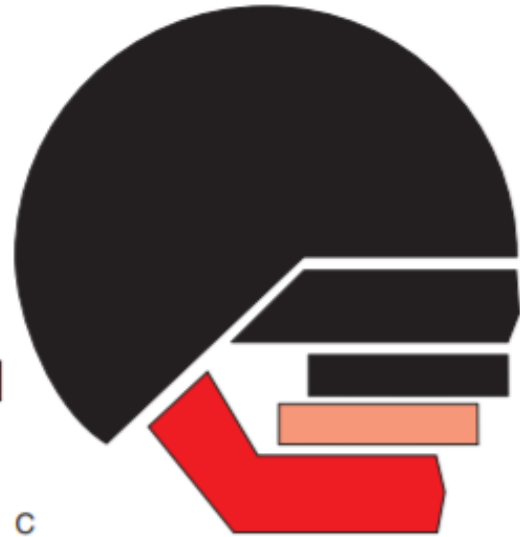Classification of malocclusion SKELTAL




A



B



C



D



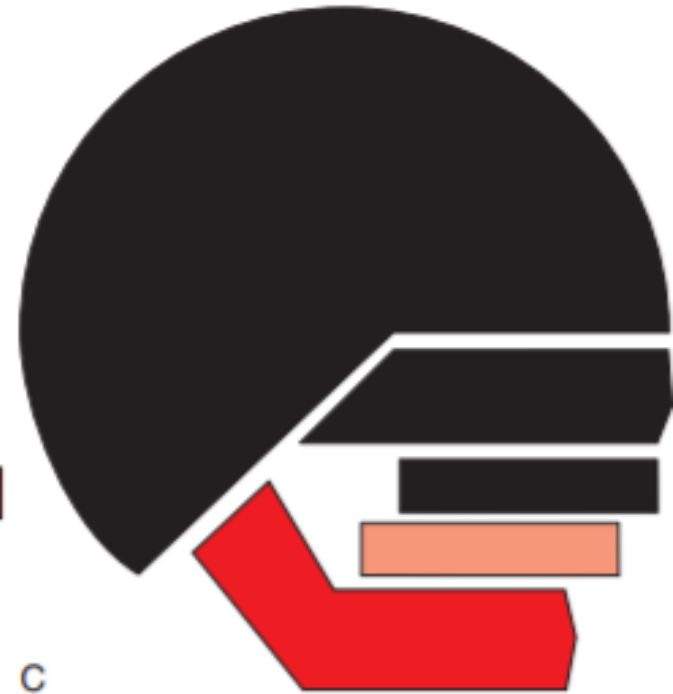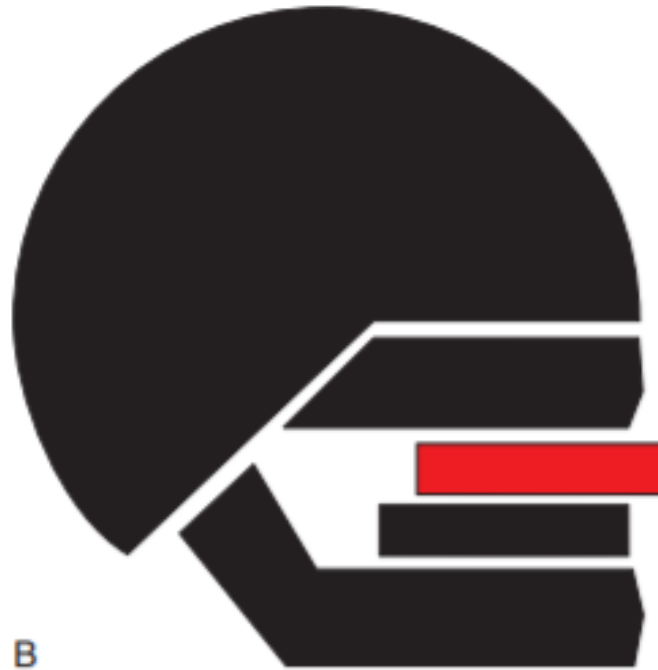E



F

Classification of malocclusion

SKELTAL



Classification of malocclusion

SKELTAL



Ass. prof. Munad Jihad AL Duliamy

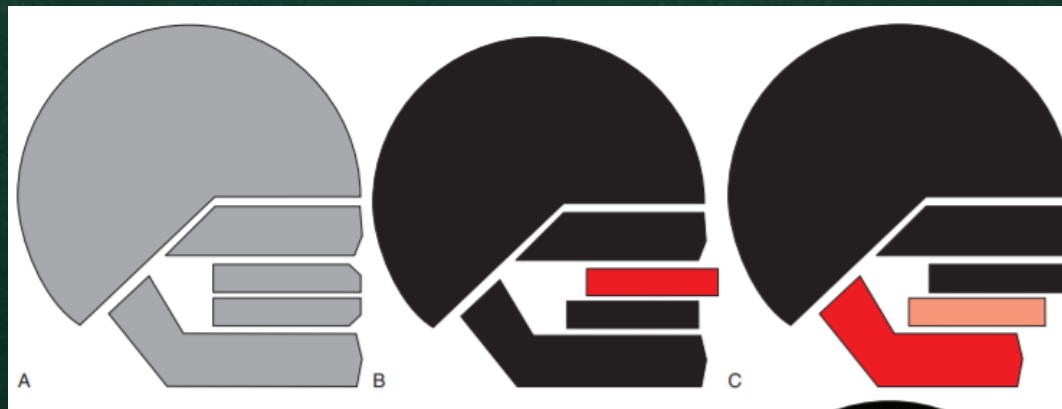
Classification of malocclusion

SKELTAL

The ideal relationships of the facial and dental components can be represented as shown in (A).

Cephalometric analysis can distinguish and clarify the differing dental and skeletal contributions to malocclusions that present identical dental relationships.

A Class II division 1 malocclusion, for example, could be produced by (B) protrusion of the maxillary teeth although the jaw relationship was normal, (C) mandibular deficiency with the teeth of both arches normally related to the jaw,



Classification of malocclusion

SKELTAL

(D) downward and backward rotation of the mandible produced by excessive vertical growth of the maxilla. A Class III malocclusion could be produced by (E) true mandibular prognathism with a normal maxilla, (F) maxillary anteroposterior and vertical deficiencies that make a normal-size mandible look prominent because the maxillary vertical deficiency allowed it to rotate up and forward, or any other combination of maxillary deficiency and mandibular excess.



References

Proffit, W. R., Fields, H. W., & Sarver, D. M. (2019). Contemporary orthodontics. St. Louis, Mo: Elsevier/Mosby

Mitchell, L., Littlewood, S. J., Nelson-Moon, Z., & Dyer, F. (2019). An introduction to orthodontics.

Morales, F. J. U. (2007). Clasificación de la maloclusión en los planos anteroposterior, vertical y transversal. *Revista de la Asociación Dental Mexicana*, 64(3), 97-109.

Davies, S. Malocclusion – a term in need of dropping or redefinition?. *Br Dent J* 202, 519–520 (2007). <https://doi.org/10.1038/bdj.2007.372>