



Definitions of certain orthodontic terms

Lec. 2

أ.م. مُنَاد جِهَاد عَاشِج

Ass. prof. Munad Jihad AL Duliamy

Classification of malocclusion

Permanent Dentition

malpositions of individual tooth

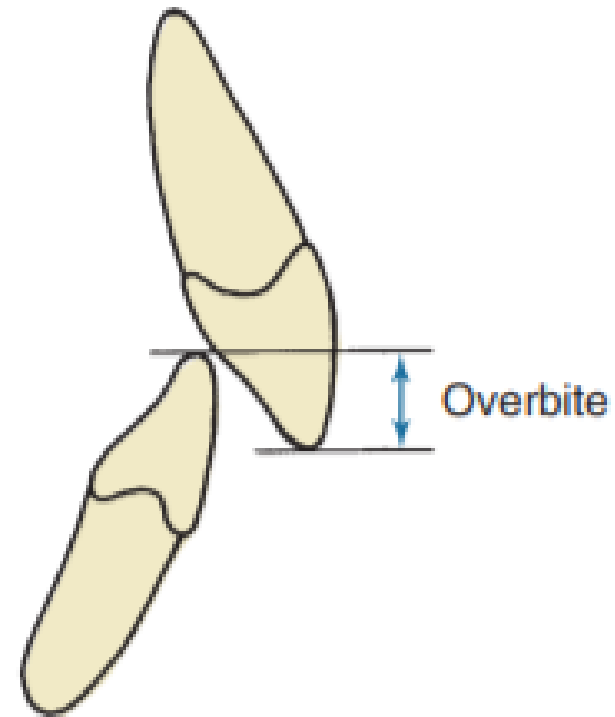
Angle described seven malpositions of individual teeth: (1) buccal or labial, (2) lingual, (3) mesial, (4) distal, (5) torso (rotated), (6) infra (not erupted sufficiently to reach the occlusal plane), and (7) supra (erupted through and beyond the occlusal plane). These individual tooth malpositions can be used to describe a malocclusion more fully.

Definitions of certain orthodontic terms

Malocclusion of individual tooth

Overbite

Overbite is the amount of vertical overlap between the maxillary and mandibular central incisors.



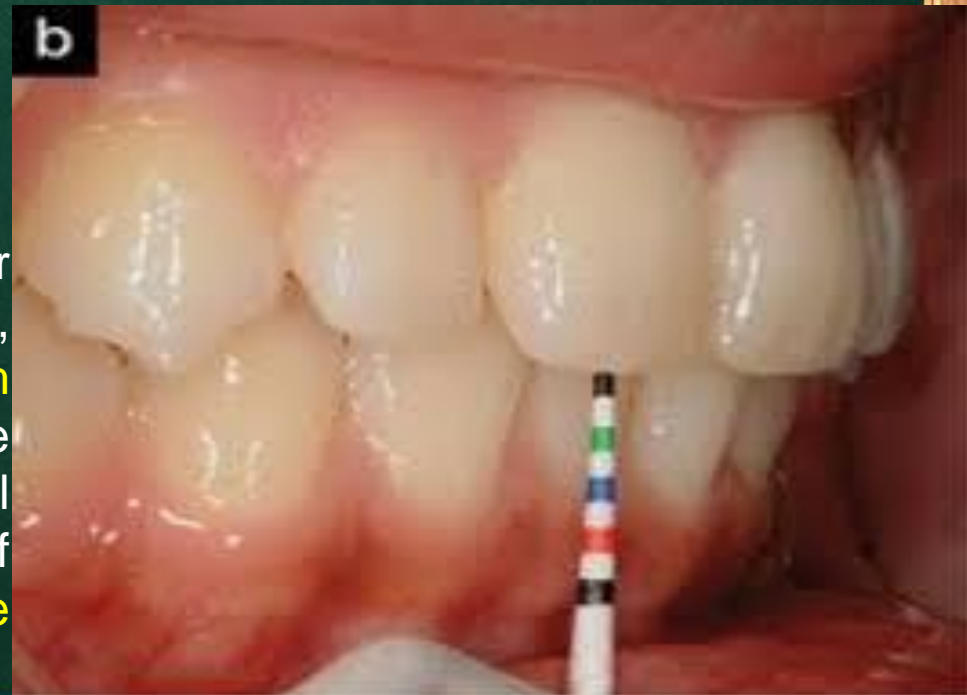Overbite

This relationship can be described either in millimeters or more often as a percentage of how much the upper central incisors overlap the crowns of the lower incisors.

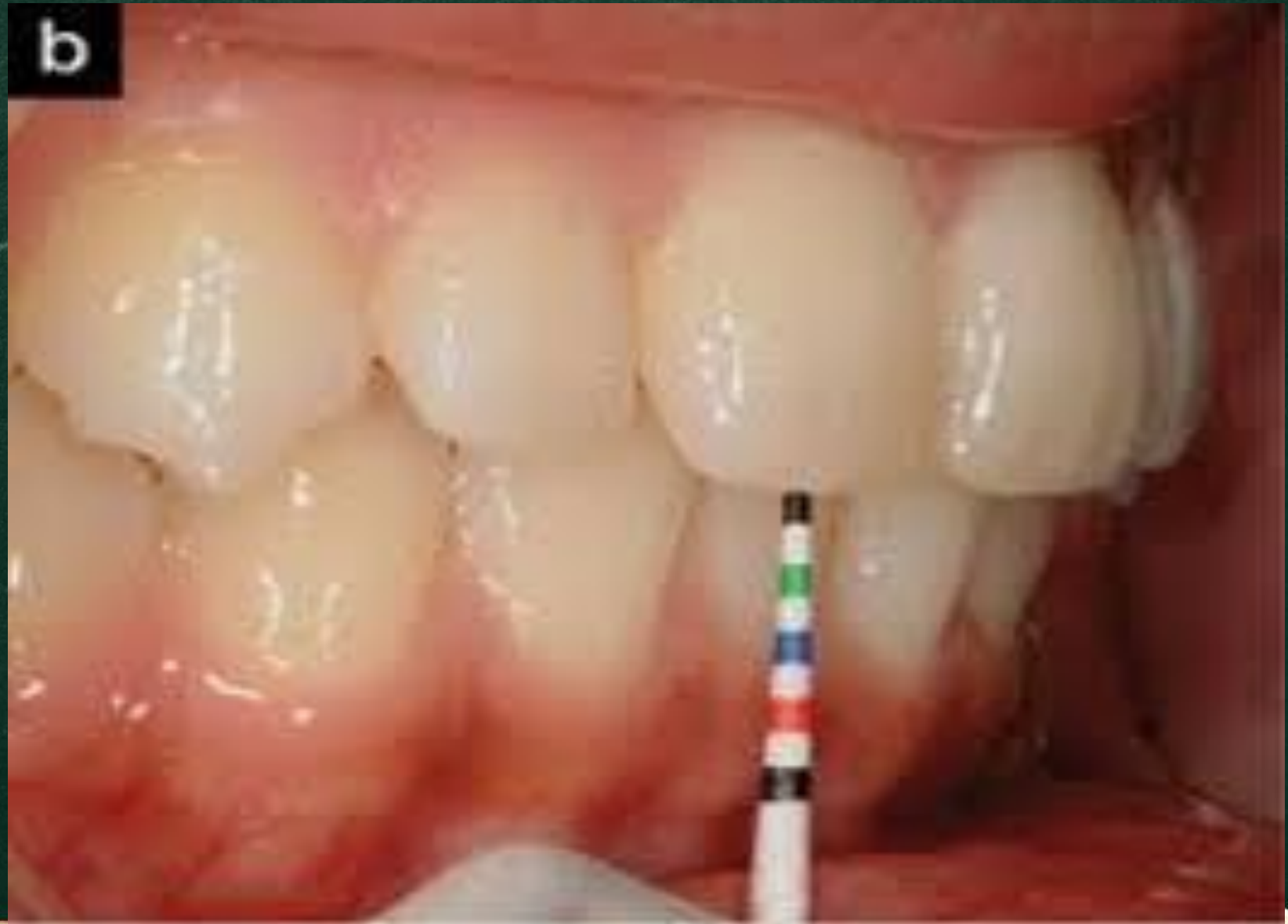Measured in

- mm
- Percentage
- third

Normally, the incisal edges of the lower teeth should contact slightly at or above the cingulum of the upper teeth, which is approximately **1-3 mm** overbite. Due to differences in the crown lengths of the incisors, normal overbite is about **30%** or **one third** of the **clinical crown height** of the **mandibular incisors**.

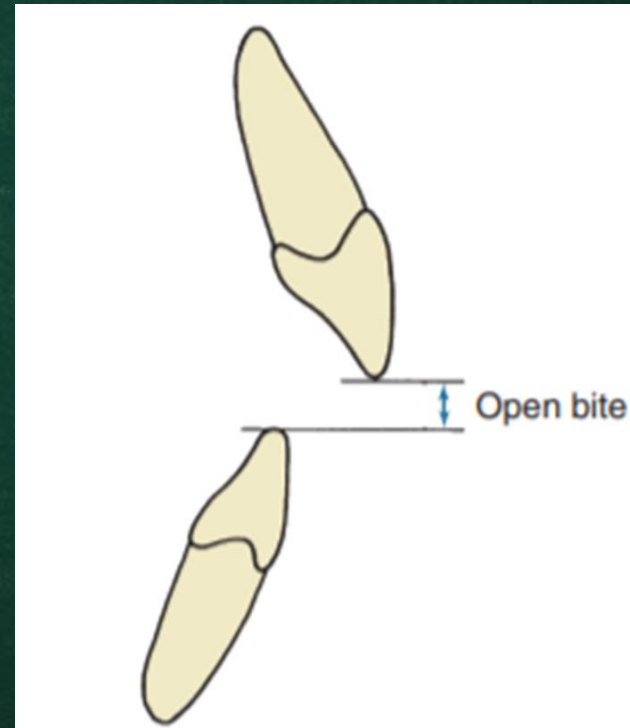
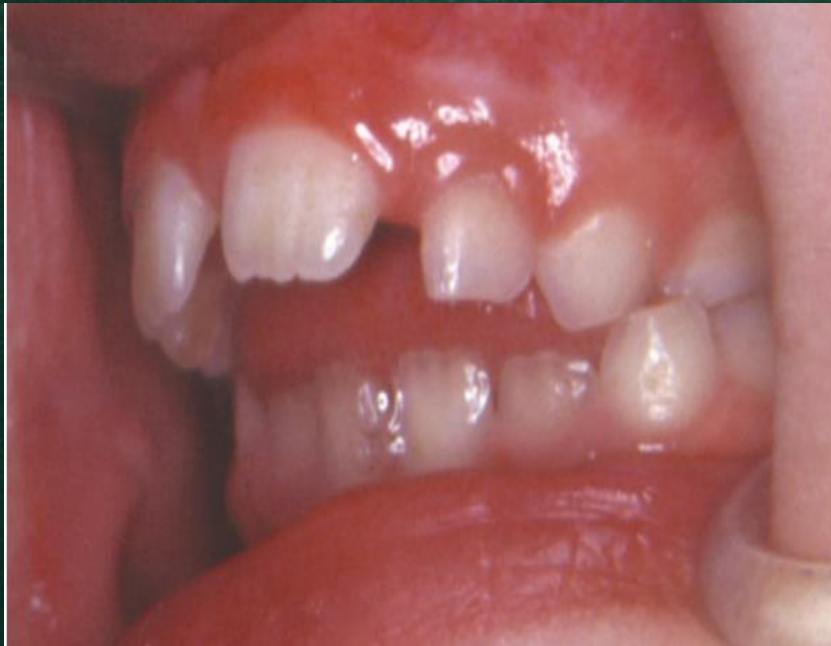

Overbite



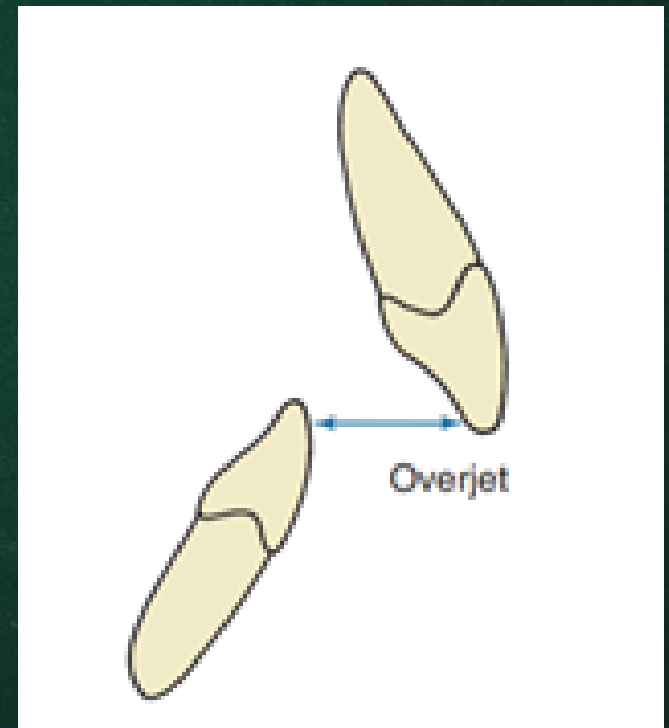
Open bite

In open bite (negative overbite), there is **no vertical overlap**, and the vertical separation of the incisors is measured to quantify its severity.



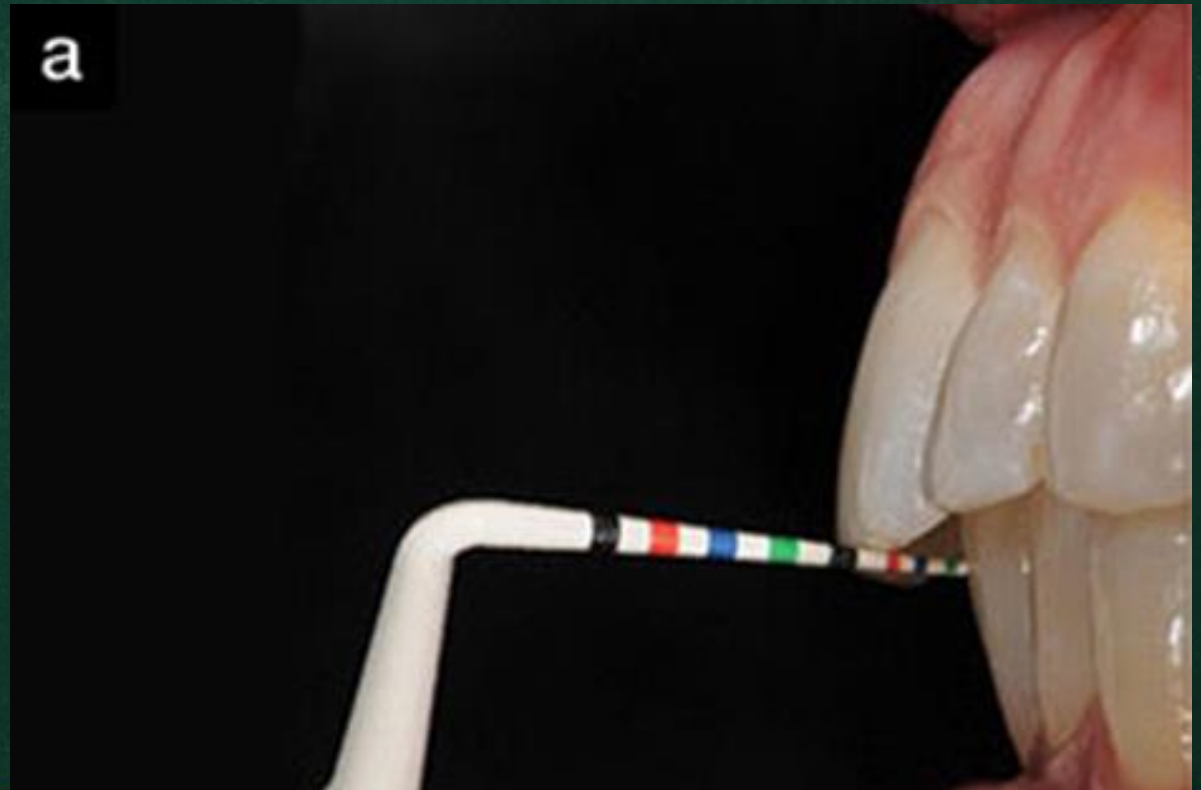Overjet

Overjet is the horizontal relationship or the distance between the most protruded maxillary central incisor and the opposing mandibular central incisor.



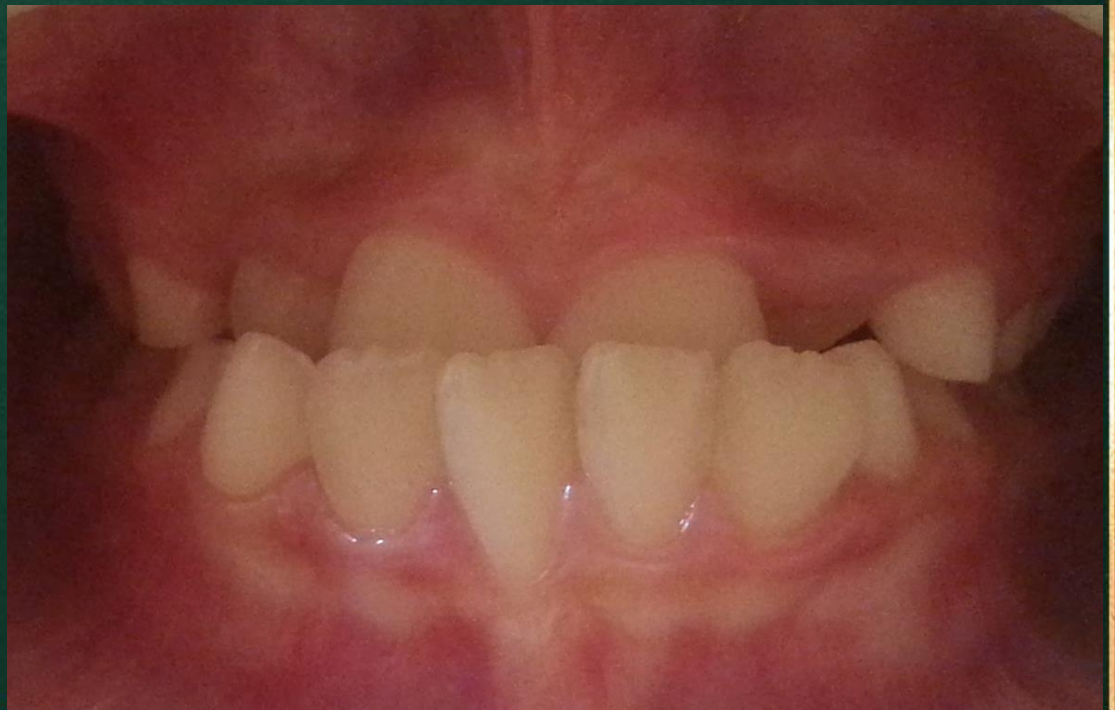Overjet

This relationship is expressed in millimeters. The normal range of overjet in the primary dentition varies between 0 and 3-4 mm.



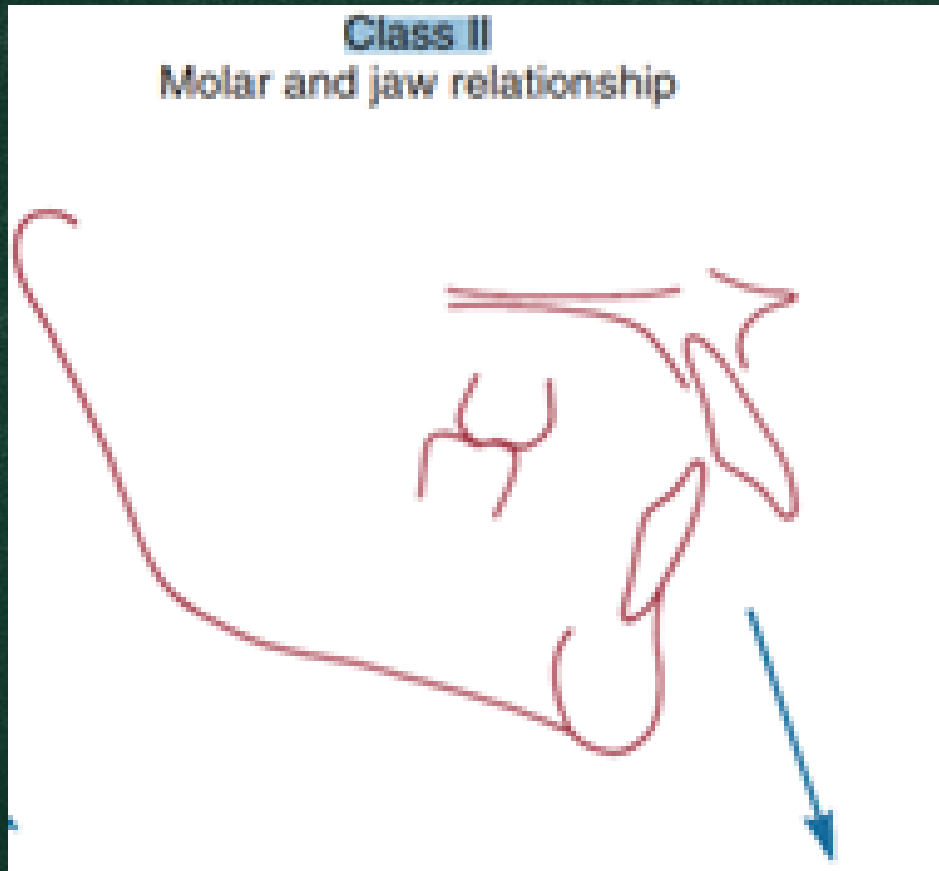
Overjet

If the maxillary incisors are lingual to the mandibular incisors, the relationship is described as an **reverse overjet OR anterior crossbite (underjet)**.



reverse overjet (Class III)

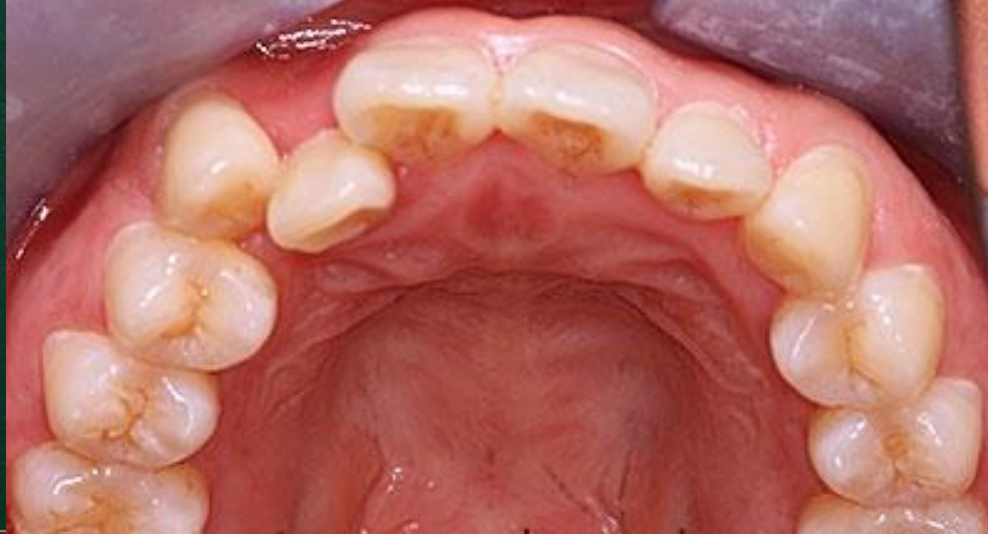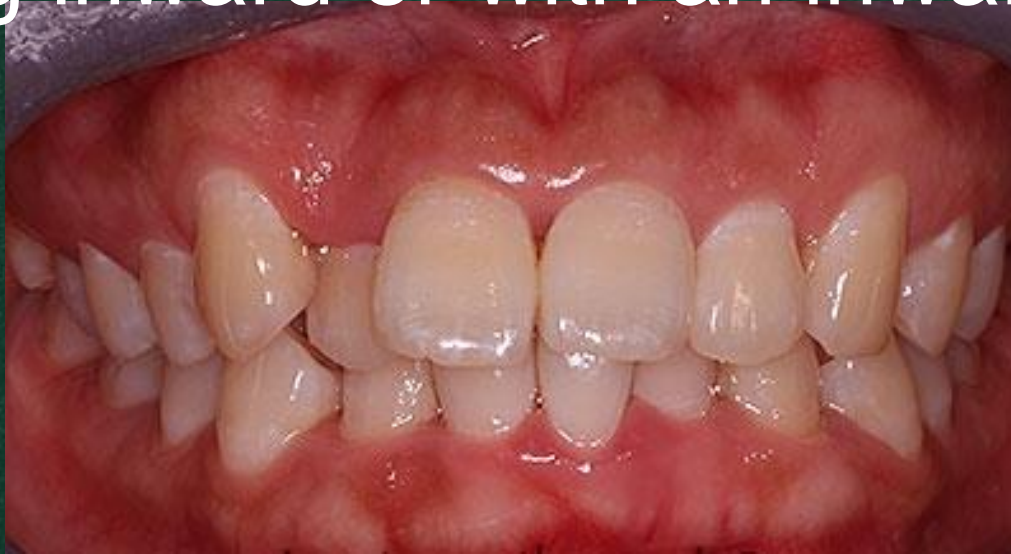Overjet



Overjet of 5 mm or more, suggesting Angle's Class II malocclusion,
increased Overjet mean (Class II)

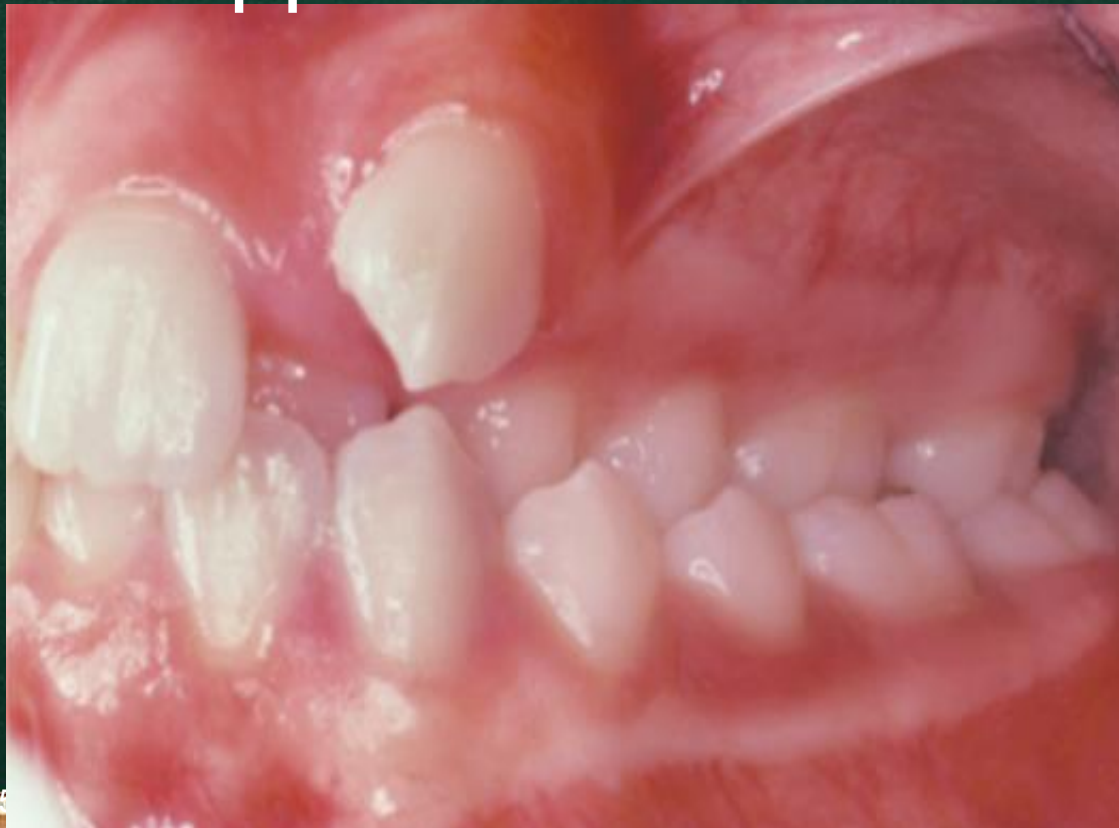Instanding tooth

Growing inward or with an inward tendency



cross bite

occlusal irregularity where a tooth (or teeth) has a more buccal or lingual position than its corresponding antagonist tooth in the upper or lower



Crossbite

No. of teeth

position

Single tooth Group of teeth

Anterior crossbite

posterior crossbite

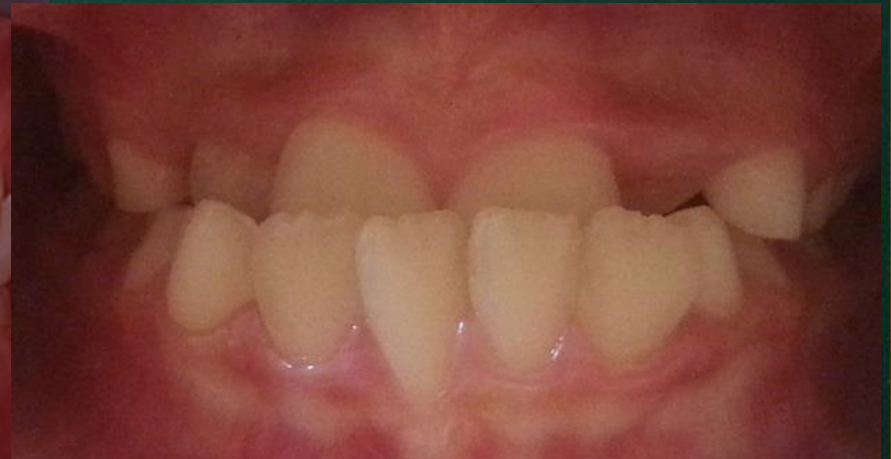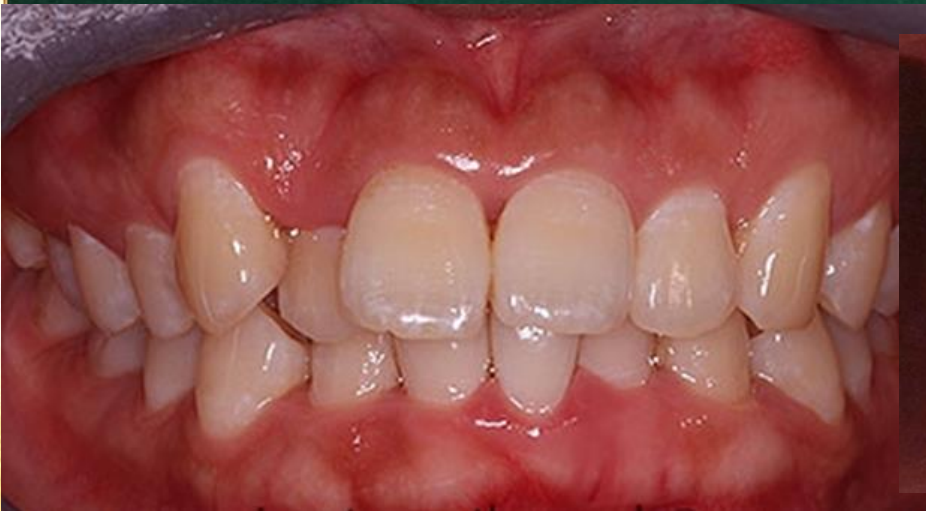unilateral crossbite bilateral crossbite

Crossbite

No. of teeth

Single tooth

Group of teeth



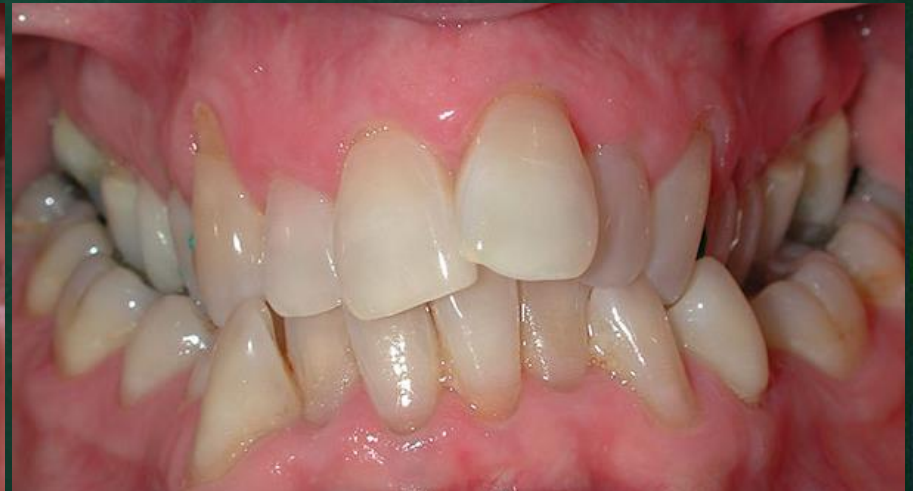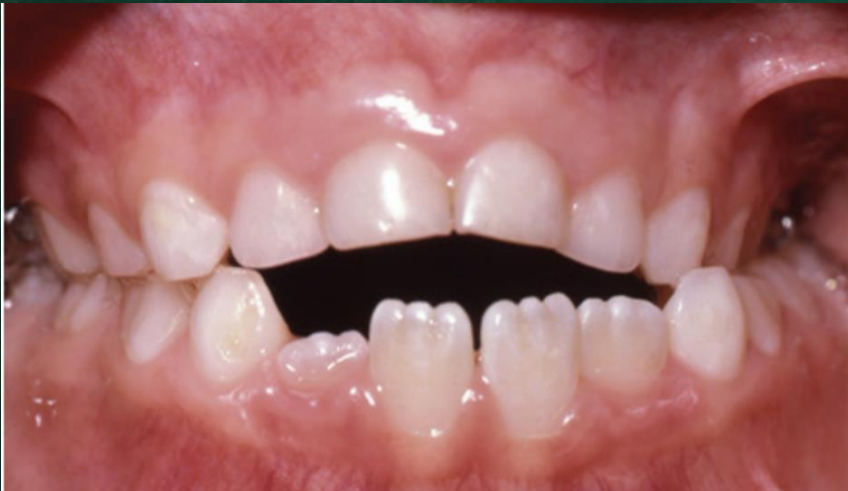Crossbite

posterior crossbite

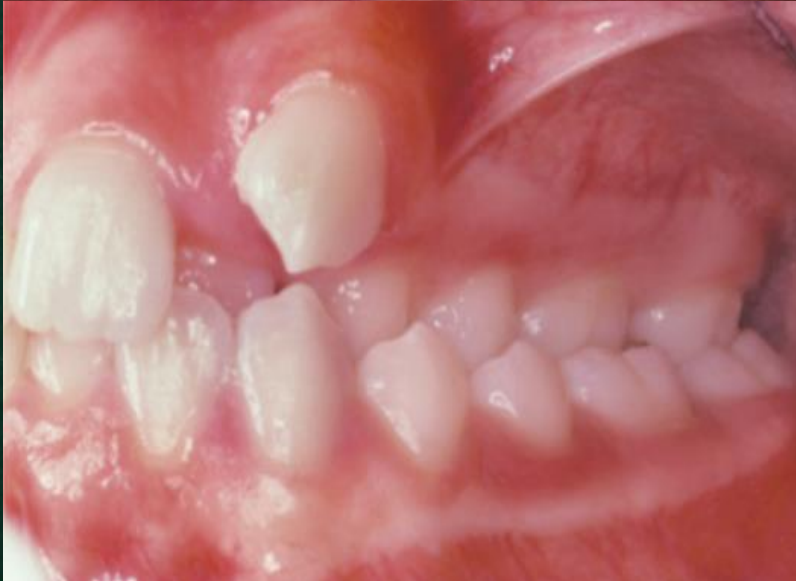
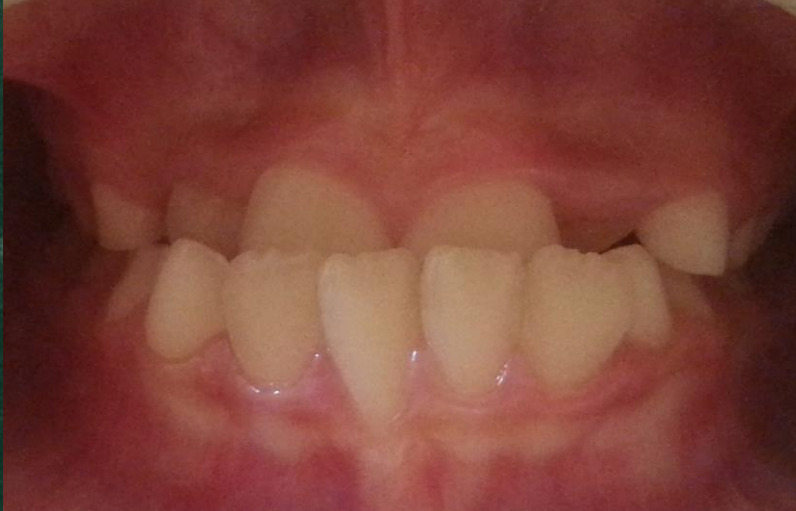
unilateral crossbite

bilateral crossbite



Crossbite position



- Anterior crossbite
- posterior crossbite



**PLEASE
NOTE:**

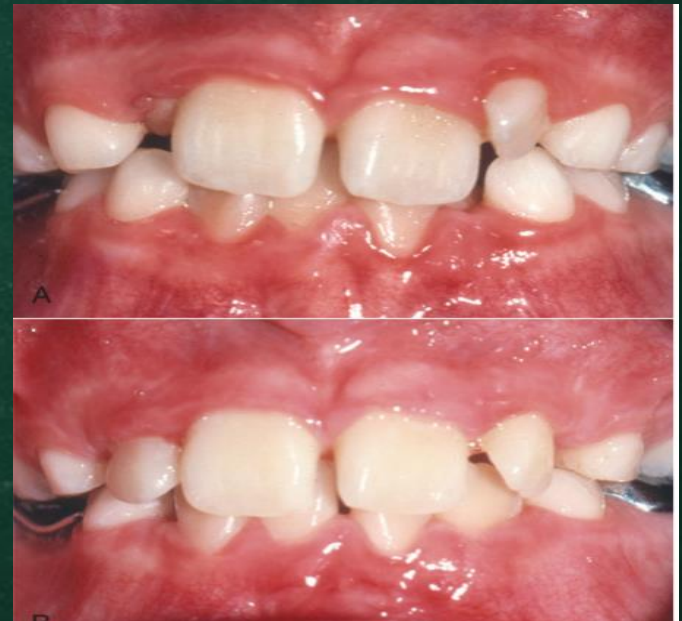Clinical consideration

Crossbite should be treated once it diagnosed, why ???

**PLEASE
NOTE:**

Clinical consideration

Crossbite should be treated once it diagnosed because
???

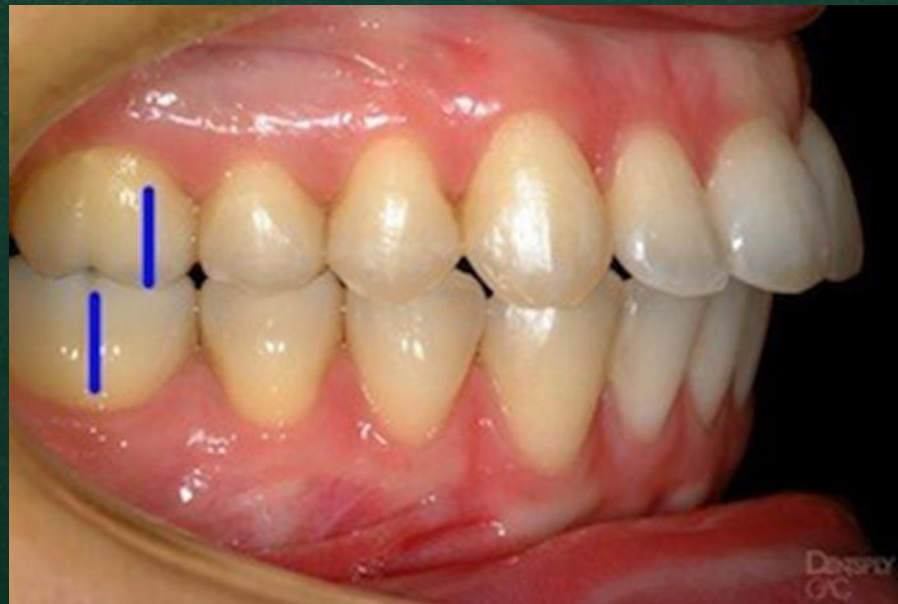

Tipping or Inclination

Buccal inclination or proclination (when the crown of the tooth is tipping outside the line of occlusion)

proclination

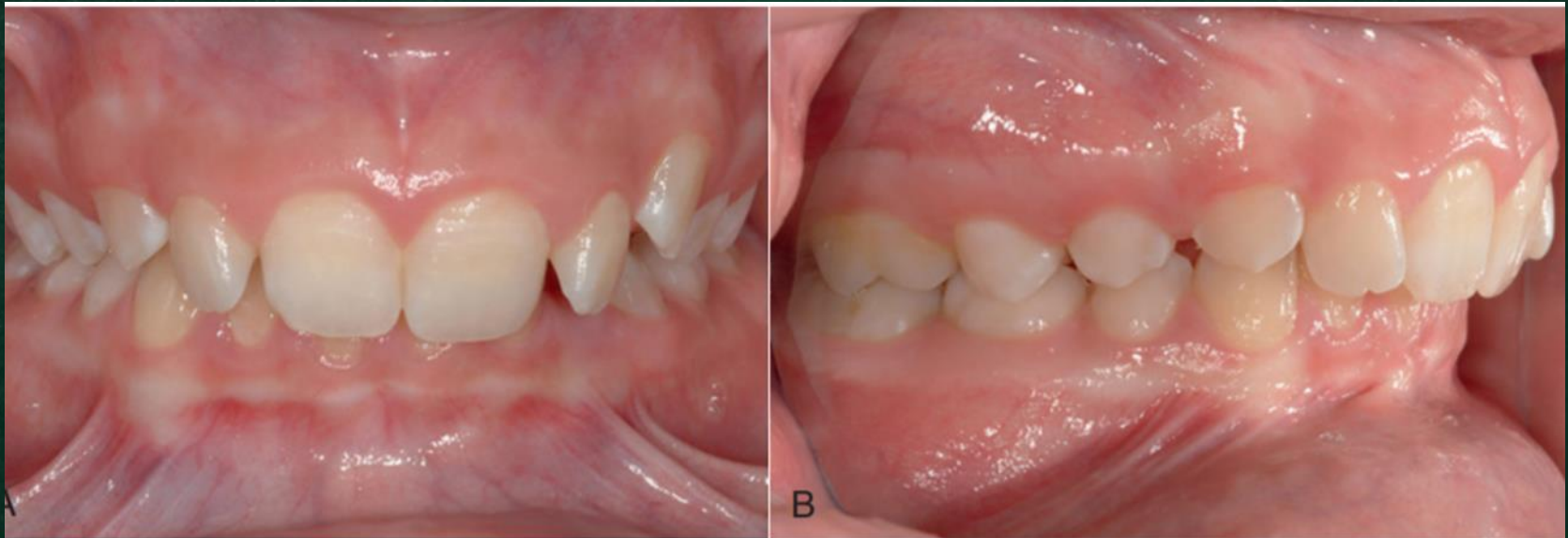Angle's Class II div. 1 With proclination of all the upper incisors



Tipping or Inclination

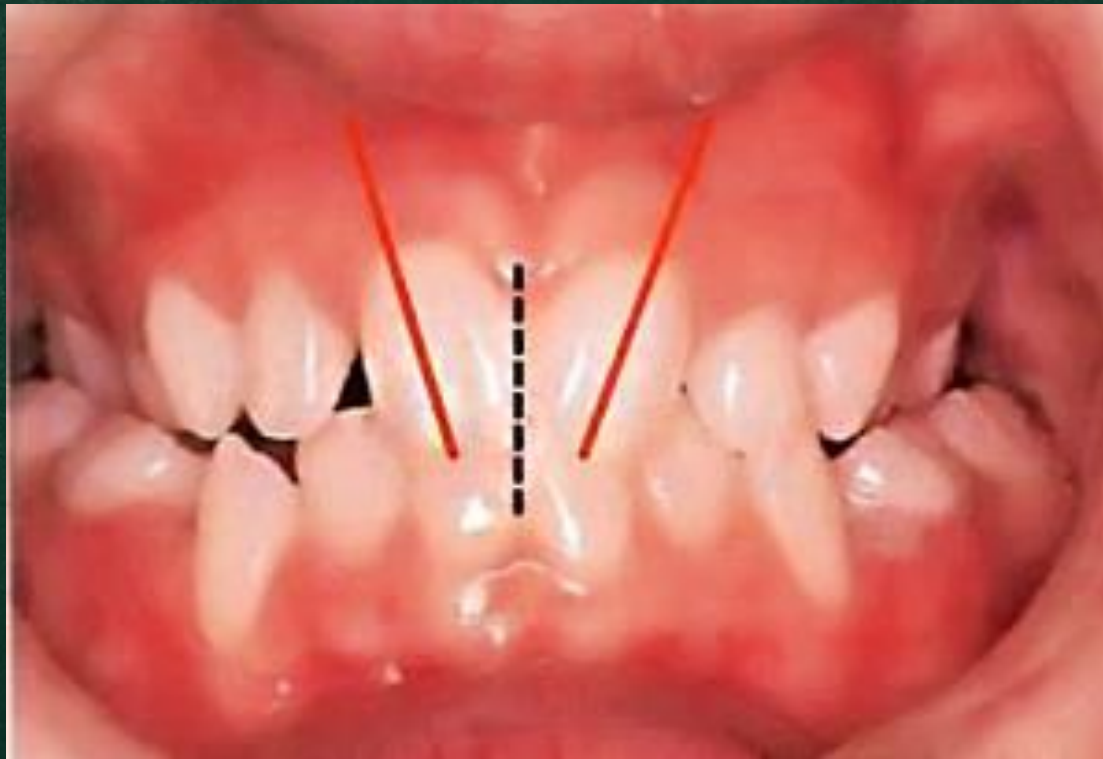Lingual inclination or—retroclination
(when the crown of the tooth is tipping
inside the line of occlusion)

Angle's Class II div. 2 With retroclination of the upper central incisors
retroclination



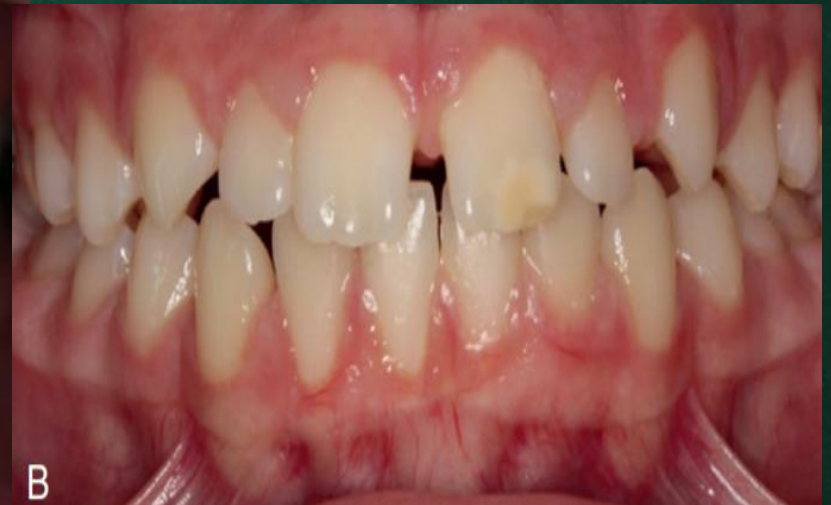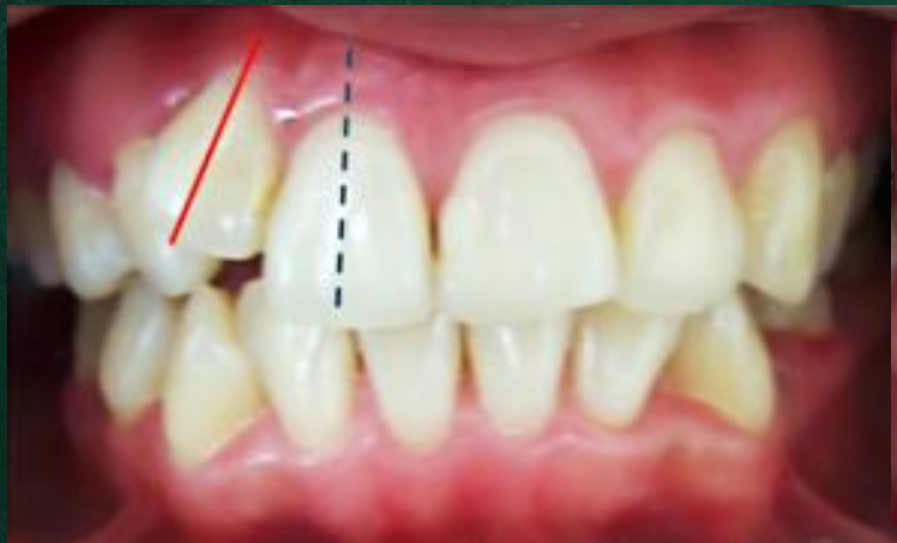Mesial inclination or tipping

crown tilted mesially or farther forward than normal



Distal inclination or tipping

crown tilted distally or backwards than normal

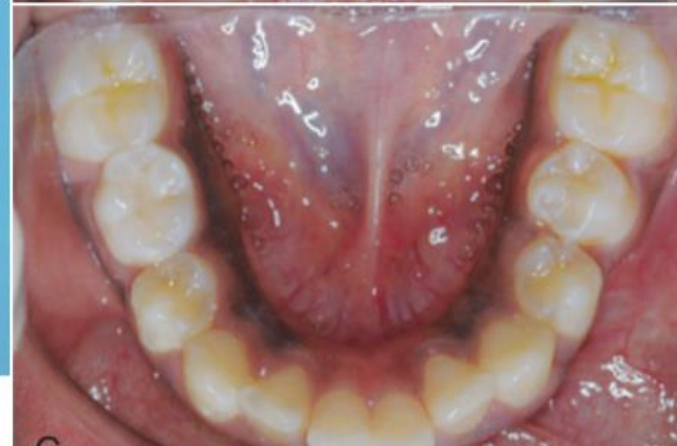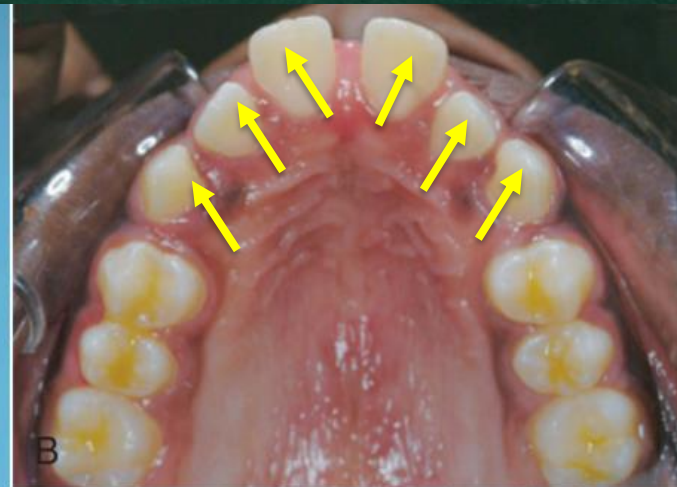

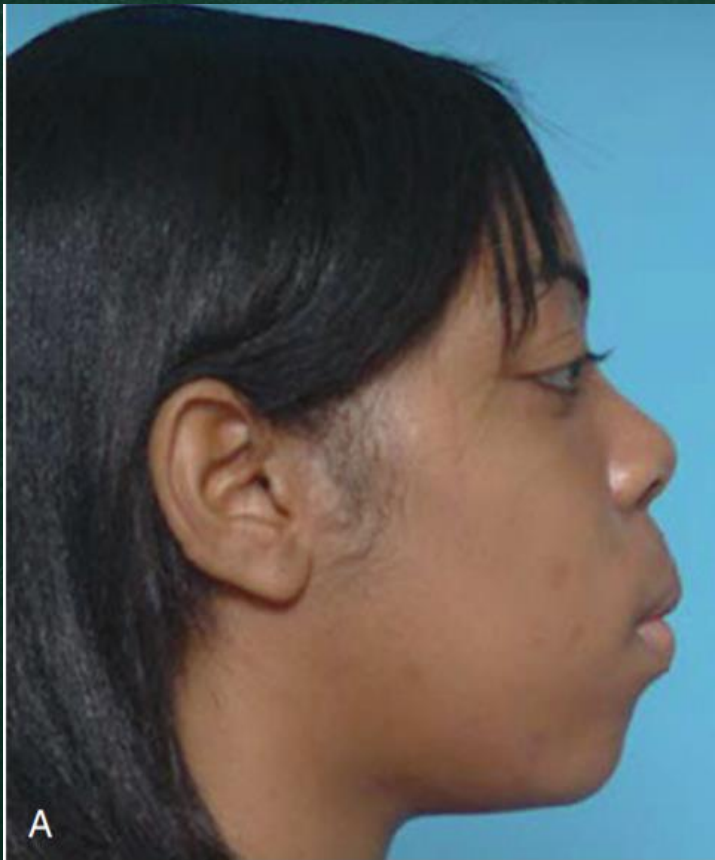
protrusion & intrusion
DENTAL & SKELETAL

Procination (dental)

common

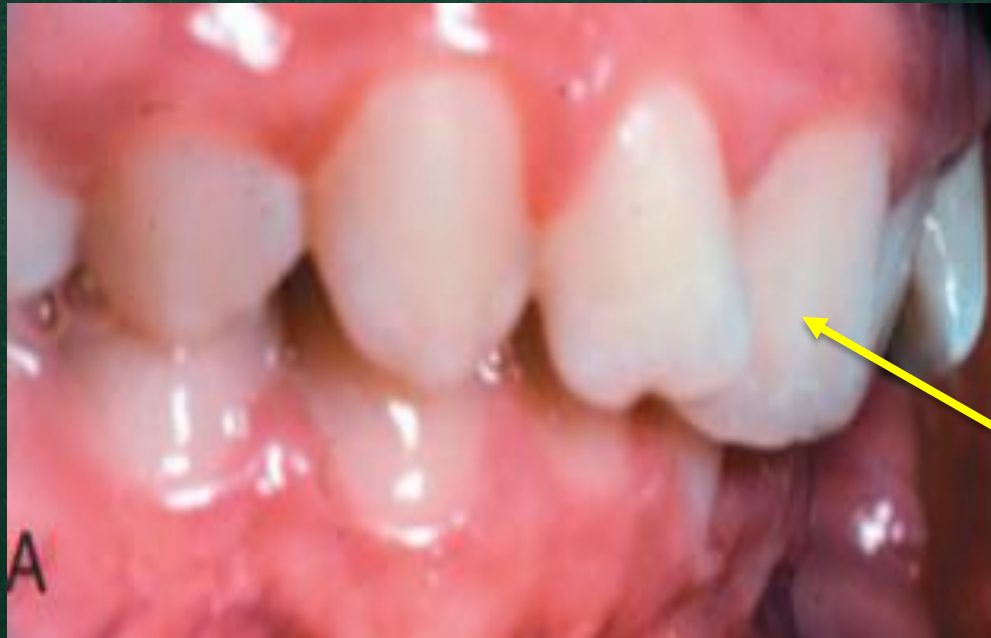if the incisors are positioned facially (proclined)



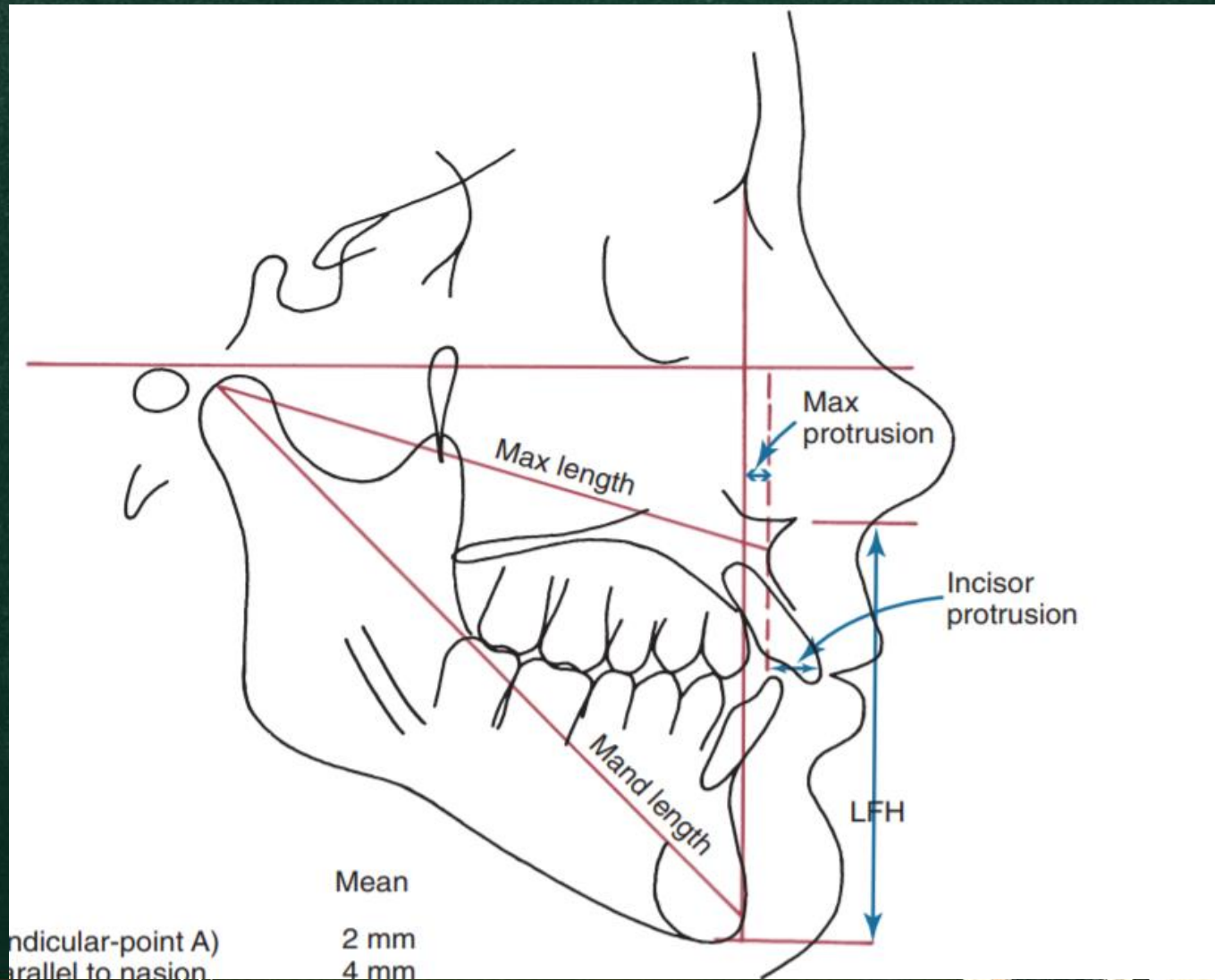
Retroclination (dental)

Rare

if the incisors are positioned lingually (retroclined)



Protrusion (dental & skeletal)

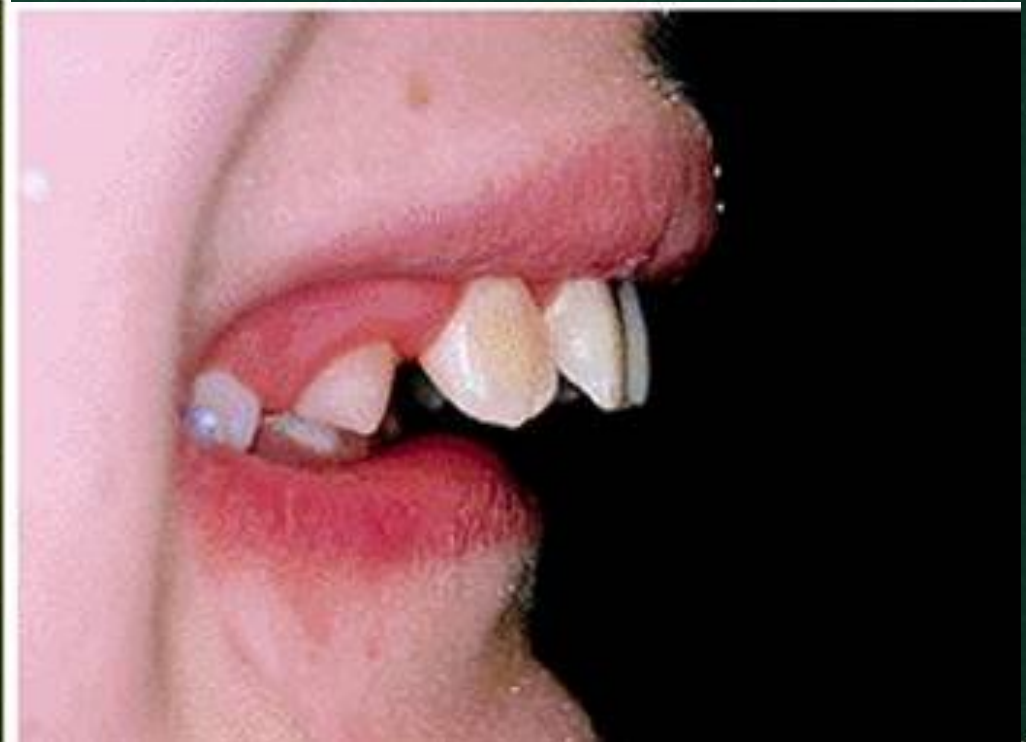
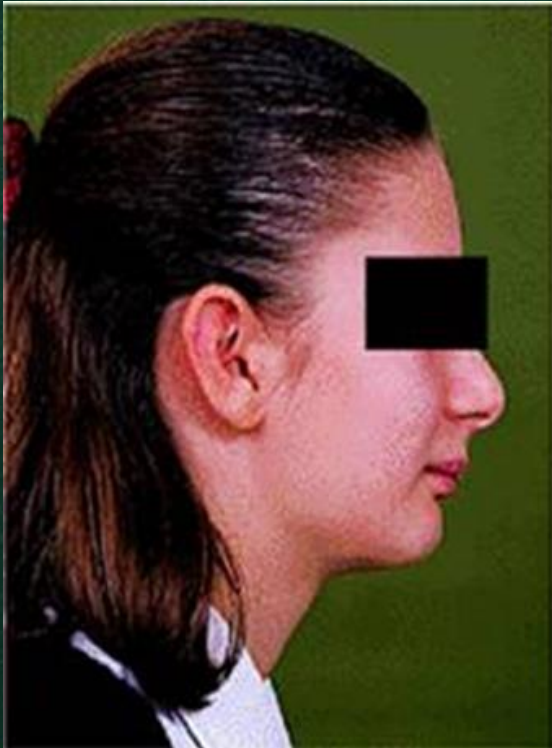
Mandibular-point A)
parallel to nasion

Mean
2 mm
4 mm

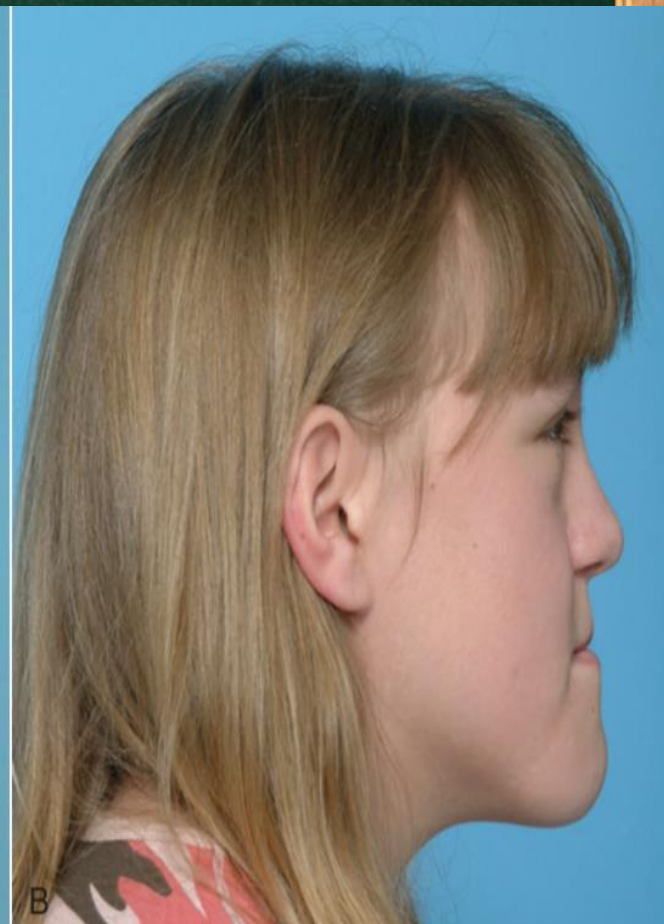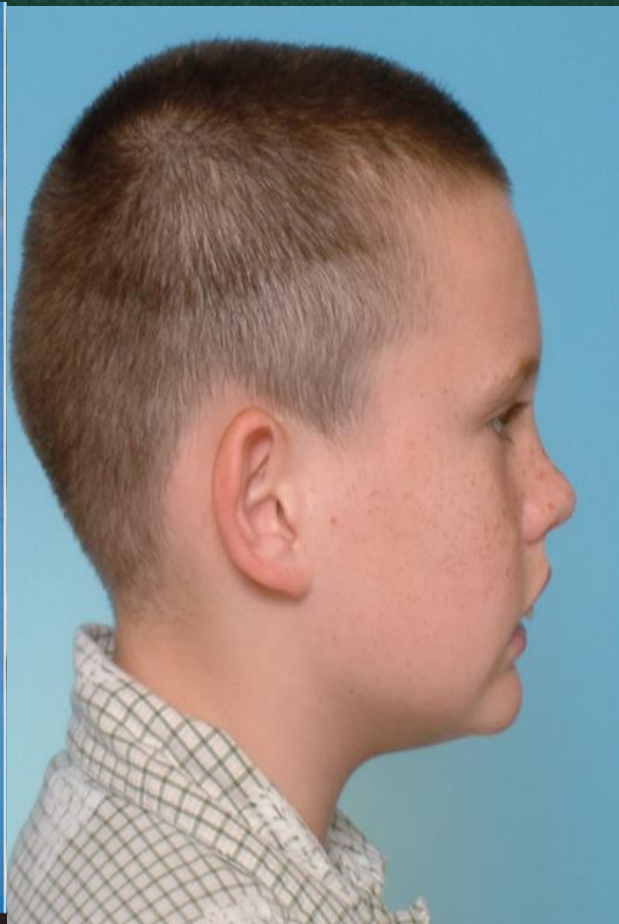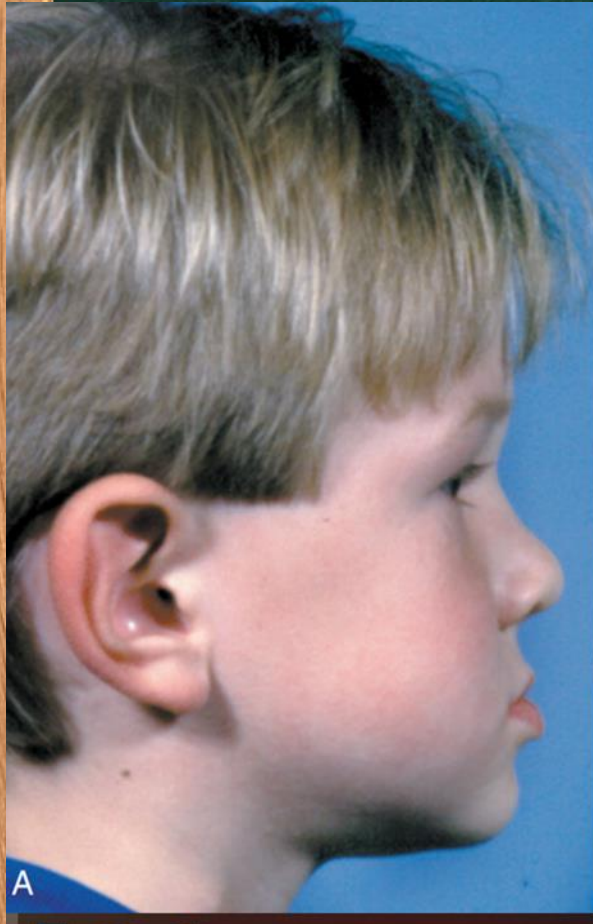Skeletal protrusion

Now we are talking about the dentoalveolar (skeletal problem)



Skeletal retrusion

Now we are talking about the dentoalveolar (skeletal problem)





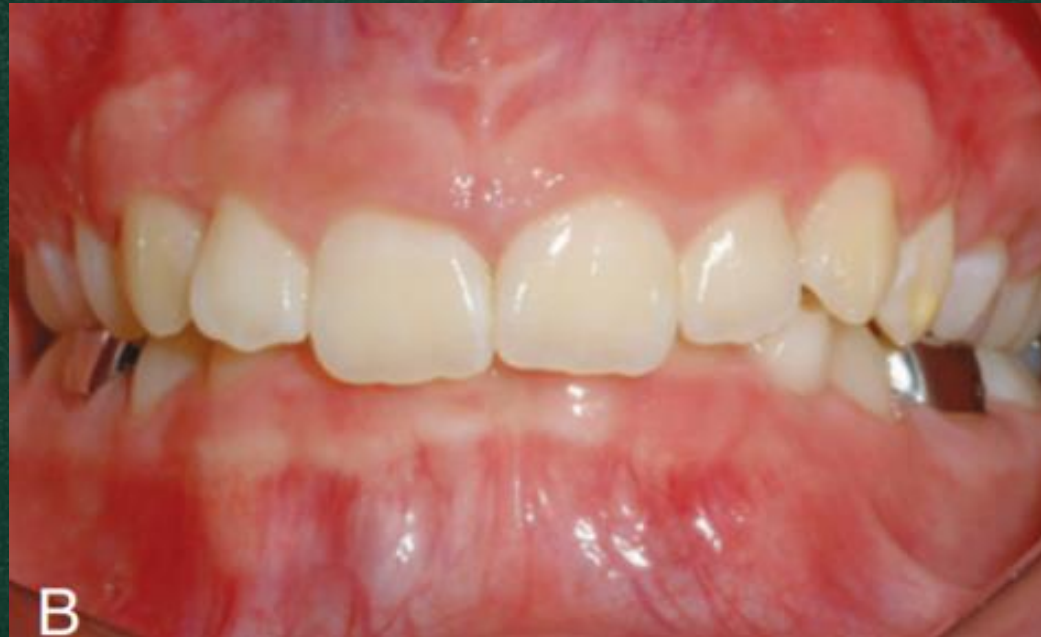**PLEASE
NOTE:**

Clinical consideration

Severe dental protrusion or retrusion, which also are complex treatment problems, should be recognized during the facial profile analysis.

The urgency for treating these problems usually depends on the **esthetic** impact or, in the case of protrusion, **the potential for traumatic injury**. Otherwise, **they should be treated as noted earlier**

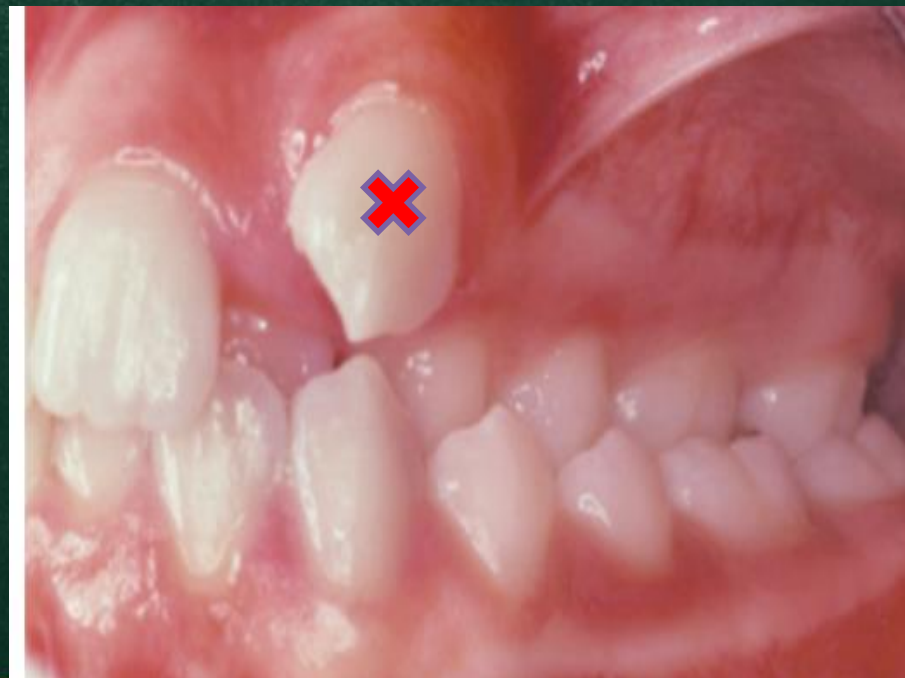
tooth displacement



There is moderate maxillary incisor crowding, with the midline off due to **displacement of the maxillary incisors**. The maxillary incisors are tipped lingually, there is minimal overjet despite Class II buccal segments, and overbite is excessive

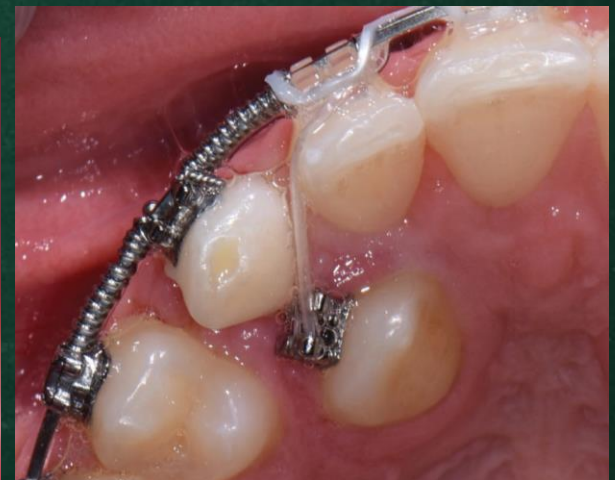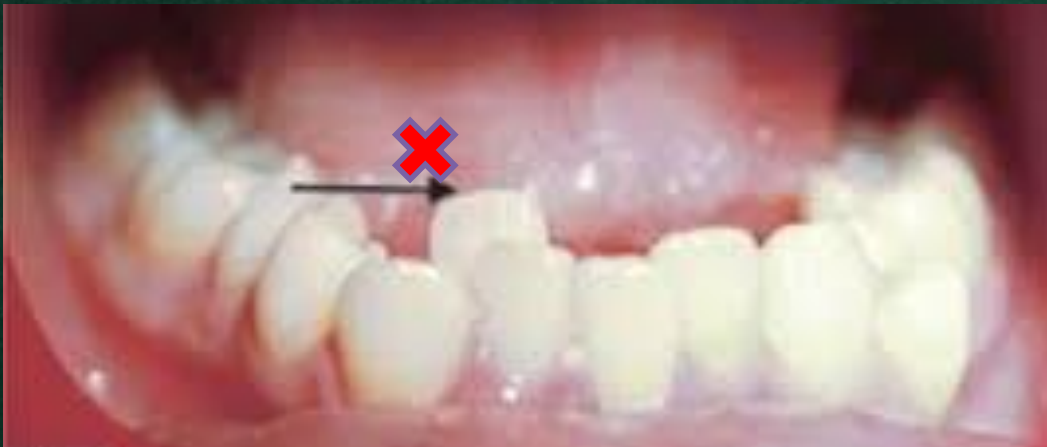Displacement

Buccal displacement—tooth that is bodily moved in labial/buccal direction



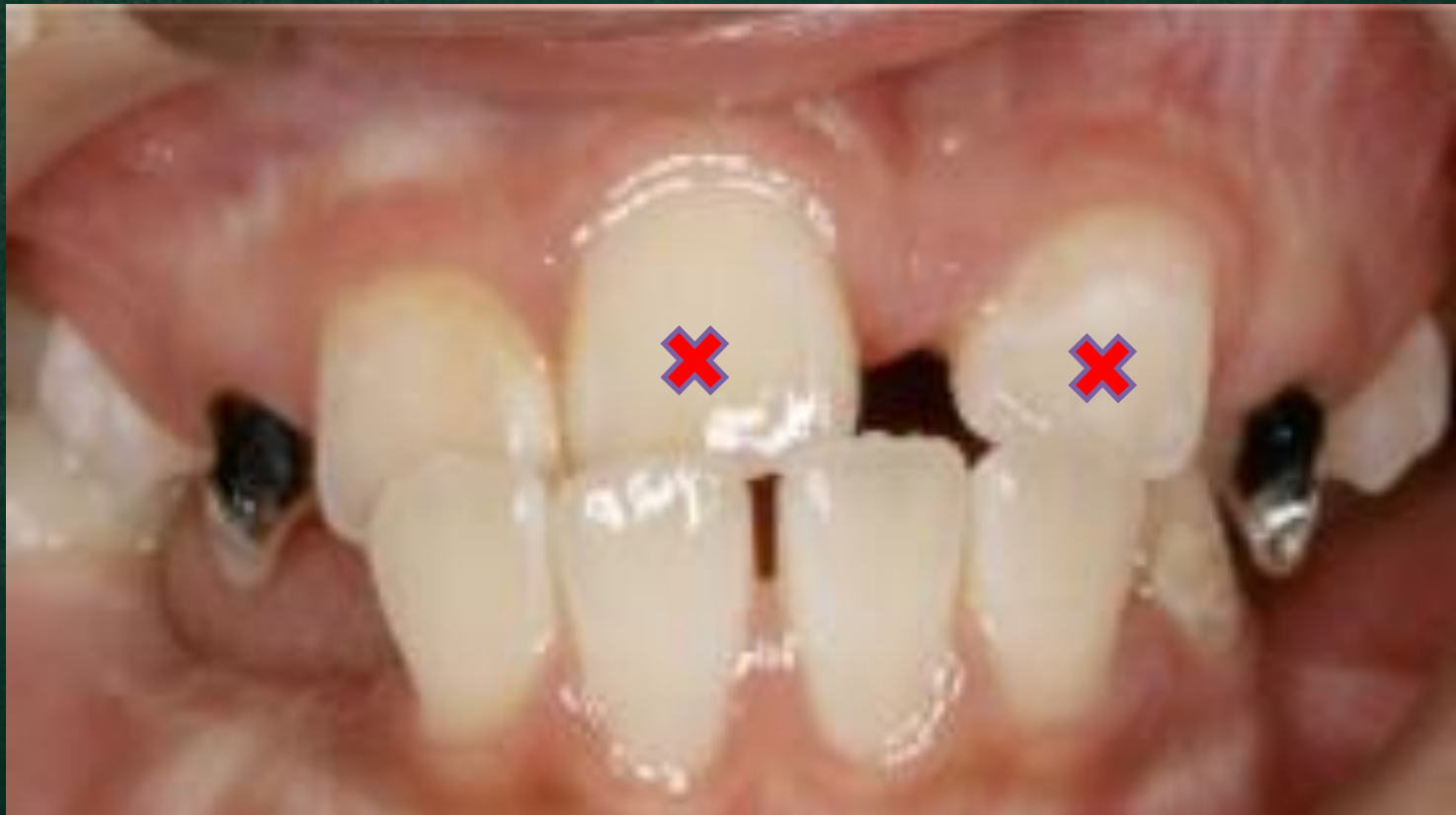Displacement

Lingual or palatal displacement—tooth that is **bodily** moved in lingual or palatal direction **=** Instanding tooth



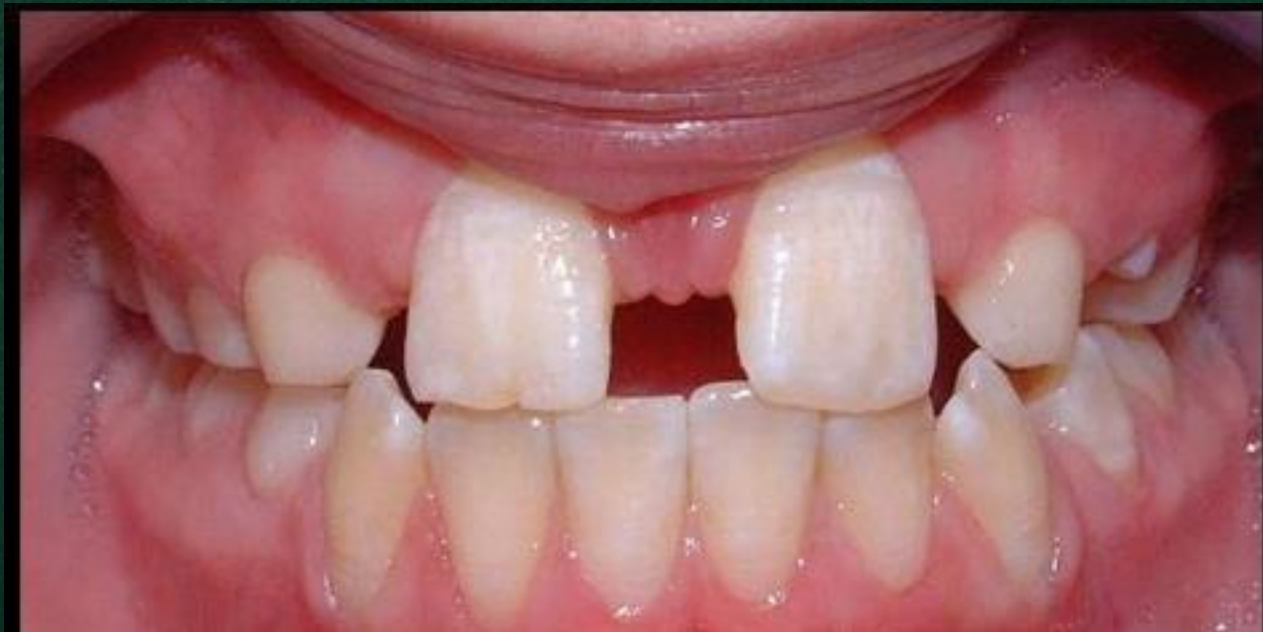Displacement

Mesial displacement—tooth that is bodily moved in mesial direction



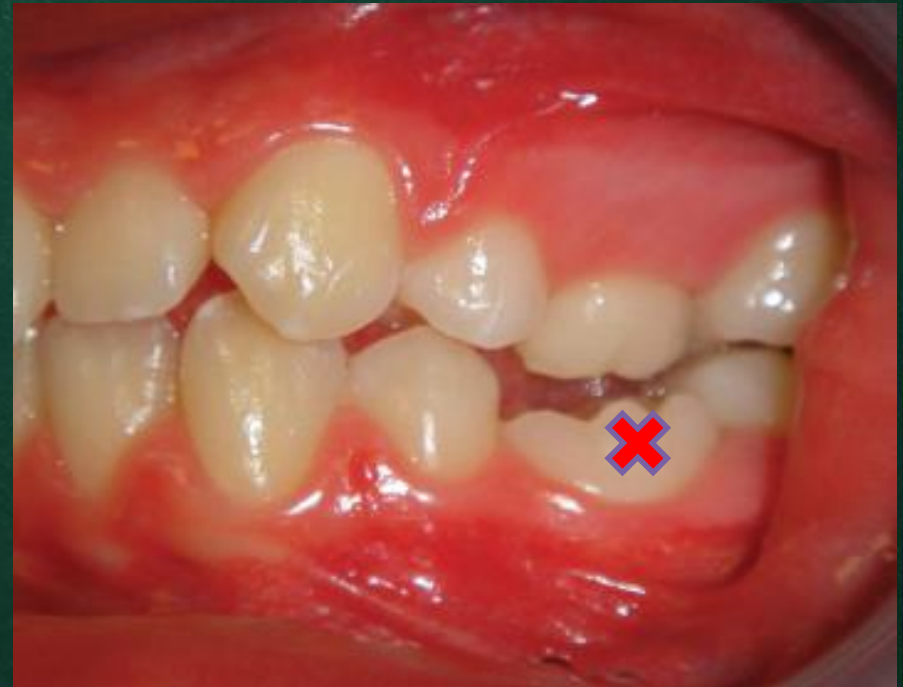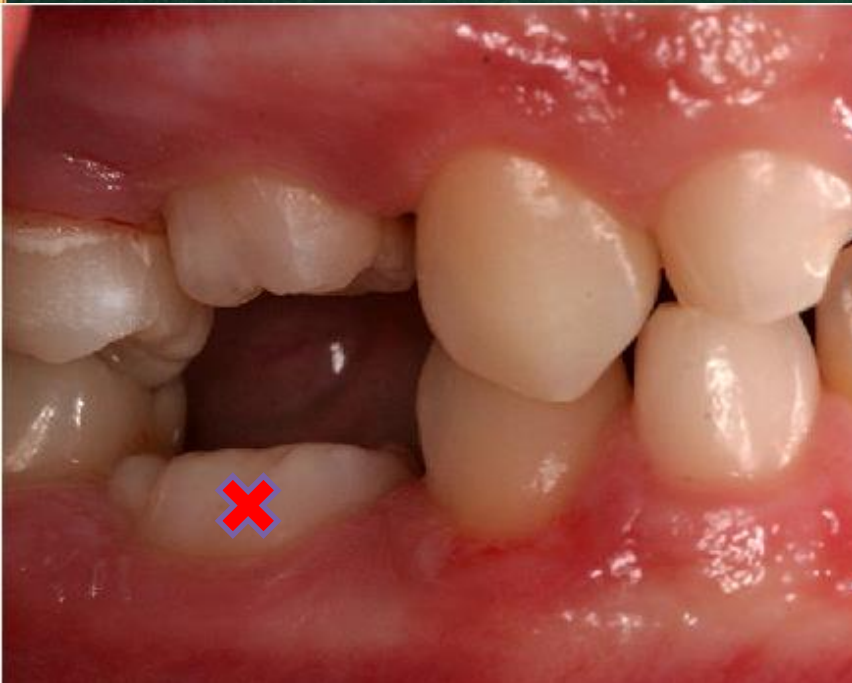Displacement

Distal displacement—tooth that is bodily moved in distal direction



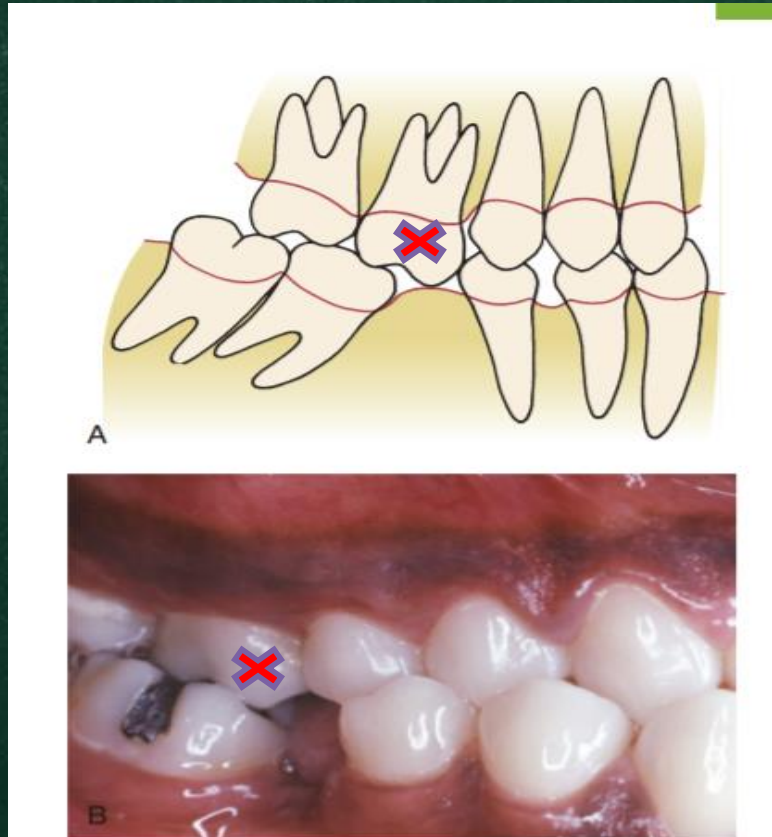
Infraversion or infraocclusion

this is a tooth that has **not erupted enough** as compared to other teeth in the arch



Supraverasion or supraocclusion

this is a tooth that has **overerupted** as compared to other teeth in the arch.

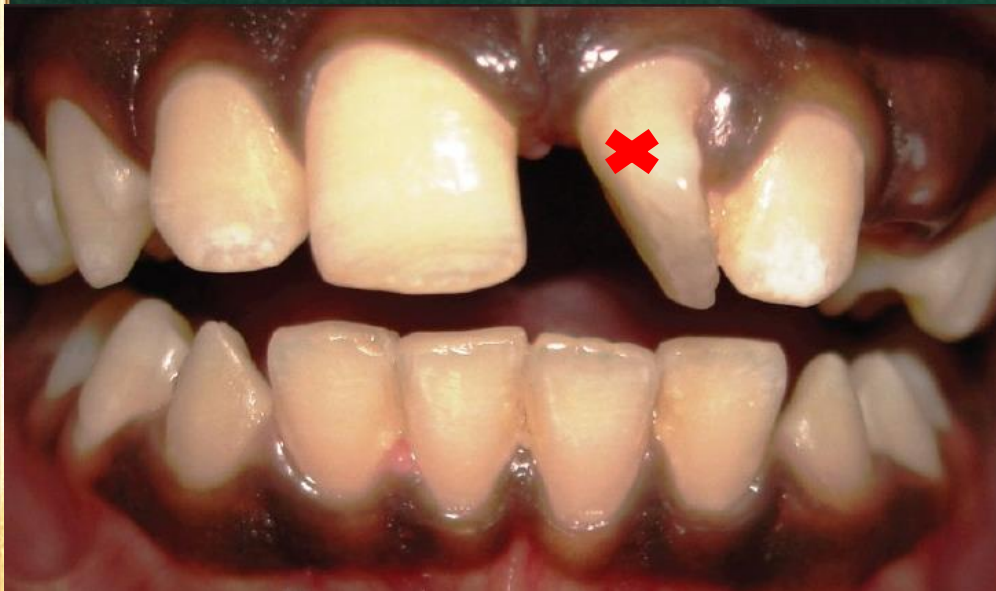

Rotation

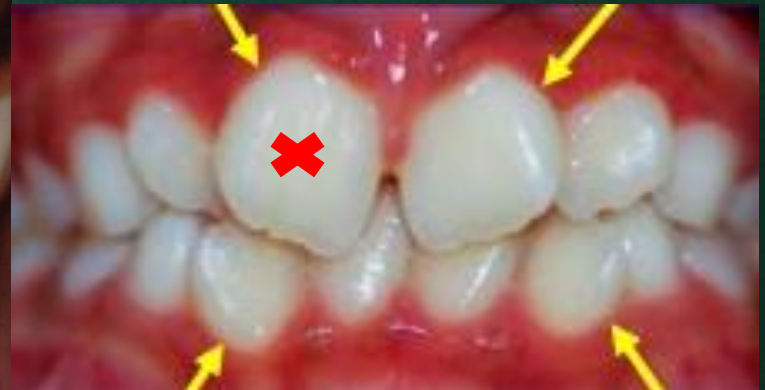tooth movement around its long axis

degree of rotation

Sever $> 90^\circ$

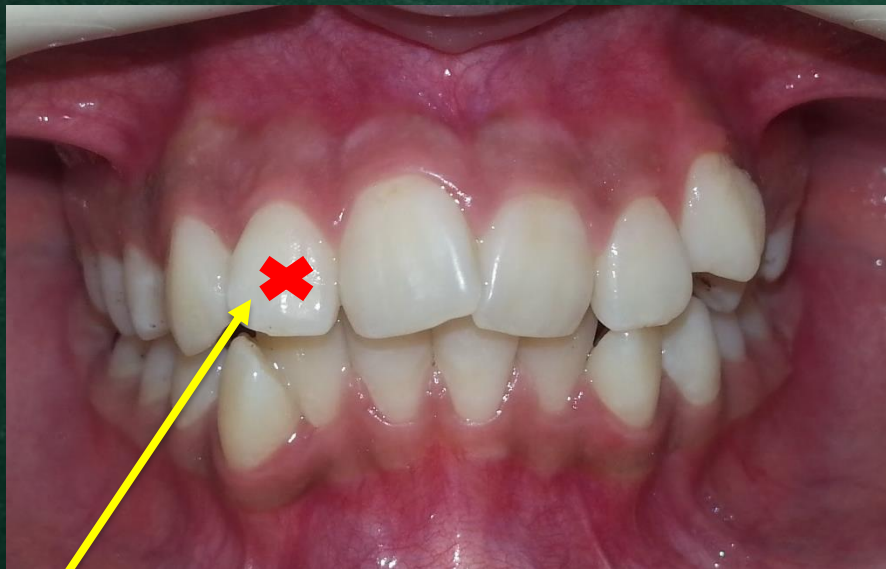

Mild

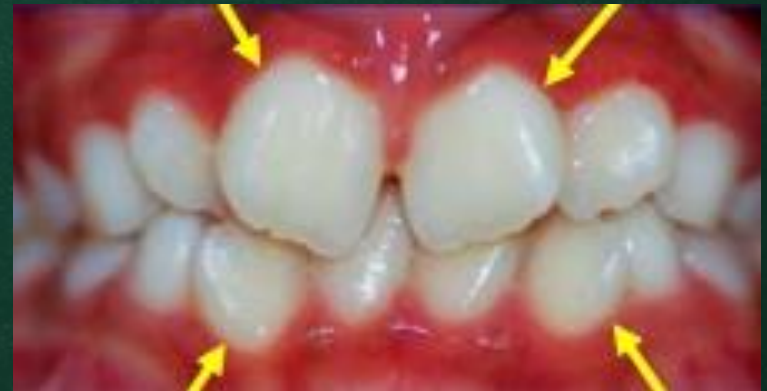

Rotation

Mesiolingual or distobuccal rotation—tooth that has mesial aspect more lingually placed

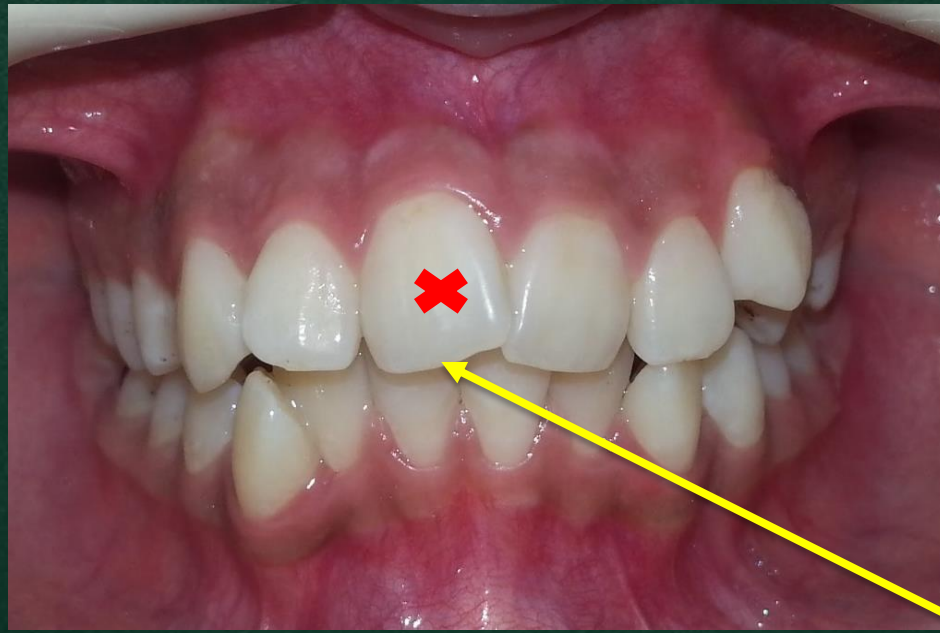


Mesiolingual



Rotation

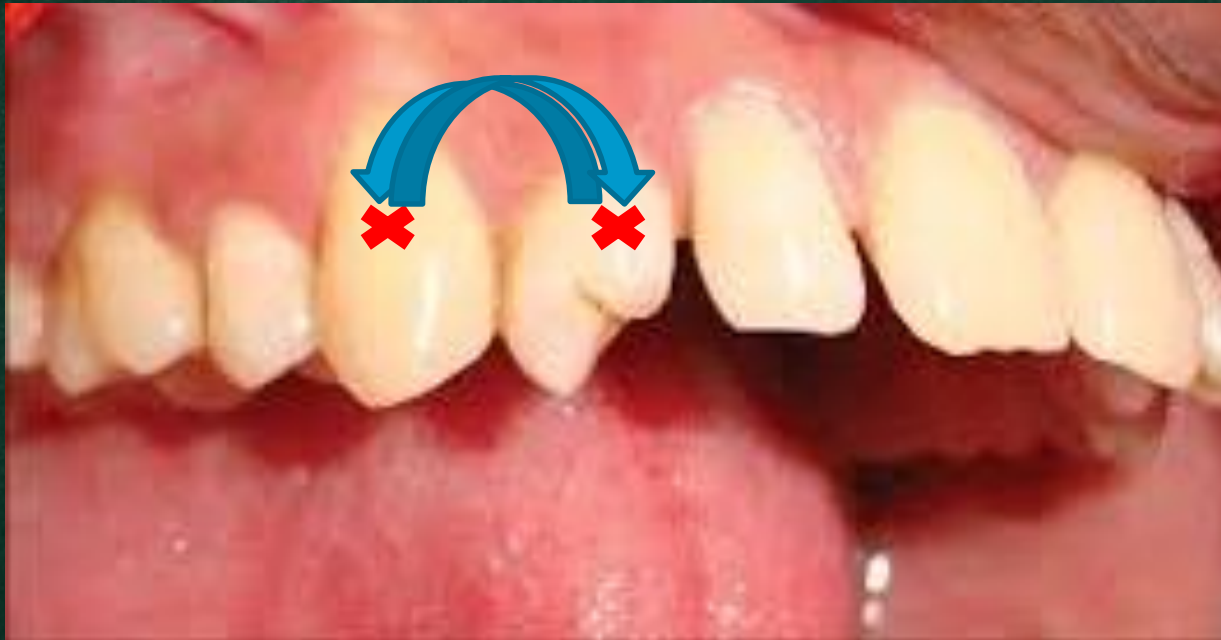Distolingual or mesiobuccal rotation—tooth that has moved around its long axis so that distal aspect is more lingually placed.



mesiobuccal

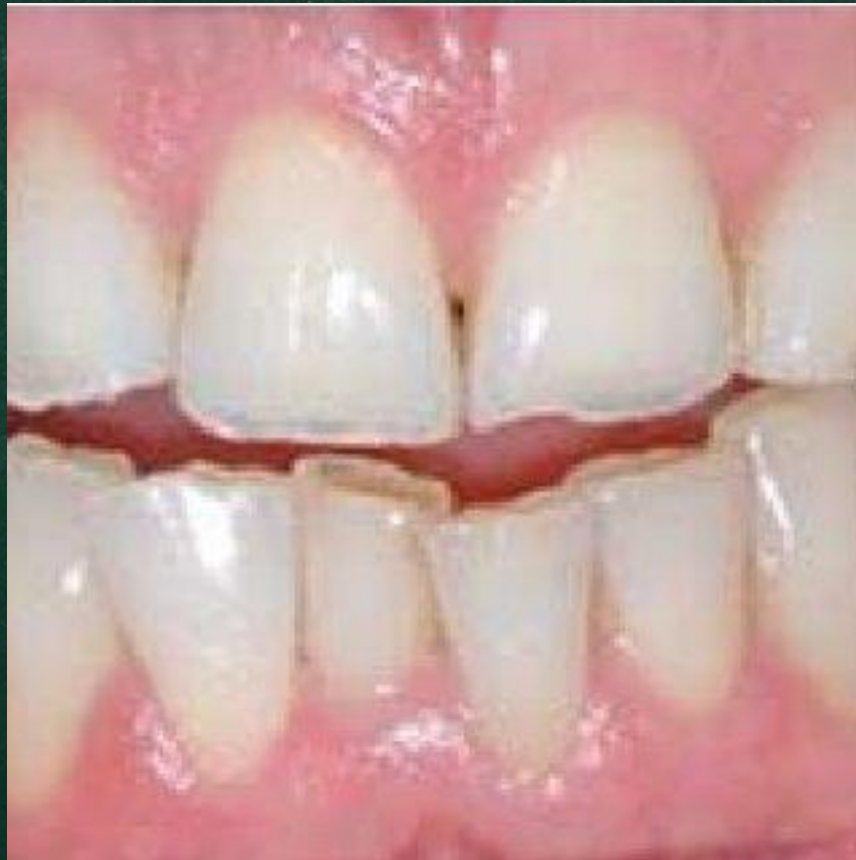Transposition

where the teeth have
exchanged/interchanged their
positions



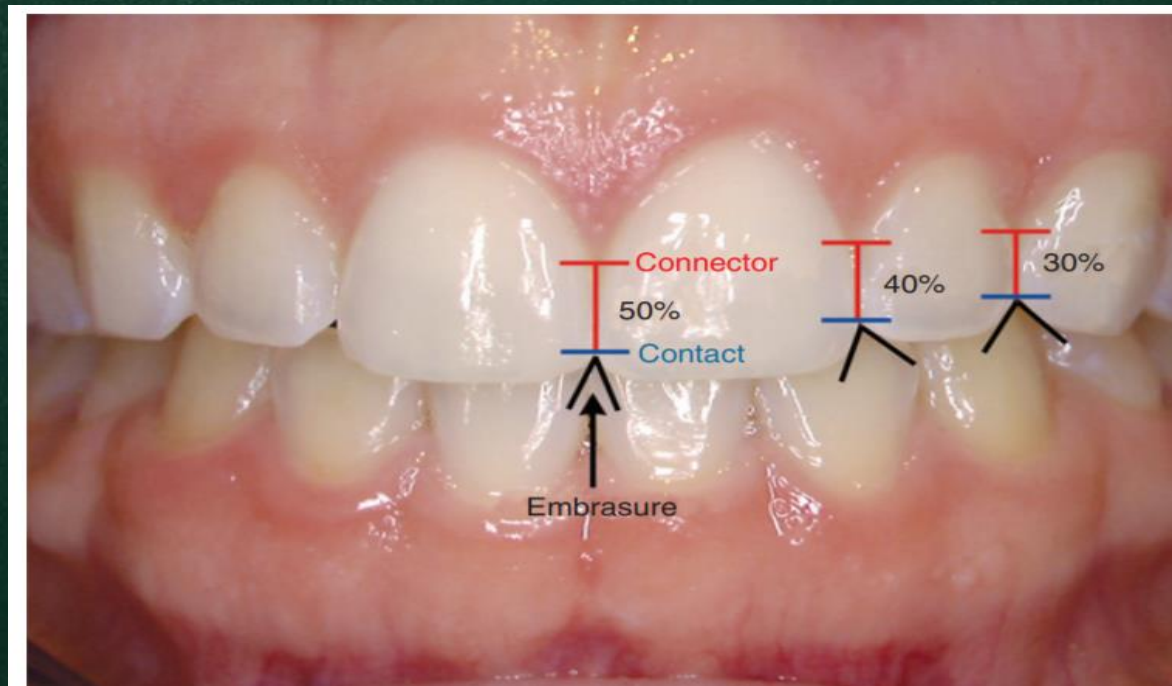
Imbrication

Imbrication denotes especially lower incisors arranged in an irregular manner within the arch due to lack of space.

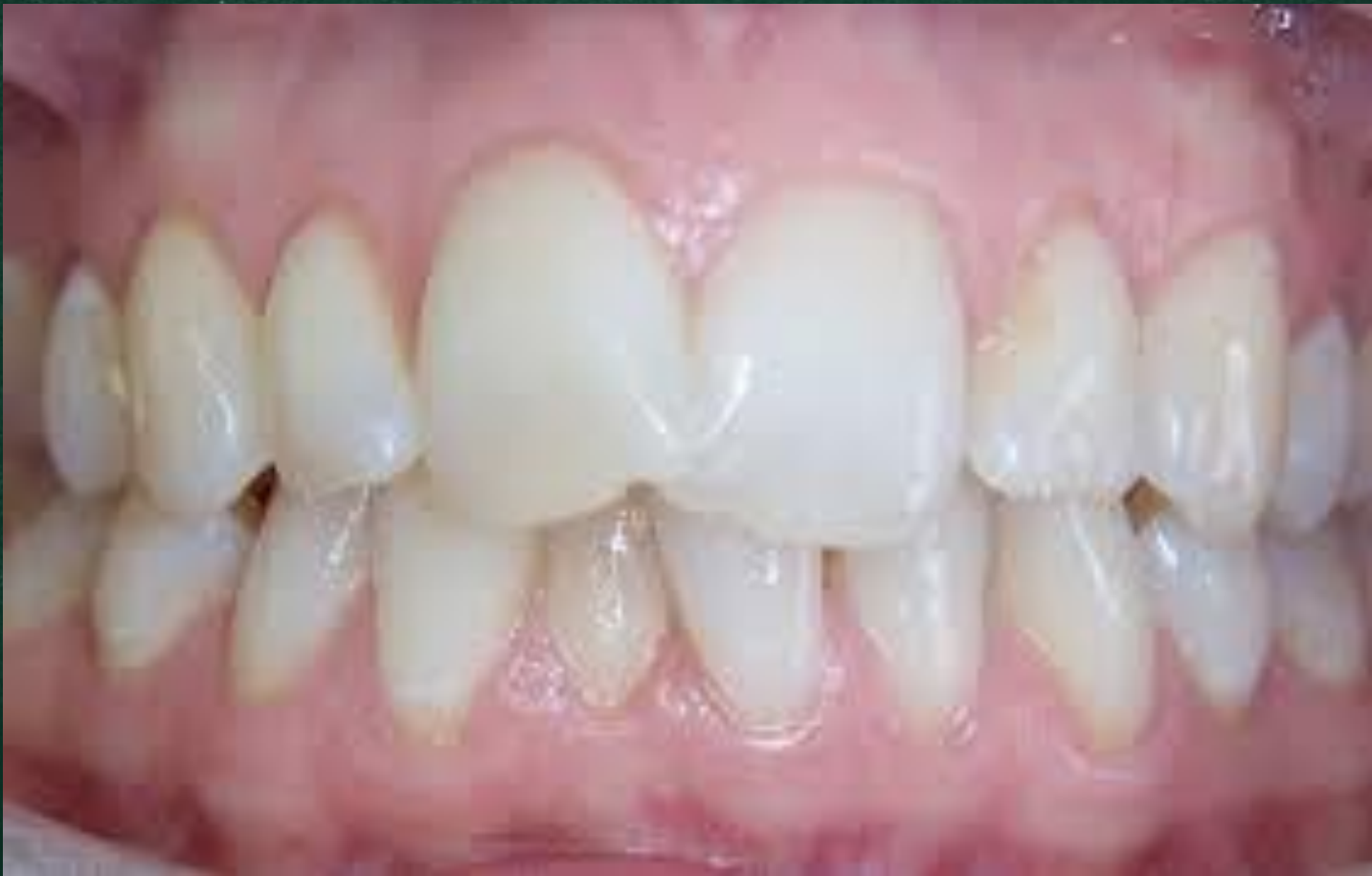

overlap

Overlap: In a normally occluding dentition, the maxillary teeth are labial/buccal to the mandibular teeth.

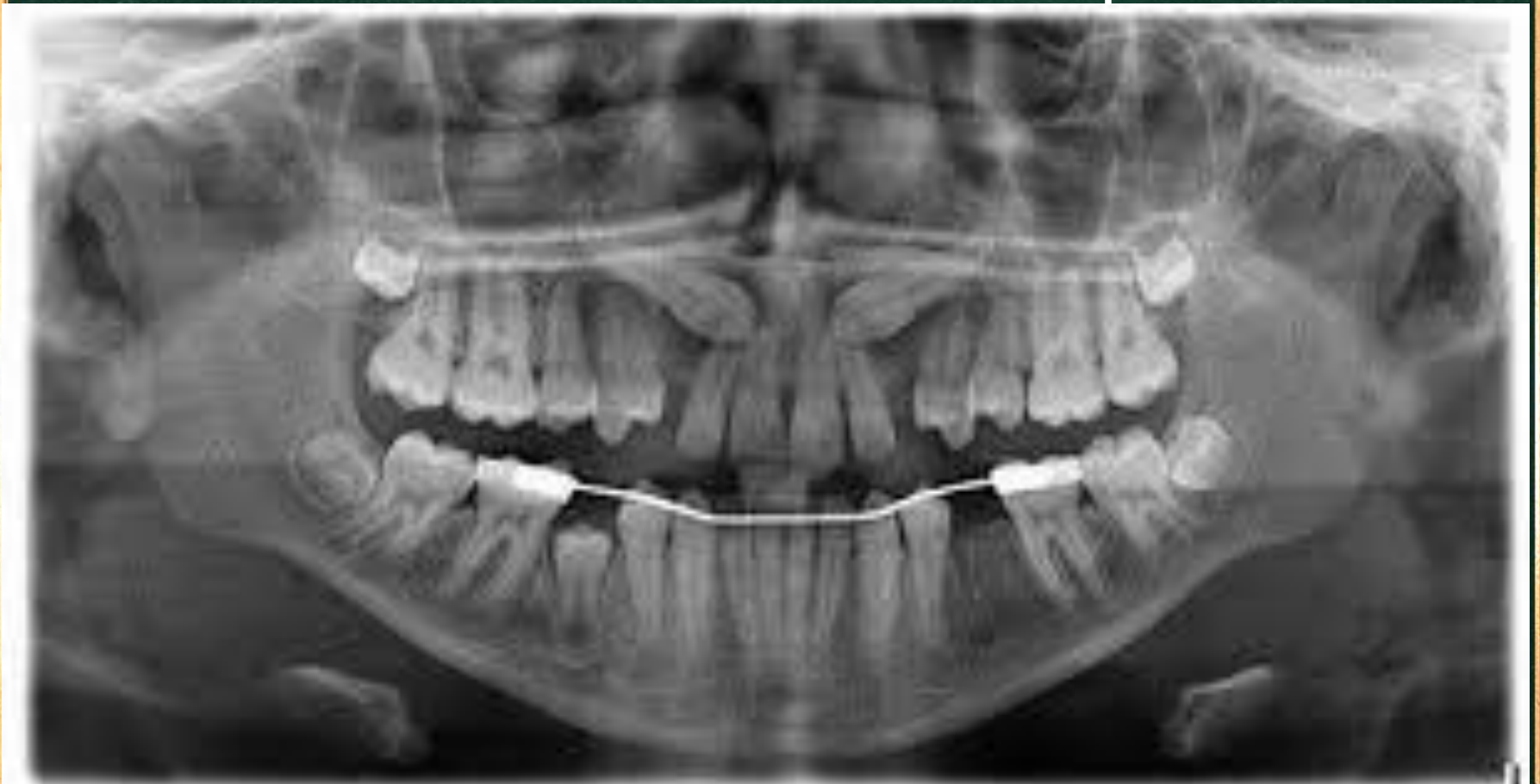

Overlap



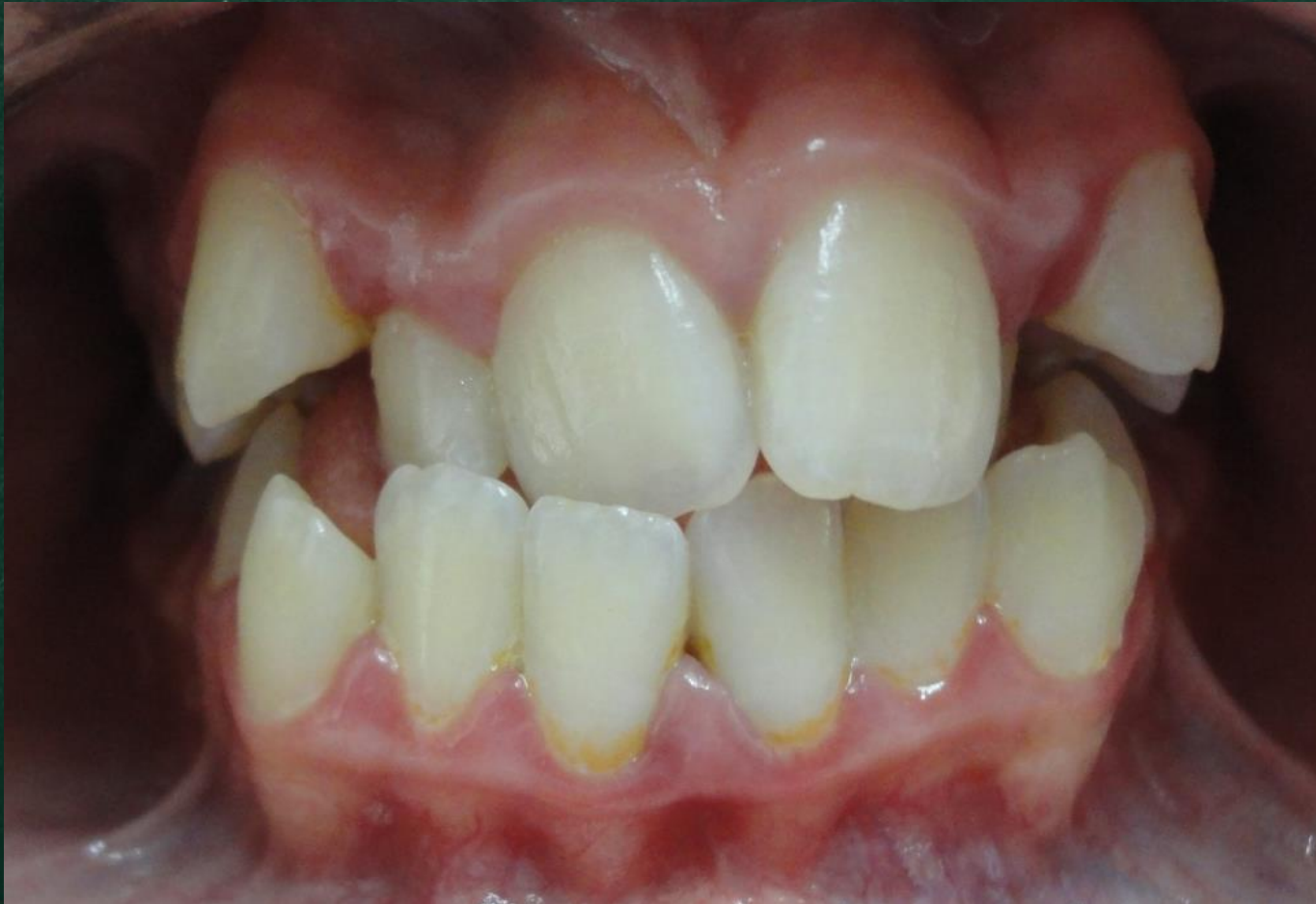impaction

Impacted teeth those teeth that fails to erupt into the dental arch within the expected time



Malposed tooth or teeth

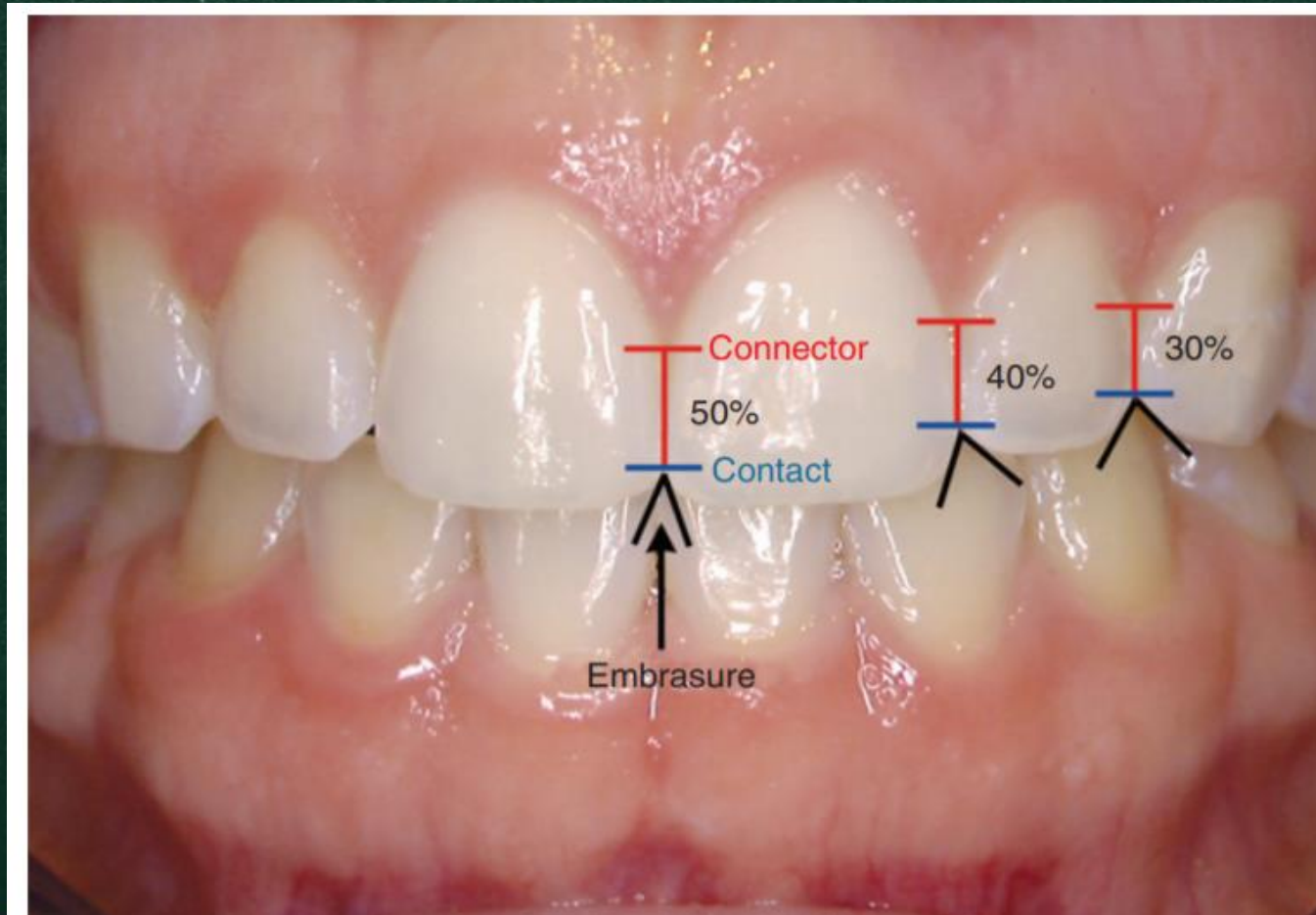
Ex. Buccaly malposed canine



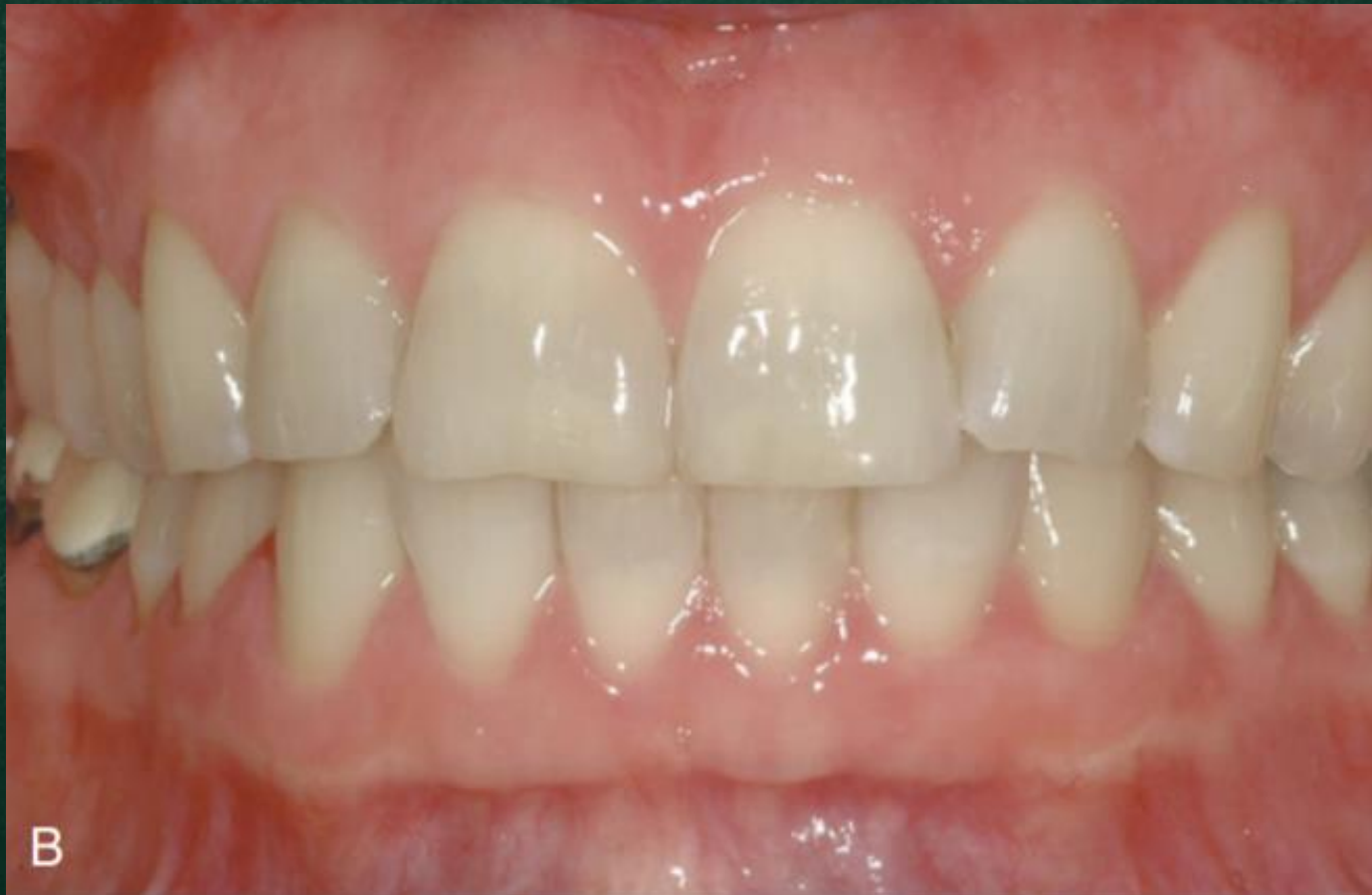وَكُلُّ شَيْءٍ عِنْدَهُ بِمِقْدَارٍ

{8 الرعد}

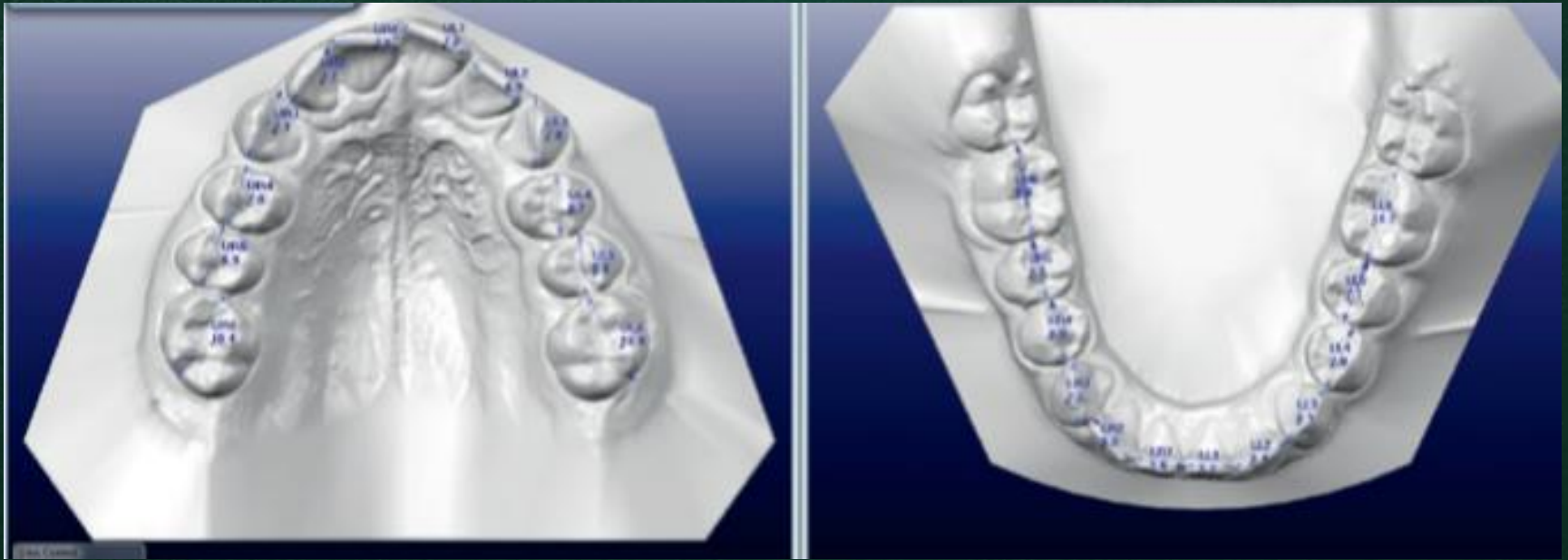
dental midline



midline deviation (shifting) or off midline



A tooth size-arch length discrepancy (TSALD)



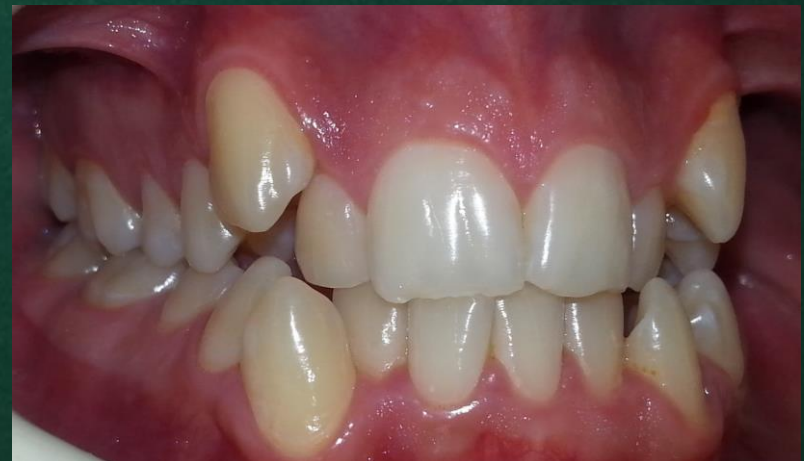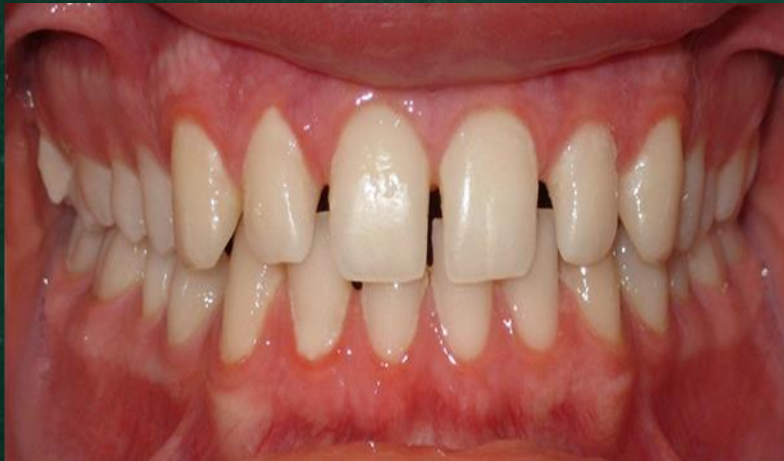A tooth size discrepancy

A tooth size discrepancy of less than **1.5 mm** is rarely significant, but larger discrepancies create treatment problems in achieving ideal interdigitation, overjet and overbite

A tooth size-arch length discrepancy (TSALD)

Spacing

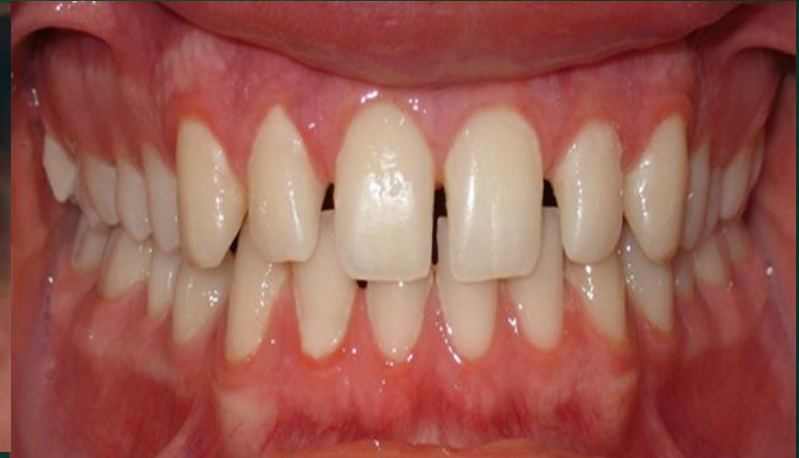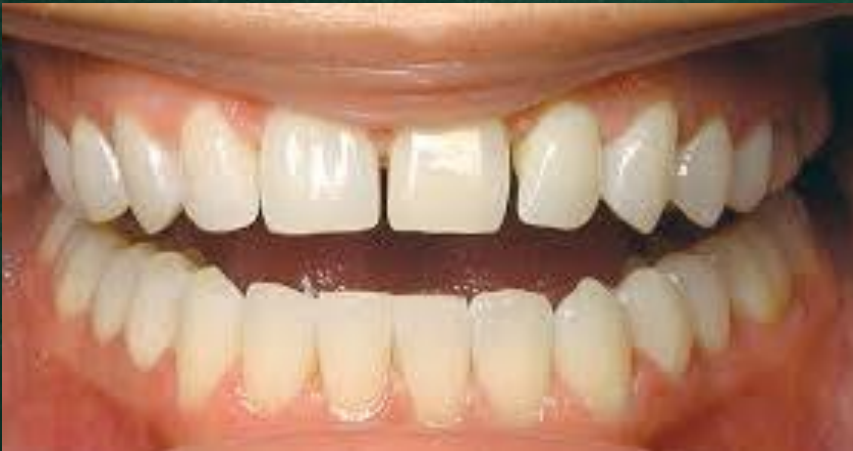crowding



Spacing

localized

generalized



Crowding

